Essentials of Dental Radiography and Radiology

THIRD EDITION

Eric Whaites

Foreword by R. A. Cawson

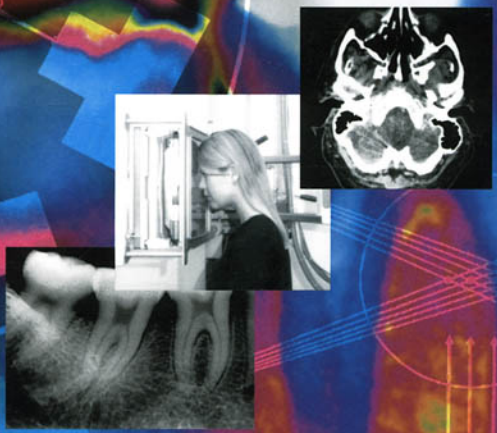

CHURCHILL LIVINGSTONE

Also available...

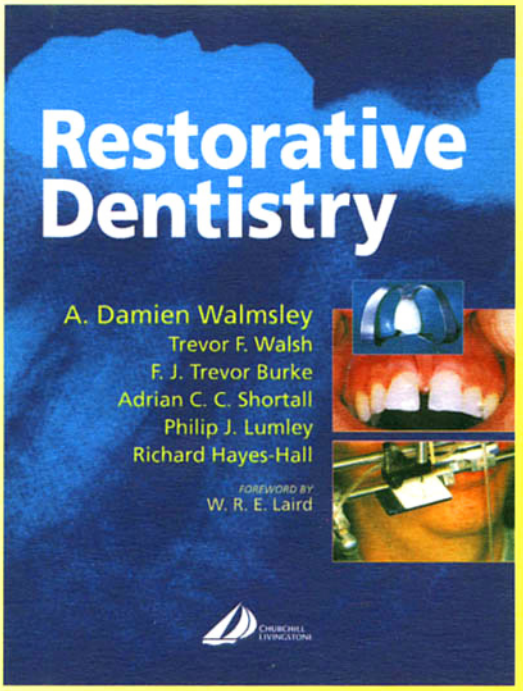

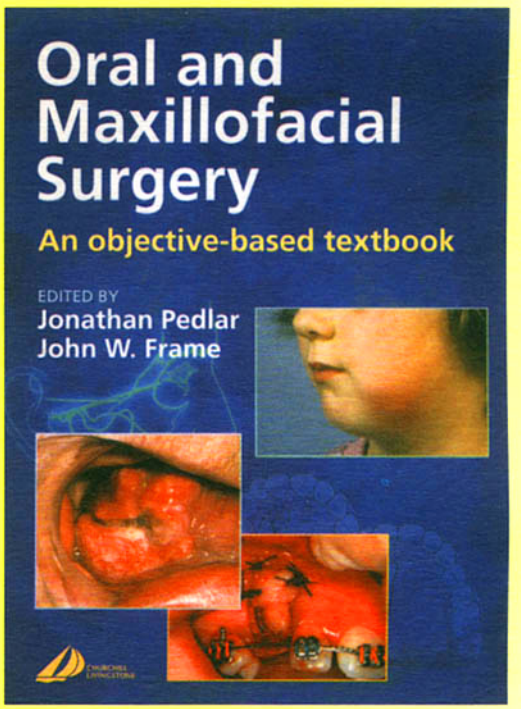

You can order these, or any other Elsevier Science title (Churchill Livingstone, Saunders, Mosby, Baillière Tindall, Butterworth-Heinemann), from your local bookshop, or, in case of difficulty, direct from us on:

EUROPE, MIDDLE EAST & AFRICA
Tel: +44 (0) 20 8308 5710
www.elsevierhealth.com

CANADA
Tel: +1 866 276 5533
www.elsevier.ca

AUSTRALIA
Tel: +61 (0) 2 9517 8999
www.elsevierhealth.com

USA
Tel: +1 800 545 2522
www.us.elsevierhealth.com

ELSEVIER SCIENCE

Essentials of Dental Radiography and Radiology

ЗНАНИЕ

Dedication
To Catriona, Stuart, Felicity and Claudia

Commissioning Editor: Micheal Parkinson
Project Development Manager: Jim Killgore
Project Manager: Frances Affleck
Designer: Erik Bigland

THIRD EDITION

Essentials of Dental Radiography and Radiology

WRITTEN AND ILLUSTRATED BY

Eric Whaites

MSc BDS(Hons) FDSRCS(Edin) DDRRCR LDSRCS(Eng)

Senior Lecturer and Honorary Consultant in Dental Radiology in charge of the Department of Dental Radiology, Guy's, King's and St Thomas' Dental Institute, King's College, University of London, London, UK

FOREWORD BY

R. A. Cawson MD FRCPath FDS

Emeritus Professor in Oral Medicine and Pathology in the University of London, UK

CHURCHILL LIVINGSTONE

EDINBURGH LONDON NEW YORK OXFORD PHILADELPHIA ST LOUIS SYDNEY TORONTO 2002

CHURCHILL LIVINGSTONE
An imprint of Elsevier Science Limited

First edition 1992
Second edition 1996
Third edition 2002
Reprinted 2003

ISBN 0443-07027-X

British Library Cataloguing in Publication Data
A catalogue record for this book is available from the British Library

Library of Congress Cataloging in Publication Data
A catalog record for this book is available from the Library of Congress

Note
Medical knowledge is constantly changing. As new information becomes available, changes in treatment, procedures, equipment and the use of drugs become necessary. The author and the publishers have taken care to ensure that the information given in this text is accurate and up to date. However, readers are strongly advised to confirm that the information, especially with regard to drug usage, complies with the latest legislation and standards of practice.

ELSEVIER SCIENCE
your source for books, journals and multimedia in the health sciences
www.elsevierhealth.com

The publisher's policy is to use **paper manufactured from sustainable forests**

Printed in China

Contents

This page intentionally left blank

Foreword

I am flattered to have been asked to write another Foreword to Eric Whaites' excellent text. It has been a great pleasure to see how successful this book has been. With the appearance of the first edition it was obvious that it provided an unusually clear, concise and comprehensive exposition of the subject. However, its success speaks for itself and the fact that no fewer than three reprints of the second edition were demanded, has confirmed that its qualities had been appreciated. There is little therefore that one needs to add except to encourage readers to take advantage of all that this book offers.

R.A.C.
2002

This page intentionally left blank

Preface

This new edition has been prompted by the introduction of new legislation and guidance on the use of ionising radiation in the UK. In addition to providing a summary of these new regulations I have taken the opportunity to update certain chapters and encompass many of the helpful suggestions and comments I have received from reviewers, colleagues and students. In particular I have increased the number of examples of many of the pathological conditions so that a range of appearances is illustrated.

However, the aims and objectives of the book remain unchanged from the first edition, namely to provide a basic and practical account of what I consider to be the essential subject matter of both dental radiography and radiology needed by undergraduate and postgraduate dental students, as well as by students of the Professions Complementary to Dentistry (PCDs). It therefore remains first and foremost a teaching manual, rather than a comprehensive reference book. The content remains sufficiently detailed to satisfy the requirements of most undergraduate and postgraduate dental examinations.

As in previous editions some things have inevitably had to be omitted, or sometimes, oversimplified in condensing a very large and often complex subject. The result I hope is a clear, logical and easily understandable text, that continues to make a positive contribution to the challenging task of teaching and learning dental radiology.

London E.W.
2002

This page intentionally left blank

Acknowledgements

Once again this edition has only been possible thanks to the enormous amount of help and encouragement that I have received from my family, friends and colleagues.

In particular I would like to thank the members of staff in my Department both past and present. Mrs Jackie Brown and Mr Nicholas Drage have provided invaluable help throughout including providing me with illustrations, their advice and constructive comments. Mr Brian O'Riordan painstakingly commented on every chapter and offered a wide range of helpful advice before his retirement. As both my teacher and colleague he has been an inspiration throughout my career and I shall miss his wise counsel. I am also particularly indebted to Professor David Smith for allowing me to plunder his radiographic collection to enable me to increase the number of illustrations of many pathological conditions. Grateful thanks also to Mrs Nadine White, Ms Jocelyn Sewell, Ms Sharon Duncan, Miss Julie Cooper, Miss Amanda Medlin, Mrs Cathy Sly, Mrs Wendy Fenton and Miss Allisson Summerfield for their collective help and encouragement. I am indeed fortunate to work with such an able and supportive team.

My thanks to the following for their help and advice with specific chapters: Dr Neil Lewis (Chapter 6), Mr Peter Hirschmann, Mr Tony Hudson, Mr Ian Napier and the NRPB for allowing me to reproduce parts of the 2001 Guidance Notes (Chapter 6), Mr Guy Palmer and Dr Carole Boyle (Chapter 7), Professor Fraser Macdonald (Chapter 13), Ms Penny Gage (Chapter 17), Mr Sohaib Safiullah (Chapter 21), Professor Richard Palmer (Chapter 22), Professor Peter Morgan and Dr Eddie Odell (Chapters 25 and 26), Mr Peter Longhurst (Chapter 28) and Mr Paul Robinson (Chapters 28 and 29). My thanks also to the many colleagues and students who provided comments and feedback on the second edition that I hope have led to improvements.

Special thanks to Mr Andrew Dyer and Mrs Emma Wing of the GKT Department of Photography, Printing and Design who spent so many hours producing the new clinical photographs and new radiographic illustrations which are so crucial to a book that relies heavily on visual images. My thanks also to Miss Julie Cooper for willingly sitting as the photographic model.

Mrs Wendy Fenton helped with the proofreading for which I am very grateful. My thanks also to Mr Graham Birnie, Mr Jim Killgore and the staff of Harcourt for their help and advice in the production process.

It is easy to forget the help provided with the initial manuscript for the first edition several years ago, but without the help of Professor Rod Cawson this book would never have been produced in the first place. My thanks once again to him and to my various colleagues who helped with the previous editions.

Finally, once again a very special thank you to my wife Catriona for all her help, advice, support and encouragement throughout the production of this edition and to my children Stuart, Felicity and Claudia for their understanding that precious family time has had to be sacrificed.

This page intentionally left blank

Introduction

Part 1

This page intentionally left blank

1 The radiographic image

Introduction

The use of X-rays is an integral part of clinical dentistry, with some form of radiographic examination necessary on the majority of patients. As a result, radiographs are often referred to as the clinician's *main diagnostic aid*.

The range of knowledge of dental radiography and radiology thus required can be divided conveniently into four main sections:

- *Basic physics and equipment* — the production of X-rays, their properties and interactions which result in the formation of the radiographic image
- *Radiation protection* — the protection of patients and dental staff from the harmful effects of X-rays
- *Radiography* — the techniques involved in producing the various radiographic images
- *Radiology* — the interpretation of these radiographic images.

Understanding the radiographic image is central to the entire subject. This chapter provides an introduction to the nature of this image and to some of the factors that affect its quality and perception.

Nature of the radiographic image

The image is produced by X-rays passing through an object and interacting with the photographic emulsion on a film. This interaction results in blackening of the film. The extent to which the emulsion is blackened depends on the number of X-rays reaching the film, which in turn depends on the density of the object.

The final image can be described as a two-dimensional picture made up of a variety of black, white and grey superimposed shadows and is thus sometimes referred to as a *shadowgraph* (see Fig. 1.1).

Understanding the nature of the shadowgraph and interpreting the information contained within it requires a knowledge of:

- The radiographic shadows
- The three-dimensional anatomical tissues
- The limitations imposed by a two-dimensional picture and superimposition.

The radiographic shadows

The amount the X-ray beam is stopped (attenuated) by an object determines the *radiodensity* of the shadows:

- The white or *radiopaque* shadows on a film represent the various dense structures within the object which have totally stopped the X-ray beam.
- The black or *radiolucent* shadows represent areas where the X-ray beam has passed through the object and has not been stopped at all.
- The grey shadows represent areas where the X-ray beam has been stopped to a varying degree.

The final *shadow density* of any object is thus affected by:

- The specific type of material of which the object is made
- The thickness or density of the material
- The shape of the object
- The intensity of the X-ray beam used

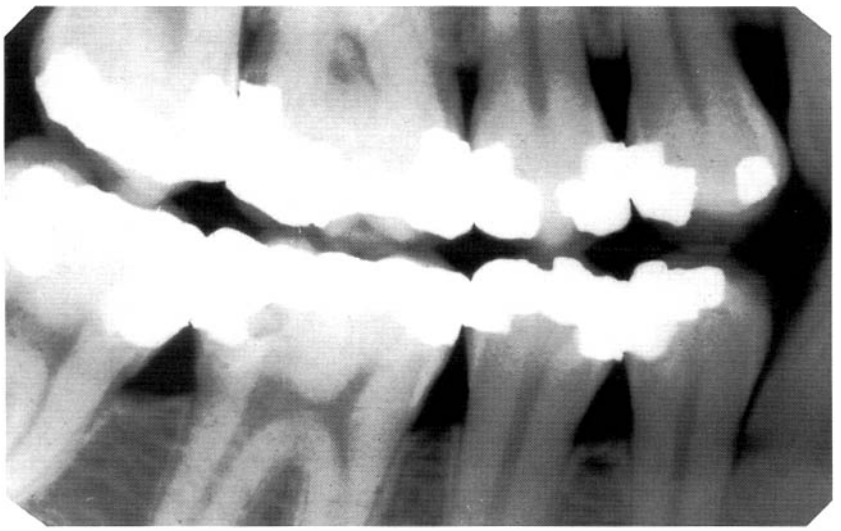

Fig. 1.1 A typical dental radiograph. The image shows the various black, grey and white radiographic shadows.



Fig. 1.2(i) Front view and **(ii)** plan view of various cylinders of similar shape but made of different materials: **A** plaster of Paris, **B** hollow plastic, **C** metal, **D** wood. **(iii)** Radiographs of the cylinders show how objects of the same shape, but of different materials, produce different radiographic images.

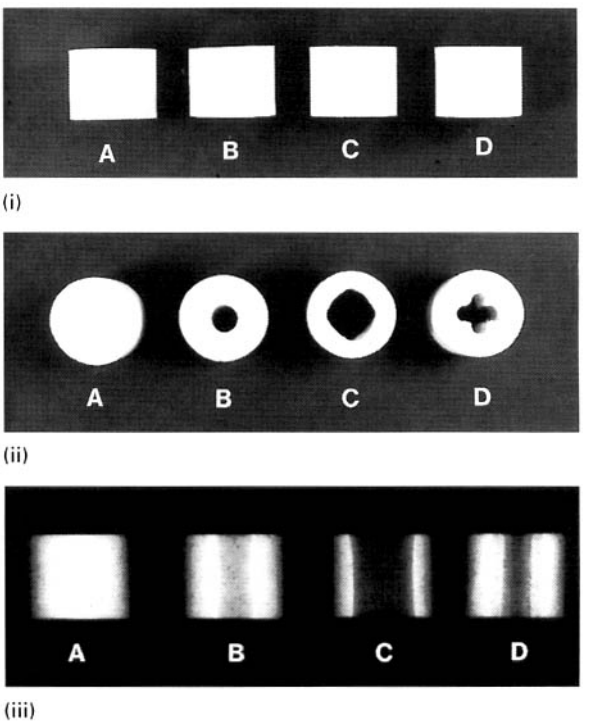

Fig. 1.3(i) Front view of four apparently similar cylinders made from plaster of Paris. **(ii)** Plan view shows the cylinders have varying internal designs and thicknesses. **(iii)** Radiographs of the apparently similar cylinders show how objects of similar shape and material, but of different densities, produce different radiographic images.

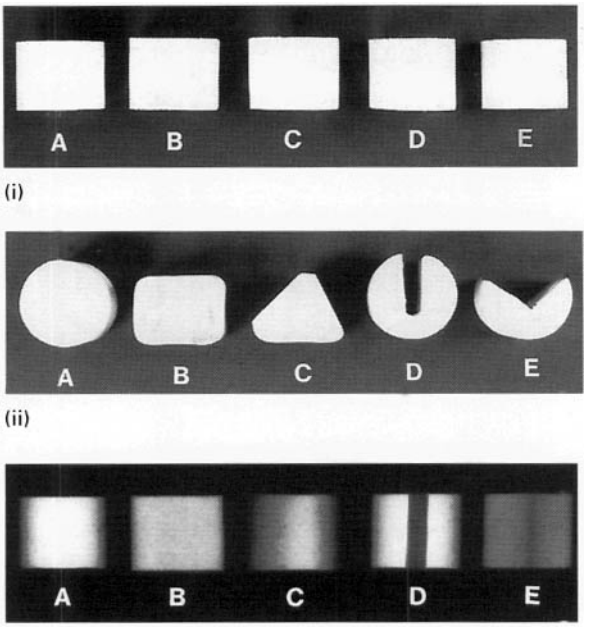

Fig. 1.4(i) Front view of five apparently similar cylinders made from plaster of Paris. **(ii)** Plan view shows the objects are in fact different shapes. **(iii)** Radiographs show how objects of different shape, but made of the same material, produce different radiographic images.



Fig. 1.5(i) Front view and **(ii)** plan view of four cylinders made from plaster of Paris but of different diameters. **(iii)** Four radiographs using different intensity X-ray beams show how increasing the intensity of the X-ray beam causes greater penetration of the object with less attenuation, hence the less radiopaque (white) shadows of the object that are produced, particularly of the smallest cylinder.

- The position of the object in relation to the X-ray beam and film
- The sensitivity of the film.

The effect of different materials, different thicknesses/densities, different shapes and different X-ray beam intensities on the radiographic image shadows are shown in Figures 1.2–1.5.

The three-dimensional anatomical tissues

The shape, density and thickness of the patient's tissues, principally the hard tissues, must also affect the radiographic image. Therefore, when viewing two-dimensional radiographic images, the three-dimensional anatomy responsible for the image must be considered (see Fig. 1.6). A sound anatomical knowledge is obviously a prerequisite for radiological interpretation (see Ch. 18).

The limitations imposed by a two-dimensional image and superimposition

The main limitations of viewing the two-dimensional image of a three-dimensional object are:

- Appreciating the overall shape of the object
- Superimposition and assessing the location and shape of structures *within* an object.

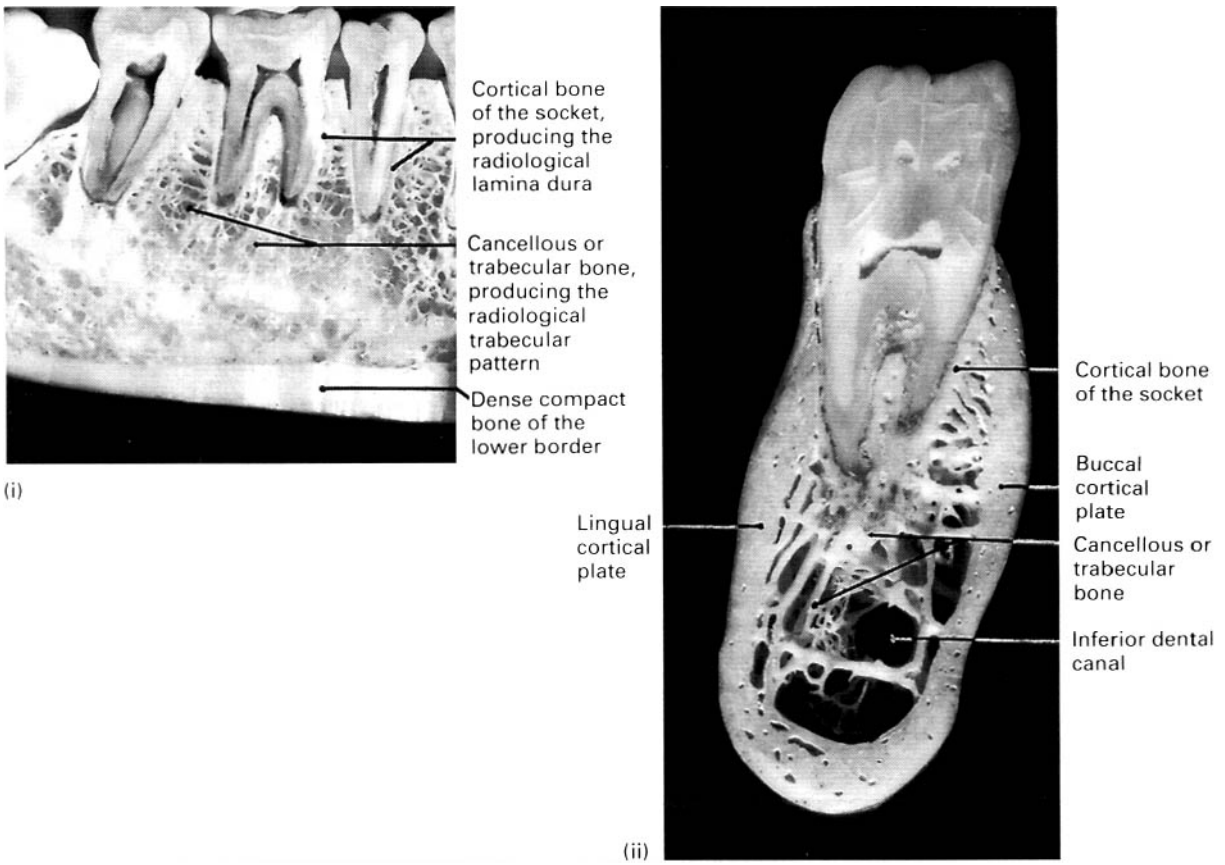

Fig. 1.6A **(i)** Sagittal and **(ii)** coronal sections through the body of a dried mandible showing the hard tissue anatomy and internal bone pattern.

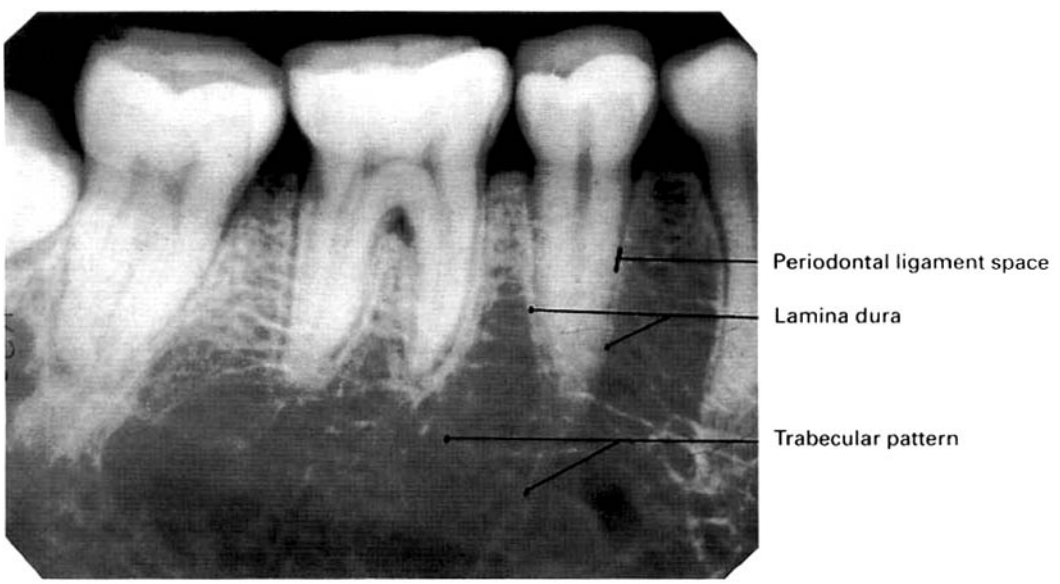

Fig. 1.6B Two-dimensional radiographic image of the three-dimensional mandibular anatomy.

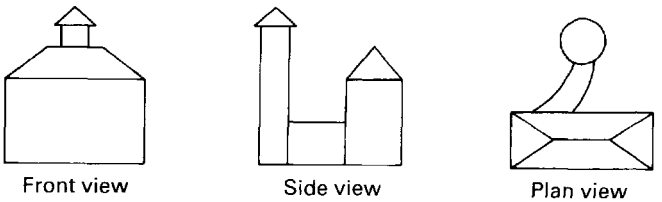

Fig. 1.7 Diagram illustrating three views of a house. The side view shows that there is a corridor at the back of the house leading to a tall tower. The plan view provides the additional pieces of information that the roof of the tall tower is round and that the corridor is curved.

Appreciating the overall shape

To visualize all aspects of any three-dimensional object, it must be viewed from several different positions. This can be illustrated by considering an object such as a *house*, and the minimum information required if an architect is to draw all aspects of the three-dimensional building in two dimensions (see Fig. 1.7). Unfortunately, it is only too easy for the clinician to forget that teeth and patients are three-dimensional. To expect one radiograph to provide *all* the required information about the shape of a tooth or patient is like asking the architect to describe the whole house from the front view alone.

Superimposition and assessing the location and shape of structures within an object

The shadows cast by different parts of an object (or patient) are superimposed upon one another on the final radiograph. The image therefore provides limited or even misleading information as to where a particular internal structure lies, or to its shape, as shown in Figure 1.8.

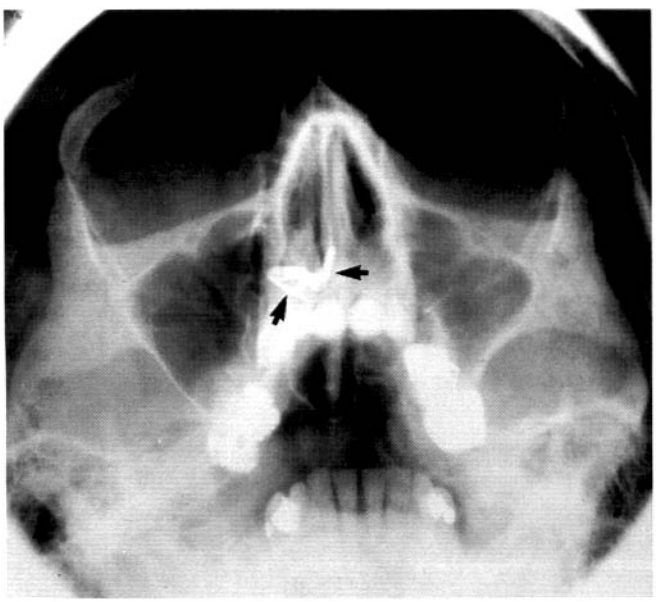

Fig. 1.8 Radiograph of the head from the front (an *occipitomental* view) taken with the head tipped back, as described later in Chapter 12. This positioning lowers the dense bones of the base of the skull and raises the facial bones so avoiding superimposition of one on the other. A radiopaque (white) object (arrowed) can be seen apparently in the base of the right nasal cavity.

In addition, a dense radiopaque shadow on one side of the head may overlie an area of radiolucency on the other, so obscuring it from view, or a radiolucent shadow may make a superimposed radiopaque shadow appear less opaque. One clinical solution to these problems is to take two views, at right angles to one another (see Figs 1.9 and 1.10). Unfortunately, even two views may still not be able to provide all the desired information for a diagnosis to be made (see Fig. 1.11).

These limitations of the conventional radiographic image have very important clinical implications and may be the underlying reason for a *negative radiographic report*. The fact that a particular feature or condition is not visible on one radiograph does not mean that the feature or condition does not exist, merely that it cannot be seen. Many of the recently developed alternative and specialized imaging modalities described in Chapter 17 have been designed to try to overcome these limitations.

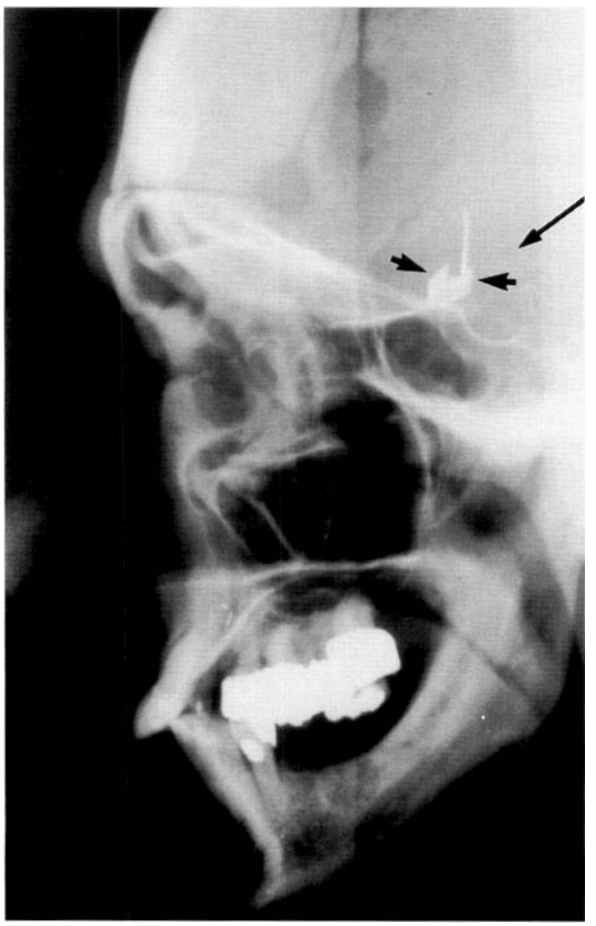

Fig. 1.9 Radiograph of the head from the side (a *true lateral skull view*) of the same patient shown in Figure 1.8. The radiopaque (white) object (arrowed) now appears intracranially just above the skull base. It is in fact a metallic aneurysm clip positioned on an artery in the Circle of Willis at the base of the brain. The dotted line indicates the direction of the X-ray beam required to produce the radiograph in Figure 1.8, illustrating how an intracranial metallic clip can appear to be in the nose.

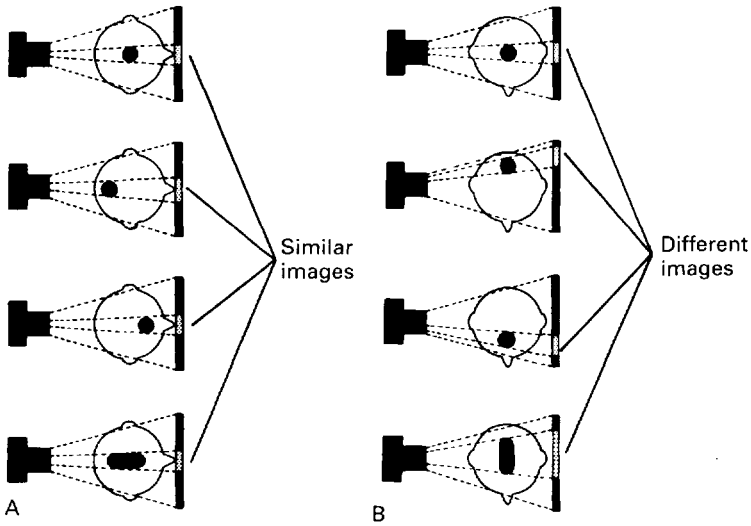

Fig. 1.10 Diagrams illustrating the limitations of a two-dimensional image: **A** Postero-anterior views of a head containing a mass in a different position or of a different shape. In all the examples, the mass will appear as a similar sized opaque image on the radiograph, providing no differentiating information on its position or shape. **B** The lateral or side view provides a possible solution to the problems illustrated in **A**; the masses now produce different images.

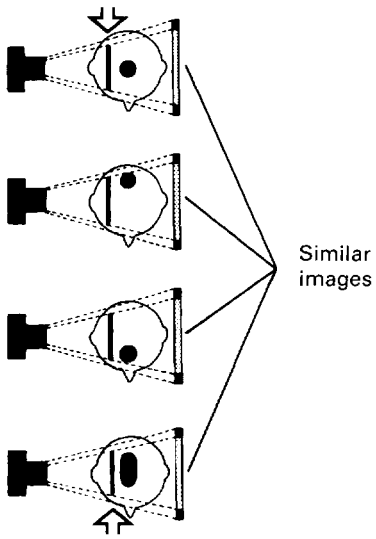

Fig. 1.11 Diagrams illustrating the problems of superimposition. Lateral views of the same masses shown in Figure 1.10 but with an additional radiodense object superimposed. This produces a similar image in each case with no evidence of the mass. The information obtained previously is now obscured and the usefulness of using two views at right angles is negated.

Quality of the radiographic image

Overall image quality and the amount of detail shown on a radiograph depend on several factors, including:

- Contrast — the visual difference between the various black, white and grey shadows
- Image geometry — the relative positions of the film, object and X-ray tubehead
- Characteristics of the X-ray beam
- Image sharpness and resolution.

These factors are in turn dependent on several variables, relating to the density of the object, the image receptor and the X-ray equipment. They are discussed in greater detail in Chapter 16. However, to introduce how the geometrical accuracy and detail of the final image can be influenced, two of the main factors are considered below.

Positioning of the film, object and X-ray beam

The position of the X-ray beam, object and film needs to satisfy certain basic geometrical requirements. These include:

- The object and the film should be in contact or as close together as possible
- The object and the film should be parallel to one another
- The X-ray tubehead should be positioned so that the beam meets both the object and the film at right angles.

These ideal requirements are shown diagrammatically in Figure 1.12. The effects on the final image of varying the position of the object, film or X-ray beam are shown in Figure 1.13.

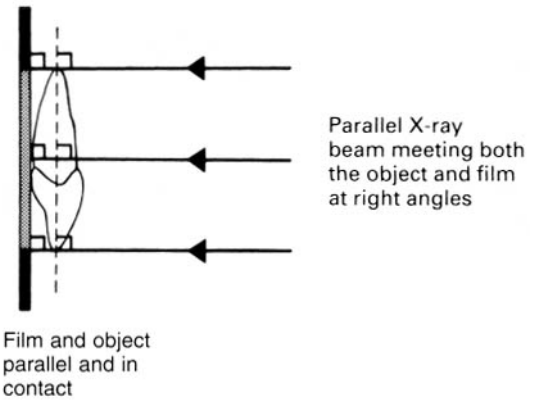

Fig. 1.12 Diagram illustrating the ideal geometrical relationship between the film, object and X-ray beam.

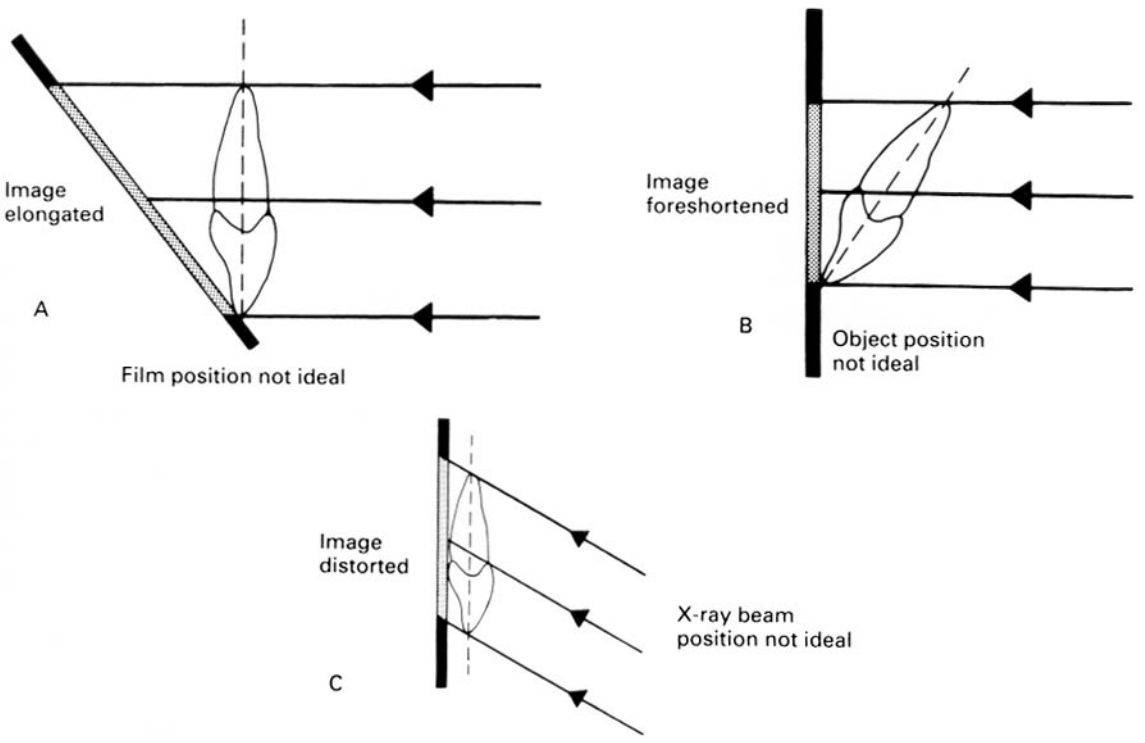

Fig. 1.13A Diagrams showing the effect on the final image of varying the position of **A** the film, **B** the object and **C** the X-ray beam.

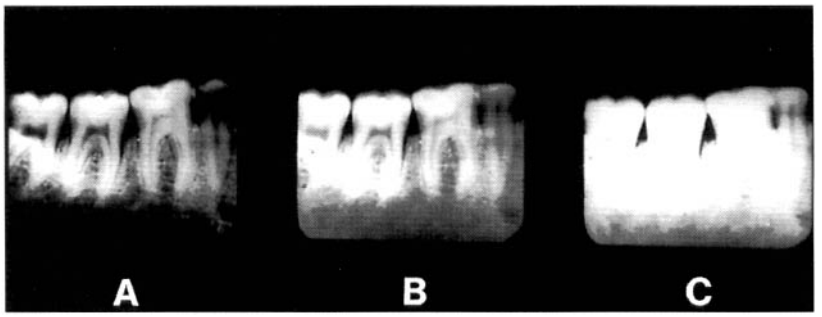

Fig. 1.14 Radiographs of the same area showing variation in contrast — the visual difference in the black, white and grey shadows due to the penetration of the X-ray beam. **A** Increased exposure (overpenetration). **B** Normal exposure. **C** Reduced exposure (underpenetration).

X-ray beam characteristics

The ideal X-ray beam used for imaging should be:

- Sufficiently penetrating, to pass through the patient and react with the film emulsion and produce good *contrast* between the different shadows (Fig. 1.14)
- Parallel, i.e. non-diverging, to prevent magnification of the image
- Produced from a point source, to reduce blurring of the edges of the image, a phenomenon known as the *penumbra* effect.

These ideal characteristics are discussed further in Chapter 5.

Perception of the radiographic image

The verb *to perceive* means *to apprehend with the mind using one or more of the senses*. Perception is the *act* or *faculty of perceiving*. In radiology, we use our sense of sight to perceive the radiographic image, but, unfortunately, we cannot rely completely on what we see. The apparently simple black, white and grey shadowgraph is a form of optical *illusion* (from the Latin *illudere*, meaning *to mock*). The radiographic image can thus mock our senses in a number of ways. The main problems can be caused by the effects of:

- Partial images
- Contrast
- Context.

Effect of partial images

As mentioned already, the radiographic image only provides the clinician with a partial image with limited information in the form of different density shadows. To complete the picture, the clinician fills in the gaps, but we do not all necessarily do this in the same way and may arrive at different conclusions. Three non-clinical examples are shown in Figure 1.15. Clinically, our differing perceptions may lead to different diagnoses.

Effect of contrast

The apparent density of a particular radiographic shadow can be affected considerably by the density of the surrounding shadows. In other words, the contrast between adjacent structures can alter the perceived density of one or both of them (see Fig. 1.16). This is of particular importance in dentistry, where metallic restorations produce densely white radiopaque shadows that can affect the apparent density of the adjacent tooth tissue. This is discussed again in Chapter 19 in relation to caries diagnosis.

Effect of context

The environment or context in which we see an image can affect how we interpret that image. A non-clinical example is shown in Figure 1.17. In dentistry, the environment that can affect our perception of radiographs is that created by the patient's description of the complaint. We can imagine that we see certain radiographic changes, because the patient has conditioned our perceptual apparatus.

These various perceptual problems are included simply as a warning that radiographic interpretation is not as straightforward as it may at first appear.



Fig. 1.15 The problem of partial images requiring the observer to fill in the missing gaps. Look at the three non-clinical pictures and what do you perceive? The objects shown are **A** a dog, **B** an elephant and **C** a steam ship. We all *see* the same partial images, but we don't necessarily *perceive* the same objects. Most people perceive the dog, some perceive the elephant while only a few perceive the ship and take some convincing that it is there. Interestingly, once observers have perceived the correct objects, it is impossible to look at the pictures again in the future without perceiving them correctly. (Figures from: Coren S, Porac C, Ward LM 1979 Sensation and perception. Harcourt Brace and Company, reproduced by permission of the publisher.)



Fig. 1.16 The effect of contrast. The four small inner squares are in reality all the same grey colour, but they appear to be different because of the effect of contrast. When the surrounding square is black, the observer perceives the inner square to be very pale, while when the surrounding square is light grey, the observer perceives the inner square to be dark. (Figure from: Cornsweet TN 1970 Visual perception. Harcourt Brace and Company, reproduced by permission of the publisher.)

A, B, C, D, E, F
10, 11, 12, 13, 14

Fig. 1.17 The effect of context. If asked to read the two lines shown here most, if not all, observers would read the letters A,B,C,D,E,F and then the numbers 10,11,12,13,14. Closer examination shows the letter B and the number 13 to be identical. They are perceived as B and 13 because of the context (surrounding letters or numbers) in which they are seen. (Figure from: Coren S, Porac C, Ward LM 1979 Sensation and perception. Harcourt Brace and Company, reproduced by permission of the publisher.)

Common types of dental radiographs

The various radiographic images of the teeth, jaws and skull are divided into two main groups:

- *Intraoral* — the film is placed *inside* the patient's mouth, including:
  - — Periapical radiographs (Ch. 8)
  - — Bitewing radiographs (Ch. 9)
  - — Occlusal radiographs (Ch. 10)
- *Extraoral* — the film is placed *outside* the patient's mouth, including:
  - — Oblique lateral radiographs (Ch. 11)
  - — Various skull radiographs (Chs 12 and 13)
  - — Dental panoramic tomographs (Ch. 15).

These various radiographic techniques are described later, in the chapters indicated. The approach and format adopted throughout these radiography chapters are intended to be straightforward, practical and clinically relevant and are based upon the essential knowledge required by clinicians. This includes:

- WHY each particular projection is taken — i.e. the main clinical indications
- HOW the projections are taken — i.e. the relative positions of the patient, film and X-ray tubehead
- WHAT the resultant radiographs should look like and which anatomical features they show.