



Chapter 6 The Elbow and Radioulnar Joints

Manual of Structural Kinesiology
R.T. Floyd, EdD, ATC, CSCS

© 2007 McGraw-Hill Higher Education. All rights reserved.

6-1

The Elbow & Radioulnar Joints

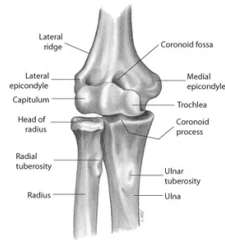- Most upper extremity movements involve the elbow & radioulnar joints
- Usually grouped together due to close anatomical relationship
- Elbow joint movements may be clearly distinguished from those of the radioulnar joints
- Radioulnar joint movements may be distinguished from those of the wrist

© 2007 McGraw-Hill Higher Education. All rights reserved.

6-2

Bones

- Ulna is much larger proximally than radius
- Radius is much larger distally than ulna
- Scapula & humerus serve as proximal attachments for muscles that flex & extend the elbow
- Ulna & radius serve as distal attachments for these same muscles

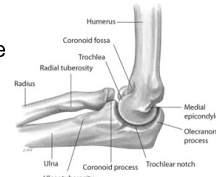

© 2007 McGraw-Hill Higher Education. All rights reserved.

6-3

Bones

- Scapula, humerus, & ulna serve as proximal attachments for muscles that pronate & supinate the radioulnar joints
- Distal attachments of radioulnar joint muscles are located on radius
- Bony landmarks
 - medial condyloid ridge
 - olecranon process
 - coranoid process
 - radial tuberosity

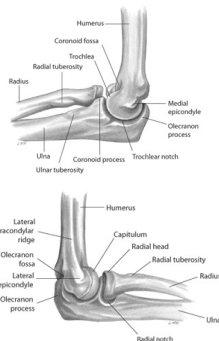

© 2007 McGraw-Hill Higher Education. All rights reserved.

6-4

Bones

- Key bony landmarks for wrist & hand muscles
 - medial epicondyle
 - lateral epicondyle
 - lateral supracondylar ridge



© 2007 McGraw-Hill Higher Education. All rights reserved.

6-5

Joints

- Ginglymus or hinge-type joint
- Allows only flexion & extension
- 2 interrelated joints
 - humeroulnar joint
 - radiohumeral joints

© 2007 McGraw-Hill Higher Education. All rights reserved.

6-6

Joints

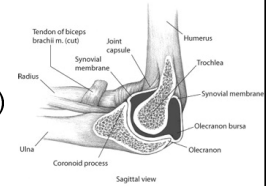
- Elbow motions
 - primarily involve movement between articular surfaces of humerus & ulna
 - specifically humeral trochlear fitting into ulna trochlear notch
 - radial head has a relatively small amount of contact with capitulum of humerus
 - As elbow reaches full extension, olecranon process is received by olecranon fossa
 - increased joint stability when fully extended

© 2007 McGraw-Hill Higher Education. All rights reserved.

6-7

Joints

- As elbow flexes 20 degrees or more, its bony stability is unlocked, allowing for more side-to-side laxity
- Stability in flexion is more dependent on the lateral (radial collateral ligament) & the medial or (ulnar collateral ligament)

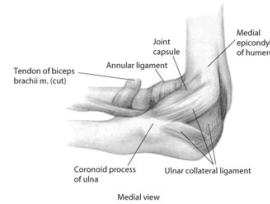


© 2007 McGraw-Hill Higher Education. All rights reserved.

6-8

Joints

- Ulnar collateral ligament is critical in providing medial support to prevent elbow from abducting when stressed in physical activity
 - Many contact sports & throwing activities place stress on medial aspect of joint, resulting in injury

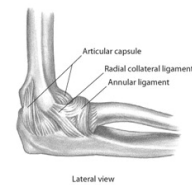


© 2007 McGraw-Hill Higher Education. All rights reserved.

6-9

Joints

- Radial collateral ligament provides lateral stability & is rarely injured
- Annular ligament provides a sling effect around radial head for stability

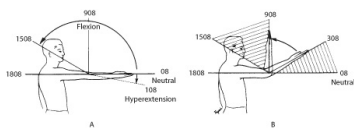


© 2007 McGraw-Hill Higher Education. All rights reserved.

6-10

Joints

- Elbow moves from 0 degrees of extension to 145 to 150 degrees of flexion

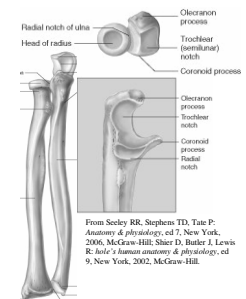


© 2007 McGraw-Hill Higher Education. All rights reserved.

6-11

Joints

- Radioulnar joint
 - Trochoid or pivot-type joint
 - Radial head rotates around at proximal ulna
 - Distal radius rotates around distal ulna
 - Annular ligament maintains radial head in its joint



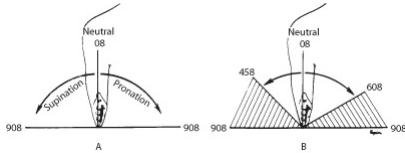
From Seeley RR, Stephens TD, Tate P: *Anatomy & physiology*, ed 7, New York, 2006, McGraw-Hill; Shier D, Butler J, Lewis R: *Human anatomy & physiology*, ed 9, New York, 2002, McGraw-Hill.

© 2007 McGraw-Hill Higher Education. All rights reserved.

6-12

Joints

- Radioulnar joint
 - Supinate 80 to 90 degrees from neutral
 - Pronate 70 to 90 degrees from neutral



© 2007 McGraw-Hill Higher Education. All rights reserved.

6-13

Joints

- Radioulnar joint
 - Joint between shafts of radius & ulna held tightly together between proximal & distal articulations by an interosseus membrane (syndesmosis)
 - substantial rotary motion between the bones

© 2007 McGraw-Hill Higher Education. All rights reserved.

6-14

Joints

- Synergy between glenohumeral, elbow, & radioulnar joint muscles
 - As the radioulnar joint goes through its ROM, glenohumeral & elbow muscles contract to stabilize or assist in the effectiveness of movement at the radioulnar joints
 - Ex. when tightening a screw with a screwdriver which involves radioulnar supination, we tend to externally rotate & flex the glenohumeral & elbow joints, respectively

© 2007 McGraw-Hill Higher Education. All rights reserved.

6-15

Joints

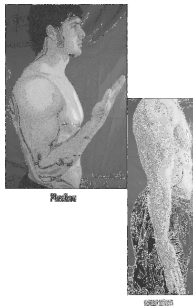- Synergy between glenohumeral, elbow, & radioulnar joint muscles
 - Conversely, when loosening a tight screw with pronation, we tend to internally rotate & extend the elbow & glenohumeral joints, respectively
 - we depend on both the agonists and antagonists in the surrounding joints to assist in an appropriate amount of stabilization & assistance with the required task

© 2007 McGraw-Hill Higher Education. All rights reserved.

6-16

Movements

- Flexion
 - movement of forearm to shoulder by bending the elbow to decrease its angle
- Extension
 - movement of forearm away from shoulder by straightening the elbow to increase its angle

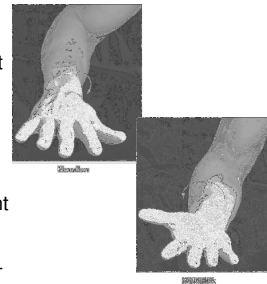


© 2007 McGraw-Hill Higher Education. All rights reserved.

6-17

Movements

- Pronation
 - internal rotary movement of radius on ulna that results in hand moving from palm-up to palm-down position
- Supination
 - external rotary movement of radius on ulna that results in hand moving from palm-down to palm-up position



© 2007 McGraw-Hill Higher Education. All rights reserved.

6-18

Muscles

- Elbow flexors
 - Biceps brachii
 - Brachialis
 - Brachioradialis
 - Weak assistance from Pronator teres
- Elbow extensor
 - Triceps brachii
 - Anconeus provides assistance

© 2007 McGraw-Hill Higher Education. All rights reserved.

6-19

Muscles

- Radioulnar pronators
 - Pronator teres
 - Pronator quadratus
 - Brachioradialis
- Radioulnar supinators
 - Biceps brachii
 - Supinator muscle
 - Brachioradialis

© 2007 McGraw-Hill Higher Education. All rights reserved.

6-20

Muscles

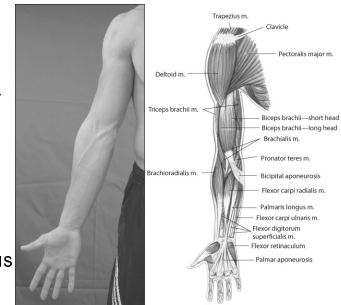
- “Tennis elbow” - common problem usually involving extensor digitorum muscle near its origin on lateral epicondyle
 - known lateral epicondylitis
 - associated with gripping & lifting activities
- Medial epicondylitis
 - somewhat less common
 - known as golfer’s elbow
 - associated with medial wrist flexor & pronator group near their origin on medial epicondyle
 - Both conditions involve muscles which cross elbow but act primarily on wrist & hand

© 2007 McGraw-Hill Higher Education. All rights reserved.

6-21

Muscles

- **Anterior**
 - Primarily flexion & pronation
 - Biceps brachii
 - Brachialis
 - Brachioradialis
 - Pronator teres
 - Pronator quadratus

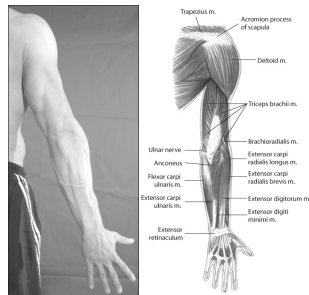


© 2007 McGraw-Hill Higher Education. All rights reserved.

6-22

Muscles

- **Posterior**
 - Primarily extension & supination
 - Triceps brachii
 - Anconeus
 - Supinator

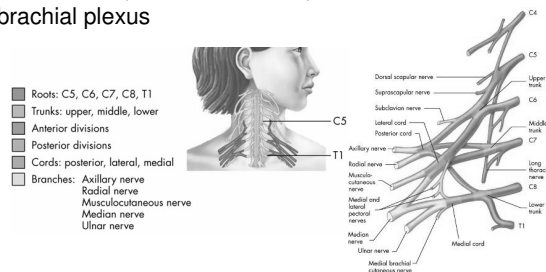


© 2007 McGraw-Hill Higher Education. All rights reserved.

6-23

Nerves

- All elbow & radioulnar joints muscles are innervated from median, musculotaneous, & radial nerves of brachial plexus

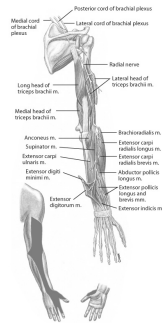


© 2007 McGraw-Hill Higher Education. All rights reserved.

6-24

Nerves

- Radial nerve - originates from C5, C6, C7, & C8
 - Triceps brachii
 - Brachioradialis
 - Supinator (posterior interosseous nerve)
 - Anconeus
 - Sensation to posterolateral arm, forearm, & hand

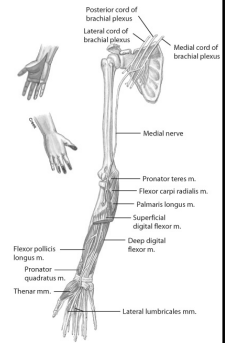


© 2007 McGraw-Hill Higher Education. All rights reserved.

6-25

Nerves

- Median nerve - derived from C6 & C7
 - Pronator teres
 - Pronator quadratus (anterior interosseous nerve)
 - Sensation to palmar aspect of hand & first three phalanges, palmar aspect of radial side of fourth finger, dorsal aspect of index & long fingers

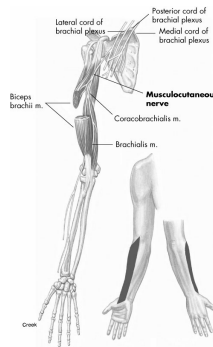


© 2007 McGraw-Hill Higher Education. All rights reserved.

6-26

Nerves

- Musculotaneous nerve - branches from C5 & C6
 - Biceps brachii
 - Brachialis

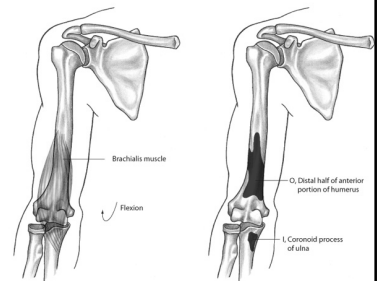


© 2007 McGraw-Hill Higher Education. All rights reserved.

6-27

Biceps Brachii Muscle

- Flexion of elbow
- Supination of forearm
- Weak flexion of shoulder joint
- Weak abduction of shoulder joint when externally rotated

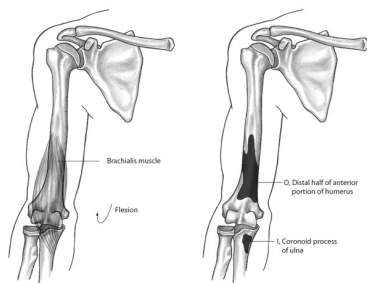


© 2007 McGraw-Hill Higher Education. All rights reserved.

6-28

Brachialis Muscle

- True flexion of elbow

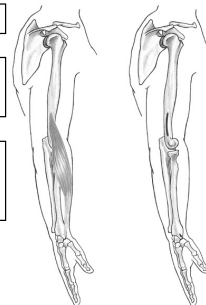

© 2007 McGraw-Hill Higher Education. All rights reserved.

6-29

Brachioradialis Muscle

- Flexion of elbow
- Pronation from supinated position to neutral
- Supination from pronated position to neutral



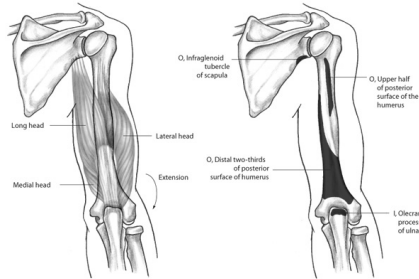
© 2007 McGraw-Hill Higher Education. All rights reserved.

6-30

Triceps Brachii Muscle

All heads:
extension
of elbow

Long head:
extension
of shoulder
joint;
adduction
of shoulder
joint;
horizontal
abduction

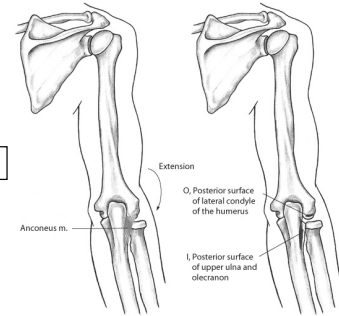


© 2007 McGraw-Hill Higher Education. All rights reserved.

6-31

Anconeus Muscle

Extension of elbow



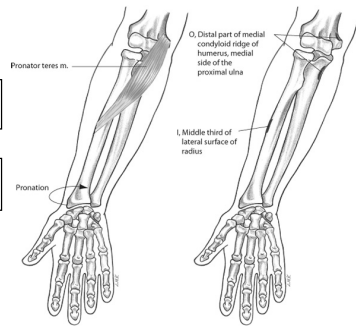
© 2007 McGraw-Hill Higher Education. All rights reserved.

6-32

Pronator Teres Muscle

Pronation of
forearm

Weak flexion
of elbow

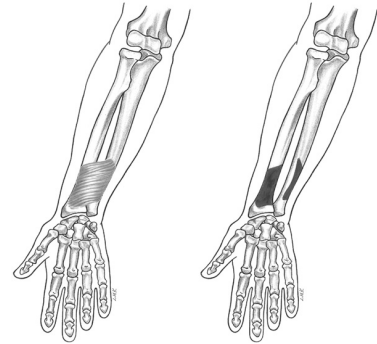


© 2007 McGraw-Hill Higher Education. All rights reserved.

6-33

Pronator Quadratus Muscle

Pronation
of
forearm

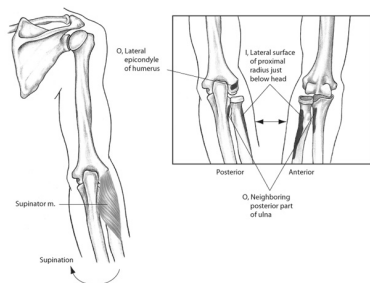


© 2007 McGraw-Hill Higher Education. All rights reserved.

6-34

Supinator Muscle

Supination of
forearm

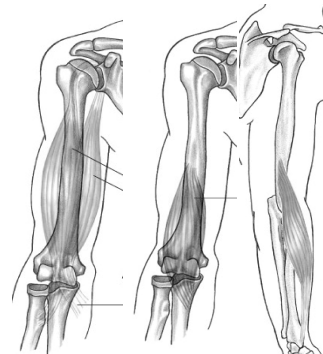


© 2007 McGraw-Hill Higher Education. All rights reserved.

6-35

Elbow Flexion

- Ex. Biceps curl
- Agonists
 - Biceps brachii
 - Brachialis
 - Brachioradialis

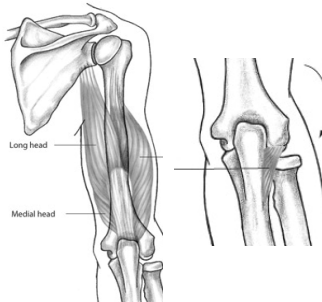


© 2007 McGraw-Hill Higher Education. All rights reserved.

6-36

Elbow Extension

- EX. Push-up
- Agonists
 - Triceps brachii
 - Anconeus

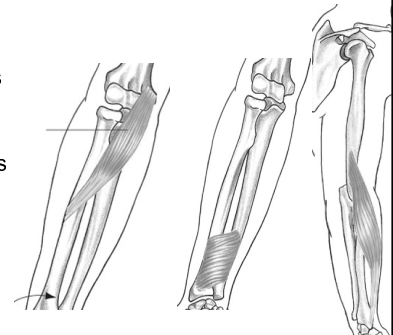


© 2007 McGraw-Hill Higher Education. All rights reserved.

6-37

Radioulnar Pronation

- Agonists
 - Pronator teres
 - Pronator quadratus
 - Brachioradialis

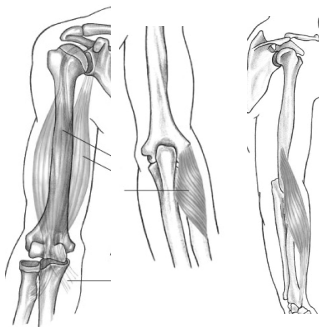


© 2007 McGraw-Hill Higher Education. All rights reserved.

6-38

Radioulnar Supination

- Ex. Tightening a screw
- Agonists
 - Biceps brachii
 - Supinator muscle
 - Brachioradialis



© 2007 McGraw-Hill Higher Education. All rights reserved.

6-39

Web Sites

American Family Physician

<http://www.aafp.org/afp/20000201/691.html>

- Evaluation of Overuse Elbow Injuries

Medical Multimedia Group

www.healthpages.org/AHP/LIBRARY/HLTHTOP/CTD/

- A Patient's Guide to Cumulative Trauma Disorder(CTD)

Lecture Topics in Kinesiology

<http://moon.ouhsc.edu/dthompsn/namics/elbow.htm>

- Describes motions caused by the muscles.

Huei Ming Chai

www.pt.ntu.edu.tw/hmchai/Kines04/KINupper/Elbow.htm

- Functions, stability and joint structure of elbow complex; kinematics, muscle action and common injuries of the elbow.

Southern California Orthopedic Institute

www.scoi.com/teniselb.htm

- Tennis elbow information

© 2007 McGraw-Hill Higher Education. All rights reserved.

6-40

Web Sites

National Aeronautics and Space Administration

<http://rehabworks.ksc.nasa.gov/education/protocols/basicwristelbow.php>

- Basic Wrist and Elbow Rehabilitation

UpToDate

http://patients.uptodate.com/topic.asp?file=bone_joi/7086

- Physical Therapy for Elbow Tendinitis

American Sports Medicine Institute

www.asmi.org/asmiweb/mpresentations/mmp.htm

- Biomechanics of the Elbow during Throwing

American Academy of Orthopaedic Surgeons

<http://orthoinfo.aaos.org/category.cfm?topcategory=Hand>

- Patient Education Library on the Elbow

© 2007 McGraw-Hill Higher Education. All rights reserved.

6-41

Web Sites

American Physical Therapy Association

<http://www.apta.org/AM/Template.cfm?Section=Home&CONTENTID=20403&TEMPLATE=/CM/HTMLDisplay.cfm>

- Taking Care of Your Hand, Wrist, and Elbow

The Physician and Sportsmedicine

http://www.physsportsmed.com/issues/1996/05_96/nirschl.htm

- Assessment and Treatment Guidelines for Elbow Injuries

The Physician and Sportsmedicine

http://www.physsportsmed.com/issues/1999/06_99/whiteside.htm

- Elbow Injuries in Young Baseball Players

Radiologic Anatomy Browser

<http://radlinux1.usuf1.usuhs.mil/rad/iong/index.html>

- This site has numerous radiological views of the musculoskeletal system.

© 2007 McGraw-Hill Higher Education. All rights reserved.

6-42

Web Sites

University of Arkansas Medical School Gross Anatomy for Medical Students

<http://anatomy.uams.edu/anatomyhtml/grossresources.html>
– Dissections, anatomy tables, atlas images, links, etc.

Loyola University Medical Center: Structure of the Human Body

www.meddean.luc.edu/lumen/MedEd/GrossAnatomy/GA.html
– An excellent site with many slides, dissections, tutorials, etc., for the study of human anatomy

Wheeless' Textbook of Orthopaedics

www.wheelessonline.com/
– This site has an extensive index of links to the fractures, joints, muscles, nerves, trauma, medications, medical topics, lab tests, and links to orthopedic journals and other orthopedic and medical news.

Arthroscopy.Com

www.arthroscopy.com/sports.htm
– Patient information on various musculoskeletal problems of the upper and lower extremity

© 2007 McGraw-Hill Higher Education. All rights reserved.

6-43

Web Sites

Premiere Medical Search Engine

<http://www.medsite.com/Default.asp?bhcp=1>
– This site allows the reader to enter any medical condition and it will search the net to find relevant articles.

Virtual Hospital

www.vh.org
– Numerous slides, patient information, etc.

© 2007 McGraw-Hill Higher Education. All rights reserved.

6-44