

X-ray–Based Volumetric Imaging of Foreign Bodies: A Comparison of Computed Tomography and Digital Volume Tomography

Georg Eggers, MD, DMD, PhD,* Thomas Welzel, MD,†

Damir Mukhamadiev, DMD,‡ René Wörtche, MD, DMD,§

Stefan Hassfeld, MD, DMD,|| and Joachim Mühling, MD, DMD¶

Foreign bodies are frequent sequelae of trauma or therapeutic intervention in the head and neck region and are responsible for up to 3.8% of all pathologic findings. Dependent on the type of trauma, composition and location of foreign bodies vary considerably.¹⁻³ Foreign bodies frequently found in dentistry are amalgam particles or endodontic instruments. The most frequent particles in the soft tissue of head and neck are needles, bullet fragments, metal, and glass.⁴

Possible negative effects, such as inflammation, disturbed wound healing, or even intracranial abscess,⁵ warrant foreign body removal, whenever possible, at reasonable risk. The task of imaging is to provide accurate detection and localization of the foreign body and surrounding anatomy, with a goal toward reducing surgical risk for the patient.⁶ Various imaging modalities, such as plain x-ray, computed tomography (CT), magnetic resonance imaging (MRI), and ultrasound, are used to detect foreign bodies.^{7,8} In dentistry and maxillofacial surgery, panoramic x-ray is performed for first diagnosis. Additional radiographs in other planes or CT scans allow more exact localization.^{5,9}

A recent development that offers a potential alternative to conventional CT is cone-beam computed

tomography (CBCT). In conventional CT, volume image data are acquired with the use of a fan-shaped x-ray beam and strip-shaped detectors. The x-ray source and the detector rotate repeatedly around the patient's body, which is advanced step by step or continuously (spiral CT) through the gantry. The axial extent of the scanned volume is determined by advancement of the patient through the gantry. In contrast, in CBCT, a cone-shaped x-ray beam and a 2-dimensional detector rotate around the patient only once. The patient's body is not moved. Hence, the dimension of volume in the axial direction is determined on the basis of the geometry of the cone beam and the detector.

This concept has been adopted for imaging in oral and maxillofacial surgery and dentistry. Devices with differences in size of the scanning volume, image resolution, and patient position have been introduced.^{10,11} Some devices have a particularly small volume of interest (VOI) but very good image quality, which can make them useful, for example, for high-resolution imaging of single teeth.^{12,13} Other devices with lesser resolution but larger VOIs have been introduced as well for use in dental implant planning, TMJ assessment, or assessment of craniofacial fractures, or in orthodontics for the assessment of growth and development.¹⁴⁻¹⁶

One of these devices is the NewTom QR DVT 9000 (QR, Verona, Italy), which was used in this study. The term digital volume tomography (DVT) was coined by the manufacturer of this device and hence designates this particular implementation of the concept of CBCT. Thus, all statements about DVT are valid for the NewTom 9000 in particular but not for CBCT in general.

Previous studies have shown that DVT imaging indeed requires a lower radiation dose than is used with conventional CT,¹⁷⁻¹⁹ and it offers a reasonable image quality.²⁰ The use of DVT imaging for the detection of foreign bodies has been shown in a previous study.²¹ The goal of this study was to assess

Received from Heidelberg University Hospital, Heidelberg, Germany.

*Doctor, Department of Oral and Cranio-Maxillofacial Surgery.

†Doctor, Department of Radio-Oncology.

‡Doctor, Department of Oral and Cranio-Maxillofacial Surgery.

§Doctor, Department of Oral and Cranio-Maxillofacial Surgery.

¶Professor, Department of Oral and Cranio-Maxillofacial Surgery.

||Professor, Department of Oral and Cranio-Maxillofacial Surgery.

Address correspondence and reprint requests to Dr Eggers: Department of Oral and Cranio-Maxillofacial Surgery, Heidelberg University Hospital, Im Neuenheimer Feld 400, 69120 Heidelberg, Germany; e-mail: georg.eggers@med.uni-heidelberg.de

© 2007 American Association of Oral and Maxillofacial Surgeons

0278-2391/07/6509-0040\$32.00/0

doi:10.1016/j.joms.2006.09.029

Table 1. SUBSTANCES THAT WERE INVESTIGATED AS FOREIGN BODIES AND VOLUME OF THE SAMPLES (MM³)

Substance	Sample Number									
	1	2	3	4	5	6	7	8	9	10
Amalgam*	18	5.3	2.8	1.2	0.7	0.46	0.3	0.19	0.11	0.05
Glass	19	5.42	2.83	1.22	0.71	0.38	0.32	0.23	0.13	0.06
Asphalt	17.6	4.3	2.8	1.23	0.85	0.41	0.31	0.21	0.12	0.06
Tooth	18.7	6.19	2.93	1.13	0.8	0.47	0.37	0.2	0.11	0.04
Resin†	19	5.5	3	1.2	0.78	0.43	0.39	0.22	0.1	0.06
Dry wood	18.5	4.5	2.75	1.6	0.8	0.42	0.3	0.19	0.11	0.06

*Dispersalloy, Dentsply International, York, Philadelphia, PA.

†Durafil VS, Heraeus Kulzer, Hanau, Germany.

Eggers et al. Volumetric X-ray-Based Foreign Body Imaging. *J Oral Maxillofac Surg* 2007.

how DVT compares with CT in the detection of foreign bodies, and to determine whether it could be an equivalent alternative for clinical use. In this systematic comparative study, foreign bodies were imaged with the use of CT and DVT.

Materials and Methods

FOREIGN BODIES

Because the goal of this study was to compare the detection limits of CT and DVT for typical foreign bodies, cuboid particles of typical foreign body substances were created in sizes ranging between 20 mm³ and 0.04 mm³ (Table 1). At first, the largest samples were used to determine whether the substance was visible at all on CT and DVT. Additionally, radio-opacity on CT image was measured in Hounsfield units.

For each substance, all samples of various sizes were imaged so that a size threshold could be determined for detection of the respective substance; foreign body samples were placed in boxes made of acrylic glass. Detection of a foreign body on imaging is always done in contrast to the surrounding tissue. Hence, to simulate possible clinically relevant locations, foreign bodies were imaged in various surroundings:

- Foreign body in air: Foreign bodies were placed in empty caskets.
- Foreign body in muscular tissue: Foreign bodies were embedded 0.5 cm deep in pieces of fresh pork meat in caskets.
- Foreign body on bone surface: Foreign bodies were placed within samples of porcine bone with adherent muscular tissue. A slot was inserted into the muscle, and the foreign body was placed directly onto the surface of the bone. The incision was sutured.

IMAGING

DVT imaging was performed with the NewTom QR DVT 9000 (Fig 1), which is designed particularly for imaging of the head. During imaging, the x-ray tube and the detector rotate 360° around the fixed headrest. An image is taken within every degree of rotation. The detector is composed of an image amplifier with an 8 × 8-inch window and an amplification of 22:1. A charge-coupled device (CCD) with a matrix of

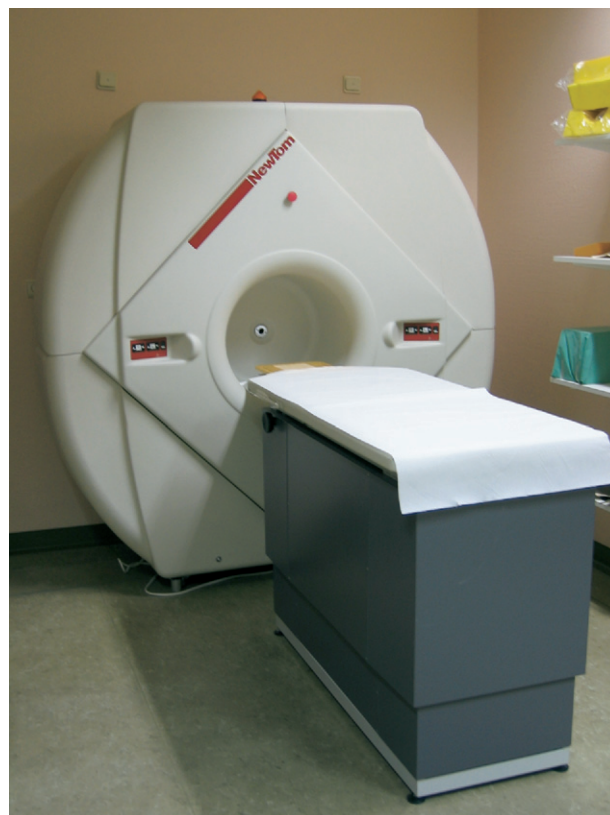

FIGURE 1. Digital volume tomography with the NewTom QR DVT 9000.

Eggers et al. Volumetric X-ray-Based Foreign Body Imaging. *J Oral Maxillofac Surg* 2007.

752 × 582 pixels is used for image data acquisition. Cassettes are placed in the middle of the gantry, with DVTs used as an integrated laser for positional adjustment. Before imaging starts, the current of the x-ray tube is adjusted automatically in a pre-scan so that the radiation dose is minimized. Hence, in this study, cool packs were placed around the boxes that contained foreign bodies to ensure sufficient absorption for automated x-ray tube adjustment. The voltage was always 110 kV; the maximum current of the system is specified as 15 mA.

The VOI measured was cylindrical with a height of 10 cm in longitudinal axis and a diameter of 12 cm. Resultant volume data sets consisted of pixels with an edge length of 0.3 mm in the *x-y* plane. Reconstruction was performed in the *z*-axis with slice thickness of 1 mm.

CT was performed with a 4-slice spiral CT scanner (Sensation 4; Siemens, Forchheim, Germany). The parameters of the imaging protocol were as follows: Collimation, 1 mm; voltage, 120 kV; and current, 100 mA. Image data were reconstructed at a slice thickness of 1 mm.

ANALYSIS

CT and DVT images were viewed using TomoCon 3.0 (TatraMed, Bratislava, Slovakia). Axial, coronal,

and sagittal planes were reconstructed from the image data and were shown simultaneously on the computer display (Fig 2). The gray scale value (in DVT) or Hounsfield units (HU; in CT) of every voxel could be displayed. The level and window settings of the display were adjusted to improve contrast between the foreign body and its surroundings. A foreign body was graded as visible when it could be identified in at least 2 of 3 orthogonal planes of the image. Evaluation was performed jointly by 2 observers, who were aware of the existence of the foreign bodies. They were free to adjust window and level settings as needed to identify the foreign bodies.

Results

VISIBILITY OF SUBSTANCES

On plain imaging in air, all large (approximately 20 mm³) foreign body samples were easily visible on CT and DVT images. In either imaging modality, they had a higher gray scale level than the surrounding air. Radio-opacity of substances in HU, as measured on CT, varied considerably between 30 and 3,070 HU (Table 2). In contrast, the radio-opacity of the surroundings was 0 HU for air, 70 HU to 176 HU for muscle, and 1,738 HU to 1,953 HU for cortical bone.

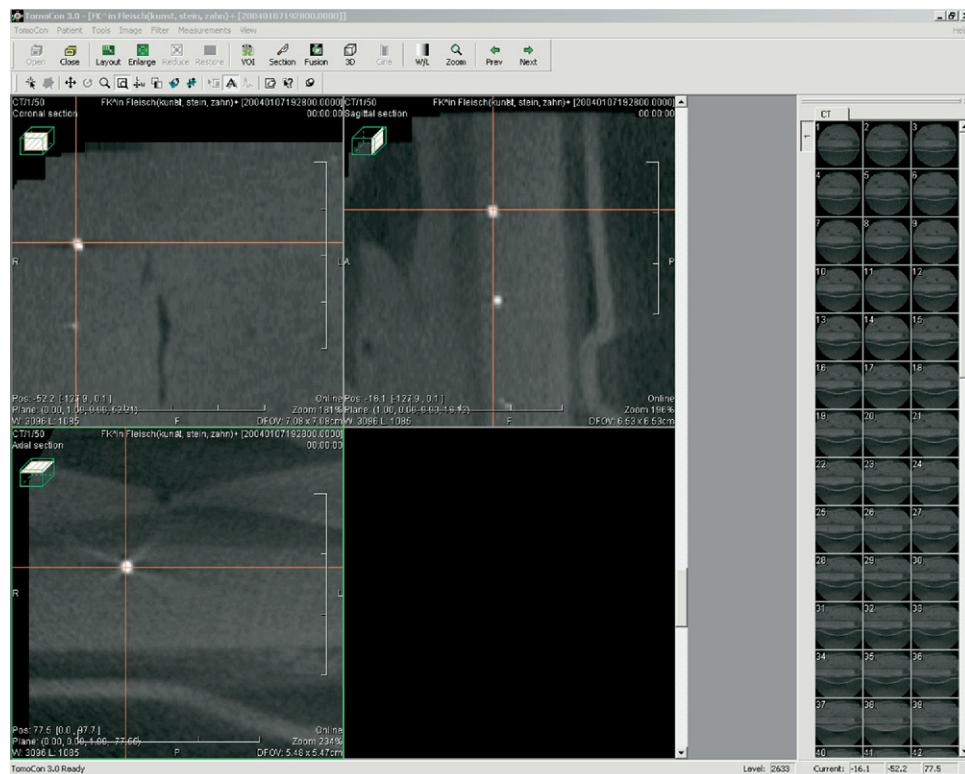


FIGURE 2. Screenshot of TomoCon 3.0 software: Triplanar (sagittal, coronal, and axial) view of a highly radio-opaque foreign body in muscle tissue, marked with cross-hairs. It is clearly visible in all planes.

Eggers et al. Volumetric X-ray-Based Foreign Body Imaging. *J Oral Maxillofac Surg* 2007.

Table 2. RADIO-OPACITY OF THE INVESTIGATED FOREIGN BODY SUBSTANCES AND SURROUNDINGS

Foreign Body	Opacity on CT Scan
Amalgam*	3040 . . . 3070 HU
Glass	2600 . . . 2900 HU
Asphalt	3000 . . . 3040 HU
Tooth	2500 . . . 3000 HU
Resin†	460 . . . 857 HU
Dry wood	30 . . . 130 HU

*Dispersalloy, Dentsply International, York, Philadelphia, PA.

†Durafil VS, Heraeus Kulzer, Hanau, Germany.

Eggers et al. *Volumetric X-ray-Based Foreign Body Imaging. J Oral Maxillofac Surg* 2007.

Foreign Body Visibility in Air

Imaging of rows of particles with decreasing volume in surrounding air yielded varying detection limits according to the substance and imaging modality used. In DVT imaging, the smallest amalgam particle was detectable, and most of the glass, asphalt, tooth, and resin samples were identified. The detection limit for wood was the highest. Detection of foreign bodies on CT imaging was similar. However, slightly smaller samples could be identified for most substances (Table 3).

Foreign Body Visibility in Muscle

When foreign bodies were imaged surrounded by muscular tissue with the use of DVT, the size of the smallest detected sample remained unchanged for amalgam (0.05 mm³) and asphalt (0.31 mm³), and rose slightly for glass (0.32 mm³ vs 0.23 mm³) and tooth (0.47 mm³ vs 0.37 mm³). Detection limits for resin and wood probes rose markedly (3.00 mm³ vs 0.39 mm³ and 18.5 mm³ vs 0.80 mm³, respectively).

In contrast, CT imaging in muscular tissue did not change the detection limits for amalgam, glass, asphalt, or tooth. The detection limit for resin (0.39

Table 3. VOLUME OF THE SMALLEST PARTICLES DETECTABLE IN AIR OR MUSCLE (mm³)

Substance	Imaging in Air		Imaging in Muscle	
	DVT	CT	DVT	CT
Amalgam*	0.05	0.05	0.05	0.05
Glass	0.23	0.13	0.32	0.13
Asphalt	0.31	0.12	0.31	0.12
Tooth	0.37	0.2	0.47	0.2
Resin†	0.39	0.22	3	0.39
Dry wood	0.8	0.8	18.5	2.75

*Dispersalloy, Dentsply International, York, Philadelphia, PA.

†Durafil VS, Heraeus Kulzer, Hanau, Germany.

Eggers et al. *Volumetric X-ray-Based Foreign Body Imaging. J Oral Maxillofac Surg* 2007.

Table 4. DETECTION OF FOREIGN BODIES AT THE BONE-MUSCLE MARGIN

Substance	Sample Size (mm ³)	Detected at the Bone-Muscle Margin in	
		CT	DVT
Amalgam*	2.8	Yes	Yes
Glass	2.83	Yes	Yes
Asphalt	2.8	Yes	Yes
Tooth	2.93	Yes	Yes
Resin†	3	No	No
Dry wood	2.75	No	No

*Dispersalloy, Dentsply International, York, Philadelphia, PA.

†Durafil VS, Heraeus Kulzer, Hanau, Germany.

Eggers et al. *Volumetric X-ray-Based Foreign Body Imaging. J Oral Maxillofac Surg* 2007.

mm³ vs 0.22 mm³) and dry wood (2.75 mm³ vs 0.80 mm³) rose less than with DVT imaging (Table 3).

Foreign Body Visibility on Bone

When located at the margin between muscle and bone, wood and resin particles measuring about 3 mm³ remained invisible on CT or DVT; all other substances were easily detected (Table 4).

Discussion

Foreign body imaging depends on the interaction of the physical principle of the imaging system and the properties of the foreign body. These must be compatible in such a way that a property of the foreign body is measured, resulting in a signal on imaging. A non-radio-opaque foreign body does not produce a signal on x-ray-based imaging. Hence, the composition of a foreign body determines whether it is visible on the image at all, and whether its size can influence the intensity and dimensions on imaging. Thus, a foreign body might be overlooked when one method is used and might be successfully detected with another method.^{2,3,5,22-25}

Certain circumstances can impair the imaging of a foreign body that is principally detectable by an imaging system. A foreign body might be invisible on ultrasound imaging because it is located deep in the body, beyond the range of the scanner. Another possible situation might be a foreign body that is not found by DVT because of the device's limited VOI. The environment can also impair the detection of a foreign body that may, for example, be hidden behind a structure that totally reflects the ultrasound waves. Artefacts (eg, metal artefacts in CT or MRI imaging) that are caused by the surrounding anatomy may also conceal the existence of an otherwise detectable foreign body.

The foreign body becomes visible when resultant imaging information differs from that of its surroundings. CT or DVT measures radio-opacity in the VOI. As with plain x-ray imaging, a highly radio-opaque foreign body is more easily detected in an environment that is surrounded by lower radio-opacity.

In this study, substances were evaluated that are typically found as foreign bodies in the head and neck region.^{1,3,26} In contrast to previous *in vitro* studies,^{1,8,25,27} we tried to provide a realistic environment for specimens so that a clinically relevant statement could be made about the imaging capabilities of investigated scanners. Foreign bodies are found in air-filled cavities like the maxillary sinus or stuck in soft tissues like the tongue, or they may be located on the surface of bone (eg, through intraoperative dislocation of an instrument).

The radio-opacity of substances was measured on CT image because HUs of the gray scale level image are calibrated. In contrast, the gray scale level image from the DVT provides no absolute measure of the physical properties of investigated matter. Foreign body substances can be divided into 2 groups: those with high radio-opacity in excess of 2,500 HU (amalgam, asphalt, tooth, glass), and those with radio-opacity below 1,000 HU (wood, resin). In air, samples of all substances were visible on CT and on DVT imaging. The minimum size of samples to be detected did not vary considerably. CT was marginally more sensitive than DVT (Table 3). However, when foreign bodies were immersed into muscle tissue, the radio-opacity of the surroundings was greater and more similar to that of the group of low-radio-opacity foreign bodies. The requirements for image contrast became greater. Hence, foreign body detection on DVT imaging was affected much more by this change in surroundings than was CT imaging, particularly in foreign bodies of low radio-opacity.

Finally, we wanted to investigate the most difficult situation for foreign body imaging—the location of the foreign body at a region with a steep gradient from high to low radio-opacity: the margin between bone and muscle. Foreign body samples with a size of approximately 3 mm³, which might be clinically relevant for surgical removal, were investigated. Foreign body samples of high radio-opacity could be identified with either method, and samples with low radio-opacity were invisible on both CT and DVT images (Table 4).

These observations are a result of the imaging process; a foreign body becomes visible when the gray scale level at its location differs sufficiently from that of the surroundings. Hence, when the radio-opacity of a foreign body and that of its surroundings converge, the gray scale level difference on imaging diminishes. Another factor is the inherently limited spatial resolu-

tion in volume imaging. The scanned volume is separated into discrete partial volumes (voxels). The voxel size was similar (ie, 0.3 × 0.3 × 1.0 mm) with both imaging modalities. If a foreign body fills only a part of the voxel, resultant gray scale value assigned to the voxel is a function of the average radio-opacity of that voxel. Hence, the contrast between the foreign body and its surroundings is reduced. This effect reduces particularly the detectability of smaller foreign bodies. DVT has a low level of contrast, with only 256 gray scale levels included in the resultant image. CT values (HU) have a range between −1,000 and 4,096 and provide far better contrast on the resultant image. This explains the difference in detection results.

CLINICAL RELEVANCE

CT is routinely used for foreign body imaging.²⁸⁻³⁰ Size and shape of the foreign body can be reproduced accurately.¹ Exact localization of the foreign body, prerequisite for successful surgical removal, is possible.³¹ It is less examiner-dependent than ultrasound^{1,7} and can be performed in patients with severe open injuries.

Basically, CT and DVT performed similarly in the imaging of foreign bodies under various conditions. Because the methods of image generation of DVT and CT are closely related, this was no surprise. However, the lower contrast of DVT images resulted in noticeable yet clinically irrelevant differences in the detection of foreign bodies.

In air, all substances were detected down to a volume of less than 1 mm³ with either method. Although DVT would detect highly radio-opaque samples of less than 1 mm³ located in muscle tissue, CT was clearly superior in the imaging of foreign bodies of low radio-opacity. However, this is no clinically relevant advantage of CT because both methods failed equally in the imaging of rather large samples of low radio-opacity located close to bone.

CT is not suitable for wooden foreign bodies.²⁹ With these, MRI is the better imaging modality, particularly in T1-weighted imaging.^{1,15,27} However, MRI is problematic in that ferromagnetic foreign bodies may cause artefacts^{1,8} and may become dislocated by the magnetic field of the MRI, with the consequence of additional injuries.⁵ Although the reduced image quality of DVT is without clinical relevance for foreign body imaging, DVT offers considerable advantages over conventional CT: first, the cost of the device is considerably lower, with prices below \$300.00. Second, a DVT can be run by a dentist or a physician with appropriate qualifications, but a CT can be used only by radiologists.

Finally, the dose of radiation the patient is exposed to with DVT is considerably lower than that associ-

ated with other imaging modalities. In recent studies, various devices for maxillofacial imaging based on the CBCT principle were compared. Although it was found that the radiation dose of CBCT devices from various manufacturers varied considerably,¹⁹ the exposure levels of CBCT imaging in general are between those of conventional radiographs and conventional CT imaging.³² In a comparison of DVT and digital panoramic imaging, the effective dose for the NewTom 9000 was 36.9 μSv , and for the OrthoPhos Plus DS, it was 6.3 μSv .¹⁸ However, because the effective dose of DVT is 8 to 10 times lower than that of conventional CT,³³ a considerable reduction in radiation exposure can be achieved.

DVT is a less costly alternative to CT that delivers a lower radiation dose to the patient. Because of its lower level of contrast, the image quality of DVT is not as good as that of CT. Resultant differences in detection threshold for highly radio-opaque foreign bodies are not clinically relevant. DVT is as suitable as CT for the detection of highly radio-opaque foreign bodies, as long as the limited VOI is not a limitation. The patient benefits from the considerably lower level of exposure to radiation. For the detection of foreign bodies of low radio-opacity, both methods are unsuitable, and MRI seems to be most appropriate.

References

- Oikarinen KS, Nieminen TM, Makarainen H, et al: Visibility of foreign bodies in soft tissue in plain radiographs, computed tomography, magnetic resonance imaging, and ultrasound: An in vitro study. *Int J Oral Maxillofac Surg* 22:119, 1993
- Clark JC, Jones JE: Tooth fragments embedded in soft tissue: A diagnostic consideration. *Quintessence Int* 18:653, 1987
- Dort JC, Robertson D: Nonmetallic foreign bodies of the skull base: A diagnostic challenge. *J Otolaryngol* 24:69, 1995
- Sitzmann F: Zahn-, Mund-, und Kiefererkrankungen, Atlas der bildgebenden Diagnostik (ed 1). München-Jena, Urban-Fischer-Verlag, 2000
- Booth PW, Schendel SA, Hausamen JE: Maxillofacial Surgery, vol 1. Edinburgh, Churchill-Livingstone, 1999
- Einisliadis G, Wagner A, Ploder O, et al: Computed intraoperative navigation guidance—A preliminary report on a new technique. *Br J Oral Maxillofac Surg* 35:271, 1997
- Manthey DE, Storrow AB, Milbourn JM, et al: Ultrasound versus radiography in the detection of soft-tissue foreign bodies. *Ann Emerg Med* 28:7, 1996
- Lagalla R, Manfre L, Caronia A, et al: Plain film, CT and MRI sensibility in the evaluation of intraorbital foreign bodies in an in vitro model of the orbit and in pig eyes. *Eur Radiol* 10:1338, 2000
- McKeown HF, Sandler PJ: A nasal foreign body detected on routine orthodontic radiographs. *Br Dent J* 185:390, 1998
- Maki K, Inou N, Takanishi A, et al: Computer-assisted simulations in orthodontic diagnosis and the application of a new cone beam X-ray computed tomography. *Orthod Craniofac Res* 6(suppl 1):95, 2003
- Yamamoto K, Ueno K, Seo K, et al: Development of dentomaxillofacial cone beam X-ray computed tomography system. *Orthod Craniofac Res* 6(suppl 1):160, 2003
- Nakata K, Naitoh M, Izumi M, et al: Effectiveness of dental computed tomography in diagnostic imaging of periradicular lesion of each root of a multiradical tooth: A case report. *J Endod* 32:583, 2006
- Hashimoto K, Kawashima S, Araki M, et al: Comparison of image performance between cone-beam computed tomography for dental use and four-row multidetector helical CT. *J Oral Sci* 48:27, 2006
- Guerrero ME, Jacobs R, Loubele M, et al: State-of-the-art on cone beam CT imaging for preoperative planning of implant placement. *Clin Oral Invest* 10:1, 2006
- Almog DM, LaMar J, LaMar FR, et al: Cone beam computerized tomography-based dental imaging for implant planning and surgical guidance. Part 1: Single implant in the mandibular molar region. *J Oral Implantol* 32:77, 2006
- Scarfe WC, Farman AG, Sukovic P: Clinical applications of cone-beam computed tomography in dental practice. *J Can Dent Assoc* 72:75, 2006
- Möbes O, Becker J, Schnelle C, Ewen K, et al: Strahlenexposition bei der digitalen Volumentomographie, Panoramaschichtaufnahme und Computertomographie. *Dtsch Zahnärztl Z* 55:336, 2000
- Ludlow JB, Davies-Ludlow LE, Brooks SL: Dosimetry of two extraoral direct digital imaging devices: NewTom cone beam CT and Orthophos Plus DS panoramic unit. *Dentomaxillofac Radiol* 32:229, 2003
- Ludlow JB, Davies-Ludlow LE, Brooks SL, et al: Dosimetry of 3 CBCT devices for oral and maxillofacial radiology: CB Mercuray, NewTom 3G and i-CAT. *Dentomaxillofac Radiol* 35:219, 2006
- Hashimoto K, Arai Y, Iwai K, et al: A comparison of a new limited cone beam computed tomography machine for dental use with a multidetector row helical CT machine. *Oral Surg Oral Med Oral Pathol Oral Radiol Endod* 95:371, 2003
- Eggers G, Mukhamadiev D, Hassfeld S: Detection of foreign bodies of the head with digital volume tomography. *Dentomaxillofac Radiol* 34:74, 2005
- Krimmel M, Corneus CP, Stojadinovic S, et al: Wooden foreign bodies in facial injury: A radiological pitfall. *Int J Oral Maxillofac Surg* 30:445, 2001
- Chisholm CD, Wood CO, Chua G, et al: Radiographic detection of gravel in soft tissue. *Ann Emerg Med* 29:725, 1997
- Kollarits CR, Di Chiro G, Christiansen J, et al: Detection of orbital and intraocular foreign bodies by computed tomography. *Ophthalmic Surg* 8:45, 1977
- Glatt HJ, Custer PL, Barrett L, et al: Magnetic resonance imaging and computed tomography in a model of wooden foreign bodies in the orbit. *Ophthalmic Plast Reconstr Surg* 6:108, 1990
- Yamaoka M, Furusawa K: The location of a disposable broken bur in the tongue. *Br Dent J* 175:55, 1993
- Wilson WB, Dreisbach JN, Lattin DE, et al: Magnetic resonance imaging of nonmetallic orbital foreign bodies. *Am J Ophthalmol* 105:612, 1988
- Chacko JG, Figueroa RE, Johnson MH, et al: Detection and localization of steel intraocular foreign bodies using computed tomography: A comparison of helical and conventional axial scanning. *Ophthalmology* 104:319, 1997
- Myllyla V, Pyhtinen J, Paivansalo M, et al: CT detection and location of intraorbital foreign bodies: Experiment with wood and glass. *ROFO Fortschr Geb Roentgenstr Nuklearmed* 146:639, 1987
- Lindahl S: Computed tomography of intraorbital foreign bodies. *Acta Radiol* 28:235, 1987
- Thiel H, Hassfeld S: Schnittbildagnostik in MKG-Chirurgie und Zahnmedizin (ed 1). Stuttgart, Georg Thieme Verlag, 2001
- Schulze D, Heiland M, Thurmann H, et al: Radiation exposure during midfacial imaging using 4- and 16-slice computed tomography, cone beam computed tomography systems and conventional radiography. *Dentomaxillofac Radiol* 33:83, 2004
- Tsiklakis K, Donta C, Gavala S, et al: Dose reduction in maxillofacial imaging using low dose cone beam CT. *Eur J Radiol* 56:413, 2005