Unlocking the secrets of the brain

A survey of the powerful tools that neuroscientists use to explore the living abode of mind, thought, and imagination

Phineas Gage may not be the most famous of the founding figures of neuroscience, but the luckless nineteenth-century American railroad builder still ranks in importance with such pioneers of brain research as Paul Broca and Carl Wernicke. Almost 150 years ago, a calamitous accidental explosion on the job rocketed a 13-pound iron rod upward into Gage's cheek, through his brain's frontal lobes, and out the top of his head, catapulting him into the annals of neuroscience.

The iron rod not only did not kill Gage, at first it did not even seem to have hurt him much, except that it cost him an eye. He moved and talked without difficulty, his memory was fine, he could still work, and his intellect appeared unaltered. But the brain damage Gage suffered did work a Jekyll-to-Hyde transformation on his personality. He changed from a kindly, cheerful, sensible, and intelligent family man, efficient and popular at work, into a profane and evil-tempered drinker, a pigheaded, willful, lazy, inconsiderate liar.

Luckily for neuroscience, his physician recorded Gage's personality changes, generating some of our earliest insights into how specialized functions are distributed in various parts of the brain. And Gage continues to contribute to neuroscience's growing body of knowledge. Scientists recently studied his skull using one of the many new methods and technologies for investigating the brain. Among the benefits of these technologies is that most of them are noninvasive—they pry open the black box of the brain, not with cranial saw and scalpel, but with mostly harmless waves from the electromagnetic spectrum. Many are mighty machines, some bulky and some sleek, that would look right at home on a *Star Trek* set. A few are surprisingly low-tech. But each is a revealing window on the complicated bundle of neurons that runs our lives, the organ that Nobel laureate James Watson has called "the most complex thing we have yet discovered in our universe."

by Tabitha M. Powledge

Gage's brain no longer exists, but for decades his damaged skull has been exhibited at a Harvard University museum. There it drew the attention of Antonio and Hanna Damasio, of the University of Iowa Hospitals and Clinics, and several of their colleagues. In 1994, with the help of imaging studies of Gage's skull, they proposed that the rod had damaged both the left and right prefrontal cortex of the roadbuilder's brain, diminishing his ability to make rational decisions and manage his emotions.

The Damasios based their conclusions partly on a dozen of their own patients who have frontal lobe damage and suffer Gagelike defects in rationality and the processing of emotions. But to help define the exact nature of the damage to Gage, the scientists also relied on imaging techniques that pinpoint their patients' lesions. The Damasio team carefully photographed Gage's skull from several angles, measured its landmarks (including the rod's entry and exit holes), and subjected the skull to a tried-and-true imaging method: X-rays. The Damasios chose a computer image of a real brain that matched the measurements of Gage's skull, and they calculated the rod's possible trajectories through the brain. One path—through the ventral and medial sectors of the frontal lobes—fit best with both the imaging data and contemporary accounts of Gage's behavior.

The Damasio study was unusual because it employed an old but reliable imaging method, albeit updated with much fancy computer manipulation of the X-ray images. Heavy computer modeling and number-crunching is a hallmark of today's imaging techniques, which began in the 1970s with computed tomography (CT), commonly called the CAT scan, a method of "slicing" thin brain sections with X-rays and then putting them back together as computer images known as tomographs.

The Damasios also are heirs to a brain study strategy pioneered by French researcher Paul Broca beginning in 1861, the year Phineas Gage died. Broca used postmortem studies of the brains of stroke victims to trace speech defects to damage in particular brain regions. The Damasios also have specialized in learning about the brain (including its language functions) by studying people with brain damage. "We use lesions to test hypotheses about the function of large-scale systems made up of cortical regions and subcortical nuclei," Antonio Damasio says. Individual brain regions exhibit parts or components of functions, such as pronouncing a word, but complex functions, such as constructing a response to something someone else has said and expressing it as a sentence, emerge from a large network of these regions.

The lesion study method continues to work brilliantly today because researchers have amassed large patient registries—the Damasios

alone have enrolled more than 2000 people—and have borrowed sophisticated neuropsychological testing tools from cognitive science. Researchers also possess space-age machines that Broca would envy, such as magnetic resonance imaging (MRI) machines, that permit them to analyze neuroanatomy in fine detail. Antonio Damasio says, "With MRI you can cut in any direction you want."

Magnetic resonance imaging

MRI uses a magnetic field and radio waves to produce detailed images of brain anatomy quickly. The technique employs magnets to detect signals from the nuclei of hydrogen atoms, which consist of single protons that spin like tops. In a strong magnetic field, the protons become aligned and spin in the same direction. If the aligned protons are then zapped with radio waves at a certain frequency, the spinning hydrogen nuclei tip over and wobble. Turn off the radio wave, and the nuclei return to their upright state while emitting weak radio signals.

Scientists can deduce the amount of hydrogen in a sample by measuring the intensity of these radio signal emissions. When the "sample" is a person positioned within the immense magnetic coil of an MRI scanner, the varying concentrations of hydrogen in the body generate traces that can be analyzed by the computer and assembled into high-resolution images of the tissues and organs within. Different tissues in the brain,such as gray matter and white matter, have different chemical compositions and, therefore, different concentrations of hydrogen. Consequently, they absorb and release radio waves in different ways. The corpus callosum, which joins the two hemispheres, for example, is mainly white matter, and so it can be distinguished from the cerebellum, which is mainly gray matter. Magnetic resonance images can be three-dimensional pictures of a whole brain in any orientation or can be carved into two-dimensional "slices" of particular brain regions.

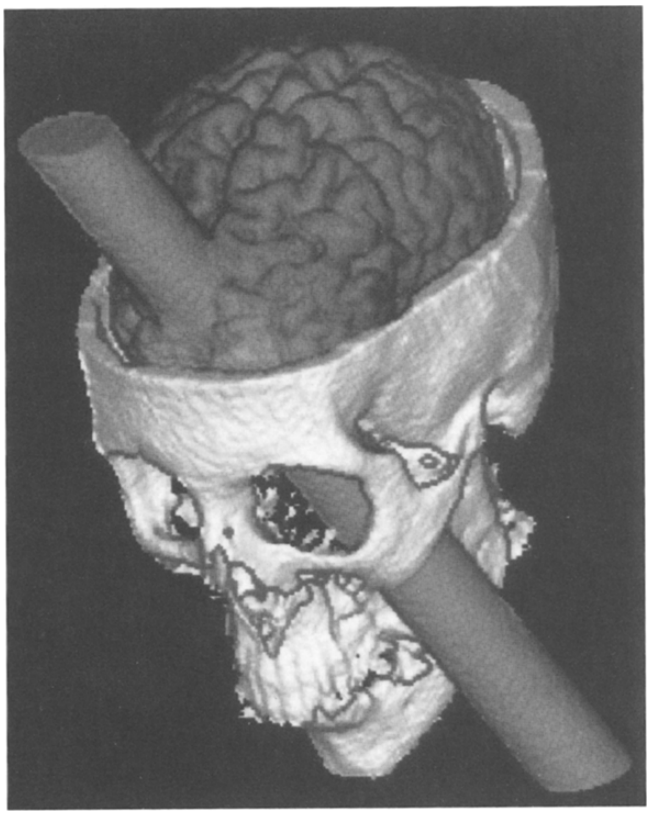

A computer-generated image of the skull of Phineas Gage shows the likely trajectory of an iron rod that passed through his brain. Studies of Gage following his nonfatal accident led to early understandings of how certain parts of the brain control behavior. Image from: H. Damasio et al., 1994. The return of Phineas Gage. *Science* 264: 1102–1105. Department of Neurology and Image Analysis Facility, the University of Iowa.

The magnetic field in an MRI machine is extremely powerful, about equal to those of the electromagnets that junkyard operators use to pick up discarded cars. This force—nearly 40,000 times as strong as Earth's own magnetic field—appears to pose no hazard to human flesh. But MRI machines can still be dangerous and even fatal. They have sucked up a hospital's floor buffers and mop buckets, transformed oxygen bottles into death-dealing missiles, and trashed both cardiac pacemakers and credit cards.

MRI, like all brain imaging techniques, has many medical applications. It can help neurologists to pinpoint brain damage shortly after a stroke. It is also the method of choice for diagnosing many other kinds of brain injuries—for example, the damage that prizefighters incur during a lifetime in the ring. MRIs have revealed specific brain abnormalities in some children exposed prenatally to alcohol, helping researchers to associate particular anatomical peculiarities (like reductions in the size of the brain, both overall and in specific regions, such as the cerebellum and basal ganglia) with cognitive symptoms such as memory deficits. And MRIs have demonstrated that the shrunken brains of adult heavy drinkers can recover lost tissue volume when the drinkers abstain.

MRI also is helping neuroscientists to sort out other kinds of brain functions that shape our lives. Elena Plante and her colleagues at the University of Arizona have been using MRI to explore the relations between neuroanatomic, behavioral, and familial components of developmental language disorder. They have discovered neuroanatomic traits that are uncommon although not grossly abnormal—atypical volumes in certain brain regions, atypical patterns of gyri and sulci on the surface—that they believe occurred during fetal development. Plante cautions, however, that the relation between these features and a par-

Exploring the brain

In this two-part series, the author covers 13 techniques for delving into the brain:

Part I

1. X-rays. This old, reliable method can be combined with computer manipulation of images to create complex renderings of the brain.
2. Computed tomography (CT). Also known as the CAT scan, this method uses X-rays to "slice" thin sections of the brain, then puts the slices together to create computer images known as *tomographs*.
3. Magnetic resonance imaging (MRI). This technique uses a magnetic field and radio waves to produce detailed brain images quickly.
4. Magnetic resonance spectroscopy (MRS). In use for about a decade now, MRS uses proton signals from brain chemicals to map gray matter.
5. Functional magnetic resonance imaging (fMRI). The newest of the magnetic resonance imaging techniques, fMRI zeros in on increases in proton radio signals that occur when the level of blood oxygen goes up in particular parts of the brain—a sign of heightened brain activity.
6. Lesion studies. Research into how brain damage correlates with loss of specific brain functions has helped scientists to map the functional role of various brain areas.
7. Postmortem studies. Examinations and comparisons of damaged and healthy brains after death have revealed some details about brain function.

Part II

8. Positron emission tomography (PET). The first scanning method to yield information about brain function rather than simply anatomy, PET measures concentrations of positron-emitting radioisotopes in living tissue, and computer analysis turns this information into colorful brain images based on the patterns of radioactivity.
9. Single photon emission computed tomography (SPECT). This method is similar to PET in that it images blood flow in the brain and also uses radioactive tracers, but it detects a different type of photon than does PET.
10. Electroencephalogram (EEG). This technique uses electrodes placed on the scalp to measure, and record on moving graph paper, the amount and type of electrical activity in the brain.
11. Low-tech indirect studies. Using ordinary medicine cabinet items like cotton swabs, scientists have been able to deduce brain activity from patients' subjective reports of what they are experiencing.
12. Magnetoencephalography (MEG). Similar to EEG, MEG measures changes in magnetic fields created by the brain's electrical currents; researchers have combined it with MRI to produce a three-dimensional map of brain areas activated by touching the fingers of one hand.
13. Transcranial magnetic stimulation (TMS). An experimental use of magnetic pulses to map the brain, TMS reportedly can cause muscles to move and moods to change dramatically by producing tiny temporary lesions that affect brain function and allow scientists to locate the physical site of sensations, feelings, and frames of mind.

ticular language disorder "is not a simple one-to-one proposition."

MRIs also have provided substantial evidence that severe emotional trauma actually damages the brain, decreasing the volume of the left and right hippocampus regions. These seahorse-shaped structures in the center of the brain are part of the limbic system and are essential in learning and memory, especially the transfer of short-term memories into permanent storage. Decrease in the size of the hippocampus shows up in adult victims of severe childhood sexual abuse as well as in veterans with combat-related post-traumatic stress disorder. These people also tend to have defects in short-term memory.

MRIs also confirm that the brains of musicians are different from other people's. The planum temporale of the left brain hemisphere, a flat and usually quarter-sized temporal lobe structure associated with the processing of sounds, is much larger in musicians than in the nonmusical—and largest of all in musicians with perfect pitch. Especially striking is the fact that the enlarged area is on the brain's left, "verbal" side, rather than the right hemisphere, long thought to be the chief seat of musical ability. The work was done at Heinrich Heine University in Düsseldorf, Germany. Senior author Gottfried Schlaug, now at Beth Israel Hospital in Boston, says that the study suggests that perfect pitch may be an innate ability, tied to development of the planum temporale at around week 30 of gestation.

Imaging techniques have also been employed for studies of the aging brain and for identifying brain differences between the sexes. MRIs have shown not only that the aging brain loses volume, but also that the patterns of loss differ in men and women. Men tend to lose volume all over the brain and in the two lobes most associated with cognitive skills, the frontal and temporal lobes. Women tend to lose more volume from the hippocampus and parietal lobes.

Magnetic resonance imaging to probe brain function

Standard MRI presents images of brain anatomy only, providing few clues about what is going on in the brain at a given moment. So scientists have devised several ways of peering at brain function as well as structure. Some are variations on magnetic resonance technology.

MRI observations derive from large hydrogen nuclei signals in brain water. But smaller signals from protons in other compounds and from other atomic nuclei can also be detected in living tissue, including the human brain. Study of these small signals is called magnetic resonance spectroscopy (MRS) to distinguish it from water proton MRI. MRS's virtue is that it provides chemical (and therefore physiological) information about the tissue under investigation, disclosing the presence of molecules of potassium, sodium, carbon, and other metabolites that reveal something about the state of the tissue. MRS has been in use for more than a decade, exploring brain biochemistry in schizophrenia and bipolar disorder; helping to plan brain surgery; and diagnosing coma, dementia, oxygen deprivation in newborns, stroke, and head injury.

Conventional MRI can detect brain tumors, but a biopsy is usually necessary to determine a tumor's type and whether it is malignant. By contrast, MRS can distinguish between different types of brain tumors, a technique that could enable patients to avoid sometimes risky biopsies. Using noninvasive MRS, Douglas Arnold and his colleagues at McGill University were able to classify 90 out of 91 tumors correctly because different tumor types have different characteristic metabolite patterns.

One disadvantage of MRS is that finding the tiny chemical signals usually requires minutes rather than the seconds a standard MRI takes. But MRS's ability to measure biochemistry directly in the human brain is unique. In addition, it can be combined with the anatomical images generated by conventional MRI to yield additional useful details. The two can even be done in the same machine.

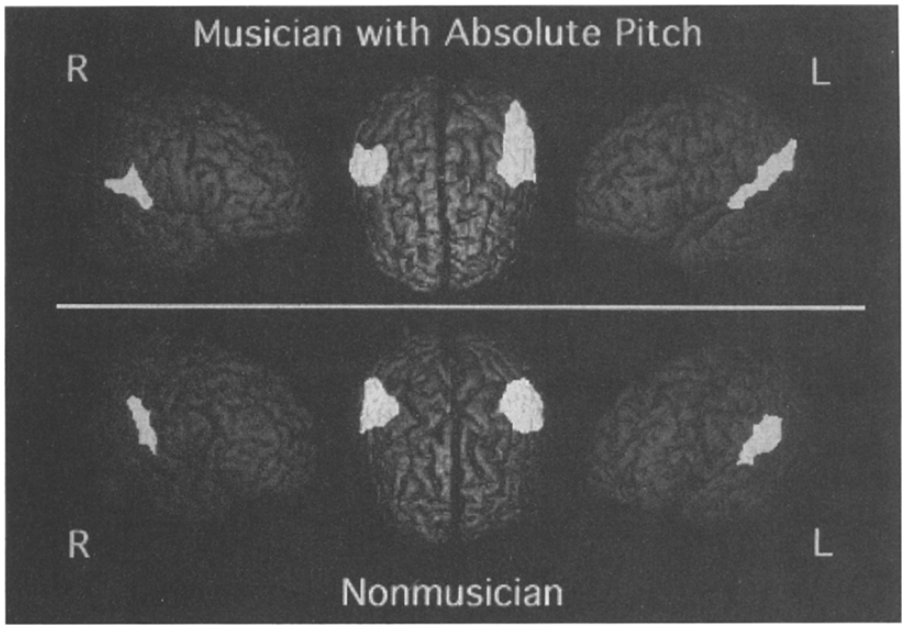

Enlargement of the planum temporale is evident in the left hemisphere of the brain of a musician with perfect pitch (upper row), compared with that of a nonmusician (bottom row). This enlargement of the planum temporale, revealed by MRI, suggests that perfect pitch is an innate ability. Photo: Gottfried Schlaug.

The newest, and perhaps brightest, star in the cluster of magnetic resonance techniques is functional magnetic resonance imaging (fMRI), in which the radio signals from protons increase when the level of blood oxygen goes up in particular regions of the brain. Oxygen level is an index of those regions' activity—that is, of the brain's response to thought and movement. Researchers can "scroll" through fMRI scans on a computer monitor or videotape, obtaining evidence about brain activity over time.

Like all the brain imaging methods, fMRI has many medical applications, such as providing guidance to brain surgeons. But, like the others, it is also used to map normal brain functions, such as how visual stimuli are processed and how tastes are perceived. Some experts expect fMRI to be the dominant tool for brain mapping for the next several years.

Thanks to fMRI, scientists may have located the overseer region that supervises nervous impulses in and out of a kind of buffer system called working memory, where information is temporarily stored and manipulated. They have hypothesized that working memory (often referred to as short-term, or telephone number, memory) must possess what they call a "central executive system" (CES) that acts as traffic cop. To find this system, Mark D'Esposito and his colleagues at the University of Pennsylvania Medical Center gave their study subjects two easy tasks to perform. One was to identify vegetables on a list of miscellaneous words; the other was to specify which of two squares contained a dot in the same location as a target square that had been rotated in space.

When subjects carried out the assignments separately, fMRI revealed activation in the left temporal lobe for the semantic task and in the

parietal and occipital regions in the back of the brain for the dot-location task. When subjects had to perform both tasks at the same time, shuttling data in and out of short-term memory, the prefrontal cortex in the front of the brain also lit up, along with the front of the cingulate gyrus, a C-shaped component of the limbic system. "[O]ur findings support the hypothesis that dorsolateral prefrontal cortex is involved in the allocation and coordination of attentional resources," the researchers wrote in the 16 November 1995 issue of *Nature*. "Moreover, recruitment of anterior cingulate and dorsolateral prefrontal cortex, which are anatomically interconnected, suggests that the CES may comprise several components."

Evidence obtained with this technique is also persuading scientists to revise some long-held beliefs about what various parts of the brain do. Using fMRI, researchers have confirmed other studies suggesting that the cerebellum, the wrinkled ball of tissue about the size of a fist that snuggles under the cortex, does more than just manage movement, the job that neuroscientists classically attributed to it. The cerebellum also appears to handle at least some sensory information, such as the texture and shape of objects. The cerebella of subjects undergoing fMRI were at their liveliest when the subjects were trying to distinguish between types of sandpaper and the shapes of small balls simply by feeling them with their fingers.

Functional MRI also has pinpointed the site of the human "interval timer," which helps us keep track of short periods of time. Warren Meck of Duke University reports that it resides in the striatum, deep within the brain. He and his colleagues found it by asking volunteers to squeeze a ball every 11 seconds and watching to see which part of the brain lit up during the exercise.

Imaging systems are a favorite tool for studying how language relates to the brain, and fMRI is no exception. It has, for example, provided support for the growing suspicion that what underlies dyslexia—problems with reading, writing, and spelling—may be defects in timing ability, not just language.

Using fMRI, Guinevere Eden and her colleagues at the National Institute of Mental Health have found that dyslexic men are somewhat less able to detect visual motion than are nondyslexic men. These men also fail to activate the brain region that responds most strongly to visual motion. Known as V5, it is located in the cortex at the junction of the occipital and temporal lobes. The researchers speculated in the 4 July 1995 issue of *Nature* that this subtle defect in perceiving visual motion actually indicates a more general deficit in timing ability. The deficit could include relative insensitivity to rapid changes in the auditory system, which might explain, for example, why dyslexics find it hard to hear the differences between consonants. The researchers also suggest that V5 inactivation might serve as an early biological marker for dyslexia that is completely unrelated to reading itself. This finding might make it possible to spot potential dyslexics before first grade and so stave off school failures.

Although fMRI is the most fashionable imaging technique right now, several additional ways of looking at the brain also possess distinct advantages. Like fMRI, many of them permit scientists to study the living brain at work. Part II of this article will look at six more of these techniques. ❑

Tabitha M. Powledge, a frequent contributor to BioScience, *is the author of* Your Brain: How You Got It and How It Works, *published by Charles Scribners' Sons, New York, 1995.*