

Junji Furusez

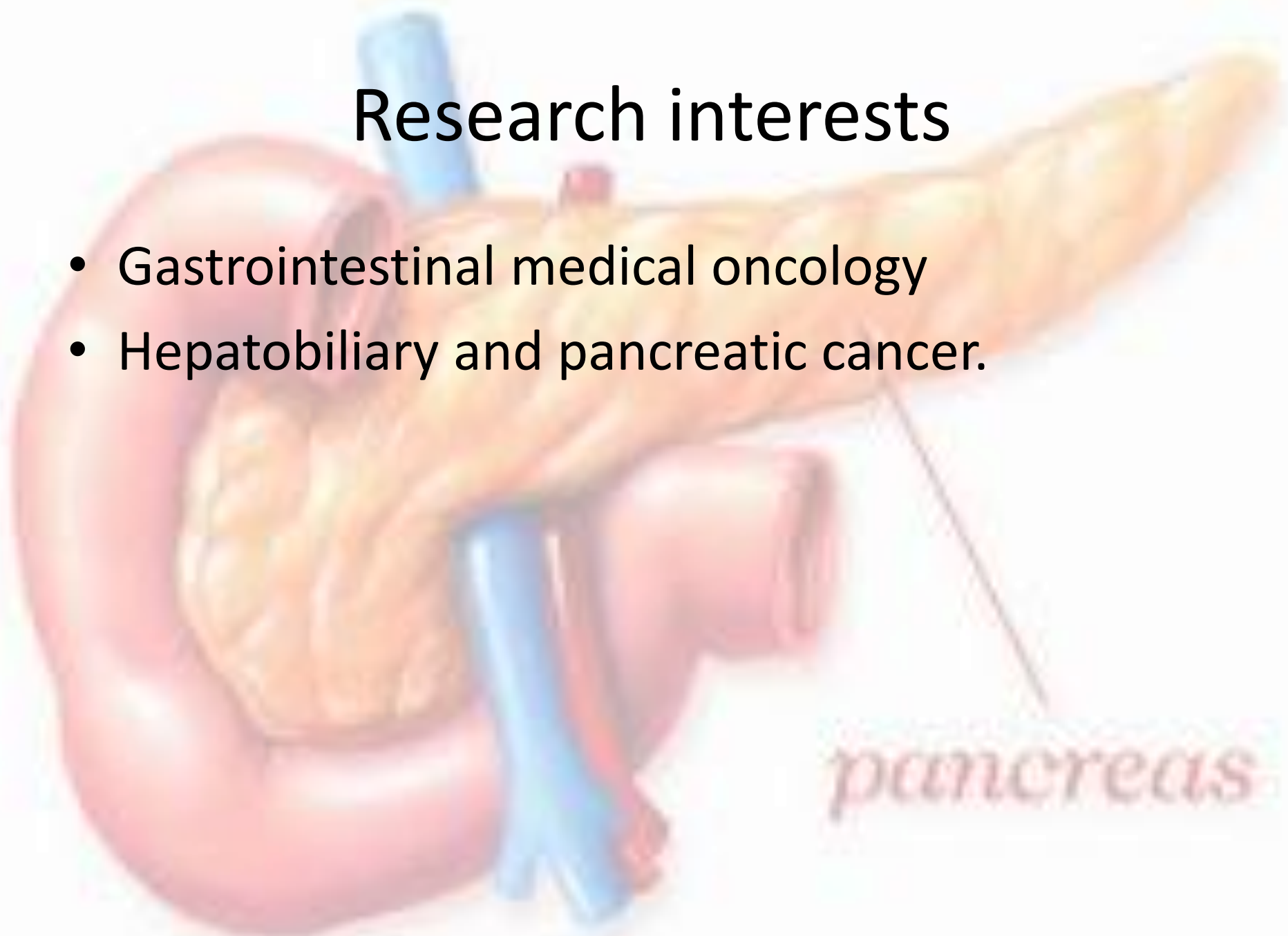

Junji Furusez
Professor
Department of Internal
Medicine
Kyorin University
Japan

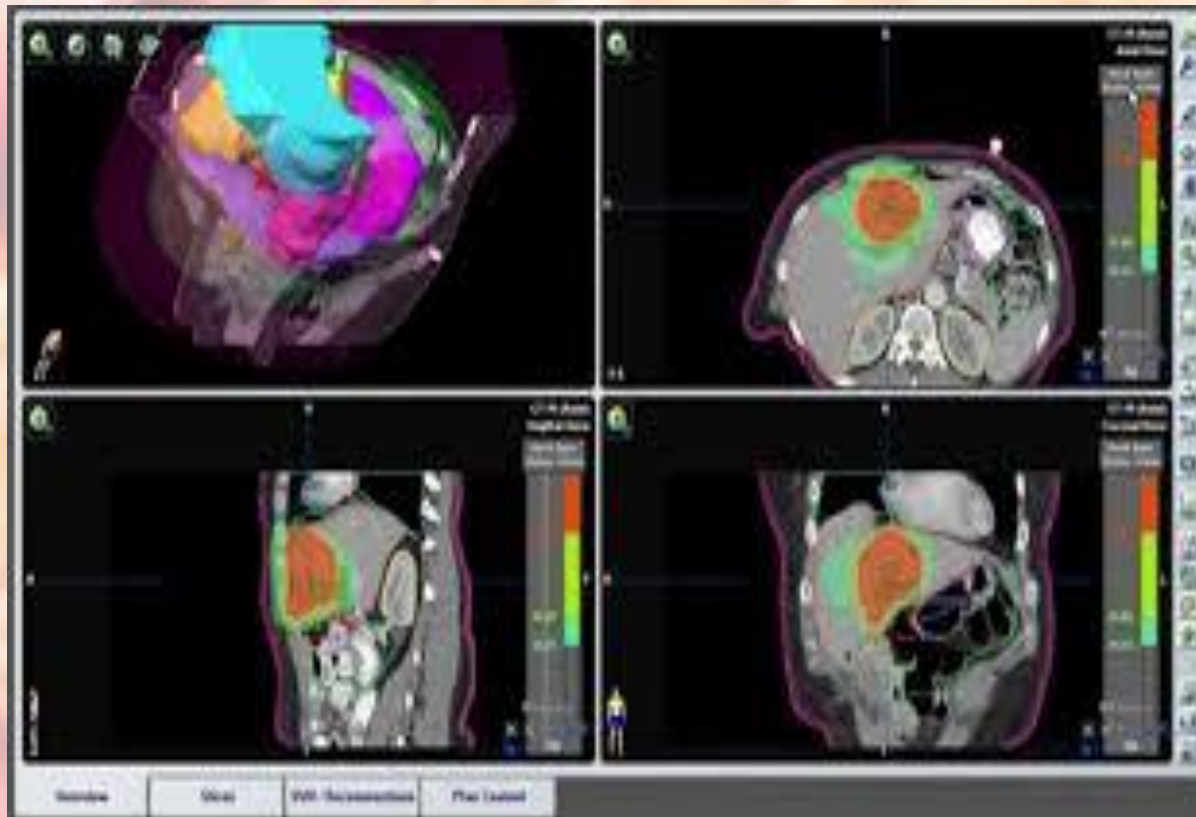
pancreas

Research interests

- Gastrointestinal medical oncology
- Hepatobiliary and pancreatic cancer.

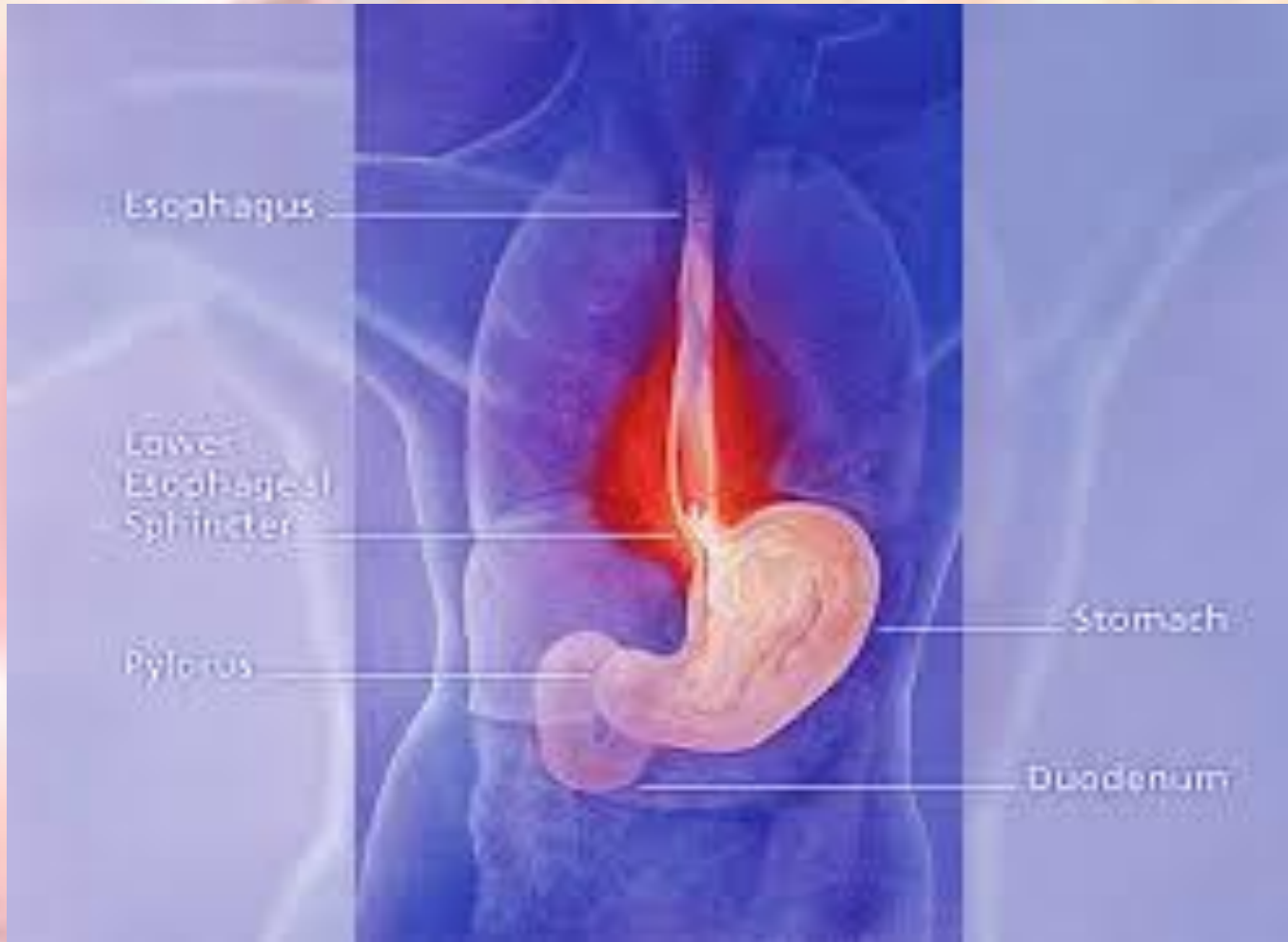

Gastrointestinal medical oncology



areas

Gastric overview



eads

Pancreatic cancer over view

Pancreatic cancer is aggressive with few symptoms until the cancer is advanced. Symptoms may include abdominal pain, weight loss, diarrhea, and jaundice. Treatments include surgery, chemotherapy, and radiation

An anatomical illustration of the human torso showing the abdominal cavity. The pancreas is highlighted in a light yellow color and is located behind the stomach. The word "pancreas" is written in a stylized, lowercase font in the bottom right corner of the image, with a thin line pointing to the organ. Other visible organs include the stomach, liver, and gallbladder.

pancreas

Hepato-biliary diseases

An anatomical illustration of the human liver and biliary system. The liver is shown in a reddish-brown color, with the gallbladder and bile ducts highlighted in yellow. The pancreas is shown in a light pink color. The illustration is set against a light blue background with a faint grid pattern. The word "pancreas" is written in a stylized, red font at the bottom right of the illustration.

- Hepato-biliary diseases affect the liver and/or biliary tract, and are studied in the branch of medicine called Hepatology.
- Acute hepatitis A
- Acute hepatitis B
- Acute hepatitis C
- Acute Hepatitis D – this is actually a superinfection with the delta-agent in a patient already infected with hepatitis B
- Acute hepatitis E
- Chronic viral hepatitis
- Other viral hepatitis viruses may exist but their relation to the disease is not firmly established like the previous ones (Hepatitis F, GB virus C, Hepatitis X)

Important publications

- **Article: [EBM-based Clinical Guidelines for Pancreatic Cancer \(2013\) Issued by the Japan Pancreas Society: A Synopsis.](#)**
- **Article: [Phase II study of FOLFIRINOX for chemotherapy-naïve Japanese patients with metastatic pancreatic cancer](#)**
- **Article: [Guidance for peptide vaccines for the treatment of cancer](#)**

Important publications

- **Article:** [Multicenter retrospective analysis of systemic chemotherapy for advanced neuroendocrine carcinoma of the digestive system](#)
- **Article:** [Japanese phase I study of GC33, a humanized antibody against glypican-3 for advanced hepatocellular carcinoma.](#)
- **Article:** [Cisplatin and gemcitabine for advanced biliary tract cancer: a meta-analysis of two randomised trials.](#)

THANK YOU

pancreas

An anatomical illustration of the pancreas, a long, yellowish, segmented organ. It is shown in a lateral view, with its head on the left and tail on the right. The pancreas is surrounded by the duodenum, a C-shaped part of the small intestine. Several blood vessels are visible: a blue vessel (likely the splenic vein) runs along the top of the pancreas, and another blue vessel (likely the superior mesenteric vein) runs along the bottom. A red vessel (likely the superior mesenteric artery) is also visible. The word "pancreas" is written in a stylized, italicized font at the bottom right, with a thin line pointing to the organ.