

1-1-2010

# A Guide to Scleral Lens Fitting

Eef van der Worp

*College of Optometry, Pacific University*

---

## Recommended Citation

van der Worp E. A Guide to Scleral Lens Fitting [monograph online]. Scleral Lens Education Society; 2010. Available from: <http://commons.pacificu.edu/mono/4/>.

This Book is brought to you for free and open access by the Pacific University Libraries at CommonKnowledge. It has been accepted for inclusion in Books and Monographs by an authorized administrator of CommonKnowledge. For more information, please contact [gilmani@pacificu.edu](mailto:gilmani@pacificu.edu).

---

# A Guide to Scleral Lens Fitting

## **Description**

This guide is based on an extended literature search on the subject of scleral lens fitting and provides an overview of the latest knowledge and understanding on this exciting vision correction method.

This guide serves as an introduction to scleral shape, scleral topography and scleral lens design as well as a generic guide to fitting scleral lenses to help the practitioner get more comfortable with the concept of scleral lenses. It provides a general overview, supported by the main experienced scleral lens fitters worldwide. Its goal is to give practitioners a framework to oversee and integrate scleral lens fitting into their practices. Being a general overview, it can never cover all of the specific scleral lens designs available and cannot be a fitting guide for all lens types available.

Modern scleral lens fitting still is in its infancy, which makes it a modality with great potential. However, fitting scleral lenses is not very black-and-white, and many differences exist among fitters, cultures, manufacturers and countries. This clinical guide tries to find “common ground” among the mentioned philosophies. For specific lens fitting rules and guidelines, the lens manufacturer and the laboratory’s consultant and specialists have the most knowledge regarding their specific lens design, which practitioners should take advantage of.

*This publication is supported by an unrestricted educational grant from Bausch + Lomb.*

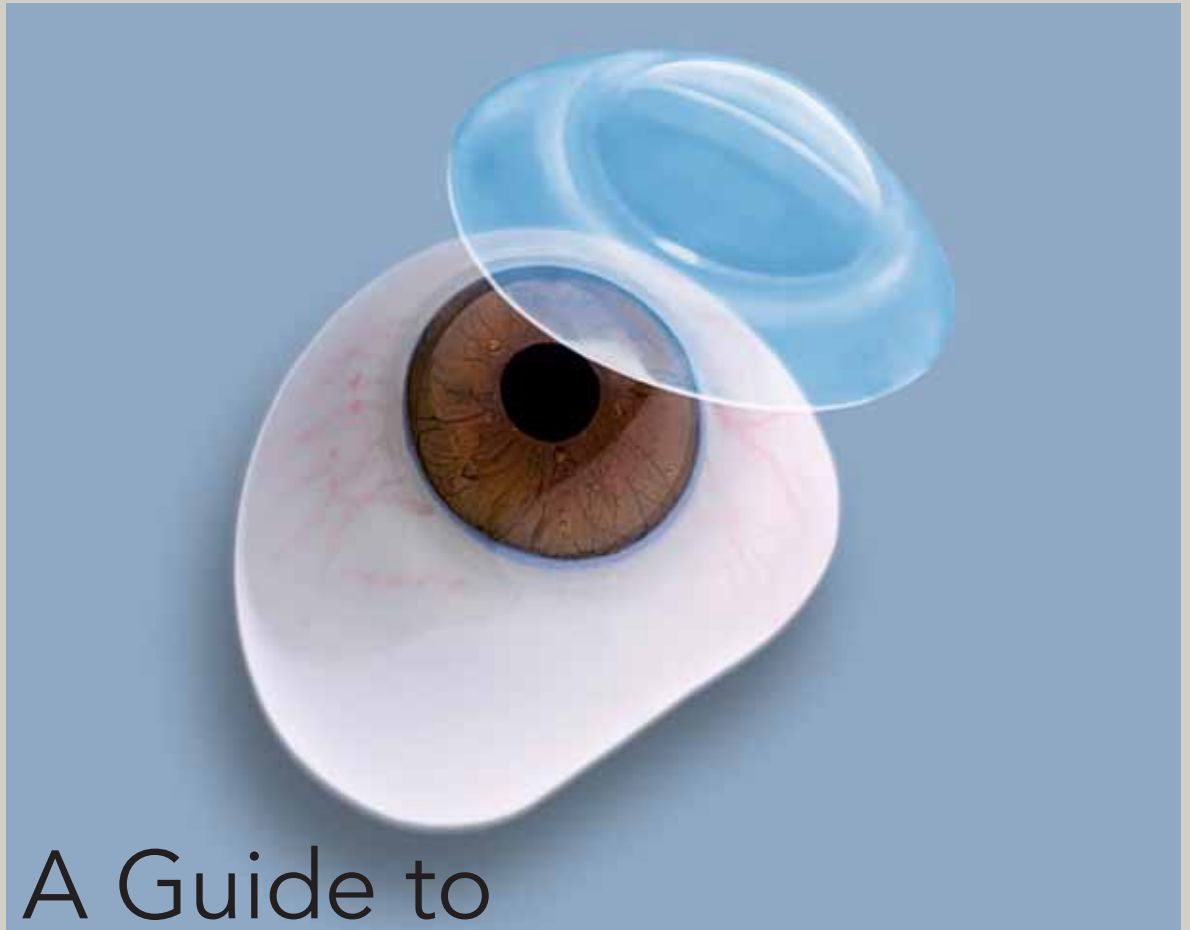## **Disciplines**

Optometry

## **Comments**

**Eef van der Worp, BOptom, PhD FAAO FIACLE FBCLA FSLs – Washington DC (USA)/Amsterdam (the Netherlands)**

Eef van der Worp is an educator and researcher in the contact lens field. Eef received his optometry degree from the Hogeschool van Utrecht in the Netherlands (NL) and his PhD from the University of Maastricht (NL). He is affiliated with [Pacific University College of Optometry](#) (USA) and the [University of Maastricht](#) and is a visiting lecturer to many optometry schools. He resides both in Amsterdam (NL) and in Washington DC (USA).



A Guide to

# Scleral Lens Fitting

Eef van der Worp

optometrist, PhD



# A Guide to Scleral Lens Fitting

## Contents

Preface .....	IV
I. Introduction .....	1
II. Anatomy and Shape of the Anterior Ocular Surface .....	8
III. Scleral Lens Design .....	16
IV. A Five Step Fitting Approach .....	23
V. Managing Scleral Lens Wear .....	38
References .....	50

## Editorial Board

### Editor

Eef van der Worp, BOptom, PhD FAAO FIAACLE FBCLA FSLs – Washington DC (USA)/Amsterdam (the Netherlands)

Eef van der Worp is an educator and researcher in the contact lens field. Eef received his optometry degree from the Hogeschool van Utrecht in the Netherlands (NL) and his PhD from the University of Maastricht (NL). He is affiliated with Pacific University College of Optometry (USA) and the University of Maastricht and is a visiting lecturer to many optometry schools. He resides both in Amsterdam (NL) and in Washington DC (USA).

Pacific University College of Optometry, Forest Grove, OR (USA)



Pacific University has been active in contact lens research over the last two decades and has been on the forefront of scleral lens education and research. Special thanks are due to Tina Graf from the Aalen University in Germany, as she was the study coordinator of the special project at Pacific University on anterior ocular surface shape. Furthermore, special thanks are due to the contact lens team at Pacific University College of Optometry, Patrick Caroline, Beth Kinoshita, Matthew Lampa, Mark André, Randy Kojima and Jennifer Smythe.

### International Board

Stephen P. Byrnes, OD FAAO – Londonderry, NH (USA)

Steve Byrnes received his optometric training at The New England College of Optometry in Boston, MA (USA) and maintains a primary care private practice with specialization in contact lenses in Londonderry, NH (USA). He is an academic education consultant to many schools and colleges of optometry in the USA for Bausch + Lomb. He lectures internationally on rigid gas permeable contact lens design, fitting and problem-solving.

Gregory W. DeNaeyer, OD FAAO FSLs – Columbus, OH (USA)

Greg DeNaeyer is the clinical director of Arena Eye Surgeons located in Columbus, OH (USA), specializing in scleral lens fitting. He is a Fellow of the American Academy of Optometry and a contributing editor for *Contact Lens Spectrum*. He is also a contributor to *Review of Cornea and Contact Lenses* and *Optometric Management*. He is the president of the Scleral Lens Education Society.

Donald F. Ezekiel, AM DipOpt DCLP FACLP FAAO FCLSA – Perth (Australia)

Don Ezekiel graduated from the University of Western Australia in Optometry in 1957. He completed his post graduate studies in London (UK). While in London, he worked in the practice of contact lens pioneer Dr. Joseph Dallos, who taught him how to research and influenced him to make contact lenses for his patients. In 1967 he started a contact lens laboratory in Australia. He is an expert and a pioneer in scleral lens fitting.

Greg Gemoules, OD – Coppell, TX (USA)

Greg Gemoules received his optometry degree from the Illinois College of Optometry (USA). He moved to Texas and established his practice in Coppell, a growing suburb of Dallas (USA). He has established a large specialty lens practice and has several publications in the peer-reviewed literature. He is a pioneer in the use of optical coherence tomography in the fitting of scleral lenses and has lectured at a number of conferences on the topic.

Tina Graf, BSc – Trier (Germany)

Tina Graf finished her optics degree in 2004, after which she enrolled in the optometry school at Aalen University in Germany, graduating in 2010. During and after her studies she worked at the university hospital in Heidelberg and in different contact lens practices. She conducted a research project at Pacific University College of Optometry on anterior ocular surface shape and presented her data in her thesis and at international meetings.

Jason Jedlicka, OD FAAO FSLs – Minneapolis, MN (USA)

Jason Jedlicka is the founder of the Cornea and Contact Lens Institute in Minneapolis, MN (USA), a referral practice specializing in specialty contact lenses, treatment and management of corneal disease, contact lens research and education. He is treasurer of the Scleral Lens Education Society.

Lynette Johns, OD FAAO

Perry Rosenthal, MD

Deborah Jacobs, MD – Boston, MA (USA)

Lynette Johns has been the senior optometrist at the Boston Foundation for Sight since 2005. She is a graduate of the New England College of Optometry where she completed a residency in cornea and contact lenses. She is an adjunct clinical faculty member at the New England College of Optometry (USA) and a fellow of the American Academy of Optometry.

Perry Rosenthal, founder of the Contact Lens Service at Massachusetts Eye and Ear Infirmary, Polymer Technology Corporation (the Boston Lens Products) (purchased by Bausch + Lomb in 1983) and Boston Foundation for Sight, is a pioneer in the development of advanced scleral lenses/prosthetic devices for the management of corneal disorders. He often guest lectures on ocular surface disease, scleral lenses and neuropathic pain at national and international professional meetings.

Deborah Jacobs has been Medical Director at Boston Foundation for Sight since 2006. She earned her MS from Oxford University as a Rhodes Scholar and her MD from Harvard Medical School (USA). She completed her ophthalmology residency and fellowship in Cornea and External Disease at Massachusetts Eye & Ear Infirmary, where she is now a faculty member. She is an assistant clinical professor of Ophthalmology at Harvard.

**Craig W. Norman FCLSA – South Bend, IN (USA)**

Craig Norman is director of the Contact Lens Section at the South Bend Clinic in South Bend, IN (USA). He is a fellow of the Contact Lens Society of America and an advisor to the GP Lens Institute. He is a clinical and educational consultant to Bausch & Lomb Incorporated.

**Jan Pauwels – Antwerp (Belgium)**

**Jacob H. van Blitterswijk – Arnhem (the Netherlands)**

Jan Pauwels, optometrist, is owner of Lens Optical Technology and is working as a contact lens practitioner in three university hospitals in Belgium, UZA Antwerp, UZG Gent and CHU Liège. He completed his study in optics and optometry in Brussels (Belgium), and spends much of his time in fitting contact lenses on irregular corneas.

Jaap van Blitterswijk is a contact lens practitioner, designer, manufacturer and owner of several Dutch contact lens practices. He completed his study in Optics, Optometry and Contact Lenses in Rotterdam, the Netherlands. Jaap spends much of his time in educating specialty lens fittings.

**Kenneth W. Pullum, BSc FCOptom DipCLP FBCLA – Hertford (United Kingdom)**

Ken Pullum graduated in 1974 at City University (UK), was awarded the FCOptom in 1975 and the DipCLP in 1978, and the fellowship of the BCLA in 2006. He is senior optometrist in the contact lens service at Moorfields and Oxford Eye Hospitals (UK), and in optometry and contact lens practice in Hertfordshire (UK). He specializes in medical applications of contact lenses, in particular in the management of keratoconus, and in the development of modern scleral lens clinical practice methods, subjects on which he has lectured and written extensively.

**Christine W. Sindt, OD FAAO FSLs – Iowa City, IA (USA)**

Christine Sindt is a graduate of The Ohio State University College of Optometry (USA). She completed a disease-based residency at the Cleveland VA Medical Center (USA). She joined the Faculty of the University of Iowa Department of Ophthalmology and Visual Sciences (USA) in 1995, where she is currently an associate professor of Clinical Ophthalmology and director of the Contact Lens Service. She is the vice president of the Scleral Lens Education Society.

**Sophie Taylor-West, BSc MCOptom**

**Nigel Burnett-Hodd, BSc FCOptom DipCLP – London (United Kingdom)**

Nigel Burnett-Hodd and Sophie Taylor-West both work at Nigel's Central London (UK) contact lens specialist practice, which specializes in challenging contact lens cases, particularly keratoconus, post-graft and post-LASIK grief patients. Sophie Taylor-West has a keen interest in fitting corneo-scleral and hybrid contact lenses and also works part time at Moorfields Eye Hospital (UK). Nigel Burnett-Hodd is past-president of both the British Contact Lens Association and the International Society of Contact Lens Specialists.

**Esther-Simone Visser, BOptom MSc**

**Rients Visser Sr – Nijmegen (the Netherlands)**

Esther-Simone Visser graduated from the School of Optometry in Utrecht (the Netherlands) in 1995. She obtained her Masters Degree at City University in London (UK) in 2004. She joined The Visser Contact Lens Practice, working at several university hospitals in the Netherlands, where she continued to specialize in medical contact lens fitting. She subsequently joined the scleral lens fitting and development team of Rients Visser. She has published and given presentations widely on scleral lenses.

Rients Visser followed the study in Optics, Optometry and Contact lenses in Rotterdam (the Netherlands). He specializes in the medical application of contact lenses and is the founder of Visser Contact Lens Practice, which consists of 19 satellite locations, most of them situated in hospitals. The scleral lens fitting and development team takes care of about 1,700 scleral lens patients. Rients has presented and published widely on scleral lenses and bifocal contact lenses and has developed his own lens designs.

## Preface and Acknowledgements

This guide is based on an extended literature search on the subject of scleral lens fitting and provides an overview of the latest knowledge and understanding on this exciting vision correction method. Being an educator, I believe the guide presents an objective, neutral overview that is not biased in any way towards any fitting technique, industry partner or even location — as different approaches exist in different parts of the world. Being slightly at a distance from any specific fitting technology or philosophy felt like an advantage in this process. However, the important feedback from scleral lens experts who work with their specific lens designs and principles on a daily basis was very much desired and appreciated to create a complete overview on scleral lenses. Several visits to large scleral lens practices, interviewing scleral lens experts and discussion forums such as at the sclerallens.org website provided me with great insights.

Trying to merge together the different philosophies and ideas that exist was the most difficult, but also the most rewarding part of creating this guide. Without the input from the international editorial board, I would not have been able to complete this. Not only has the input directly from the contributors and reviewers added tremendously to the content of this guide, their (online) publications and presentations were also invaluable. The International Association of Contact Lens Educators contact lens course modules proved to be an excellent resource as well — both for understanding the anatomy of the anterior segment as well as for good basic understanding of scleral lenses — and are highly recommended for practitioners. See the reference section at the end of the guide for details and a full overview of all material used for this guide.


This guide serves as an introduction to scleral shape, scleral topography and scleral lens design as well as a generic guide to fitting scleral lenses to help the practitioner get more comfortable with the concept of scleral lenses. It provides a general overview, supported by the main experienced scleral lens fitters worldwide. Its goal is to give practitioners a framework to oversee and integrate scleral lens fitting into their practices. Being a general overview, it can never cover all of the specific scleral lens designs available and cannot be a fitting guide for all lens types available.

Modern scleral lens fitting still is in its infancy, which makes it a modality with great potential. However, fitting scleral lenses is not very black-and-white, and many differences exist among fitters, cultures, manufacturers and countries. This clinical guide tries to find “common ground” among the mentioned philosophies. For specific lens fitting rules and guidelines, the lens manufacturer and the laboratory’s consultant and specialists have the most knowledge regarding their specific lens design, which practitioners should take advantage of.

The International Association of Contact Lens Educators in 2006 wrote in its comprehensive contact lens course on specialty lens fitting, “Although fitted by few contact lens practitioners, scleral lenses can play a major role in providing an optimal visual correction.” This picture has changed dramatically in the meantime, as the modality has gained a lot of momentum. This guide is an update on the latest developments in the dynamic field of this vision correction method and provides an overview of managing the scleral lens patient.

*Eef van der Worp*

*Getting comfortable  
with scleral lenses...*





# I. Introduction

- Terminology
- Indications

The concept of optically neutralizing the cornea with an enclosed liquid reservoir over its front surface was first proposed in 1508 by Leonardo da Vinci. This section briefly covers the history of scleral lenses, followed by currently used terminology and the broad spectrum of indications for fitting scleral lenses.

Large diameter contact lenses that have their resting point beyond the corneal borders are believed to be among the best vision correction options for irregular corneas; they can postpone or even prevent surgical intervention as well as decrease the risk of corneal scarring. For true clearance of the cornea, without any mechanical involvement, it seems advised to avoid any contact between the lens and the cornea by bridging over it. These lenses are technically not “contact lenses,” at least not with the corneal surface — which can be one of the biggest advantages of this modality.

*Indications for scleral lens fitting have been evolving over the last few years, emerging from a lens for severely irregular corneas only to a much broader spectrum of indications.*



A scleral lens hand-held

A few years ago, only a handful of very specialized lens fitters around the world were capable of fitting scleral lenses successfully, and only a few manufacturers were making scleral lenses. Now many contact lens manufacturers have scleral lens designs in their arsenal. Improved manufacturing processes allow for better design, make lenses more reproducible and decrease costs, which combined with better lens materials has contributed to better ocular health, longer wearing time and ease of lens fit. Recently introduced special websites and organizations are devoted to scleral lenses, and conferences and the ophthalmic literature are reporting on scleral lens fitting frequently.

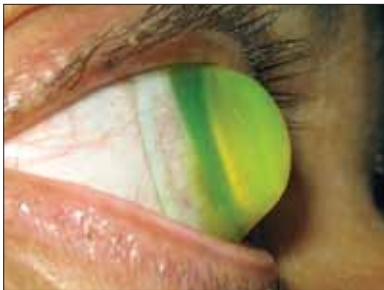It is in the interest of the patient that more practitioners get familiar with the modality to serve patients with the best optical correction available — which is often a scleral lens for the more challenging eyes.

The first scleral lenses were produced 125 years ago and made of glass blown shells. The introduction of molding techniques for the glass lenses by Dallos in 1936 and the introduction of polymethyl methacrylate (PMMA) in the 1940s by workers such as Feinbloom, Obrig and Gyoffry were important breakthroughs for the development of this lens modality, according to Tan et al (1995a). These lenses could now be manufactured on a lathe-cut basis and in a much more accurate manner to mimic the anterior shape of the eye. The use of oxygen permeable lenses, as first described by Ezekiel in 1983, was another breakthrough, since this brought major improvements in ocular health. The development of the smaller, corneal gas permeable lenses and later of soft lenses in the meantime temporarily stopped further development of scleral lens fitting, but the scleral lens is now fully back on the agenda as a solution for more challenging eyes, with many scleral lens options available to practitioners right now including back toric, quadrant specific and bifocal lens designs.

## Terminology

The terminology for scleral lenses and the definitions for different lenses and lens types are very diverse, locally determined, oftentimes arbitrary and very confusing. Typically, the different lens types are defined by different diameter ranges, but it may be better to classify lens types based on purpose and “landing zone area,” since this is independent of eyeball size. In this system, a corneal lens is a lens that rests entirely on the cornea (in normal, adult eyes the lens diameter would be smaller than 12.5 mm).

The next categories in the overview, increasing in diameter, fall under the broad category of “scleral lenses,” as they rest at least in part on the sclera. The smallest lens size within this group, with the landing zone area of the lens partly on the cornea and partly on the sclera, are referred to as corneo-scleral (or cornea-scleral), corneo-limbal lenses or simply as limbal lenses. The often used term semi-scleral also describes this lens type, since it is not a true scleral lens (as it does not rest on the sclera alone). This lens category is typically in the 12.5–15.0 mm diameter range on the average eye, and will be referred to as corneo-scleral lenses going forward.



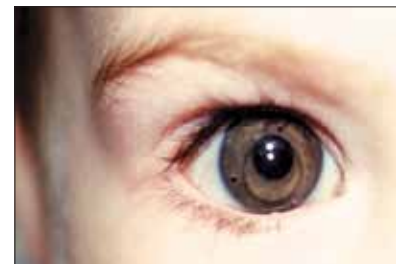GREG DENAEYER

Large diameter scleral lens holding a large tear reservoir

The next category of lenses, again increasing in lens size, is a true or full scleral lens, which rests entirely on the anterior scleral surface. Within this group, different categories can be recognized to acknowledge the differences in lens fit and challenges. Roughly, these lenses can be categorized as large-scleral lenses and mini-scleral lenses, in which there are substantial differences both in landing zone area—and therefore in mechanical bearing area on the sclera and conjunctiva—and in lens design. Bear in mind that mini-scleral lenses are still bigger in size than corneo-scleral lenses—typically, mini-scleral lenses are in the 15.0–18.0 mm diameter range.

Somewhat confusing is that the term “scleral lens” is used to describe lenses that are typically 18.0 to 25.0 mm in diameter, and this term is also used to describe all lenses that have their resting point at least in part beyond the corneal borders. In this guide, the term scleral lens is used to describe the broad range of all large diameter lens modalities, but if a specific lens type is referred to, then that terminology (e.g. corneo-scleral, full scleral, mini-scleral and large-scleral) will be used.

The biggest difference apart from bearing area and location among the smaller- and the larger-diameter lenses is the amount of clearance that can be created underneath the central lens. In small diameter lenses the tear reservoir capacity is typically small, while in the large diameter scleral lenses the tear reservoir capacity is almost unlimited. But all types of (semi-) scleral contact lens designs have the ability to promote good apical clearance to some degree compared to corneal contact lenses, which can reduce mechanical stress to the cornea and is the major advantage of any type of scleral lens.



DON EZEKIEL

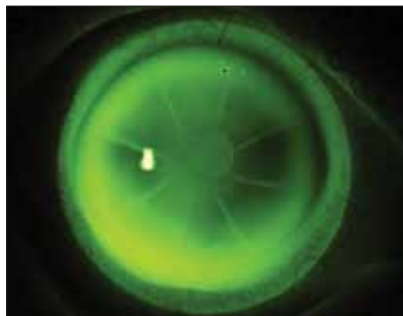
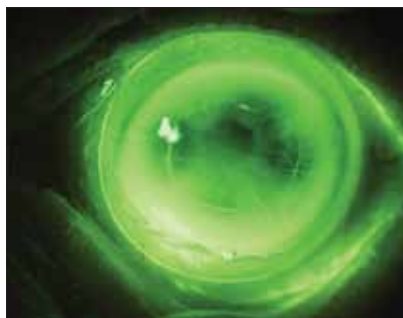
Pediatric aphakic scleral lens

*Because scleral lenses bridge the cornea, comfort of lens wear is really one of the most spectacular benefits of these lenses. Some of our scleral lens patients actually complained to their physicians why they weren't referred for scleral lenses earlier, since comfort of lens wear is so good. We also see that many keratoconus patients with a scleral lens on one eye also want to be fitted with a scleral lens on the other eye instead of a corneal GP lens—again because of comfort.*

*Esther-Simone Visser and Rients Visser*

## Terminology

	Alternative Names	Diameter	Bearing	Tear Reservoir
Corneal		8.0 to 12.5 mm	All lens bearing on the cornea	No tear reservoir
Corneo-scleral	Corneal-Limbal Semi-scleral Limbal	12.5 to 15.0 mm	Lenses share bearing on the cornea and the sclera	Limited tear reservoir capacity
(Full) Scleral	Haptic	15.0 to 25.0 mm	All lens bearing is on the sclera	Somewhat limited tear reservoir capacity
		Mini-scleral 15.0 to 18.0 mm		
		Large-scleral 18.0 to 25.0 mm		



SOPHIE TAYLOR-WEST

Corneo-scleral lenses on post RK corneas

keratoplasty technique, often require a contact lens post-surgery to fully restore vision. A scleral lens may be indicated in many of these cases. Other irregular cornea indications with the primary goal to restore vision include post-trauma corneas. Eyes with significant scarring and severely irregular corneas due to trauma can achieve excellent vision with scleral lenses — often to the surprise of both the patient and the practitioner. Corneal scars as a result of corneal infections, especially Herpes Simplex, are

## Indications

Indications for scleral lens fitting have been evolving over the last few years, emerging from a lens for severely irregular corneas only to a much broader spectrum of indications, which can be broadly categorized as:

### 1. Vision Improvement

Correcting the irregular cornea to restore vision is the main indication for fitting scleral lenses. The largest segment in this category is corneal ectasia, which can be subdivided into two groups. First is the primary corneal ectasia group, which includes conditions such as keratoconus, keratoglobus and pellucid marginal degeneration. The secondary ectasia group includes post-refractive surgery, including post-laser assisted in-situ keratomileusis (LASIK), post-laser assisted epithelial keratoplasty (LASEK), post-photorefractive keratectomy (PRK) and post-radial keratotomy (RK), and trauma.

Corneal transplants, especially the penetrating

*Keep in mind that corneo-sclerals are easier for part-time users compared to corneal GPs due to little or no adaptation. The larger diameter means less lid interaction — and very little adaptation is necessary.*

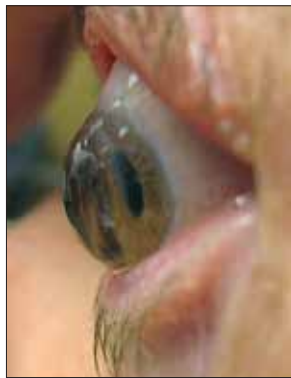*Jason Jedlicka 2010b*

frequently indications for fitting scleral lenses. Corneal degenerations or dystrophies, such as Terrien’s marginal degeneration and Salzmann’s nodular degeneration, are also indications.

In some cases, patients with high refractive corrective errors who cannot be successfully fit with corneal lenses can benefit from scleral lenses (Visser 1997). On occasion, scleral lenses can be used to incorporate horizontal or base-up prisms as they are very stable on the eye. This is usually not possible with corneal lenses because of lens rotation (Millis 2005).

## 2. Corneal Protection

There is a large group of exposure keratitis/ocular surface disease patients that can particularly benefit from scleral lenses because of the retention of a fluid reservoir behind the scleral lens. Sjögren’s syndrome is a common scleral lens indication. Under this category also fall conditions such as persistent epithelial corneal defects, Steven’s Johnson Syndrome, Graft Versus Host Disease, ocular cicatricial pemphigoid, neurotrophic corneal disease and atopic keratoconjunctivitis.

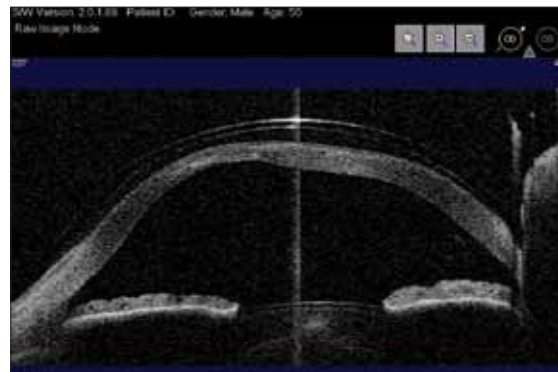
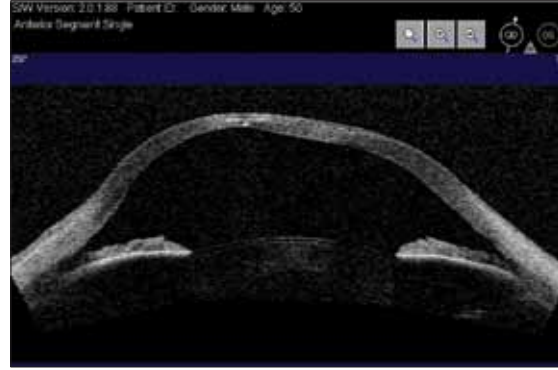
CHRISTINE SINDT

Corneal graft, unfittable with any other lens type than a scleral lens

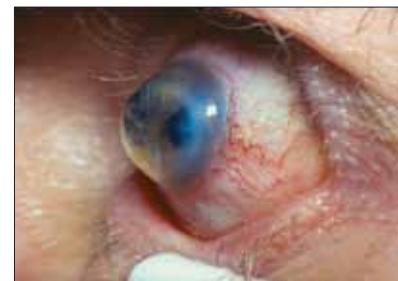Also, if lid closure is incomplete such as in eyelid coloboma, exophthalmus, ectropion, nerve palsies and after lid retraction surgery (Pullum 2005), a scleral lens may be a good indication. In addition: in cases of trichiasis and entropion, scleral lenses have shown to be effective in protecting the ocular surface. In symblepharon, a scleral lens can act as a device to maintain the fornix, for instance after chemical burns. In acoustic neuroma, scleral lenses have also been reported to show excellent results.

More recently, scleral lenses have also been applied to deliver pharmaceuticals to the anterior surface for different reasons. One such indication is the application of antibiotics while the ocular surface recovers/heals, such as the treatment of persistent corneal epithelial defects with the scleral lenses and an antibiotic adjunct (Lim 2009). Jacobs et al (2008) discussed the possibility of using scleral lenses as a novel drug delivery system for bevacizumab for neovascularization. Also, the application of scleral lenses with low levels of sodium channel modulators has been proposed as a form of pain mediation by Rosenthal of the Boston Foundation for Sight (Rosenthal 2009b).



GREG GEMOULES

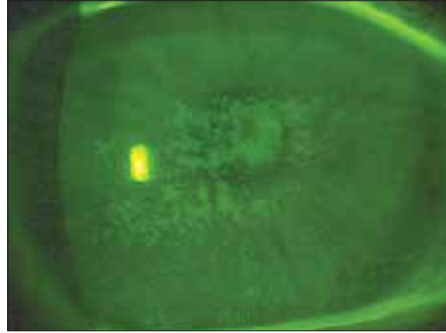
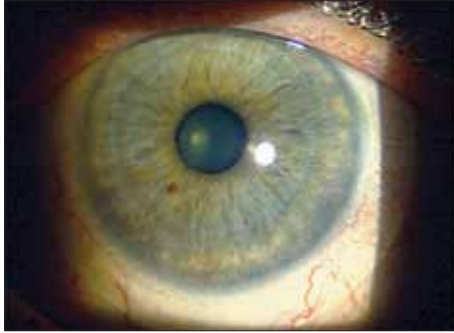OCT images of a severely irregular cornea without and with a scleral lens for visual rehabilitation (Zeiss Visante®)



VISSER CONTACT LENS PRACTICE

Pellucid marginal degeneration—a good indication for scleral lenses.





JASON JEDLIČKA

A case of a 55-year-old dry eye patient fitted with mini-scleral lenses, resulting in excellent comfort and relief of the dry eye symptoms. The lens also includes a bifocal front surface that consists of a 2.0 mm central add zone of +2.00D. The visual acuity with this lens is 20/20 for distance and 20/25 for near.

– Jason Jedlicka

### 3. Cosmetics/Sports

Hand painted scleral lenses have been used for cosmetic purposes in a variety of cases, often related to atrophica bulbi (Otten 2010). Painted lenses have also been used to reduce glare in aniridia and albinism (Millis 2005), although this would technically fall under the vision improvement category rather than under cosmetic indications. Scleral lenses have also been used for cosmetic reasons in cases of a ptosis.

Scleral lenses may be helpful for those involved in active water sports such as water-polo or canoeing, diving and water skiing as well as for other vigorous sports activities or for those that involve exposure to dusty environments. Scleral lenses also are frequently used by the film industry to create special eye effects.

*It seems that age restrictions are virtually non-existing in scleral lenses. The Boston Foundation for Sight reported on a retrospective study of successful scleral lens fitting in 47 eyes of 31 pediatric patients aged 7 months to 13 years—with ocular surface disease being the predominant indication rather than refractive disorders.*

Gungor et al 2008

### Regular GP Lenses or Scleral Lenses?

*Advantages of scleral lenses with advancing ectasia are that the ectasia may advance underneath a well bridging/vaulting lens and the patient will never observe the difference nor require a refitting.*

Lynette Johns

Why would an eye care practitioner fit a scleral lens rather than a clinically well-proven, regular rigid gas permeable (GP) lens? First of all, the cornea, which is one of the most sensitive parts of the human body, is bypassed as a bearing area with scleral lenses. In order for the cornea to remain transparent— its main characteristic — corneal nerves lack the myelinated sheath (which is nontransparent) that is present in most other nerves in the human body. But this also leaves the nerves exposed, and mechanical stress such as a contact lens can trigger the nerves, causing discomfort.

The sclera shows a very low sensitivity, which makes it very suitable for lens bearing. So while at first glance choosing scleral lenses may be counterintuitive because of size, scleral lenses are in fact experienced as very comfortable. When first exposed to a scleral lens, patients almost without exception show their positive excitement about comfort of lens wear.

Scleral lenses basically do not touch the cornea, and therefore there is little or no corneal distortion (e.g. corneal warpage) with scleral lens wear. Scleral lens wear has been reported to be an excellent way of letting

*Another valid point as to why comfort of scleral lenses is so good is the fact that with large diameter lenses there is much less lid interaction with the lens. Corneal lenses are uncomfortable not only due to the lens contact with the cornea, but also because on blinking the lids rub against the edges of the lens, making them move around and feel scratchy. Because the edges of scleral lenses are tucked away under the lids in their natural position, this issue is eliminated.*

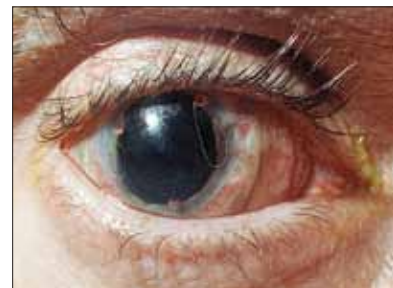*Sophie-Taylor-West and  
Nigel Burnett Hodd*

Additionally, although keratoconus patients typically have high levels of toricity, which in theory would benefit from toric lenses, in reality these lenses have little application. In a back or bitoric lens, the toric curvatures and corresponding power corrections are 90 degrees apart. This is often not the case in keratoconus, especially in moderate and advanced cases. A scleral lens, vaulting over the cornea, can help correct these irregularities. Also, scleral lenses typically have large optical zones, which make them more forgiving in terms of visual function if the lens decenters. This is especially important in patients with keratoglobus or decentered cones (Bennett 2009). Generally speaking, scleral lenses tend to center better than smaller GP lenses do.

*Large diameter contact lenses that have at least part of their resting point beyond the corneal borders are believed to be among the best vision correction options for irregular corneas. They can often postpone or even prevent surgical intervention and may also decrease the risk of corneal scarring.*

the cornea return to its baseline flattening after PMMA lens wear, orthokeratology, and other cases in which the cornea was altered — either wanted or unwanted.

In the Collaborative Longitudinal Evaluation of Keratoconus (CLEK) study in the United States, 1,209 keratoconus patients were observed over a period of eight years at several different sites. Results from the CLEK study show that scar formation in keratoconus may lead to a loss in contrast sensitivity, which may create a vision problem. This is especially a concern because keratoconus patients already have increased higher-order aberrations, primarily vertical coma, that may result in reduced contrast sensitivity. Baseline factors predictive of incident scarring included corneal curvature greater than 52.00 D, contact lens wear, marked corneal staining and a patient age of less than 20 years (Barr 1999). Avoiding pressure on the apex of the cornea with contact lenses seems advised. This seems especially true in the case of a central keratoconus, since a central scar almost certainly leads to a loss in visual acuity.



DON EZEKIEL

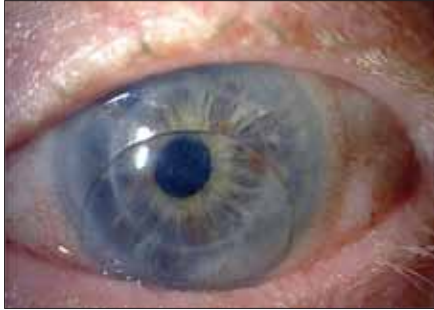Corneal trauma with iris loss fitted with a scleral lens

GP lens fitting has evolved and improved dramatically over the last 10 years with the addition of sophisticated lens designs based on corneal topography, such as highly aspheric and quadrant specific lens designs. But despite this, reducing mechanical stress on the cornea is a challenge with every keratoconus lens fit. In many cases, a scleral lens can be an excellent option to restore

vision. For true corneal clearance without any mechanical involvement, and for better optics, it seems advised to avoid any contact between the lens and the cornea by bridging over it.

## Scleral Lenses or Surgery?

Corneal ectasia, including keratoconus, is the main indication for fitting scleral contact lenses to restore vision. The National Keratoconus Foundation in the USA (2010) estimates that about 15 percent to



VISSER CONTACT LENS PRACTICE

Poor corneal GP lens fit on a post-penetrating keratoplasty

20 percent of keratoconus patients will eventually undergo surgical treatment for the condition. The main form of surgical intervention in keratoconus is a keratoplasty. The survival rate of penetrating corneal grafts is 74 percent after five years, 64 percent after 10 years, 27 percent after 20 years and is very limited at 2 percent after 30 years (Borderie 2009). Partial keratoplasties (lamellar keratoplasty) in which only the anterior portion of the cornea is removed may help overcome the rejection problems, but a suboptimal visual outcome continues to be a concern (Jedlicka 2010a).

But even when medically successful and without complications, many patients post-keratoplasty still need a contact lens, usually a corneal GP lens, to restore vision because of irregularities and high corneal astigmatism. The newest technology in this field is corneal cross-linking. No longterm results are available with this technique, but it aims at halting the progression of keratoconus, in which it seems reasonably successful. But although halted, the corneal changes cannot be restored to baseline with this technique, and usually some form of vision correction is needed after the procedure to optimize vision.

It is estimated that the vast majority of corneal ectasia patients will need GP lenses at some point in life to achieve acceptable vision. A study by Smiddy et al (1988) found that 69 percent of patients who were referred for a keratoplasty could be successfully fit with contact lenses without surgery. These statements seem to indicate a need for eye care practitioners to evaluate all contact lens options first before referring a patient for surgery, and this includes scleral lenses. Always check how much the visual acuity can be improved with scleral lenses before referring the patient for a corneal transplant. This seems especially true in cases involving Herpes Simplex corneal scars.

*A study found that 69 percent of patients who were referred for a keratoplasty could be successfully fit with contact lenses without surgery.*  
Smiddy et al 1988

---

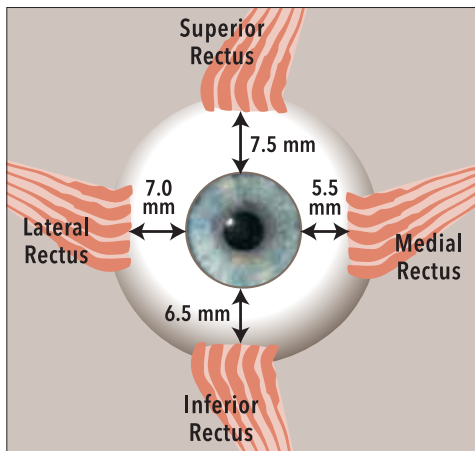
*Key points:*

- *Indications for scleral lenses have evolved from a lens for the highly irregular cornea only to a broad range of indications, including corneal protection and cosmetic reasons.*
  - *Even when medically successful and without complications, many patients post-keratoplasty still need a contact lens to restore vision because of irregularities and high corneal astigmatism.*
  - *For true clearance of the cornea without any mechanical involvement, it seems advised to avoid any contact between the lens and the cornea by bridging over it.*
-

## II. Anatomy and Shape of the Anterior Ocular Surface

- What does the anterior ocular surface tissue consist of?
- What is the shape of the limbus and anterior ocular sclera?

The need for scleral lenses appears to be ever increasing lately. But what do we know about the anatomy and the shape of the anterior ocular surface area to enable adequate scleral lens fitting?



### Anterior Ocular Surface Anatomy

Textbook knowledge tells us that when looking at the anterior ocular surface, it appears that in the temporal, superior and inferior direction there is roughly 7.0 mm of space between the limbus of the cornea and the insertion of the eye muscle (7.0 mm, 7.5 mm and 6.5 mm respectively). However, on the nasal side there is only 5.0 mm of space. With an average corneal diameter of 11.8 mm, this means that horizontally, 22.00 to 24.00 mm is the maximum physical diameter a scleral lens can have for the average eye before it may interfere with the location of the eye muscle insertion, assuming the lens does not move.

### Conjunctival Anatomy

It is actually the conjunctiva that is the landing plane for scleral lenses. But since the conjunctiva has no structure (e.g. it follows the scleral shape), the shape of the anterior eye beyond the corneal borders is referred to as “scleral shape,” and the lens type that lands here is called a scleral lens rather than a conjunctival lens. The conjunctiva is a mucous membrane consisting of loose, vascular connective tissue that is transparent. It is loose to allow free and independent movement over the globe, and it is thinnest over the underlying Tenon’s capsule. The conjunctiva consists of

*In the temporal, superior and inferior direction there is roughly 7.0 mm of space between the limbus of the cornea and the insertion of the eye muscle, however, on the nasal side there is only 5.0 mm of space.*

*It is actually the conjunctival surface that is the landing plane for scleral lenses. But since the conjunctiva has no structure (e.g. it follows the scleral shape), the shape of the anterior eye beyond the corneal borders is referred to as “scleral shape.”*

an epithelial and a stromal layer. At the limbus, the five layers of the corneal epithelium form into 10–15 layers of the conjunctival epithelium. The surface cells of the conjunctival epithelium have microplacae and microvilli, and the surface is not as smooth as the corneal surface. The conjunctival stroma is made up of loosely arranged bundles of coarse collagen tissue.

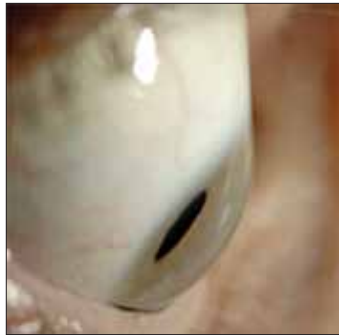

## Eye Muscle Insertion

The eye muscles insert underneath the conjunctival layer onto the sclera. Because of the anatomical location of the eyeball in the orbita, the temporal eye muscle wraps around the globe and stays in contact with it at all times, regardless of eye movements. The nasal eye muscle, on the other hand, comes loose from the globe with a medial eye movement despite its more anterior position of insertion on the eyeball. In a chapter of the book *Contact Lenses* by Phillips and Speedwell, Pullum (2005) describes that “with large diameter scleral lenses, this could theoretically mean that a lateral movement of the lens on the eye or a slight lift of the lens off the cornea can occur.” Furthermore, he describes that it appears that the limbus on the temporal side of the cornea is less pronounced on average than it is on the nasal side because the center of curvature of the temporal sclera curve is contralaterally offset. Basically this means that the nasal scleral portion appears “flatter.” In addition, the nasal curve of the sclera is often actually flatter, adding to the effect of a flatter nasal than temporal portion of the sclera, according to Pullum.

*The limbus on the temporal side of the cornea is less pronounced on average than it is on the nasal side because the center of curvature of the temporal sclera curve is contralaterally offset.*

*Ken Pullum 2005*



PATRICK CAROLINE

A normal limbal-scleral shape profile

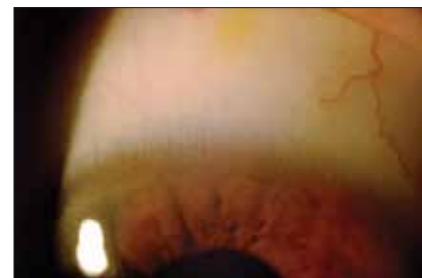## Scleral Anatomy

The opaque sclera forms the main part of the eyeball and converts into the transparent cornea anteriorly on the eyeball. Duke-Elder (1961) reported that the scleral thickness is 0.8 mm at the limbus, 0.6 mm in front of the rectus muscle insertions, 0.3 mm behind the rectus muscle insertions, 0.4–0.6 mm at the equator of the globe and 1.0 mm near the optic nerve head.

The scleral radius is about 13.0 mm for the average eye — as a reference; the average central corneal radius is 7.8 mm. The equatorial length of the eyeball is 24.1 mm transverse and 23.6 mm vertically. This implies that the scleral shape is not equal in all meridians.

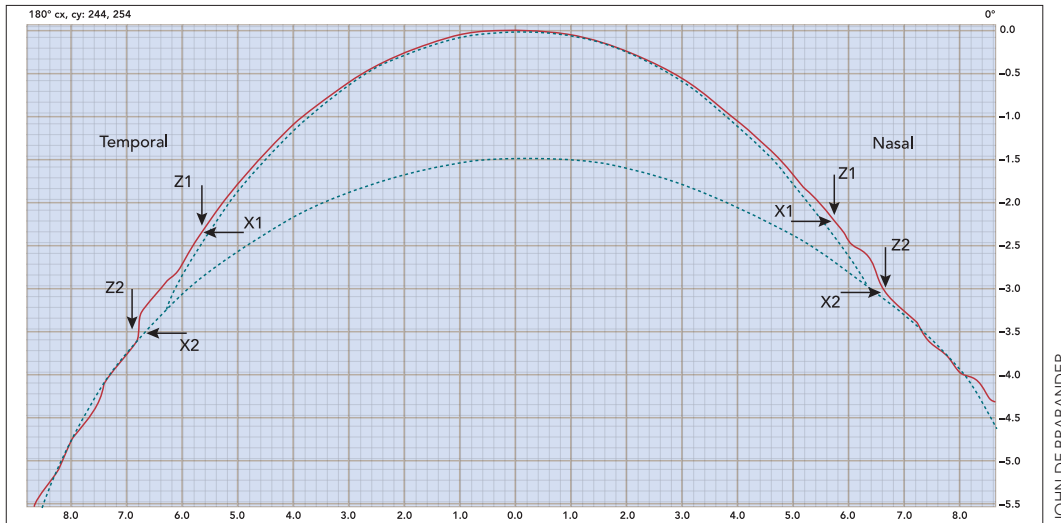
The sclera is relatively metabolically inactive, but is rather durable and tough. There are only limited blood vessels and nerves in the sclera, and thus it is less sensitive than the cornea. Underneath the lamina episcleralis, the top layer, is the substantia propria sclerae (or scleral stroma). This is the thickest layer of the sclera and consists of interweaved collagen fibers. The fibers stabilize the sclera and, consequently, the eyeball. The sclera appears opaque because of the irregular alignment of the fibers. The sclera consists of bundles of flat white collagen fibers crossing parallel to the scleral surface in all directions.

The limbus is the transition zone between the transparent cornea and the opaque sclera. The official transition from cornea to limbus is where Bowman’s layer ends, but the width of the total limbal transition zone is larger: approximately 1.5 mm wide on each side of the cornea in the horizontal plane and up to 2.0 mm in the vertical direction. The corneal stroma fibers are irregular in thickness and arrangement, and change into scleral stroma fibers. So while the five layer epithelium of the cornea phases into the 10 to 15 layer epithelium of the conjunctiva, Bowman’s layer ends and transitions into the conjunctival stroma and Tenon’s capsule. Epithelial radial “pegs” produce the Palisades of Vogt, which are seen more in the inferior and superior quadrant of the limbus and may be pigmented in darker races. The corneal stroma extends into the scleral stroma.



HANS KLOES

Limbal area with Palisades of Vogt



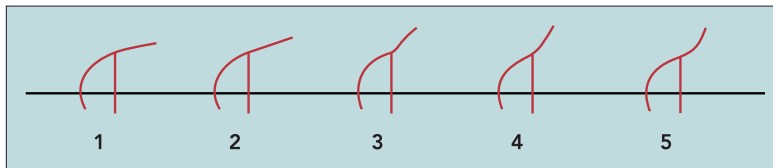
Limbal and scleral shape profile with the MST. Note the nasal flatter appearance in this picture – John de Brabander.

From *Clinical Manual of Contact Lenses*, Bennett and Henry (Van der Worp 2009)

## Limbal and Anterior Scleral Shape

The limbal area and the first part of the sclera beyond the limbus have always been assumed to be curved in shape, but it appears that this is not necessarily always the case. From the molds taken of the anterior segment of human eyes (in normal eyes and in keratoconus), it seems that at least in some cases the sclera often continues in a straight line (tangential) from the peripheral cornea onward. Also, when using contour maps from the experimental Maastricht Shape Topographer (Van der Worp 2009), one of the first topographers to image the limbus and part of the sclera up to an 18.0 mm diameter of the anterior eye surface, it seems on a case-by-case analysis that the transition is often tangential rather than curved, as can be seen in the figure above.

*The limbal area and the first part of the sclera beyond the limbus have always been assumed to be curved in shape, but it appears that this is not necessarily always the case.*



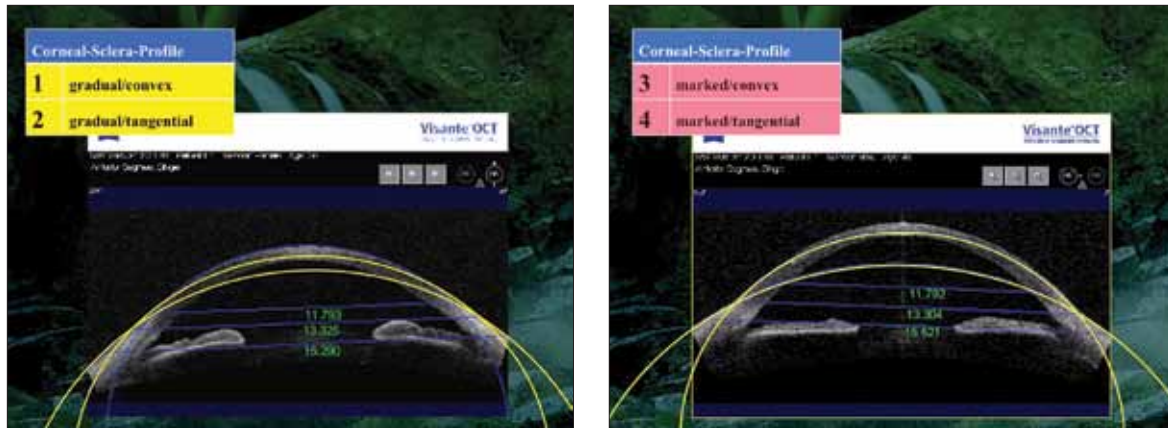
Different transition profiles from cornea to sclera.

Courtesy of Daniel Meier/*die Kontaktlinse*

topic can be found in the German contact lens literature. Meier, a Swiss eye care practitioner, defines in *die Kontaktlinse* (1992) different transition profiles from cornea to sclera. He describes five different models: a gradual transition from cornea to sclera, where the scleral portion is either convex (profile 1) or tangential (profile 2), or a marked transition where again the scleral portion can be either convex (profile 3) or tangential (profile 4). As a fifth option, he describes a convex corneal shape with a concave scleral shape (profile 5). The profiles in the Meier scale are decreasing in sagittal depth, in which profile number 1 has the highest sagittal height and profile number 5 has the lowest sagittal height — an important parameter for fitting scleral lenses.

## Limbal Profiles

It is surprising how little is known about the limbal shape, which is a very important parameter when fitting soft and scleral lenses. One of the few publications on this



Corneo-scleral profiles based on OCT images of the anterior eye with a gradual transition (figure on the left) and a marked transition (figure on the right) (Zeiss Visante®)

Reprinted with permission of Contact Lens Spectrum, Wolters Kluwer Pharma Solutions, Inc., © 2010, all rights reserved

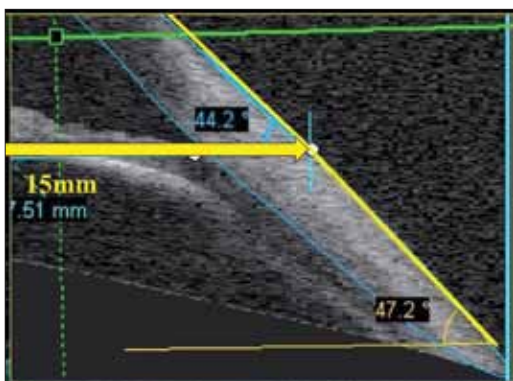
Studies by Meier, and another study published in *die Kontaktlinse* by Rott-Muff et al (2001), tried to identify how often the different profiles were observed in the general population. The study results were remarkably similar. Profile 2 (gradual-tangential) followed by profile 3 (marked-convex) were respectively the number one and two in presence, followed by profile 1 (gradual-convex). Profiles 4 and 5, marked-tangential and convex-concave, were seen minimally, with the latter one almost nonexistent.

But how accurately can these profiles be subjectively rated by practitioners? This also was addressed in an article in *die Kontaktlinse* (Bokern 2007) a few years later. The authors found a repeatability of only 54 percent using 73 investigators. For some profiles the repeatability was much lower.


The use of optical coherence tomography (OCT) has been proposed and described in the literature as a possible aid to image the anterior ocular shape. A small study by Van der Worp et al (2010b) tried to better identify corneo-scleral profiles, for which OCT imaging and applied software were used to manually draw a forced circle through the periphery of the cornea and through the anterior sclera. The results of the 46 analyzed profiles indicated that the average peripheral corneal radius was 9.10 mm (range 7.80 mm to 10.80 mm) and that the average anterior scleral radius (average of nasal and temporal) was 12.40 mm (range 10.10 mm to 16.60 mm). Note that some peripheral corneal radii were actually flatter than were some anterior corneas. The median difference between the two was 3.40 mm (range 1.50 mm to 6.50 mm) in radius, which we used as a critical cut-off point to define gradual versus marked transition, as described in the Meier studies. Using this criterion, the distribution was 50–50 for gradual versus marked. If, in a masked fashion, three different investigators observed and rated the same limbal profiles, then in 75 percent of cases the subjective observation by the masked investigators correlated with the objective measurement by the computerized method. In 70 percent of the cases, the observers agreed with each other on the type of profile.

## Limbal and Scleral Angles

Although the information described in the previous section provides some insight into the transition zone and possibility for lens fit, OCT can measure only single meridians (such as in the horizontal section, for instance), it cannot create a complete topographical map such as with corneal topography. But by manually imaging different meridians in an experimental setting, the technique can be used to explore what the normal limbal and anterior scleral shape looks like. Another limitation seems to be that OCT in its standard modality can measure only up to 16.0 mm of the anterior ocular surface. But if the instrument is slightly decentered, easily up to 20.0 mm and further can be imaged (van der Worp 2010a).



Steep anterior segment angles: 44.2 and 47.2 degrees respectively for the limbal and scleral angle with the Zeiss Visante® OCT (Pacific University – the Scleral Shape Study)



Flat anterior segment angles: 26.1 and 25.1 degrees respectively for the limbal and scleral angle with the Zeiss Visante® OCT (Pacific University – the Scleral Shape Study)

Purely based on theoretical considerations, we would expect the limbal area to be concave. But contrary to that general belief, the shape of the transition area between the cornea and sclera appears to be straight in many cases based on OCT measurements of 96 eyes of 48 normal subjects in eight different directions: (nasal, nasal-inferior, inferior, inferior-temporal, temporal, temporal-superior, superior, and superior-nasal), with only one quarter of cases exhibiting concave shapes and few exhibiting convex shapes. In addition, illustrating the individual character of the limbal shape, within one eye different profiles were measured in different meridians. And what about the anterior scleral shape (between 15.0 mm and 20.0 mm diameters)? In this zone, we would expect the anterior scleral shape to be convex: the eye is an eyeball in the end. But instead it appears that in most cases the anterior scleral shape is also tangential (e.g. straight), with the expected convex shape a distant second (in roughly less than one third of the cases) and a minimal number of concave shapes.

In summary, the results from the Pacific University study indicate a couple of things: practitioners shouldn't expect the limbal area and the anterior sclera to necessarily have the concave/convex shapes that would be expected based on theoretical consideration when fitting/designing a scleral lens. It is suggested that using tangent angles rather than using curves (or using very flat curves) may be appropriate in many cases when

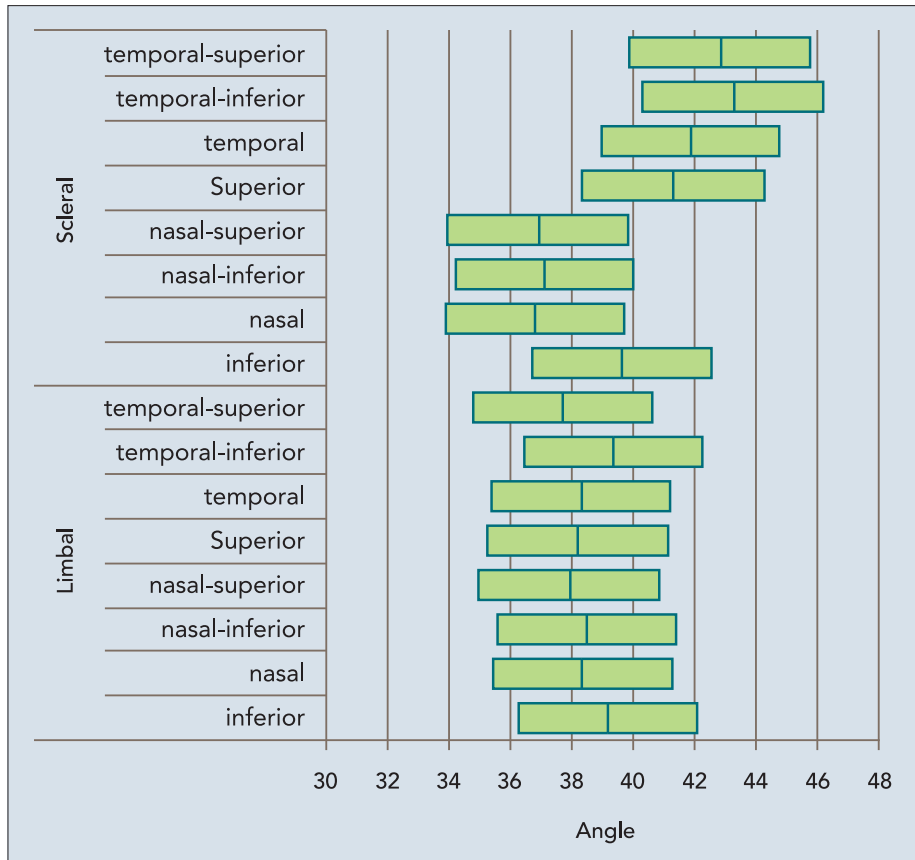
fitting scleral lenses. But large individual limbal and anterior scleral shape differences appear, even within the same eye among meridians.

*"Purely based on theoretical considerations, we would expect the limbal area to be concave and the anterior scleral shape to be convex (the eye is an eyeball in the end). But contrary to that general belief, the shape of the transition area between cornea and sclera and that of the anterior sclera appears to be straight in many cases based on OCT measurements..."*

*Pacific University –  
the Scleral Shape Study*

The Pacific University College of Optometry studies furthermore measured the corneal-scleral tangential angle between 10.0 mm and 15.0 mm (defined in this study as the limbal angle) as well as the angle from 15.0 mm to 20.0 mm (the scleral angle) in 96 eyes of 48 normal subjects, all taken in reference to the horizontal plane.

The summary table on the next page shows the average angles in all sections. From this, it appears first of all that in the average eye the nasal portion typically is flatter compared to the rest, which is in line with corneal topography findings since the peripheral cornea is typically flattest in the nasal quadrant, too. But this effect is smaller in the limbal angles



Summary of the average limbal and scleral angle measurements in different meridians—the bars represent the mean (center line) and 84% confidence intervals. (Pacific University – the Scleral Shape Study)

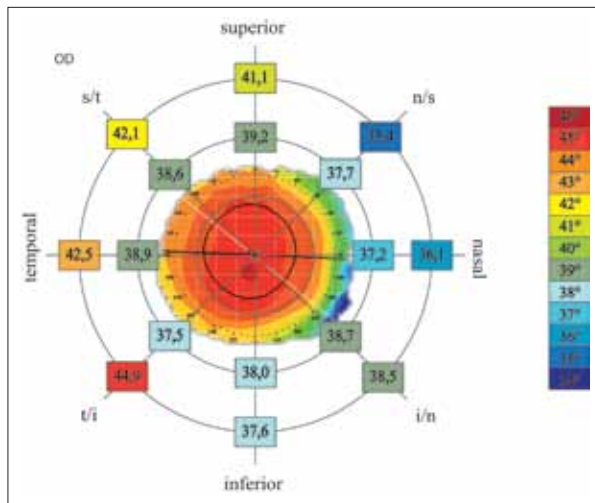
than in the scleral angles. Roughly, the limbal angles are in the same range and were not found to be statistically significantly different from each other. But on the scleral angle, this is not the case: especially between the nasal region and the temporal-inferior section, remarkable differences exist. It appears that on the scleral angles, the inferior segment is almost the “benchmark,” while the nasal angles are lower in comparison and the temporal angles are higher, with statistically significant differences between those.

Generally speaking, the “model-eye” based on this data looks like this: the inferior segment of the eye typically is “on par” both for the limbal and for the scleral angle, with almost no difference between the two angles as well. The temporal portion of the anterior ocular surface typically is steeper compared to other areas; the angles are higher in value. The superior segment is somewhat in between the nasal and the temporal in shape, but with a substantial difference between limbal and scleral angle.

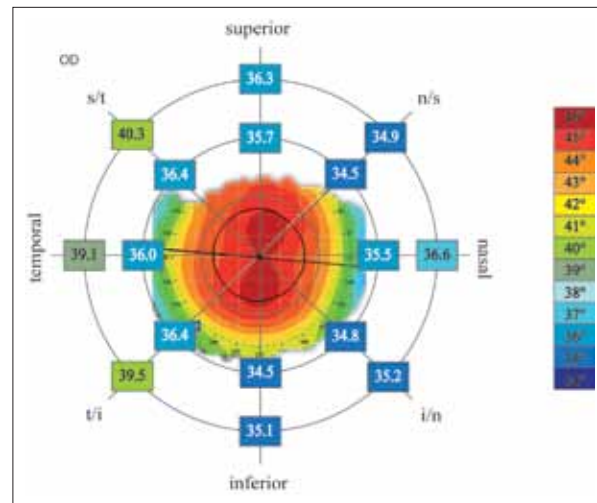
Within the limbal zone, the angle differences are on average 1.8 degrees, although large variations exist among individuals. In the scleral zone, the differences are larger (up to 6.6 degrees on average), but again with large individual differences. It is estimated that 1 degree difference on an average scleral angle would represent a difference of roughly 60 microns in sagittal height. This would mean that within the limbal area, typically a 100 micron difference in sagittal height can occur, while this can be close to 400 microns in the scleral zone. For the scleral shape this could prove to be highly clinically relevant.

Regarding scleral toricity, it is unclear at this point whether corneal cylinder extends into the sclera (e.g. a with-the-rule scleral toricity is visible if a corneal cylinder is present). It has been suggested, especially if the





A typical eye in the Pacific University study. The limbal and scleral angles in eight directions are shown and the corneal topography image is superimposed. The corneal surface is spherical; the limbal and scleral flattening nasally is visible as well as the steepening temporally. (Pacific University – the Scleral Shape Study)



The right eye of a normal subject, the limbal and scleral angles showing a very flat appearance. (Pacific University – the Scleral Shape Study)

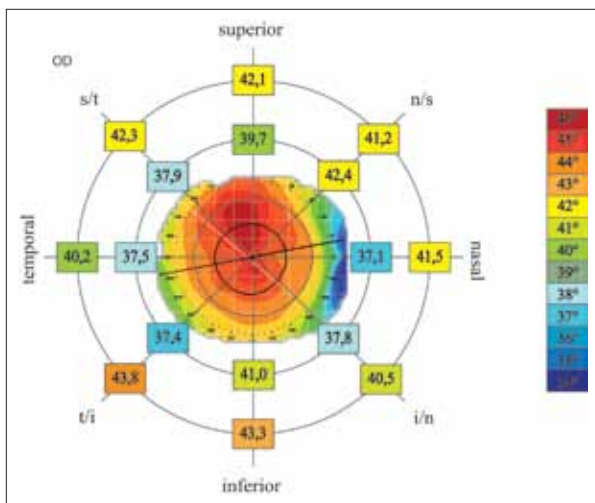
Reprinted with permission of *Contact Lens Spectrum*, Wolters Kluwer Pharma Solutions, Inc., © 2010, all rights reserved

TINA GRAF

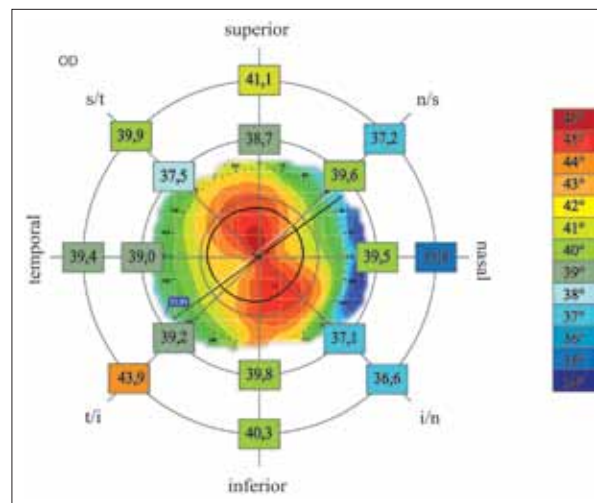
corneal cylinder is congenital in nature, that this may be the case. No published scientific studies have been found on this topic so far to confirm this.

What these results seem to indicate is that on the average eye the ocular surface beyond the cornea is nonrotationally symmetrical, and it seems that for the average eye nonrotationally symmetrical lenses such as toric and quadrant specific lenses, both which are

*Within the limbal zone, the angle differences are on average 1.8 degrees—in the scleral zone, the differences are much larger (up to 6.6 degrees on average); for sure in the scleral area this could be highly clinically relevant.*



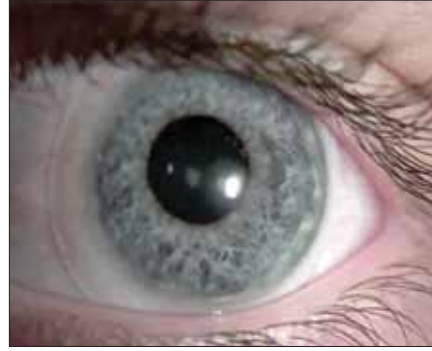The right eye of a normal subject: a rather steep appearance with relative limited differences within both the limbal and the scleral ring (which was not a typical finding in the study). (Pacific University – the Scleral Shape Study)



The right eye of a normal subject with a toric cornea and a nonrotationally symmetrical anterior ocular shape. (Pacific University – the Scleral Shape Study)

TINA GRAF

*The results of the Pacific University studies suggest that a nonrotationally symmetrical nature of the ocular surface beyond the cornea is in line with clinical experience. In fact, in many practices nonrotationally symmetrical lens designs are used more often than not today when fitting scleral lenses.*



Bi-toric corneo-scleral lens on a toric eye

commercially available, could be the preferred option to optimally respect the shape of the eye. This is especially the case if the lens diameter goes beyond the 15.0 mm mark.

The same effect has been reported from clinical experience: the nonspherical nature of the sclera has been described previously by Visser et al (2006). In fact, in many practices nonrotationally symmetrical lens designs are used more often than not today when fitting scleral lenses.

---

*Key points:*

- *Typically in the average eye the nasal portion is flatter compared to the rest, which is in line with corneal topography.*
  - *It seems that the shape of the limbus and the anterior sclera is frequently tangential rather than curved.*
  - *Many eyes are nonrotationally symmetrical in nature beyond the corneal borders. This may call for nonrotationally symmetrical lenses such as toric and quadrant specific lenses.*
-

## III. Scleral Lens Design

- What does a standard scleral lens geometry look like?
- What advanced scleral lens designs are available?

Scleral lens fitting has evolved from glass blown shells in the late 19th century to today's sophisticated, computer generated, state-of-the-art, custom made lenses. Modern scleral lens fitting is primarily based on preformed scleral lenses in which a trial lens set is used to select the desired optimal scleral lens. The design of these preformed lenses will be covered in detail here. In the early days of scleral lens fitting, impression techniques were more commonly used, which will be briefly discussed later in this chapter.

### Preformed Scleral Lenses

Although the different scleral lens designs by various manufacturers differ to some extent, all scleral lenses in essence share the same basic geometry. This section will outline the general standard spherical (rotationally symmetrical) lens design as well as more advanced lens designs such as nonrotationally symmetrical (toric or quadrant specific) and bifocal lens designs. Lens material and lens fenestrations will be discussed as well later in this section, as they are both highly relevant to the lens design and lens fit.

### Spherical Designs

The mother of all contact lenses is the spherical scleral lens. The geometry of these lenses can be broken down into three zones:

1. The optical zone
2. The transition zone
3. The landing zone

*As you gain experience with scleral lenses, you may rely on consultants at one lab more than others. Working with consultants gives you less control of parameter decisions but may bring you to success more quickly.*

*Stephen Byrnes*

### 1. The Optical Zone

The optical zone acts as an optical device, creating the desired optical effect. The front surface optics of this zone can be manufactured spherical or aspheric. The aspheric lens surfaces may reduce some aberrations of the average eye, if the lens centers well.

The back surface shape of the optical zone should ideally have roughly the same shape as the cornea, at least in theory. This way, an even layer of post-lens clearance is

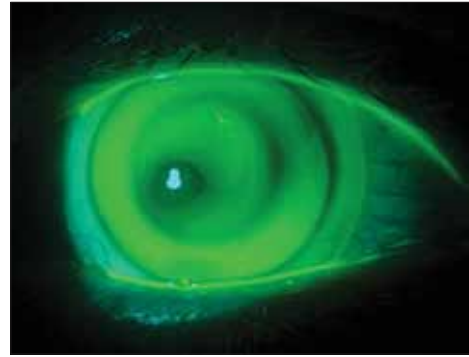
visible behind the scleral lens's optical zone. In order to follow the corneal shape, the back optic zone can be chosen with flatter or steeper radii of curvature.

*I typically start fitting my patients with diagnostic lenses, rather than empirical fitting. It can be intimidating to stray from the parameters outside of the current fitting set when beginning scleral lens fitting. I will order lenses 0.5 mm larger or smaller than my fitting trial lens diameter if desired—but I find that changes greater than 0.5 mm can produce a significantly different fit.*

*Lynette Johns*



Unlike with corneal GP lenses, the back surface of the scleral lens optical zone usually does not touch the cornea. When using smaller diameter scleral lenses, such as corneo-scleral lenses, manufacturers typically suggest some form of “feather touch” on the center of the cornea because it is hard to get the full clearance that may be desired in the more challenging corneas, such as in advanced keratoconus. As long as there is adequate clearance under most of the lens, a good result can be reached according to corneo-scleral lens experts. Alternatively, a larger lens diameter should be chosen to increase the clearance that may be needed. For further details on this topic, see fitting step 2 in the next chapter of this guide on creating adequate corneal clearance and sagittal depth.



SOPHIE TAYLOR-WEST

Light touch with corneo-scleral lens in a keratoconus eye

*A decentered scleral lens will not only decenter the lens optics, it will also displace a large fluid lens on the eye. Low riding scleral lenses will create a base-down prismatic effect. The displacement of the centre of curvature from the visual axis (in centimeters) multiplied by the power of the surface will determine the prism power due to anterior displacement. Prismatic effects of any contact lens fitted on or near alignment will be small.*

*Douthwaite 2006*

The same optics rules apply with scleral lenses as with corneal lenses: post-lens fluid power changes can be adjusted based on the approximate rule that a 0.10 mm of radius change produces a 0.5 D power change. If the changes between the base curve radius of the trial lens and the scleral lens to be ordered are exceptionally large, then a more accurate scale such as Heine’s scale may be better applied. For instance, if we change a 7.80 mm contact lens radius by 0.40 mm to 8.20 mm, the approximate correction for power would be 2.00 D — while in fact a 2.33 D power change occurs (using a refractive index of 1.336) (Douthwaite 2006). In addition: every 100 micron increase in sagittal height adds approximately 0.12 D to the effective power of the system. However, for highly irregular corneas, these theoretical optical rules may not always be accurate. If possible, a trial lens as close to the patient’s needs as possible or an empirically ordered lens would be preferred to avoid this.

Aspheric anterior scleral lens surfaces may allow for improved optical correction of vision in patients with scleral lenses for corneal ectasia, as opposed to spherical front surfaces (Hussoin et al 2009).

## 2. The Transition Zone

A scleral lens has a transition zone between the optical zone and the landing zone that is also referred to as the mid-peripheral or limbal zone. It connects point A (the location of the end of the optical zone) and point B (the beginning of the landing zone going outwards). This zone sets the sagittal height of the lens. When trial sets of preformed lenses are set up based on sagittal height, the next step up (or down) in height basically means an alteration in the transition zone. This is usually independent of optical zone and landing zone parameters.

For large diameter scleral lenses, the transition zone causes the lens to stay clear of the cornea and the limbus. The transition zone geometry as such is not the most critical part of the lens with the large diameter designs. Oftentimes splines or more sophisticated lens logarithms are used to define this zone (Rosenthal 2009b), which explains some of the differences among the various lens designs. Alternatively, this zone consists of a series of peripheral curves, extending out into the landing zone area.

With smaller size scleral lenses and specifically corneo-scleral lenses, it is important to consider the shape of the transition zone and to make sure it is in line with the limbal shape to minimize mechanical pressure in that area, since limbal clearance is typically absent (this is where the lens rests). The shape of the transition zone can be adjusted with some lens designs, in which different profiles are available to follow the limbal shape as accurately as possible. Other lens designs again use a series of peripheral curves to adjust this zone.

*The landing zone, also called the haptic zone, is where the lens actually “fits” and makes contact with the eye. The word haptic is derived from a Greek word meaning “to fasten” or “to attach.”*

### 3. The Landing Zone

The area of the lens that rests on, and tries to mimic the shape of, the anterior ocular surface is called the landing zone, often also referred to as the scleral zone or haptic zone. This is where the lens actually “fits” and makes contact with the eye. The word haptic is derived from a Greek word meaning “to fasten” or “attach.” The design and characteristic of this zone is slightly dependent on lens category (see chapter I of this

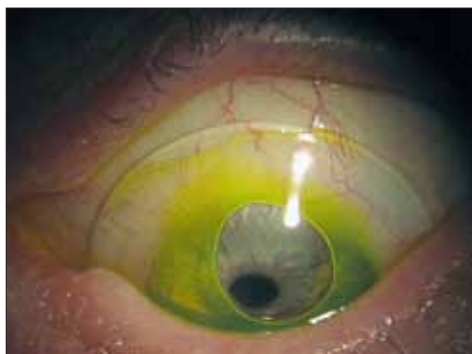guide). “Landing zone” is a term that is independent of lens size and where the lens rests, and will be used hereafter in this guide in reference to this parameter.

The back surface geometry of the landing zone must align with the scleral shape when fitting full scleral lenses or with the limbal shape when fitting corneo-scleral lenses. It is important to evenly distribute pressure over the landing zone area. Because of this, a complete corneal bridge can be achieved, thus creating adequate clearance.

Typically, the landing zone is defined as a flat curve, or series of curves, often in the range of 13.5 to 14.5 mm of radius, with which the majority of eyes normally can be fitted (Pullum 2007). You can modify the landing zone area by using flatter or steeper radii of curvature. Because both clinical experience and recent studies have shown that the shape of the anterior eye is tangential in shape rather than curved in many cases (see chapter II of this guide), some companies have developed tangential landing zone designs. These lenses use “opening angles” (e.g. straight lines) rather than curves to influence the landing zone fit. Alternatively, and maybe somewhat confusing: some tangential lens designs have a curved landing zone, but when altering the landing zone the curve itself is kept constant while angles are used to flatten or steepen the landing zone area (rather than changing the curvature of the landing zone).

*The landing zone area should be at least 3 mm wide to provide comfortable lens wear. More comfort is typically reached by increasing the landing zone diameter.*

*Esther-Simone Visser  
and Riens Visser*



GREG DENAEYER

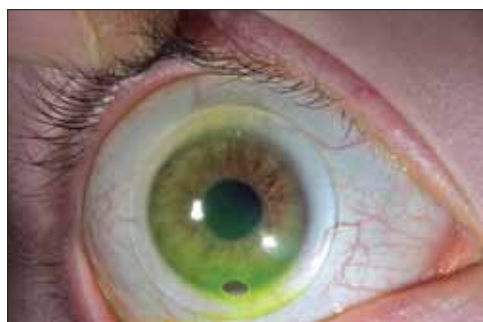
Quadrant-specific lift of a rotationally symmetrical lens on a very toric sclera

### Toric Lens Designs

More recently the availability of specialized scleral lens designs has expanded considerably. Practitioners now have access to a variety of toric lens designs, with a choice of front, back or bitoric scleral lenses. This section will first discuss back toric lenses, followed by front surface toric lens options. The latter is used to improve visual performance and is located in the central optical zone of the lens. When referred to back toric scleral lenses, it is the landing zone (or haptic) area that is made toric to improve lens fit, and this does not include the central zone of the scleral lens. A combination of back and

front toric lenses would be considered bitoric lens designs, which combine the fitting characteristics of the back toric lens geometry (on the landing zone) with the vision benefits of the front surface scleral lens in the central optical zone.

As discussed earlier in this guide, the anterior ocular surface seems to be nonrotationally symmetrical at least to some degree in most eyes. Nonrotationally symmetrical lenses can lead to better ocular health because fewer areas of localized pressure are created, which can result in reduced conjunctival blanching—a term used to describe a decrease in local conjunctival blood supply (see step 3 of chapter IV). Practitioners using the corneo-scleral lens designs typically report that they less frequently need nonrotationally symmetrical designs such as toric or quadrant specific lenses compared to practitioners using larger diameter scleral lenses. Still, even with smaller lens designs, a number of cases may fail or be suboptimal because of a tight lens-to-ocular surface relationship in one or more quadrants, resulting in localized mechanical pressure and possibly conjunctival staining. With larger scleral lens diameters, the nonrotationally symmetrical nature of the sclera becomes much more prominent.



JAN PAUWELS

Rotationally symmetrical scleral lens on a nonrotationally symmetrical sclera.  
© Universitair ziekenhuis Antwerpen

Back surface toric lenses also help to avoid air bubbles underneath the lens and prevent conjunctival blood vessels from being bound by the lens edge. However, back toric lenses also help to stabilize the lens on the eye. In a study by Visser (2006), on average it took six seconds for the toric lenses to return to their initial position after the lenses were manually rotated to a different position.

Generally it is believed that the further the lens's landing zone goes out across the limbus (e.g. the larger the scleral lens diameter is), the higher the need becomes for a nonrotationally symmetrical lens. This may at least in part explain the large variation among practices: some practices

report almost exclusively using nonrotationally symmetrical lenses, while many others hardly use them and many lens designs do not even offer the option.

One step up from this, which seems to be supported by the data on scleral shape as described in chapter II, is to upgrade to quadrant specific lens designs. Since the sclera does not appear to be equal in shape in all directions, this could be a valuable next step in the evolution of scleral lenses. A limited number of manufacturers are currently capable of successfully manufacturing quadrant specific scleral lenses. The fitting of these lenses is mostly done based on clinical experience and trial and error, primarily by looking at localized areas of pressure or lift of the scleral lens's landing zone. See chapter IV step 5 for more details.

Visser (2006) clearly emphasized the advantages of back toric scleral lenses, and Gemoules (2008) presented a fitting technique using the Zeiss Visante® OCT to optimize the fitting technique. Both studies boast longer wearing time and better comfort in well-fitted back surface designs with these nonrotationally symmetrical geometries in the landing zone area.

Because nonrotationally symmetrical lenses follow the shape of the anterior eye beyond the cornea more precisely, they are exceptionally stable on the eye, which opens up the possibility for additional optical corrections such as front cylinders, but also for higher-order corrected aberrations such as vertical coma, a very frequent finding in for instance keratoconus. This can help improve visual performance, which can

*The advantages of back toric scleral lenses seem evident; longer wearing time and better comfort in well-fitted back surface designs have been described—especially for larger diameter scleral lenses.*

further benefit patients with ectasia and other corneal irregularities. If no toric back surface design is used, or if for some reason the lens is not stable on the eye, front toric optical correction may be indicated. See chapter IV, step 5, for a more detailed description on the fitting details regarding these kinds of lenses.

## Bifocal Contact Lens Designs

More recently, some bifocal scleral lens designs have entered the market. Most probably these are more suitable for patients with nonpathological eyes, but combinations should not be excluded up front. The design of these lenses would fall into the “simultaneous bifocal lens design” group, in which two images with different focal points are presented at the same time to the eye. The major advantage that these scleral bifocal lenses have over corneal GP bifocal simultaneous lenses is that they are very stable on eye and the concentric zones can be matched more precisely within the desired corneal zones and the pupil zone compared with lenses that move, quite excessively, over the ocular surface. To some degree, scleral lenses may have this advantage even compared to soft lenses. A bigger advantage compared to soft lenses would be the optical quality of scleral lenses as they are made of a lens material with excellent optical quality that is superior to that of soft lenses.

## Lens Material

Scleral lens material has evolved from PMMA with a DK of zero to the currently available high Dk lens materials, as are used for corneal GP lens wear. Scleral lenses are considerably thicker than normal GP lenses — scleral lenses can be 0.4 to 0.6 mm in thickness, which can dramatically decrease the effective Dk/t of the lenses. The lenses are made out of special buttons with a diameter of up to 26 mm.

The oxygen permeability of the lens allows oxygen to pass through the lens. Tear flow underneath the lens, if present, can also bring in oxygen-rich tears to supplement the oxygen demand of the cornea. Since typically the lens vaults the limbus in scleral lenses, oxygen from the conjunctival and limbal vessels can also contribute to the oxygen supply in the fluid layer. Fitting fenestrated lenses may add to this effect, according to some practitioners.

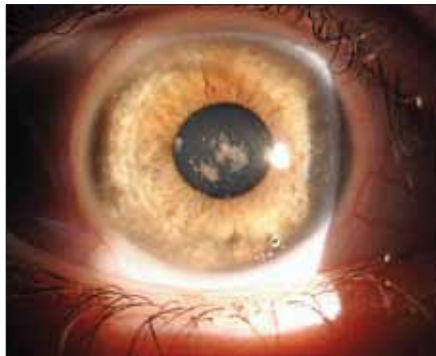The thickness of the scleral lenses needs to be sufficient to prevent lens warpage. Thin scleral lenses have the tendency to quickly warp, either on-eye because of the nonsymmetrical nature of the anterior surface or ex vivo due to handling. Keratometry or topography over the scleral lens can be helpful to detect lens

flexure. For spherical scleral lenses, the anterior surface needs to be spherical: if the keratometry values indicate a cylinder, the lens is warped, which may lead to vision problems. Replacing the lens and potentially increasing its central thickness may solve the problem. Switching to a toric lens design also may be indicated. See chapter V for more on lens flexure.

Many scleral lenses are plasma treated to improve wettability. Replacement schedule of the lenses varies widely from one year to several years. Some practitioners report that after several months of lens wear, presumably in part because the plasma treatment wears off, wettability decreases and comfort degrades.

*Due to difficulty in cleaning of the back surface of scleral lenses, lens comfort can degrade with time due to back surface deposition.*

*Jason Jedlicka*



SOPHIE TAYLOR-WEST

Heavy protein buildup on a scleral lens



*Nonfenestrated lenses float more on the eye, while fenestrated lenses “sink” more into the anterior ocular surface. Typically, corneal clearance in fenestrated lenses is much lower than in nonfenestrated lenses.*

## Fenestrations

In the “PMMA scleral lens era,” fenestrations or channels were commonly used to provide circulation of fresh oxygenated tears. But modern scleral lenses are all gas permeable, and oxygen delivery is not the most important consideration for fenestrations anymore. It is still under debate as to what degree fenestrations are beneficial to the oxygen delivery effect to the cornea.

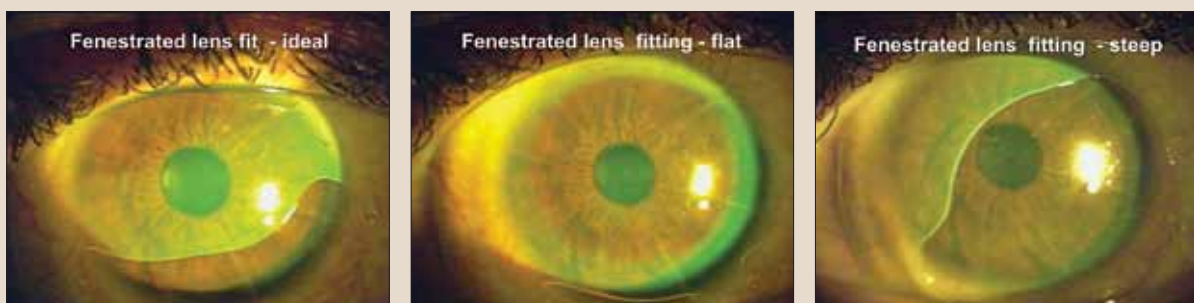
Fenestrations have become a focal point of discussion in the scleral lens field. It has been suggested that in theory, more

“suction” of the lens can occur in nonfenestrated lenses and that fenestrated lenses can be easier to remove and can improve the exchange of metabolic debris, but no scientific evidence for these theories is available.

Fitting fenestrated lenses is significantly different than fitting nonfenestrated lenses. Nonfenestrated lenses float more on the eye, while fenestrated lenses “sink” more into the anterior ocular surface. Typically, the clearance in fenestrated lenses is much lower than in nonfenestrated lenses. The preferred typical clearance is 200–600 microns with nonfenestrated lenses, while with fenestrated lenses this can be down to 100–200 microns or even less with the same lens design and diameter. This may be an advantage for keeping the clearance area air-bubble free, but fenestrations can actually also cause air bubbles in the area of the fenestration. In smaller scleral lens designs a fenestration hole may be beneficial in relieving negative pressure. It should also be kept in mind that lens solution and debris, as well as potentially micro-organisms, may accumulate in the fenestrations, since the fenestrations holes cannot be manually cleaned. Nonfenestrated lenses may allow for an easier and simpler lens fit, according to some manufacturers.

*Fenestrations can sometimes allow bubble formation, but can also, on occasion, allow bubbles to escape—especially in smaller type scleral lenses.*

*Jason Jedlicka*



### Fenestrated Lenses

*There is a general belief that fenestrated lenses are difficult to fit as these lenses tend to settle on the eye. But it is not difficult to estimate this effect and to compensate to allow for this in the initial lens ordered. There are a number of advantages of a fenestrated lens over a sealed lens:*

- 1. Having a fenestration in the lens promotes renewal of flow of tears over the cornea and may help remove waste products from under the lens.*
- 2. Fenestrated lenses are inserted without the need to have a solution in the lens bowl. This makes the insertion and removal of the lens quite straightforward, especially with pediatric patients.*

*Don Ezekiel*

If fenestrations are used, they should be roughly 0.5 mm to 1.0 mm in size and placed in the deepest pooling area over the limbus (DePaolis 2009). If the fenestration hole is obscured on the inside by corneal or conjunctival tissue, it will have no effect. In some cases of loose conjunctiva (as in conjunctival chalasis), the negative pressure under the lens can be such that the conjunctiva can be sucked underneath the lens and even through the hole.

## Impression Technique Scleral Lenses

Although not very commonly used in modern contact lens practice, impression techniques have been utilized successfully for many years (Pullum 2007). With this technique, a mold is made of the anterior ocular surface (the positive cast). Of this impression, a negative mold is created. Typically dental material is used in recreating the anterior ocular surface shape. This positive cast can be sent to a specialized manufacturer to produce a scleral lens. Specialized equipment is needed to perform this procedure, whereby local anesthetics are normally required. These lenses follow the shape of the anterior surface precisely, and the impression retains its shape indefinitely so the lens can be reproduced at a later time.

The optical specifications can be ordered by requesting an optic radius 0.20–0.50 mm flatter than the flattest keratometry reading and specifying a central clearance from the cast. The central clearance for a first impression can be around 200 microns, which should result in a corneal apical clearance of about 100 microns, according to Douthwaite (2006).

The technique has been described as very invasive and time consuming, and it is not commonly applied today on a regular basis. The biggest downside would be that heat is required, which makes this technique basically limited to PMMA materials.

Furthermore, preformed scleral lenses can be made thinner than molded lenses. Also, preformed lenses are more reproducible because the precise lens specifications are known and the lenses are easier to adjust. The fact that impression lenses may follow the shape of the anterior eye very closely has been described as an advantage, but may also be a disadvantage: lens adherence or binding can occur. An advantage of the system is that the practitioner does not require expensive fitting sets. There still may be a need to perform impression molding in cases of markedly disfigured eyes or for custom-fitted ocular prostheses.

New technology such as OCT, as described earlier, to image the anterior ocular shape could potentially lead to a revival of these custom made lenses without having to make the invasive molds and casts, which can then be manufactured in the highest Dk materials available.

---

### Key points:

- *Scleral lenses basically consist of three zones: the optical, transition and landing zones.*
  - *Toric and bifocal scleral lenses are available and could be highly beneficial to some patients.*
  - *Impression technique scleral lenses are not commonly used today; modern scleral lens fitting relies almost exclusively on preformed scleral lenses.*
-

## IV. Fitting Scleral Lenses— a Five Step Fitting Approach

- What parameters to consider when fitting scleral lenses
- How to follow a five step fitting approach for general scleral lens fitting

In the past, the major disadvantage of fitting scleral lenses has always been the time, skill and expense required to fit them. This has dramatically changed over the recent years as a result of improved knowledge about the ocular surface and new design possibilities as well as improved materials to work with. The five step fitting approach presented here for preformed scleral lenses is a general fitting guide to explain the essence of scleral lens fitting for the different types of scleral lenses available. Different rules may apply for specific types of lenses, as will be indicated in the text. The order of the five steps is almost arbitrary: many practitioners, for instance, prefer to work from the periphery back to the center, which would be the opposite of standard corneal GP lenses.

*In this five step fitting approach for preformed scleral lenses, the total lens diameter and optical zone diameter are the first points to consider (step 1), followed by establishing the central and limbal clearance (step 2), the appropriate landing zone alignment (step 3), adequate lens edge lift (step 4) and finally the rotationally symmetrical design of the lens (step 5).*

Scleral lenses are primarily fitted based on sagittal depth; keratometric readings are of relatively limited use. Two eyes with the same keratometric values can have totally different sagittal heights. The average total sagittal height of the fitted area of a normal eye easily reaches 4,000 microns (over a 15.0 mm cord). Sagittal height is dependent on a number of variables including lens diameter, radius of curvature, asphericity of the cornea, and the shape of the anterior sclera. The inability to measure the latter makes calculation of the sagittal height virtually impossible in clinical practice. Only with advanced topographical technology such as the OCT (see chapter II of this guide) can the total sagittal height of the anterior eye be measured. But by using a fitting set, the anterior surface topography can be empirically met in a clinically proven, successful way.

This chapter focuses on the individual steps needed to fit scleral lenses, independent of manufacturer and design.

### Step 1: Diameter

- How to choose the overall scleral lens diameter
- How to assess the optical/clearance zone diameter

#### Total Diameter

The total lens diameter is the first and most basic consideration that scleral lens practitioners have to consider in the fitting process. This decision is a subject of discussion within the scleral contact lens field,

where individual practitioner preference plays an important role. But there are also a number of independent variables to consider.

In favor of larger diameter lenses is the amount of tear fluid reservoir that can be created. Typically, the more clearance required, the larger the lens diameter chosen. This means that for a fragile corneal epithelium, a larger lens may be required to completely clear the cornea. Larger diameter lenses are also typically suggested for large sagittal height differences on the cornea, such as in corneal ectasia. With bigger lenses, a much larger area of bearing is created in the landing zone area, which prevents local areas of excessive pressure and may improve comfort. Small diameter lenses typically “sink” more into the conjunctiva and may show less movement than large diameter scleral lenses.

The case for the smaller lenses is that they may be easier to handle, may not need to be filled with fluid upon insertion and will cause fewer air bubbles under the lens. For the more normally shaped cornea and for noncompromised eyes, this may be a valid option. Since the clearance is smaller than with larger diameter scleral lenses, visual acuity is typically good with these lenses. Also, these lenses tend to be less expensive than large diameter scleral lenses.

Large lens diameters may tend to decenter, typically more temporally due to the flatter appearance of the nasal shape in many cases. Also, for really large lens diameters, there may be limited space between the limbus and insertion of the nasal eye muscle (see chapter II of this guide). If large scleral lenses decenter, switching to a smaller diameter may solve the problem. The decentration caused by nasal pressure may also be alleviated with a nonrotationally symmetrical lens (see step 5 of this chapter).

It seems there is certainly a place for both large as well as small diameter scleral lenses. The diameter choice can actually be arbitrary because there is no right diameter for a patient. An acceptable fit can be reached with a 15 mm lens or with a 23 mm lens on the same patient (Jedlicka 2010b). Many companies offer different diameter options within their lens designs. Some lens designs limit practitioners to one lens diameter; adding another lens design that has a different total lens diameter to the arsenal may be advised to deal with all challenges of the scleral lens practice.

*Small increments in lens diameter can have dramatic effects on surface coverage area. Increasing lens diameter from 14.0 mm to 15.0 mm results in an increase in total surface area under the lens from 616 mm<sup>2</sup> to 707 mm<sup>2</sup>: an increase of 92 mm<sup>2</sup>. With larger lenses this effect is even greater: from 1,275 mm<sup>2</sup> in a 20.0 mm lens to 1,485 mm<sup>2</sup> in a 21.0 mm diameter lens (a difference of 128 mm<sup>2</sup>).*

*Small children can be difficult to get full scleral lenses on because of the necessity of filling the lens and the inability of little children to sit still in a face down position; therefore, sometimes the vault needs to be decreased. However, it is possible, and children do get better at application as they get older.*

*Christine Sindt*

### Optical/Clearance Zone Diameter

Within the diameter consideration of the scleral lens fitting process, it is important to also discuss the optical zone diameter. This is quite a critical consideration in theory, but many scleral lens designs have fixed optical zone diameters, so it may not always be possible to change this parameter within one lens design.

The optical zone diameter is important to provide a good optical outcome, and therefore it should not interfere with the pupil diameter, taking into account the depth of the anterior chamber including lens clearance. When determining optical zone diameter size, it should also be taken into account that scleral lenses can somewhat decenter.



Total corneal vaulting is the objective, and even limbal clearance is desired with many scleral lenses, so determining an adequate optical zone diameter is crucial. Corneal diameter can be used as a guideline and starting point. The clearance zone area, consisting of the optical and the transition zone of the scleral lens (which is often fixed in diameter) is often chosen roughly 0.2 mm larger than the corneal diameter.

If the optical and transition zones are fixed in diameter, this parameter can be checked on-eye to assess whether the zone diameter is adequate and can be switched to alternative lens designs if it is not desirable. The size of the optical zone diameter itself depends on the lens design used. It should cover the pupil zone fully to prevent any optical disturbances. As said: often the optical zone diameter is set, and not all lens designs allow for alterations of this parameter. Switching to a larger overall lens diameter may be an option.

## Step 2: Clearance

- How to define corneal clearance
- How to define limbal clearance

### Corneal Clearance

The next step is to define the amount of central corneal clearance. Corneal clearance is probably the single most important advantage that scleral lenses have over corneal lenses, and it seems advised to take advantage of that. Up to 600 microns of corneal clearance can be easily achieved if desired. The terms “flat” and “steep” should be avoided in this regard because they are confusing and do not do justice to the description. Increase or decrease in sagittal height seems to be more appropriate terminology, and many lens designs exclusively define their trial lenses in terms of sagittal height. Increasing the sagittal height of the lens causes the lens to “lift” off the eye, increasing the clearance or vault of the lens.

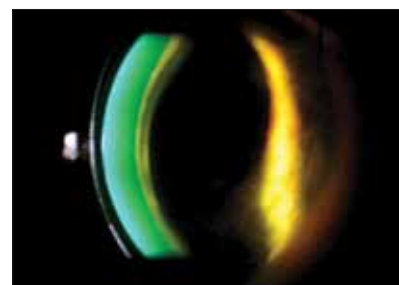*Corneal clearance is probably the single most important advantage that scleral lenses can offer over corneal lenses.*

### Amount of Central Corneal Clearance

There are no “rules” for the exact central corneal clearance, but typically a minimum of 100 microns seems desired, although in corneo-scleral lenses smaller clearances of as low as 20–30 microns have been reported (DeNaeyer 2010). With true scleral lenses, a clearance of 200–300 microns is usually considered sufficient, but this can easily go up to 500 microns if desired with the end stage large diameter lenses. Mini-scleral lenses are positioned in between corneo-scleral and large-scleral lenses with regard to level of clearance.

For comparison and as a reference when evaluating the clearance on-eye, the average corneal thickness of a normal eye (e.g. in, for instance, keratoconus this can be significantly less) is in the 530 microns range in

*The desired sagittal depth differs with the condition — e.g., a keratoconus patient needs a different (larger) total sagittal lens height than a post-corneal graft patient. But having said that, in central and nipple shaped keratoconus a normal sagittal height may be needed. In ocular surface disease typically larger sagittal heights are desired.*



GREG DENAEYER

As an illustration, an 18 mm lens holding a 1600 micron tear reservoir

*To assess the shape of the anterior ocular surface, we try to grade the total sagittal height as either shallow, normal deep or very deep, and based on this the first trial lens is decided on.*

*Esther-Simone Visser and  
Rients Visser*

the center of the cornea, with values up to the 650 micron range in the periphery (Doughty 2000) near the limbus, and this can be used as a reference when evaluating corneal clearance on-eye. Central lens thickness, if known, can also serve as a reference point.

The desired sagittal depth differs with the condition — e.g., a keratoconus patient needs a different (larger) total sagittal lens height than a post-corneal graft patient. But having said that, in central and nipple shaped keratoconus a normal sagittal height may be needed.

In ocular surface disease typically larger sagittal heights are desired. Some companies offer different fitting sets for different conditions (ranging from post-LASIK, post-RK and post-graft to normal eyes

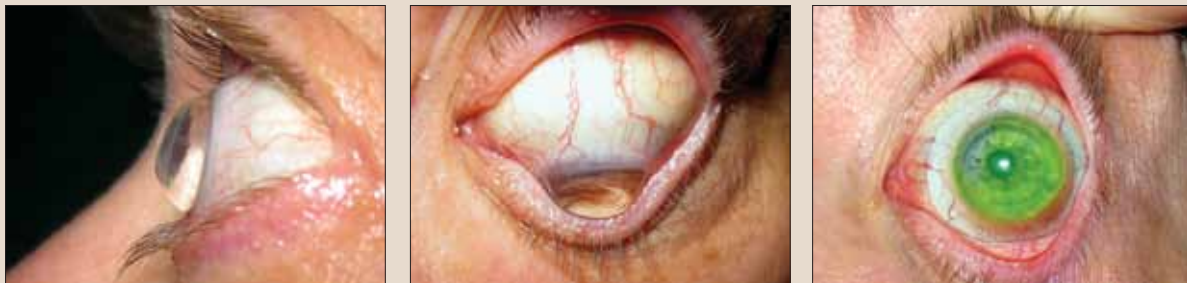and ectasia). This may make finding the optimal lens clearance easier. Some companies use keratometric values to estimate the sagittal height of the first trial lens to be applied to the eye: for very steep corneas, the highest sagittal heights are advised (as in keratoconus) while for very flat corneas (typically post-graft and post-refractive surgery) the lowest sagittal height lenses are advised as a first step in the trial lens procedure.

### Evaluation of Central Corneal Clearance

It is advised to always start with a lower sagittal height lens for a particular cornea and then to gradually try diagnostic lenses with more sagittal height (some practitioners prefer the reverse: starting with a high sagittal height and gradually going lower) until the lens no longer shows apical touch on the cornea, or a “feather touch” with corneo-scleral lenses, as will be discussed later in this chapter.

Since the clearance retains a fluid-filled reservoir, it is advised to fill the scleral lens with saline upon insertion. With corneo-scleral lenses this may not always be needed, although for truly irregular corneas it is advised to fill the lens with fluid even in corneo-scleral lenses to avoid air bubbles (especially when they are not fenestrated). Fluorescein should be added at this point to the fluid filled lens, since tear film exchange is limited once the lens is placed on the eye. A green, equal fluorescein pattern should be visible in front view, preferably without bearing zones. The human eye is capable of observing 20 microns or more of fluorescein layer thickness. Anything less will appear black, but this doesn't necessarily mean there is “touch.” Lens decentration can be easily observed this way as well.

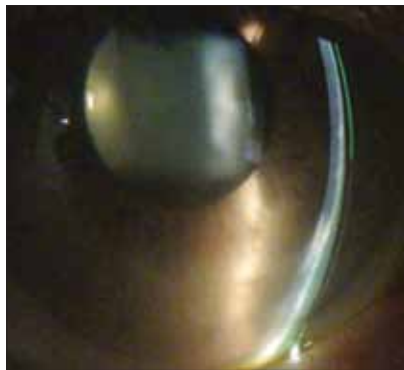
If corneal bearing is visible in larger diameter scleral lenses, this means the sagittal height of the lens is too small. Typically, the larger the area of central touch, the more the sagittal height needs to be increased. On



*Patients with keratoglobus can be challenging to fit. Since the whole cornea is steep, scleral lenses that have larger than normal optic zones and large sagittal heights are often needed to vault these extreme corneas. A reverse geometry design may allow for more lift to improve overall clearance. Above is a patient with recurrent keratoglobus 15 years after a PK. The sagittal depth of this lens is over 8,000 microns. – Greg DeNaeyer*

the other hand, air bubbles underneath the lens (if not caused by incorrect lens placement) are a sign of excessive corneal clearance. Many practitioners fit scleral lenses by this simple fact—they vary sagittal height based on corneal bearing and air bubble presence from shallow to greater sagittal height until the bearing is gone and/or air bubbles are not present. The size of the bearing area/air bubble also can be a guideline; larger bearing areas or bubble formation requires larger steps change in sagittal height. It is important to note that a good insertion technique is key to prevent “false bubbles” (see chapter V—management of scleral lenses). Also, bubbles may form due to a nonsymmetrical shape of the anterior segment (see step 5 of this chapter). Small bubbles that move may be acceptable as long as they do not cross the pupil area, but large stationary bubbles are not. Excessive clearance (more than 500 microns), even if no bubbles are formed, can sometimes reduce visual acuity and cause visual disturbances.

In keratoconus or other conditions with high corneal sagittal heights, larger lens diameters may be required to achieve complete clearance. Some manufacturers of smaller scleral lenses allow a minimal “feather touch central bearing” or “gracing touch” on the top of the cornea in these cases. The goal with these lenses still would be to find the minimum sagittal height that vaults the cornea with little to no apical bearing. While central clearance is desired at all times, central bearing with scleral lenses is typically well tolerated compared to corneal GP lenses according to many experienced fitters, presumably because scleral lenses usually do not move enough to irritate the apex of the cone.



STEPHEN BYRNES

Mini-scleral lens with inadequate vault over corneal graft optic section

To further evaluate corneal clearance, an optical section behind the slit lamp can be moved across the eye at a 45 degree angle to observe the post-lens tear film thickness (with and without fluorescein). While the post-lens tear film with corneal GP lenses is hard to image, with scleral lenses this is much easier to see.

Scleral lenses may need some time to settle as they can “sink” into the conjunctiva to some degree, but this is subject to a high individual variance. It is recommended to wait about 20–30 minutes before evaluating the lens on the eye. If the clearance decreases too much to be adequate, a lens with a higher sagittal depth should be tried. Fenestrated lenses may settle more than nonfenestrated lenses. Always choose a large enough corneal clearance to allow the lens to adjust to the ocular surface—lenses may settle more over longer periods of time.

*Air bubbles underneath the lens, if not caused by incorrect lens placement, are a sign of excessive corneal clearance. Many practitioners fit scleral lenses by this simple fact—they vary sagittal height based on corneal bearing and air bubble presence from shallow to greater sagittal height until the bearing is gone and/or air bubbles are not present.*

*Scleral lenses may need some time to settle as they can “sink” into the conjunctiva to some degree, but this is subject to a high individual variance. It is recommended to wait about 20-30 minutes before evaluating the lens on the eye.*

### Peripheral Corneal Clearance

Once corneal clearance has been established over the top of the cornea, then the clearance over the rest of the cornea may need to be adjusted. At this point the base curve radius of the lens may come into play. Choosing the back optic zone radius of the lens slightly flatter than the flattest keratometry values usually

*Sometimes vision can be improved by reducing lens clearance, up to the point where there is a minimal touch on the cornea. This may give an improvement of one to two lines on the chart, which can be crucial at times, but frequent follow up eye exams are required.*

*Esther-Simone Visser and  
Rients Visser*

helps alleviate pressure in the peripheral optical zone and limbal area (see chapter IV). By adjusting the base curve radius, the back surface shape of the scleral lens can be adjusted so that it should create an alignment tear film reservoir behind the lens. A flatter base curve radius can be used to create limbal clearance as well (see next section in this chapter).

Changing the base curve radius of the lens does mean that the sagittal height of the lens may also be altered. Flattening the base curve will reduce the sagittal height of the lens. This means that the sagittal height may need to be adjusted to compensate for the radius changes. However, many manufacturers have already compensated for this automatically—a change in radius results by default with an alteration in sagittal height (e.g. the sagittal height remains constant although the radius of curvature is changed).

Similarly, sagittal height is also dependent on lens diameter. If the lens diameter is increased while the back optic zone radius is kept stable, the total sagittal height goes up, which can be quite dramatically in terms of an increase in volume. Conversely, a smaller lens decreases the sagittal height if the base curve radius stays the same, unless the manufacturer compensates for this automatically. In short: in principle, one parameter cannot be changed without taking others into account. But to simplify the fitting process, manufacturers can adjust for this automatically. Check with your manufacturer to see whether this is the case to avoid double-compensating for sagittal height.

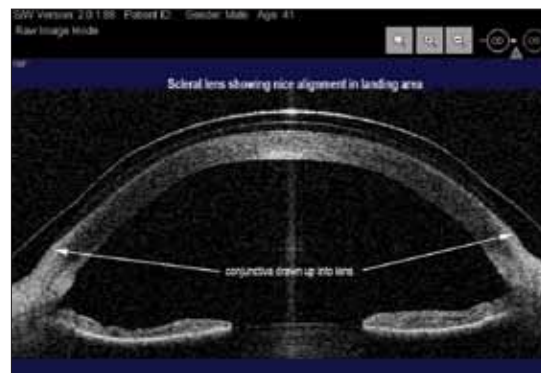
## Limbal Clearance

Bridging over the entire cornea is important, as discussed. This may also include the limbal area where the stem cells are located. Stem cells are believed to be crucial for corneal health, in particular for processing new epithelial cells, which are then distributed over the entire cornea. Limbal pooling may be important to bathe the fragile limbal stem cells. A limbal clearance of 100 microns is often striven for, but this depends on lens size; less clearance in this area may lead to corneal touch upon lens movement. Any type of limbal staining is believed to be unacceptable.

Limbal clearance can be achieved in different ways, depending on the manufacturer rules and lens design. Basically, choosing a back optic zone radius slightly flatter than the flattest keratometric values helps alleviate pressure in the limbal area.

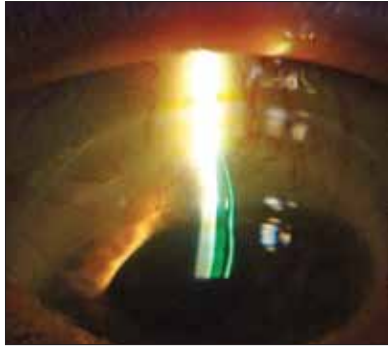
With corneo-scleral lenses it is hard to avoid the limbal zone, since by definition this is where the lens's landing zone is positioned. Still, the aim is to avoid excessive pressure in the limbal zone. Fluorescein evaluation should reveal minimum bearing in the limbal area, which

*Stem cells are located in the limbal area and are crucial for corneal health, in particular for processing new epithelial cells, which are then distributed over the entire cornea. Practitioners should strive to avoid mechanical pressure in the limbal area.*



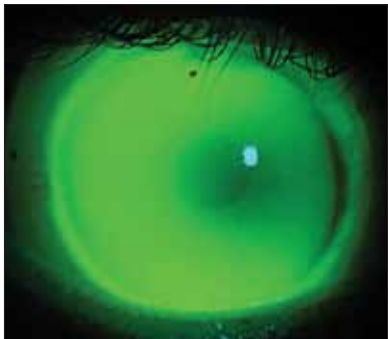
Corneal and limbal clearance visualized with the OCT (Zeiss Visante®)



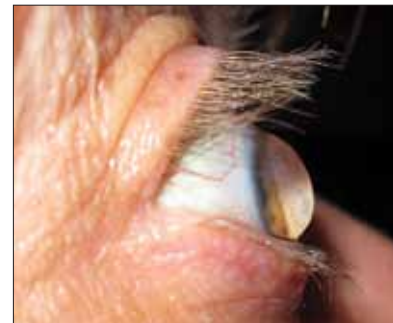
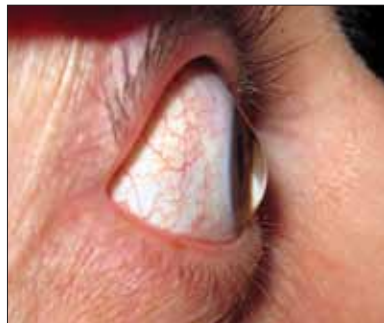
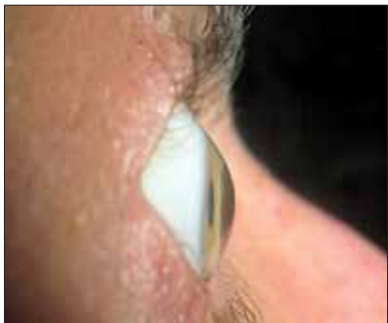STEPHEN BYRNES

Limbal vaulting with mini-scleral lens



Limbal bearing nasally visible in the fluorescein pattern



GREG DENAEYER

I have found that just observing the eye from the side allows me to determine whether I should start with a diagnostic lens that has either a low, medium, or high amount of sagittal height. – Greg DeNaeyer

*In a grading scale system described in Eye & Contact Lens by Visser et al for large diameter scleral lenses, a slightly suboptimal clearance that is too low is rated as grade -1 (clearance of 100 and 200 microns), while a grade -2 would be less than 100 microns. A clearance between 300 and 500 microns is considered "big" (grade +1) but acceptable in this scale, while a clearance of more than 500 microns may be considered excessive (grade +2). For limbal clearance, an absence of clearance would be grade -2, while between 0 and 100 microns of clearance would be regarded as grade -1. A clearance of roughly 100 microns is considered optimal, while a clearance of up to 200 microns may be considered slightly excessive (grade +1). More than 200 microns is considered excessive (grade +2). As with any other lens fitting, grade one of any variable is usually considered "acceptable," while a grade two typically means action is required to alleviate the problem.*

Visser et al 2007a

should be checked regularly for staining. Some corneo-scleral lens designs come with different transition zone profiles, increasing or decreasing the limbal zone clearance. Choosing a different limbal zone profile can alleviate pressure in the limbal zone.

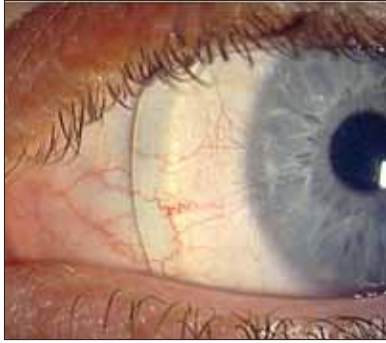
If persistent bubbles are present in the limbal zone, decreasing the limbal clearance (by lowering the back optic zone radius or by choosing a lower limbal zone profile) may alleviate this problem.

OCT imaging can show and even precisely determine the amount of clearance from center to limbus in different meridians, which could be a useful tool in lens fit assessment.

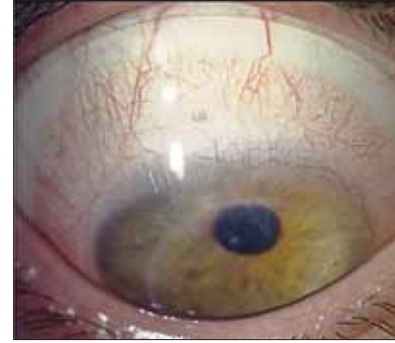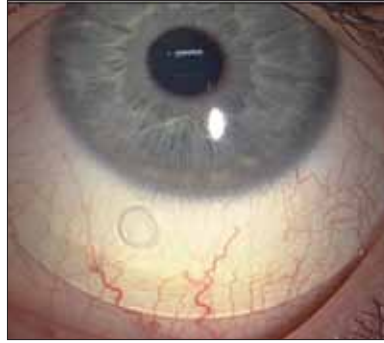### Step 3: Landing Zone Fit

- How to align the periphery of the lens with (corneo-) scleral shape
- How to evaluate and assess conjunctival blanching

The landing zone is closely related to the clearance: a landing zone that is too steep will lift the entire lens off the cornea creating more clearance, while if there is severe central corneal touch the lens landing zone will be lifted off the ocular surface, making its fit difficult to assess.



Good distribution of pressure underneath the landing zone area in a large diameter scleral lens



Local blanching underneath the landing zone of a large scleral lens

VISSER CONTACT LENS PRACTICE

The goal with this zone is to create an alignment with the sclera or corneo-scleral transition (depending on lens type). No current instrument in clinical practice is able measure this. The only two options available seem to be objective slit lamp evaluation and the experimental OCT technique. Some practitioners evaluate the corneo-scleral profile by using the slit lamp with a cross-sectional view of the anterior ocular surface or by simply observing the anterior ocular shape without magnification by having the patient look downward to get a first impression of the anterior ocular surface shape. Others rely fully on trial lenses to observe and potentially adjust the alignment of the landing zone with the anterior ocular shape.

Once the trial lens is placed, assess the fit based on how the landing zone bears on the ocular surface. A ring of bearing on the inner part of the landing zone indicates that the landing zone is too flat. Air bubbles in the periphery of the lens also indicate this. Frothing may be present at or under the peripheral lift, indicating the same effect. Additionally, fluorescein evaluation can be helpful in evaluating the landing zone, as reported by some practitioners, but may be limited in use compared to corneal GP lens fitting assessment.

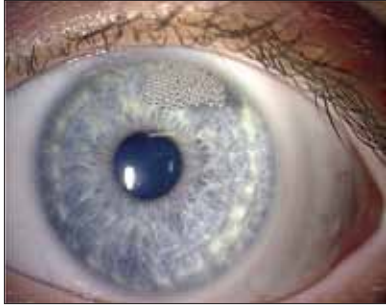
*The landing zone is closely related to the clearance: a landing zone that is too steep will lift the entire lens off the cornea creating more clearance, while if there is severe central corneal touch the lens landing zone will be lifted off the ocular surface, making its fit difficult to assess.*

*Manufacturers typically have long-term experience with average landing zone shapes for their particular lens designs. Use the recommended landing zone trial lens as a start, based on their knowledge and insights.*

*The analogy of snowshoes has been made for large size scleral lenses as compared to stiletto heels for smaller scleral lenses with regard to potential indentation and compression.*  
*DePaolis et al 2009*

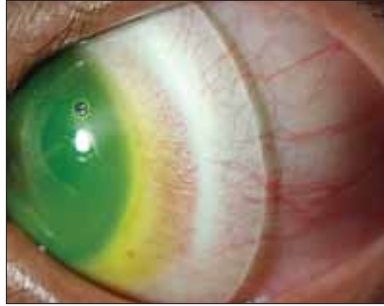For steep lens fits in the landing zone area, the bearing would be on the outer zone and fluorescein pooling would be visible extending inward underneath the landing zone from the corneal clearance. A steep landing zone will “lift” the entire lens off the cornea, increasing the total vault of the lens.

Since it is actually the bulbar conjunctiva that is being fit, it is very helpful to look at pressure of the lens periphery on the bulbar conjunctiva. Localized areas of the conjunctiva surrounding the limbus can be “whitened” because compression of the lens on the conjunctiva restricts blood flow — which is referred to as conjunctival



VISSER CONTACT LENS PRACTICE

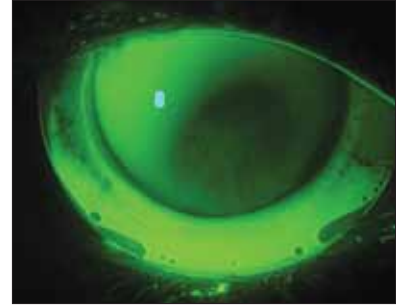
Air bubbles/frothing under scleral lens in the periphery



JAN PAUWELS

Circumcorneal blanching underneath the landing zone of a large scleral lens

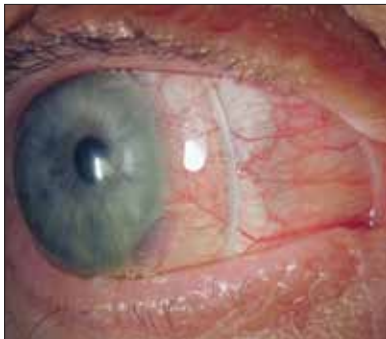© Universitair ziekenhuis Antwerpen



Air bubbles underneath the landing zone periphery

blanching. Circumcorneal blanching, or blanching in more than one direction, seems more problematic than a single area of blanching, which may be acceptable at times. Practitioners are advised to observe and assess the blanching in different eye gaze positions, since decentered lenses can cause a different pattern than would the static slit lamp position with a straight eye gaze.

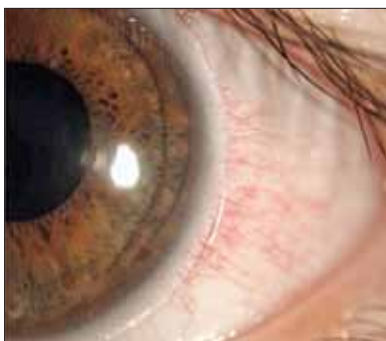This blanching of the conjunctival vessels is the result of excessive bearing of the scleral lens on the peripheral curve and is often referred to as compression. Compression typically will not result in conjunctival staining following lens removal, but rebound hyperemia at the location of the compression may be seen.



GREG DENAEYER

If the edge of the lens is focally pinching the conjunctival tissue, this will result in “impingement,” and this may cause conjunctival staining after lens removal. Long-term impingement may result in conjunctival hypertrophy.

The discussion on lens diameter has its main weight—literally—on this parameter, the landing zone fit: the larger the scleral lens, the more lens weight is distributed over a larger area of the sclera. This causes the large scleral lens to “float” more and, although counterintuitive, movement is often better (although still limited) with larger scleral lenses compared to smaller scleral lenses.




SOPHIE TAYLOR-WEST

Conjunctival impingement

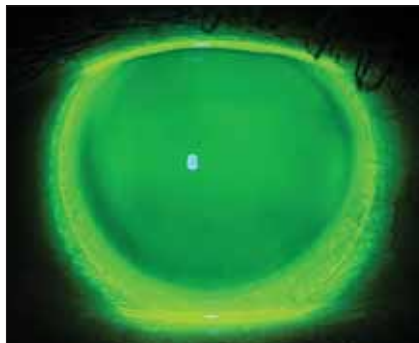
*Since it is actually the bulbar conjunctiva that is being fit, it is very helpful to look at pressure of the lens periphery on the conjunctiva. Localized areas of the conjunctiva surrounding the limbus can be “whitened” because compression of the lens on the conjunctiva restricts blood flow—which is referred to as conjunctival blanching.*

Use the “push-in” method to assess the lens periphery: nudge the lower lid just below the lens edge and indent the sclera gently to assess how much pressure is needed to cause slight stand off. A well fitting edge will need a gentle push. If a hard push is needed, a tight periphery is indicated. If very little pressure is required, the edge may be too flat.

Sophie Taylor-West 2009



The “push-in” method to assess the lens periphery



Impingement ring is seen in this case after lens removal.

SOPHIE TAYLOR-WEST

## Step 4: Lens Edge

- How to assess scleral lens edge lift
- How to increase or decrease edge lift

As with GP corneal lenses, a scleral lens needs some edge lift. However, this should not be excessive or it may affect comfort. Although lens movement with scleral lenses is not always possible and is usually not achieved, a good edge lift may promote healthy lens wear and, upon push-up, it would be preferred if the lens showed some mobility. This may be more the case with larger lens diameters than with smaller scleral lenses.

Too much edge lift can cause lens awareness and discomfort, whereby it is advised to decrease the edge lift by changing the landing zone angle or by choosing a smaller landing zone radius of curvature.

Low edge lifts can leave a full or partial impingement ring on the conjunctiva after lens removal, and larger blood vessels may be impeded by the lens edge, causing an obstruction in blood flow through the vessel. In the absence of any injection or conjunctival staining this may be without consequences according to experienced scleral lens fitters, but long-term impingement may result in conjunctival staining and possibly hypertrophy.

You can evaluate the edge lift in a number of ways. Simply observe the edge lift with white light and observe how much it “sinks” into the conjunctiva and/or whether there is a lift-off, in which case a dark band or shadow will be visible underneath the lens edge. Or fluorescein can be very helpful, as with corneal GP lens fitting. Some practitioners observe the volume of the tear meniscus that is present around the lens edge to evaluate this parameter.

Some practitioners also evaluate how much tear film exchange is occurring by adding fluorescein to the ocular environment after the lens has been placed on the eye and waiting to see how long it takes before fluorescein reaches the tear reservoir behind the lens. Sometimes it takes only a minute for fluorescein to reach the post-lens tear film reservoir — but it also can take several minutes to infinity for fluorescein to penetrate behind the lens. Likewise, the time it takes for fluorescein to “empty” from behind the scleral lens if it was added at the time of lens placement may also provide some kind of indication on tear film exchange (Ko 1970).

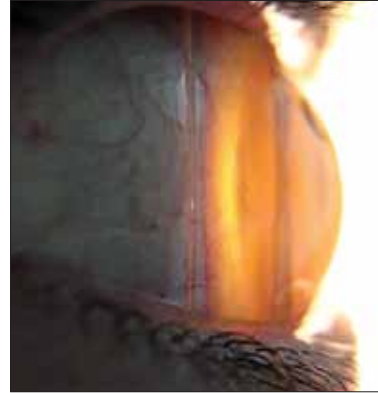
*As with some other parameters, the lens edge design is not always variable in all lens designs. If the lens edge is undesirable, the landing zone (step 3) may need to be altered to optimize this if the edge lift itself is fixed.*



**Compression:** Blanching of the conjunctival vessels as a result of excessive bearing of the scleral lens peripheral curve. Compression typically will not result in conjunctival staining following lens removal, but you may observe rebound hyperemia at the location of the compression.

**Impingement:** The edge of the lens focally pinching the conjunctival tissue. Impingement will result in conjunctival staining after lens removal. Long-term impingement may result in conjunctival hypertrophy.

Lynette Johns



STEPHEN BYRNES

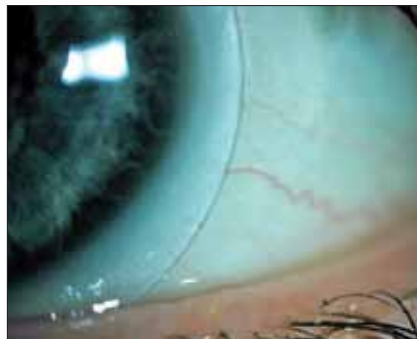

Lens edge and profile of a mini-scleral lens on extreme keratoconic eye—note the air bubble behind lens.

As with some other parameters, the lens edge design is not always variable in all lens designs. However, it is an important variable to evaluate when assessing the lens fit. If undesirable, the landing zone (step 3) may need to be altered to optimize this if the edge lift itself is fixed. For tangential landing zone designs, the landing zone angle can be chosen with a lower level of incline (seen from a horizontal plane), while for curvature-based landing zones the periphery of the lens can be altered by increasing the radius of curvature. Both would have the effect of a “flatter” periphery. Steps 3 and step 4 of this guide are therefore typically closely related. For more details on specific lens design options—see chapter III of this guide.

Different parts of the lens, 360 degrees circumcorneal, can be very different because of the described nonrotationally symmetrical nature of the anterior ocular shape. If one or more areas are considerable outliers, either by lift (causing air bubbles) or by impingement/blanching, a nonrotationally symmetrical lens design may be required (see next step in this chapter).

*A method to determine where a problem with a scleral lens is located is to have the patient squeeze his or her eyes with the lenses on. A well fitting scleral lens will cause no symptoms or increased awareness when the patient squeezes his or her eyes. Patients can be very “quadrant specific” after the squeeze test of areas where there is either impingement or edge lift.*

Lynette Johns



SOPHIE TAYLOR-WEST

Larger blood vessels may be impeded by the lens edge.

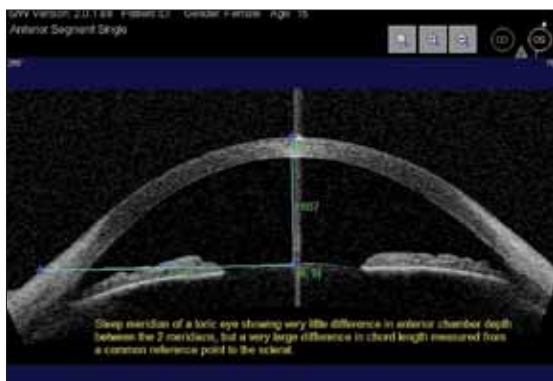
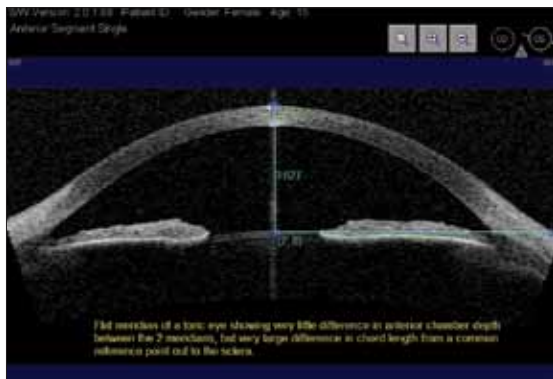
## Step 5: Nonrotationally Symmetrical Lens Design

- How to choose a toric scleral lens design
- How to choose a quadrant specific scleral lens designs

From clinical experience and from pilot studies on corneal shape as described in chapter II of this guide, it appears that more often than not the anterior ocular surface is nonrotationally symmetrical in shape. This means that one or more segments of the sclera are either steeper or flatter than other parts. Oftentimes when a scleral lens is placed on the eye, one segment of the conjunctiva is pressed more, possibly resulting in blanching in one or two segments underneath the lens. This is difficult to deal with: some companies have tried to truncate the lens where the blanching occurs to alleviate pressure in that direction or to “grind” the back surface of the scleral lens to reduce pressure in specific areas. These methods may work, but also have their limitations. Toric or quadrant specific scleral lenses are now available as an alternative to overcome this problem in a more structured and controlled way. The toric or quadrant specific portion of these lenses is

*If you observe 3-o'clock-to-9 o'clock blanching in the absence of pinguecula, order a toric landing zone or decrease the overall sagittal depth of the lens — either by flattening the base curve or adjusting the peripheral curves — provided it does not result in edge lift off from 12 o'clock to 6 o'clock.*

*Christine Sindt 2008*



GREG GEMOULES

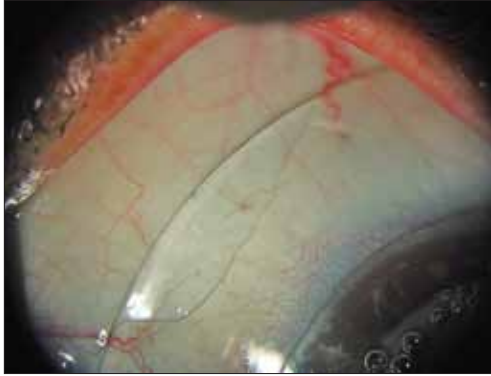Flat and steep meridian of an eye with a toric anterior ocular shape – note the difference in chord length measured from a common reference point: 8.02 mm in the flat meridian (165 degrees) versus 7.34 mm in the steep meridian (75 degrees) with the Zeiss Visante® OCT. – Greg Gemoules

situated on the landing zone; the optical zone is free of any toricity unless optically a front toric correction is needed and added to the lens.

Applying toric and quadrant specific lenses may be one of the more challenging aspects of scleral lens fitting, but at the same time it also is one of the most promising: nonrotationally symmetrical scleral lenses can significantly improve scleral lens fit and comfort of wear. This technology proves to be a successful addition to the standard scleral lenses available. Scleral lenses are usually made of high Dk materials, which will allow for some flexure on-eye that can smooth out the irregularities on the ocular surface to some degree (DeNaeyer 2010), but since this can lead to lens flexure, nonrotationally symmetrical lenses seem advised if the anterior ocular surface shows an irregular shape.

### Fitting Toric Scleral Lenses

Visser et al (2006) reported that toric scleral lenses allow for a more equal distribution of pressure over the sclera, which promotes anterior ocular surface health and improves comfort of lens wear. It also creates a stable lens on the eye. The lens finds its own resting position, just like a back toric corneal GP lens would, although it seems advised to place a mark on the lens so that patients know how to insert the lens correctly



Rotationally symmetrical scleral lens on a nonrotationally symmetrical sclera.  
© Universitair ziekenhuis Antwerpen

JAN PAUWELS

straight away. But even after manually rotating the lens it returns to its natural position on the eye within seconds, according to Visser.

Typically, toric scleral lenses have fixed differences in sagittal height between the two principal meridians. The first and smallest difference between the two principle meridians may be labeled “toric one,” followed by “toric two,” etc. (which does not reflect dioptric differences as in corneal GP lenses). The exact difference in microns between the two meridians depends on lens manufacturer, and often is confidential. The range can be between 100 and 1,000 micron, but based on theoretical considerations, the difference within the average eye between meridians easily could be 500 microns, as this appears to be the difference in sagittal height on the average cornea on paper (see chapter II).

The scleral lens fit should be evaluated just like a rotationally symmetrical lens: there should be no or limited compression or lift of the landing zone on the ocular surface. If the lens fit is still unacceptable, a next step up in sagittal height difference between the meridians can be tried until an acceptable situation is reached. If the fitting is acceptable, an overrefraction should be performed and a front cylinder can be added if the visual acuity is suboptimal. This can be done without any prism ballast, taking the inclination of the lens into account to determine the lens astigmatism axis as with standard corneal lenses (e.g. LARS rule — left add, right subtract).

This opens up this modality for other front surface optical applications, which are often required for irregular corneas such as vertical COMA (which is highly prevalent in keratoconus).

*The scleral lens fit in toric or quadrant specific lenses should be evaluated just like a rotationally symmetrical lens: there should be no or limited blanching or lift of the landing zone on the anterior ocular surface.*

### Fitting Quadrant Specific Lenses

For quadrant specific lenses, typically an empirical lens fitting approach is used: the practitioner uses a standard fitting set and defines the area of lift-off at the edge of the lens and tries to establish the amount of lift in one or more quadrants. The level of lift-off may be judged by using an optical section and a reference, such as the central corneal thickness. If only one quadrant is changed, in theory it does not matter where that quadrant is placed by the manufacturer since the lens should find its way on the eye. However, in practice it is seen that these lenses do not move much, and typically a mark is placed on the lens just like in toric scleral lenses so that the patient knows how to insert the lens in order to get it right upon insertion. To do so, the practitioner must indicate which quadrant needs to be adjusted to the manufacturer. Also if more than one quadrant needs to be altered (flattening one quadrant and steepening another is technically doable), the location of the specific quadrants needs to be indicated.

Very advanced scleral lens fitters actually would be able to give the manufacturer a pretty detailed description of the desired quadrant specific design, e.g.; the lens needs 100 microns flatter in the inferior segment, 200 microns superiorly etc. If desired, front optics can be applied, as with toric scleral lenses and using the LARS rule (see item above).

*It is interesting to note that front toric against-the-rule cylinders will naturally align on axis in eyes having eyelid margins that oppose each other in the vertical meridian—as these lenses create thin zones at 6 and 12 o'clock. If the lid margins oppose each other more obliquely, the lens will rotate obliquely. With-the-rule optical corrections rotate off axis in the absence of another form of stabilization. Best success regarding front toric scleral lenses is with against-the-rule cylinders on Caucasian eyes.*

*Stephen Byrnes*

### Fitting Front Toric Scleral Lenses

If the overrefraction indicates the need to include a cylindrical correction, while no toric back surface toricity is present, a true front toric scleral lens may be needed. These lenses need to be stabilized somehow on the eye, just as front toric corneal GP lenses or soft toric lenses do. Double slab-off ballasting stabilization lenses have been used to stabilize a front toric optical correction on the eye. Eyelid composition may have an effect of lens rotation and inclination.

When ordering these lenses, taking the inclination of the lens into account to determine the lens astigmatism axis as with standard corneal lenses (e.g. LARS rule) is required.

### Movement

Scleral lenses typically do not move. As discussed, larger lenses tend to be somewhat more mobile on the eye. Upon slight pressure with the push-up method, the lens should ideally be reasonably mobile. Spontaneous lens movement upon blinking is not very common. In fact, too much movement can actually be problematic. Unlike corneal lenses, vertical movement in scleral lenses does not seem to increase tear circulation (DePaolis 2009). It can, on the other hand, cause patient discomfort and dissatisfaction.

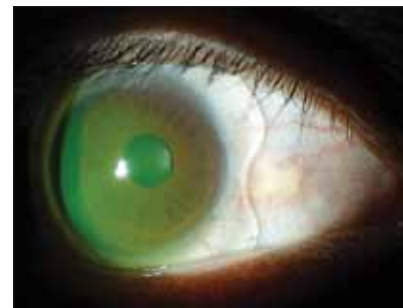The landing zone is an important variable concerning lens movement, and blanching in this area should be avoided. Changing the lens edge does not necessarily have an influence on lens movement, especially not if blanching is present. Scleral lenses with too little apical clearance may “rock” on the central cornea, and this may cause an increase in lens mobility as well as discomfort and decentration. Oftentimes, movement corresponds to the scleral toricity as well. It may rock along the flat meridian, while changing to a nonrotationally symmetrical lens design can stabilize the lens.

### Overrefraction

Lens power should not be a main consideration during the lens fit. Creating the optimal lens fit is the first and most important objective, which can be challenging enough; refractive power is a later consideration. Strive for a lens fit that respects the shape of the anterior eye; only once the most optimal lens fit is reached is an overrefraction required. The overrefraction should be converted back to a vertex distance of zero if this exceeds 4.0 D spherical equivalent.

*I have effectively used pinguecula notches to stop rotation—I get the lens lined up on axis on the eye, mark the lens, then notch the lens at the pinguecula and I have a non-rotating lens that stays on axis. Truncations at the lower lid do not work very well to stabilize front toric scleral lenses on the eye.*

*Stephen Byrnes*



EMILY KACHINSKY

In some instances it may be necessary to be creative in order to fit scleral lens patients, for example, the use of a pinguecula notch. This modification can even be adapted to help accommodate a patient with a filtering bleb. – Emily Kachinsky

*A well fit, non-suctioning scleral lens may demonstrate no tear exchange and still be successful. Having tear exchange means that the lens will not suction. Not having tear exchange does not necessarily mean it will suction. Excessive tear exchange may mean that tear debris will be brought into the lens reservoir.*

*Lynette Johns*

For overrefraction, some practitioners recommend trial lens frames and lenses over a phoropter.

If the base curve radius of the final lens will be ordered differently from that of the diagnostic lens, the standard corneal GP lens “rule of thumb” applies: 0.10 mm of change in radius is 0.5D change in refraction according to the SAM/FAP rule (SAM — steep add minus, FAP — flatter add plus) — see also the optics section in chapter III of this guide.

---

*Key points:*

- *Scleral lenses should have enough total diameter to bear the weight of the entire lens on the anterior ocular surface and to create a sufficient tear reservoir (step 1).*
  - *Creating adequate corneal clearance is the key advantage in scleral lens fitting (step 2).*
  - *To respect the shape of the anterior surface, aligning the landing zone with the anterior ocular surface (step 3) and creating adequate edge lift (step 4) is important while in addition, nonrotationally symmetrical lens designs may be desired to reach this goal (step 5).*
-



## v. Managing Scleral Lens Wear

- How to handle, store and care for scleral lenses
- How to manage the most common scleral lens complications

This section will discuss factors that play a role in scleral lens fit, wear and follow up. The first part of this chapter will outline handling and storage of scleral lenses plus lens care and the role of solutions, followed by the management of scleral lens complications and problem solving in the second part.

### Handling, Storage and Solutions

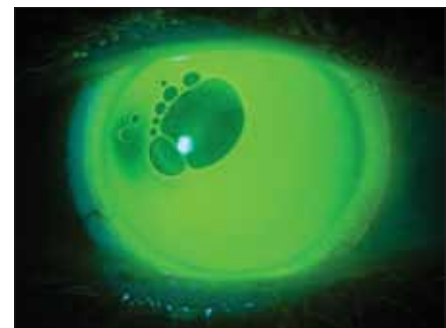
#### Handling

Handling, and especially “bubble free” lens insertion, may be one of the most challenging parts of the scleral lens fitting process for both practitioners and patients.

#### Lens Placement

1. When placing the lens on the eye, it is of the utmost importance to make sure the patient’s face is completely parallel to a horizontal plane, typically the table.
2. The scleral lens should be fully filled with fluid upon lens placement.
3. To support the lens, use the thumb and the index and middle fingers (and maybe the ring finger), or use a plunger for this purpose.
4. Lift the upper eyelid slightly using the other hand by pushing the eyelid against the superior orbital rim and gently slide the lens edge underneath the upper eyelid.
5. Keep the lens in that position and then slide back the lower eyelid while the patient looks slightly down.
6. Place the lens on the eye (fluid from lens may spill) and let go of the lower eyelid. The eyelid will then slide over the lower part of the lens edge and the lens is in place.
7. The upper eyelid can be let go as well at this point, and if a plunger is used to support the lens it can be released.

For lens evaluation, the scleral lens should be fully filled with fluid and fluorescein. Be careful with this: fluorescein may stain clothing. In the fitting process, allow the lens to settle for 20–30 minutes, but always check the patient behind the slit lamp before referring them to the waiting room to see if there is adequate clearance, whether the lens wettability is acceptable and check the eye for foreign bodies behind the lens as they can irritate the eye but don’t necessarily lead to immediate discomfort (as with corneal lenses). Also immediately check for air bubbles, and if present — reinsert the lens.



Insertion air bubble underneath the scleral lens

## Lens Removal

Removal of lenses is typically done in one of two ways: the manual, two-finger removal method and/or with the use of a plunger. Oftentimes both methods are explained to the patient. The first choice may be the manual removal method, since no additional accessory is required. If that for some reason is not successful, for instance in older patients, then the plunger method can be used as an alternative.

## Lens Removal

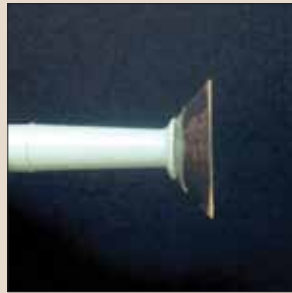
For the manual method:

1. Instruct the patient to look slightly down.
2. Slide the lower eyelid gently outward while slightly putting pressure on the eyeball.
3. Gently push the lower eyelid with the index finger underneath the lower edge of the lens.
4. The lower part of the lens will come loose from the ocular surface and will “drop” out of the eye — preferably into the hand of the person removing the lens.

When removing the scleral lens with a plunger:

1. Aim for the lower half of the lens with the plunger.
2. Once the plunger is sucked on, make a movement away from the eye, and upward. This will break the seal and the lens can easily be removed.
3. Lift the lens edge from the eye.

Upon lens removal, it is important to break the negative pressure underneath the lens, which can also be accomplished by gently pressing on the sclera adjacent to the lens edge if the initial method is causing problems.



GREG DENAEYER

*It is critical that the plunger be positioned at the edge of the scleral lens during removal. In this position, as in the picture on the left here, the lens edge is lifted off, releasing the negative pressure, which prevents the lens from pulling on the anterior segment.*

*Positioning the plunger in the center of the lens during removal, as in the picture on the right here, can put the patient's eye at risk for significant injury. In this position the scleral lens now becomes a giant plunger. If removal is attempted in this situation, the patient can suffer significant pain, an abrasion, or graft dehiscence in the case of a corneal transplant.*

*Another situation involves a patient attempting removal with a plunger when the lens is actually not on his or her eye. The patient could easily plunge the cornea or conjunctiva, causing significant injury. With these thoughts in mind, it is critical that patients receive complete instructions on how to use plungers and the dangers that they pose if not used properly. – Greg DeNaeyer*

The plunger method has the disadvantage that corneal damage can occur in patients who attempt to remove the lens while it is no longer in place (and the cornea is directly approached). This is particularly of concern in patients with a corneal transplant: incidental cases have been reported of corneal grafts being plunged with irreversible damage to the eye.

## Storage and Solutions

### Disinfection

A point that cannot be stressed enough to the patient is that the lenses cannot be stored in saline overnight because of the risk of microorganism growth and the consequential risk for a microbial keratitis. A contact lens disinfection solution should be used for storage at all times and should be refreshed every night. GP lens disinfection solutions as well as GP multipurpose solutions have been recommended by practitioners for scleral lens care. Peroxide systems have also been frequently mentioned as a good alternative to provide a care system that is neutral and safe to the eye. Large size containers specially designed for scleral lenses are available for this purpose. Peroxide systems do have the disadvantage that occasionally peroxide can get in the eye and cause irritation, and it is not recommended for storage times longer than one night since there is usually no continuous disinfection action once the solution is neutralized.

*Because of the limited tear film exchange behind scleral lenses, exposure to any substance behind the lens is many times greater than with corneal contact lens wear, so many practitioners advise using the most neutral system available.*

### Lens Placement

The scleral lens should usually be filled with fluid. Nonpreserved saline is most commonly recommended by all practitioners when applying scleral lenses to the ocular surface, although in the United States of America this is not approved by the Food and Drug Administration (FDA) and this would be considered an off-label use. Because of the limited tear film exchange behind scleral lenses, exposure to any substance behind the lens is many times greater than with corneal contact lens wear, so many practitioners advise using the most neutral system available. Even the buffer content in saline has been reported to cause sensitivity reactions to the eye (Sindt 2010b).

Rinsing off any conditioning solution, if present, with nonpreserved saline solution before placement has been most frequently advised by experienced practitioners. Instruct patients that nonpreserved solutions can only be used for a very limited time once the package has been opened, and single-dose units are highly recommended for this purpose. Again — make sure patients understand that saline cannot be used for overnight storage. Aerosols are best avoided as they tend to create small air bubbles and have been reported to be uncomfortable.

### Wettability

Wettability issues can affect the success of lens fitting, and for some patients using a conditioning solution instead of the commonly used saline solution upon lens placement is reported to be helpful. But as said, proceed cautiously regarding lens applications with these solutions because of the viscosity and the preservatives in the solution. Filling the lens with a conditioning solution when inserting the lens is usually not recommended. Some practitioners advise to gently add saline to the lens when it is removed from the storage case of conditioning solution, leaving as much of the conditioning solution on the lens surface as possible. Others recommend rubbing the lens surface with a conditioning solution before insertion to improve wettability (but not to fill the bowl with the solution).

## Cleaning

Cleaning of a scleral lens is usually done manually, with alcohol-based cleaners often preferred. This is believed to have a positive effect on lens surface wettability. Excessive rinsing is important to remove all cleaning solution from the lens. Occasional cleaning with a 2-component intensive cleaner that contains sodium hypochlorite and potassium bromide is frequently mentioned as an additional procedure that is effective, especially against protein buildup.

Some practitioners recommend using a soft lens multipurpose solution for the cleaning step. The cleaning action may not be as good as with special cleaners, but compatibility with the eye may be better. This also would be considered off-label use in the USA.

Find out what the scleral lens manufacturer's recommendations and guidelines are for the lens solution system of choice.

For longer storage intervals, e.g. in trial sets and spare lenses, scleral lenses can usually be stored dry. Upon application of the lens, alcohol-based cleaners can be used to optimize wettability.

Scleral lenses are recommended for daily wear only, but overnight use of scleral lenses may be indicated on occasion (Pullum 2007), but only if there are extenuating circumstances, that is, if there is a therapeutic application which makes overnight wear necessary to alleviate pain or to maintain corneal hydration. Since overnight wear has been shown to generate more hypoxic response compared to daily wear, there must be a justifiable reason to do so such as overnight protection or overnight corneal hydration. In extended lens wear, the lenses still need to be removed regularly for a cleaning cycle and refilled with fresh fluids. Some practitioners work with two pairs of scleral lenses in case extended wear is needed: one for the night and one for the day. While one pair is worn, the other pair undergoes a cleaning and disinfection cycle.

*Be aware of what medications patients use with their lenses, since this in itself can alter wettability and can cause toxic reactions.*

*Jason Jedlicka 2008*

## Sports

A frequently mentioned advantage of scleral lenses is that they can be very advantageous for vigorous sports, mainly because loss, displacement and decentration are unlikely. For some water sports, scleral lenses are indicated. Scleral lenses will not wash out, absorb contaminants, or change their fitting characteristics during water sports, and even underwater loss of the lens is unlikely. But hygienic considerations apply as with normal lens wear for swimming with lenses, and the increased risk of corneal infection should be explicitly explained to the lens wearer.

---

### *Key points — Handling, Storage and Solutions:*

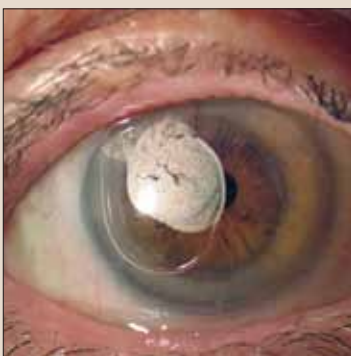
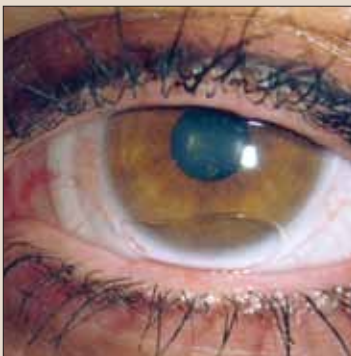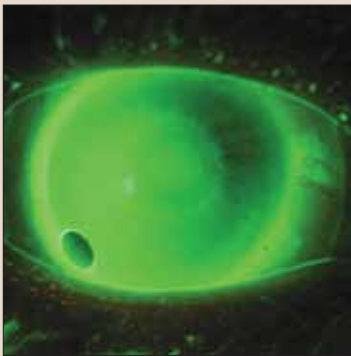
- *Handling and "bubble free" lens insertion may be one of the most challenging parts of the scleral lens fitting process.*
  - *Practitioners should be careful when instructing patients about the plunger technique to remove scleral lenses, especially in the case of patients with a corneal transplant.*
  - *Neutral solutions are advised, since the exposure time of the tear reservoir to the ocular surface is high.*
-

## Scleral Lens Complications

The most commonly described complications that may occur as a part of scleral lens wear are listed here in alphabetical order. The key learning points are given directly after each item in this part of the guide, rather than at the end of the chapter as is done in the other chapters in this guide.

*A successful fit means the patient is comfortable with no or minimal signs of staining or injection after removal. The best time to observe early complications is after the lens has been worn for three to six hours. Look to see what stains when the lens is removed, after observing how the lens sits on the eye.*

*Jedlicka et al 2010b*



GREG DENAEYER

*Scleral lenses with diameters over 18 mm with air bubbles secondary to insertion.*

*Greg DeNaeyer*

### Air Bubbles

One of the most common “complications” of scleral lens fitting is air bubbles that get trapped behind the lens, either caused by inadequate lens placement or because of improper lens fit. They can cause discomfort and vision problems and may lead to dry spot formation on the cornea. The first cause is a handling issue; see the session earlier in this chapter on lens insertion. The second cause, related to lens fit, could be approached by looking at the location and size of the bubbles. If air bubble formation happens frequently, then there is a bigger chance that this is due to a lens fit complication. If it happens infrequently, then chances are it is related to the insertion technique. Following are a few tips and tricks for trying to manage air bubbles behind the lens.

First of all: bubbles may subside as the lens settles on the eye. It is advised to give it some time. However, if the bubbles remain — observe their location. Central bubbles indicate that the central sagittal height value is too large and needs to be lowered. Small bubbles that move behind the lens may be acceptable as long as they do not cross the pupil margin. Large stationary bubbles are not acceptable.

Peripheral bubbles can be arch-shaped. Bubbles may more commonly form temporally than nasally due to the difference in scleral shape in the horizontal meridian (see chapter II). Nasal-inferior bubbles may be bothersome for patients while reading. Bubbles in the limbal area indicate too much limbal clearance, and this needs to be dealt with by adjusting the base curve radius (steepening the base curve) or by decreasing the limbal shape profile, depending on lens design used.

Air bubbles are unfortunately not always preventable, especially when the tear reservoir is not uniform, as in corneal ectasia, for instance. Some recommend using a more viscous solution to insert the lenses if air bubbles are consistent upon insertion,



but be aware of toxic reactions. Nonfenestrated lenses, as well as smaller size lenses, can also be tried if air bubble formation is persistent.

Determining the path of entry of the bubbles can be helpful to guide the fit and eliminate bubble formation. The bubble entry point follows tear film exchange. Oftentimes, nonrotationally symmetrical designs may be needed to “seal” the lens on the ocular surface and to prevent air bubbles from emerging behind the lens. See step 5 in chapter IV for more on toric and quadrant specific lenses.

---

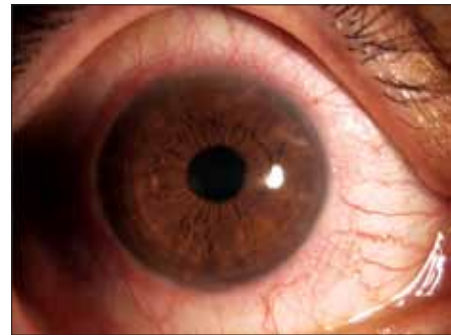#### *Air Bubbles*

- *Decrease the central or limbal clearance depending in the location of the bubbles.*
  - *More viscous solutions, nonfenestrated and nonrotationally symmetrical lenses may be helpful in alleviating the problem.*
- 

#### **Bulbar Redness**

Bulbar redness can occur with scleral lens wear for a variety of reasons. These include mechanical stress on the conjunctiva, corneal hypoxia (edema), toxic reactions and bearing of the lens on the cornea or limbus. Usually this sign is secondary to a fitting problem, which should be dealt with first. For lenses that cause lens adhesion (also see the “lens adhesion” section in this chapter), redness may occur after lens removal as a rebound effect. Some patients are very sensitive to mechanical stress, but in these cases the redness can reverse itself fairly quickly.

Always exclude external causes of bulbar redness, including microbial involvement and allergic reactions, because the redness may not be directly lens related. Especially check for cells in the anterior chamber as one of the indications for this.



SOPHIE TAYLOR-WEST

Rebound bulbar redness after scleral lens removal

---

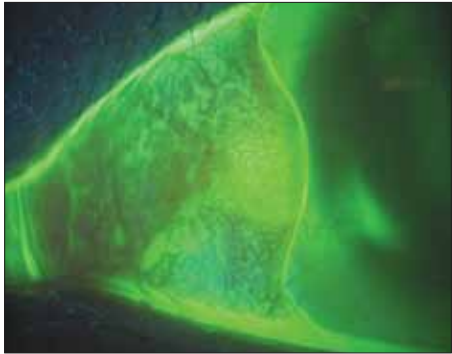
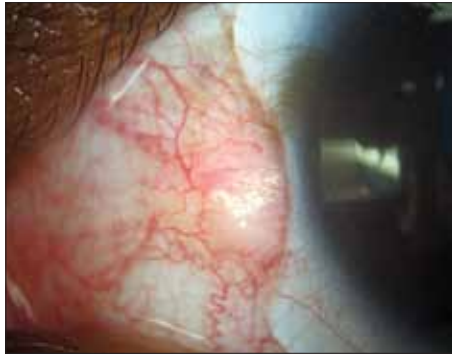#### *Bulbar Redness*

- *Conjunctival redness may be, among other things, an indication of a poor lens fit or hypoxic or toxic reactions.*
  - *Always exclude external causes of bulbar redness, as the redness may not be directly lens related.*
- 

#### **Conjunctival Blanching and Staining**

Conjunctival blanching is caused by local pressure on the conjunctiva, which can be sectorial or circumcorneal (see chapter IV). If the blanching is sectorial, this may be the result of an irregular scleral shape. A pinguecula can also cause local pressure and blanching. Loosening the periphery may work in some cases, but more likely nonrotationally symmetrical lenses or a notch ground into lens edge may remedy the situation.

Circumcorneal blanching results from a suboptimal landing zone of the lens (too steep or too flat). If the entire area underneath the scleral lens is blanched, increasing the landing zone surface area, usually by increasing the lens diameter may help. If the edge of the lens focally pinches the conjunctival tissue, this



CHRISTINE SINDT

Inflamed pinguecula fit with a newly fit pinguecula notch— with and without fluorescein

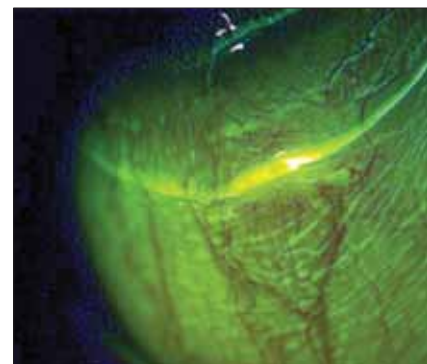
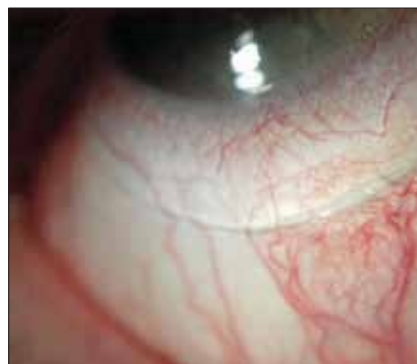of the staining. In corneal GP lens wear, it has been shown that dryness in the nasal and temporal portions immediately adjacent to the lens edge can lead to significant levels of corneal staining (3- and 9-o'clock staining). With scleral lenses the same effect could occur on the conjunctiva. Covering this area with the landing zone of the scleral lens by using a larger lens diameter may solve the problem.

may result in conjunctival staining after lens removal. Long-term result of this could be conjunctival hypertrophy. For full coverage of this topic see step 3 of the fitting process (chapter IV).

Since the cornea is less directly involved than the conjunctiva in scleral lens fitting, conjunctival staining may be more common than corneal staining. Sometimes conjunctival swelling and hypertrophy occurs. Conjunctival flaps or tears (the conjunctiva is torn) have been observed occasionally, caused by a sharp or damaged lens edge.

Conjunctival staining can be caused by a steep lens edge or possibly by mechanical pressure of the landing zone portion of the lens. The better the lens aligns with the scleral shape, the better the spread of pressure, which can decrease the amount of conjunctival staining. This occurs more often in the horizontal meridian. If the staining is present underneath the landing zone area, this seems to imply that the horizontal meridian is often flatter, causing more mechanical stress in the horizontal meridian. Nonrotationally symmetrical lenses may be indicated at this point.

If the staining is beyond the scleral lens borders, which can happen particularly in smaller scleral lenses, exposure and therefore dryness issues also may play a role in the etiology



LYNETTE JOHNS

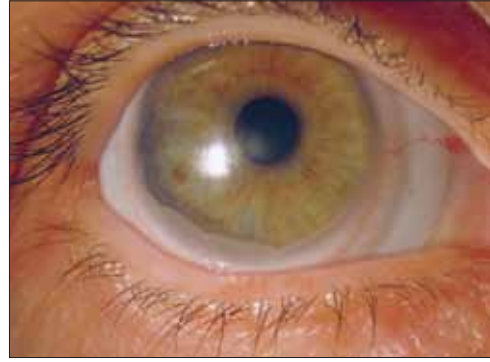Impingement of the scleral lens on the conjunctiva (left) causing local conjunctival staining (right).

### Conjunctival Blanching and Staining

- May be caused by a steep lens edge or by compression of the landing zone portion on the conjunctiva.
- Exposure also may cause conjunctival staining.

## Conjunctival Loose Tissue

In some cases loose conjunctival tissue (like in conjunctival chalasis) can be sucked underneath the lens because of the negative pressure under the lens. Loose conjunctiva is sometimes sucked into the transition zone of the lens, and it can even appear in the optical zone. In fenestrated lenses, it can also be sucked through the fenestration hole. Excessive conjunctival tissue can be removed surgically, but it does tend to be recurrent (Bartels 2010). Neovascularization has been reported to sometimes develop underneath the conjunctival flap.



GREG DENAEYER

Loose conjunctival tissue sucked underneath the scleral lens

---

### *Loose Conjunctiva*

- *Loose conjunctiva can be sucked underneath the lens.*
  - *It can be removed surgically but tends to be recurrent.*
- 

## Corneal Staining

Corneal staining may not be a frequent problem in scleral lens wear, presumably because the lens bridges most or the entire cornea.

If localized staining appears on the cornea, mechanical involvement due to lens handling should be included. Handling staining patterns can sometimes occur more in elderly patients, in patients with limited motor skills or in those with poor visual acuity. Upon removal, the scleral lens may scrape the cornea, possibly resulting in a vertical pattern of staining.

Incidentally, the scleral lens's fenestration holes can also cause abrasions if the tear reservoir underneath the lens is too minimal. Increasing the vault of the lens should alleviate this problem. Damaged lenses too can cause corneal abrasions. Large air bubbles have also been shown to cause localized areas of dryness, with consequent corneal staining.

For full corneal staining, consider toxic reactions or hypoxia as possible causes. As mentioned earlier, the exposure time of the cornea to the fluid underneath the lens is very high, and special caution should be taken regarding any substances used in lens care. The presence of preservatives and other chemicals in the post-lens tear film should be minimized as much as possible. Check the cornea for very faint patterns of corneal staining, which can potentially cover the entire corneal surface. Most practitioners advise to always take out the lens with every eye exam and to evaluate the ocular surface with fluorescein.

On the other hand: scleral lens wear does not result in some of the commonly seen types of corneal staining that occur in traditional lens wear, like dehydration in soft lens wear and 3- and 9-o'clock staining in corneal GP lens wear. In fact, persistent 3- and 9-o'clock staining in, for instance, a keratoconus patient wearing corneal GP lenses may be an indication to switch to a scleral lens.

---

### *Corneal Staining*

- *Localized staining: consider handling causes or lens related issues.*
  - *Full corneal staining: consider toxic reactions or hypoxia.*
-

## Discomfort

While in general comfort of scleral lenses is recognized as one of their main advantages, not all scleral fits achieve comfortable lens wear — even though technically they appear to be optimal. Bearing of the lens anywhere in the optical zone area, limbal occlusion or an ill-fitting landing zone may lead to discomfort. Changing the lens fit may alleviate the comfort issues.

Although tight lenses will be comfortable at first, patients with scleral indentation, vascular impingement and negative pressure buildup will complain of discomfort after lens removal and they frequently will be unable to wear the lens the next day (DePaolis 2009).

Lens discomfort also frequently is a sign of toxic reactions to preservatives in the solutions used and/or to tear debris in the post-lens fluid reservoir.

End-of-day discomfort may be alleviated by using comfort drops, but it is advised to use preservative-free drops.

---

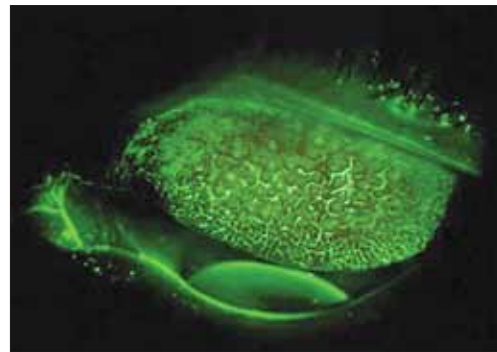
### Discomfort

- *Can be related to poor lens fit, but is not always avoidable.*
  - *Could result from toxic reaction to preservatives or debris in tear reservoir.*
- 

## Giant Papillary Conjunctivitis (GPC)

Because of prolonged periods of lens wear and the potential of surface debris buildup, GPC (also referred to in the literature as contact lens induced papillary conjunctivitis, CLPC) may not be uncommon in scleral lens wear, but it does not seem to be more of a problem than in normal soft and corneal GP lens wear. GPC is thought to be caused by a combination of mechanical irritation and/or an allergic or toxic reaction either to substances in contact lens solution or denatured protein on the lens surface. The latter can also cause mechanical problems, since the upper eyelid has to slide over the “rough” surface on every single eye blink. Keeping the lens clean and replacing it frequently may help prevent these problems.

GPC can cause excessive debris problems on the surface of the lens and wettability problems. Always check for GPC with every eye exam, and take preventive measures if indicated.



GPC in a GP lens wearer

HANS KLOES

---

### GPC

- *Appears to not be more prevalent in scleral lens wear than in corneal GP or soft lens wear.*
  - *Decrease mechanical irritation and potentially toxic/allergic substances.*
- 

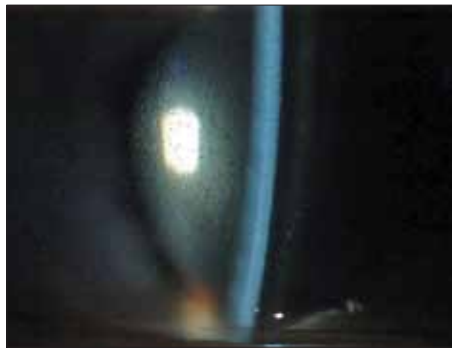## Hypoxia and Edema

Regarding hypoxic stress: it is advised, even with modern lens materials, to keep a close eye on corneal edema and corneal transparency during lens wear. See the lens material section in chapter III for more information on Dk versus Dk/t in scleral lens wear. High Dk GP lens materials are available today. To get

a good transmissibility (Dk/t) however, the lens thickness should be regulated as well. Thin lenses provide a better Dk/t, but lens flexure can be a problem with thinner lenses. Also, high Dk materials have been reported to result in some debris, wettability and clouding problems. Extra attention should be given to cleaning and maintaining the lens, as well as more frequent lens replacement.

Instruct patients to be wary of decreased visual acuity, especially at the end of the day, to monitor hypoxic conditions. Neovascularization can occur (also see the “neovascularization” section in this chapter), but was more of a complication in the time that PMMA materials were used.

Limbal edema is more likely to occur as a result of mechanical stress or lens adhesion (Sindt 2010a), as the oxygen supply is coming from the vasculature of the limbus. If limbal pressure is causing the edema, increasing the limbal clearance should alleviate the problem. If persistent, consider other contact lens options, including corneal GP lenses, piggybacking or hybrid lenses.



Graft microcystic edema

A low endothelial cell count may be one of the few scenarios in which scleral lenses may be contraindicated, as the endothelium plays a crucial role in providing the cornea with enough oxygen. It has been reported that an endothelial cell count of less than 800 cells/mm<sup>2</sup> is where the problems may arise (Sindt 2010a), and endothelial cell counts < 1,000 cells/mm<sup>2</sup> should be handled with extra care and may not be fitted with scleral lenses to avoid edema. More advanced stages of Fuchs’s dystrophy may be a true contraindication for scleral lens wear. Also, be careful in corneal transplant cases where graft rejection is a concern: the scleral lens may trigger the problem and may be the tipping point in causing major problems. Especially in these cases, watch for

graft swelling observed by the patient as a rainbow pattern around light sources (Sattler’s veil), or by the practitioner as microcystic corneal edema. Choose in any case a good corneal clearance and a high Dk/t material, maybe fenestrated lenses (as they may provide more oxygen to the cornea) and potentially lens discontinuation.

---

### *Hypoxia and Edema*

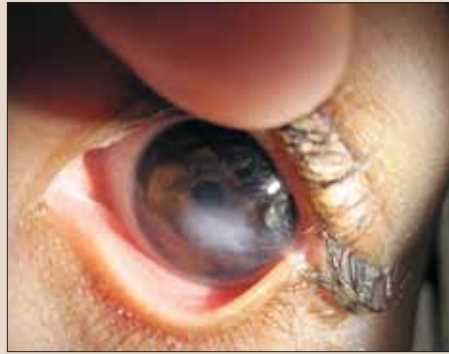- *High Dk/t materials should be considered to prevent corneal edema.*
  - *Limbal edema is more likely to occur as a result of mechanical stress or lens adhesion.*
- 

### **Lens Adhesion**

Lens adhesion is not a very common finding, but it can occur — more so after prolonged periods of lens wear. Lens adhesion may cause significant discomfort, reduced wearing time and may have a large impact on ocular health if it is not dealt with. Very rarely, lens adhesion could cause damage to the eye as a result of suction underneath the lens, especially in fragile corneas, such as in corneal transplants.

Lower corneal clearance lenses may give rise to more lens adhesion, and an increase in sagittal height may help overcome this problem. Lens adherence appears to happen more often if the lens creates a seal-off on the ocular surface and in dry eye conditions, such as Sjögren’s syndrome. Check the lens fit for excessive pressure on the conjunctiva. Lens flexure can also cause lens adhesion; increase the lens thickness to help avoid this. Comfort drops and an extra cleaning step during the day have been reported to be helpful.





CHRISTINE SINDT

*A 2 year old with neurotrophic keratitis after an Anaplastic Ependymoma resection left him with a 5th, 6th and 7th nerve palsy. This child had chronic eye infections until fit with a scleral lens for protection. Note the incredible elevation of the scar (picture on the left). Successfully fit with a scleral lens (picture on the right). – Christine Sindt*

Fenestrations may also help alleviate the pressure. When removing a lens that is adhering to the ocular surface, place pressure on the eyeball to release the seal and let fluid get behind the lens.

Lens adherence can also occur because of conjunctival swelling: the lens sinks into the conjunctival cushion. Conjunctival swelling may sometimes result from a lack of limbal clearance.

---

#### *Lens Adhesion*

- *Is more seen with lower corneal clearance and in dry eye conditions.*
  - *Change lens fit, thickness and/or consider fenestrated lenses, comfort drops and extra cleaning.*
- 

#### **Microbial Keratitis and Infiltrates**

Microbial keratitis is very rare in GP lens wear, as has been reported repeatedly. This seems to include scleral lens wear. Nevertheless, isolated case presentations have indicated that corneal infections can occur. Special attention should be paid toward hygiene and lens care (see the “disinfection” section in this chapter), especially since oftentimes the anterior ocular surface is compromised in scleral lens wearers, by indication.

Infiltrates have been recorded in scleral lens wear as well. Infiltrates do not necessarily represent corneal infection. They are part of the inflammation cascade, which can be triggered by many things. Location, size and staining with fluorescein of the infiltrate as well as bulbar redness, pain sensation and anterior chamber reactions are all very important to exclude a microbial cause of the inflammation. A lack of tear film exchange behind the scleral lens may be partly responsible for the development of corneal infiltrates.

---

#### *Microbial Keratitis and Infiltrates*

- *Prevalence in GP lens wear is low.*
  - *Special attention should be paid toward hygiene and lens care to prevent infection.*
-

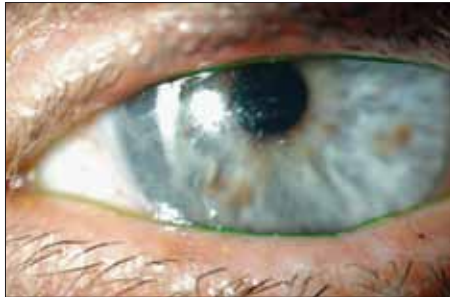## Mucus and Debris

A fairly common feature in scleral lens wear is mucus buildup in the fluid reservoir behind the lens, and this seems to be more prevalent in patients with atopic conditions, ocular surface disease and in post-surgical eyes.

Comfort and vision may be affected if this happens. Some patients have to remove, manually clean and replace the lens once or twice a day. Thick, viscous GP lens solutions may promote the formation of debris behind the lens, and their use may be better avoided in these cases. In a study by Visser et al (2007b) of patients using large, full size scleral lenses, 50% of patients could wear the scleral lenses all day without replacing them while the other half had to replace them once or twice a day. This number increased for patients with dry eye conditions.

The problem of tear debris behind the lens seems to be less of an issue with smaller type scleral lenses, such as corneo-scleral lenses, presumably because of the smaller tear reservoir.

It may be advised to discuss the possibility of an extra cleaning step during the day with new patients, as they are more likely to accept this extra step if it is explained to them in advance. With this intervention the wearing time and overall satisfaction can be very good. More frequent lens replacement may also reduce some of the problems.



LYNETTE JOHNS

Debris on and behind the scleral lens

In cases of severe wettability and anterior surface debris problems, check the Meibomian glands for dysfunction (Sindt 2010a) and treat if necessary. Also check for GPC (see earlier in this chapter), as it may result in excessive surface debris. Plasma treatment of the lenses and peroxide solutions have been promoted in these cases. Cleaning the front surface of the lens on-eye with a Q-tip has been mentioned as well. Also check for other topical treatment the patients may use, as this can interfere with the tear film dynamics.

---

### *Mucin and Debris*

- *Manually clean and reinsert the lens once or twice daily.*
  - *Decrease lens clearance.*
- 

## Neovascularization

A true complication of scleral lens fitting is corneal neovascularization. A serious problem with PMMA scleral lenses, this phenomenon is quite rare in modern scleral lens wear because of the high Dk materials available (see the “hypoxia” section in this chapter).

Apart from long-term hypoxia, neovascularization can result from prolonged periods of mechanical stress. Always check for mechanical stress on the limbal area — staining, conjunctival blanching, and hyperemia — with every eye exam. Prolonged periods of lens adhesion may also lead to corneal neovascularization. Neovascularization has been occasionally reported underneath loose conjunctival tissue (see the “conjunctival loose tissue” section earlier in this chapter) that can be sucked into the transition zone of the lens and should be monitored closely for.

---

### *Neovascularization*

- *Corneal neovascularization can be caused by hypoxia.*
  - *Mechanical stress, lens adhesion or conjunctival loose tissue may also lead to neovascularization.*
- 

### **Vision Problems**

Vision problems are commonly caused by air bubbles underneath the lens, and monocular diplopia may be present. Reinserting the lens properly may alleviate the problem. An excessive tear reservoir can also cause vision-related complaints. Sometimes vision can be improved by reducing the clearance, up to the point where there is a minimal touch on the cornea.

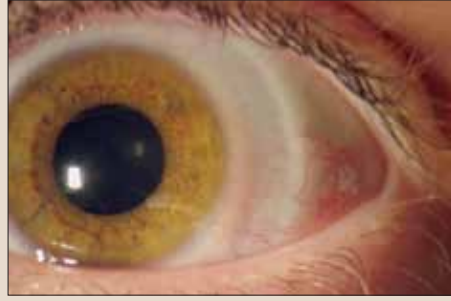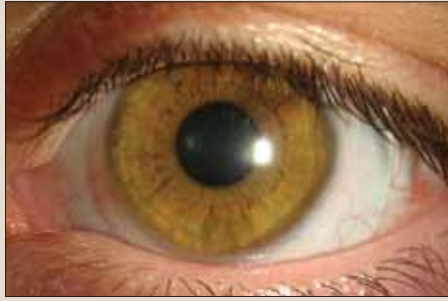Drying of the lens surface is another fairly common cause of vision problems, usually transient. Extra cleaning, rewetting drops and conditioning solutions should be considered, as well as polishing or replacing the lens. Blurred vision after lens removal may be caused by hypoxia and edema or by corneal warpage if the cornea is compromised in some way.

Lens flexure can cause unwanted astigmatism and lens warpage. To check for this, perform corneal topography or keratometry over the lens to determine the optical quality of the front surface. With persistent lens flexure, increase the lens thickness.

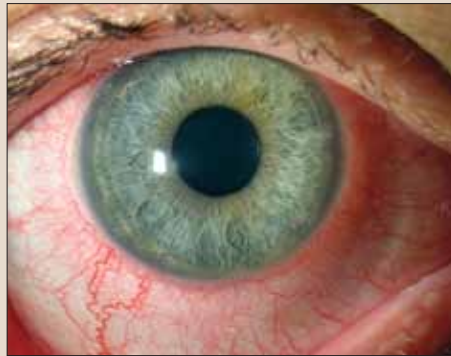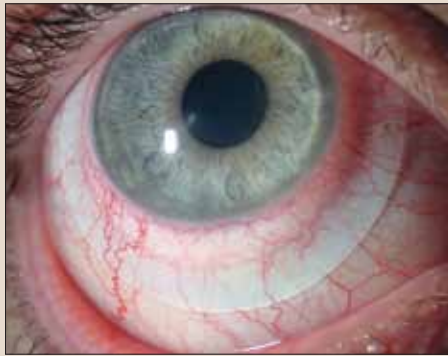---

### *Vision Problems*

- *Air bubbles underneath the lens (change lens fit or insertion technique) or wettability issues (cleaning) are common causes.*
  - *Lens flexure leading to warped lenses (increase center thickness of the lens).*
-



*The above lens (picture on the left) is semi-sealed to the eye, and the patient has comfortable 16-hour-per-day wear time: it shows no blanching during lens wear. After lens removal an impression ring is visible, with no injection (picture on the right).*



GREG DENAEYER

*Scleral lenses semi-seal to the eye. Oftentimes they will settle into the scleral conjunctiva and leave an impression ring that will be noticeable after removal. This is of no consequence as long as there is no blanching of the vessels. Significant blanching and limbal congestion indicates seal off, and the lens will become unwearable. The lens in the picture on the left has a complete seal, which causes significant injection and irritation, as in the picture on the right. This lens is not wearable for more than a few hours. Flattening the landing zone area will loosen the fit and get the patient back to full-time wear.*

*– Greg DeNaeyer*

## References

- Barr JT, Schechtman KB, Fink BA, Pierce GE, Pensyl CD, Zadnik K, Gordon MO, the CLEK Study Group (1999) Corneal scarring in the Collaborative Longitudinal Evaluation of Keratoconus (CLEK) study: baseline prevalence and repeatability of detection. *Cornea*; 18, 34–46
- Bartels MC (2010) personal communication; Deventer Ziekenhuis
- Bennett ES, Barr JT, Szczotka-Flynn LB (2009) Keratoconus. In: *Clinical Manual of Contact Lenses*. Bennett and Henry, Wolters Kluwer. Chapter 18, 468–507
- Bleshoy H, Pullum KW (1988) Corneal response to gas-permeable impression scleral lenses. *Journal of the British Contact Lens Association*; 2, 31–34
- Bokern S, Hoppe M, Bandlitz S (2007) Genauigkeit und wiederholbarkeit bei der klassifizierung des corneo-skleral profils. *Die Kontaktlinse*; 7–8, 26–8
- Borderie VM, Touzeau O, Allouch C, Boutboul S, Laroche L (2009) Predicted long-term outcome of corneal transplantation. *Ophthalmology*; 116, 2354–60
- De Brabander J (2002) With an eye on contact lenses — technological advancements in medical and optical applications. PhD thesis; University of Maastricht, the Netherlands
- DeNaeyer G, Breece R (2009) Fitting Techniques for a Scleral Lens Design. *Contact Lens Spectrum*; 1, 34–37
- DeNaeyer G (2010) Modern scleral contact lens fitting. *Contact Lens Spectrum*; 6, 20–5
- DePaolis M, Shovlin J, DeKinder JO, Sindt C (2009) Postsurgical contact Lens fitting. In: *Clinical Manual of Contact Lenses*. Bennett and Henry, Wolters Kluwer. Chapter 19, 508–41
- Doughty MJ, Zaman ML (2000) Human corneal thickness and its impact on intraocular pressure measures: a review and meta-analysis approach. *Survey of Ophthalmology*; 5, 367–408
- Douthwaite WA (2006) The contact lens. In: *Contact Lens Optics and Lens Design*. Elsevier. Chapter 2, 27–5
- Duke-Elder S (1961) System of Ophthalmology. *The anatomy of the visual system*, Henry Kimpton.
- Eggink FAGJ, Nuijts RMMA (2007) Revival of the scleral contact lens. *Cataract & Refractive Surgery Today Europe*; 9, 56–7
- Ezekiel D (1983) Gas permeable haptic lenses. *Journal of the British Contact Lens Association*; 6, 158–61
- Gemoules G (2008) A novel method of fitting scleral lenses using high resolution optical coherence tomography. *Eye & Contact Lens*; 3, 80–83
- Graf T (2010) Limbal and anterior scleral shape. Thesis; Faculty of Optik und Mechatronik HTW Aalen, Germany
- Gungor I, Schor K, Rosenthal P, Jacobs DS (2008) The Boston scleral lens in the treatment of pediatric patients. *Journal of AAPOS*; 3, 263–7
- Hussoin T, Carrasquillo KG, Johns L, Rosenthal P, Jacobs DS (2009) The effect of scleral lens eccentricity on vision in patients for corneal ectasia. ARVO poster; 6349
- IACLE - International Association of Contact Lens Educators (2006) contact lens course; module 1 (anterior segment of the eye) and module 9 (special topics)
- Jacobs DS (2008) Update on scleral lenses. *Current Opinion in Ophthalmology*; 19, 298–301
- Jedlicka J (2008) Beyond the limbus: corneoscleral lenses in today's contact lens practice. *Review of Cornea & Contact Lenses*; 4, 14–21



- Jedlicka J, Awad O (2010a) Differences in deep lamellar keratoplasties. *Review of Cornea & Contact Lenses* – online; posted 6/17/10
- Jedlicka J, Johns LK, Byrnes SP (2010b) Scleral contact lens fitting guide. *Contact Lens Spectrum*; 10, 30–36
- Ko L, Maurice D, Ruben M (1970) Fluid exchange under scleral contact lenses in relation to wearing time. *British Journal of Ophthalmology*; 7, 486–89
- Kok JHC, Visser R (1992) Treatment of ocular surface disorders and dry eyes with high gas-permeable scleral lenses. *Cornea*; 6, 518–522
- Lim P, Jacobs DS, Rosenthal P (2009) Treatment of persistent corneal epithelial defects with the Boston ocular surface prosthesis and an antibiotic adjunct. ARVO poster; 6530
- Legerton JA (2010) It's Time to Rethink Mini-Scleral Lenses. *Review of Cornea & Contact Lenses* – online; posted: 4/16/10
- Meier D (1992) Das cornea-skleral-profil – ein kriterium individueller kontaktlinsenanpassung. *Die Kontaktlinse*; 10, 4–11
- Millis EAW (2005) Scleral and prosthetic lenses. In: *Medical contact lens practice*. Elsevier. Chapter 12, 121–128
- National Keratoconus Foundation (2010); [www.nkcf.org](http://www.nkcf.org)
- Otten H (2010) True Colors – a case report. *I-site newsletter*; Edition 6, posted 6/14/10
- Pickles V (2008) Super-size it! Making a difference with scleral lenses. *Boston Update*; Nov, 1–6
- Pullum K (1997) A study of 530 patients referred for rigid gas permeable scleral contact lens assessment. *Cornea*; 6, 612–622
- Pullum K (2005) Scleral lenses. In: *Clinical Contact Lens Practice*. Philadelphia, USA: Lippincott, Williams and Wilson. Chapter 15, 629–48
- Pullum KW (2007) Scleral contact lenses. In: *Contact Lenses*. Phillips and Speedwell, Elsevier. Chapter 15, 333-353
- Rosenthal P, Cotter, JM, Baum J (2000) Treatment of persistent corneal epithelial defect with extended wear of a fluid-ventilated gas-permeable scleral contact lens. *American Journal of Ophthalmology*; 1, 33–41
- Rosenthal P, Cotter J (2003) The Boston scleral lens in the management of severe ocular surface disease. *Ophthalmology Clinics of North America*; 16, 89–93
- Rosenthal P, Baran I, Jacobs DS (2009a). Corneal pain without stain: is it real? *The Ocular Surface*; 1, 28–40
- Rosenthal P (2009b). Evolution of an ocular surface prosthesis. *Contact Lens Spectrum*; 12, 32–38
- Rott-Muff D, Keller U, Hausler M, Spinell M (2001) Das cornea-skleral-profil und seine auswirkungen auf die form von weichlinsen. *Die Kontaktlinse*; 5, 26–34
- Segal O, Barkana Y, Hourovitz D, Behrman S, Kamun Y, Avni I, Zadok D.. Scleral lenses (2003) Scleral contact lenses may help where other modalities fail. *Cornea*; 4, 612–622
- Sindt CW (2008) Basic scleral lens fitting and design. *Contact Lens Spectrum*; 10, 32–36
- Sindt CW (2010a) Scleral lens complications slideshow; [www.sclerallens.org/resources](http://www.sclerallens.org/resources)
- Sindt CW (2010b) Buffered Saline. Forum at [www.sclerallens.org/buffered-saline](http://www.sclerallens.org/buffered-saline). Posted 04/19/10
- Smiddy WE, Hamburg TR, Kracher GP, Stark WJ (1988) Keratoconus – contact lens or keratoplasty? *Ophthalmology*; 95, 487–92
- Tan DTH, Pullum KW, Buckley RJ (1995a) Medical application of scleral lenses: 1. A retrospective analysis of 343 cases. *Cornea*; 2, 121–29

- Tan DTH, Pullum KW, Buckley RJ (1995b) Medical application of scleral lenses: 1. Gas permeable applications of scleral contact lenses. *Cornea*; 2, 130–137
- Taylor-West S (2009) Lens file: SoClear. *The Optician*; Nov 6, 32–3
- Van der Worp E, De Brabander J, Jongsma F. Corneal topography (2009) In: *Clinical Manual of Contact Lenses*. Bennett and Henry, Wolters Kluwer. Chapter 3, 48–78
- Van der Worp E (2010a) New technology in contact lens practice. *Contact Lens Spectrum*; 2, 22–29
- Van der Worp E, Graf T, Caroline P (2010b) Exploring beyond the corneal borders. *Contact Lens Spectrum*; 6, 26–32
- Visser ES (1997) Advanced contact lens fitting part five: the scleral contact lens: clinical indications. *The Optician*; Dec 5, 15–20
- Visser ES, Visser R, Van Lier HJ (2006) Advantages of toric scleral lenses. *Optometry & Vision Science*; 4, 233–6
- Visser ES, Visser R, Van Lier HJ, Otten HM (2007a) Modern Scleral Lenses Part I: Clinical Features. *Eye & Contact Lens*; 1, 13–6
- Visser ES, Visser R, Van Lier HJ, Otten HM (2007b) Modern Scleral Lenses Part II: Patient Satisfaction. *Eye & Contact Lens*; 1, 21–5
- Yoon G, Johns L, Tomashevskaya O, Jacobs DS, Rosenthal P (2010) Visual benefit of correcting higher order aberrations in keratoconus with customized scleral lenses. ARVO poster; 3432



The Scleral Lens Education Society (SLES) is a non-profit organization committed to teaching contact lens practitioners the science and art of fitting all designs of scleral contact lenses for the purpose of managing corneal irregularity and ocular surface disease. SLES supports public education that highlights the benefits and availability of scleral contact lenses.

The SLES is an international association for vision care professionals who develop and/or fit scleral contact lenses. Membership in SLES is free and open to optometrists and ophthalmologists, students, Fellows of the Contact Lens Society of America, educators and researchers, and other eyecare professionals interested in scleral lenses. SLES provides its members with the latest research, didactic and hands-on educational programs, case reports and a troubleshooting and problem-sharing venue.

The SLES supports all brands and diameters of scleral contact lenses.

In addition to membership, eyecare professionals who have proven themselves in the field of scleral lens fitting can apply for status as a Scleral Lens Specialist, entitling them to be listed as a scleral lens fitter in the database available to the public, and can apply for fellowship of the Scleral Lens Society (FSLs).

For more information, go to: [www.sclerallens.org](http://www.sclerallens.org)







Supported by an unrestricted  
educational grant from:

**BAUSCH+LOMB**

**Boston**<sup>™</sup>  
Materials and Solutions