



Surgical importance of using musculo-aponeurotic landmarks as a guide to identify the radial nerve in posterior approach for humeral fractures a cadaveric study in a south indian population

Gajapriya Palaniappan¹, Sivaraj Sathappan^{2*}, Anandhi Veeraraghavalu³

¹ Assistant professor in Anatomy, K.A.P.V Government Medical College, Tiruchirappalli, Tamilnadu, India

² Assistant professor in Orthopaedics, K.A.P.V Government Medical College, Tiruchirappalli, Tamilnadu, India

³ Professor and HOD of Anatomy, K.A.P.V Government Medical College, Tiruchirappalli, Tamilnadu, India

***Corresponding author:** Sivaraj Sathappan, **Address:** K.A.P.V Government Medical College, Tiruchirappalli, Tamilnadu, India
Email: siva.soundaram@gmail.com, **Tel:** +919894325929

Abstract

Background & Aims: Long course of the radial nerve and its proximity to the humerus makes Radial Nerve (RN) prone to injury in diaphyseal fractures. In an effort to maintain its integrity, soft tissue landmarks can be readily made use of to provide facile nerve identification, as osseous landmarks might get altered in fractures. The aim of this study was to provide an idea of safe zone for securing radial nerve in relation to soft tissue structures and thereby, preventing the concomitant iatrogenic injury.

Materials & Methods: 40 Upper limb specimens from 20 cadavers were dissected. The radial nerve was identified proximal to the apex of Tricipital aponeurosis (TA) in posterior arm, at the level of entry into the lateral inter muscular septum and along the lateral border of TA. The mean distance between the radial nerve and aponeurosis was measured at all the three sites to find the safe zone for securing the radial nerve during surgeries.

Results: The radial nerve was found proximally from the medial apex of tricipital aponeurosis at a distance of 43.49 ± 6.67 mm (range 30.34-55.72 mm) within the muscle belly of triceps. The minimal permissible distance for the triceps split was 3.03 cm from the medial apex for both right and left arms. The distance of above 15 mm (range from 15.56 to 47.47mm) from the lateral border of tricipital aponeurosis was considered as a safe zone and no branches of the radial nerve were found in this zone. Radial nerve was identified along its course in the range of 15.56 to 47.47 mm from the lateral border of TA and this should be taken into consideration by the operating surgeon.

Conclusion: The Tricipital aponeurosis is a useful soft tissue landmark to secure the radial nerve safely throughout its course in the arm. Knowledge of safe and dangerous zones of the radial nerve would help the orthopedic surgeons to avoid the risk of iatrogenic nerve injury, which is not an uncommon phenomenon.

Keywords: Musculo-Aponeurotic Landmarks, Radial Nerve, Anatomical Dissection, Humeral Fracture

Received 30 May 2022; accepted for publication 16 September 2022

Introduction

Radial nerve (RN) is the largest branch arising from the posterior cord of brachial plexus (C5, C6, C7, C8, T1). The nerve with its accompanying profunda brachii artery courses obliquely from medial to the lateral side on the spiral groove. At the junction of middle and distal third of the humeral shaft, it pierces the lateral intermuscular septum to enter the anterior compartment. It descends down in relation to the lateral border of tricipital aponeurosis between the brachioradialis and extensor carpi radialis longus laterally and the brachialis muscle medially. As RN approaches the lateral epicondyle, it divides into superficial and deep terminal branches (1, 2).

Radial nerve as opposed to median and ulnar nerves is commonly associated with injury in humeral shaft fractures. Humeral shaft fractures constituted 3.5 % of all skeletal fractures and 20 % of all humeral fractures (3). Risk of radial nerve injury following shaft fractures is more, due to its close proximity to the periosteum of the humerus. The overall prevalence of radial nerve palsy following humeral shaft fractures had been reported as 11.8% (532 palsies in 4517 fractures) with significant association in the middle and middle-distal diaphysis than the other parts of the humerus (4). Among these shaft fractures, the Holstein-Lewis humeral shaft fracture constitutes 7.5%, with an increased risk of 22% of acute radial nerve palsy compared with other types of humeral shaft fractures which constituted only 8% (5). Radial nerve palsy can primarily be due to entrapment of the nerve within the fracture fragments or secondary due to iatrogenic causes like surgeries (3). The latter depended on the approach (posterior) as well as the modality of treatment (open reduction and internal fixation), which was chosen for the fracture fixation. The radial nerve palsies were reported around 16.67 to 8.18 % in posterior plating (6). It seemed to be mandatory in elbow arthroplasty that necessitated safe mobilization of the soft tissue envelope around the dia-metaphyseal segment of the humerus (7). It is very crucial to identify and mobilize the nerve away from the operating field depending on the site of fractures.

Wider clinical implications of radial nerve with humeral fractures had induced so many authors to draw the anatomical relationship of the nerve in reference to various osseous landmarks; nevertheless, such relations will not hold true or get altered in traumatic fractures. In the standard posterior approach for fixing the humeral shaft fractures, radial nerve identification and protection are of utmost importance as it is always a challenge for the operating surgeons. A definite superficial soft tissue landmark gains importance for the facile nerve identification in clinical settings. Since the position of patient in the posterior approach is an unaltered parameter, tricipital aponeurosis as a soft tissue landmark will provide a definitive guide for the orthopedic surgeons to prevent the iatrogenic injury of the radial nerve. Few such studies have been conducted in this field worldwide.

With such a facile, our primary aim was to determine the position of radial nerve with reference to the constant and superficial soft tissue structure, the tricipital aponeurosis at its apex and along its lateral border in the arm. Secondary aim was to provide an idea of the safe zone for securing radial nerve in relation to soft tissue structure, thereby preventing iatrogenic injury of the same.

Materials & Methods

After obtaining Ethical committee clearance, forty upper limb extremities belonging to 20 adult cadavers (male 14, female 6) aged between 50-75 obtained from the Department of Anatomy, K.A.P.V. Government Medical College, Tiruchirappalli, India were evaluated. Routine embalming procedure with standardized method of fixation was done to prevent the shrinkage of the skin. Arms that were malformed, deformed and arms with the evidence of injury or prior surgery were excluded. Dissection was done in the specimens after scapula humeral thoracic disarticulation and mid-clavicular amputation of upper extremities. Proximal humerus and elbow were fixed at 90 degrees with clamps simulating the operative position for the posterior approach of the humerus. Dissection was done in layers to expose the shiny aponeurosis along with the

intersection of long and lateral head of triceps from its origin to the insertion. The tricipital aponeurosis had an obliquity proximally with two apices namely medial-proximal apex (MA) and lateral-distal apex (LA). The border between the two apices was noted. Lateral border of aponeurosis was identified throughout. Radial nerve was then carefully dissected from proximal to distal. A point was marked and dissected two finger breadth from the medial proximal apex (MA) to identify the radial nerve within the muscle bellies of triceps. Distally, the radial nerve was dissected from its point of entry into the anterior compartment piercing the lateral intermuscular septum, and then along the lateral border of tricipital aponeurosis till its termination. Care was taken not to manipulate the course of radial nerve so that the relation between the soft tissue landmark and the nerve was unaltered.

The medial apex was marked as point A and the lateral apex as point B. Another point two finger breadth proximal to the point A was marked as point T (Figure

1). Dissection was done at the point T within the bellies of triceps muscle to locate the radial nerve. The mean distance between the medial proximal apex (MA) of tricipital aponeurosis and the radial nerve in posterior arm was measured using vernier calliper and tabulated (Figure 2). Radial nerve was then dissected at its point of entry into the anterior compartment piercing the lateral intermuscular septum (Figure 3), and its distance from the point A was marked as AN. The distance between the radial nerve and the lateral border of tricipital aponeurosis was then measured proximally from point B at four equally spaced sites. The straight distance between point A and point B was calculated and considered as the mean distance. The distance between the radial nerve and the lateral border was measured from four equally spaced sites (B, C, D, E) and marked as BN, CN, DN, and EN, respectively (Figure 4) and further analyzed. All the measurements were done by the first author using vernier calliper to avoid the inter observer variation.



Fig 1: medial apex marked as A, lateral apex marked as B, two finger breadth from the medial apex point T is marked



Fig 2: Measurement of the distance between the medial apex and the radial nerve proximally using vernier calliper.

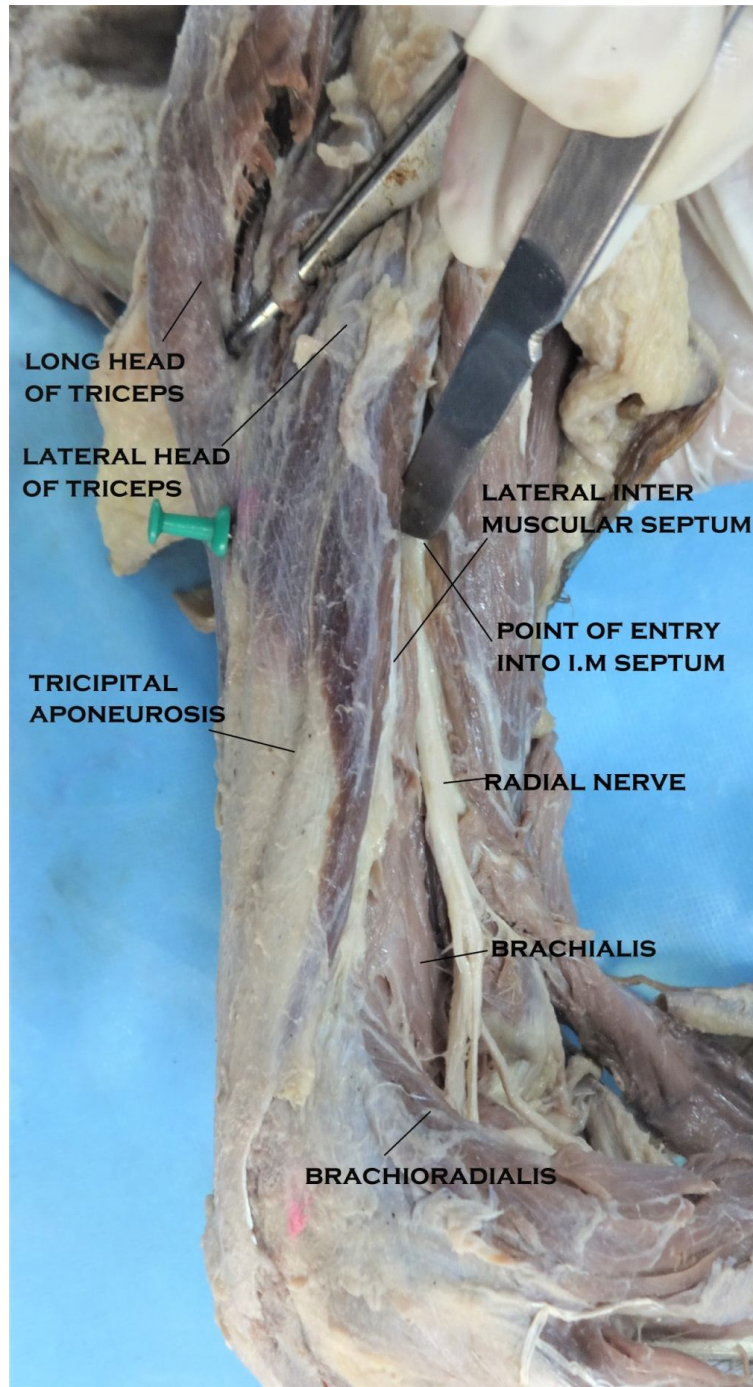


Fig 3: Point of entry of radial nerve into the lateral inter muscular septum.

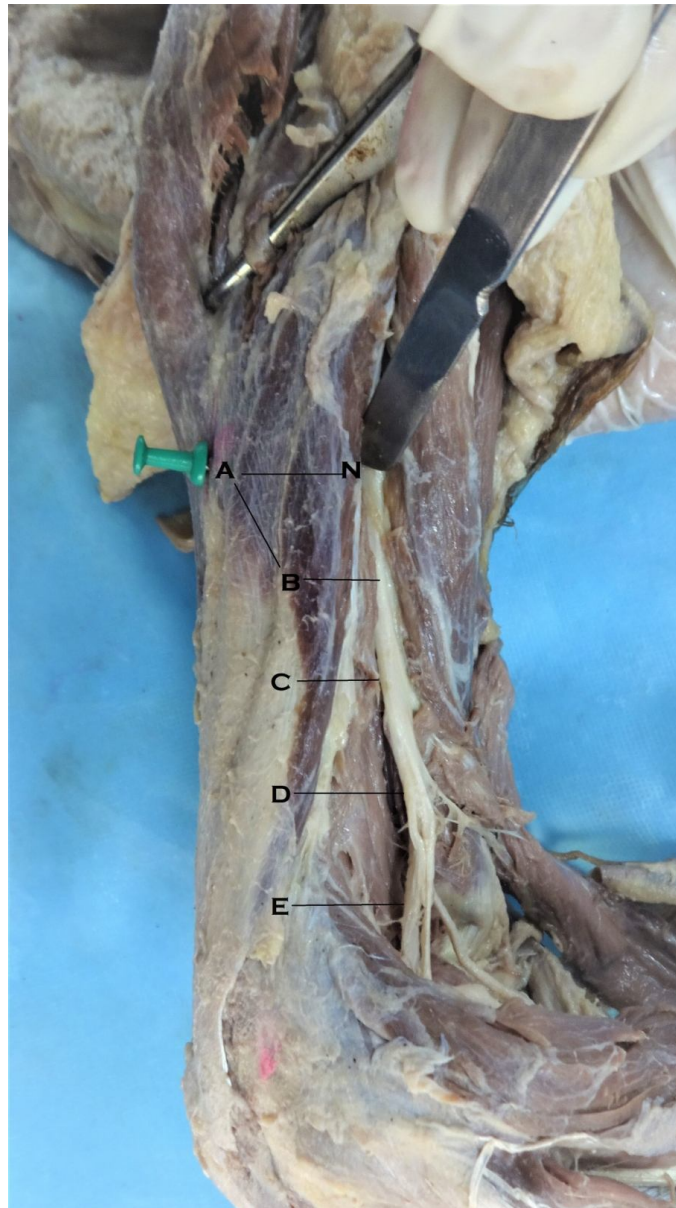


Fig4: Measurement of the distance between the tricipital aponeurosis and the radial nerve measured at four equally spaced points (AN, BN, CN, DN, EN)

Data Management and Analysis:

The data entered in excel sheet was analyzed using software SPSS. Continuous variables were summarized as mean and standard deviation and the significance between their mean variables was analyzed using unpaired T test.

Results

The radial nerve was located proximally from the medial apex of tricipital aponeurosis at a distance of 43.49 ± 6.67 mm (range from 30.34 to 55.72 mm) within the muscle belly of triceps. It is easy to locate and take the radial nerve away from the field of surgery along the

posterior aspect at an average distance of 4.3 cm from the medial apex. Table 1. shows the mean distance for the right and left side groups with its standard deviation. Statistical analysis using unpaired T test revealed no significant difference for the mean distance between the two sides ($p=0.762$). The minimal permissible distance

for the triceps split from the medial apex for both right and left arms was 3.03 cm and 3.14 cm, respectively. Table 2. shows the distance of radial nerve (N) from the lateral border of tricipital aponeurosis proximal (at medial apex point A) to distal at four sites (B, C, D, and E).

Table 1: Mean distance for the right and left side groups with its standard deviation.

Matched pairs	Right side (mm)	Left side (mm)	P value*
1	55.13	54.30	
2	56.34	55.72	
3	46.37	48.53	
4	45.16	44.43	
5	50.05	45.13	
6	52.38	50.81	
7	45.72	42.88	
8	35.63	38.68	
9	45.13	42.86	
10	38.07	40.70	
11	37.33	40.54	
12	33.63	31.42	
13	45.72	43.69	
14	40.38	36.15	
15	30.34	32.58	
16	43.63	45.69	
17	45.73	40.15	
18	39.38	38.15	
19	53.17	51.23	
20	37.19	39.44	
Mean (SD)	43.82 (7.29)	43.15 (6.60)	0.762
Total Mean (SD)	43.49 (6.67)		

*Unpaired t test p value

Table 2. Distance of radial nerve (N) from the lateral border of tricipital aponeurosis proximal (at medial apex point A) to distal at four sites (B, C, D, and E).

PARAMETERS	MEAN±SD	RANGE
Measurement from medial apex(AN)	26.49±7.5	15.56 - 43.16
Aponeurosis to nerve 1/4 (BN)	30.30±8.04	17.46 – 47.47
Aponeurosis to nerve 2/4 (CN)	29.48±7.03	20.12 – 47.33
Aponeurosis to nerve 3/4 (DN)	32.69±4.99	19.84 – 40.14
Aponeurosis to nerve 4/4 (EN)	37.33±4.52	25.57 – 42.56

The minimum distance of the radial nerve from the aponeurosis was found 15.56 mm at the site A at its point of entry into the lateral intermuscular septum. The maximum distance was found 25.57 mm at the site E. The distance of < 15 mm from the lateral border of tricipital aponeurosis was considered as a safe zone as

even the branches of radial nerve were not found in this zone. Radial nerve was identified along its course in the range of 15.56 to 47.47 mm from the lateral border of tricipital aponeurosis, which should be taken into consideration. Table 3. shows the difference between the safe zone for the right and the left sides.

Table 3. The difference between the safe zone for the right and the left sides.

Parameters	Right side (mm)	Range	Left side (mm)	Range	P value*
Measurement from apex of Tricipital aponeurosis	25.93+/-6.9	15.60 – 40.56	27.04+/-8.2	15.56 – 43.16	0.648
Aponeurosis to nerve 1/4	30.01+/-7.2	18.56 – 43.23	30.59+/-9.0	17.46 – 47.47	0.822
Aponeurosis to nerve 2/4	29.09+/-5.9	20.12 – 45.37	29.87+/-8.2	20.12 – 47.33	0.732
Aponeurosis to nerve 3/4	32.55+/-4.0	25.32 – 39.54	32.83+/-5.9	19.84 – 40.14	0.863
Aponeurosis to nerve 4/4	37.41+/-3.6	31.23 – 42.56	37.25+/-5.4	25.57 – 42.56	0.912

Unpaired T test

As per the study, the difference between the right and the left sides did not show any statistically significant difference, and in overall, <15 mm was found to be the safer zone for both sides (Figure 5).

The danger zone where the nerve could be identified, ranges from 15.60 – 45.37 mm on the right side and 15.56 – 47.47 mm on left side.

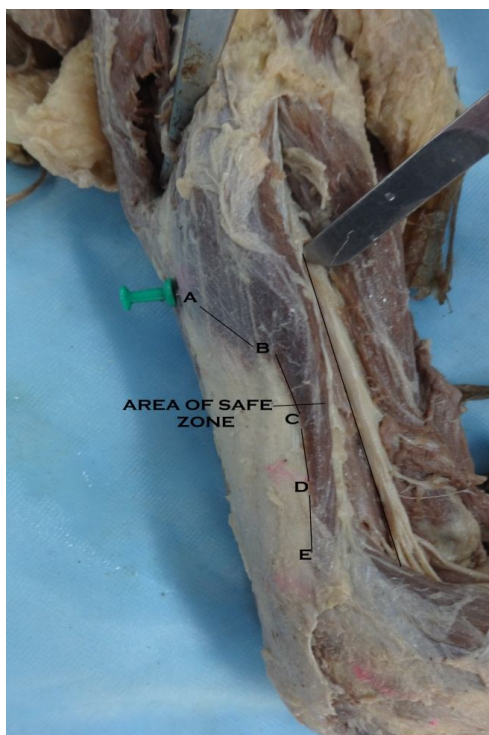


Fig 5. Area of safe zone between the lateral border of aponeurosis and the radial nerve

Discussion

The radial nerve and its proximity to the bone in its course, as explained *vide supra*, are commonly associated with radial nerve palsy in fracture humerus. The palsy depended on the force of injury (high energy trauma in younger individuals more than low energy trauma due to osteoporosis in older age groups), site of fracture (middle and middle distal fractures more than the rest sites), type of fractures (transverse and spiral type more than oblique and comminuted types), and the open type of fractures more associated with palsy than the closed type of fractures. The recovery rate between the primary (due to trauma) and secondary (iatrogenic) nerve palsy showed no statistical difference, while the recovery rate difference between the complete and incomplete as well as between open and close types were found statistically significant (4). This created an interest for various authors to find the relationship of radial nerve with reference to osseous landmarks of the humerus such as medial epicondyle, lateral epicondyle, spiral groove, intercondylar distance, and from the tip of acromion to establish a safe zone to identify the nerve.

Guse et al. and Gerwin et al. studied the relationship of the radial nerve in the spiral groove with reference to medial and lateral epicondyle (8, 9). In the former study, nerve was positioned 18.1 cm from the medial epicondyle and 12.6 cm from the lateral epicondyle (8). In the latter study, it was positioned 20.7 cm proximal to the medial epicondyle and 14.2 cm from the lateral epicondyle (9). Another study done by Carlan et al. described the relationship of the radial nerve with lateral epicondyle and with the deltoid tuberosity and concluded that the deltoid tuberosity is the most reliable landmark (10). Nevertheless, these relationships will not hold true of its kind in clinical settings like fractures, where these bony landmarks will be altered. Kamineni et al. positioned the radial nerve in the mid-lateral plane which is 1.4 to 2 times the trans epicondylar distance from the lateral epicondyle. This could be used even in fracture patterns limited to humerus with no shortening or angulation. As above, with the displaced fractures with intercondylar extension, this landmark would again be a topic of debate (11). Fleming et al. studied the

course of radial nerve from the acromion to lateral epicondyle and found that the nerve could be located in the lateral intermuscular septum 5 mm from the upper two third and middle one third junction of the humerus. It should be noted that their study was a qualitative study rather than a quantitative one (12).

Considering these drawbacks, studies were conducted to establish the relationship between the radial nerve and superficial soft tissue structure tricipital aponeurosis.

Chaudry et al. was the first to study the relation of the lateral border of tricipital aponeurosis with the radial nerve. They considered the plane less than 22 to 27 mm from the lateral border as the safe zone (13). Arora et al. examined the radial nerve in relation to the apex of the tricipital aponeurosis in cadaver and operative setting. They noted radial nerve at a distance of 25 mm from the apex (14). Similar studies have been conducted in Indian population also. Athwal et al. witnessed that after one-year follow-up of the operated patients in their study, extensive union occurred radiographically with the demonstration of 53% complication rate and 16% specifically related to radial nerve palsy (15). This shows that extensive manipulation, if done for the radial nerve exploration and mobilization, could pose higher risk of injury. In the present study, we found all the possible soft tissue landmarks to identify the nerve with minimal exploration during the surgery in posterior approach. Even though tricipital aponeurosis is a reliable landmark, it has its own variations in its morphological features. So combining the lateral border of tricipital aponeurosis with the intersection of muscular septum of long and lateral heads of triceps (point of confluence) and with the apex of the aponeurosis could provide a vast idea and sufficient way for the operating surgeons along their plane of surgery in posterior approach for the facile nerve identification, and thereby, potential iatrogenic nerve injury can be avoided.

Siegerman et al. studied the relation of radial nerve about 39 ± 2.1 mm from the point of confluence of the long and lateral head of triceps with the apex of tricipital aponeurosis (16). This study goes in favor with our

study finding that nerve was positioned at an average distance of 43 ± 6.6 mm from the apex of tricipital aponeurosis. This difference in the margin might be due to ethnic variation in the cadaveric specimens (17). The difference in the positions for right and left sides showed no statistical difference.

Apurba Patra et al. studied the relation of radial nerve from the lateral border of the aponeurosis in north Indian population, and found the area less than 1 cm adjacent to the lateral border as the safe zone (18). Similarly, the study conducted by Prasad et al. in south Indian population found the nerve at a distance of 1.2 to 1.9 cm and never found closer than 0.4 cm (19).

In our present study conducted in 40 specimens, radial nerve relation with the lateral border of tricipital aponeurosis was measured from its point of piercing the lateral intermuscular septum till its termination at the level of lateral epicondyle. Our study goes in favor with the study conducted by Chaudry et al and Apurba Patra et al. (13, 18) showing the area less than 15 mm (ranges from 15.56 to 47.47 mm) from the lateral border of the aponeurosis as a safe zone. The minimum distance of the radial nerve from the aponeurosis was found at the site A (15.56 mm), the maximum distance being found at the site E (25.57 mm). Our study provides a good idea about all the possible landmarks one could plan during the surgery for effortless nerve identification.

Limitations: The study was conducted in the embalmed specimens, and in operative setting there will be more mobility within the arm as well as gliding between the structures. The position of radial nerve can have inter-individual variations based on the arm length, height of the individual, and the built of the body, which may influence the value of measured parameters. The smaller number of study sample could not allow us to demonstrate the gender difference between specimens.

Conclusion

Rapid and precise identification with safe mobilization of the radial nerve offers a way for the successful surgery in humerus. The methods used in the present study is an adjunct and complement to previously cited methods for localizing the radial nerve

in posterior approach and can be used as a primary means for localization or in lieu of other methods when there are injury patterns that compromise the reliability of bony reference points. The apex and the lateral border of tricipital aponeurosis are the most stable and reliable landmarks to visualize the radial nerve in the posterior approach. The truly novel technique with the knowledge of safe and danger zones affords protection to the nerve while performing plate fixation in middle and distal third humeral shaft fractures. We believe that our study will definitely act as a useful guide and help to reduce the chances of iatrogenic nerve injury.

Financial Support: NIL

Acknowledgments

We would like to thank all the dissection hall attenders who helped us in procuring specimens and all the postgraduates of the Department of Anatomy for helping us in creating the illustrations. We would like to pay due respect to all the kind-hearted departed souls who donated their body for education and teaching purposes.

Conflict of interest

The authors have no conflict of interest in this study.

Ethics Statement

This study was conducted in accordance with the ethical standards of the Institutional Ethics Committee of Government Medical College, Tiruchirapalli, India. The research protocol was approved by the committee under the reference number KAPV/LEC/2022/03/005.

References

1. Standring S, editor. Gray's anatomy e-book: the anatomical basis of clinical practice. Elsevier Health Sciences; 2021. P. 581-8
2. Dutta AK. Essentials of Human Anatomy. 5th ed. 2010. P. 106-7
3. Theeuwes HP, van der Ende B, Potters JW, Kerver AJ, Bessems JH, Kleinrensink GJ. The course of the radial nerve in the distal humerus: A novel, anatomy based, radiographic assessment. PLoS One 2017;12(10):e0186890.

4. Shao YC, Harwood P, Grotz MR, Limb D, Giannoudis PV. 2005. Radial nerve palsy associated with fractures of the shaft of the humerus: A systematic review. *J Bone Joint Surg Br* 87:1647–52.
5. Ekholm R, Ponzer S, Törnkvist H, Adami J, Tidermark J. The Holstein-Lewis humeral shaft fracture: aspects of radial nerve injury, primary treatment, and outcome. *J Orthop Trauma* 2008;22(10):693-7.
6. Ahad A, Haque A, Armstrong A, Modi A, Pandey R, Singh HP. The management of displaced humeral shaft fractures—A survey of UK shoulder and elbow surgeons. *Shoulder Elbow* 2021;1758573220986940.
7. McCann PA, Smith GC, Clark D, Amirfeyz R. The tricipital aponeurosis—a reliable soft tissue landmark for humeral plating. *Hand Surg* 2015;20(1):53-8.
8. Guse TR, Ostrum RF. The surgical anatomy of the radial nerve around the humerus. *Clin Orthop Relat Res* 1995;320:149–53.
9. Gerwin M, Hotchkiss RN, Weiland AJ. Alternative operative exposures of the posterior aspect of the humeral diaphysis. With reference to the radial nerve. *J Bone Joint Surg Am* 1996;78(11):1690–5.
10. Carlan D, Pratt J, Patterson JM et al. The radial nerve in the brachium: An anatomic study in human cadavers, *J Hand Surg* 2007;32:1177–82.
11. Kamineni S, Ankem H, Patten DK. Anatomic relationship of the radial nerve to the elbow joint: Clinical implications of safe pin placement. *Clin Anat* 2009;22:684–8.
12. Fleming P, Lenehan B, Sankar R, Folan-Curran J, Curtin W. One-third, two-thirds: Relationship of the radial nerve to the lateral intermuscular septum in the arm. *Clinical Anatomy: The Official Journal of the American Association of Clinical Anatomists and the British Association of Clin Anat* 2004;17(1):26-9.
13. Chaudhry T, Noor S, Maher B, Bridger J. The surgical anatomy of the radial nerve and the triceps aponeurosis. *Clin Anat* 2010;23(2):222-6.
14. Arora S, Goel N, Cheema GS et al. A method to localize the radial nerve using the ‘apex of triceps aponeurosis’ as a landmark. *Clin Orthop Relat Res* 2011;469(9):2638–44.
15. Athwal GS, Hoxie SC, Rispoli DM et al. Precontoured parallel plate fixation of AO/OTA type C distal humerus fractures. *J Orthop Trauma* 2009 23:575–80.
16. Seigerman DA, Choung EW, Yoon RS, Lu M, Frank MA, Gaines LRJ, et al. Identification of the radial nerve during the posterior approach to the humerus: a cadaveric study. *J Orthop Trauma* 2012;26(4):226-8
17. Chou PH, Shyu JF, Ma HL et al. Courses of the radial nerve differ between Chinese and Caucasians: Clinical applications. 2008 Jan;466(1):135-8
18. Patra A, Chaudhary P, Arora K, Ravi KS. Surgical anatomy of the radial nerve in the anterior compartment of the arm: relationship with the triceps aponeurosis. *Surg Radiol Anat* 2021 May;43(5):689-94.
19. Prasad M, Isaac B, Premkumar PS. Anatomic Landmarks to Identify the Radial Nerve during the Posterior Approach of the Humerus: A Cadaveric Study. *J Clin Diagn Res* 2018 Nov 1;12(11):1-4.

This is an open-access article distributed under the terms of the [Creative Commons Attribution-NonCommercial 4.0 International License](https://creativecommons.org/licenses/by-nc/4.0/) which permits copy and redistribute the material just in noncommercial usages, provided the original work is properly cited.