

Textbook of LAPAROSCOPIC UROLOGY

Edited by
Inderbir S. Gill, MD, MCh

Textbook of
**LAPAROSCOPIC
UROLOGY**

Textbook of LAPAROSCOPIC UROLOGY

Edited by
Inderbir S. Gill, MD, MCh

*Vice Chairman and Professor of Surgery
Head, Section of Laparoscopic and Robotic Surgery
Director, Center for Advanced Study
Glickman Urological Institute
Cleveland Clinic Foundation
Cleveland, Ohio, U.S.A.*

informa
healthcare

New York London

Informa Healthcare USA, Inc.
270 Madison Avenue
New York, NY 10016

© 2006 by Informa Healthcare USA, Inc.
Informa Healthcare is an Informa business

No claim to original U.S. Government works
Printed in the United States of America on acid-free paper
10 9 8 7 6 5 4 3 2 1

International Standard Book Number-10: 0-8493-3994-4 (Hardcover)
International Standard Book Number-13: 978-0-8493-3994-3 (Hardcover)

This book contains information obtained from authentic and highly regarded sources. Reprinted material is quoted with permission, and sources are indicated. A wide variety of references are listed. Reasonable efforts have been made to publish reliable data and information, but the author and the publisher cannot assume responsibility for the validity of all materials or for the consequences of their use.

No part of this book may be reprinted, reproduced, transmitted, or utilized in any form by any electronic, mechanical, or other means, now known or hereafter invented, including photocopying, microfilming, and recording, or in any information storage or retrieval system, without written permission from the publishers.

For permission to photocopy or use material electronically from this work, please access www.copyright.com (<http://www.copyright.com/>) or contact the Copyright Clearance Center, Inc. (CCC) 222 Rosewood Drive, Danvers, MA 01923, 978-750-8400. CCC is a not-for-profit organization that provides licenses and registration for a variety of users. For organizations that have been granted a photocopy license by the CCC, a separate system of payment has been arranged.

Trademark Notice: Product or corporate names may be trademarks or registered trademarks, and are used only for identification and explanation without intent to infringe.

Library of Congress Cataloging-in-Publication Data

Textbook of laparoscopic urology / edited by Inderbir S. Gill.
p. ; cm.

Includes bibliographical references and index.

ISBN-13: 978-0-8493-3994-3 (hardcover : alk. paper)

ISBN-10: 0-8493-3994-4 (hardcover : alk. paper)

1. Genitourinary organs--Laparoscopic surgery. 2. Endourology. I. Gill, Inderbir S.

[DNLM: 1. Laparoscopy. 2. Urologic Surgical Procedures--methods. WJ 168 T3552 2006]

RD572.T49 2006
617.4'60597--dc22

2006049524

Visit the Informa Web site at
www.informa.com

and the Informa Healthcare Web site at
www.informahealthcare.com

*To the loving memories of my father, my mother, and my younger brother
and
to my family (Tania, Karan, and Neeti) and my "team" at work
for the love, inspiration, and strength.*

PREFACE

Laparoscopy is now a major domain in urologic surgery. The past decade has witnessed a literally logarithmic increase in the application and appropriateness of minimally invasive techniques for an entire spectrum of urologic surgical conditions. These advances have been fueled by many factors. Foremost is the natural order of change and progress. Change must not be adopted just because it is new or different. The reference standard, the tried and trusted open surgery, must not be cast aside until its novel, minimally invasive alternative has undergone a thorough, due-diligence evaluation. As such, laparoscopy is being incorporated into main-stream urology with appropriate caution and constructive critique. Second, the explosion of technological advances and novel imaging modalities have made possible minimally invasive techniques hitherto considered in the realm of science fiction. Finally, the surgical patient at the dawn of the 21st century, awash with information gleaned from the cyber-media, now has a better understanding of the available therapeutic options, rightfully leading to heightened expectations. This is only as it should be. The result is the emergence of a new surgical mentality, wherein the “big surgeons make big incisions” mindset is now aptly giving way to “the minimally invasive, maximally effective” mindset.

For minimally invasive oncologic surgeons, our work has only just begun. For laparoscopy to conclusively supplant open surgery where appropriate, stringent comparative analyses and joint research efforts need to occur in a spirit of healthy cooperation. These are ongoing. In this regard, combining the strengths of the two respected societies, the Society of Urologic Oncology and the Endourology Society, will go a long way towards advancing both fields. Our future is together.

This textbook aims to provide comprehensive, state-of-the-art information about the field of urologic laparoscopic surgery. Encyclopedic in scope, its 101 chapters have been organized into eleven distinct sections: Basic Considerations; Equipment; Laparoscopy: General Techniques; Adult Laparoscopy: Benign Disease; Laparoscopic Urologic Oncology; Pediatric Laparoscopy; Hand-Assisted Laparoscopy; Laparoscopy: Developing Techniques; Laparoscopic Complications: Etiology, Prevention, Management; Laparoscopy: Select Aspects; and The Future. Depending on the individual topic, emphasis has been placed on basic concepts, patient selection, laparoscopic technique and caveats, published outcomes, controversies, and future horizons. To enhance readability, important information has been graphically represented in a stand-alone manner in the left-hand column of the page. For certain chapters, invited commentaries have been solicited to stimulate debate, providing a broader perspective. Schematic figures, multiple tables, and thorough bibliographies combine to provide the reader a complete picture within one cover. This will benefit the novice as well as the experienced urologist.

Leading authorities have provided their opinions and thoughts herein. Collectively, these distinguished authors, each selected for recognized expertise and pre-eminence, comprise the *Who's Who* in the discipline.

It is our hope that the *Textbook of Laparoscopic Urology* will mature into the standard reference text in the field. Future editions will keep pace with the rapidly changing landscape of minimally invasive urology. Personally, it has been a true privilege to be able to edit the textbook. I am deeply grateful.

Inderbir S. Gill

ACKNOWLEDGMENTS

I owe heartfelt gratitude to Massimiliano Spaliviero, M.D., Jose Roberto Colombo, Jr., M.D., and the editorial staff at Informa Healthcare U.S.A., Inc. Dr. Spaliviero did yeoman work in all the “nuts and bolts” aspects of putting together this textbook: cataloging author information and manuscripts and logging innumerable hours of just plain hard work. Dr. Colombo provided invaluable assistance in galley proof editing and tracking down last-minute illustrations and author data. The Informa editorial staff made it all come together seamlessly. Special and heartfelt thanks to Vanessa Sanchez, Joseph Stubenrauch, and Sandra Beberman, the outstanding team at Informa, and Joanne Jay, at The Egerton Group Ltd., who provided the many innovative suggestions and technical support to bring the book to its final form.

CONTENTS

Preface v
Acknowledgments vii
Contributors xxvii

SECTION I: BASIC CONSIDERATIONS

CHAPTER 1: HISTORY OF LAPAROSCOPY: AN ODYSSEY OF INNOVATIONS ■ 3

Sergio G. Moreira, Jr., Raul C. Ordorica, and Sakti Das
■ References 11

CHAPTER 2: LAPAROSCOPIC ANATOMY: UPPER ABDOMEN ■ 13

Dinesh Singh
■ Introduction 13
■ Right Kidney 13
■ Left Kidney 14
■ Right Adrenal Gland 15
■ Left Adrenal Gland 16

CHAPTER 3: LAPAROSCOPIC ANATOMY OF THE MALE PELVIS ■ 19

Bertrand Guillonneau, Karim A. Touijer, and Jeffery W. Saranchuk
■ Introduction 19
■ Intra-Abdominal Anatomy of the Pelvis 19
■ The Retropubic Space 22
■ Prostatic Fascia and Prostatic Pedicles 24
■ Sphincteric Complex 26
■ Conclusion 27
■ References 27

CHAPTER 4: PHYSIOLOGIC ASPECTS OF LAPAROSCOPY ■ 29

J. Stuart Wolf, Jr.
■ Introduction 29
■ Physiologic Factors 29
■ Physiologic Responses 32
■ Physiologic Complications 35
■ References 41

CHAPTER 5: MODERN ABDOMINAL IMAGING: IMPLICATIONS FOR LAPAROSCOPIC SURGERY ■ 47

Erick M. Remer, Joseph C. Veniero, and Brian R. Herts
■ Introduction 47
■ Computed Tomography 48
■ Computed Tomography Protocol for Laparoscopic Surgical Planning 48
■ Magnetic Resonance Imaging 49
■ Magnetic Resonance Protocol for Laparoscopic Surgical Planning 51
■ Image Interpretation and Three-Dimensional Volume Rendering 52
■ Radiologic Guidance During Laparoscopic Surgery 55
■ Postoperative Imaging 59
■ Conclusion 62
■ References 63

SECTION II: EQUIPMENT

CHAPTER 6: LAPAROSCOPIC INSTRUMENTATION ■ 67

Mihir M. Desai

- Introduction 67
- Laparoscopic Instrumentation 67
- Operating Room Setup 73
- Conclusion 74
- References 75

CHAPTER 7: AUDIOVISUAL EQUIPMENT AND THE OPERATING ROOM OF THE FUTURE ■ 77

James O. L'Esperance and Glenn M. Preminger

- Introduction 77
- Digital Imaging 77
- Video Endoscopy (AKA “Chip on A Stick”) 79
- Digital Imaging, Video Documentation, and Editing 80
- Illumination 81
- Image Display Systems and High-Definition Video Systems 82
- Three-Dimensional Video Endoscopic/Laparoscopic Systems 83
- Virtual Reality Endoscopic/Laparoscopic Simulation 84
- Internet and Telemedicine 85
- The Operating Rooms of the Future—Today 86
- Conclusion 88
- References 88

CHAPTER 8: BIOADHESIVE TECHNOLOGY ■ 91

Andrew B. Joel and Marshall L. Stoller

- Introduction 91
- Hemostasis 92
- Topical Biologic Agents: Pharmacologic 93
- Topical Biologic Agents: Physical 96
- Urologic Laparoscopic Applications 97
- Potential Complications 100
- Topical Synthetic Agents 101
- Conclusion 101
- References 102

CHAPTER 9: SURGICAL ROBOTICS ■ 105

Akshay Bhandari, Lee Richstone, and Ashutosh Tewari

- Introduction 105
- History of Robotics 105
- Robotics in Surgery 106
- Robotics in Urology 107
- Telesurgery 111
- Virtual Reality 112
- Limitations of Robotic Surgery 113
- Future Robotic Surgery Systems 113
- References 114

SECTION III: LAPAROSCOPY: GENERAL TECHNIQUES

CHAPTER 10: BASICS OF RETROPERITONEAL LAPAROSCOPY ■ 119

Monish Aron, Benjamin Chung, and Inderbir S. Gill

- Introduction 119
- Indications 119
- Contraindications 119
- Preoperative Workup 120
- Surgical Technique 120
- Intraoperative Troubleshooting 126
- Time Management 126
- Complications 127
- Conclusion 127
- References 127

CHAPTER 11: LAPAROSCOPIC SUTURING TECHNIQUES: GENERAL CONSIDERATIONS ■ 129*Louis J. Giorgi, Jr. and Michael E. Moran*

- Introduction 129
- Laparoscopic Suturing Time Line 130
- Essentials of Laparoscopic Suturing 131
- Laparoscopic Extracorporeal Knotting 139
- Laparoscopic Intracorporeal Suturing and Knotting 142
- References 153

CHAPTER 12: LAPAROSCOPIC SUTURING: PROCEDURE-SPECIFIC ■ 159*Louis J. Giorgi, Jr. and Michael E. Moran*

- Laparoscopic Urologic Sutured Reconstruction 159
- Robotic Reconstruction 170
- Conclusion 175
- Practical Skills Acquisition Exercises 177
- References 177

SECTION IV: ADULT LAParoscopy: BENIGN DISEASE**CHAPTER 13: LAPAROSCOPIC ADRENALECTOMY: TECHNIQUE ■ 185***T. R. J. Gianduzzo and C. G. Eden*

- Introduction and Background 185
- Patient Selection: Indications and Contraindications 186
- Preoperative Preparation 188
- Technique 189
- Lateral Transperitoneal Technique 193
- General Technical Modifications 198
- Anterior Transperitoneal Technique 199
- Lateral Retroperitoneal Technique 199
- Posterior Retroperitoneal Technique 200
- Other Techniques and Modifications 200
- Conclusion 202
- References 203

CHAPTER 14: LAPAROSCOPIC PARTIAL ADRENALECTOMY ■ 207*Günter Janetschek*

- Introduction 207
- Relevant Anatomic Details 207
- Indications and Contraindications 208
- Therapeutic Concepts 208
- Preoperative Investigation 210
- Preoperative Optimization 210
- Pheochromocytoma: Potential Surgical Risks 210
- Anesthetic Management 211
- Surgical Technique 211
- Results 213
- Laparoscopic Partial Adrenalectomy for Recurrent Pheochromocytomas 214
- References 215

CHAPTER 15: LAPAROSCOPIC SURGICAL MANAGEMENT OF EXTRA-ADRENAL PHEOCHROMOCYTOMA ■ 217*Ashish Behari and McClellan M. Walther*

- Introduction 217
- Embryology 217
- Clinical Presentation and Diagnosis 217
- Surgical Technique 218
- Discussion 220
- Conclusion 221
- References 221

CHAPTER 16: LAPAROSCOPIC ADRENALECTOMY FOR BENIGN DISEASE: CURRENT STATUS ■ 223*David S. Wang and Howard N. Winfield*

- Introduction 223
- Diagnosis 223

- Aldosteronomas 225
- Cushing's Syndrome 225
- Pheochromocytoma 225
- Indications for Laparoscopic Adrenalectomy 226
- Results of Laparoscopic Adrenalectomy for Benign Disease 226
- References 228

CHAPTER 17: LAPAROSCOPIC SIMPLE NEPHRECTOMY: TECHNIQUE ■ 231

Simon V. Bariol and David A. Tolley

- Introduction 231
- Patient Selection 231
- Preoperative Preparation 231
- Technique 232
- Postoperative Care 236
- Complications 237
- References 238
- Bibliography 239

CHAPTER 18: LAPAROSCOPIC SIMPLE NEPHRECTOMY: CURRENT STATUS ■ 241

Moses Kim, Debora K. Moore, and Robert G. Moore

- Introduction 241
- Indications 241
- Special Considerations 242
- References 244

CHAPTER 19: LAPAROSCOPIC RENAL BIOPSY: TECHNIQUE AND RESULTS ■ 247

Christopher A. Warlick and David Y. Chan

- Introduction 247
- Surgical Technique 247
- Results 250
- Discussion 250
- References 251

CHAPTER 20: LAPAROSCOPIC NEPHROPEXY ■ 253

Lewis CH. Liew and Adrian D. Joyce

- Introduction 253
- Patient Selection and Diagnosis 254
- Surgical Technique 254
- Results 256
- References 258

CHAPTER 21: LAPAROSCOPIC RENAL CYST ABLATION: TECHNIQUE AND RESULTS ■ 259

Li-Ming Su

- Introduction 259
- Patient Selection 260
- Preoperative Preparation 263
- Surgical Technique 265
- Postoperative Care 273
- Measures to Avoid Complications 274
- Results 275
- References 278

CHAPTER 22: LAPAROSCOPIC SURGERY FOR CALCULOUS DISEASE: TECHNIQUE AND RESULTS ■ 279

Ashok K. Hemal

- Introduction/Background 279
- Patient Selection: Indications and Contraindications 280
- Preoperative Preparation and Patient Position 281
- Technique 281
- Pyelolithotomy 281
- Pyelolithotomy with Concomitant Pyeloplasty 283
- Robot-Assisted Pyelolithotomy and Pyeloplasty 283
- Anatomic Nephrolithotomy 283

- Removal of Urachovesical Calculus 284
- Ureterolithotomy 284
- Retroperitoneal vs. Transperitoneal Nephrectomy for Nonfunctioning Kidneys Due to Calculous Disease 286
- Retroperitoneoscopic Nephrectomy for Hydronephrotic Kidney Due to Ureteropelvic Junction Obstruction with Stones 286
- Laparoscopic Nephrectomy for Xanthogranulomatous Kidneys 286
- Laparoscopic Nephrectomy for Patients with History of Previous Stone Surgery or Percutaneous Nephrostomy 286
- Retroperitoneoscopic Nephroureterectomy for Nonfunctioning Kidneys Due to Calculous Disease 287
- Partial Nephrectomy 287
- Bladder Diverticulectomy with Stone Removal 287
- Results 287
- Complications 289
- References 291
- Commentary *D. Assimos* 292

CHAPTER 23: LAPAROSCOPIC PYELOPLASTY: TECHNIQUE ■ 295

George K. Chow

- Introduction 295
- Patient Selection and Diagnosis 296
- Preoperative Preparation 296
- Surgical Technique 296
- Postpyeloplasty Procedure 299
- Postoperative Management 300
- Postoperative Complications 300
- References 301

CHAPTER 24: ROBOTIC-ASSISTED ADULT AND PEDIATRIC PYELOPLASTY ■ 303

Joseph J. Del Pizzo, Michael A. Palese, Ravi Munver, and Dix P. Poppas

- Introduction 303
- Patient Selection: Indications and Contraindications 304
- Preoperative Preparation 305
- Robotic-Assisted Technique 306
- Specific Measures to Avoid Complications 311
- References 311

CHAPTER 25: LAPAROSCOPIC PYELOPLASTY: CURRENT STATUS ■ 313

Ioannis M. Varkarakis and Thomas W. Jarrett

- Introduction 313
- Current Management of Ureteropelvic Junction Obstruction and Indications for Laparoscopic Pyeloplasty 313
- Results: Transperitoneal Laparoscopic Pyeloplasty 314
- Results: Retroperitoneal Laparoscopic Pyeloplasty 315
- Laparoscopic Pyeloplasty in Children 316
- Robot-Assisted Laparoscopic Pyeloplasty 316
- Laparoscopic Pyeloplasty for Secondary Ureteropelvic Junction Obstruction 317
- Laparoscopic Pyeloplasty with Concomitant Pyelolithotomy 317
- Laparoscopic Pyeloplasty in the Presence of Upper Urinary Tract Abnormalities 318
- Management of Failed Primary Laparoscopic Pyeloplasty 318
- References 319
- Commentary *Michael C. Ost and Arthur Smith* 320

CHAPTER 26: LAPAROSCOPY FOR THE CALYCEAL DIVERTICULUM: TECHNIQUE AND RESULTS ■ 325

Christopher S. Ng

- Background 325
- Indications for Urologic Intervention 326
- Imaging 326
- Urologic Treatment Modalities 326
- Patient and Treatment Selection 327
- Preoperative Preparation 328
- Technique: Laparoscopic Calyceal Diverticulectomy 329
- Postoperative Management 335
- Results 335
- References 336

CHAPTER 27: LAPAROSCOPIC LIVE DONOR NEPHRECTOMY: TECHNIQUE ■ 337

Joseph J. Del Pizzo

- Introduction 337
- Patient Selection 338
- Preoperative Preparation 339
- Operative Preparation 339
- Laparoscopic Donor Nephrectomy: Basic Instrumentation 341
- Operative Technique 341
- References 351

CHAPTER 28: LAPAROSCOPIC DONOR NEPHRECTOMY: CURRENT STATUS ■ 353

Michael W. Phelan and Stephen C. Jacobs

- Initial Experience and Motivation 353
- Early Controversies 354
- Unsolved Controversies 357
- Surgical Technical Issues 358
- Donor Evaluation 359
- Expansion of Live Renal Donation 359
- Current Status of Laparoscopic Approach 361
- References 362
- Commentary *John M. Barry* 366

CHAPTER 29: LAPAROSCOPIC URETERAL SURGERY: NONCALCULOUS APPLICATIONS ■ 369

Thomas H. S. Hsu and Keith L. Lee

- Introduction 369
- Retrocaval Ureter 369
- Idiopathic Retroperitoneal Fibrosis 370
- Transureteroureterostomy 371
- Cutaneous Ureterostomy 372
- Ureteroneocystostomy 372
- References 373

CHAPTER 30: LAPAROSCOPIC MARSUPIALIZATION OF LYMPHOCELE ■ 375

W. Patrick Springhart, Charles D. Scales, Jr., and David M. Albala

- Introduction 375
- Patient Selection: Indications and Contraindications 375
- Preoperative Preparation 376
- Laparoscopic Technique 376
- Avoiding Complications 378
- References 378

CHAPTER 31: LAPAROSCOPIC BLADDER AUGMENTATION: WITH AND WITHOUT URINARY DIVERSION ■ 381

Raymond R. Rackley and Joseph B. Abdelmalak

- Introduction 381
- Patient Selection: Indications and Contraindications 381
- Preoperative Preparation 382
- Surgical Technical Steps 382
- Results 390
- References 391

CHAPTER 32: LAPAROSCOPIC BLADDER NECK SUSPENSION: TECHNIQUE AND RESULTS ■ 393

Jim Ross and Mark Preston

- Introduction 393
- Selection, Evaluation, and Anatomy 393
- Set-Up, Instrumentation, and Surgical Procedure 395
- Entry into the Space of Retzius 397
- Outcomes, Comparative Studies, Complications, and Costs 398
- Paravaginal Repair 405
- References 406

CHAPTER 33: LAPAROSCOPIC MANAGEMENT OF VESICOVAGINAL FISTULA ■ 411

Ali Mahdavi, Farr Nezhat, Bulent Berker, Ceana Nezhat, and Camran Nezhat

- Introduction 411
- Etiology 411

- Diagnosis 412
- Surgical Technique 412
- Prevention 414
- Results 414
- References 414

CHAPTER 34: LAPAROSCOPIC SURGERY OF THE SEMINAL VESICLES ■ 417

Robert B. Nadler and Scott E. Eggener

- Introduction 417
- Anatomy, Embryology, and Function 417
- Indications 417
- Imaging 418
- Surgical Technique 419
- References 421

CHAPTER 35: LAPAROSCOPIC VARICOCELECTOMY ■ 423

James F. Donovan and Marlou B. Heiland

- Introduction 423
- Diagnosis 423
- Indications for Treatment 424
- Treatment Options 424
- Contraindications to Laparoscopic Varix Ligation 425
- Surgical Technique 425
- Results 427
- References 428

CHAPTER 36: LAPAROSCOPIC PLACEMENT OF PERITONEAL DIALYSIS CATHETER ■ 431

Wisoot Konchareonsombat, Arif Asif, and Raymond J. Leveillee

- Introduction 431
- Anatomy of the Abdominal Wall and Peritoneum 432
- Factors Affecting Peritoneal Dialysis Efficiency 433
- The Indication for Dialysis 433
- Peritoneal Access Devices 434
- Contraindications to Peritoneal Dialysis Catheter Placement 434
- Surgical Techniques 434
- Laparoscopic Implantation of Continuous Ambulatory Peritoneal Dialysis Catheter 438
- Videolaparoscopy-Assisted Implantation of Continuous Ambulatory Peritoneal Dialysis Catheter 439
- Minilaparoscopic Placement of Peritoneal Dialysis Catheter 439
- Burying the Peritoneal Dialysis Catheter 440
- Postoperative Care 441
- Complications of Laparoscopic Placement of Chronic Peritoneal Dialysis Catheter 441
- Peritoneal Dialysis Catheter Removal 443
- References 444

CHAPTER 37: LAPAROSCOPIC SURGERY FOR CHYLURIA ■ 447

N. P. Gupta and M. S. Ansari

- Introduction 447
- Etiopathogenesis 447
- Clinical Presentation and Evaluation 449
- Conservative Treatment 449
- Patient Selection for Laparoscopic Lymphatic Disconnection 450
- Technique of Retroperitoneoscopic Laparoscopic Lymphatic Disconnection 450
- Technical Tips to Aid Laparoscopic Lymphatic Disconnection 452
- Postoperative Care and Follow-Up 453
- Advantages of Laparoscopy 453
- Retroperitoneal vs. Transperitoneal Lympholysis 454
- References 454

CHAPTER 38: LAPAROSCOPIC INGUINAL HERNIA SURGERY ■ 455

Bipan Chand and Jeffrey Ponsky

- Introduction 455
- Indications and Contraindications 455
- Anatomy 456

- Surgical Techniques 457
- Postoperative Care 458
- Technical Pearls 458
- References 460

SECTION V: LAPAROSCOPIC UROLOGIC ONCOLOGY

CHAPTER 39: LAPAROSCOPIC ADRENALECTOMY FOR MALIGNANCY ■ 465*Alireza Moinzadeh*

- Introduction 465
- Adrenalectomy for Solitary Metastasis 465
- Adrenalectomy for Adrenocortical Carcinoma 466
- Controversy About the Role of Laparoscopy for Malignancy 467
- Laparoscopy for Malignant Adrenal Lesions 468
- General Guidelines for Surgery 469
- Laparoscopic Adrenalectomy for Malignancy: Caveats 469
- References 470

CHAPTER 40: LAPAROSCOPIC RADICAL NEPHRECTOMY: TRANSPERITONEAL APPROACH ■ 473*Michael Grasso III*

- Introduction 473
- Indications for Surgical Intervention Using a Transperitoneal Laparoscopic Approach 473
- Contraindications to Laparoscopic Radical Nephrectomy 474
- Preoperative Evaluation 474
- Surgical Technique 475
- Results 479
- References 480

CHAPTER 41: LAPAROSCOPIC RADICAL NEPHRECTOMY: RETROPERITONEAL TECHNIQUE ■ 483*Howard Evans and Michael G. Hobart*

- Introduction 483
- Indications and Contraindications 484
- Preoperative Preparation 484
- Procedure 484
- Specific Measures Taken to Avoid Complications 490
- References 491

CHAPTER 42: LAPAROSCOPIC RADICAL NEPHRECTOMY: CURRENT STATUS ■ 493*Isaac Yi Kim and Ralph V. Clayman*

- Introduction 493
- Surgical Approaches 493
- Intraoperative and Perioperative Results 494
- Oncologic Outcome 495
- Complications 496
- Futures 497
- References 497
- Commentary R. C. Flanigan 499

CHAPTER 43: SMALL RENAL TUMORS: OVERVIEW AND MANAGEMENT BY ACTIVE SURVEILLANCE ■ 501*Alessandro Volpe and Michael A. S. Jewett*

- Natural History of Small Renal Tumors 502
- Active Surveillance of Small Renal Tumors 503
- References 505
- Commentary Morton A. Bosniak 507

CHAPTER 44: LAPAROSCOPIC PARTIAL NEPHRECTOMY: TECHNIQUE ■ 511*Jihad H. Kaouk*

- Introduction 511
- Indications and Contraindications 511
- Perioperative Patient Preparation 511
- Surgical Techniques 512
- Alternative Techniques 516
- References 517

CHAPTER 45: LAPAROSCOPIC PARTIAL NEPHRECTOMY: CURRENT STATUS ■ 519*Massimiliano Spaliviero and Inderbir S. Gill*

- Introduction 519
- Nephron-Sparing Surgery: Current Concepts 519
- Nephron-Sparing Surgery: Current Indications 521
- Open Partial Nephrectomy vs. Laparoscopic Radical Nephrectomy 522
- Laparoscopic Partial Nephrectomy 522
- Results 523
- Multiple Tumors 524
- Concomitant Adrenalectomy 526
- Complications 526
- Hemostatic Aids and Impact of Floseal 527
- Impact of Warm Ischemia 530
- Laparoscopic Renal Hypothermia 530
- Oncologic Outcomes 531
- Impact of Pelvicalyceal Suture Repair 532
- Laparoscopic Heminephrectomy 532
- Central vs. Peripheral Tumor 533
- Hilar Clamping vs. Non-Clamping 533
- Effect of Tumor Size 533
- Laparoscopic Partial Nephrectomy for Cystic Masses 534
- Laparoscopic Partial Nephrectomy for Hilar Tumors 534
- Laparoscopic Partial Nephrectomy in the Solitary Kidney 535
- Transperitoneal vs. Retroperitoneal Laparoscopic Partial Nephrectomy 535
- Financial Analysis 536
- Hand-Assisted Laparoscopic Partial Nephrectomy 536
- Follow-Up 537
- Future Directions: Hydro-Jet Technology 537
- Lasers 538
- References 539

CHAPTER 46: RENAL CRYOABLATION: TECHNIQUE AND RESULTS ■ 543*Murali K. Ankem and Stephen Y. Nakada*

- Introduction 543
- Patient Selection: Indications and Contraindications 544
- Preoperative Preparation 544
- Technique 545
- Instrument List 547
- Results 549
- References 551

CHAPTER 47: RENAL RADIOFREQUENCY ABLATION: TECHNIQUE AND RESULTS ■ 553*Edward D. Matsumoto and Jeffrey A. Cadeddu*

- Introduction 553
- Mechanism of Action 553
- Patient Selection: Indication and Contraindications 554
- Preoperative Preparation 554
- Laparoscopic Radiofrequency Ablation Technique 554
- Percutaneous Radiofrequency Ablation Technique 556
- Radiofrequency Ablation Follow-Up 557
- Pros and Cons 557
- Results: Experimental Studies 558
- Results: Clinical Studies 559
- References 561
- Commentary Harrison K. Rhee and John A. Libertino 562

CHAPTER 48: LAPAROSCOPIC RADICAL NEPHROURETERECTOMY: TECHNIQUES FOR THE MANAGEMENT OF DISTAL URETER AND BLADDER CUFF ■ 565*Gary W. Chien, Marcelo A. Orvieto, and Arie L. Shalhav*

- Introduction 565
- Techniques for Management of Distal Ureter and Bladder Cuff 565
- Open Management of the Distal Ureter and Bladder Cuff Following Laparoscopic Radical Nephroureterectomy 569
- References 571
- Commentary John M. Fitzpatrick 572

CHAPTER 49: LAPAROSCOPIC RADICAL NEPHROURETERECTOMY: CURRENT STATUS ■ 573

Surena F. Matin

- Introduction 573
- Nephrectomy 573
- The Current Status of Laparoscopic Radical Nephroureterectomy, Distal Ureterectomy, and Bladder Cuff Excision 575
- Morbidity Associated with Laparoscopic Radical Nephroureterectomy 577
- Oncologic Efficacy 578
- Adjunctive Procedures During Laparoscopic Radical Nephroureterectomy: Lymphadenectomy and Adrenalectomy 578
- Local Recurrences: Port Site and Ureteral Stump 579
- References 582
- Commentary *J. deKernion* 584

CHAPTER 50: KIDNEY CANCER SPECIMEN EXTRACTION: INTRACORPOREAL MORCELLATION ■ 587

Maxwell V. Meng

- Introduction 587
- Background 587
- Description of Method 588
- Outcomes of Morcellation 591
- Pathologic Considerations 592
- References 596

CHAPTER 51: LAPAROSCOPIC RETROPERITONEAL LYMPH NODE DISSECTION TECHNIQUE ■ 599

Nasser Albqami and Günter Janetschek

- Introduction 599
- Therapeutic Concepts and Patient Selection 599
- Contraindications for Laparoscopic Retroperitoneal Lymph Node Dissection 601
- Preoperative Preparation 601
- Templates 602
- Patient Positioning 602
- Trocar Placement and Pneumoperitoneum 603
- Procedure 603
- Extraperitoneal Approach 606
- References 609

CHAPTER 52: LAPAROSCOPIC RETROPERITONEAL LYMPH NODE DISSECTION FOR CLINICAL STAGE I NONSEMINOMATOUS GERM CELL TESTICULAR CANCER: CURRENT STATUS ■ 611

Sam B. Bhayani and Louis R. Kavoussi

- Introduction 611
- Differences in Laparoscopic Retroperitoneal Lymph Node Dissections 611
- Efficacy of Treatment Options 612
- Complications of Laparoscopic Retroperitoneal Lymph Node Dissection 614
- Postchemotherapy Laparoscopic Retroperitoneal Lymph Node Dissection 614
- References 614
- Commentary *Jerome P. Richie* 615

CHAPTER 53: LAPAROSCOPIC PELVIC LYMPHADENECTOMY FOR PROSTATE AND BLADDER CANCER ■ 617

Antonio Finelli

- Introduction 617
- Prostate Cancer 617
- Bladder Cancer 619
- Port-Site Tumor Seeding and Local Recurrence 621
- References 621

CHAPTER 54: LAPAROSCOPIC RADICAL CYSTECTOMY (PROSTATE SPARING) ■ 625

Xavier Cathelineau, Carlos Arroyo, François Rozet, Eric Barret, and Guy Vallancien

- Introduction 625
- Patient Selection: Indications and Contraindications 625
- Preoperative Preparation 626
- Detailed Laparoscopic Technique 626
- Description of Technical Modifications 628
- Specific Measures Taken to Avoid Complications 630
- Postoperative Evaluation 631

- Results 631
- Discussion 632
- References 634

CHAPTER 55: LAPAROSCOPIC RADICAL CYSTECTOMY: TECHNIQUE ■ 637

Karim A. Touijer and Stephen J. Savage

- Introduction 637
- Patient Selection 637
- Preoperative Patient Preparation 638
- Surgical Technique 638
- Laparoscopic Radical Cystectomy in the Male Patient 638
- Laparoscopic Radical Cystectomy in the Female Patient 641
- Robot-Assisted Laparoscopic Radical Cystectomy 642
- Urinary Diversions 642
- Conclusion 642
- References 642

CHAPTER 56: LAPAROSCOPIC BOWEL SURGERY: GENERAL CONSIDERATIONS ■ 643

Anthony J. Senagore

- Introduction 643
- Patient Selection: Indications and Contraindications 643
- Perioperative Care 643
- Operative Techniques 644
- References 646

CHAPTER 57: LAPAROSCOPIC URINARY DIVERSION ■ 647

David Canes, Harrison K. Rhee, and Ingolf Tuerk

- Introduction 647
- Indications and Contraindications 648
- A: Noncontinent Urinary Diversions 650
- Ileal Conduit 650
- Lap-Assisted Ileal Conduit Urinary Diversion 651
- Pure Laparoscopic Ileal Conduit Urinary Diversion 653
- B: Continent Urinary Diversion 655
- Orthotopic Neobladder 655
- Lap-Assisted Orthotopic Neobladder 656
- Pure Laparoscopic Orthotopic Neobladder 658
- Laparoscopic Mainz II Pouch (Sigma-Rectum Pouch) 660
- Future Directions 663
- References 664
- Commentary *John P. Stein* 665
- Commentary *Urs E. Studer* 667

CHAPTER 58: LAPAROSCOPIC SURGERY FOR BLADDER CANCER: CURRENT STATUS ■ 669

Osamu Ukimura and Inderbir S. Gill

- Introduction 669
- Histologic and Experimental Background 670
- Clinical Series 670
- International Registry and Future Direction 674
- References 675

CHAPTER 59: TRANSPERITONEAL LAPAROSCOPIC RADICAL PROSTATECTOMY: TECHNICAL VARIATIONS, ONCOLOGIC AND FUNCTIONAL RESULTS, AND TRAINING ■ 677

Jens J. Rassweiler, Tibet Erdogru, Marto Sugiono, Marzel Hrutza and Dogu Teber

- The History of Laparoscopic Radical Prostatectomy 677
- Indications of Laparoscopic Radical Prostatectomy 678
- Specific Contraindications 679
- Laparoscopic Transperitoneal Ascending Radical Prostatectomy (The Heilbronn Technique) 679
- Laparoscopic Transperitoneal Descending Radical Prostatectomy (The Montsouris Technique) 685
- Technical Variations 688
- Results 691
- Training 698
- References 700
- Commentary *Guy Vallancien* 702

CHAPTER 60: LAPAROSCOPIC RADICAL PROSTATECTOMY: EXTRAPERITONEAL TECHNIQUE ■ 705*Clément-Claude Abbou, Andrés Hoznek, Laurent Salomon, Matthew T. Gettman, and Philippe Sebe*

- Introduction 705
 - Operative Technique 705
 - Discussion 711
 - Conclusion 712
 - References 713
 - Commentary *Renaud Bollens and Claude Schulman* 714
-

CHAPTER 61: ROBOTIC RADICAL PROSTATECTOMY: TECHNIQUE AND RESULTS ■ 717*Melissa C. Fischer, James O. Peabody, Mani Menon, and Ashok K. Hemal*

- Introduction and Background 717
 - Patient Selection: Indications and Contraindications 717
 - Preoperative Preparation 718
 - Detailed Robotic Prostatectomy Technique 718
 - Extraperitoneal Approach for Robotic Radical Prostatectomy 724
 - Specific Measures Taken to Avoid Complications 724
 - Results 724
 - References 726
 - Commentary *Guy Vallancien* 727
-

CHAPTER 62: LAPAROSCOPIC RADICAL PROSTATECTOMY: CURRENT STATUS ■ 729*Karim A. Touijer, Edouard Trabulsi, and Bertrand Guillonéau*

- Introduction 729
 - Technique 730
 - Perioperative Parameters 731
 - Cancer Control 734
 - Functional Results 736
 - New Innovations in Laparoscopic Prostate Surgery 737
 - Personal Experience of the Senior Author (B. G.): The Lessons Learned 737
 - References 739
 - Commentary *Robert P. Myers* 741
-

CHAPTER 63: PORT SITE METASTASIS IN UROLOGIC LAPAROSCOPY ■ 745*Steven M. Baughman and Jay T. Bishoff*

- Introduction 745
 - History: Gynecologic and General Surgery Literature 745
 - Urologic Experience 746
 - Basic Science and Predisposing Factors 749
 - Port Site Recurrence Prevention 751
 - Percutaneous Ablation 751
 - References 752
-

SECTION VI: PEDIATRIC LAPAROSCOPY

CHAPTER 64: LAPAROSCOPY IN THE CHILD: SPECIFIC ISSUES ■ 757*Craig A. Peters*

- Indications 757
- Oncology 757
- Patient Preparation 758
- Port Positioning and Setup 758
- Cannulae 759
- Hand Instruments 759
- Access 759
- Manipulation Principles 760
- Retroperitoneal Access 761
- Physiology and Anesthetic Considerations 762
- Complications 762
- Surgical Complications 763
- Postoperative Course 763
- References 764

CHAPTER 65: LAPAROSCOPIC MANAGEMENT OF THE UNDESCENDED NONPALPABLE TESTICLE ■ 767*Gerald H. Jordan and Linda Baker*

- Introduction 767
- Considerations for Orchidopexy 768
- Therapeutic Laparoscopy 771
- References 776

CHAPTER 66: LAPAROSCOPIC URETERAL REIMPLANTATION ■ 779*Jonathan H. Ross and Richard Sutherland*

- Introduction 779
- Vesicoureteral Reflux: Management 779
- Transvesical Cross-Trigonal Approach 780
- Laparoscopic Extravesical Approach 780
- References 781

SECTION VII: HAND-ASSISTED LAPAROSCOPY**CHAPTER 67: HAND-ASSISTED LAPAROSCOPIC NEPHRECTOMY ■ 785***Steven J. Shichman and Joseph R. Wagner*

- Introduction 785
- Patient Selection: Indications and Contraindications 786
- Preoperative Preparation 786
- Detailed Laparoscopic Technique 787
- Pros and Cons of Different Techniques 793
- Specific Measures Taken to Avoid Complications 795
- References 796

CHAPTER 68: HAND-ASSISTED LAPAROSCOPY: CURRENT STATUS ■ 799*J. Stuart Wolf, Jr. and Stephen Y. Nakada*

- Introduction 799
- History 799
- Experience with Hand-Assisted Laparoscopy 800
- Complications of Hand-Assisted Laparoscopy 803
- Comparison of Hand-Assisted Laparoscopy to Other Laparoscopic Techniques 804
- Selection of Patients for Hand-Assisted Laparoscopy 808
- References 809

CHAPTER 69: GASLESS LAPAROSCOPY ■ 813*Kazuo Suzuki*

- Introduction 813
- History 813
- Equipment and Technique 815
- Gasless vs. Pneumoperitoneum 817
- References 819

SECTION VIII: LAPAROSCOPY: DEVELOPING TECHNIQUES**CHAPTER 70: THORACOSCOPIC TRANSDIAPHRAGMATIC ADRENALECTOMY ■ 825***Massimiliano Spaliviero and Anoop M. Meraney*

- Introduction 825
- Current Indications and Contraindications of Laparoscopic Adrenalectomy 825
- Transthoracic Laparoscopy: Experimental and Clinical Data 826
- Thoracoscopic Transdiaphragmatic Adrenalectomy: Patient Selection 827
- Surgical Technique 828
- Results 831
- Technical Limitations 833
- References 833

CHAPTER 71: RENAL HYPOTHERMIA ■ 835*Anup P. Ramani*

- Introduction 835
- Physiology of Renal Hypothermia 835
- Techniques of Laparoscopic Renal Hypothermia 836

- Laparoscopic Ice Slush Renal Hypothermia 836
- Endoscopic Retrograde Cold Saline Infusion 837
- Transarterial Renal Hypothermia 838
- The Laparoscopic Cooling Sheath 839
- Ancillary Techniques for Ischemic Renoprotection 839
- References 840

CHAPTER 72: LAPAROSCOPIC RENOVASCULAR SURGERY ■ 841*Thomas H. S. Hsu*

- Introduction 841
- Laparoscopic Aortorenal Bypass 841
- Laparoscopic Renal Autotransplantation 842
- Laparoscopic Repair of Renal Artery Aneurysm 843
- References 843

CHAPTER 73: LAPAROSCOPIC SURGERY FOR THE HORSESHOE KIDNEY ■ 845*Hyung L. Kim and Peter Schulam*

- Introduction 845
- Pyeloplasty 845
- Heminephrectomy 847
- References 849

CHAPTER 74: LAPAROSCOPIC BOARI FLAP URETERONEOCYSTOSTOMY AND ILEAL URETER REPLACEMENT ■ 851*Amr F. Fergany*

- Laparoscopic Boari Flap Ureteroneocystostomy 851
- Laparoscopic Ileal Ureter Replacement 852
- References 854

CHAPTER 75: TRANSVESICAL LAPAROSCOPIC BLADDER DIVERTICULECTOMY ■ 855*Vito Pansadoro*

- Introduction 855
- History of Laparoscopic Diverticulectomy 855
- Indications and Contraindications 855
- Surgical Technique 856
- Current Data from the Literature 857
- Complications 857
- Advantages and Disadvantages 857
- References 857

CHAPTER 76: LAPAROSCOPIC SIMPLE PROSTATECTOMY ■ 859*Rene Sotelo Noguera and Alejandro Garcia-Segui*

- Introduction 859
- Patient Selection 860
- Preoperative Preparation 860
- Laparoscopic Technique 861
- Technical Modifications 862
- Pros and Cons of Various Techniques 864
- Specific Measures Taken to Prevent Complications 866
- References 866

CHAPTER 77: TECHNIQUES FOR URETHROVESICAL ANASTOMOSIS IN LAPAROSCOPIC RADICAL PROSTATECTOMY ■ 869*Roland F. P. van Velthoven*

- Introduction 869
- Patient Positioning 869
- Surgeon Positioning 870
- Preparation of the Urethral Stump 870
- Preparation of the Bladder Neck 871
- Urethrovesical Anastomosis in the Montsouris Technique 871
- Running Suture Technique for Vesicourethral Anastomosis 872
- Single Knot Method for the Laparoscopic Running Urethrovesical Anastomosis 874
- Discussion 876
- References 879

CHAPTER 78: MINILAPAROSCOPIC UROLOGIC SURGERY ■ 883*Anoop M. Meraney*

- Introduction 883
- Minilaparoscopic Instruments 883
- Minilaparoscopic Urologic Procedures 884
- Benefits and Limitations 887
- Current Status and Future Potential 887
- References 888

CHAPTER 79: ROBOTIC SURGERY: OTHER APPLICATIONS ■ 889*Amy E. Krambeck and Matthew T. Gettman*

- Introduction 889
- Upper Urinary Tract 889
- Lower Urinary Tract 893
- Conclusion 895
- References 896

SECTION IX: LAPAROSCOPIC COMPLICATIONS: ETIOLOGY, PREVENTION, MANAGEMENT**CHAPTER 80: VASCULAR COMPLICATIONS DURING UROLOGIC LAPAROSCOPY ■ 901***James R. Porter*

- Introduction 901
- Frequency of Laparoscopic Vascular Injury 901
- Access-Related Injury 904
- References 908

CHAPTER 81: LAPAROSCOPIC COMPLICATIONS: GASTROINTESTINAL ■ 911*Ramakrishna Venkatesh and Jaime Landman*

- Introduction 911
- Abdominal Access-Related Bowel Injuries 911
- Non-Access-Related Bowel Injuries 913
- Electrocautery Bowel Injury 915
- Mechanical Bowel Injury 917
- Gastric or Duodenal Injuries 917
- Hepatobiliary, Splenic, or Pancreatic Injury 917
- Previous Open Abdominal Surgery and Laparoscopic Surgery 918
- Hand-Assisted Laparoscopy 918
- Trocar Site Hernia 919
- Rectal Injury During Radical Prostatectomy 919
- Surgeon Experience 920
- References 921

CHAPTER 82: LAPAROSCOPIC COMPLICATIONS: NEUROMUSCULAR ■ 923*Dan B. French and Robert Marcovich*

- Introduction 923
- Anatomic Overview 923
- Risk Factors for Neuromuscular Injury 925
- Types of Injuries 927
- References 932

CHAPTER 83: COMPLICATIONS: THORACIC ■ 933*Sidney C. Abreu, João Batista G. Cerqueira, and Gilvan Neiva Fonseca*

- Introduction 933
- Incidence 933
- Etiology 933
- Diagnosis and Management 936
- Prevention 936
- References 937

CHAPTER 84: GYNECOLOGIC INJURIES INVOLVING THE URINARY SYSTEM ■ 939*John E. Jelovsek, Tommaso Falcone, and Paul K. Tulikangas*

- Introduction 939
- Gynecologic Disorders That Involve the Lower Urinary Tract 939

- Preoperative Gynecologic Evaluation 939
- Uterine Leiomyomata 940
- Hysterectomy 941
- Pelvic Adhesions 941
- Pelvic Inflammatory Disease 943
- Adnexal Masses 944
- Ovarian Remnant 945
- Cervical Cancer 945
- Endometriosis 946
- Fistula 947
- Urinary Tract Injury During Gynecologic Procedures 947
- Injury to the Urethra 947
- Injury to the Bladder 947
- Injuries to the Ureter 948
- Manipulators 948
- References 949

SECTION X: LAPAROSCOPY: SELECT ASPECTS

CHAPTER 85: IMMUNOLOGIC ASPECTS OF LAPAROSCOPY ■ 953

Prokar Dasgupta and Ben Challacombe

- Introduction 953
- Basic Principles of Immunology 954
- Laparoscopy and Systemic Immunity 955
- Laparoscopy and Intraperitoneal Immune Function 959
- Tumor Growth, Metastasis, and Immune Function 961
- Laparoscopic Bowel Injury 962
- Immunologic Aspects of Laparoscopic Urology 962
- Future Directions 965
- References 967

CHAPTER 86: LAPAROSCOPIC SURGERY IN THE HIGH RISK PATIENT ■ 971

Assaad El-Hakim and Benjamin R. Lee

- Previous Abdominal Surgery 971
- Coagulation Disorders 973
- Cardiopulmonary Disorders 976
- Ascites 977
- Obesity 978
- Advanced Age 980
- References 981

CHAPTER 87: LAPAROSCOPIC SURGERY DURING PREGNANCY ■ 983

Michael D. Rollins and Raymond R. Price

- Introduction 983
- Anatomic and Physiologic Considerations 984
- Special Considerations 986
- Advantages of Laparoscopic Surgery 988
- Safety of Laparoscopy 988
- Nongynecologic Laparoscopic Procedures 989
- Common Gynecologic Laparoscopic Procedures 992
- Recommendations 992
- References 993

CHAPTER 88: LAPAROSCOPY AND TRAUMA ■ 997

Abraham A. Nisim and Daniel R. Margulies

- Introduction and Background 997
- Penetrating Injuries 998
- Blunt Trauma 999
- References 999

CHAPTER 89: LAPAROSCOPIC ULTRASONOGRAPHY ■ 1001

Osamu Ukimura

- General Principles of Laparoscopic Ultrasound 1001
- Technique 1001

- Doppler Ultrasound 1002
- Urologic Utility of Laparoscopic Ultrasonography 1003
- Prospects and Limitations for Laparoscopic Ultrasonography and New Technology 1006
- References 1007

CHAPTER 90: FINANCIAL ASPECTS OF UROLOGIC LAPAROSCOPY ■ 1009

Yair Lotan and Jeffrey A. Cadeddu

- Introduction 1009
- The Importance of Perspective 1009
- Cost vs. Charge 1010
- Current Financial State of Laparoscopic Procedures 1012
- Laparoscopic Nephrectomy 1012
- Laparoscopic Prostatectomy 1013
- References 1015

CHAPTER 91: LAPAROSCOPIC SURGERY AND THE COMMUNITY UROLOGIST ■ 1017

Scott D. Miller

- Introduction 1017
- The Private Practice Model 1017
- Patient Outcome 1018
- Building a Laparoscopic Practice 1020
- References 1022

CHAPTER 92 LAPAROSCOPIC SURGERY: MEDICOLEGAL ASPECTS ■ 1025

Michael Perrotti, Peter J. Millock, and Michael E. Moran

- Introduction 1025
- Laparoscopic Complications 1029
- Informed Consent 1041
- References 1046

SECTION XI: THE FUTURE

CHAPTER 93: TISSUE ENGINEERING ■ 1053

J. Daniell Rackley and Anthony Atala

- Introduction 1053
- Basic Principles of Tissue Engineering 1053
- Biomaterials for Genitourinary Tissue Engineering 1054
- References 1058

CHAPTER 94: HYDRO-JET TECHNOLOGY ■ 1061

Bijan Shekarritz

- Introduction 1061
- Principles of Dissection 1062
- Experimental Data in Urology 1063
- Clinical Applications in Urology 1065
- Future Perspectives 1065
- References 1066

CHAPTER 95: TISSUE EXPANSION ■ 1067

Jose R. Colombo, Jr., Osamu Ukimura, and Inderbir S. Gill

- Pathophysiology 1068
- Visceral Tissue Expansion in Urinary Tract 1068
- Desai Study 1069
- Results 1071
- Clinical Study 1075
- Clinical Implications 1075
- References 1076

CHAPTER 96: EXTRACORPOREAL TISSUE TRIPSY IN UROLOGY ■ 1079

M. Marberger and Y. K. Fong

- Introduction 1079
- Radiosurgery 1079

- Mechanical Tissue Tripsy 1079
- Thermal Tissue Ablation 1082
- References 1088

CHAPTER 97: TELEMENTORING AND TELESURGERY ■ 1091

Mehran Anvari

- Introduction 1091
- Telementoring 1092
- Robot-Assisted Remote Telepresence Surgery 1093
- References 1096

CHAPTER 98: VIRTUAL REALITY AND SIMULATION IN UROLOGY ■ 1097

Robert M. Sweet and Jeffrey Berkley

- Introduction 1097
- History 1099
- Virtual Reality Role in Procedural Training 1100
- Building a Virtual Reality Simulator 1100
- Survey of Virtual Reality Urologic Simulators 1116
- Cognitive Simulation Engines 1117
- Complete Procedures 1117
- References 1125

CHAPTER 99: MATHEMATICAL MODELING FOR PREDICTING OUTCOMES IN LAPAROSCOPIC UROLOGY ■ 1129

Sijo Joseph Parekattil

- Introduction 1129
- What Is Mathematical Modeling? 1130
- How Good Is a Model? 1131
- Application of Modeling in Urology 1131
- Application of Modeling in Laparoscopy 1131
- Results 1134
- The Future 1138
- References 1139

CHAPTER 100: NANOTECHNOLOGY AND UROLOGY ■ 1141

Iqbal S. Shergill, Manjit Arya, and Hiten Patel

- Introduction 1141
- Potential Applications of Nanotechnology in Urology 1141
- Delivery Systems for Drug and Gene Therapy 1142
- Imaging and Labeling with Nanostructured Materials 1142
- Molecular Recognition 1142
- Nanosurgical Tools 1143
- Synthetic Therapeutic Devices 1143
- Nanotechnology and Limitations 1143
- Nanotechnology and the Future 1143
- Conclusion 1144
- References 1144

CHAPTER 101: THE SURGEON OF THE FUTURE ■ 1145

Richard M. Satava

- Introduction 1145
- Clinical Practice 1146
- Emerging Technologies 1147
- Education and Training 1148
- Research for Clinical Trials 1149
- Moral and Ethical Challenges 1149
- Conclusion 1149
- References 1150

CONTRIBUTORS

Clément-Claude Abbou Service d'Urologie, Centre Hospitalier Universitaire Henri Mondor, Créteil, France

Joseph B. Abdelmalak Section of Voiding Dysfunction and Female Urology, Glickman Urological Institute, Cleveland Clinic Foundation, Cleveland, Ohio, U.S.A.

Sidney C. Abreu Section of Laparoscopy, ANDROS-Santa Helena Hospital of Brasilia, Brasilia, Brazil

David M. Albala Division of Urology, Duke University Medical Center, Durham, North Carolina, U.S.A.

Nasser Albqami Department of Urology, KH der Elisabethinen, Teaching Hospital of University of Innsbruck, Linz, Austria

Murali K. Ankem Department of Urology, Louisiana State University Health Sciences Center, and Overton Brooks VA Medical Center, Shreveport, Louisiana, U.S.A.

M. S. Ansari Department of Urology and Renal Transplantation, Sanjay Gandhi Postgraduate Institute of Medical Sciences, Lucknow, India

Mehran Anvari Department of Surgery, McMaster University, St. Joseph's Healthcare, Hamilton, Ontario, Canada

Monish Aron Section of Laparoscopic and Robotic Surgery, Glickman Urological Institute, Cleveland Clinic Foundation, Cleveland, Ohio, U.S.A.

Carlos Arroyo Institut Montsouris, Université Pierre et Marie Curie, Paris, France

Manit Arya Institute of Urology and Nephrology, University College London, London, U.K.

Arif Asif University of Miami Miller School of Medicine, Miami, Florida, U.S.A.

D. Assimos Department of Urology, Wake Forest University School of Medicine, Winston-Salem, North Carolina, U.S.A.

Anthony Atala Department of Urology, Wake Forest University Baptist Medical Center, Winston-Salem, North Carolina, U.S.A.

Linda Baker Department of Urology, University of Texas Southwestern Medical Center, Dallas, Texas, U.S.A.

Simon V. Bariol Scottish Lithotripter Centre, Western General Hospital, Edinburgh, U.K.

Eric Barret Institut Montsouris, Université Pierre et Marie Curie, Paris, France

John M. Barry Division of Urology and Renal Transplantation, The Oregon Health & Science University, Portland, Oregon, U.S.A.

Steven M. Baughman Urology Flight, Wilford Hall Medical Center, Lackland AFB, Texas, U.S.A.

Ashish Behari National Institute of Health, Bethesda, Maryland, U.S.A.

Bulent Berker Center for Special Minimally Invasive Surgery, Palo Alto, California, U.S.A.

Jeffrey Berkley Department of Industrial Engineering, University of Washington, Seattle, Washington, U.S.A.

Akshay Bhandari Vattikuti Urology Institute, Henry Ford Health System, Detroit, Michigan, U.S.A.

Sam B. Bhayani Johns Hopkins Medical Institutions, Baltimore, Maryland, U.S.A.

Jay T. Bishoff Urology Flight, Wilford Hall Medical Center, Lackland AFB, Texas, U.S.A.

Renaud Bollens Department of Urology, University Clinics of Brussels, Erasme Hospital, Brussels, Belgium

Morton A. Bosniak Department of Radiology, NYU Medical Center, New York, New York, U.S.A.

Jeffrey A. Cadeddu Department of Urology, University of Texas Southwestern Medical Center, Dallas, Texas, U.S.A.

David Canes Lahey Clinic Medical Center, Institute of Urology, Burlington, Massachusetts, U.S.A.

Xavier Cathelineau Institut Montsouris, Université Pierre et Marie Curie, Paris, France

João Batista G. Cerqueira Section of Renal Transplantation, Federal University of Ceará, Fortaleza, Brazil

Ben Challacombe Laparoscopic Urology and Robotics, Guy's Hospital and Guy's King's and Thomas's School of Medicine, London, U.K.

David Y. Chan The James Buchanan Brady Urological Institute, Johns Hopkins Medical Institutions, Baltimore, Maryland, U.S.A.

Bipan Chand Department of Minimally Invasive Surgery, Cleveland Clinic Foundation, Cleveland, Ohio, U.S.A.

Gary W. Chien Section of Urology, University of Chicago Pritzker School of Medicine, Chicago, Illinois, U.S.A.

George K. Chow Department of Urology, Mayo Clinic, Rochester, Minnesota, U.S.A.

Benjamin Chung Section of Laparoscopic and Robotic Surgery, Glickman Urological Institute, Cleveland Clinic Foundation, Cleveland, Ohio, U.S.A.

Ralph V. Clayman Department of Urology, University of California, Orange, California, U.S.A.

Jose R. Colombo, Jr. Section of Laparoscopic and Robotic Surgery, Glickman Urological Institute, Cleveland Clinic Foundation, Cleveland, Ohio, U.S.A.

Sakti Das Department of Urology, University of California Davis School of Medicine, Sacramento, California, U.S.A.

Prokar Dasgupta Laparoscopic Urology and Robotics, Guy's Hospital and Guy's King's and Thomas's School of Medicine, London, U.K.

J. deKernion Department of Urology, UCLA Medical School, Los Angeles, California, U.S.A.

Joseph J. Del Pizzo Department of Urology, James Buchanan Brady Foundation, The New York Presbyterian Hospital–Weill Cornell Medical Center, New York, New York, U.S.A.

Mihir M. Desai Section of Laparoscopic and Minimally Invasive Surgery, Glickman Urological Institute, Cleveland Clinic Foundation, Cleveland, Ohio, U.S.A.

James F. Donovan Division of Urology, Department of Surgery, University of Cincinnati, Cincinnati, Ohio, U.S.A.

C. G. Eden Department of Urology, The North Hampshire Hospital, Basingstoke, Hampshire, U.K.

Scott E. Eggener Department of Urology, Northwestern University Feinberg School of Medicine, Chicago, Illinois, U.S.A.

Assaad El-Hakim Department of Urology, Long Island Jewish Medical Center, New Hyde Park, New York, U.S.A.

Tibet Erdogru Department of Urology, SLK Heilbronn Hospital, Heilbronn, Germany

Howard Evans Division of Urology, Department of Surgery, University of Alberta, Alberta, Canada

Tommaso Falcone Department of Gynecology and Obstetrics, Cleveland Clinic Foundation, Cleveland, Ohio, U.S.A.

Amr F. Fergany Section of Oncology, Laparoscopy and Minimally Invasive Surgery, Glickman Urological Institute, Cleveland Clinic Foundation, Cleveland, Ohio, U.S.A.

Antonio Finelli Section of Laparoscopic and Minimally Invasive Surgery, University of Toronto, Toronto, Ontario, Canada

Melissa C. Fischer Vattikuti Urology Institute, Henry Ford Health System, Detroit, Michigan, U.S.A.

R. C. Flanigan Department of Urology, Loyola University of Chicago, Chicago, Illinois, U.S.A.

John M. Fitzpatrick Department of Surgery, University College Dublin, Dublin, Ireland

Y. K. Fong Department of Urology, University of Vienna, Vienna, Austria

Gilvan Neiva Fonseca Federal University of Goiás, Goiás, Brazil

Dan B. French Department of Urology, University of Texas Health Science Center at San Antonio, San Antonio, Texas, U.S.A.

João Batista Gadelha Section of Renal Transplantation, Federal University of Ceará, Fortaleza, Brazil

Alejandro Garcia-Segui Section of Laparoscopic and Minimally Invasive Surgery, Department of Urology, “La Floresta” Medical Institute, Caracas, Venezuela

Matthew T. Gettman Service d’Urologie, Centre Hospitalier Universitaire Henri Mondor, Créteil, France

T. R. J. Gianduzzo Department of Urology, The North Hampshire Hospital, Basingstoke, Hampshire, U.K.

Inderbir S. Gill Section of Laparoscopic and Robotic Surgery, Glickman Urological Institute, Cleveland Clinic Foundation, Cleveland, Ohio, U.S.A.

Louis J. Giorgi, Jr. Mercy Medical Group, Carmichael, California, U.S.A.

Michael Grasso III Department of Urology, St. Vincent’s Catholic Medical Center, New York, New York, U.S.A.

Bertrand Guillonnet Department of Urology, Sidney Kimmel Center for Prostate and Urologic Cancers, Memorial Sloan-Kettering Cancer Center, New York, New York, U.S.A.

N. P. Gupta Department of Urology, All India Institute of Medical Sciences, New Delhi, India

Marlou B. Heiland University of Cincinnati, Cincinnati, Ohio, U.S.A.

Ashok K. Hemal Department of Urology, All India Institute of Medical Sciences, New Delhi, India and Vattikuti Urology Institute, Henry Ford Health System, Detroit, Michigan, U.S.A.

Brian R. Herts Section of Abdominal Imaging, Division of Diagnostic Radiology and Glickman Urological Institute, Cleveland Clinic Foundation, Cleveland, Ohio, U.S.A.

Michael G. Hobart Division of Urology, Department of Surgery, University of Alberta, Alberta, Canada

Andrés Hoznek Service d’Urologie, Centre Hospitalier Universitaire Henri Mondor, Créteil, France

Marzel Hrutza Department of Urology, SLK Heilbronn Hospital, Heilbronn, Germany

Thomas H. S. Hsu Department of Urology, Stanford University Medical Center, Stanford University School of Medicine, Stanford, California, U.S.A.

Stephen C. Jacobs Division University of Maryland School of Medicine, Baltimore, Maryland, U.S.A.

Günter Janetschek Department of Urology, KH der Elisabethinen, Teaching Hospital of University of Innsbruck, Linz, Austria

Thomas W. Jarrett The James Buchanan Brady Urological Institute, Johns Hopkins Medical Institutions, Baltimore, Maryland, U.S.A.

John E. Jelovsek Department of Gynecology and Obstetrics, Cleveland Clinic Foundation, Cleveland, Ohio, U.S.A.

Michael A. S. Jewett Division of Urology, Department of Surgical Oncology, Princess Margaret Hospital and the University Health Network, University of Toronto, Toronto, Ontario, Canada

Andrew B. Joel Department of Urology, Georgetown University Hospital, Washington, D.C., U.S.A.

Gerald H. Jordan Department of Urology, Eastern Virginia Medical School, Norfolk, Virginia, U.S.A.

Adrian D. Joyce St. James's University Hospital, Leeds, U.K.

Jihad H. Kaouk Section of Laparoscopic and Robotic Surgery, Glickman Urological Institute, Cleveland Clinic Foundation, Cleveland, Ohio, U.S.A.

Louis R. Kavoussi Johns Hopkins Medical Institutions, Baltimore, Maryland, U.S.A.

Hyung L. Kim Department of Urology, Roswell Park Cancer Institute, Buffalo, New York, U.S.A.

Isaac Yi Kim Department of Urology, University of California, Orange, California, U.S.A.

Moses Kim Scott Department of Urology, Baylor College of Medicine, Houston, Texas, U.S.A.

Wisoot Kongchareonsombat Division of Endourology, Laparoscopy, and Minimally Invasive Surgery, Department of Urology, University of Miami Miller School of Medicine, Miami, Florida, U.S.A.

Amy E. Krambeck Department of Urology, Mayo Clinic College of Medicine, Rochester, Minnesota, U.S.A.

James O. L'Esperance Department of Urology, Naval Medical Center, San Diego, California, U.S.A.

Jaime Landman Department of Urology, Columbia University Medical Center, New York, New York, U.S.A.

Benjamin R. Lee Department of Urology, Long Island Jewish Medical Center, New Hyde Park, New York, U.S.A.

Keith L. Lee Department of Urology, Stanford University Medical Center, Stanford University School of Medicine, Stanford, California, U.S.A.

Raymond J. Leveillee Division of Endourology, Laparoscopy and Minimally Invasive Surgery, Department of Urology, University of Miami Miller School of Medicine, Miami, Florida, U.S.A.

John A. Libertino Lahey Clinic Medical Center, Burlington, Massachusetts, U.S.A.

Lewis CH. Liew St. James's University Hospital, Leeds, U.K.

Yair Lotan Department of Urology, University of Texas Southwestern Medical Center, Dallas, Texas, U.S.A.

Ali Mahdavi Department of Obstetrics and Gynecology, Division of Gynecologic Oncology, Mount Sinai School of Medicine, New York, New York, U.S.A.

M. Marberger Department of Urology, University of Vienna, Vienna, Austria

Robert Marcovich Department of Urology, University of Texas Health Science Center at San Antonio, San Antonio, Texas, U.S.A.

Daniel R. Margulies Department of Surgery, Cedars-Sinai Medical Center, Los Angeles, California, U.S.A.

Surena F. Matin Department of Urology, The University of Texas M.D. Anderson Cancer Center, Houston, Texas, U.S.A.

Edward D. Matsumoto Division of Urology, Department of Surgery, McMaster University, Hamilton, Ontario, Canada

Maxwell V. Meng Department of Urology and UCSF Comprehensive Cancer Center, University of California School of Medicine, San Francisco, California, U.S.A.

Mani Menon Vattikuti Urology Institute, Henry Ford Health System, Detroit, Michigan, U.S.A.

Anoop M. Meraney Section of Laparoscopic and Robotic Surgery, Glickman Urological Institute, Cleveland Clinic Foundation, Cleveland, Ohio, U.S.A.

Scott D. Miller Georgia Urology, Atlanta, Georgia, U.S.A.

Peter J. Millock Capital District Urologic Surgeons, Albany, New York, U.S.A.

Alireza Moinzadeh Section of Laparoscopic and Robotic Surgery, Glickman Urological Institute, Cleveland Clinic Foundation, Cleveland, Ohio, U.S.A.

Debora K. Moore Minimally Invasive Urology of the Southwest, Las Palmas Medical Center, El Paso, Texas, U.S.A.

Robert G. Moore Minimally Invasive Urology of the Southwest, Las Palmas Medical Center, El Paso, Texas, U.S.A.

Michael E. Moran Capital District Urologic Surgeons, Albany, New York, U.S.A.

Sergio G. Moreira, Jr. Division of Urology, University of South Florida, Tampa, Florida, U.S.A.

Ravi Munver Department of Urology, Center for Minimally Invasive Urologic Surgery, Hackensack University Medical Center, Hackensack, New Jersey, U.S.A.

Robert P. Myers Department of Urology, Mayo Clinic, Mayo Clinic College of Medicine, Rochester, Minnesota, U.S.A.

Robert B. Nadler Department of Urology, Northwestern University Feinberg School of Medicine, Chicago, Illinois, U.S.A.

Stephen Y. Nakada Division of Urology, Department of Surgery, University of Wisconsin School of Medicine and Public Health, Madison, Wisconsin, U.S.A.

Camran Nezhat Stanford University Medical School, Palo Alto, California, U.S.A.

Ceana Nezhat Nezhat Medical Center, Endometriosis Clinic, Atlanta, Georgia, U.S.A.

Farr Nezhat Mount Sinai School of Medicine, New York, New York, U.S.A.

Christopher S. Ng Minimally Invasive Urology Institute, Cedars-Sinai Medical Center, Los Angeles, California, U.S.A.

Abraham A. Nisim Department of Surgery, Cedars-Sinai Medical Center, Los Angeles, California, U.S.A.

Rene Sotelo Noguera Section of Laparoscopic and Minimally Invasive Surgery, Department of Urology, “La Floresta” Medical Institute, Caracas, Venezuela

Raul C. Ordorica Division of Urology, University of South Florida, Tampa, Florida, U.S.A.

Marcelo A. Orvieto Section of Urology, University of Chicago Pritzker School of Medicine, Chicago, Illinois, U.S.A.

Michael C. Ost Department of Urology, North Shore–Long Island Jewish Medical Center, New Hyde Park, New York, U.S.A.

Michael A. Palese Department of Urology, The Mount Sinai Medical Center, New York, New York, U.S.A.

Vito Pansadoro Vincenzo Pansadoro Foundation, Rome, Italy

Sijo Joseph Parekattil Glickman Urological Institute, Cleveland Clinic Foundation, Cleveland, Ohio, U.S.A.

Hiten Patel Institute of Urology and Nephrology, University College London, London, U.K.

James O. Peabody Vattikuti Urology Institute, Henry Ford Health System, Detroit, Michigan, U.S.A.

Michael Perrotti Capital District Urologic Surgeons, Albany, New York, U.S.A.

Craig A. Peters Department of Urology, Children’s Hospital, Harvard Medical School, Boston, Massachusetts, U.S.A.

Michael W. Phelan Division University of Maryland School of Medicine, Baltimore, Maryland, U.S.A.

Jeffrey Ponsky Department of Minimally Invasive Surgery, Cleveland Clinic Foundation, Cleveland, Ohio, U.S.A.

Dix P. Poppas Institute for Pediatric Urology, New York Presbyterian Hospital–Weill Medical College of Cornell University, New York, New York, U.S.A.

James R. Porter Department of Urology, University of Washington Medical Center, Seattle, Washington, U.S.A.

Glenn M. Preminger Division of Urologic Surgery, Comprehensive Kidney Stone Center, Duke University Medical Center, Durham, North Carolina, U.S.A.

Mark Preston Gynecologic Center for Women’s Health, Waterbury, Connecticut, U.S.A.

Raymond R. Price Intermountain Healthcare/Salt Lake Clinic, Salt Lake City, Utah, U.S.A.

J. Daniell Rackley Department of Urology, Wake Forest University Baptist Medical Center, Winston-Salem, North Carolina, U.S.A.

Raymond R. Rackley Section of Voiding Dysfunction and Female Urology, Glickman Urological Institute, Cleveland Clinic Foundation, Cleveland, Ohio, U.S.A.

Anup P. Ramani Section of Laparoscopy, Department of Urological Surgery, University of Minnesota, Minneapolis, Minnesota, U.S.A.

Jens J. Rassweiler Department of Urology, SLK Heilbronn Hospital, Heilbronn, Germany

Erick M. Remer Section of Abdominal Imaging, Division of Diagnostic Radiology, Cleveland Clinic Foundation, Cleveland, Ohio, U.S.A.

Harrison K. Rhee Lahey Clinic Medical Center, Burlington, Massachusetts, U.S.A.

Jerome P. Richie Harvard Medical School, Boston, Massachusetts, U.S.A.

Lee Richstone Brady Urologic Health Center, Weill Medical College of Cornell University, Ithaca, New York, U.S.A.

Michael D. Rollins Intermountain Healthcare/Salt Lake Clinic, Salt Lake City, Utah, U.S.A.

Jim Ross Center for Female Continence, Department of Obstetrics and Gynecology, University of California Los Angeles School of Medicine, Salinas, California, U.S.A.

Jonathan H. Ross Glickman Urological Institute, Cleveland Clinic Foundation, Cleveland, Ohio, U.S.A.

François Rozet Institut Montsouris, Université Pierre et Marie Curie, Paris, France

Laurent Salomon Service d’Urologie, Centre Hospitalier Universitaire Henri Mondor, Créteil, France

Jeffery W. Saranchuk Department of Urology, Sidney Kimmel Center for Prostate and Urologic Cancers, Memorial Sloan-Kettering Cancer Center, New York, New York, U.S.A.

Richard M. Satava Department of Surgery, University of Washington Medical Center, Seattle, Washington and Advanced Biomedical Technologies, Defense Advanced Research Projects Agency (DARPA), Arlington, Virginia, U.S.A.

Stephen J. Savage Department of Urology, Medical University of South Carolina, Charleston, South Carolina, U.S.A.

Charles D. Scales, Jr. Division of Urology, Duke University Medical Center, Durham, North Carolina, U.S.A.

Claude Schulman Department of Urology, University Clinics of Brussels, Erasme Hospital, Brussels, Belgium

Peter Schulam Department of Urology, UCLA School of Medicine, Los Angeles, California, U.S.A.

Philippe Sebe Service d'Urologie, Centre Hospitalier Universitaire Henri Mondor, Créteil, France

Anthony J. Senagore Department of Colorectal Surgery, Cleveland Clinic Foundation, Cleveland, Ohio, U.S.A.

Arieh L. Shalhav Section of Urology, University of Chicago Pritzker School of Medicine, Chicago, Illinois, U.S.A.

Bijan Shekarriz Department of Urology, SUNY, Upstate Medical University, Syracuse, New York, U.S.A.

Iqbal S. Shergill Institute of Urology and Nephrology, University College London, London, U.K.

Steven J. Shichman Division of Urology, Department of Surgery, University of Wisconsin Medical School, Madison, Wisconsin, U.S.A.

Dinesh Singh Section of Laparoscopic and Robotic Surgery, Glickman Urological Institute, Cleveland Clinic Foundation, Cleveland, Ohio, U.S.A.

Arthur Smith Department of Urology, North Shore–Long Island Jewish Medical Center, New Hyde Park, New York, U.S.A.

Massimiliano Spaliviero Section of Laparoscopic and Robotic Surgery, Glickman Urological Institute, Cleveland Clinic Foundation, Cleveland, Ohio, U.S.A.

W. Patrick Springhart Division of Urology, Duke University Medical Center, Durham, North Carolina, U.S.A.

John P. Stein Department of Urology, Keck School of Medicine of the University of Southern California, Los Angeles, California, U.S.A.

Marshall L. Stoller Department of Urology, University of California San Francisco, San Francisco, California, U.S.A.

Urs E. Studer Department of Urology, University of Bern, Bern, Switzerland

Li-Ming Su Brady Urological Institute, The Johns Hopkins University School of Medicine, Baltimore, Maryland, U.S.A.

Marto Sugiono Department of Urology, SLK Heilbronn Hospital, Heilbronn, Germany

Richard Sutherland Glickman Urological Institute, Cleveland Clinic Foundation, Cleveland, Ohio, U.S.A.

Kazuo Suzuki Department of Urology, Shintoshin Clinic, Iwata, Shizuoka, Japan

Robert M. Sweet Department of Urologic Surgery, University of Minnesota, Minneapolis, Minnesota, U.S.A.

Dogu Teber Department of Urology, SLK Heilbronn Hospital, Heilbronn, Germany

Ashutosh Tewari Robotic Prostatectomy and Urologic Oncology Outcomes, Weill Medical College of Cornell University, Ithaca, New York, U.S.A.

David A. Tolley Scottish Lithotripter Centre, Western General Hospital, Edinburgh, U.K.

Karim A. Touijer Department of Urology, Sidney Kimmel Center for Prostate and Urologic Cancers, Memorial Sloan-Kettering Cancer Center, New York, New York, U.S.A.

Edouard Trabulsi Department of Urology, Sidney Kimmel Center for Prostate and Urologic Cancers, Memorial Sloan-Kettering Cancer Center, New York, New York, U.S.A.

Ingolf Tuerk Lahey Clinic Medical Center, Institute of Urology, Burlington, Massachusetts, U.S.A.

Paul K. Tulikangas Division of Urogynecology, Department of Obstetrics and Gynecology, University of Connecticut, Hartford, Connecticut, U.S.A.

Osamu Ukimura Section of Laparoscopic and Robotic Surgery, Glickman Urological Institute, Cleveland Clinic Foundation, Cleveland, Ohio, U.S.A.

Guy Vallancien Institut Montsouris, Université Pierre et Marie Curie, Paris, France

Roland F. P. van Velthoven Department of Urology, Institut Jules Bordet and CHU Saint-Pierre, Université Libre de Bruxelles, Brussels, Belgium

Ioannis M. Varkarakis The James Buchanan Brady Urological Institute, Johns Hopkins Medical Institutions, Baltimore, Maryland, U.S.A.

Joseph C. Veniero Section of Abdominal Imaging, Division of Diagnostic Radiology, Cleveland Clinic Foundation, Cleveland, Ohio, U.S.A.

Ramakrishna Venkatesh Minimally Invasive Urology, Division of Urology, Washington University School of Medicine, St. Louis, Missouri, U.S.A.

Alessandro Volpe Division of Urology, Department of Surgical Oncology, Princess Margaret Hospital and the University Health Network, University of Toronto, Toronto, Ontario, Canada

Joseph R. Wagner Department of Urology, Beth Israel Medical Center, Albert Einstein College of Medicine, New York, New York, U.S.A.

McClellan M. Walther National Institute of Health, Bethesda, Maryland, U.S.A.

David S. Wang Department of Urology, Boston University School of Medicine, Boston, Massachusetts, U.S.A.

Christopher A. Warlick The James Buchanan Brady Urological Institute, Johns Hopkins Medical Institutions, Baltimore, Maryland, U.S.A.

Howard N. Winfield Department of Urology, University of Iowa Hospitals and Clinics, Iowa City, Iowa, U.S.A.

J. Stuart Wolf, Jr. Division of Minimally Invasive Urology, Department of Urology, University of Michigan, Ann Arbor, Michigan, U.S.A.

BASIC CONSIDERATIONS

HISTORY OF LAPAROSCOPY: AN ODYSSEY OF INNOVATIONS

Sergio G. Moreira, Jr. and Raul C. Ordorica

Division of Urology, University of South Florida, Tampa, Florida, U.S.A.

Sakti Das

Department of Urology, University of California Davis School of Medicine, Sacramento, California, U.S.A.

*"The principal mark of genius is not perfection but originality, the opening of new frontiers."
—Arthur Koestler*

Urologists once only peered into the "new frontier" of laparoscopy. Today we are now embracing it and thriving within it, bringing its benefits to our patients. Even as we witness its growth and realize its potential, it is instructive to peer into the past.

At the time of this writing, interest in laparoscopic urology continues to rise at an unprecedented rate. This interest is currently evident in both urologic practice and training. The wide range and availability of information has led the patient population to demand laparoscopic knowledge and skills from the urologic community. Thus, residency programs are increasingly emphasizing laparoscopic training, and graduates should have enhanced familiarity with laparoscopic technique once delegated to specialty training. Laparoscopic fellowship programs continue to thrive, producing tomorrow's academic leaders. Courses in advanced laparoscopic urology are available both nationally and internationally for established urologists.

Urologists once only peered into the "new frontier" of laparoscopy. Today we are now embracing it and thriving within it, bringing its benefits to our patients. Even as we witness its growth and realize its potential, it is instructive to peer into the past.

Laparoscopic surgery owes much of its history to the development of endoscopic technique in the beginning of the 19th century. Initial methods to examine body orifices were developed in 1805 by the German physician Phillip Bozzini (Fig. 1) (1), who constructed a thin silver funnel illuminated by reflected candlelight held within its stand (Fig. 2). After several modifications, the instrument was demonstrated at a scientific gathering in Frankfurt in July of 1806 and was indeed considered remarkable for the examination of the pharynx and nasal cavities. The "Lichtleiter" was purchased by order of the Emperor, and given to the Josephinum for testing its utility with unbiased studies. A set of tests on actual patients conducted by the faculties at the University of Vienna showed unfavorable results. The use of the instrument was considered an



FIGURE 1 ■ Phillip Bozzini.



FIGURE 2 ■ Bozzini's endoscope (ca. 1805).

unnatural act and there is no evidence that Bozzini had used the instrument again. Although the instrument would have proven cumbersome, inefficient, and painful for both the operator and the patient, it is considered the first major foray into endoscopy. The original Lichtleiter of Bozzini is now enshrined in the Josephinum in Vienna (2).

Throughout the mid 1800s, several scientists attempted to construct endoscope-like instruments. Pierre Segalas from France refined the urethroscope in 1826 adding an introduction cannula and mirrors for light reflection. Antonin Desormeaux, Segalas' fellow countryman, presented the first serviceable endoscope to the Academy of Paris in 1853 (Fig. 3) (1,3). He performed and reported several investigations of the urethra and bladder using such instrument, of which major development consisted of an illumination source of increased intensity obtained utilizing the reflected light from an alcohol lamp. A clear intellectual milestone had been reached, and Desormeaux was awarded a portion of the Argenteuil Prize for such an achievement (4).

The development of a light source that could be transported into the body cavity was the next, awaited major innovation. Using a platinum wire loop heated by an electric current, Julius Bruck, a dentist of Breslau, heralded the development of internal illumination in 1867 (5). Despite great success in the exploration of the oral cavity, Bruck's technique of water-cooled, diaphanoscopic bladder transillumination by a rectally placed coil was still dangerous, and rather ineffective. Apparently unaware of Bruck's earlier attempts, Max Nitze from Germany successfully applied this kind of illumination source to his cystoscope in the late 1800s (Fig. 4).

Compelled by the concept of an internal light source, Nitze succinctly stated: "in order to light up a room, one must carry a lamp into it" (5). Applying these concepts, Nitze and Diecke, an instrument maker in Dresden, were able to manufacture their first cystoscope in 1877 (6). This instrument was still rather bulky and unreliable. Teaming up with Joseph Leiter, a renowned instrument maker in Vienna, Nitze developed the necessary further improvements consisting of an electrically-heated platinum wire light source placed behind a quartz shield. The Nitze–Leiter cystoscope was presented in 1879 (Fig. 5).

Despite these advances, the heat generated within the bladder required a bulky water-cooling device, and the electrical apparatus that created the necessary current for the platinum wire was difficult to maintain (Fig. 6). Further progress awaited Thomas Edison's invention of the incandescent lamp in 1880. This landmark development provided increased illumination and alleviated the need for the water-cooling system. A larger part of the scope could be dedicated to the optical lens system, resulting in better visualization with improved light delivery (1). Multiple endoscopists, including David Newman (1883), Nitze (1887), Leiter (1887), and Dittel (1887) employed the incandescent bulb (6).

Refining the mignon lamp in 1898, Charles Preston provided a more dependable illumination source consisting of a bright light produced with low-amperage current (Fig. 7) (7). This became the standard light source for endoscopy until an adequate external systems of light delivery was developed 50 years later when Dimitri O. Ott, a famous Petrograd gynecologist, introduced "ventroscopy" for the inspection of the



FIGURE 3 ■ Desormeaux's endoscope (ca. 1853).



FIGURE 4 ■ Max Nitze.



FIGURE 5 ■ The Nitze-Leiter cystoscope (ca. 1879).



FIGURE 6 ■ An early cystoscope.

abdominal cavity (8). He employed a head mirror to reflect light into a speculum introduced through a small anterior abdominal wall incision (9,10). Although technically primitive, the idea of closed diagnostic inspection of intraperitoneal contents was conceived. However, the concept of distending the peritoneal cavity with air to aid in visual inspection was not realized even though in 1870 Simons from Bonn had already reported safe air pumping into animal abdomen. Wegner from Berlin corroborated Simon's studies in 1877, and in 1882, Mosetitz-Moorhof from Vienna successfully created pneumoperitoneum to treat tubercular peritonitis in a child (11). George Kelling from Germany (Fig. 8) had the pioneering idea of employing the Nitze cystoscope for the inspection of abdominal viscera. During the 73rd Congress of German Naturalists in 1901, he performed a so-called "celioscopy" on a dog. After insufflating the peritoneal cavity with air flowing through a needle, Kelling observed changes to the intra-abdominal organs at pneumoperitoneum pressures sufficient to stop intra-abdominal hemorrhage (i.e., up to 50–60 mmHg) (12). Kelling's advanced work was particularly notable for the use of a separate needle to produce the pneumoperitoneum. However, he failed to publish in a timely fashion his work on humans, and the



FIGURE 7 ■ Light source developed by Preston in 1898 for the mignon lamp.



FIGURE 8 ■ George Kelling.



FIGURE 9 ■ Hans Christian Jacobaeus.



FIGURE 10 ■ B. M. Bernheim.

technical refinements he developed. Hans Christian Jacobaeus of Sweden (an internist in Stockholm) published on both human laparoscopy and thoracoscopy in 1910, highlighting the low morbidity of such procedure despite the use of a single trocar to both produce the pneumoperitoneum and provide endoscopic access (Fig. 9) (13). By 1912, his reported series included a total of 115 patients (13–16). At Johns Hopkins University in 1911, Bernheim performed an *organoscopy* using a proctoscope to visually inspect the peritoneal cavity (Fig. 10) (17).

Minor variations in equipment and technique were described in subsequent reports from both Europe and the United States (18). In 1920, Orndoff devised a trocar with a pyramidal point and an automatic cannula valve to prevent the escape of gas from the pneumoperitoneum (19). He published his experience with laparoscopy performed using such devices and a roentgen screen. To prevent the leakage of gas, Stone from the United States described the fitting of the outer portion of the trocar with a rubber gasket in 1924 (20). At the same time, Zollikofer from Switzerland introduced the use of CO₂ for insufflation and observed its ease of absorption (21). The primary medium was previously filtered air, with its intrinsic risk of air embolism. To minimize the risks related to initial abdominal puncture, Goetze from Germany developed an automatic insufflation needle in 1918 (22). Initially, the insufflating medium for this instrument was oxygen, a gas with lower incidence emboli formation when compared to air. However, it soon became obsolete with the advent of electrocautery. In 1938, Veress from Hungary further refined the automatic needle initially used for the creation of pneumothorax in the treatment of tuberculosis (Fig. 11) (23). The Veress needle is now routinely used to create pneumoperitoneum.

Besides for developing technical advances, many physicians are renowned and responsible for the instruction of laparoscopy as an accepted method. H. Kalk from Germany exemplified this as an outstanding proponent of “peritoneoscopy” throughout Europe (Fig. 12) (24–26). In fact, in addition to devising a 135°, fore oblique viewing system, his teachings led to the widespread adoption of his methods. With some 21 papers on the management of liver and gallbladder disease published between 1929 and 1959, he is referred to as the “Father of Modern Laparoscopy” (10), a title oftentimes shared with Kurt Semm (Fig. 13), a German gynecologist who developed many laparoscopic operative techniques and instruments including intracorporeal suturing techniques, a controlled insufflation apparatus, and safe endocautery devices. Semm first performed a laparoscopic appendectomy, which

FIGURE 11 ■ Veress's automatic needle (ca. 1938).





FIGURE 12 ■ H. Kalk.



FIGURE 13 ■ Kurt Semm.

was a considerable task, given the limited ability to convey the otherwise “closed” world of laparoscopy.

Although multiple devices had been designed for photographing laparoscopic detail, the majority of description was by illustration alone. These limitations continued until a single lens reflex camera for endophotography was introduced by Henning in 1931 (27). The first black and white and color photographic atlas was published by Kalk in 1935 (27). Later on Caroli, Ricordeau, and Foures from France first used an electronic flash intra-abdominally (28). Further major advances in visual reproduction awaited the development of improved light transmission, lens systems, cinephotography, and eventual video technology.

Meanwhile, laparoscopy made its initial forays into the interventional realm. Due to advances and modifications in high frequency unipolar electrocautery, in 1933, Fervers from Germany burned abdominal adhesions and performed excisional biopsy (29). In the United States, Ruddock further perfected his own peritoneoscope, pneumoperitoneum needle, trocar, and ancillary instruments for biopsy (30–34). He published his initial series of 200 cases in 1934, followed by his entire experience with more than 2500 cases. Laparoscopic tubal sterilization using electrocautery was first described in the porcine model by the Swiss Boesch in 1935 (35). Power and Barnes from the United States performed this on a patient in 1941; their report included an interim published discussion of the technique by Anderson (36,37). The American Donaldson used the Ruddock peritoneoscope to perform a uterine suspension in 1942 (38). Further progress in laparoscopic abdominal surgery had to await the better provisions for safe hemostasis achieved by improved electrocautery.

During World War II, culdoscopy, as described by Albert Decker in 1944, gained the attention of the American surgical community and became a standard gynecologic procedure in the United States for many years (39–41). Contemporarily, the French Raoul Palmer greatly furthered gynecologic laparoscopy throughout Europe (9,42). Interest was not rekindled in the United States until the publication, in 1967, of the first English laparoscopic textbook by the British gynecologist Steptoe, who was influenced by his European colleagues (43). The resurrection of American laparoscopy occurred through the dissemination of contemporary experience and by the accompanying advances in optics, light transmission, insufflators, and ancillary materials. These largely European developments broadened the field’s utility and better ensured patient safety.

In 1952, the French Fourestier, Gladu, and Valmiere developed a method for light transmission along a quartz rod that greatly improved the quality of light produced, and removed the risk of electrical and heat injury plaguing previous systems (44). The same year Hopkins and Kapany from England first employed fiber optics similar to those used into the fiber optic gastroscope (45). Hopkins was also developed a quartz rod lens, which replaced prior lens systems of rigid endoscopes (46). Frangenheim

incorporated many of these advances in laparoscopy, using diathermy for tubal sterilization in 1963, and fiber optics in 1965 (46). His extensive publications regarding anesthetic methods, pneumoperitoneum, tissue emphysema, air embolism, intestinal perforation, hemorrhage, burns, and cardiopulmonary problems furthered the course of safe laparoscopic procedure (47).

In the United States, Cohen, followed by Hulka, were at the forefront of laparoscopy through the late 1960s and early 1970s, disseminating and popularizing laparoscopy within the gynecologic community (47,48). After initially diagnostic application, the major indication was voluntary sterilization. These methods were so widespread, that Jordan M. Phillips founded the American Association of Gynecologic Laparoscopists in 1972 (48). Its second annual meeting was held in 1973 in conjunction with the First International Congress of Gynecologic Laparoscopy, and counted 600 attendees. At that time, approximately 500,000 laparoscopic procedures were performed annually in the United States, and laparoscopy became a requirement of residency training in obstetrics–gynecology programs by 1981 (48).

Meanwhile, substantial pioneering work by Kurt Semm advanced the safety and scope of laparoscopy (4,35,49–53). Automatic control systems were developed for induction and maintenance of the pneumoperitoneum using CO₂. Through the 1970s, further Semm's work in conjunction with WISAP (Sauerlach, West Germany) led to the development of electronically controlled units. The development of the open trocar technique of Hasson expanded the indications for laparoscopy including patients with a history of prior laparotomy and adhesions, considered a contraindication to laparoscopy so far (46,54).

Semm takes great note regarding the lack of safe hemostasis as additional impediment in the advancement of laparoscopic surgery (35). The use of high frequency monopolar cautery within the abdominal cavity had been historically fraught with the serious sequelae of bowel injury. Indeed, the second most frequent cause for lawsuits against obstetrician–gynecologists in the early 1970s was for laparoscopic bowel burns (7). Therefore, a great deal of investigation was devoted to eliminate these dangers, particularly, with the growing popularity of laparoscopic tubal disruption. The electrical shielding of instruments and current reduction were introduced to obviate these problems, along with the subsequent development of the 100°C endocoagulator. Hemostatic methods also included the use of “endoloop” and suturing devices for large blood vessel control (4,50,53).

Laparoscopy, initially performed to diagnose liver and gallbladder diseases, was employed progressively less frequently as radiographic imaging developed and moved to the forefront. After performing the first laparoscopic cholecystectomy in Germany in 1985, Muhe suffered the indignities of collegial criticism and ostracism like Semm did before after performing the first laparoscopic appendectomy. In 1987, Philippe Mouret, a French gynecologist, performed laparoscopic cholecystectomy during a routine pelvic procedure (45), and presented his experience during a meeting. The first clinical series of laparoscopic cholecystectomy were performed by Francois Dubois in France in 1988, and McKernan and Saye (1988) and Reddick (1989) in the United States (45,55). Reddick's and Dubois' documented the capability of laparoscopic cholecystectomy to duplicate open surgical principles (56). Based on these pioneering experiences, interest on laparoscopic cholecystectomy raised tremendously resulting in rapid widespread of the procedure to the point of almost replacing elective open cholecystectomy in many centers over a three-year period (45). While this may be startling when viewed as an isolated event, it is predictable when perceived within a broader framework.

The performance of complex intra-corporeal procedures in a safe and reliable manner required more than the simple development of advanced mechanical instrumentation. It was also the result of the coordinate efforts of many operators. During standard laparoscopic practice, only the primary could actually see the operative field, while the ability of the assistant to substantially participate was limited blind involvement. Additional eyepiece attachments were incorporated for learning purposes to allow the novice to gain the necessary skills to subsequently operate alone. Although closed circuit television was manufactured since 1959, portable systems were not available until 1970 (48). The term “portable” should be applied sparingly, because the initial cameras weighed some 10 pounds and were equipped with an attachable ceiling harness. Their size, image quality, and cost relegated them to the rare and cumbersome teaching aid. Only the advent of microchip technology allowed practical real-time video monitoring of the operative field. Widespread and extensive use of such technology throughout all areas of endoscopy marked the groundwork for major laparoscopic intervention. With the entire surgical team watching at the surgical field, more complex procedures could be undertaken.

Laparoscopy in urology paralleled, to a large extent, the changes in general surgery. Up to the late 1980s, urologic laparoscopy had limited applications. In 1976, Cortesi reported laparoscopic abdominal exploration in an 18-year old patient with bilateral abdominal testes (57). Since then, cumulative experience by multiple authors has substantiated laparoscopic management of cryptorchidism (58–61). Another anecdotal application was reported by Wickham, who, in 1979, performed laparoscopic ureterolithotomy by a retroperitoneal approach (62). Additional stone manipulation was performed by Eshghi, who, in 1985, laparoscopically monitored the percutaneous transperitoneal removal of staghorn calculi from a pelvic kidney (63).

However, apart from its use in the pediatric population for cryptorchidism, urologic laparoscopy lacked a broad application when compared to the large population of patients with cholelithiasis treated laparoscopically by general surgeons. In fact, in many urologic procedures the benefits of laparoscopy were initially outweighed by the technically challenging anatomy that greatly limited access and compromised control. Varicocelectomy and bladder neck suspension were deemed feasible but showed little benefit over open surgery. Laparoscopic pelvic lymphadenectomy performed to overtake inaccuracy of imaging techniques for staging of patients with prostate carcinoma was deemed both feasible and effective (64). Laparoscopic pelvic lymphadenectomy in a porcine model was described by Howard Winfield in 1989 (65). Schuessler and associates first performed this procedure in a series of patients with prostate cancer. Nevertheless, interest in laparoscopic pelvic lymph node dissection dropped precipitously in mid 1990s due to advances in nonoperative staging of prostate cancer. After initial, isolated but encouraging reports, Janetschek et al. performed laparoscopic retroperitoneal lymph node dissection in an attempt to reduce the morbidity of open retroperitoneal lymph node dissection (66). Kavoussi and coworkers reported the feasibility of laparoscopic retroperitoneal lymph node dissection for patients with stage I non-seminomatous germ cell tumors. Efficacy was similar to traditional retroperitoneal lymph node dissection (67).

Renal procedures are the main target for urologic laparoscopic organ resection. Laparoscopic nephrectomy in a porcine model was first attempted via a retroperitoneal approach by Weinberg and Smith in 1988 (68). In 1991, after extensive laboratory trials including the development of the basic concepts of organ entrapment and tissue morcellation, Clayman and coworkers performed the first clinical laparoscopic nephrectomy. Subsequent continued results of transperitoneal laparoscopic nephrectomy have been reported by the same group (69–71). With increasing skills and experience, the total operative time of almost eight hours required to complete the initial case was reduced to four hours. Such procedures heralded a new era in laparoscopic urology that began to challenge and compete with conventional open surgery. However, many technical refinements were necessary to make laparoscopy an appealing alternative to open surgery. Using retroperitoneal balloon dissection to create an adequate retroperitoneal space, Gaur obviated the initial difficulties with closed insufflation of the retroperitoneum (72). In addition to these advances, significant improvements in vascular control and soft tissue hemostasis are constantly evolving. As a result, more challenging laparoscopic renal procedures were progressively attempted and executed. Winfield and colleagues performed the first laparoscopic partial nephrectomy in 1993. Subsequent series of laparoscopic partial nephrectomy reported by many authors showed cancer control similar to open nephron-sparing procedures. Capitalizing on the relatively benign recovery from laparoscopic surgery, in 1994, Gill et al. demonstrated the feasibility of laparoscopic donor nephrectomy in the porcine model (73). The first clinical donor nephrectomy performed by Kavoussi and coworkers in 1995 (74). Over the next five years, the technique became more refined, and it has since spread

worldwide. At many centers, laparoscopic donor nephrectomy is the now standard of care. The development of a handport providing direct hand assistance has increased accessibility to renal surgery. The ability to manipulate tissue has greatly increased the comfort zone for many urologists, broadening the indications for minimally invasive procedures. One of the critiques raised by laparoscopic purists regards the size of the incision required to place the handport. Undoubtedly, hand-assisted laparoscopy provides greater control and easier organ retrieval for the naïve laparoscopic surgeon.

The next urologic milestone in laparoscopic organ resection was the management of prostate and bladder diseases. Laparoscopic radical prostatectomy was innovated and perfected in Paris by Guillonnet and Vallancien (2000) (75) as well as by Abbou et al.

(2000) (76). Although a steep learning curve was necessary to perform Laparoscopic radical prostatectomy in a time-sensitive manner, today several centers worldwide perform laparoscopic radical prostatectomies routinely with results similar to those of the open counterpart. Improved magnification and better identification of the anatomical structures are potential benefits, and decreased morbidity is anticipated. However, at the time of this writing, open prostatectomy remains the standard of care. Nevertheless, laparoscopic technology and experience on Laparoscopic radical prostatectomy, and their acceptance, continue to evolve.

Laparoscopy has been applied also to the technically demanding area of cystectomy. In 2000, Gill et al. reported their initial experience with bilateral pelvic lymphadenectomy, cystectomy, and ileal conduit urinary diversion in patients with muscle-invasive bladder cancer (77). The ability to complete this procedure intracorporeally required a high level of reconstruction that has also been applied to other areas in urology. The same laparoscopic techniques for suturing and knot tying were efficaciously employed to perform, ureteral reimplantation, ureteroureterostomy, and pyeloplasty. In fact, in select centers laparoscopic pyeloplasty is becoming the standard of care for ureteropelvic junction obstruction.

The development of robot technology (*da Vinci*® Surgical System^a) is the epitome of surgical magnification and technical refinement (Fig. 14). Such expensive sophistication allows for intricate manipulation within a limited operative space.

It is becoming increasingly evident that laparoscopy has the potential to duplicate the principles of open urologic surgery for the management of several medical conditions involving the lymph nodes, kidney, adrenal gland, bladder, or ureter. However, although technical pioneers have demonstrated the feasibility of many demanding laparoscopic procedures, long-term results are awaited before these procedures would become routinely part of the urologic armamentarium. In order for evolution to occur and to continue, nuances must prove to be superior to the status quo. The hallmark of this current period of urologic laparoscopic history is the combination of technical achievement demonstrating what can be done, with the application of academic rigor to determine what should be done. In an increasing number of multi-institutional studies, laparoscopic procedures are compared with their open surgical counterparts. The evidence of comparable efficacy combined with improvements in postoperative pain, cosmesis, recovery, and length of hospital stay shows that laparoscopy belongs in the mainstream of urologic surgery.

FIGURE 14 ■ The *da Vinci*® Surgical System. Source: Courtesy of Intuitive Surgical, Inc.



^aIntuitive Surgical, Inc., Sunnyvale, CA.

In this current era, feasibility and benefit of many urologic laparoscopic procedures have been proven on a large scale. As we enter the new millennium, the craft of open surgery may have an ever-decreasing role in the treatment of urologic diseases. This evolution will require the demonstration of benefit over existing standard practice, which then must be embraced by urology in order to be implemented. This evolution, initially charted by the relentless pioneers mentioned in this chapter along with countless others, will continue to be written as an odyssey of innovations in the hands of modern stalwarts.

REFERENCES

1. Herman J. Development of the cystoscope. In: *Urology: A View Through the Retrospectroscope*. Hagerstown: Harper and Row, 1973:67.
2. Engel RM, Philipp Bozzini-the father of endoscopy. *J Endourol* 2003; 17(10):859–862.
3. Desormeaux A. Transactions of the Societe de Chirurgie, Paris. *Gazette des Hop*, 1865.
4. Semm K. Endoscopic intraabdominal surgery in gynecology. *Wiener Klinische Wochenschrift* 1983(May 27); 95(11):353–367.
5. Luys, G.H.o.c.I.A.T.o.C.a. History of Cystoscopy. A Treatise on Cystoscopy and Urethroscopy (trans). St. Louis: C.V. Mosby, 1918:55.
6. Belt, A.a.C., DA.: In: Cabot H, ed. The History of the Cystoscope In Modern Urology. Philadelphia: Lea & Fibiger, 1936:15.
7. Hulka J. History and Introduction. Textbook of Laparoscopy. Orlando: Grune & Stratton, 1985:1–5.
8. Ott D. Ventroscopic illumination of the abdominal cavity in pregnancy. *Zhurnal Akusherstva I Zhenskikh Boleznei* 1901; 15:7–8.
9. Palmer, R.L.C.p.l.v.t.C.R.S.F. La Coelioscopie par la vois transvaginale. *CR Soc Franc Gynec* 1947; 17:229.
10. Wittman I. Peritoneoscopy. Budapest: Publishing House of the Hungarian Academy of Sciences, 1966:3–5.
11. Litynski GS. Highlights in the History of Laparoscopy. Frankfurt, Germany: Barbara Bernert Verlag, 1996:367.
12. Kelling GM. Ueber oesophagoskopie, Gastroskopie und Koelioskopie. *Med Wochenschr* 1902; 49:21.
13. Jacobaeus HC. Über die möglichkeit die zystoskopie bei untersuchung seröser höhlen anzuwenden. *Munch Med Wochenschr* 1910; 57:2090–2092.
14. Jacobaeus HM. Kurze Übersicht uber mei erfahrungen mit der laparo-thorakoskopie. *Med Wschr* 1911; 58:2017.
15. Jacobaeus H. Laparo-thorakoskopie. *Hygiea (Stockholm)* 1912; 74:1070.
16. Jacobaeus H. Über laparo- und thorakoskopie. *Beitr Klin Tuberk* 1912; 25:183.
17. Bernheim BM. Organoscopy: cystoscopy of the abdominal cavity. *Ann Surg* 1911; 53:764–767.
18. Nadeu, O.a.K., OF. Endoscopy of the abdomen: abdominoscopy. A preliminary study, including a summary of the literature and a description of the technique. *Surg Gynec* 1925; 41:259.
19. Orndoff R. The peritoneoscope in diagnosis of diseases of the abdomen. *J Radiol* 1920; 1:307.
20. Stone Z. Intra-abdominal examination with the aid of the peritoneoscope. *J Kans Med Soc* 1924; 24:63.
21. Zollikofer R. Zur laparoskopie. *Schweiz Med Wschr* 1924; 54(264).
22. Goetze O. Die rontgendiagnostik bei gasgefüllter bauchhöhle; eine neue methode. *Med Wschr* 1918; 65:1275.
23. Veress J. Neues Instrument zue Auführung von Brust Oder Bauchpunktionen. *Dt Med Wschr* 1938; 41:1480–1481.
24. Kalk H. Erfahrungen mit der laparoskopie (Zugleich mit beschreibung eines neuen instrumentes). *Z Klin Med* 1929; 111:303.
25. Kalk H. Laparoskopie (Die besichtigung der bauchhöhle am lebenden Menschen). *Ges Krankenh* 1935; 5:97.
26. Kalk HB., W; and Sieke, E. Die gezielte leberpunktion. *Dtsch Medl Wschr* 1943; 69:693.
27. Saleh, J.I.a.I.I.L. Laparoscopy: Indications and Limitations. Philadelphia: W.B. Saunders, 1988:1.
28. Caroli J. La Laparophotographie en couleurs par l'endographe de Foures. *Rev Int Med* 1955; 5:951.
29. Fervers C. Die Laparoskopie mit dem Cystoskop. Ein Beitrag zur Vereinfachung der Technik und zur Endoskopischen Strangdurchtrennung in der Bauchhöhle. *Med Klin* 1933; 29:1042.
30. Ruddock, J.A.a.e.o.p.C.M. Application and evaluation of peritoneoscopy. *Calif Med* 71:110.
31. Ruddock J. Peritoneoscopy. *Surg.*, 1939; 8:113.
32. Ruddock J. Peritoneoscopy. *Surg Gynec Obstet* 1937; 65:637.
33. Ruddock J. Peritoneoscopy. *West J Surg* 1934; 42:392.
34. Ruddock J. Pertoneoscopy: a critical review. *Surg Clin North Am* 1957; 37:1249–1260.
35. Semm K. In: Sanfilippo JS, Levine RL, eds. *Operative Gynecologic Endoscopy: History*. New York: Springer-Verlag, 1989.
36. Anderson E. Peritoneoscopy. *Am J Surg* 1937; 35:136–139.
37. Power FB, AC. Sterilization by means of peritoneoscopic tubal fulguration. *Am J Obstet Gynec* 1941; 41:1038.
38. Donaldson J.S., JH; Harrell, WB, Jr. A method of suspending the uterus without open abdominal incision. *Am J Surg* 1942; 55:537.
39. Decker A. Culdoscopy: its diagnostic value in pelvic disease. *JAMA* 1949; 140:378.
40. Decker A.C., T. Culdoscopy: a new method in diagnosis of pelvic disease. *Am J Surg* 1944; 64:40.
41. Decker A. Culdoscopy. *Am J Obstet Gynec* 1952; 63:654.
42. Palmer, R.L.C.B.-m. La Coelioscopie. *Brux.-med* 1948; 28:305.
43. Steptoe P. Laparoscopy in Gynaecology. Edinburgh: E&S Livingston Ltd, 1967.

44. Fourestier M, Gladu A, Vulmiere J. Perfectionnements a l'endoscopie medicale. Realization bronchoscopique. *Presse Med* 1952; 60:1292.
45. Gaskin TI, Isobe JH, Mathews JL, Winchester SB, Smith RJ. Laparoscopy and the general surgeon. *Surg Clin North Am* 1991; 71(5):1085-1097.
46. Hasson H. Open laparoscopy: a report of 150 cases. *J Reprod Med* 1974; 12:234-238.
47. Cohen M. Historical background. *Laparoscopy, Culdoscopy and Gynecography*. Philadelphia: WB Saunders, 1970:6.
48. Gunning J. The history of laparoscopy. In: Phillips JM, ed. *Laparoscopy*. Baltimore: William & Wilkins Co, 1977.
49. Semm K. Change in the classic gynecologic surgery: review of 3,300 pelviscopies in 1971-1976. *Int J Fertil* 1979; 24(1):13-20.
50. Semm K. Endoscopic appendectomy. *Endoscopy* 1983(Mar); 15(2):59-64.
51. Semm K. New methods of pelviscopy (gynecologic laparoscopy) for myomectomy, ovariectomy, tubectomy and adnectomy. *Endoscopy* 1979; 11(2):85-93.
52. Semm, K.T. Tissue puncher and loop ligation new aids for surgical therapeutic pelviscopy (laparoscopy)—endoscopic intraabdominal surgery. *Endoscopy* 1978(May); 10(2):119-124.
53. Semm KML. Technical progress in pelvic surgery via operative laparoscopy. *Am J Obstet Gynecol* 1980(Sep 15); 139(2):121-127.
54. Hasson H. A modified instrument and method for laparoscopy. *Am J Obstet Gynecol* 1971; 110:886.
55. Reddick EJ, Olsen DO. Laparoscopic laser cholecystectomy: a comparison with minilaparoscopic cholecystectomy. *Surg Endosc* 1989; 3:131.
56. Dubois F, Icard P, Bertholet G, et al. Coelioscopic cholecystectomy: preliminary report of thirty-six cases. *Ann Surg* 1990; 211:60.
57. Cortesi NF, Ferrari P, Zambarda E, et al. Diagnosis of bilateral abdominal cryptorchidism by laparoscopy. *Endoscopy* 1976; 8:33-34.
58. Das SA, Amar AD. The impact of laparoscopy on modern practice. *Urol Clin North Am* 1988; 15(3):537-540.
59. Duckett J. Laparoscopy for cryptorchidism. *Dialogues. Pediatr Urol* 1988; 11(7):6.
60. Elder J. Laparoscopy and Fowler-Stephens orchiopexy in the management of the impalpable testis. *Urol Clin North Am* 1989; 16(2):399-401.
61. Weiss RS, Seashore JH. Laparoscopy in the management of the nonpalpable testis. *J Urol* 1987; 138:382-384.
62. Wickham J. The surgical treatment of renal lithiasis. *Urinary Calculus Disease*. New York: Churchill Livingstone, 1979:145-198.
63. Eshghi AR, Roth JS, Smith AD. Percutaneous transperitoneal approach to a pelvic kidney for endourological removal of staghorn calculus. *J Urol* 1985; 134:525-527.
64. Griffith DS, Schuessler WW, Nickell KG, Meaney JT. Laparoscopic pelvic lymphadenectomy for prostatic adenocarcinoma. *Urol Clin N Am* 1992; 19(2):407-415.
65. Winfield, H.R., KJ. Laparoscopy—new urological applications. Presented at the American Urological Association 84th Annual Meeting, May 7, 1989.
66. Janetschek G, et al. Laparoscopic retroperitoneal lymph node dissection. *Urology* 2000; 55(1):136-140.
67. Bhayani SB, Allaf ME, Kavoussi LR. Laparoscopic retroperitoneal lymph node dissection for clinical stage I nonseminomatous germ cell testicular cancer: current status. *Urol Oncol* 2004; 22(2):145-148.
68. Weinberg JS, Smith AD. Percutaneous resection of the kidney: preliminary report. *J Endourol* 1988; 2:355.
69. Clayman RV, Kavoussi LR. Laparoscopic Procedures: Nephrectomy: Technique and Results. Presented at The Society for Minimally Invasive Therapy Third International Meeting, Nov 12, 1991.
70. Clayman RV, Kavoussi LR, Soper NJ, et al. Laparoscopic nephrectomy: initial case report. *J Urol* 1991(Aug); 146(2):278-282.
71. Copcoat, M.J., A; Rassweiler, J; Popert R, Laparoscopic Nephrectomy: The Kings clinical experience. presented at the American Urological Association 87th Annual Meeting, May 13, 1992.
72. Gaur RS, Ravandale AV, Gopichand M. A single-centre experience of retroperitoneoscopy using the balloon technique. *BJU Int* 2001(May); 87(7):602-606.
73. Gill IS, Ccarbone JM, Clayman RV, et al. Laparoscopic live-donor nephrectomy. *J Endourol* 1994(Apr); 8(2):143-148.
74. Ratner LE, Ciseck L, Moore RG, Cigarroa FG, Kaufman HS, Kavoussi LR. Laparoscopic live donor nephrectomy. *Transplantation*. 1995(Nov 15); 60(9):1047-1049.
75. Guillonnet B, Vallencien G. Laparoscopic radical prostatectomy: the Montsouris technique. *J Urol* 2000; 163:1643-1649.
76. Abbou CC, Salomon L, Hoznek A, et al. Laparoscopic radical prostatectomy: preliminary results. *Urology* 2000; 55:630-633.
77. Gill IS, Fergany A, Klein EA, et al. Laparoscopic radical cystoprostatectomy with ileal conduit performed completely intracorporeally: the initial 2 cases. *Urology* 2000(Jul); 56(1):26-29.

Dinesh Singh

Section of Laparoscopic and Robotic Surgery, Glickman Urological Institute, Cleveland Clinic Foundation, Cleveland, Ohio, U.S.A.

- | | |
|-----------------|-----------------------|
| ■ INTRODUCTION | ■ CAVEAT |
| ■ RIGHT KIDNEY | ■ RIGHT ADRENAL GLAND |
| Transperitoneal | Transperitoneal |
| ■ CAVEAT | Retroperitoneal |
| Retroperitoneal | ■ CAVEAT |
| ■ CAVEAT | ■ LEFT ADRENAL GLAND |
| ■ LEFT KIDNEY | Transperitoneal |
| Transperitoneal | ■ CAVEAT |
| ■ CAVEAT | Retroperitoneal |
| Retroperitoneal | ■ CAVEAT |

Because every urologist has studied gross anatomy and basic surgical abdominal anatomy during general surgery and urology training, this chapter details urologic laparoscopic abdominal anatomy.

INTRODUCTION

A clear and confident understanding of surgical anatomy and anatomic interrelationships is a prerequisite for performing laparoscopic surgery. The surgeon must understand the anatomy of the operated organ and its relationships with surrounding structures and what potential pitfalls exist.

Because every urologist has studied gross anatomy and basic surgical abdominal anatomy during general surgery and urology training, this chapter details urologic laparoscopic abdominal anatomy.

These topics will be reviewed in the following order: organ (kidney, adrenal), type of approach (transperitoneal vs. retroperitoneal), and anatomical caveats.

RIGHT KIDNEY

Transperitoneal

The right kidney, when viewed in the transperitoneal approach, lies posterior to the ascending colon, inferior to the liver, and anterior to the psoas muscle.

The first step in any approach to the right kidney is mobilizing the ascending colon off Gerota's fascia.

Laparoscopically, the defined layer of Gerota's fascia is clearly separate and evident from the mesenteric fat of the left mesocolon. The lateral border of the second portion of the duodenum may be attached to Gerota's fascia. When the duodenum is released from Gerota's fascia sharply (avoiding cautery so as to avoid thermal injury to the duodenum), the inferior vena cava comes into view. The gonadal vein and ureter lie directly on the psoas muscle. The gonadal vein is encountered more medially and posteriorly than the ureter in most cases. One must also beware that a relatively common venous abnormality is for the right gonadal vein to drain into the right renal vein, rather than the more usual inferior vena cava.

The renal vein is seen anterior to the pulsations of the renal artery.

With the 30 degree laparoscope rotated to the 9 o'clock position, the posterior relationship of the renal artery to the renal vein is well appreciated.

One must remember that the gonadal vein can insert into the right renal vein, though its typical insertion is to the inferior vena cava. This is important as one may confuse the renal vein for the inferior vena cava.

The first step in any approach to the right kidney is mobilizing the ascending colon off Gerota's fascia.

One must remember that the gonadal vein can insert into the right renal vein, though its typical insertion is to the inferior vena cava. This is important as one may confuse the renal vein for the inferior vena cava.

Anomalous accessory renal arteries and the often accompanying accessory renal vein are present in approximately 20% of patients.

After the surgeon obtains proper retroperitoneal access, the psoas muscle becomes the horizontal floor of the surgeon's view. This horizontal orientation must be maintained at all times.

The renal vein cannot be fully visualized until the renal artery is completely dissected.

The left kidney lies behind the descending colon, anterior to the psoas and caudal to the spleen.

The anatomic relationship of the superior mesenteric artery and the left renal vein is occasionally appreciated during left-sided transperitoneal laparoscopic donor nephrectomy in which left renal vein length is maximized by ligation at the interaortocaval region.

CAVEAT

When dealing with a large, hydronephrotic pelvis, it may be best to dissect the colon and duodenum away from the pelvis prior to draining the pelvis, because the hydronephrosis serves as a good backboard to complete the dissection. It is advisable to have a preoperative three-dimensional computed tomography scan in order to appreciate, among other things, anomalous vasculature. This recognition will help avoid iatrogenic injury. Accessory renal blood vessels may or may not lie in a slightly more anterior plane than the main renal vessels and are end arteries without collateral supply. Anomalous accessory renal arteries and the often accompanying accessory renal vein are present in approximately 20% of patients.

Retroperitoneal

After the surgeon obtains proper retroperitoneal access, the psoas muscle becomes the horizontal floor of the surgeon's view. This horizontal orientation must be maintained at all times.

In order to see the bulk of the kidney and to get adequate anterior traction on the kidney, one must recognize the bands that attach Gerota's fascia to the psoas fascia. These bands must initially be incised sharply, followed by blunt dissection in order to get separation of the kidney and its investing Gerota's fascia from the fascia of the psoas muscle. The main renal blood vessels are encountered at a view such that the laparoscope is at a 45 degree angle with the body's horizon. Here the pulsations of the renal artery can be detected. Because this is the retroperitoneal approach, the renal artery is seen prior to the renal vein. The renal vein cannot be fully visualized until the renal artery is completely dissected.

After the renal artery is clipped and divided, the renal vein is seen more medially and superiorly. In this perspective, the ureter is seen just anterior to (above) the inferior vena cava. The gonadal vein is seen further anterior to the ureter. The kidney and investing Gerota's fascia can be dissected sharply from the peritoneum by incising the thin, bloodless areolar tissue between the two.

CAVEAT

One must identify the gently undulating venous pulsations of the inferior vena cava early in the operation. If this is not appreciated, one can inadvertently dissect posterior to the inferior vena cava in a retrocaval fashion. Additionally, there have been reports of inadvertent transection of the inferior vena cava via the retroperitoneal approach (inferior vena cava transection in the transperitoneal approach has also occurred). The sentinel points for avoiding this complication are three-fold: (i) identify the cranial and caudal right angle junction of the right renal vein to the inferior vena cava; (ii) ensure the horizon of the camera is properly oriented by seeing the psoas running horizontally; (iii) visualize the renal vein coursing toward the kidney (toward the top of the television monitor).

LEFT KIDNEY

Transperitoneal

The left kidney lies behind the descending colon, anterior to the psoas and caudal to the spleen.

The spleen lies directly adjacent to the superior pole of the kidney and should be mobilized away from the kidney early on in the dissection to avoid splenic injury. The renal vein is seen lying anterior to the renal artery. Although not commonly seen in most laparoscopic cases, the superior mesenteric artery, which courses directly anterior of the medial-most portion of the left renal vein, must always be kept in mind. The anatomic relationship of the superior mesenteric artery and the left renal vein is occasionally appreciated during left-sided transperitoneal laparoscopic donor nephrectomy in which left renal vein length is maximized by ligation at the interaortocaval region.

The left gonadal vein drains into the left renal vein. The adrenal vein junction with the left renal vein is almost always medial to the gonadal vein insertion. A lumbar vein is frequently encountered on the posterior aspect of the left renal vein, which is far less

The lumbar vein is best seen with gentle anterior traction on a clipped and ligated left gonadal vein.

common on the right renal vein. The lumbar vein location relative to the gonadal vein is more variable.

The lumbar vein is best seen with gentle anterior traction on a clipped and ligated left gonadal vein.

CAVEAT

It is a good idea to have a nasogastric tube placed to keep the stomach decompressed. Although uncommon, the body of the stomach at times can lie just cranial to the upper pole of the left kidney. As stated above, the lumbar vein runs directly posterior from the posterior surface of the left renal vein. When specific identification of this vein is required, as during a laparoscopic donor nephrectomy, it is good to place a Weck clip on the gonadal vein, leaving approximately a 2 cm stump attached to the renal vein. This can serve as a handle to obtain anterior traction on the renal vein, revealing the posterior lumbar vein (and potentially its branches).

Retroperitoneal

The retroperitoneal approach to the left kidney differs from the right in several critical aspects. First the aorta, rather than the inferior vena cava, is the horizontally running major vessel. Its sharp, horizontal pulsations are easily appreciated when the kidney is lifted anteriorly away from the psoas muscle. Although the renal artery pulsations are again seen when the laparoscope is at a 45 degree angle to the body, in the retroperitoneal view, the surgeon sees the renal artery lying superior (to the right on the screen) and slightly posterior to the renal vein. On the left side, the renal vein and artery can be seen at the same time running parallel to one another. As described above, this is not the case on the right side. Additionally the level at which the renal vein is ligated and transected is more lateral (toward the kidney parenchyma) than when the renal vein is transected on the right side. As a result, the adrenal vein usually enters the renal vein medial to the ligated renal vein. This has consequences when performing an adrenalectomy with the nephrectomy (see Left Adrenal Gland: Retroperitoneal below for details).

CAVEAT

At times a lumbar vein will be seen in the retroperitoneal approach. This should be ligated after the renal artery is controlled. When the lumbar vein is adequately controlled, the renal vein releases, facilitating further renal vein dissection.

Although it is rare and difficult to visualize the superior mesenteric artery via the retroperitoneal approach, the surgeon must be ever mindful of its anatomical location to ensure its safety.

Although it is rare and difficult to visualize the superior mesenteric artery via the retroperitoneal approach, the surgeon must be ever mindful of its anatomical location to ensure its safety.

The superior mesenteric artery runs anterior to the aorta and medial to the renal artery. Therefore one should not dissect medial to the renal artery and vein, so as to avoid entering the superior mesenteric artery territory. Medial attachments of the kidney to the aorta or posterior peritoneum should be approached from an anterior and lateral approach (over the kidney rather than under the kidney). This enables the surgeon to appreciate the attachments that run exclusively to the kidney, thereby avoiding the superior mesenteric artery. The same principle holds true for left adrenal gland dissection as described below.

RIGHT ADRENAL GLAND

Transperitoneal

The right adrenal gland lies cranial and slightly medial to the superior pole of the kidney. The medial portion of the adrenal gland abuts the inferior vena cava, and at times a significant portion of its parenchyma can be located retrocaval (posterior to the inferior vena cava).

Superiorly, the adrenal gland abuts the under surface of the liver. Laterally, the adrenal gland is bounded by the most inferior portions of the diaphragm and the lateral abdominal wall. Posteriorly, the adrenal gland lies atop the psoas muscle.

It receives collateral blood supply from small arterial perforating vessels originating from the inferior phrenic artery, the aorta, and the right renal artery. Specific and identifiable arteries to the adrenal gland are usually not appreciated.

The medial portion of the adrenal gland abuts the inferior vena cava, and at times a significant portion of its parenchyma can be located retrocaval (posterior to the inferior vena cava).

Controlling the adrenal vein before any mobilization is preferable. If the vein tears, it will avulse at its junction to the inferior vena cava, which can lead to significant and difficult-to-control bleeding.

The inferior vena cava acts as the “highway” to the adrenal vein, which is usually seen in the retroperitoneal approach to be coursing anterior-medially when anterior traction is put on the adrenal gland.

When mobilizing the adrenal gland, it is beneficial to delay freeing the caudal attachments of the adrenal gland to the kidney to be the last step of mobilization, reason being that once Gerota’s fascia is entered, a significant amount of unwieldy perirenal fat narrows the surgeon’s field of view.

Unlike the right adrenal gland, the left adrenal gland lies in a more medial position with respect to the upper pole of the right kidney.

There is not a retroaortic portion of the left adrenal gland as there often is a retrocaval portion of the gland on the right side.

There is a single, short adrenal vein that drains directly into the inferior vena cava. The adrenal vein originates from the superior, medial aspect of the adrenal gland. This vein cannot be seen without significant cranial mobilization of the liver.

Controlling the adrenal vein before any mobilization is preferable. If the vein tears, it will avulse at its junction to the inferior vena cava, which can lead to significant and difficult-to-control bleeding.

Retroperitoneal

This is the author’s preferred approach to most operations of the right adrenal gland. Three major anatomically related advantages that enable rapid and safe right retroperitoneoscopic adrenal surgery are: (i) no requirement for bowel and liver mobilization; (ii) rapid identification and control of the adrenal vein; (iii) direct access to any retrocaval portion of the adrenal gland to ensure complete resection in case of cancer surgery.

As is the case for all surgery, one must have a clear understanding of the retroperitoneal anatomy and the relation of the right adrenal gland to surrounding structures. The right adrenal vein is best approached by first noting the location of the right kidney hilum. This is performed as described above. If one then dissects immediately superior to the right renal vein and dissects directly along the inferior vena cava in a cranial direction, the adrenal vein will come into view. The inferior vena cava acts as the “highway” to the adrenal vein, which is usually seen in the retroperitoneal approach to be coursing anterior-medially when anterior traction is put on the adrenal gland.

Of course, the direction in which the adrenal vein is seen is entirely dependent on the vector of traction the surgeon puts on the adrenal gland itself. As is the case for the renal vein, the cranial and caudal junctions of the adrenal vein to the inferior vena cava must be seen before ligating the adrenal vein. If one dissects too far cranially on the inferior vena cava, superior to the adrenal vein, the hepatic veins will be encountered.

The adrenal gland is then mobilized by freeing it from its cranial attachments to the peritoneum and diaphragm. Next the adrenal gland is typically mobilized by freeing it of its anterior attachments to the peritoneum which is typically a bloodless, areolar tissue. Finally, the last attachments of the adrenal gland to the kidney are freed by entering Gerota’s fascia and baring the superior pole of the right kidney.

CAVEAT

One must be aware that when the adrenal gland is on traction before ligating and transecting the adrenal vein, the inferior vena cava may be kinked and not course in the expected direction cranial to the adrenal vein. One must also be aware of the fact that if overzealous dissection is carried out too cranially along the inferior vena cava, one may approach the hepatic veins.

When mobilizing the adrenal gland, it is beneficial to delay freeing the caudal attachments of the adrenal gland to the kidney to be the last step of mobilization, reason being that once Gerota’s fascia is entered, a significant amount of unwieldy perirenal fat narrows the surgeon’s field of view.

LEFT ADRENAL GLAND

Transperitoneal

The left adrenal gland, similar to the right adrenal gland, lies cranial to the upper pole of the right kidney. Unlike the right adrenal gland, the left adrenal gland lies in a more medial position with respect to the upper pole of the right kidney.

Medially, just as the right adrenal gland lies contiguous with the inferior vena cava, the left adrenal gland lies in close proximity to the left, lateral boarder of the aorta. There is typically more clearance between the aorta and the left adrenal gland than there is between the inferior vena cava and the right adrenal gland. There is not a retroaortic portion of the left adrenal gland as there often is a retrocaval portion of the gland on the right side.

Superiorly, the adrenal gland abuts the under surface of the spleen. Laterally, the adrenal gland is bounded by the most inferior portions of the diaphragm and the lateral abdominal wall. Posteriorly, the adrenal gland lies atop the psoas muscle.

Unlike the right adrenal vein, the left adrenal vein drains into the left renal vein.

The blood supply to the left adrenal gland is similar to the right side: branches of the inferior phrenic artery, the left renal artery, and perforating branches of the aorta. Again, these named arteries are rarely appreciated. Unlike the right adrenal vein, the left adrenal vein drains into the left renal vein.

The adrenal vein drains into the renal vein in a more medial position relative to the gonadal and lumbar vein. The adrenal vein is visualized by partially skeletonizing the renal vein. When this medial dissection of the renal vein is carried out, the insertion of the adrenal vein will be seen on the cranial margin of the renal vein.

CAVEAT

The antero-medial adrenal gland lies very close to the tail of the pancreas. If this relation is not understood and if there is a prominent tail of the pancreas, it is easy to confuse the initial dissection of the adrenal gland with the tail of the pancreas.

Retroperitoneal

The anatomical relation of the adrenal gland to surrounding structures is the same as described via the transperitoneal approach. However, the approach to the adrenal vein is quite different. Unlike the transperitoneal approach, the left renal vein need not be dissected at all. Rather the adrenal vein is seen just cranial (to the right on the television monitor) to the pulsations of the left renal artery. Furthermore, it courses approximately 0.5 to 1 cm anterior and parallel to the horizon of the anterior psoas muscle.

The mobilization of the adrenal gland is similar to that described for the right retroperitoneal approach. Specifically the gland is freed of its cranial attachments to the peritoneum underlying the spleen, then the anterior-medial attachments to the peritoneum, and lastly, cranially from the superior surface of the bared kidney.

CAVEAT

When dissecting the postero-medial attachments of the adrenal gland, it is advisable to exert lateral traction (toward the surgeon) on the adrenal gland so that just the attachments connected to the adrenal gland are divided. This step further minimizes the chances of injury to the superior mesenteric artery.

LAPAROSCOPIC ANATOMY OF THE MALE PELVIS

Bertrand Guillonnet, Karim A. Touijer, and Jeffery W. Saranchuk

Department of Urology, Sidney Kimmel Center for Prostate and Urologic Cancers, Memorial Sloan-Kettering Cancer Center, New York, New York, U.S.A.

<ul style="list-style-type: none"> ■ INTRODUCTION ■ INTRA-ABDOMINAL ANATOMY OF THE PELVIS <ul style="list-style-type: none"> The Bladder The Medial Umbilical Ligament The Lateral Umbilical Ligament The Spermatic Cord The Iliac Vessels The Ureter The Seminal Complex The Rectum and Sigmoid Colon ■ THE RETROPUBIC SPACE <ul style="list-style-type: none"> The Pubis The Obturator Muscles 	<ul style="list-style-type: none"> The Bladder The Endopelvic Fascia The Santorini's Plexus ■ PROSTATIC FASCIA AND PROSTATIC PEDICLES <ul style="list-style-type: none"> The Visceral Fascia The Denonvilliers' Fascia Rectourethralis Muscle The Prostatic Neurovascular Plexuses ■ SPHINCTERIC COMPLEX <ul style="list-style-type: none"> The Rhabdomyosphincter ■ CONCLUSION ■ REFERENCES
---	--

INTRODUCTION

Anatomy is the key element to surgery. This is true for open or laparoscopic approach. Clear knowledge of anatomy is the “primum movens” of good surgical technique. In laparoscopy, the anatomical perspective of the surgical field is somewhat different from the one usually seen during open surgery. The magnification and the ease of access to the depths of the male pelvis bring into view anatomical details not fully described in currently available anatomy textbooks. To adapt and revise the anatomy incorporating this different perspective is thus a prerequisite to the realization of safe and efficient laparoscopic surgery. Furthermore, tactile feeling is somewhat diminished in laparoscopy and vision remains the primary fully available sense. Mastery of laparoscopic topographic anatomy is thus indispensable for visually identifying various structures and recognizing their spatial relationships with each other.

In this chapter we attempt to summarize our understanding of male pelvic anatomy from a laparoscopic standpoint.

INTRA-ABDOMINAL ANATOMY OF THE PELVIS

Upon entering the abdomen and visualizing the intra-abdominal pelvis, several structures are identifiable: the bladder and the median umbilical ligament in the mid-line, the medial and lateral umbilical ligament, and the spermatic vessels entering the deep inguinal ring more laterally (Fig. 1).

The Bladder

The bladder dome is median. It constitutes the mobile portion of the bladder, whose relationships change according to its state of distension. However, because a Foley catheter is routinely inserted into the bladder prior to creation of pneumoperitoneum, the bladder is empty and its anatomical boundaries are not visible at the inspection. To better delineate its limits, the bladder needs to be distended.

Once filled, the bladder visibly distends posteriorly, reduces the pouch of Douglas (also called rectovesical recess), and expands (i) laterally toward the medial umbilical ligament; (ii) anterosuperiorly underneath the anterior abdominal wall; and (iii) toward the umbilicus to which it is attached through the urachus.

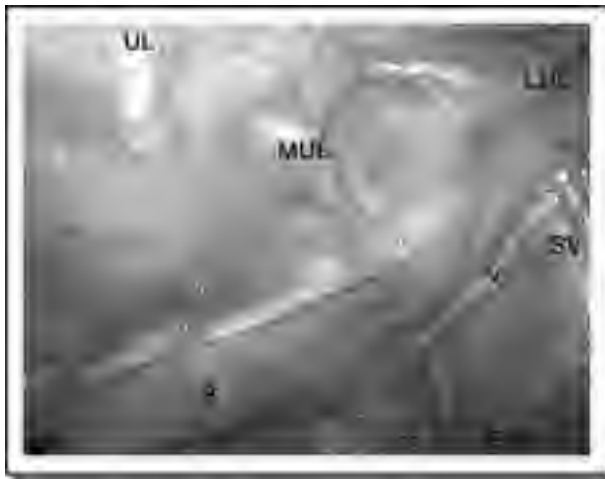


FIGURE 1 ■ The umbilical ligaments. Transperitoneal view of the right half of the pelvis. Ureter (asterisk). Abbreviations: UL, umbilical ligament; MUL, medial umbilical ligament; LUL, lateral umbilical ligament; B, bladder; V, vas deferens; SV, spermatic vessels; EIV, external iliac vein.

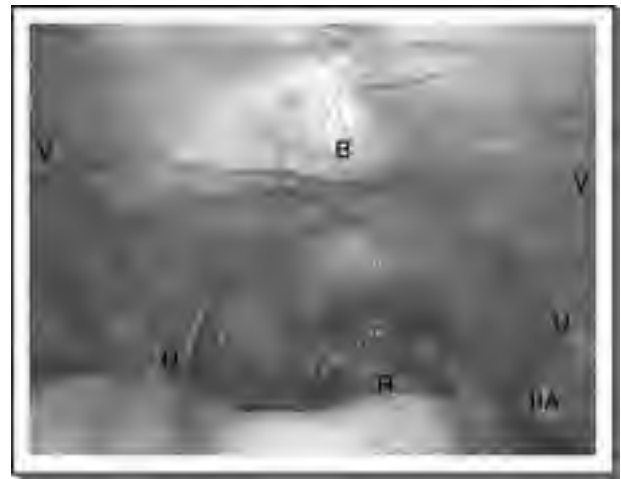


FIGURE 2 ■ The pouch of Douglas. Abbreviations: B, bladder; V, vas deferens; U, ureter; IIA, internal iliac artery.

The vesicular complex usually lies about 2 cm above the pouch of Douglas.

The urachus (median umbilical ligament) is visible along the anterior parietal peritoneum. It consists of a cord often accompanied by vessels that must be controlled when dividing the urachus. On either side, laterally, the median umbilical ligament is separated from the medial umbilical ligament by a peritoneal recess. The latter allows access to the vesical space (space of Retzius).

The pouch of Douglas (Fig. 2) appears as a cul-de-sac between the bladder anteriorly and the rectum posteriorly. Its depth varies among patients. Although in thin males the outline of the seminal vesicles and the distal portions of the vasa deferentia may be clearly visible through the visceral peritoneum covering the bladder posteriorly, most often the exact location of the vesicular complex is not visible. The vesicular complex usually lies about 2 cm above the pouch of Douglas.

The Medial Umbilical Ligament

The medial umbilical ligaments, the continuation of the obliterated hypogastric artery, are particularly easy to visualize in laparoscopy and represent an important anatomical landmark. The prominence of the medial umbilical ligament varies according to the amount of surrounding adipose tissue. The ligaments consist of an anteriorly tented cord between the umbilicus (superiorly) and the distal portion of the superior vesical artery branch of the internal iliac artery. At this anatomic location the hypogastric artery within the medial umbilical ligament is almost always completely obliterated, and does not bleed.

The medial umbilical ligament can be used as a guide to approach the pelvic ureter because at this level, the superior vesical artery crosses the ureter medially.

Laterally, the medial umbilical ligament is separated from the lateral umbilical ligament (fold of peritoneum covering the inferior epigastric artery) by the medial umbilical fossa.

The umbilical fossa is divided in a superior and inferior portion by the vas deferens, providing access to the obturator fossa.

The Lateral Umbilical Ligament

The lateral umbilical ligament can be used as a guide to approach the external iliac vessels.

This ligament is the least pronounced of the three umbilical ligaments but its visualization is important for the insertion of the lower abdominal quadrant trocars. This ligament represents the peritoneal fold covering the inferior epigastric vessels. The inferior epigastric artery, a medial branch of the distal external iliac artery, ascends along the medial margin of the deep inguinal ring, continues between the rectus abdominis muscle and the posterior lamina of its sheath, and then raises the anterior parietal peritoneum creating the lateral umbilical ligament, which is crossed at its origin by the vas deferens superiorly.

The medial umbilical ligament can be used as a guide to approach the pelvic ureter because at this level, the superior vesical artery crosses the ureter medially.

The umbilical fossa is divided in a superior and inferior portion by the vas deferens, providing access to the obturator fossa.

The lateral umbilical ligament can be used as a guide to approach the external iliac vessels.

The vas deferens and the medial umbilical ligament are major landmarks for pelvic lymph node dissection.

The genitofemoral nerve lies lateral to the external iliac artery. It can be used for nerve grafting after neurovascular bundle resection during radical prostatectomy.

Dissection at the confluence of the internal and external vessels gives access to the superior vesical artery.

The obturator fossa, a triangular area formed by the pubic rami with the obturator muscle, and the internal and external iliac vein as its sides, comprises an important lymphatic drainage zone for the prostate and the bladder, and represents the area to be dissected during pelvic lymphadenectomy.

Transverse incision of the peritoneal fold about 2 cm above the base of the pouch of Douglas allows access to the seminal complex, and further distally to the Denonvilliers' fascia.

The Spermatic Cord

The convergence of the spermatic vessels—spermatic artery and veins—and the vas deferens with its proper vessels forms the spermatic cord. The spermatic vessels course over the psoas-iliac muscle and are joined by the vas deferens before entering the deep inguinal ring.

The vas deferens, rarely visible behind the prostate even at its posterolateral aspect, becomes more superficial and visible laterally, covered with the parietal peritoneum where it crosses the external iliac vessels.

The vas deferens and the medial umbilical ligament are major landmarks for pelvic lymph node dissection.

In fact, a vertical incision of the parietal peritoneal fold across the vas deferens, in the medial umbilical fossa, leads to the external iliac vessels, with the artery located anterolaterally and superficially and the vein located posteromedially and more deeply.

The Iliac Vessels

Pulsations of the external iliac artery are usually seen through the overlying parietal peritoneum fold, at the level where the vas deferens joins the spermatic vessels.

The genitofemoral nerve lies lateral to the external iliac artery. It can be used for nerve grafting after neurovascular bundle resection during radical prostatectomy.

The external iliac vein, located medial to the external iliac artery, can be masked by a tortuous iliac artery. Furthermore, visualization of the vein may be impaired by the high-pressure pneumoperitoneum. In this situation, a reduction of the intra-abdominal pressure (5 mmHg) typically decompresses the iliac vein, bringing its gentle undulating pulsations into clear view.

To expose the external iliac vein, the parietal peritoneum directly overlying its medial aspect must be incised along the length of the vein. During such dissection, the surgeon should be aware of the presence of two medial venous branches. The first one, located proximally, or upstream, is the inconstant accessory circumflex vein, which reaches the external iliac vein just below the inferior aspect of the superior pubic ramus. The second branch, more distal, or downstream, is the internal iliac or hypogastric vein that runs in a posteroanterior orientation.

Dissection at the confluence of the internal and external vessels gives access to the superior vesical artery.

It should be noted that the left external iliac vessels are generally located somewhat more posteriorly, deeper in the pelvic cavity, as compared to the right external iliac vessels. As such, a laparoscopic left pelvic lymph node dissection may be technically somewhat more difficult.

The obturator nerve is located posteromedially to the external iliac vein. It appears as a white, shining, striated cord, usually flattened, entering the obturator fossa at the level of the convergence of the internal and external iliac veins, somewhat closer to the internal iliac vein. The obturator nerve enters the obturator canal at its superolateral edge. The nerve is accompanied by the obturator artery (branch of the internal iliac artery), and usually an obturator vein, which typically lies posterior to the nerve.

The obturator fossa, a triangular area formed by the pubic rami with the obturator muscle as its base, and the internal and external iliac vein as its sides, comprises an important lymphatic drainage zone for the prostate and the bladder, and represents the area to be dissected during pelvic lymphadenectomy.

The Ureter

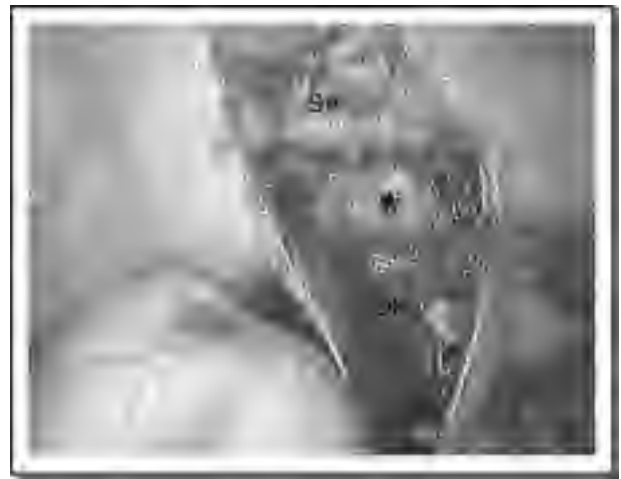
The ureter crosses anteriorly over the common iliac vessels and can be readily identified at this level. The left ureter, covered by the parietal peritoneum and the pelvic mesocolon, remains medial to the internal iliac artery and crosses medially across the proximal part of the superior vesical artery before entering the bladder. Near its entrance in the detrusor, the ureter is also in the vicinity of the lateral aspect of the seminal vesicle, near the inferior hypogastric plexus (see The Seminal Complex).

The Seminal Complex

The distal portion of the two vasa deferentia, the ampullas, and the two seminal vesicles compose the seminal complex. This complex is rarely visible through the visceral peritoneal fold of the anterior aspect of the pouch of Douglas.

Transverse incision of the peritoneal fold about 2cm above the base of the pouch of Douglas allows access to the seminal complex, and further distally to the Denonvilliers' fascia (see The Denonvilliers' Fascia) (Fig. 3).

FIGURE 3 ■ Transperitoneal view of the Denonvilliers' fascia after its opening through an incision of the anterior peritoneal fold of the pouch of Douglas. Anterior of the rectum recovered by fatty layer (asterisk). *Abbreviations:* SV, seminal vesicle; DF, Denonvilliers' fascia.



Transverse incision of the Denonvilliers' fascia exposes the seminal complex, where the vasa deferentia are identified laterally and ventrally. Anterior to each vas runs a deferential artery.

The superior portion of the Denonvilliers' fascia appears as a vertically striated tissue, covering the seminal complex posteriorly. Its dissection leads to the prerectal space with the adipose tissue on its proximal aspect.

Transverse incision of the Denonvilliers' fascia exposes the seminal complex, where the vasa deferentia are identified laterally and ventrally. Anterior to each vas runs a deferential artery.

The seminal vesicles, whose size varies physiologically, lie posteriorly, inferiorly, and laterally to the vas. The posterior aspect of the seminal vesicle is easy to dissect from the prostatorectal fascia. The anterior aspect of the tip of the seminal vesicle is traversed by the seminal vesicular artery, often a sizable blood vessel, which is a branch of the superior vesical artery. The lateral aspect and tip of the seminal vesicle is in close relationship with the inferior hypogastric plexus also known as the pelvic plexus, which carries innervating fibers to the pelvis (1). The inferior hypogastric plexus measures about 40 mm in height, 10 mm in width and 3 mm in thickness, and is molded to the contours of the seminal vesicle as far as the vesiculoprostic junction. The inferior hypogastric plexus receives afferent fibers from the superior hypogastric plexus-or preaortic plexus (sympathic fibers arising from the thoracic region) and from the pelvic splanchnic nerves-or erector nerves, nervi erigentes (parasympathetic preganglionic fibers arising from the sacral plexus S2 to S4). The cavernous nerves emerge at the level of the anteroinferior border of the inferior hypogastric plexus.

The Rectum and Sigmoid Colon

Only the superior half or superior third of the rectum is visible during pelvic laparoscopic surgery.

Trendelenburg positioning of the patient allows upward mobilization of the sigmoid colon by gravity, and access to the pouch of Douglas.

The sigmoid colon is attached by the sigmoid mesocolon to the left lateral aspect of the pelvis, overlying the left external iliac vessels.

Trendelenburg positioning of the patient allows upward mobilization of the sigmoid colon by gravity, and access to the pouch of Douglas.

THE RETROPUBIC SPACE

The retropubic or prevesical space can be approached laparoscopically either transperitoneally or extraperitoneally. The retropubic space has a triangular shape, limited (i) anteriorly by the pubis and the fascia transversalis covering the posterior surface of the anterior abdominal wall; (ii) posteriorly by the bladder through the umbilicoprevesical fascia and the endopelvic fascia; and (iii) laterally by the internal obturator muscles.

The Pubis

The superior ramus of pubis is covered with fascia that thickens laterally, forming Cooper's ligament.

The Obturator Muscles

On each side of the pelvis, the obturator muscle is tented between the ischial spine and the inferior border of the pubic ramus, and is supported inferiorly by the tendinous arch

of the levator ani muscle. The muscle covers the obturator foramen, yielding, laterally and anteriorly, the passage of the obturator pedicle through the obturator canal.

The Bladder

The bladder is covered with a layer of fat that can be dissected easily off the detrusor. Therefore, there are two spaces of dissection that can be developed. The first one is close to the bladder wall, between the detrusor and the layer of perivesical fat. The second, corresponding to the Retzius space, is more anterior, between the layer of perivesical fat and the posterior aponeurosis of the rectus sheath, up to the arcuate line or aponeurosis of Douglas.

Laterally, the bladder is attached to the pelvic cavity through the vesical ligament, which, from top to bottom, carries the superior vesical artery and veins (a branch of which is obliterated and becomes the median umbilical ligament), the distal portion of the ureter, and (inferiorly) the inferior vesical veins and artery.

A branch of the inferior vesical artery joins the prostatic pedicle, gives origin to the prostatic arteries, the vesicular arteries, the deferential arteries, and the arteries running along the cavernous nerves forming the so-called “neurovascular bundle.”

A branch of the inferior vesical artery joins the prostatic pedicle, gives origin to the prostatic arteries, the vesicular arteries, the deferential arteries, and the arteries running along the cavernous nerves forming the so-called “neurovascular bundle.”

The Endopelvic Fascia

The endopelvic fascia is the inferior limit of the Retzius space. It is stretched between the tendinous arches of the levator ani muscle, and covers the anterior aspect of the prostate.

Laterally, the endopelvic fascia presents two recesses—or sulci—situated between the prostate medially and the pelvic muscles laterally.

The lateral recess of the endopelvic fascia constitutes a weak part of the endopelvic fascia that is incised to approach the lateral aspect of the prostate.

The endopelvic fascia recess is particularly weak and thin toward the prostate base, and anteriorly toward the apex where it is fenestrated between lateral expansions of the puboprostatic ligaments.

In some patients, an accessory pudental artery branch of the obturator artery, can be seen on the superior surface of the endopelvic fascia and should be preserved because it may represent the single major source of vascularization to the corpus cavernosum. (2)

The incision of the endopelvic fascia should start proximally, because there is a paucity of blood vessels at that level. This incision uncovers the medial aspect of the levator ani muscle, below the tendinous arch. In some patients, the dissection may be conducted medially up to the parietal fascia of this muscle, but most often the dissection has to be more lateral, leaving the levator ani fascia on the prostate. Inferiorly, this fascia fuses with the lateral aspect of the Denonvilliers’ fascia in the area of the neurovascular bundle.

More laterally and anteriorly, posterior and inferior to the lateral oblique extension of the puboprostatic ligament, veins running from the levator ani muscle to the superolateral aspect of the prostatic apex may be identified. More specifically, it is not unusual to find an artery coming through the fibers of the levator ani muscle and running to the superolateral aspect of the prostatic apex where it turns toward the venous complex after giving a branch(es) to the apex.

Anteriorly, the puboprostatic ligaments are a condensation of the endopelvic fascia attached to the inferior border of the inferior pubic ramus. On each side, the puboprostatic ligament is either single and vertical or multiple with often a lateral oblique extension (Fig. 4). In the sagittal plane, the most medial ligament does not appear as a cord tended between the pubis and the prostatic apex, but more as a fold that is in continuity with the transverse perineal ligament (arcuate pubic ligament). Histologically, it has been shown that the puboprostatic ligaments are detrusor muscle extensions (detrusor apron) that partially cover the anterior surface of the prostate, hence the name pubovesical ligaments (3).

Between the two puboprostatic ligaments emerges the superficial dorsal vein separated from the deep venous complex by a plane easy to develop. Frequently, the superficial dorsal vein runs within the fat covering the anterior layer of the endopelvic fascia and gives multiple branches at the level of the vesicoprostatic junction where it enters the detrusor muscle. In some patients, the deep dorsal vein bifurcates or trifurcates immediately after its entrance into the pelvis. The puboprostatic ligaments are not vascularized and can be cut safely at their most anterior portion.

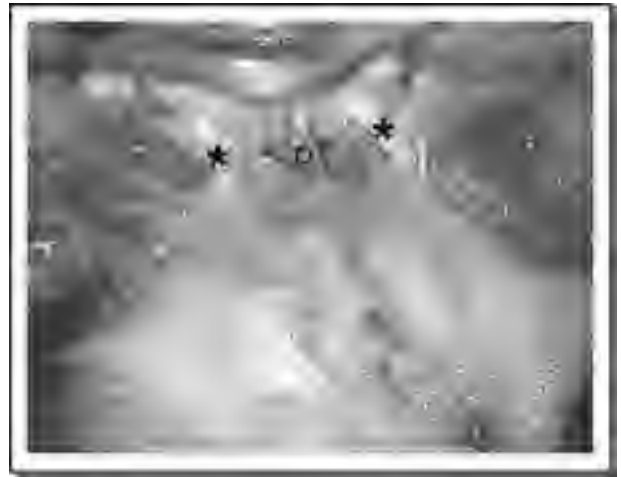
Laterally, the puboprostatic ligament fuses with the extension of the parietal fascia of the levator ani and the visceral prostatic fascia, creating a relatively thick “sphincteric” fascia that covers the lateral aspect of the deep venous complex. More posteriorly, this sphincteric fascia covers the ischioprostatic ligaments—or Müller’s ligaments or

The lateral recess of the endopelvic fascia constitutes a weak part of the endopelvic fascia that is incised to approach the lateral aspect of the prostate.

In some patients, an accessory pudental artery branch of the obturator artery, can be seen on the superior surface of the endopelvic fascia and should be preserved because it may represent the single major source of vascularization to the corpus cavernosum.

The puboprostatic ligaments are not vascularized and can be cut safely at their most anterior portion.

FIGURE 4 ■ The puboprostatic ligaments. View of the Retzius space showing the fat covering the anterior aspect of the endopelvic fascia. Main puboprostatic ligaments (asterisks) and superficial dorsal vein (circle).



Walsh's pillars—which anchor the rhabdomyosphincter and the sphincteric membranous urethra to the bony structures.

Posteriorly, the endopelvic fascia becomes attenuated and merges with the detrusor muscle.

The Santorini's Plexus

The Santorini's plexus is composed of the superficial dorsal vein (described above) and the so-called or deep venous complex (Fig. 5). In fact, this complex is composed of large veins draining the penis, and one or two arteries. It may seem therefore more appropriate to name this complex the "deep vascular complex."

Posteriorly, the deep venous complex is separated from the anterior surface of the urethra by an avascular plane that can be developed easily as it extends cephalad, the deep venous complex branches into a network of veins on the anterior aspect of the prostate. Some branches penetrate the prostatic apron and drain into the prostatic pedicular veins. Others drain directly into the pudendal veins along the neurovascular bundles (4).

PROSTATIC FASCIA AND PROSTATIC PEDICLES

The Visceral Fascia

The visceral fascia covers the external surface of the prostate, bladder, and seminal vesicles.

Along the posterolateral surface of the prostate, the visceral fascia is in continuation with the Denonvilliers' fascia, and its dissection off the prostatic capsule delineates the medial surface of the neurovascular bundle.

An "interfascial" dissection conducted between the prostate capsule and the prostate visceral fascia leaves the neurovascular bundle totally intact and surrounded by its fascia.

With this approach the cavernous nerves, the vessels of the bundle, and the fatty tissue embedding them all are not directly seen. As mentioned, it seems appropriate to name this dissection as the "interfascial" neurovascular bundle dissection, as opposed to the "extrafascial" dissection where the dissection is performed with variable width into the neurovascular bundle itself (5). The term "intrafascial" dissection would imply that the plane of dissection is developed between the prostatic parenchyma and the capsule, an oncologically inappropriate plane of dissection.

Distally, the fusion of the visceral fascia with the inferior extension of the puboprostatic fascia and the parietal fascia of the levator ani muscle forms the "sphincteric" fascia that recovers laterally the deep venous complex and the ischioprostatic ligaments.

The Denonvilliers' Fascia

This fascia has several terminologies. It is variously known as "posterior prostaticorectal fascia," "septum rectovesicale," or "prostatoseminal vesicular fascia." To comply with common custom, the eponym terminology, "Denonvilliers' fascia," will be used here. The Denonvilliers' fascia is posterior to the prostate and anterior to the rectum. Superiorly, it surrounds the seminal vesicles where it fuses with the usual visceral fascia. On the anterior aspect of the seminal vesicle, the Denonvilliers'

An "interfascial" dissection conducted between the prostate capsule and the prostate visceral fascia leaves the neurovascular bundle totally intact and surrounded by its fascia.




FIGURE 5 ■ Apex of the prostate. The Santorini's plexus has been ligated and divided. Periurethral fascia (asterisks). *Abbreviations:* DVC, deep vascular complex; U, sphincteric urethra; PA, prostatic apex.

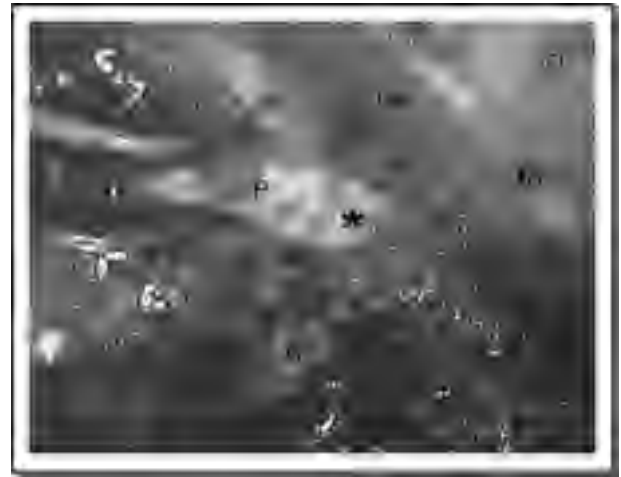


FIGURE 6 ■ Right neurovascular bundle recovered by its fascia, fusion of the prostatic visceral fascia and the Denonvilliers' fascia. Urethra (asterisk). *Abbreviations:* P, prostate; LA, levator ani muscle; O, obturator muscle; TA, tendinous arch of the levator ani muscle; R, rectum.

The Denonvilliers' fascia can be closely adherent to the prostatic gland and at risk of malignant involvement in patients with invasive prostate cancer. Thus, the Denonvilliers' fascia should be posteriorly removed en bloc with the radical prostatectomy specimen.

fascia merges with a prostatic extension of the detrusor and becomes multilayered and rich with muscular fibers. Inferiorly, it merges with the expansion of the rectourethralis muscle, posteriorly to the sphincteric-membranous urethra. Laterally, it merges with the lateral fold of the visceral fascia, determining the superomedial and inferomedial borders of the neurovascular bundle (Fig. 6).

The Denonvilliers' fascia is more adherent to the prostate than to the rectum, particularly on its superior aspect where it is separated from the rectum by a layer of fatty tissue. Distally, this layer of adipose tissue fades and the Denonvilliers' fascia becomes much more adherent to the rectal wall.

The Denonvilliers' fascia can be closely adherent to the prostatic gland and at risk of malignant involvement in patients with invasive prostate cancer. Thus, the Denonvilliers' fascia should be posteriorly removed en bloc with the radical prostatectomy specimen (6).

Rectourethralis Muscle

The rectourethralis is a Y-shaped muscle arising within the substance of the rectal wall deep to the outer longitudinal smooth muscle and inserts into the central tendon of the perineum. As such, this structure is rarely encountered in laparoscopy (7). It is currently accepted that the Denonvilliers' fascia inserts distally on the rectourethralis muscle, merging with it.

The Prostatic Neurovascular Plexuses

The prostatic neurovascular plexus contains veins, arteries and autonomic nerves. Its limits are the parietal fascia of the levator ani laterally, and the fusion of the Denonvilliers' fascia and the prostatic visceral fascia medially.


The Cavernous Nerves

The cavernous nerves arise from the inferior hypogastric plexus and contain autonomic, sympathetic and parasympathetic fibers. These nerves appear like a network distributed to the prostate and to the corpus cavernosum. The nerves join the prostatic artery at the level of the pedicle. The cavernous branches of the network then follow the posterolateral aspect of the prostate toward the apex, accompanied by veins and arterial branches of the prostatic pedicular artery (8). Apically, the nerves run more posteromedially to the prostate. Along their course, small branches of the cavernous nerves penetrate the prostate capsule (intracapsular nerves). However, visualization of these branching nerves is difficult, even during the laparoscopic "interfascial" dissection. Nonetheless, their existence is confirmed by pathological studies (9).

The Arteries

The arteries are very visible during laparoscopic dissection and are important landmarks for initiating the dissection plane of the "interfascial" neurovascular

FIGURE 7 ■ Right prostatic pedicle. Main prostatic pedicular artery (asterisk). Abbreviation: PPF, periprostatic fascia.



dissection (Fig. 7). At the level of the arborescence of the prostatic arteries into prostatic, vesicular, and deferential arteries, at least one branch runs anteroinferiorly on the lateral aspect of the base of prostate and joins the cavernous nerves to form the neurovascular bundle posterolaterally. Once within the neurovascular bundle, the artery generates an arterial network. Rarely, one of these arteries crosses the medial visceral fascia to enter the prostatic capsule at the mid portion of the gland. More often the arteries run all along the prostate and only give a retrograde branch to the apex.

The Veins

A vein originating from the deep venous complex and running along the anterior tip of the crescent shape neurovascular bundle can be used as a landmark for the neurovascular preservation.

Although the veins usually follow the course of the artery, it is not infrequent in the case of a large vein originating from the deep venous complex and running along the anterior tip of the crescent shape neurovascular bundle.

SPHINCTERIC COMPLEX

The Rhabdomyosphincter

Urinary continence relies on a combined function of detrusor, trigone, and urethral sphincter muscles. The external urethral sphincter covers the ventral surface of the prostate as a crescent shape above the veru montanum, assumes a horseshoe shape below the veru montanum, and then becomes more crescent shaped along the proximal bulbar urethra. The levator ani muscles form an open circle around the external sphincter with a hiatus at the ventral aspect. The smooth and striated muscle components of the urethral sphincteric complex are inseparable (10).

The length of the sphincteric urethra measured by magnetic resonance imaging is variable among individuals (between 6 and 24 mm; average, 14 mm) and seems to be directly related to the recovery of continence (11).

Innervation of the Rhabdomyosphincter

The innervation of the so-called “rhabdomyosphincter” is supported mainly by fibers coming from the S2 to S4 roots and traveling via the pudental nerve. These nerves are not visualized during a laparoscopic pelvic surgery because they run posterolateral to the rectum, and then inferior to the levator ani muscle. More distally the main trunk gives terminal branches to the inferolateral aspect of the urethral sphincter.

Extrapudendal nerves can sometimes be found inside the pelvis and may be damaged during pelvic surgery (12,13).

Rhabdomyosphincteric innervation by branches arising from the pelvic plexus (S4 root) have also been described as a branch of the pelvic splanchnic nerve. They also are posterolateral to the rectum and are not visible during a pelvic dissection for urologic disease (14).

A vein originating from the deep venous complex and running along the anterior tip of the crescent shape neurovascular bundle can be used as a landmark for the neurovascular preservation.

The length of the sphincteric urethra measured by magnetic resonance imaging is variable among individuals (between 6 and 24 mm; average, 14 mm) and seems to be directly related to the recovery of continence.

Extrapudendal nerves can sometimes be found inside the pelvis and may be damaged during pelvic surgery.

CONCLUSION

The understanding of anatomy is ever evolving. Laparoscopy with its inherent limitations and advantages necessitates a somewhat different comprehension of the surgical anatomy, adapted to a certain angle of vision and magnification. There is no doubt that the knowledge of the laparoscopic anatomy of the pelvis will grow over time, and will allow surgery to reach its ultimate goal: being curative without being deleterious.

REFERENCES

1. Mauroy B, Demondion X, Drizenko A, et al. The inferior hypogastric plexus (pelvic plexus): its importance in neural preservation techniques. *Surg Radiol Anat* 2003; 25:6–15.
2. Benoit G, Droupy S, Quillard J, Paradis V, Giuliano F. Supra and infralevator neurovascular pathways to the penile corpora cavernosa. *J Anat* 1999; 195:605–615.
3. Myers RP. Detrusor apron, associated vascular plexus, and avascular plane: relevance to radical retropubic prostatectomy—anatomic and surgical commentary. *Urology* 2002; 59:472–479.
4. Breza J, Aboseif SR, Orvis BR, Lue TF, Tanagho EA. Detailed anatomy of penile neurovascular structures: surgical significance. *J Urol* 1989; 141:437–443.
5. Villers A, Stamey TA, Yemoto C, Rischmann P, McNeal JE. Modified extrafascial radical retropubic prostatectomy technique decreases frequency of positive surgical margins in T2 Cancers < 2 cc. *Eur Urol* 2000; 38:64–73.
6. Villers A, McNeal JE, Freiha FS, Boccon-Gibod L, Stamey TA. Invasion of Denonvilliers' fascia in radical prostatectomy specimens. *J Urol* 1993; 149:793–798.
7. Brooks JD, Eggener SE, Chao WM. Anatomy of the rectourethralis muscle. *Eur Urol* 2002; 41:94–100.
8. Walsh PC, Lepor H, Eggleston JC. Radical prostatectomy with preservation of sexual function: anatomical and pathological considerations. *Prostate* 1983; 4:473–485.
9. Villers A, McNeal JE, Redwine EA, Freiha FS, Stamey TA. The role of perineural space invasion in the local spread of prostatic adenocarcinoma. *J Urol* 1989; 142:763–768.
10. Yucel S, Baskin LS. An anatomical description of the male and female urethral sphincter complex. *J Urol* 2004; 171:1890–1897.
11. Coakley FV, Eberhardt S, Kattan MW, Wei DC, Scardino PT, Hricak H. Urinary continence after radical retropubic prostatectomy: relationship with membranous urethral length on preoperative endorectal magnetic resonance imaging. *J Urol* 2002; 168:1032–1035.
12. Zvara P, Carrier S, Kour NW, Tanagho EA. The detailed neuroanatomy of the human striated urethral sphincter. *Br J Urol* 1994; 74:182–187.
13. Hollabaugh RS, Dmochowski RR, Steiner MS. Neuroanatomy of the male rhabdosphincter. *Urology* 1997; 49:426–434.
14. Akita K, Sakamoto H, Sato T. Origins and courses of the nervous branches to the male urethral sphincter. *Surg Radiol Anat* 2003; 25:387–392.

J. Stuart Wolf, Jr.

Division of Minimally Invasive Urology, Department of Urology, University of Michigan, Ann Arbor, Michigan, U.S.A.

- | | |
|--|--|
| <ul style="list-style-type: none"> ■ INTRODUCTION ■ PHYSIOLOGIC FACTORS <ul style="list-style-type: none"> Positioning Increased Intra-abdominal Pressure Carbon Dioxide ■ PHYSIOLOGIC RESPONSES <ul style="list-style-type: none"> Cardiovascular Pulmonary | <ul style="list-style-type: none"> Renal and Hormonal Responses to Alternative Techniques ■ PHYSIOLOGIC COMPLICATIONS <ul style="list-style-type: none"> Cardiovascular Collapse Other Physiologic Complications ■ SUMMARY ■ REFERENCES |
|--|--|

INTRODUCTION

Laparoscopy for the most part is physiologically beneficial for the patient, especially with regard to pulmonary function, but the benefits occur in the post-operative period (1–4). During the procedure itself, laparoscopy is physiologically more stressful on the patient than open surgery.

Pronounced positional issues, increased intra-abdominal pressure, and the sequelae of absorbed CO₂ combine to create unfamiliar physiologic effects. Fortunately, most patients tolerate the physiologic insult of laparoscopy well. On occasion, either in a patient with significant cardiovascular compromise or owing to unusual response, significant and potentially life-threatening complications that have little to do with the inherent steps of the particular surgical procedure but instead result from physiologic reactions to the laparoscopic environment can occur.

In a survey of outcomes of laparoscopic cholecystectomy, one-half of the mortality was due to physiologic rather than surgical events (5). A prepared surgeon can avoid these complications, or at least manage them appropriately if they do occur.

PHYSIOLOGIC FACTORS

The primary factors influencing the physiologic response to laparoscopy are

- The increased intra-abdominal pressure from intraperitoneal insufflation of gas and
- The absorption of CO₂, which is used as the insufflant gas in most procedures.

Patient positioning, such as extreme Trendelenburg (head down) or extreme lateral flexion, can play a significant role. These factors can have both stimulatory and inhibitory effects, and their influence can be varied independently to some extent.

Positioning

The lateral position used for laparoscopic renal surgery does not have much effect on hemodynamics unless impingement on the vena cava by extreme lateral flexion reduces venous return (6). For upper abdominal laparoscopic procedures, the patient is sometimes placed in a head-up tilt (reverse Trendelenburg) position to drop bowel away from the operative field. This position decreases cardiac output (7,8), and there is inconsistent evidence that this position may improve pulmonary mechanics during laparoscopy (9–11).

The intraperitoneal approach to radical prostatectomy and other laparoscopic pelvic surgeries is facilitated by a head-down tilt (Trendelenburg) position, which tends to modestly increase cardiac output (12–15). Most, but not all, studies suggest that this position restricts diaphragmatic movement and increases ventilation-perfusion mismatch during laparoscopy (10,16,17).

In a survey of outcomes of laparoscopic cholecystectomy, one-half of the mortality was due to physiologic rather than surgical events. A prepared surgeon can avoid these complications, or at least manage them appropriately if they do occur.

The intraperitoneal approach to radical prostatectomy and other laparoscopic pelvic surgeries is facilitated by a head-down tilt (Trendelenburg) position, which tends to modestly increase cardiac output. Most, but not all, studies suggest that this position restricts diaphragmatic movement and increases ventilation-perfusion mismatch during laparoscopy.

Insufflation of gas elevates the intra-abdominal pressure. Increase in intra-abdominal pressure is the most prominent of the physiologic insults of laparoscopy and can have dramatic effects with only small changes.

Vascular compression by elevated intra-abdominal pressure increases the systemic vascular resistance, which tends to reduce cardiac output. The magnitude of the effect of intra-abdominal pressure on systemic vascular resistance varies with the extent and duration of insufflation pressure and the volume status of the subject.

Intra-abdominal pressure directly impacts venous return, which also affects cardiac output.

Increased Intra-Abdominal Pressure

Insufflation of gas elevates the intra-abdominal pressure. Increase in intra-abdominal pressure is the most prominent of the physiologic insults of laparoscopy and can have dramatic effects with only small changes.

Increased intra-abdominal pressure compresses the splanchnic circulation (Fig. 1) (18), in both capillaries and capacitance vessels, and in both the venous and arterial systems (14,15,19–22). An intra-abdominal pressure of 20 mmHg or more diminishes blood flow to all abdominal and retroperitoneal organs except the adrenal gland (18,23–25).

Vascular compression by elevated intra-abdominal pressure increases the systemic vascular resistance, which tends to reduce cardiac output. The magnitude of the effect of intra-abdominal pressure on systemic vascular resistance varies with the extent and duration of insufflation pressure and the volume status of the subject.

In the canine model, Kashtan et al. (22) found that at an intra-abdominal pressure of 20 mmHg, the cardiac output fell slightly in the presence of normovolemia, decreased significantly with experimental simulation of hypovolemia, and increased with experimental simulation of hypervolemia. The adverse effects of hypovolemia (26,27) and the beneficial effect of volume loading (28) in the presence of increased intra-abdominal pressure are now well recognized. Thus, it is recommended that patients should be well hydrated prior to undergoing laparoscopy.

Intra-abdominal pressure directly impacts venous return, which also affects cardiac output.

At an intra-abdominal pressure less than 10 mmHg in normovolemic subjects, venous return, and therefore cardiac output, is augmented by emptying of abdominal capacitance vessels (29–31). High intra-abdominal pressure (>20 mmHg) decreases venous return and cardiac output (Fig. 2) (19–21,32). Even variation of intra-abdominal pressure between approximately 7 and 15 mmHg has a discernable effect, with more adverse hemodynamic impact at the greater pressure (31,33,34).

Mean arterial pressure is the product of cardiac output and arterial resistance. At intra-abdominal pressures less than 20 mmHg, increases in arterial resistance are more than decreases in cardiac output, and therefore mean arterial pressure is elevated (14,15,20,29,30,32,35,36). At excessive intra-abdominal pressures (>40 mmHg), the more dramatic reduction in cardiac output reduces arterial pressure (21,37). Similarly, venous pressure is determined by venous resistance and the volume of blood returning from capillary beds. However, the increase of venous resistance and pressure with insufflation (19,29) is difficult to accurately measure during insufflation. Intracardiac (transmural) venous pressure is the effective cardiac filling pressure, but central venous pressures as measured by a catheter within the right atrium also include

FIGURE 1 ■ Splanchnic circulation is restricted by pneumoperitoneum. Source: From Ref. 122.



FIGURE 2 ■ Reduction of venous return and cardiac output during laparoscopy. Source: From Ref. 122.



The balance between the resistance and pressure changes that determine venous return and cardiac output is dependent upon circulating blood volume. Given normovolemia, an intra-abdominal pressure less than 20 mmHg is not associated with major hemodynamic alterations in most patients.

The primary advantages of using CO₂ during laparoscopy include its rapid absorption and its noncombustible nature.

Mild-to-moderate hypercapnia (excess of CO₂ in the blood) during laparoscopy with CO₂ pneumoperitoneum causes a mild respiratory acidosis.

Overall, moderate levels of CO₂ absorption elevate cardiac output and blood pressure and decrease systemic vascular resistance. The tendency to reduce systemic vascular resistance counteracts the increase caused by the increased intra-abdominal pressure.

intrathoracic (pleural) pressures. The intrathoracic pressure rises along with increases in intra-abdominal pressure (20,22). This impedes venous return and cardiac filling, such that the central venous pressure measured by a right atrial catheter is a poor indicator of cardiac filling unless intrathoracic pressure is taken into account.

The complex effects of increased intra-abdominal pressure on hemodynamics are best understood in the context of the volume status of the patient. An increase in intra-abdominal pressure by less than 10 mmHg increases venous pressure more than resistance, thereby augmenting venous return and cardiac output. As intra-abdominal pressure rises, the increase in resistance exceeds the increase in pressure at some point, and venous return falls. The transition point occurs at a low intra-abdominal pressure in the hypovolemic state where vessels collapse easily. As volume status increases, increases in vascular pressure remain proportional to that of intra-abdominal pressure transition point at greater intra-abdominal pressures, because the full vessels do not collapse (and dramatically increase resistance) as readily.

The balance between the resistance and pressure changes that determine venous return and cardiac output is dependent upon circulating blood volume. Given normovolemia, an intra-abdominal pressure less than 20 mmHg is not associated with major hemodynamic alterations in most patients.

Increased intra-abdominal pressure also effects pulmonary function in a negative manner similar to that of the head-down tilt position. Elevation and restriction of the diaphragm (38) reduces lung capacity and compliance (30,39), with worsening of ventilation-perfusion mismatch (Fig. 3) (38).

Carbon Dioxide

Carbon dioxide (CO₂), introduced for insufflation by Zollikofer in 1924, is the most popular insufflant for laparoscopy under anesthesia (40).

The primary advantages of using CO₂ during laparoscopy include its rapid absorption and its noncombustible nature.

The absorption of CO₂ has contradictory effects at different sites. CO₂ is directly cardioinhibitory, reducing heart rate, cardiac contractility, and vascular resistance (41). However, CO₂ also stimulates the sympathetic nervous system, and the increase in heart rate, cardiac contractility, and vascular resistance mediated by sympathetic nerves and circulating catecholamines counteract the direct effects of CO₂ (42,43).

Mild-to-moderate hypercapnia (excess of CO₂ in the blood) during laparoscopy with CO₂ pneumoperitoneum causes a mild respiratory acidosis (21,44).

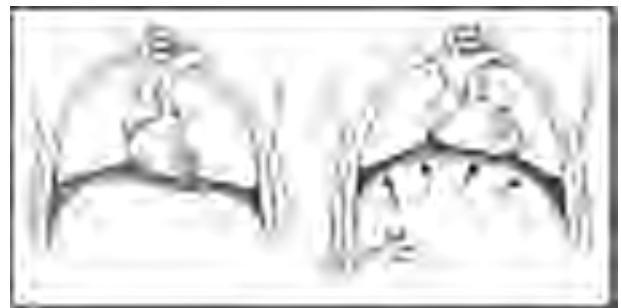Severe hypercapnia induces more dramatic acidosis (see below), and the parasympathetic nervous system is also stimulated (41).

Overall, moderate levels of CO₂ absorption elevate cardiac output and blood pressure and decrease systemic vascular resistance. The tendency to reduce systemic vascular resistance counteracts the increase caused by the increased intra-abdominal pressure.

Insufflation of gases other than CO₂ results in a lower cardiac output for a given intra-abdominal pressure (35,36,45–47).

During intra-abdominal insufflation, the sum of gas movement is directed outwards from the peritoneal cavity into the surrounding tissue because the intra-abdominal pressure is greater than the atmospheric pressure (48). Partial-pressure gradients determine the direction of movement of each gas. The rate of movement is determined by the absorptive capacity of the surrounding tissue, temperature, the area of tissue exposed, and the tissue permeance of the gas. The well-vascularized peritoneal membrane has a high absorptive capacity, so gases with high tissue permeance are

FIGURE 3 ■ Elevation of diaphragm and restriction of lung expansion during pneumoperitoneum. Source: From Ref. 122.



If CO₂ elimination does not equal the sum of metabolic production and absorption of CO₂, hypercapnia and respiratory acidosis develop.

Hypercapnia can develop or persist after the conclusion of a prolonged laparoscopic procedure.

Cardiovascular effects of intra-abdominal insufflation with CO₂ are clinically insignificant in healthy and normovolemic patients.

With 15 mmHg pressure of CO₂ insufflation, central venous pressure, systemic vascular resistance, heart rate, and mean arterial pressure increase. The effect on cardiac output may range from a decrease of 17% to 28%, to no net change, to an increase of 5% to 7%.

Numerous studies have confirmed the more marked cardiovascular effects of laparoscopy in individuals with cardiac disease. However, thorough patient preparation, attentive monitoring, and careful intraoperative management make pneumoperitoneum tolerable even for these patients.

absorbed readily. Of the gases used for insufflation during laparoscopy, CO₂ has the highest tissue permeance (Table 2) (49). Insufflated CO₂ rapidly diffuses into the blood stream. The baseline production of CO₂ in adults is 150–200 mL/min (50). During intra-abdominal insufflation at typical pressures, CO₂ is absorbed into the body at a rate of 14–48 mL/min (51). The amount of absorbed CO₂ can be greater with increased intra-abdominal pressure.

CO₂ absorbed or produced by tissue metabolism is eliminated by ventilation. CO₂ is first hydrated to carbonic acid (catalyzed by carbonic anhydrase), which rapidly ionizes to bicarbonate and hydrogen ions (50). Bicarbonate is soluble in blood. Hydrogen ions reduce hemoglobin in red blood cells. Hemoglobin is reoxidized in the alveolar capillaries, and the hydrogen ions are released to bind bicarbonate, produce carbonic acid, and subsequently form CO₂ and water for expiration.

If CO₂ elimination does not equal the sum of metabolic production and absorption of CO₂, hypercapnia and respiratory acidosis develop.

The vascular content of CO₂ (estimated by PaCO₂ or partial arterial pressure of carbon dioxide) is the “rapid” compartment of CO₂ storage. The rise in PaCO₂ is tempered by storage of CO₂ in the “medium” (primarily skeletal muscle) and “slow” (fat) compartments. These storage sites can hold up to 120 L of CO₂ (50). Therefore, not all of the absorbed CO₂ is immediately available for elimination. In a patient with compromised ventilation, large amounts of PaCO₂ can build up in the body and several hours may be necessary to eliminate the accumulation (39,52).

Hypercapnia can develop or persist after the conclusion of a prolonged laparoscopic procedure (53).

PHYSIOLOGIC RESPONSES

Cardiovascular

Cardiovascular effects of intra-abdominal insufflation with CO₂ are clinically insignificant in healthy and normovolemic patients.

Table 1 summarizes the cardiovascular effects of an intra-abdominal pressure of 15 mmHg with typical CO₂ absorption (moderate hypercapnia). Certainly, the response of any individual patient will vary.

With 15 mmHg pressure of CO₂ insufflation, central venous pressure, systemic vascular resistance, heart rate, and mean arterial pressure increase. However, the effect on cardiac output may range from a decrease of 17% to 28% (15,31,32), to no net change (14,19), to an increase of 5% to 7% (35,54).

Intra-abdominal CO₂ insufflation pressure between 5 and 10 mmHg may increase cardiac output in patients by 4% to 28% (29–31). Intra-abdominal pressure above 40 mmHg risks marked reduction of cardiac output (19). Hypovolemia will negatively alter these hemodynamic effects. The head-down tilt position for pelvic laparoscopy has a moderately favorable impact on hemodynamics.

Urine output decreases during laparoscopy (64,65).

Patients with cardiac disease (ischemic or myopathic) are at greater risk for intraoperative hemodynamic problems (55,56).

Numerous studies have confirmed the more marked cardiovascular effects of laparoscopy in individuals with cardiac disease. However, thorough patient preparation, attentive monitoring, and careful intraoperative management make pneumoperitoneum tolerable even for these patients (57–59).

TABLE 1 ■ Hemodynamic Response to Laparoscopy

	Intra-abdominal pressure of 15 mmHg	Moderate hypercapnia	Combined
Central venous pressure	Increase	Increase	Increase
Systemic vascular resistance	Increase	Decrease	Increase
Heart rate	Increase	Increase	Increase
Mean arterial pressure	Increase	Increase	Increase
Cardiac output	Decrease	Increase	Variable

Reduction in lung capacity and compliance, and worsening of ventilation-perfusion mismatch are the most pronounced pulmonary effects of intra-abdominal insufflation with CO₂. These effects are exacerbated by the head-down tilt position for pelvic laparoscopy.

Normal pulmonary function is adequate to eliminate the small amount of absorbed CO₂. In most patients, any tendency toward an increase in PaCO₂ owing to CO₂ absorption and worsened lung mechanics is easily addressed by increasing minute ventilation.

Urine output decreases during laparoscopy.

The mechanisms involved in oliguria during CO₂ insufflation include (i) increased renal vein resistance (with subsequent decreased renal blood flow); (ii) renal parenchymal compression; (iii) activation of hormonal factors such as the renin-angiotensin system; and (iv) increased levels of antidiuretic hormone.

The kidney appears to be particularly compromised more than other organs by the combination of hypovolemia and increased intra-abdominal pressure.

When compared to open surgery, laparoscopy tends to be associated with less stress, immunologic compromise, and inflammation. However, results of published studies have been markedly variable in this regard.

Operative laparoscopy can be performed safely in patients with cardiac ejection fractions less than 15% (60), or morbid obesity (54).

Pulmonary

Reduction in lung capacity and compliance, and worsening of ventilation-perfusion mismatch are the most pronounced pulmonary effects of intra-abdominal insufflation with CO₂. These effects are exacerbated by the head-down tilt position for pelvic laparoscopy.

The response to these factors is a tendency toward atelectasis, hypoxemia, and hypercapnia. CO₂ absorption has no direct effect on pulmonary function. The anesthesiologist's manipulation of ventilatory parameters during laparoscopy allows the body to keep pace with the excess CO₂ absorbed by the peritoneal membrane.

Normal pulmonary function is adequate to eliminate the small amount of absorbed CO₂. In most patients, any tendency toward an increase in PaCO₂ owing to CO₂ absorption and worsened lung mechanics is easily addressed by increasing minute ventilation.

Because invasive arterial-blood gas sampling is required to measure PaCO₂, end-tidal CO₂ [P(et)CO₂] is monitored intraoperatively with capnography to estimate the PaCO₂ during general anesthesia; the P(et)CO₂ is 3 to 5 mmHg lower than the PaCO₂. The P(a-et)CO₂ gradient, equal to the difference between PaCO₂ and P(et)CO₂, is not significantly worsened during short laparoscopic procedures in healthy patients (39,53,61). Therefore, a sustained P(et)CO₂ between 30 and 40 mmHg indicates acceptable PaCO₂ in most patients. In patients with pulmonary disease, however, a PaCO₂ rise causes an unpredictable P(a-et)CO₂ increase (62,63). Sampling of arterial blood gases may be necessary to monitor accurately the CO₂ elimination in patients with pulmonary disease.

Renal and Hormonal

Urine output decreases during laparoscopy (64,65). In one study, urine output during laparoscopy was only 0.03 mL/kg/hr, compared to 1.70 mL/kg/hr immediately postoperatively, despite an average intravenous intraoperative fluid administration of 13.0 mL/kg/hr (66). In rodents, an intra-abdominal pressure less than 10 mmHg produces only mild oliguria, whereas pressures greater than 10 mmHg reduce urine output by 50% to 100% (67). Using a porcine model, McDougall et al. observed a 29% reduction of the urine output during intra-abdominal insufflation at pressures lesser than 10 mmHg, and a 65% reduction with pneumoperitoneum greater than 10 mmHg pressure (68).

The mechanisms involved in oliguria during CO₂ insufflation include (i) increased renal vein resistance (with subsequent decreased renal blood flow); (ii) renal parenchymal compression; (iii) activation of hormonal factors such as the renin-angiotensin system; and (iv) increased levels of antidiuretic hormone (67,69–76).

A reduction in creatinine clearance occurs corresponding to the decreased urine output during laparoscopy. In one study on laparoscopic cholecystectomy, creatinine clearance decreased in 29 of 48 patients, with the decrease being more than 50% in eight patients (77). Creatinine clearance decreased 18% with intra-abdominal pressures less than 10 mmHg, and 53% with pressures above 10 mmHg also in the porcine model studied by McDougall et al. (68).

The kidney appears to be particularly compromised more than other organs by the combination of hypovolemia and increased intra-abdominal pressure (27).

In addition to the respiratory acidosis that usually accompanies CO₂ insufflation, various investigators have reported coexisting trends toward both metabolic alkalosis (61) and metabolic acidosis (53,78). Experimentally, metabolic acidosis is noted only at gas insufflation pressures greater than 20 mmHg (68). The cause does not appear to be lactate acidosis from splanchnic hypoperfusion because there is no increase in the anion gap. Reduction in renal function due to acid retention occurring at high intra-abdominal pressures is a more likely etiology (68).

Several studies have evaluated systemic stress, immunologic derangement, and inflammation associated with laparoscopy using a number of humoral and cell-mediated measures.

When compared to open surgery, laparoscopy tends to be associated with less stress, immunologic compromise, and inflammation. However, results of published studies have been markedly variable in this regard (73,79–89).

Many of the effects appear to be related to CO₂ directly (84,90). Although laparoscopy appears to be beneficial in terms of less impact on nitrogen balance and energy metabolism when compared to open surgery, the clinical significance of these findings is uncertain (88,91,92).

Responses to Alternative Techniques

Retroperitoneal Insufflation

Pathophysiology of laparoscopy has been investigated vis-a-vis intraperitoneal insufflation of gas. Although many of the phenomena pertaining to gas insufflation into the peritoneal cavity likely apply to retroperitoneal insufflation as well, some important differences need to be highlighted. Some clinical studies have suggested that extraperitoneal insufflation (51,93,94) increases CO₂ absorption; however, experimental studies failed to prove this finding (95–97). Using cuffed-balloon ports that minimized gas leakage into the subcutaneous tissue as opposed to the conventional ports used in prior clinical studies, Ng et al. (98) found no difference in CO₂ absorption during extraperitoneal versus transperitoneal laparoscopy, suggesting that subcutaneous emphysema may have confounded the earlier clinical studies.

When compared to intraperitoneal insufflation, extraperitoneal insufflation appears to have less untoward physiologic sequelae.

When compared to intraperitoneal insufflation, extraperitoneal insufflation appears to have less untoward physiologic sequelae.

In two different experimental studies in the porcine model, extraperitoneal insufflation altered venous pressures and cardiac output similar to intraperitoneal insufflation, but of a lesser magnitude (96,97). Giebler et al. found no change in cardiac output up to retroperitoneal insufflation pressures of 20 mmHg (99). In a comparative clinical study, the same investigators subsequently determined that retroperitoneal insufflation actually augmented venous return slightly, whereas intraperitoneal insufflation reduced venous return (100). The smaller volume of gas required to fill the retroperitoneal space compared to the intraperitoneal space may possibly account for some of these differences.

Alternative Insufflants/Gasless Laparoscopy

The rapid absorption of CO₂ is well tolerated physiologically as long as the hypercapnia can be maintained at moderate levels (PaCO₂ = 45 mmHg). In fact, cardiovascular stimulation by moderate hypercapnia alleviates some of the hemodynamic burden of pneumoperitoneum (35,36,45–47). However, because excessive hypercapnia is cardiodepressive and can produce dysrhythmias (see below), there has been interest in investigating alternative gases for laparoscopic insufflation. Following the first published reports of the physiologic hazards of CO₂ pneumoperitoneum (101), nitrous oxide (N₂O) was employed as an alternative gas insufflant (102). N₂O is similar to CO₂ in its rapid absorption (Table 2) and has fewer physiologic effects at the blood concentration achieved with intraperitoneal insufflation. N₂O, however, can support combustion in the abdominal cavity.

N₂O is a suitable alternative for intra-abdominal insufflation only if a heat source (electrocautery or laser) is not used. N₂O insufflation is excellent for diagnostic laparoscopy under local anesthesia because it is less irritating to the peritoneal membrane than CO₂.

N₂O is a suitable alternative for intra-abdominal insufflation only if a heat source (electrocautery or laser) is not used. N₂O insufflation is excellent for diagnostic laparoscopy under local anesthesia because it is less irritating than CO₂ to the peritoneal membrane (103–105).

Helium and argon, monoatomic noble gases not supporting combustion, are other alternative gases (47,106). These gases are not associated with insufflant-related cardiopulmonary problems (106,107), and are absorbed slowly (Table 2). Because argon may have some adverse hemodynamic effects, helium appears more attractive (105). Helium insufflation has been successfully employed in several clinical laparoscopic series (46,108–110). For example, laparoscopic nephrectomy being performed in a patient with severe pulmonary disease who developed extreme hypercapnia was completed after switching the insufflant gas to helium (111). The slow absorption of helium is a liability, however, because the clinical effects of a venous gas embolism may be exacerbated (see below). Because the risk of venous gas embolism is higher during the initial insufflation, starting the procedure with CO₂ insufflation and then switching to helium

TABLE 2 ■ Insufflant Characteristics

	Solubility ^a	Diffusibility ^a	Tissue permeance ^a
Nitrogen	1.0	1.0	1.0
Helium	0.7	2.7	1.3
Oxygen	1.9	0.9	1.8
Argon	2.2	0.9	2.0
Nitrous oxide	33.0	0.9	28.0
Carbon dioxide	47.0	0.9	39.0

^aValue relative to nitrogen.
Source: From Ref. 49.

Gasless laparoscopy is another alternative to CO₂ pneumoperitoneum in patients with significant cardiac or pulmonary disease, which would place them at risk of physiologic complications during CO₂ pneumoperitoneum.

Most physiologic complications may be prevented by knowledgeable control of intra-abdominal pressure and fluid status, and careful intraoperative patient monitoring. However, complications can occur even in prepared hands.

Tension pneumoperitoneum is the precipitous reduction of venous return, cardiac output, and blood pressure due to increased intra-abdominal pressure from gas insufflation.

Whenever hemodynamic compromise due to excessive intra-abdominal pressure is suspected, immediate desufflation will quickly improve the situation, and the surgeon may be able to complete the procedure using a lower intra-abdominal pressure.

A reasonable precaution against hemodynamic compromise is to operate at the minimal intra-abdominal pressure that provides adequate exposure.

Most venous gas embolisms occur during and within a few minutes of initial gas insufflation, but delayed cases have been reported.

to address the occurrence of dangerous hypercapnia is probably the best approach (111,112). The gas regulator used for helium is different than that for CO₂; thus, even if helium tanks are available to the surgeon, these gases cannot be used until the appropriate gas-specific regulator has been fitted to the laparoscopic insufflator. Due to flow characteristics different from CO₂, helium alters the behavior of the insufflator and leaks more easily around laparoscopic ports.

Finally, laparoscopy can be performed with an abdominal wall-lifting device creating a working space without insufflation of gas. There are many technical concerns with this approach, including more difficult surgical exposure for some procedures and no pneumoperitoneum-induced tamponade of bleeding by increased intra-abdominal pressure from gas insufflation. From the physiological standpoint, however, the use of an abdominal wall-lifting device rather than pneumoperitoneum obviates all of the aforementioned physiological considerations (65,113,114).

Gasless laparoscopy is another alternative to CO₂ pneumoperitoneum in patients with significant cardiac or pulmonary disease, which would place them at risk of physiologic complications during CO₂ pneumoperitoneum.

PHYSIOLOGIC COMPLICATIONS

The knowledge of laparoscopic physiology facilitates the avoidance, recognition, and management of physiologic complications.

Most physiologic complications may be prevented by knowledgeable control of intra-abdominal pressure and fluid status, and careful intraoperative patient monitoring. However, complications can occur even in prepared hands.

Cardiovascular Collapse Tension Pneumoperitoneum

Tension pneumoperitoneum is the precipitous reduction of venous return, cardiac output, and blood pressure due to increased intra-abdominal pressure from gas insufflation (115).

Fatalities have been reported (116). As intra-abdominal pressure becomes excessive, e.g., greater than 40 mmHg, vascular resistance increases and overwhelms the increase in venous pressure driving venous return. The effect of elevated intra-abdominal pressure is potentiated by hypovolemia (21,22); therefore, volume status must be optimized before laparoscopy. Parra et al. (117) reported the development of tension pneumoperitoneum caused by a malfunctioning insufflator allowing the intra-abdominal pressure to exceed 32 mmHg. Although the procedure was completed after returning to an appropriate level of pneumoperitoneum and administering atropine, the patient exhibited hypotension and bradycardia, and suffered a cerebrovascular accident thought to be due to the intraoperative event.

Whenever hemodynamic compromise due to excessive intra-abdominal pressure is suspected, immediate desufflation will quickly improve the situation, and the surgeon may be able to complete the procedure using a lower intra-abdominal pressure (115).

Although brief periods of intra-abdominal pressures of 20 mmHg and above during laparoscopy are well tolerated in healthy patients and are used by many surgeons at the outset of a procedure to make primary port insertion safer and easier, the pressure should be kept at 15 mmHg or less for the majority of the duration of the procedure. Occasionally, even typically acceptable pressures (15 mmHg) can be associated with hemodynamic deterioration (118). A reasonable precaution against hemodynamic compromise is to operate at the minimal intra-abdominal pressure that provides adequate exposure (87).

Venous Gas Embolism

A venous gas embolism is a gas bubble in the venous system. Clinically significant venous gas embolism passes into the heart and pulmonary circulation, blocking the pulmonary circulation with subsequent hypoxemia, hypercapnia, and depressed cardiac output. Several fatalities have been reported (119–121). If pressure in the right heart exceeds that in the left heart, a foramen ovale defect may allow gas to embolize into the arterial system (20,119,120). Symptomatic venous gas embolism is rare during laparoscopy, with an estimated incidence of 0.002% to 0.08% (122). Using careful surveillance with echocardiography, however, detectable venous gas embolism were noted in 0.59% of laparoscopic cases in one study (123).

Most venous gas embolisms occur during and within a few minutes of initial gas insufflation, but delayed cases have been reported (119).

The most useful indication of venous gas embolism is (i) a sudden fall in $P(\text{et})\text{CO}_2$ on capnometry if the CO_2 embolus is large or (ii) its abrupt but transient increase if the CO_2 embolus is small.

Venous gas embolism should be suspected in the presence of clinical indicators, especially if they occur suddenly or during initial insufflation. Swift response may be lifesaving.

Immediate desufflation prevents more gas from entering the venous system. Placing the patient in a steep head-down tilt position with the right side up tends to trap gas in the right ventricle and prevent passage into the pulmonary circulation. Rapid ventilation with 100% oxygen and general resuscitative maneuvers are recommended to address hypoxemia, hypercapnia, and hypotension.

The moderate hypercapnia that occurs during most laparoscopic procedures using CO_2 pneumoperitoneum is beneficial via a mild sympathetically mediated cardiostimulatory effect. However, the direct cardiodepressive effects of CO_2 and the severe respiratory acidosis associated with hypercapnia of this magnitude can lead to cardiovascular collapse and/or fatal dysrhythmias if the level of PaCO_2 exceeds 60 mmHg.

FIGURE 4 ■ Arterial tracing after rapid intravenous injection of 7.5 cc/kg CO_2 (top) and helium (bottom) in a dog. There is recovery within one minute after the CO_2 injection but complete cardiovascular collapse after the helium injection. Source: From Ref. 130.

Venous gas embolism has also been produced experimentally in a bleeding vena cava model. In this setting, the risk is greatest when blood flow cephalad from the venotomy is reduced, owing to either mechanical occlusion of the vena cava or significant blood loss (124). At any point in the laparoscopic procedure, when a venotomy is created and flow past the injury is reduced, venous gas embolism must be considered. However, if the cavotomy is appropriately managed with attention to minimizing blood loss and potential for gas entering the proximal end, then venous gas embolism is unlikely (125).

The most useful indication of venous gas embolism is (i) a sudden fall in $P(\text{et})\text{CO}_2$ on capnometry if the CO_2 embolus is large or (ii) its abrupt but transient increase if the CO_2 embolus is small (121,126).

Other clinical signs of venous gas embolism include hypoxemia, pulmonary edema, increased airway pressure, hypotension, jugular venous distention, facial plethora, dysrhythmias, auscultation of a mill-wheel cardiac murmur, or the appearance of a widened QRS complex with right heart strain patterns on electrocardiography.

Venous gas embolism should be suspected in the presence of clinical indicators, especially if they occur suddenly or during initial insufflation. Swift response may be lifesaving.

The goal is to minimize further passage of gas into the pulmonary circulation, and to correct the ventilation problems.

Immediate desufflation prevents more gas from entering the venous system. Placing the patient in a steep head-down tilt position with the right side up tends to trap gas in the right ventricle and prevent passage into the pulmonary circulation. Rapid ventilation with 100% oxygen and general resuscitative maneuvers are recommended to address hypoxemia, hypercapnia, and hypotension.

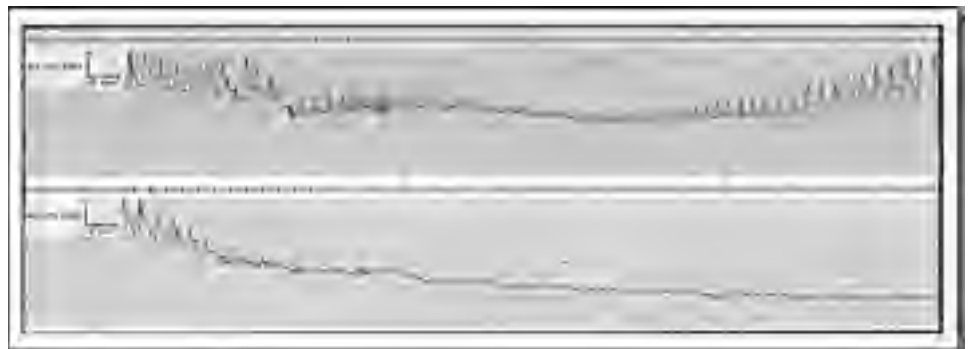
If a central venous catheter is already in place, attempts to aspirate the gas are reasonable (127).

The nature of the gas that embolizes is an important determinant of the outcome of venous gas embolism (128). As outlined in Table 2, CO_2 is 47 times more soluble than nitrogen. A venous gas embolism composed of CO_2 would therefore be reabsorbed much more quickly than one composed of nitrogen. Comparing intravenous injection of air versus CO_2 in a canine model, LD50 (lethal dose in 50% of subjects) of air (~80% nitrogen) was five times lesser than LD50 of CO_2 (129). Helium, used as an alternative to CO_2 for insufflation in some series (46,108–110), is even less soluble than nitrogen. In canine experiments, intravenous injection of helium was lethal on four of six occasions whereas injection of the same amount of CO_2 was followed by hemodynamic recovery in all cases (Fig. 4) (130). Argon venous gas embolism during use of a laparoscopic argon beam coagulator has been reported (131).

Hypercapnia

The moderate hypercapnia that occurs during most laparoscopic procedures using CO_2 pneumoperitoneum is beneficial via a mild sympathetically mediated cardiostimulatory effect. However, the direct cardiodepressive effects of CO_2 and the severe respiratory acidosis associated with hypercapnia of this magnitude can lead to cardiovascular collapse and/or fatal dysrhythmias if the level of PaCO_2 exceeds 60 mmHg (132–134).

In healthy patients, hypercapnia is due to absorption of the insufflated CO_2 , rather than any change in tissue metabolism or pulmonary function (106). In three clinical studies comparing N_2O insufflation to CO_2 insufflation during laparoscopy under general anesthesia with fixed ventilation, the increase in PaCO_2 averaged 10.7 mmHg in the CO_2 group and 0.5 mmHg in the N_2O group (45,78,102). The clinical practice during laparoscopy of increasing ventilation rates and tidal volumes to increase CO_2 elimination is usually but not always effective. In one laparoscopic cholecystectomy series,



A diffusion limit of carbon monoxide measurement less than 50% of the predicted value is predictive of the inability to adequately eliminate CO₂ during laparoscopy with CO₂ pneumoperitoneum. In such patients, open surgery, alternative gases, or gasless laparoscopy should be considered.

Reduction of intra-abdominal pressure to the lowest pressure that allows acceptable exposure is prudent, facilitates CO₂ elimination by reducing the interference of pneumoperitoneum with pulmonary mechanics, and reduces CO₂ absorption.

Typically, tachycardia and ventricular extrasystoles associated with CO₂ stimulation are benign and can be prevented by avoiding excessive hypercapnia.

Intraperitoneal gas may leak into several extraperitoneal tissue planes or spaces. Subcutaneous emphysema is the most common site.

Spontaneous pneumomediastinum and pneumothorax may occur during laparoscopy without any evidence of diaphragmatic injury. Although usually with no clinical significance, they can inhibit cardiac filling and limit lung excursion. Fatality has been reported.

6.7% of procedures had to be converted to open surgery because of hypercapnia (62), and similar conversion rates have been reported during urologic laparoscopy (49,135). Preoperative pulmonary assessment is recommended for patients with clinically significant pulmonary disease.

A diffusion limit of carbon monoxide measurement less than 50% of the predicted value is predictive of the inability to adequately eliminate CO₂ during laparoscopy with CO₂ pneumoperitoneum (136). In such patients, open surgery, alternative gases, or gasless laparoscopy should be considered.

Patients with chronic obstructive pulmonary disease without such severe diffusion impairment can usually undergo laparoscopy without complication (137).

Clinical studies have suggested that CO₂ absorption is increased in the presence of subcutaneous emphysema (51,94,138), elevated intra-abdominal pressure (19), and increased duration of insufflation (38,46,78,112). Some authors have found extraperitoneal insufflation to increase CO₂ absorption (51,93,94), whereas others have not (95–97). As the anesthesiologist monitors the P(et)CO₂, any worrisome elevation must be immediately reported to the operating surgeon. Often, just a brief period of desufflation to eliminate the excess CO₂ is all that is needed. When laparoscopy is resumed, rapid ventilation should be continued.

Reduction of intra-abdominal pressure to the lowest pressure that allows acceptable exposure is prudent, facilitates CO₂ elimination by reducing the interference of pneumoperitoneum with pulmonary mechanics, and reduces CO₂ absorption (19).

If hypercapnia recurs, options include aborting the procedure entirely, converting to open surgery, or using alternative insufflants or gasless laparoscopy.

Cardiac Dysrhythmias

When carefully monitored during laparoscopy, cardiac dysrhythmias are noted to occur in 17% to 50% of cases (139,140). Fatal dysrhythmias can occur with marked elevation of PaCO₂ (41).

Typically, tachycardia and ventricular extrasystoles associated with CO₂ stimulation are benign and can be prevented by avoiding excessive hypercapnia.

Hypercapnia potentiates parasympathetic actions in some situations (41). Vagal stimulation by peritoneal manipulation or distention during CO₂ laparoscopy can occasionally produce bradydysrhythmias. Asystolic arrest during CO₂ laparoscopy has been reported (132,134). Because vagal reactions may be accentuated during awake laparoscopy (local anesthesia), some recommend premedication with atropine in this setting (141).

Extraperitoneal Gas Collections

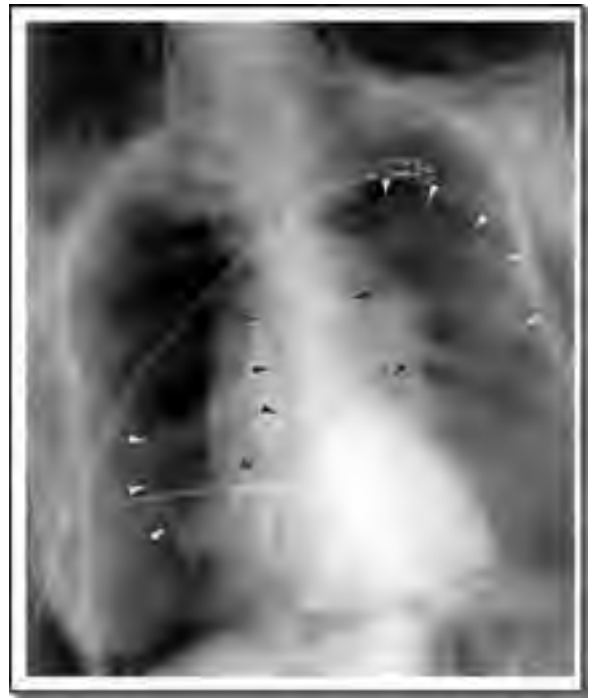Intraperitoneal gas may leak into several extraperitoneal tissue planes or spaces. Subcutaneous emphysema is the most common site.

Etiology of extraperitoneal gas collections may be a technical error such as incorrect insufflation due to superficial needle placement, excessive intra-abdominal pressure, or a malfunctioning insufflator. However, subcutaneous emphysema most commonly occurs due to leakage around a laparoscopic port. Subcutaneous gas is a risk factor for hypercapnia, so its presence should prompt an assessment for hypercapnia and its effects. Gas insufflation into the preperitoneal space or omentum is usually not a concern (although it may also increase the risk of hypercapnia) unless it occurs during the initial Veress needle placement in which case it might interfere with subsequent laparoscopic visualization. Preperitoneal insufflation is occasionally the cause for aborting a laparoscopic procedure (117).

Spontaneous pneumomediastinum and pneumothorax may occur during laparoscopy without any evidence of diaphragmatic injury (Fig. 5) (142–145). Although usually with no clinical significance, they can inhibit cardiac filling and limit lung excursion. Fatality has been reported (146).

Insufflated gas may enter the thorax through many pathways, such as (i) persistent fetal connections (pleuroperitoneal, pleuropericardial, and pericardioperitoneal); (ii) extrafascial plane around great vessels; (iii) in between diaphragmatic fibers (extraperitoneal or extrapleural); or (iv) dissection of subcutaneous gas from the anterior neck directly into the superior mediastinum (Fig. 6) (122). Pneumothorax also may occur secondary to barotrauma when the peak airway pressure rises with pneumoperitoneum (39). When pneumothorax occurs, it is usually accompanied by pneumomediastinum and subcutaneous emphysema (51,94,122). Extraperitoneal gas can more easily gain access into the thoracic cavity, either via the extrafascial planes described above or via an increase in subcutaneous emphysema. In a pair of reports from the same institution, pneumomediastinum and/or pneumothorax were noted in 36% of

FIGURE 5 ■ Portable antero-posterior chest radiograph demonstrating extensive subcutaneous emphysema, pneumomediastinum (black arrowheads), and bilateral pneumothoraces (white arrowheads) found after laparoscopic pyeloplasty with no evidence of diaphragm injury. Intraperitoneal gas is still present. Source: From Ref. 145.



If CO₂ or N₂O has been insufflated, the pneumothorax usually will resolve. Thoracostomy should be performed to manage a large or symptomatic pneumothorax.

patients undergoing extraperitoneal laparoscopy and in 6% of patients after transperitoneal laparoscopy (51,94).

If CO₂ or N₂O has been insufflated, the pneumothorax usually will resolve (147). Thoracostomy should be performed to manage a large or symptomatic pneumothorax.

Pneumopericardium has also been reported after laparoscopy (142). Subcutaneous gas has been present in all reported cases of pneumopericardium, and in most cases, there has been radiographic evidence of pneumomediastinum as well. The entry of mediastinal gas into the pericardial space alongside blood vessels is the most likely mechanism, although persistent embryological pleuropericardial and pericardioperitoneal connections would also allow gas into the pericardium.

Intra-Abdominal Explosion

The use of pure oxygen for pneumoperitoneum was abandoned after Fervers' (148) 1933 report of an intra-abdominal explosion during laparoscopy with oxygen insufflation. N₂O supports combustion (149) and is explosive in the presence of methane or

FIGURE 6 ■ Possible routes of gas into mediastinum, pericardial sac, or pleural cavity during laparoscopy include persistent fetal connections at the site of pleuroperitoneal membrane (A1, forme fruste of diaphragmatic hernia), pleuropericardial membrane (A2), and pericardioperitoneal canal (A3); leakage of gas through intact membrane at a weak point such as diaphragmatic hiatus (B1), at pulmonary hilum (B2), and pericardial sac alongside blood vessels (B3); gas outside membrane-bound cavities such as pro- or retroperitoneal gas in between fibers of the diaphragm or alongside great vessels (C1) or subcutaneous gas from the anterior neck (C2); gas from the rupture of an airspace (barotrauma) enters the mediastinum or pleural cavity by dissecting along the pulmonary vasculature (D). Source: From Ref. 122.



To reduce the risk of explosion, both inhaled and insufflated N₂O should be avoided when electrocautery or laser might be used.

As demonstrated by Doppler flow studies, the increased intra-abdominal pressure of pneumoperitoneum diverts blood from the splanchnic circulation into the lower extremities, with subsequent lower-extremity venous engorgement and stasis during transperitoneal laparoscopy.



FIGURE 7 ■ Pneumoperitoneum promotes lower-extremity venous engorgement and stasis. Source: From Ref. 122.

The relative risk of thrombotic complications following laparoscopic surgery compared to open surgery is unknown. Until certain laparoscopic procedures have been determined to be at very low risk, prophylaxis against venous thrombosis is recommended.

Intravenous fluid requirements during laparoscopy are less than during open surgery. The combination of decreased insensible losses (no body cavity open to air) and decreased urine output predisposes patients to volume overloading during laparoscopy.

hydrogen (150). Although the necessary conditions for explosion in association with N₂O pneumoperitoneum are rare (151), cardiac rupture and death from an explosion during N₂O pneumoperitoneum has been reported (152). Hydrogen at a concentration of 69% (the maximum reported content of hydrogen in bowel gas) is combustible in the presence of 29% N₂O (153). It has been determined that when the anesthetic gas contained 60% N₂O, the N₂O content in the peritoneal cavity increased to 36% after 30 minutes of CO₂ pneumoperitoneum (153).

To reduce the risk of explosion, both inhaled and insufflated N₂O should be avoided when electrocautery or laser might be used.

Even without N₂O insufflation, electrocautery injury to the colon can produce explosion (154).

Other Physiologic Complications

Venous Thrombosis

As demonstrated by Doppler flow studies, the increased intra-abdominal pressure of pneumoperitoneum diverts blood from the splanchnic circulation into the lower extremities (155), with subsequent lower-extremity venous engorgement and stasis during transperitoneal laparoscopy (Fig. 7) (156–158).

Femoral vein pressure generally parallels intra-abdominal pressure. Comparing intraperitoneal and preperitoneal gas insufflation in the same patients, one study demonstrated that femoral vein flow decreased with the former but not the latter (159). In two studies comprising 133 patients, no cases of deep venous thrombosis were detected with lower limb venous duplex scans following low-risk laparoscopic surgery (157,160). Larger series using clinical rather than routine imaging assessment have described a 0% to 1% incidence of deep venous thrombosis after laparoscopy (161–164). Pulmonary emboli following laparoscopy have also been reported (161,164–167).

The relative risk of thrombotic complications following laparoscopic surgery compared to open surgery is unknown. Until certain laparoscopic procedures have been determined to be at very low risk, prophylaxis against venous thrombosis is recommended.

Use of sequential compression devices during laparoscopy reverses the pneumoperitoneum-induced reduction of femoral vein flow (168). In a study at the author's institution, of 354 consecutive urologic patients, 189 received subcutaneous fractionated heparin for venous thrombosis prophylaxis, and 165 were managed with sequential compression devices (164). Thrombotic complications in the heparin group included two deep venous thromboses without pulmonary emboli (1.0%). In the sequential compression devices group, there were two pulmonary emboli and one thrombosis of a dialysis fistula (1.8%) ($p = 0.03$). The rates of hemorrhagic complication were 18/189 (9.5%) and 6/165 (3.6%), respectively ($p > 0.05$). For urologic laparoscopic patients, these data suggest that fractionated subcutaneous heparin is associated with increased hemorrhagic complications without an apparent reduction in thrombotic complications as compared to sequential compression devices.

Elevated Intracranial Pressure and Cerebral Ischemia

In a small study of pigs insufflated with CO₂ at a pressure of 15 mmHg, the intracranial pressure increased by 5 mmHg (169). In two myelomeningocele patients with ventriculoperitoneal shunts, the intracranial pressure increased more than 15 mmHg above baseline during a CO₂ pneumoperitoneum of 10 mmHg pressure only (170). In another study of 18 patients with ventriculoperitoneal shunts undergoing 19 laparoscopic procedures, however, bradycardia and hypertension, which would be expected if the intracranial pressure increase is clinically significant, were not observed (171). Cerebral vascular engorgement is the probable mechanism of increased intracranial pressure during laparoscopy, although in patients with ventriculoperitoneal shunts, obstruction of the catheter may play a role as well. Patients with significant cerebral vascular disease could suffer ischemia because the cerebral circulation responds to the increased intracranial volume and pressure with a decrease in blood flow (172).

Fluid Overload

Intravenous fluid requirements during laparoscopy are less than during open surgery. The combination of decreased insensible losses (no body cavity open to air) and decreased urine output predisposes patients to volume overloading during laparoscopy.

In Clayman's initial nephrectomy series, 2 of the first 10 patients developed transient congestive heart failure, possibly due to excessive intravenous fluid and blood products administration at a time when the decreased urine output during

laparoscopy was not yet appreciated (173). Similar cases have been reported after other laparoscopic procedures (174). Intraoperative fluid administration should be limited to appropriate replacement for blood loss plus a maintenance rate of 5 mL/kg/hr. Because hypovolemia predisposes patients to adverse hemodynamic effects of pneumoperitoneum, the volume status of the patient should be optimized prior to insufflation.

Despite the well-documented oliguria associated with laparoscopy, acute renal failure following laparoscopy, in the absence of another obvious etiology, is rare.

If acute renal failure does occur after laparoscopy, other etiologies should be evaluated before ascribing this adverse event to the pneumoperitoneum.

Acute Renal Failure

Despite the well-documented oliguria associated with laparoscopy, acute renal failure following laparoscopy, in the absence of another obvious etiology, is rare.

However, in one 67-year-old man with chronic renal insufficiency, renal tubular acidosis, and hypertension, renal failure lasted for two weeks following laparoscopy (175). The effect of laparoscopy on kidney function is transient, with renal indices returning almost to baseline within two hours of the release of pneumoperitoneum (68). This has been shown to be the case even in a high-risk renal insufficiency model (176). The adverse effects of nephrotoxic agents such as aminoglycosides are not worsened by laparoscopy (177).

If acute renal failure does occur after laparoscopy, other etiologies should be evaluated before ascribing this adverse event to the pneumoperitoneum.

Hypertension

The mild increase in arterial pressure, which occurs in the setting of PaO₂ pneumoperitoneum of 15 mmHg in a healthy patient, is not problematic. Clinically significant hypertension during laparoscopy may be due to pneumoperitoneum-related causes such as hypervolemia (fluid overload in the setting of oliguria), hypoxemia, hypercapnia, or moderately increased intra-abdominal pressure. Hypertension in this setting is a clue to look for these other problems, and the underlying cause, rather than the hypertension itself, should be addressed first.

Hypoxemia

PaO₂ may decrease during laparoscopy for several pneumoperitoneum-related causes, such as decreased cardiac output, worsened ventilation-perfusion mismatch, decreased alveolar ventilation, acidosis, venous gas embolism, and pneumothorax (178). Clinical studies revealed a slight but clinically insignificant reduction of PaO₂ during laparoscopy (21,39,44,62,102). Although one group reported a less than 100 mmHg drop in PaO₂ during N₂O laparoscopy in two patients with heavy smoking history (179), others have found PaO₂ during laparoscopy to be unaffected significantly by preoperative pulmonary status (62).

Hypothermia

Because cold CO₂ is cycled through the pneumoperitoneum, heat may be absorbed from the patient, resulting in hypothermia (180,181). Studies have shown that heating

TABLE 3 ■ Physiologic Recommendations for Laparoscopy

Cardiac and pulmonary status should be assessed preoperatively
Adequate circulating blood volume should be attained preoperatively, but once this is achieved, maintenance level of fluids should be administered intraoperatively
Verify insufflator settings before and during initiation of pneumoperitoneum
Intraoperative monitoring must include end-tidal carbon dioxide
Use the lowest intra-abdominal pressure that will allow adequate exposure of the field
Low-pressure pneumoperitoneum, abdominal wall-lifting devices, or helium for insufflation may be beneficial in some very high-risk patients
Apply sequential compression devices for venous thrombosis prophylaxis

TABLE 4 ■ Physiologic Complications of Laparoscopy

Cardiovascular collapse
Tension pneumoperitoneum
Venous gas embolism
Hypercapnia
Cardiac dysrhythmias
Extraperitoneal gas collections
Intra-abdominal explosion
Others
Venous thrombosis
Elevated intracranial pressure and cerebral ischemia
Fluid overload
Acute renal failure
Hypertension
Hypoxemia
Hypothermia

and humidifying the insufflant prevents a decrease in core temperature (182,183), while others have found that there is no effect from this intervention (184–186). With the use of other modalities such as simple heating blankets, core temperatures may actually increase rather than decrease during laparoscopy, even without heating the insufflant (186,187).

SUMMARY

- The primary determinants of the physiologic effects of laparoscopy are the intra-abdominal pressure, the type of gas insufflated, and the position of the patient.
- Table 3 lists physiologic recommendations grounded in scientific evidence and good practice, which should be considered by every surgeon performing laparoscopy.
- Important physiologic issues for the surgeon are the cardiopulmonary health of the patient, preoperative volume status, and careful intraoperative monitoring.
- Surgeons need to be aware of the prevention, recognition, and treatment of physiologic complications during laparoscopy (Table 4). Intraoperative cardiovascular collapse can occur from the physiologic complications of tension pneumoperitoneum, venous gas embolism, hypercapnia, cardiac dysrhythmias, extraperitoneal gas collections, and intra-abdominal explosion.
- Other physiologic complications include venous thrombosis, elevated intracranial pressure/cerebral ischemia, fluid overload, acute renal failure, hypertension, hypoxemia, and hypothermia.

REFERENCES

1. Putensen-Himmer G, Putensen C, Lammer H, Lingnau W, Aigner F, Benzer H. Comparison of post-operative respiratory function after laparoscopy or open laparotomy for cholecystectomy. *Anesthesiology* 1992; 77:675.
2. Rademaker BM, Ringer JN, Odoom JA, de Wit LT, Kalkman CJ, Oosting J. Pulmonary function and stress response after laparoscopic cholecystectomy: comparison with subcostal incision and influence of thoracic epidural analgesia. *Anesth Analg* 1992; 75:381.
3. Nguyen NT, Lee SL, Goldman C, et al. Comparison of pulmonary function and post-operative pain after laparoscopic versus open gastric bypass: a randomized trial. *J Am Coll Surg* 2001; 192:469.
4. Bablekos GD, Roussou T, Rasmussen T, Vassiliou MP, Behrakis PK. Post-operative changes on pulmonary function after laparoscopic and open cholecystectomy. *Hepato-Gastroenterology* 2003; 50:1193.
5. Deziel DJ, Millikan KW, Economou SG, Doolas A, Ko S-T, Airan MC. Complications of laparoscopic cholecystectomy: a national survey of 4,292 hospitals and an analysis of 77,604 cases. *Am J Surg* 1993; 165:9.
6. Lawson NW. The lateral decubitus position. In: Martin JT, ed. *Positioning in Anesthesia and Surgery*. Philadelphia: W.B. Saunders, 1987:155.
7. Cunningham AJ, Turner J, Rosenbaum S, Rafferty T. Transoesophageal echocardiographic assessment of haemodynamic function during laparoscopic cholecystectomy. *Br J Anaesth* 1993; 70:621.
8. Hirvonen EA, Poikolainen EO, Paakkonen ME, Nuutinen LS. The adverse hemodynamic effects of anesthesia, head-up tilt, and carbon dioxide pneumoperitoneum during laparoscopic cholecystectomy. *Surg Endosc* 2000; 14:272.
9. Casati A, Comotti L, Tommasino C, et al. Effects of pneumoperitoneum and reverse Trendelenburg position on cardiopulmonary function in morbidly obese patients receiving laparoscopic gastric banding. *Eur J Anaesthesiol* 2000; 17:300.
10. Rauh R, Hemmerling TM, Rist M, Jacobi KE. Influence of pneumoperitoneum and patient positioning on respiratory system compliance. *J Clin Anesth* 2001; 13:361.
11. Salihoglu Z, Demiroglu S, Dikmen Y. Respiratory mechanics in morbid obese patients with chronic obstructive pulmonary disease and hypertension during pneumoperitoneum. *Eur J Anaesthesiol* 2003; 20:658.
12. Sibbald WJ, Paterson NAM, Holliday RL, Baskerville J. The Trendelenburg position: hemodynamic effects in hypotensive and normotensive patients. *Crit Care Med* 1979; 7:218.
13. Reich DL, Konstadt SN, Raissi S, Hubbard M, Thys DM. Trendelenburg position and passive leg raising do not significantly improve cardiopulmonary performance in the anesthetized patient with coronary artery disease. *Crit Care Med* 1989; 17:313.
14. Torrielli R, Cesarini M, Winnock S, Cabiro C, Mene JM. Hemodynamic changes during celioscopy: a study carried out using thoracic electric bioimpedance. *Can J Anaesth* 1992; 37:46.
15. Johannsen G, Andersen M, Juhl B. The effect of general anaesthesia on the haemodynamic events during laparoscopy with CO₂-insufflation. *Acta Anaesthesiol Scand* 1989; 33:132.
16. Fahy BG, Barnas GM, Flowers JL, Nagle SE, Njoku MJ. The effects of increased abdominal pressure on lung and chest wall mechanics during laparoscopic surgery. *Anesth Analg* 1995; 81:744.
17. Makinen MT, Yli-Hankala A. Respiratory compliance during laparoscopic hiatal and inguinal hernia repair. *Can J Anaesth* 1998; 45:865.
18. Caldwell CB, Ricotta JJ. Changes in visceral blood flow with elevated intraabdominal pressure. *J Surg Res* 1987; 43:14.

19. Motew M, Ivankovich AD, Bieniarz J, Albrecht RF, Zahed B, Scommegna A. Cardiovascular effects and acid-base and blood gas changes during laparoscopy. *Am J Obstet Gynecol* 1973; 115:1002.
20. Ivankovich AD, Miletich DJ, Albrecht RF, Heyman HJ, Bonnet RF. Cardiovascular effects of intraperitoneal insufflation with carbon dioxide and nitrous oxide in the dog. *Anesthesiology* 1975; 42:281.
21. Diamant M, Benumof JL, Saidman LJ. Hemodynamics of increased intra-abdominal pressure: interaction with hypovolemia and halothane anesthesia. *Anesthesiology* 1978; 48:23.
22. Kashtan J, Green JF, Parsons EQ, Holcroft JW. Hemodynamic effects of increased abdominal pressure. *J Surg Res* 1981; 30:249.
23. Hashikura Y, Kawasaki K, Munakata Y, Hashimoto S, Hayahi K, Makuuchi M. Effects of peritoneal insufflation on hepatic and renal blood flow. *Surg Endosc* 1994; 8:759.
24. Eleftheriadis E, Kotzampassi K, Botsios D, Tzartinoglou E, Farmakis H, Dadoukis J. Splanchnic ischemia during laparoscopic cholecystectomy. *Surg Endosc* 1996; 10:324.
25. Schilling MK, Redaelli C, Krahenbuhl L, Signer C, Buchler MW. Splanchnic microcirculatory changes during CO₂ laparoscopy. *J Am Coll Surg* 1997; 18:378.
26. Ho HS, Saunders CJ, Corso FA, Wolfe BM. The effects of CO₂ pneumoperitoneum on hemodynamics in hemorrhaged animals. *Surgery* 1993; 114:381.
27. Pastor CM, Morel DR, Clergue F, Mentha G, Morel P. Effects of abdominal CO₂ insufflation on renal and hepatic blood flows during acute hemorrhage in anesthetized pigs. *Crit Care Med* 2001; 29:1017.
28. Cullen DJ, Coyle JP, Teplick R, Long MC. Cardiovascular, pulmonary, and renal effects of massively increased intra-abdominal pressure in critically ill patients. *Crit Care Med* 1989; 17:118.
29. Versichelen L, Serreyn R, Rolly G, Vanderkerckhove D. Physiopathologic changes during anesthesia administration for gynecologic laparoscopy. *J Reprod Med* 1984; 29:697.
30. Ekman LG, Abrahamsson J, Biber B, Forssman L, Milsom I, Sjöqvist B-A. Hemodynamic changes during laparoscopy with positive end-expiratory pressure ventilation. *Acta Anaesthesiol Scand* 1988; 32:447.
31. Dexter SP, Vucevic M, Gibson J, McMahon MJ. Hemodynamic consequences of high- and low-pressure capnoperitoneum during laparoscopic cholecystectomy. *Surg Endosc* 1999; 13:376.
32. Lenz RJ, Thomas TA, Wilkins DG. Cardiovascular changes during laparoscopy: studies of stroke volume and cardiac output using impedance cardiography. *Anaesthesia* 1976; 31:4.
33. Rishimani AS, Gautam SC. Hemodynamic and respiratory changes during laparoscopic cholecystectomy with high and reduced intraabdominal pressure. *Surg Laparosc Endosc* 1996; 6:201.
34. Wallace DH, Serpell MG, Baxter JN, O'Dwyer PJ. Randomized trial of different insufflation pressures for laparoscopic cholecystectomy. *Br J Surg* 1997; 84:455.
35. Marshall RL, Jebson PJR, Davie IT, Scott DB. Circulatory effects of carbon dioxide insufflation of the peritoneal cavity for laparoscopy. *Br J Anaesth* 1972; 44:680.
36. Marshall RL, Jebson PJR, Davie IT, Scott DB. Circulatory effects of peritoneal insufflation with nitrous oxide. *Br J Anaesth* 1972; 44:1183.
37. Richardson JD, Trinkle JK. Hemodynamic and respiratory alterations with increased intra-abdominal pressure. *J Surg Res* 1976; 20:401.
38. Hodgson C, McClelland RMA, Newton JR. Some effects of the peritoneal insufflation of carbon dioxide at laparoscopy. *Anaesthesia* 1970; 25:382.
39. Puri GD, Singh H. Ventilatory effects of laparoscopy under general anaesthesia. *Br J Anaesth* 1992; 68:211.
40. Zollikofer R. Zur Laparoskopie. *Schweizerische Medizinische Wochenschrift* 1924; 5:264.
41. Price HL. Effects of carbon dioxide on the cardiovascular system. *Anesthesiology* 1960; 21:652.
42. Richardson DW, Wasserman AJ, Patterson JL. General and regional circulatory responses to change in blood pH and carbon dioxide tension. *J Clin Invest* 1961; 40:31.
43. Sato N, Kawamoto M, Yuge O, et al. Effects of pneumoperitoneum on cardiac autonomous nervous activity evaluated by heart rate variability analysis during sevoflurane, isoflurane, or propofol anesthesia. *Surg Endosc* 2000; 14:362.
44. Kenefick JP, Leader A, Maltby JR, Taylor PJ. Laparoscopy: blood-gas values and minor sequelae associated with three techniques based on isoflurane. *Br J Anaesth* 1987; 59:189.
45. El-Minawi MF, Wahbi O, El-Bagouri IS, Sharawi M, El-Mallah SY. Physiologic changes during CO₂ and N₂O pneumoperitoneum in diagnostic laparoscopy. A comparative study. *J Reprod Med* 1981; 26:338.
46. Bongard FS, Pianim NA, Leighton TA, et al. Helium insufflation for laparoscopic operation. *Surg Gynecol Obstet* 1993; 177:140.
47. Eisenhauer DM, Saunders CJ, Ho HS, Wolfe BM. Hemodynamic effects of argon pneumoperitoneum. *Surg Endosc* 1994; 8:315.
48. Piiper J. Physiological equilibria of gas cavities in the body. In: Fenn WO, Rahn H, eds. *Handbook of Physiology, Section 3: Respiration*. Vol. 2. Washington, D.C.: American Physiological Society, 1965:1205.
49. Stoller ML, Wolf JS Jr. Physiological considerations in laparoscopy. In: Das S, Crawford ED, eds. *Urologic Laparoscopy*. Philadelphia: W.B. Saunders, 1994:17.
50. Nunn JF. Carbon dioxide. *Applied Respiratory Physiology*. London: Butterworths, 1987:207.
51. Wolf JS Jr, Clayman RV, Monk TG, McClennan BL, McDougall EM. Carbon dioxide absorption during laparoscopic pelvic surgery. *J Am Coll Surg* 1995; 180:555.
52. Tolksdorf W, Strang CM, Schippers E, Simon HB, Truong S. [The effects of the carbon dioxide pneumoperitoneum in laparoscopic cholecystectomy on postoperative spontaneous respiration]. *Anaesthesist* 1992; 41:199.
53. Liu SY, Leighton T, Davis I, Klein S, Lippmann M, Bongard F. Prospective analysis of cardiopulmonary responses to laparoscopic cholecystectomy. *J Laparoendosc Surg* 1991; 1:241.
54. Nguyen NT, Ho HS, Fleming NW, et al. Cardiac function during laparoscopic versus open gastric bypass. *Surg Endosc* 2002; 16:78.

55. Joris JL, Noirot DP, Legrand MJ, Jacquet NJ, Lamy ML. Hemodynamic changes during laparoscopic cholecystectomy. *Anesth Analg* 1993; 76:1067.
56. Safran D, Sgambati S, Orlando R III. Laparoscopy in high-risk cardiac patients. *Surg Gynecol Obstet* 1993; 176:548.
57. Dhoste K, Lacoste L, Karayan J, Lehuède MS, Thomas D, Fuscuardi J. Haemodynamic and ventilatory changes during laparoscopic cholecystectomy in elderly ASA III patients. *Can J Anaesth* 1996; 43:783.
58. Hein HAT, Joshi GP, Ramsay MAE, et al. Hemodynamic changes during laparoscopic cholecystectomy in patients with severe cardiac disease. *J Clin Anesth* 1997; 9:261.
59. Zollinger A, Krayser S, Singer T, et al. Haemodynamic effects of pneumoperitoneum in elderly patients with an increased cardiac risk. *Eur J Anaesthesiol* 1997; 14:266.
60. Jones PE, Sayson SC, Koehler DC. Laparoscopic cholecystectomy in a cardiac transplant candidate with an ejection fraction of less than 15%. *J Soc Laparoendosc Surg* 1998; 2:89.
61. Verbessem D, Camu F, Devroey P, Steirteghem AV. Pneumoperitoneum induced pH changes in follicular and Douglas fluids during laparoscopic oocyte retrieval in humans. *Human Reprod* 1988; 3:751.
62. Wittgen CM, Andrus CH, Fitzgerald SD, Baudendistel LJ, Dahms TE, Kaminski DL. Analysis of the hemodynamic and ventilatory effects of laparoscopic cholecystectomy. *Arch Surg* 1991; 126:997.
63. Wahba RWM, Mamazza J. Ventilatory requirements during laparoscopic cholecystectomy. *Can J Anaesth* 1993; 40:206.
64. Koivusalo AM, Kellokumpu I, Ristkari S, Lindgren L. Splanchnic and renal deterioration during and after laparoscopic cholecystectomy: a comparison of the carbon dioxide pneumoperitoneum and the abdominal wall lift method. *Anesth Analg* 1997; 85:886.
65. Ninomiya K, Kitano S, Yoshida T, Bandoh T, Baatar D, Matsumoto T. Comparison of pneumoperitoneum and abdominal wall lifting as to hemodynamics and surgical stress response during laparoscopic cholecystectomy. *Surg Endosc* 1998; 12:124.
66. Chang DT, Kirsch AJ, Sawczuk IS. Oliguria during laparoscopic surgery. *J Endourol* 1994; 8:349.
67. Kirsch AJ, Hensle TW, Chang DT, Kayton ML, Olsson CA, Sawczuk IS. Renal effects of CO₂ insufflation: oliguria and acute renal dysfunction in a rat pneumoperitoneum model. *Urology* 1994; 43:453.
68. McDougall EM, Monk TG, Hicks M, et al. The effect of prolonged pneumoperitoneum on renal function in an animal model. *J Am Coll Surg* 1996; 182:317.
69. McDougall EM, Monk TG, Hicks M, et al. Effect of pneumoperitoneum on renal function in an animal model (abstract #938). *J Urol* 1994; 151(suppl):462A.
70. Vukasin A, Lopez M, Shichman S, Horn D, Vaughan ED Jr, Sosa RE. Oliguria in laparoscopic surgery (abstract #462). *J Urol* 1994; 151(suppl):343A.
71. Chiu AW, Azadzi KM, Hatzichristou DG, Siroky MB, Krane RJ, Babayan RK. Effects of intra-abdominal pressure on renal tissue perfusion during laparoscopy. *J Endourol* 1994; 8:99.
72. Koivusalo AM, Kellokumpu I, Scheinin M, Tikkanen I, Halme L, Lindgren L. Randomized comparison of the neuroendocrine response to laparoscopic cholecystectomy using either conventional or abdominal wall lift techniques. *Br J Surg* 1996; 83:1532.
73. Ortega AE, Peters JH, Incabone R, et al. A prospective randomized comparison of the metabolic and stress hormonal responses of laparoscopic and open cholecystectomy. *J Am Coll Surg* 1996; 183:249.
74. Razvi HA, Fields D, Vargas JC, Vaughan ED Jr, Vukasin A, Sosa RE. Oliguria during laparoscopic surgery: evidence for direct parenchymal compression as an etiologic factor. *J Endourol* 1996; 10:1.
75. Bloomfield GL, Blocher CR, Fakhry IF, Sica DA, Sugerman HJ. Elevated intra-abdominal pressure increases plasma renin activity and aldosterone levels. *J Trauma* 1997; 42:997.
76. Guler C, Sade M, Kirkali Z. Renal effect of carbon dioxide insufflation in rabbit pneumoperitoneum model. *J Endourol* 1998; 12:367.
77. Kubota K, Kajiura N, Teruya M, et al. Alterations in respiratory function and hemodynamics during laparoscopic cholecystectomy under pneumoperitoneum. *Surg Endosc* 1993; 7:500.
78. Magno R, Medegård A, Bengtsson R, Tronstad S-E. Acid-base balance during laparoscopy: the effects of intraperitoneal insufflation of carbon dioxide on acid-base balance during controlled ventilation. *Acta Obstet Gynecol Scand* 1979; 58:81.
79. Redmond HP, Watson RW, Houghton T, Condron C, Watson RG, Bouchier-Hayes D. Immune function in patients undergoing open vs laparoscopic cholecystectomy. *Arch Surg* 1994; 129:1240.
80. Karayiannakis AJ, Makri GG, Mantzioka A, Karousos D, Karatzas G. Systemic stress response after laparoscopic or open cholecystectomy: a randomized trial. *Br J Surg* 1997; 84:467.
81. Lausten SB, Ibrahim TM, El-Sefi T, et al. Systemic and cell-mediated immune response after laparoscopic and open cholecystectomy in patients with chronic liver disease. A randomized, prospective study. *Dig Surg* 1999; 16:471.
82. Le-Blanc-Louvry I, Coquerel A, Koning E, Maillot C, Ducrotte P. Operative stress response is reduced after laparoscopic compared to open cholecystectomy: the relationship with postoperative pain and ileus. *Dig Dis Sci* 2000; 45:1703.
83. Mendoza-Sagaon M, Hanly EJ, Talamini MA, et al. Comparison of the stress response after laparoscopic and open cholecystectomy. *Surg Endosc* 2000; 14:1136.
84. Marcovich R, Williams AL, Seifman BD, Wolf JS Jr. A canine model to assess the biochemical stress response to laparoscopic and open surgery. *J Endourol* 2001; 15:1005.
85. Grande M, Tucci GF, Adorisio O, et al. Systemic acute-phase response after laparoscopic and open cholecystectomy. *Surg Endosc* 2002; 16(2):313.
86. Miyake H, Kawabata G, Gotoh A, et al. Comparison of surgical stress between laparoscopy and open surgery in the field of urology by measurement of humoral mediators. *Int J Urol* 2002; 9:329.
87. Neudecker J, Sauerland S, Neugebauer E, et al. The European Association for Endoscopic clinical practice guideline on the pneumoperitoneum for laparoscopic surgery. *Surg Endosc* 2002; 16:1121.
88. Luo K, Li JS, Li LT, Wang KH, Shun JM. Operative stress response and energy metabolism after laparoscopic cholecystectomy compared to open surgery. *World J Gastroenterol* 2003; 9:847.
89. Landman J, Olweny E, Sundaram CP, et al. Prospective comparison of the immunological and stress response following laparoscopic and open surgery for localized renal cell carcinoma. *J Urol* 2004; 171:1456.

90. Ure BM, Niewold TA, Bax NM, Ham M, van der Zee DC, Essen GJ. Peritoneal, systemic, and distant organ inflammatory responses are reduced by a laparoscopic approach and carbon dioxide versus air. *Surg Endosc* 2002; 16:836.
91. Glerup H, Heindorff H, Flyvbjerg A, Jensen SL, Vilstrup H. Elective laparoscopic cholecystectomy nearly abolishes the postoperative hepatic catabolic stress response. *Ann Surg* 1995; 221:214.
92. Hammarqvist F, Westman B, Leijonmarck CE, Andersson K, Wernerman J. Decrease in muscle glutamine, ribosomes, and the nitrogen losses are similar after laparoscopic compared with open cholecystectomy during the immediate postoperative period. *Surgery* 1996; 119:417.
93. Mullett CE, Viale JP, Sagnard PE, et al. Pulmonary CO₂ elimination during surgical procedures using intra- or extraperitoneal CO₂ insufflation. *Anesth Analg* 1993; 76:622.
94. Wolf JS Jr, Monk TG, McDougall EM, McClennan BL, Clayman RV. The extraperitoneal approach and subcutaneous emphysema are associated with greater absorption of carbon dioxide during laparoscopic renal surgery. *J Urol* 1995; 154:959.
95. Wright DM, Serpell MG, Baxter JN, O'Dwyer PJ. Effect of extraperitoneal carbon dioxide insufflation on intra-operative blood gas and hemodynamic changes. *Surg Endosc* 1995; 9:1169.
96. Bannenberg JJ, Rademaker BM, Froeling FM, Meijer DW. Hemodynamics during laparoscopic extra- and intraperitoneal insufflation. An experimental study. *Surg Endosc* 1997; 11:911.
97. Giebler RM, Kabatnik M, Stegen BH, Scherer RU, Thomas M, Peters J. Retroperitoneal and intraperitoneal CO₂ insufflation have markedly different cardiovascular effect. *J Surg Res* 1997; 68:153.
98. Ng CS, Gill IS, Sung GT, Whalley DG, Graham R, Schweizer D. Retroperitoneoscopic surgery is not associated with increased carbon dioxide absorption. *J Urol* 1999; 162:1268.
99. Giebler RM, Walz MK, Peitgen K, Scherer RU. Hemodynamic changes after retroperitoneal CO₂ insufflation for posterior retroperitoneoscopic adrenalectomy. *Anesth Analg* 1996; 82:827.
100. Giebler RM, Behrends M, Steffens T, Walz MK, Peitgen K, Jurgen P. Intraperitoneal and retroperitoneal carbon dioxide evoke different effects on caval vein pressure gradients in humans: evidence for the Starling resistor concept of abdominal venous return. *Anesthesiology* 2000; 92:1568.
101. Siegler AM, Berenyi KJ. Laparoscopy in gynecology. *Obstet Gynecol* 1969; 34:572.
102. Alexander GD, Brown EM. Physiologic alterations during laparoscopy. *Am J Obstet Gynecol* 1969; 105:1078.
103. Sharp JR, Pierson WP, Brady CE III. Comparison of CO₂- and N₂O-induced discomfort during peritoneoscopy under local anesthesia. *Gastroenterology* 1982; 82:453.
104. Minoli G, Terruzzi V, Spinzi GC, Benvenuti C, Rossini A. The influence of carbon dioxide and nitrous oxide on pain during laparoscopy: a double-blind, controlled trial. *Gastrointest Endosc* 1982; 28:173.
105. Menes T, Spivak H. Laparoscopy: searching for the proper insufflation gas. *Surg Endosc* 2000; 14:1050.
106. Leighton TA, Liu SY, Bongard FS. Comparative cardiopulmonary effects of carbon dioxide versus helium pneumoperitoneum. *Surgery* 1993; 113:527.
107. Fitzgerald SD, Andrus CH, Baudendistel LJ, Dahms TE, Kaminski DL. Hypercarbia during carbon dioxide pneumoperitoneum. *Am J Surg* 1992; 163:186.
108. Fernandez-Cruz L, Taura P, Saenz A, Benarroch G, Sabater L. Laparoscopic approach to pheochromocytoma: hemodynamic changes and catecholamine secretion. *World J Surg* 1996; 20:762.
109. Neuberger TJ, Andrus CH, Wittgen CM, Wade TP, Kaminski DL. Prospective comparison of helium versus carbon dioxide pneumoperitoneum. *Gastrointest Endosc* 1996; 43:38.
110. Fleming RY, Dougherty TB, Feig BW. The safety of helium for abdominal insufflation. *Surg Endosc* 1997; 11:230.
111. Wolf JS Jr, Clayman RV, McDougall EM, Shepherd DL, Folger WH, Monk TG. Carbon dioxide and helium insufflation during laparoscopic radical nephrectomy in a patient with severe pulmonary disease. *J Urol* 1996; 155:2021.
112. Neuberger TJ, Andrus CH, Wittgen CM, Wade TP, Kaminski DL. Prospective comparison of helium versus carbon dioxide pneumoperitoneum. *Gastrointest Endosc* 1994; 40:P30.
113. Galizia G, Prizio G, Lieto E, et al. Hemodynamic and pulmonary changes during open, carbon dioxide pneumoperitoneum, and abdominal wall-lifting cholecystectomy. A prospective, randomized study. *Surg Endosc* 2001; 15:477.
114. Andersson L, Lindberg G, Bringman S, Ramel S, Anderberg B, Odeberg-Wernerman S. Pneumoperitoneum versus abdominal wall lift: effects on central haemodynamics and intrathoracic pressure during laparoscopic cholecystectomy. *Acta Anaesth Scand* 2003; 47:838.
115. Lee CM. Acute hypotension during laparoscopy: a case report. *Anesth Analg* 1975; 54:142.
116. Arthure H. Laparoscopy hazard. *Br Med J* 1970; 4:492.
117. Parra RO, Hagood PG, Boullier JA, Cummings JM, Mehan DJ. Complications of laparoscopic urological surgery: experience at St. Louis University. *J Urol* 1994; 151:681.
118. Lew JKL, Gin T, Oh TE. Anaesthetic problems during laparoscopic cholecystectomy. *Anaesth Intens Care* 1992; 20:91.
119. Root B, Levy MN, Pollack S, Lubert M, Pathak K. Gas embolism death after laparoscopy delayed by "trapping" in portal circulation. *Anesth Analg* 1978; 57:232.
120. Gomar C, Fernandez C, Villalonga A, Nalda MA. Carbon dioxide embolism during laparoscopy and hysteroscopy. *Ann Fr Anesth Reanim* 1985; 4:380.
121. Beck DH, McQuillan PJ. Fatal carbon dioxide embolism and severe haemorrhage during laparoscopic salpingectomy. *Br J Anesth* 1994; 72:243.
122. Wolf JS Jr, Stoller ML. The physiology of laparoscopy: basic principles, complications, and other considerations. *J Urol* 1994; 152:294.
123. Hynes SR, Marshall RL. Venous gas embolism during gynaecological laparoscopy. *Can J Anaesth* 1992; 39:748.
124. O'Sullivan DC, Micali S, Averch TD, et al. Factors involved in gas embolism after laparoscopic injury to inferior vena cava. *J Endourol* 1998; 12:149.
125. Jacobi CA, Junghans T, Peter F, Naundorf D, Ordemann J, Muller JM. Cardiopulmonary changes during laparoscopy and vessel injury: comparison of CO₂ and helium in an animal model. *Langenbecks Arch Surg* 2000; 385:459.

126. Shulman D, Aronson HB. Capnography in the early diagnosis of carbon dioxide embolism during laparoscopy. *Can Anaesth Soc J* 1984; 31:455.
127. Mongan P, Peterson RE, Culling RD. Pressure monitoring can accurately position catheters for air embolism aspiration. *J Clin Monit* 1992; 8:121.
128. Roberts MW, Mathiesen KA, Ho HS, Wolfe BM. Cardiopulmonary responses to intravenous infusion of soluble and relatively insoluble gases. *Surg Endosc* 1997; 11:341.
129. Graff TD, Arbogast NR, Phillips OC, Harris LC, Frazier TM. Gas embolism: a comparative study of air and carbon dioxide as embolic agents in the systemic venous system. *Am J Obstet Gynecol* 1959; 78:259.
130. Wolf JS Jr, Carrier S, Stoller ML. Gas embolism: helium is more lethal than carbon dioxide. *J Laparoendosc Surg* 1994; 4:173.
131. Mastragelopoulos N, Sarkar MR, Kaissling G, Bahr R, Daub D. Argon gas embolism in laparoscopic cholecystectomy with the Argon Beam One coagulator. *Chirurg* 1992; 63:1053.
132. Shifren JL, Adlestein L, Finkler NJ. Asystolic cardiac arrest: a rare complication of laparoscopy. *Obstet Gynecol* 1992; 79:840.
133. Holzman M, Sharp K, Richards W. Hypercarbia during carbon dioxide gas insufflation for therapeutic laparoscopy: a note of caution. *Surg Laparosc Endosc* 1992; 2:11.
134. Biswas TK, Pembroke A. Asystolic cardiac arrest during laparoscopic cholecystectomy. *Anaesth Intens Care* 1994; 22:289.
135. Kavoussi LR, Sosa E, Chandhoke P, et al. Complications of laparoscopic pelvic lymph node dissection. *J Urol* 1993; 149:322.
136. Wittgen CM, Naunheim KS, Andrus CH, Kaminski DL. Preoperative pulmonary function evaluation for laparoscopic cholecystectomy. *Arch Surg* 1993; 128:880.
137. Hsieh CH. Laparoscopic cholecystectomy for patients with chronic obstructive pulmonary disease. *J Laparoendosc Adv Surg Tech, Part A* 2003; 13:5.
138. Sosa RE, Weingram J, Stein B, et al. Hypercarbia in laparoscopic pelvic lymph node dissection. *J Urol* 1992; 147:A246.
139. Scott DB, Julian DG. Observations on cardiac arrhythmias during laparoscopy. *Br Med J* 1972; 1:411.
140. Cimino L, Petitto M, Nardon G, Budillon G. Holter dynamic electrocardiography during laparoscopy. *Gastrointest Endosc* 1988; 34:72.
141. Borten M. Choice of anesthesia. *Laparoscopic Complications*. Toronto: B.C. Decker, Inc., 1986:173.
142. Pascual JB, Baranda MM, Tarrero MT, Gutiérrez FM, Garrido IM, Errasti CA. Subcutaneous emphysema, pneumomediastinum, bilateral pneumothorax and pneumopericardium after laparoscopy. *Endoscopy* 1990; 22:59.
143. Altarac S, Janetschek G, Eder E, Bartsch G. Pneumothorax complicating laparoscopic ureterolysis. *J Laparoendosc Surg* 1996; 6:193.
144. Perez JE, Alberts WM, Mamel JJ. Delayed tension pneumothorax after laparoscopy. *Surg Laparosc Endosc* 1997; 7:70.
145. Siu W, Seifman BD, Wolf JS Jr. Subcutaneous emphysema, pneumo-mediastinum, and bilateral pneumothoraces after laparoscopic pyeloplasty. *J Urol* 2003; 170:1936.
146. Sivak BJ. Surgical emphysema: report of a case and review. *Anesth Analg* 1964; 43:415.
147. Batra MS, Driscoll JJ, Coburn WA, Marks WM. Evanescent nitrous oxide pneumothorax after laparoscopy. *Anesth Analg* 1983; 62:1121.
148. Fervers C. Die Laparoskopie mit dem Cystoskop. *Medizinische Klinik* 1933; 29:1042.
149. Soderstrom RM. Dangers of nitrous oxide pneumoperitoneum. *Am J Obstet Gynecol* 1976; 124:668.
150. Robinson JS, Thompson JM, Wood AW. Laparoscopy explosion hazards with nitrous oxide. *Br Med J* 1975; 4:760.
151. Vickers MD. Fire and explosions in operating theatres. *Br J Anaesth* 1978; 50:659.
152. El-Kady AA, Abd-el-Razek M. Intraperitoneal explosion during female sterilization by laparoscopic electrocoagulation. A case report. *Int J Gynaecol Obstet* 1976; 14:487.
153. Neuman GG, Sidebotham G, Negoiana E, et al. Laparoscopy explosion hazards with nitrous oxide. *Anesthesiology* 1993; 78:875.
154. Altmore DF, Memeo V. Colonic explosion during diathermy colostomy. *Dis Colon Rectum* 1993; 36:291.
155. Borten M. Circulatory changes. *Laparoscopic Complications*. Toronto: B.C. Decker, Inc., 1986:185.
156. Jorgensen JO, Hanel K, Lalak NJ, Hunt DR, North L, Morris DL. Thromboembolic complications of laparoscopic cholecystectomy. *BMJ* 1993; 306:518.
157. Wazz G, Branicki F, Taji H, Chishty I. Influence of pneumoperitoneum on the deep venous system during laparoscopy. *J Laparoendosc Surg* 2000; 4:291.
158. Rosen DM, Chou DC, North L, et al. Femoral venous flow during laparoscopic gynecologic surgery. *Surg Laparosc Endosc Percutan Tech* 2000; 10:158.
159. Morrison CA, Schreiber MA, Olsen SB, Hetz SP, Acosta MM. Femoral venous flow dynamics during intraperitoneal and preperitoneal laparoscopic insufflation. *Surg Endosc* 1998; 12:1213.
160. Feng L, Song J, Wong F, Xia E. Incidence of deep venous thrombosis after gynecological laparoscopy. *Chin Med J* 2001; 114:632.
161. Lindberg F, Bergqvist D, Rasmussen I. Incidence of thromboembolic complications after laparoscopic cholecystectomy: review of the literature. *Surg Laparosc Endosc* 1997; 7:324.
162. Catherine JM, Capelluto E, Gaillard JL, Turner R, Champault G. Thromboembolism prophylaxis and incidence of thromboembolic complications after laparoscopic surgery. *Int J Surg Invest* 2000; 2:41.
163. Blake AM, Toker SI, Dunn E. Deep venous thrombosis prophylaxis is not indicated for laparoscopy cholecystectomy. *J Soc Laparoendosc Surg* 2001; 5:215.
164. Montgomery JS, Wolf JS Jr. Thrombotic and hemorrhagic complications associated with fractionated subcutaneous heparin vs. sequential compression boots as deep venous thrombosis prophylaxis in patients undergoing urologic laparoscopy. *J Urol* 2004; 171(suppl):392.
165. Mayol J, Vincent HE, Sarmiento JM, et al. Pulmonary embolism following laparoscopic cholecystectomy: report of two cases and review of the literature. *Surg Endosc* 1994; 8:214.

166. Abad C, Caceres JJ, Alonso A. Fatal pulmonary embolism after laparoscopic cholecystectomy. *Surg Endosc* 2001; 15:1360.
167. Tsutsumi N, Tomikawa M, Konishi K, et al. Pulmonary embolism following laparoscopic surgery: a report of 2 cases. *Hepato-Gastroenterology* 2002; 49:719.
168. Schwenk W, Bohm B, Fugener A, Muller JM. Intermittent pneumatic sequential compression (ISC) of the lower extremities prevents venous stasis during laparoscopic cholecystectomy. A prospective randomized study. *Surg Endosc* 1998; 12:7.
169. Josephs LG, Este-McDonald JR, Birkett DH, Hirsch EF. Diagnostic laparoscopy increases intracranial pressure. *J Trauma* 1994; 36:815.
170. Poppas DP, Peters CA, Bilsky MH, Sosa RE. Intracranial pressure monitoring during laparoscopic surgery in children with ventriculoperitoneal shunts. *J Endourol* 1994; 8:S93.
171. Jackman SV, Weingart JD, Kinsman SL, Docimo SG. Laparoscopic surgery in patients with ventriculoperitoneal shunts: safety and monitoring. *J Urol* 2000; 164:1352.
172. Prentice JA, Martin JT. The Trendelenburg position. Anesthesiologic considerations. In: Martin JT, ed. *Positioning in Anesthesia and Surgery*. Philadelphia: W.B. Saunders, 1987:127.
173. Clayman RV, Kavoussi LR, Soper NJ, Albala DM, Figenshau RS, Chandhoke PS. Laparoscopic nephrectomy: review of the initial 10 cases. *J Endourol* 1992; 6:127.
174. Giaquinto D, Swigar K, Johnson MD. Acute congestive heart failure after laparoscopic cholecystectomy: a case report. *AANA J* 2003; 71:17.
175. Ben-David B, Croitoru M, Gaitini L. Acute renal failure following laparoscopic cholecystectomy: a case report. *J Clin Anesth* 1999; 11:486.
176. Cisek LJ, Gobet RM, Peters CA. Pneumoperitoneum produces reversible renal dysfunction in animals with normal and chronically reduced renal function. *J Endourol* 1998; 12:95.
177. Beduschi R, Beduschi MC, Williams AL, Wolf JS Jr. Pneumoperitoneum does not potentiate the nephrotoxicity of aminoglycosides in rats. *Urology* 1999; 53:451.
178. Nunn JF. *Oxygen. Applied Respiratory Physiology*. London: Butterworths, 1987:235.
179. Corall IM, Knights K, Potter D, Strunin L. Arterial oxygen tension during laparoscopy with nitrous oxide in the spontaneously breathing patient. *Br J Anaesth* 1974; 46:925.
180. Ott DE. Laparoscopic hypothermia. *J Laparoendosc Surg* 1991; 1:127.
181. Ott DE. Correction of laparoscopic insufflation hypothermia. *J Laparoendosc Surg* 1991; 1:183.
182. Backlund M, Kellokumpu I, Scheinin T, von Smitten K, Tikkanen I, Lindgren L. Effect of temperature of insufflated CO₂ during and after prolonged laparoscopic surgery. *Surg Endosc* 1998; 9:1126.
183. Bessel JR, Ludbrook G, Millard SH, Baxter PS, Ubhi SS, Maddern GJ. Humidified gas prevents hypothermia induced by laparoscopic insufflation. *Surg Endosc* 1999; 13:101.
184. Nelskyla K, Yli-Hankala A, Sjoberg J, Korhonen I, Korttila K. Warming of insufflation gas during laparoscopic hysterectomy: effect on body temperature and the autonomic nervous system. *Acta Anaesth Scand* 1999; 43:974.
185. Mouton WG, Bessel JR, Millard SH, Baxter PS, Maddern GJ. A randomized controlled trial assessing the benefit of humidified insufflation gas during laparoscopic surgery. *Surg Endosc* 1999; 13:106.
186. Nguyen NT, Furdui G, Fleming NW, et al. Effect of heated and humidified carbon dioxide gas on core temperature and post-operative pain. *Surg Endosc* 2002; 16:1050.
187. Teichman JMH, Floyd M, Hulbert JC. Does laparoscopy induce operative hypothermia? *J Endourol* 1994; 8:S92.

MODERN ABDOMINAL IMAGING: IMPLICATIONS FOR LAPAROSCOPIC SURGERY

Erick M. Remer and Joseph C. Veniero

Section of Abdominal Imaging, Division of Diagnostic Radiology, Cleveland Clinic Foundation, Cleveland, Ohio, U.S.A.

Brian R. Herts

Section of Abdominal Imaging, Division of Diagnostic Radiology and Glickman Urological Institute, Cleveland Clinic Foundation, Cleveland, Ohio, U.S.A.

- | | |
|--|--|
| <ul style="list-style-type: none"> ■ INTRODUCTION ■ COMPUTED TOMOGRAPHY ■ COMPUTED TOMOGRAPHY PROTOCOL FOR LAPAROSCOPIC SURGICAL PLANNING ■ MAGNETIC RESONANCE IMAGING ■ MAGNETIC RESONANCE PROTOCOL FOR LAPAROSCOPIC SURGICAL PLANNING | <ul style="list-style-type: none"> ■ IMAGE INTERPRETATION AND THREE-DIMENSIONAL VOLUME RENDERING ■ RADIOLOGICAL GUIDANCE DURING LAPAROSCOPIC SURGERY ■ POSTOPERATIVE IMAGING ■ SUMMARY ■ CONCLUSION ■ REFERENCES |
|--|--|

INTRODUCTION

Advances in both imaging capabilities and postprocessing methods have broadened the way in which radiologists can assist urologists in managing laparoscopic surgery patients. For instance, the days of merely characterizing and staging a renal tumor and then later assessing for recurrent or metastatic disease are now gone. The development of multislice computed tomography scanners that can rapidly obtain thin slice image data, advancements in magnetic resonance imaging software design and coil technology, the emergence of sophisticated three-dimensional rendering methods, and the development of laparoscopic ultrasound probes have now allowed the radiologist to participate in the planning of laparoscopic surgery, guiding its performance, and then following patients for possible complications or tumor recurrence.

The laparoscopic urologist must have an accurate understanding of the renal parenchymal and vascular anatomy and tumor location to preserve normal renal tissue and, thus, preserve renal function (1,2).

Imaging methods must now provide anatomic information not previously considered when interpreting computed tomography scans, such as a description or demonstration of the arterial anatomy, venous anatomy, and tumor location and extension into the parenchyma or central renal sinus. The proximity of the tumor to the vascular structures and the pelvocalyceal system, and the number and course of both ureters must also be identified (3–6).

Accurate surgical planning information helps to minimize postoperative complications, such as urinary leak or renal infarct, and to maximize preserved renal parenchyma.

The radiologist's role has also expanded into the operating room. Imaging is frequently used during nephron-sparing surgery. Intraoperative ultrasound is used to localize a tumor, to identify and characterize any additional lesions, and to demarcate surgical margins. Ultrasonography can be performed laparoscopically using specially designed ultrasound transducers. When ablative techniques such as laparoscopic radiofrequency or cryoablation are performed, ultrasound is used to monitor the ablation. After surgery, magnetic resonance or computed tomography is used to assess the success of an ablation and to follow the patient for complications, local recurrence, and metastatic disease.

This chapter discusses the use of computed tomography and magnetic resonance as surgical planning tools specifically for nephron-sparing laparoscopic surgery, although many of these principles have been applied in several other areas of urologic surgery. Dedicated computed tomography and magnetic resonance imaging protocols, their importance for surgical planning, and the use of three-dimensional renderings will be discussed. A discussion of intraoperative laparoscopic ultrasound for nephron-sparing surgery and tumor ablation will follow. Lastly, postoperative imaging follow-up will be discussed.

The laparoscopic urologist must have an accurate understanding of the renal parenchymal and vascular anatomy and tumor location to preserve normal renal tissue and thus preserve renal function.

Accurate surgical planning information helps to minimize postoperative complications, such as urinary leak or renal infarct, and to maximize preserved renal parenchyma.

computed tomography is considered the gold standard for detection, diagnosis, and staging of renal cell carcinoma.

Magnetic resonance is often reserved for problem solving, or for those patients with renal insufficiency or a history of severe allergy to iodinated contrast.

COMPUTED TOMOGRAPHY

Computed tomography is considered the gold standard for detection, diagnosis, and staging of renal cell carcinoma (7,8).

However, both computed tomography (9–14) and magnetic resonance (15,16) are highly sensitive and specific for the detection of solid renal masses and can characterize cystic renal lesions. Magnetic resonance has higher soft-tissue contrast resolution and is more sensitive to intravenous contrast enhancement than computed tomography, but spatial resolution and availability are less than that of computed tomography.

Magnetic resonance is often reserved for problem solving, or for those patients with renal insufficiency or a history of severe allergy to iodinated contrast.

Either computed tomography or magnetic resonance imaging can be used for surgical planning (7,8,15–19). Success with 3-D real-time rendering using computed tomography datasets has led to a preferential use of computed tomography by most centers.

Computed tomography examinations are performed before and after intravenous contrast, but without oral barium contrast because positive enteric contrast material interferes with three-dimensional renderings.

- Patients with a normal or mildly elevated creatinine level (below 2.0 mg/dL) are given a full dose of low-osmolar nonionic contrast agent.
- Patients with any degree of renal insufficiency are instructed to drink fluids after the scan.
- Patients with elevated creatinine levels between 2.0 and 2.5 mg/dL are hydrated intravenously with 0.9 normal saline solution before the examination and also instructed to drink fluids after the scan. Iso-osmolar contrast agents are recommended in these patients because of the reduced nephrotoxicity that has been reported in studies evaluating renal function after coronary angiography (20).
- Patients with creatinine levels of 2.5 g/dL or higher are referred for magnetic resonance imaging, which avoids the increased risk for nephrotoxicity in already compromised kidneys. Also, when renal function is poor, the enhancement of normal parenchyma that is needed in order to detect small tumors does not occur.

Developments in computed tomography technology have been dramatic in the last 15 years. Spiral or helical computed tomography was developed in the early 1990s. This revolutionary advancement allows for the constant acquisition of computed tomography data while the patient moves through the scanner gantry, with the X-ray tube rotating continuously around him. Rather than the individual slices that were obtained with prior nonspiral technology, a volume of data is acquired. To better depict anatomy or pathology, this volume can then be reformatted electronically into planes other than the axial plane in which it was obtained. Additional advantages of spiral technology include faster image acquisition, so that the dynamics of contrast enhancement can be exploited and motion artifacts reduced. By late 1998, computed tomography manufacturers developed a further advancement consisting of multirow detector arrays (multirow or multislice helical computed tomography) (21). Rather than one X-ray detector row encircling the patient as he moves through the scanner, multiple rows of detectors are used in this advanced model. In addition to further increasing the speed of scanning compared to single row scanners, multiple row scanners achieve true isotropic voxel (volume element) resolution. The elements that are summed up to make an image are cubic and, therefore, can be reformatted in any plane and be equally sharp. This development has allowed for true three-dimensional imaging.

Three-phase computed tomography protocols are the state-of-the-art for imaging the kidneys and provide all the necessary information for surgical planning for laparoscopic surgery.

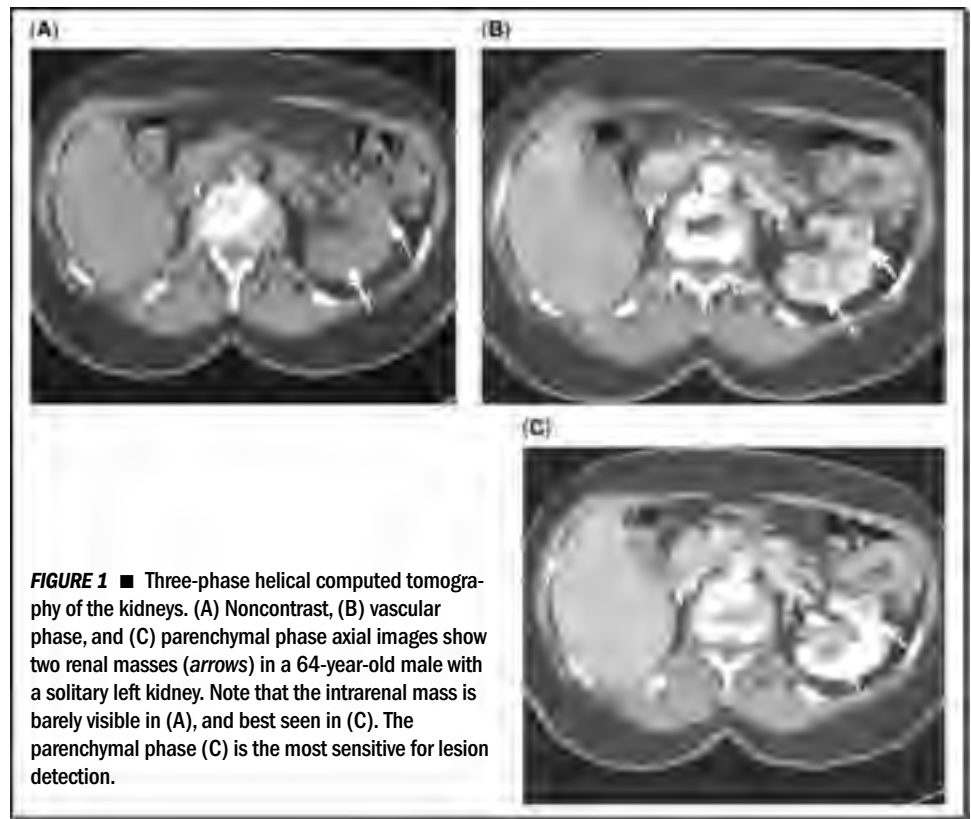
COMPUTED TOMOGRAPHY PROTOCOL FOR LAPAROSCOPIC SURGICAL PLANNING

Three-phase computed tomography protocols are the state-of-the-art for imaging the kidneys and provide all the necessary information for surgical planning for laparoscopic surgery (Fig. 1) (3–5).

These scans should be performed on a multidetector helical scanner, which allows efficient use of intravenous contrast and facilitates creating thin-slice datasets for smooth two-dimensional and three-dimensional reformations.

The first scan phase is a noncontrast computed tomography scanning of the abdomen, including the adrenal glands and both kidneys. This is essential not only to plan the contrast study, but because it provides baseline attenuation value for all renal masses and detects calcifications in the urinary tract and renal lesions.

The second scan phase is a vascular phase computed tomography scan (22). The timing for this phase is determined either by scanning after a test bolus of 20 mL of contrast injected at 3 or 4 mL/sec or by using an automated bolus-tracking technique set to trigger from a threshold value set from enhancement in the upper abdominal aorta. Because extra time is needed to ensure enhancement of the renal



veins, an additional five seconds is added. Most scan delays are between 25 and 35 seconds in otherwise healthy patients.

The third scan phase is obtained during the parenchymal or nephrographic phase of enhancement, after a delay of 120 to 150 seconds from the initiation of the bolus contrast injection (the longer delay times are used for older patients or patients with cardiac dysfunction). The parenchymal phase scan is the most sensitive and specific for lesion detection and characterization, but the vascular phase scan is also useful when characterizing masses (7,9–11,15,16,22).

For each scan phase, thin sections (typically 3 mm) are reconstructed without image overlap for diagnostic interpretation and filming. Softcopy (electronic) reading is recommended using a picture archiving and communication system workstation.

In addition to the 3 mm slices for diagnostic interpretation, a separate set of 1 mm thick slices with 20% overlap (reconstruction interval of 0.8 mm) are created and used for multiplanar reformations and three-dimensional real-time volume rendering reconstructions.

The thin slices with image overlap improve the smoothness of reformations and three-dimensional rendering. The computed tomography data is depicted in an imaging plane other than the axial by a process called “multiplanar reformation.” multiplanar reformations that are true sagittal and coronal oblique images oriented parallel to the long axis of the kidney are helpful for localization of the tumor within the kidney and are sent to the referring urologist with the diagnostic images. Summing up the highest attenuation pixels within a volume creates a maximum intensity projection.

Thin-section (3–5 mm thickness) coronal oblique thin-slab maximum intensity projections through the aorta and kidneys are helpful for delineating the renal vasculature.

These thin-slab maximum intensity projection images improve visualization of the renal vasculature and facilitate measurements of the distance to first renal arterial branches and distances between renal arterial ostia in those patients with multiple renal arteries. These multiplanar reformations and maximum intensity projection reformations are performed at the scanner console by the technologists using the thin-section (1 mm) dataset and sent for image review along with the diagnostic axial images (Figs. 2 and 3).

MAGNETIC RESONANCE IMAGING

As with computed tomography evaluations, the preoperative evaluation for laparoscopic surgery with magnetic resonance also includes both pre- and postcontrast

In addition to the 3 mm slices for diagnostic interpretation, a separate set of 1 mm thick slices with 20% overlap (reconstruction interval of 0.8 mm) are created and used for multiplanar reformations and three-dimensional real-time volume rendering reconstructions.

Thin-section (3–5 mm thickness) coronal oblique thin-slab maximum intensity projections through the aorta and kidneys are helpful for delineating the renal vasculature.

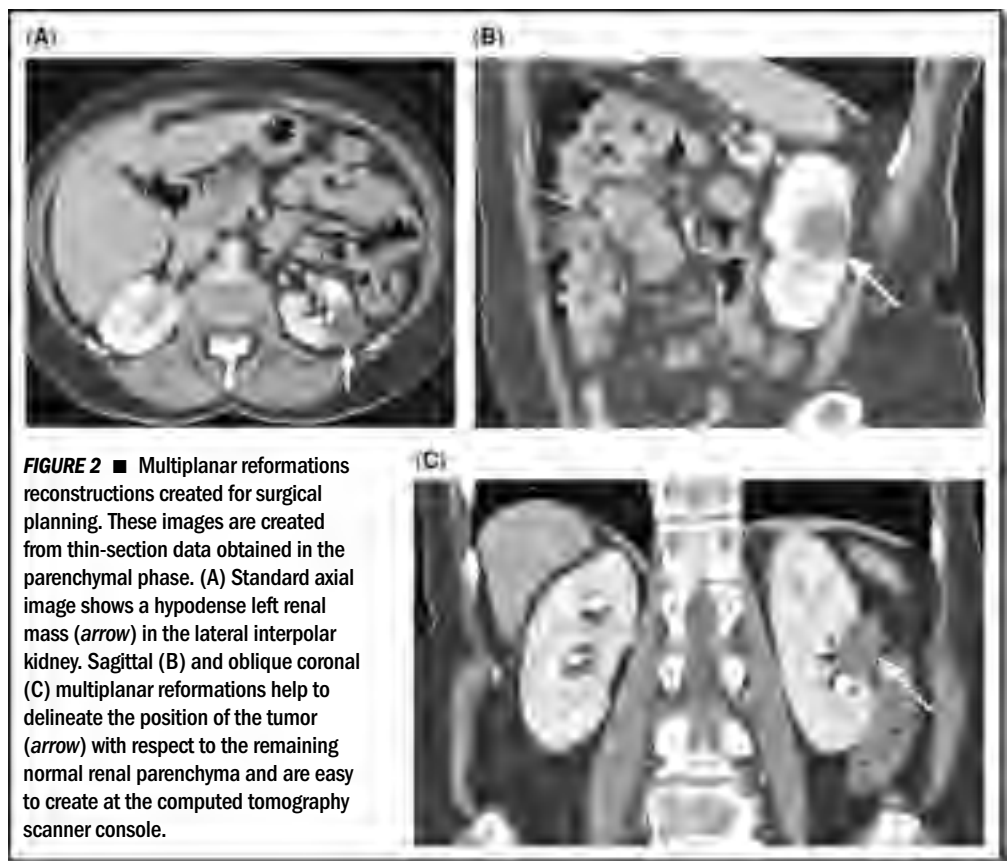


FIGURE 2 ■ Multiplanar reformations reconstructions created for surgical planning. These images are created from thin-section data obtained in the parenchymal phase. (A) Standard axial image shows a hypodense left renal mass (arrow) in the lateral interpolar kidney. Sagittal (B) and oblique coronal (C) multiplanar reformations help to delineate the position of the tumor (arrow) with respect to the remaining normal renal parenchyma and are easy to create at the computed tomography scanner console.

FIGURE 3 ■ Thin-slab maximum intensity projection reconstruction. This image created for surgical planning is created from thin-section data obtained in the vascular phase. Coronal oblique maximum intensity projection through the aorta shows two right renal arteries (arrows).



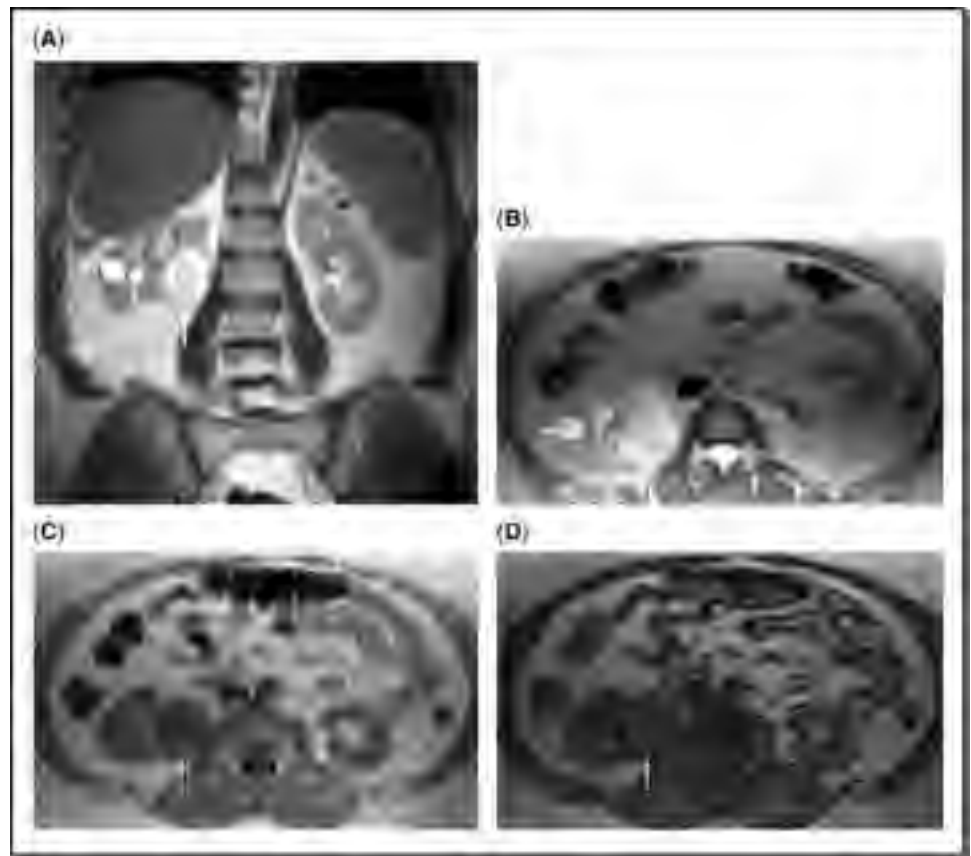
exams (23). As in most body magnetic resonance imaging, the precontrast T1- and T2-weighted imaging is performed to evaluate anatomy, identify abnormalities, and begin characterizing any identified renal or adrenal lesions (Fig. 4). Following intravenous gadolinium administration, postcontrast T1-weighted sequences are performed in multiple phases to define the enhancement characteristics of lesions and to define the anatomy for surgical planning, specifically the arterial, venous, and collecting system anatomy.

The importance of patient preparation and general technique in body magnetic resonance imaging cannot be understated. Anterior and posterior phased array surface coils, rather than a body coil, should be used to increase the signal and must be positioned over the kidneys. Patient motion during image acquisition, including respiratory motion, leads to image blurring and artifacts. Eliminating this motion is an important factor in improving imaging quality in body magnetic resonance imaging. In addition to eliminating image artifacts from respiratory motion, the reproducible suspension of respiration is needed to take advantage of a variety of postprocessing techniques.

The most sensitive technique used to determine the presence of lesion enhancement is image subtraction.

The most sensitive technique used to determine the presence of lesion enhancement is image subtraction.

FIGURE 4 ■ Precontrast T1- and T2-weighted magnetic resonance images. Coronal (A) and axial (B) precontrast, T2 weighted (half-Fourier single-shot turbo spin echo) show the heterogeneous mixed intensity of this exophytic renal cell carcinoma (arrow), a homogeneously hyperintense simple cortical cyst (arrowhead), and a distended collecting system in the right kidney (thin arrow). (C) Axial, in-phase and (D) out-of-phase, precontrast T1-weighted images showing the generally low-precontrast, T1-weighted signal of a renal cell carcinoma (arrow).



To perform accurate image subtraction, the datasets to be manipulated must be nearly perfectly aligned in three-dimensional space. Thus, this technique requires reproducible breath holding. This is especially true for evaluating small lesions.

In anxious, nervous, or claustrophobic patients, using mild anxiolytic medication can allow diagnostic studies to be carried out in patients who would otherwise be unable to follow instructions.

With this technique, images obtained before intravenous contrast are mathematically subtracted from images obtained with contrast, so that any remaining signal intensity represents enhancement.

To perform accurate image subtraction, the datasets to be manipulated must be nearly perfectly aligned in three-dimensional space. Thus, this technique requires reproducible breath holding. This is especially true for evaluating small lesions.

To obtain motion-free imaging with specific temporal resolution, the magnetic resonance sequences are kept as short as possible and patients are asked to hold their breath during image acquisition at end expiration. Breath holding is done during end expiration because it is more reproducible. This can be a challenge for some patients; in those who have difficulty suspending respiration at end expiration, hyperventilation and supplemental oxygen can allow longer breath holds, enabling examinations of a much higher quality.

In anxious, nervous, or claustrophobic patients, using mild anxiolytic medication can allow diagnostic studies to be carried out in patients who would otherwise be unable to follow instructions.

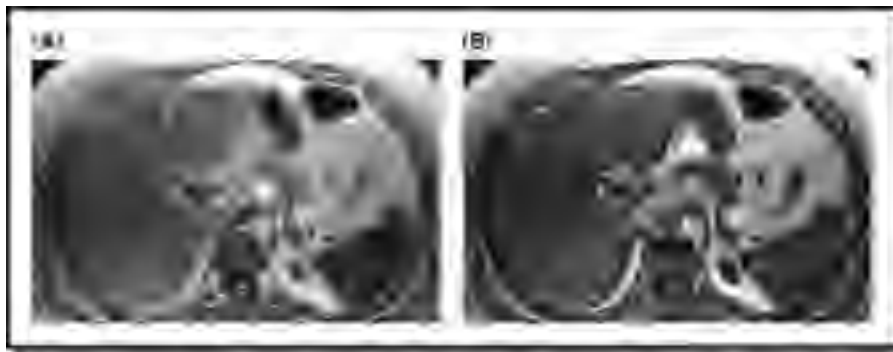
MAGNETIC RESONANCE PROTOCOL FOR LAPAROSCOPIC SURGICAL PLANNING

T1-weighted in- and out-of-phase images are obtained using a two-dimensional fast gradient echo sequence without fat saturation. On this sequence, voxels (volume elements) containing both fat and water will have a degree of signal cancellation leading to signal-intensity loss or signal dropout on the out-of-phase images when compared to the in-phase images. Thus, tissue such as lipid-rich adrenal adenomas and liver with fatty infiltration with intracellular or microscopic fat are identified by signal dropout on the out-of-phase images (Fig. 5). A T1-weighted sequence with frequency-specific fat saturation is also employed to identify regions of bulk or macroscopic fat, such as that seen in an angiomyolipoma. This is one of the same sequences used after contrast administration.

Two goals are achieved by acquiring precontrast and postcontrast data using the same sequence: the precontrast images identify bulk and macroscopic fat, and postprocessing can be performed using the precontrast sequence as a mask for image subtraction.

Two goals are achieved by acquiring precontrast and postcontrast data using the same sequence: the precontrast images identify bulk and macroscopic fat, and postprocessing can be performed using the precontrast sequence as a mask for image subtraction.

FIGURE 5 ■ Axial in-phase (A) and out-of-phase (B) precontrast T1-weighted images of an incidental adrenal mass (arrow) in a patient with a renal tumor. There is signal dropout on the out-of-phase image, indicating fat in an adrenal adenoma.



Because intravenous contrast volume is small in magnetic resonance imaging, there is typically only a 10-second window of ideal arterial opacification. Therefore, obtaining the proper timing for scans obtained during the arterial phase of imaging is critical.

In patients whose lesions approach the renal sinus, it is desirable to distend the calyces in order to better assess calyceal involvement. Administration of a small dose (10 mg) of intravenous furosemide during the timing examination will promote diuresis, distending the collecting system to achieve a better quality magnetic resonance urogram.

Tumor size, renal vein, and inferior vena cava tumor thrombus, and lymphadenopathy are all criteria used for staging. If the patient is a nephron-sparing surgery candidate, images are transferred to a dedicated three-dimensional imaging workstation for postprocessing, typically using real-time volume-rendering techniques.

Next, T2-weighted images are obtained to detect and evaluate areas of fluid including cystic lesions and the collecting system. These are generally obtained using fast techniques, either fast or turbo spin echo, or single shot fast spine echo or half-Fourier acquisition single-shot turbo spin-echo.

Because intravenous contrast volume is small in magnetic resonance imaging, there is typically only a 10-second window of ideal arterial opacification. Therefore, obtaining the proper timing for scans obtained during the arterial phase of imaging is critical.

A timing examination has been proven useful to consistently obtain images during the arterial phase of contrast enhancement.

Postcontrast imaging is obtained in multiple phases using a gradient echo T1-weighted, three-dimensional interpolated, fat-saturated sequence. This allows a slice resolution of 1.5 mm for images in the coronal plane and 2 mm for images in the axial plane. In-plane resolution for the sequences is at or below the slice thickness. This yields near isotropic voxels and allows data manipulation in multiple planes. Both arterial and venous phase imaging in the coronal plane is obtained using an angiographic sequence. This sequence tends to suppress background tissue signal, thereby highlighting vascular structures (24). Following this, anatomic imaging in the axial plane is obtained during the cortical phase of renal enhancement using a more tissue-sensitive sequence (25). Accurate assessment of the vasculature and characterization of renal lesions is possible by combining these different techniques.

To obtain an magnetic resonance urogram, coronal images are obtained at about 5 to 10 minutes after contrast administration.

In patients whose lesions approach the renal sinus, it is desirable to distend the calyces in order to better assess calyceal involvement. Administration of a small dose (10 mg) of intravenous furosemide during the timing examination will promote diuresis, distending the collecting system to achieve a better quality magnetic resonance urogram.

In patients who are not on chronic furosemide therapy, a dose of 10 mg given intravenously is almost always adequate. For patients who are on chronic therapy, dosage adjustments must be made.

IMAGE INTERPRETATION AND THREE-DIMENSIONAL VOLUME RENDERING

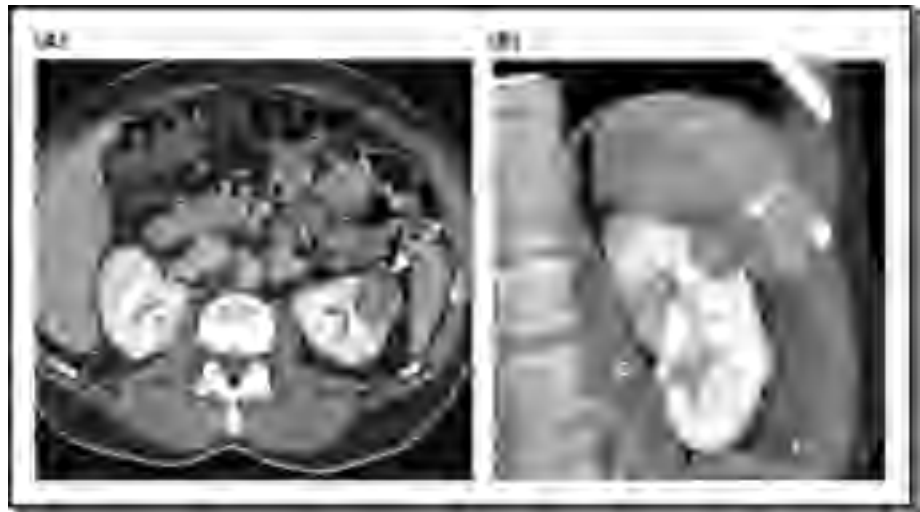Computed tomography and magnetic resonance images are reviewed to characterize all lesions for lesion size and location and to determine the number of arteries and veins; whether it is local, regional, or distant lymphadenopathy; the presence of renal vein tumor extension; and if it is a local or regional metastatic disease.

Tumor size, renal vein, and inferior vena cava tumor thrombus, and lymphadenopathy are all criteria used for staging. If the patient is a nephron-sparing surgery candidate, images are transferred to a dedicated three-dimensional imaging workstation for postprocessing, typically using real-time volume-rendering techniques (26).

In the past, surface-shaded display renderings have been used for nephron-sparing surgical planning, but they are limited by the need for intensive image editing, which is too time consuming for most radiologists. As shown in Figures 6 and 7, volume rendering typically requires little image editing and preserves the entire dataset (3,4,26,27).

To film images from the diagnostic study, a computed tomography technologist can perform multiplanar reformations and maximum intensity projections easily. However,

FIGURE 6 ■ Volume rendering of renal tumor before nephron-sparing surgery. (A) Conventional axial image and (B) volume-rendered image. Volume rendering uses the entire dataset and projects a three-dimensional view of the renal tumor (*arrow*). The psoas muscle (p) and spleen (s) are seen and provide relational cues to interpreting the image.



because of the quality of information needed for surgical planning, the radiologist typically uses a dedicated three-dimensional workstation to perform real-time three-dimensional volume rendering.

- Although a set of static images, either digital or filmed, may also suffice, our current practice is to create one or two short MPEG-encoded (.avi) digital movie files for each case, which illustrates the critical anatomy for surgical planning.

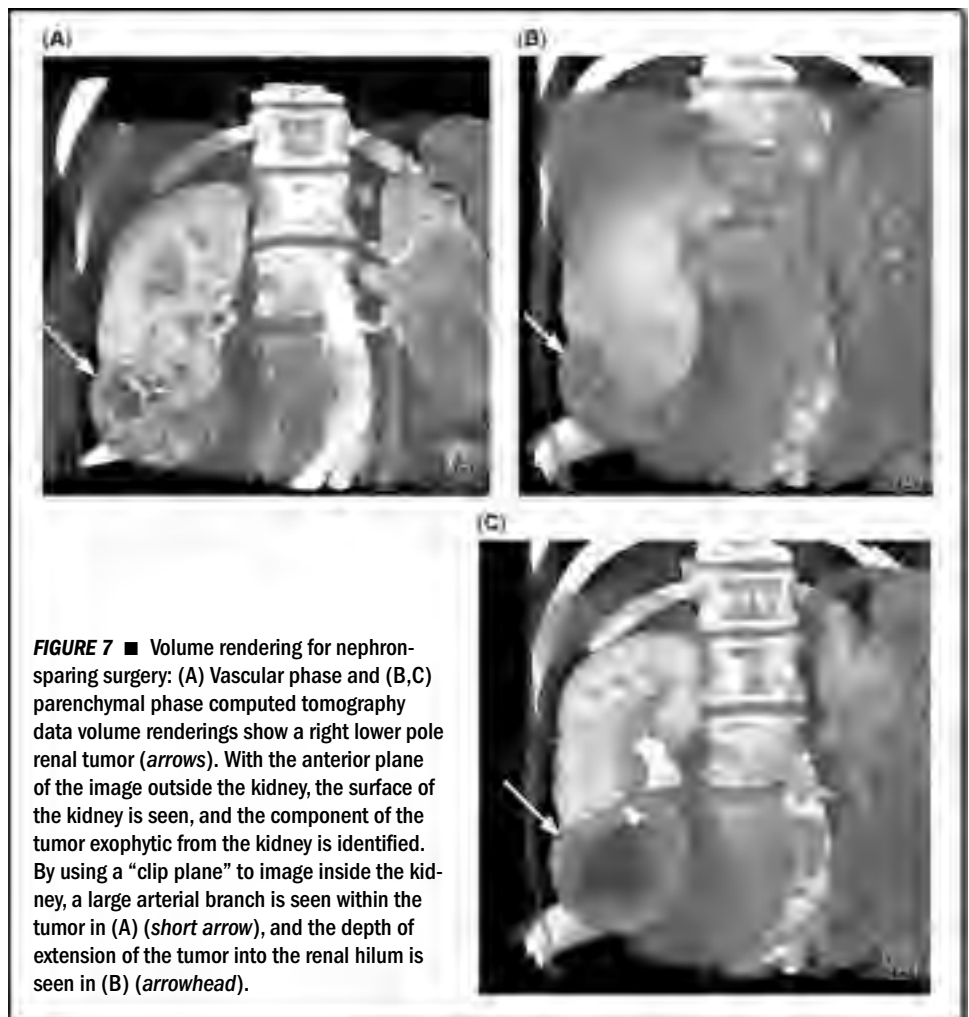

FIGURE 7 ■ Volume rendering for nephron-sparing surgery: (A) Vascular phase and (B,C) parenchymal phase computed tomography data volume renderings show a right lower pole renal tumor (*arrows*). With the anterior plane of the image outside the kidney, the surface of the tumor exophytic from the kidney is identified. By using a “clip plane” to image inside the kidney, a large arterial branch is seen within the tumor in (A) (*short arrow*), and the depth of extension of the tumor into the renal hilum is seen in (B) (*arrowhead*).

- At our institution, the anatomical structures and relationships shown by three-dimensional imaging were defined in conjunction with a urologist highly experienced in performing nephron-sparing surgery.
- A thorough discussion between the radiologist and the referring urologist regarding their surgical approach and surgical planning needs is recommended.

Control of the renal vasculature is necessary during nephron-sparing surgery and, therefore, the renal vessels are rendered first. This portion of the rendering shows the size, origin, and course of all renal arteries, renal veins, major segmental arterial branches, left adrenal vein, gonadal vein, and any prominent lumbar veins (Figs. 8–11). Next, using the renal parenchymal phase, renderings show the position of the kidney, tumor location, and depth of tumor extension and its relationship to the pelvocalyceal system (Fig. 12). The rendering process takes between 10 and 30 minutes, depending on the user's experience and case complexity.

Postcontrast three-dimensional magnetic resonance datasets are manipulated and displayed in the same manner as computed tomography data, using a combination of the postcontrast image series. Image subtraction facilitates data analysis and display. Subtraction of the precontrast data from the cortical phase data results in a dataset that can then be used to assess true enhancement within renal lesions, and facilitates the characterization of the lesion (Fig. 13). A gadolinium-enhanced three-dimensional gradient echo magnetic resonance sequence provides inherent suppression of background signal and gives excellent volume-rendered views of the renal vasculature (Fig. 14). Subtraction of the precontrast data from the arterial phase data results in a dataset that has high signal

FIGURE 8 ■ Conventional left renal vascular anatomy: Volume-rendered image of the left kidney during the vascular phase shows (A) single left artery (*arrow*) and (B) single left renal vein (*arrow*).

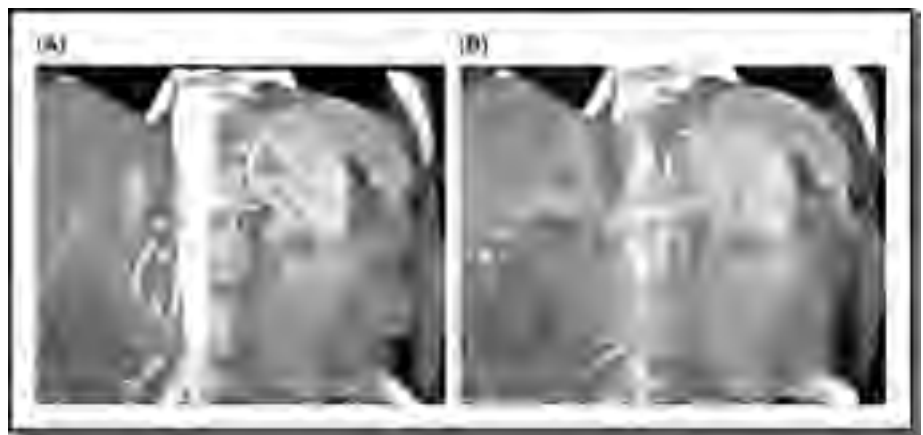
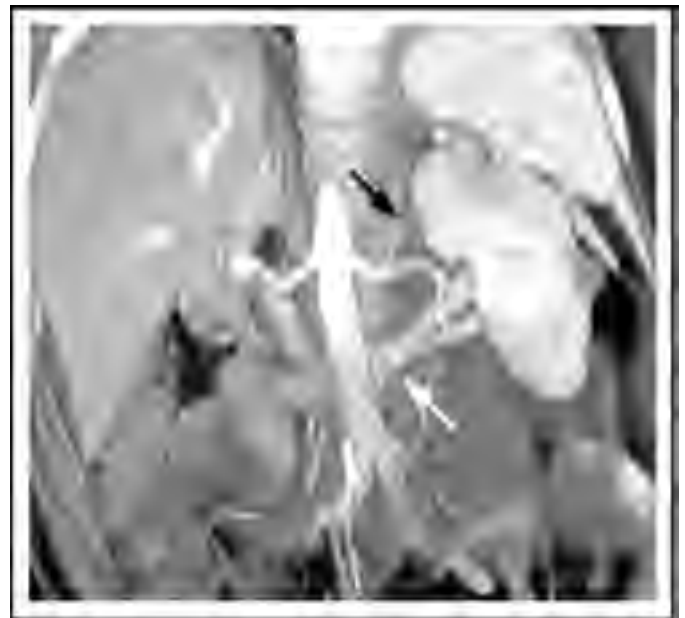

FIGURE 9 ■ Anatomic left renal arterial and vein variants. An early apical polar branch is seen (*black arrow*) supplying the upper pole of the left kidney entering from the cortex. A retroaortic left renal vein (*arrow*) is also identified; retroaortic left renal veins usually cross behind the aorta several centimeters below the level of the renal artery.



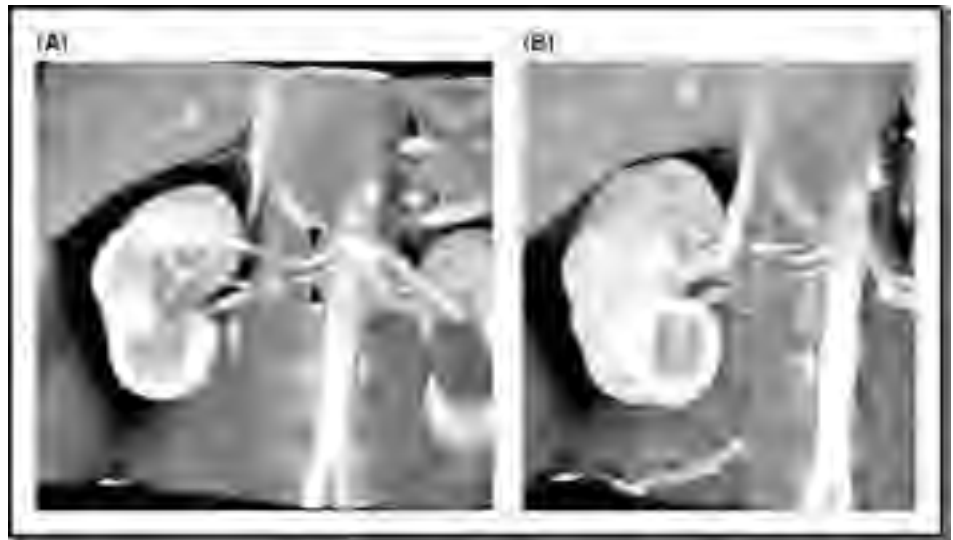


FIGURE 10 ■ Anatomic right renal arterial and vein variants. (A) Two right renal artery origins are seen (arrowhead) along with an accessory right renal vein (arrow). (B) The main right renal vein is seen (arrow) along with an unusual branch of the vein (long thin arrow) that results in a third renal vein entrance into the inferior vena cava. The plane in image (B) is slightly more anterior than in image (A).

The enhanced images obtained during the venous phase are useful in assessing vascular invasion (Fig. 15).

contrast within the arteries and suppressed signal in the rest of the image. These can then be used to produce angiographic images, such as maximum intensity projections, with minimal additional editing (28).

The enhanced images obtained during the venous phase are useful in assessing vascular invasion (Fig. 15).

Sequences acquired or reconstructed in the coronal or sagittal plane yield diagnostic information and help localize a lesion within the kidney.

RADIOLOGIC GUIDANCE DURING LAPAROSCOPIC SURGERY

Intraoperative guidance for partial nephrectomy using laparoscopic ultrasound and guidance for laparoscopic tumor ablation is another important role for imaging during nephron-sparing surgery. Dedicated intraoperative probes, which yield high-resolution

FIGURE 11 ■ Accessory right renal artery. Vascular phase volume rendering shows an accessory right renal artery (arrow). Right renal arteries that arise from inferior side of the inferior vena cava, off the aorta, often course anterior to the inferior vena cava, as in this patient.

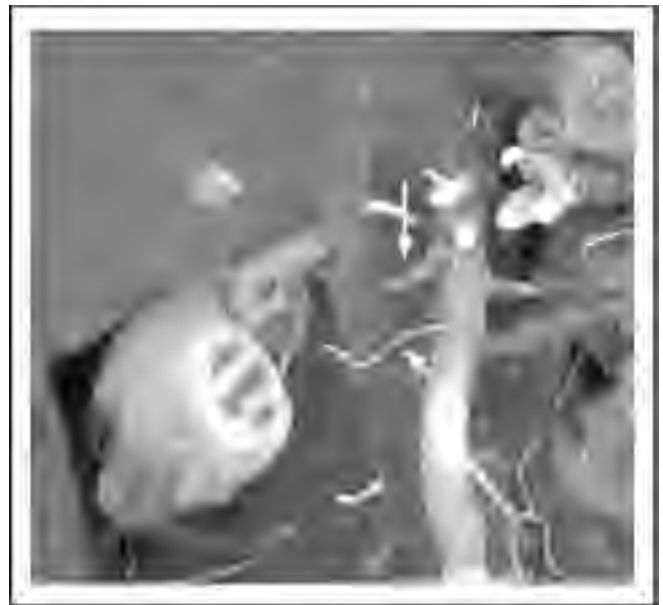
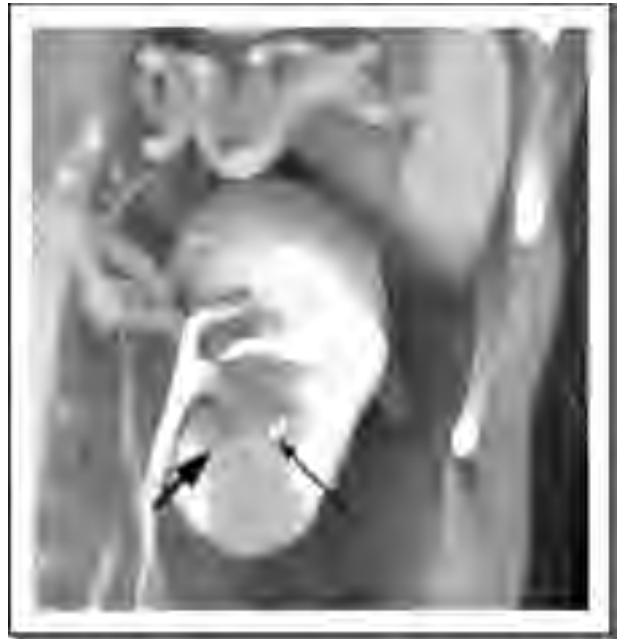
FIGURE 12 ■ Depth of tumor extension. Tumors that extend into the renal hilum (*arrow*) will often abut larger vessels and the pelvocalyceal system (*thin arrow*). This is important for the urologist, who may opt for conservative surgery or be ready to anticipate repair of the collecting system and cauterize the vasculature.



The laparoscopic ultrasound transducer is constructed with the transducer elements on a flexible arm that fits through a 10 mm laparoscopic port. The transducer elements can typically be steered into different positions, although limited by the access ports and flexibility of the transducer. Doppler capability is helpful to identify vascular structures in proximity to the surgical site.

images, are used for intraoperative ultrasound during partial nephrectomy, whether open or laparoscopic (Fig. 16) (29). Such probes are smaller in size than conventional probes, and are shaped for the laparoscopic operative environment. The ultrasound transducer can be placed directly on the surface of the kidney during an open partial nephrectomy.

The laparoscopic ultrasound transducer is constructed with the transducer elements on a flexible arm that fits through a 10 mm laparoscopic port. The transducer elements can typically be steered into different positions, although limited by the access ports and flexibility of the transducer. Doppler capability is helpful to identify vascular structures in proximity to the surgical site.

During open partial nephrectomy, the urologist can palpate masses that extend to the renal surface. In this setting, ultrasound is used to localize small intrarenal

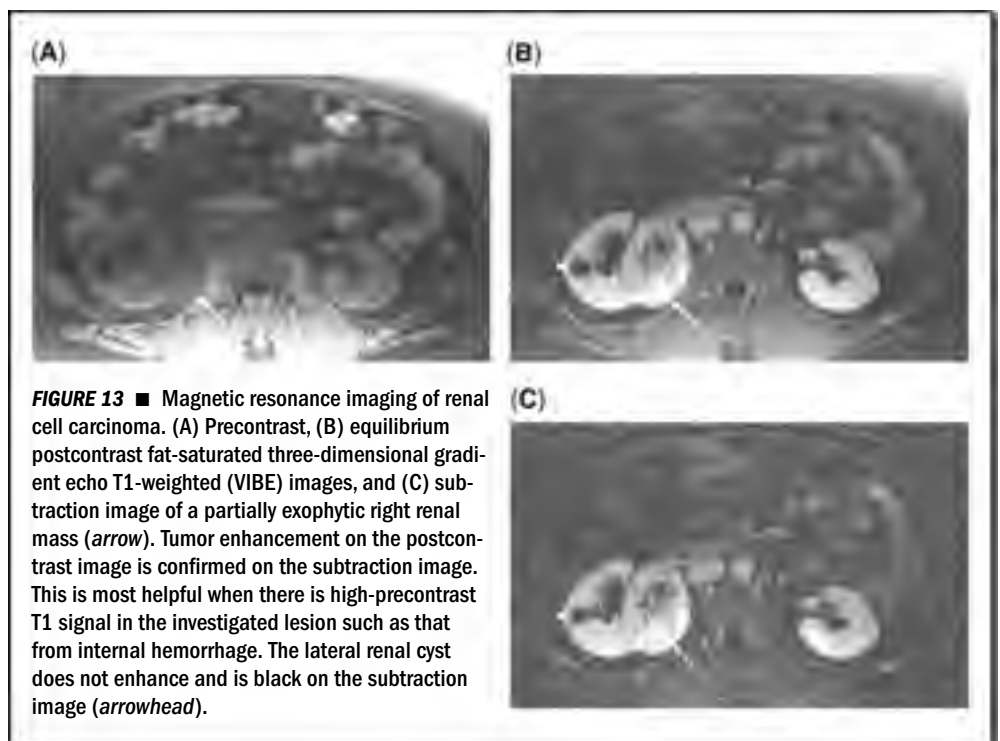


FIGURE 13 ■ Magnetic resonance imaging of renal cell carcinoma. (A) Precontrast, (B) equilibrium postcontrast fat-saturated three-dimensional gradient echo T1-weighted (VIBE) images, and (C) subtraction image of a partially exophytic right renal mass (*arrow*). Tumor enhancement on the postcontrast image is confirmed on the subtraction image. This is most helpful when there is high-precontrast T1 signal in the investigated lesion such as that from internal hemorrhage. The lateral renal cyst does not enhance and is black on the subtraction image (*arrowhead*).

FIGURE 14 ■ Volume-rendered arterial phase magnetic resonance for renal vasculature. Both the main right renal artery (*arrowhead*) and a small inferior accessory renal artery (*thin arrow*) are demonstrated on this volume-rendered angiogram. The partially exophytic tumor (*arrow*) is also seen. The arterial phase fat-saturated three-dimensional gradient echo T1-weighted (FLASH) data were used to create the image.

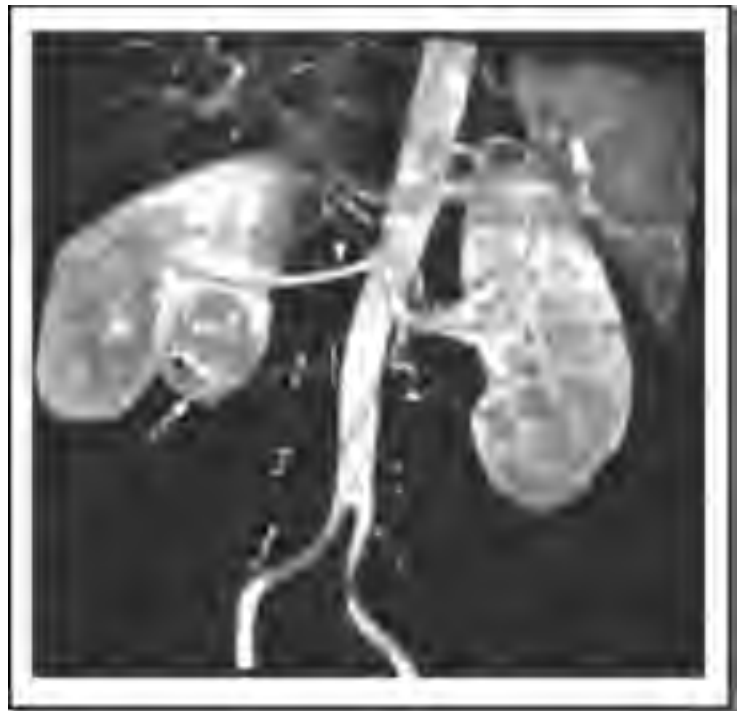

FIGURE 15 ■ Renal vein evaluation by magnetic resonance. Oblique, coronal, thin, maximum-intensity, projection images show two right renal veins (A, *arrows*) and left renal vein expanded by tumor thrombus (B, *arrow*) that does not extend to the inferior vena cava but is seen to extend into the left adrenal vein (*arrowhead*). The images are derived from the equilibrium phase postcontrast fat-saturated 3-D gradient echo T1-weighted (VIBE) data.

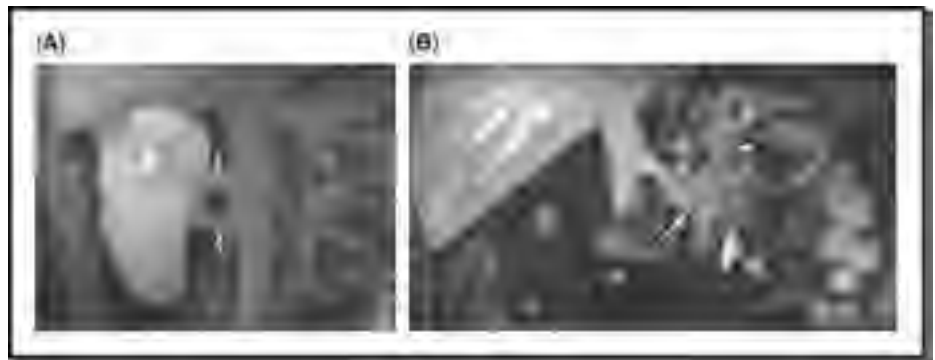
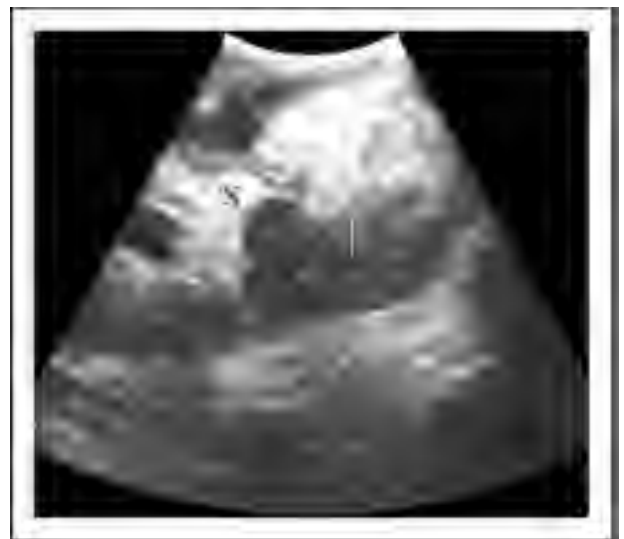

FIGURE 16 ■ Intraoperative laparoscopic ultrasound shows an ovoid hyperechoic mass (*arrows*) that extends from the lower pole into the hyperechoic fat of the central renal sinus (S).



During laparoscopic partial nephrectomy, unless a hand-assisted procedure is performed, the ability of ultrasound to localize a renal mass is invaluable, because the tactile cues available during open surgery are not available.

Laparoscopic ultrasound is also used to guide and monitor both cryoablation and radiofrequency ablation of renal masses.

Ultrasound findings correlate well with the actual size and location of the iceball at surgery. Scanning from the surface opposite the cryotherapy probe ensures that shadowing does not obscure deep margin and protects the probe from the cryoablation. Using multiple probe positions (i.e., rotating and translating the probe along the renal surface) may be necessary to ensure complete ablation. Extension of the iceball more than 3 mm beyond the tumor margin ensures adequate freezing of the lesion for cell death.

masses and assess the proximity to the central sinus structures, the pyelocalyceal system, and vessels. The margins of the mass are determined using ultrasound and subsequently demarcated on the renal surface using the electrocautery to score the kidney surface. A search for additional lesions that may not have been identified on preoperative imaging is also performed.

During laparoscopic partial nephrectomy, unless a hand-assisted procedure is performed, the ability of ultrasound to localize a renal mass is invaluable, because the tactile cues available during open surgery are not available.

Most masses treated laparoscopically are small, and some may not be visible on the renal surface. After identifying the mass by ultrasound, the surface of the kidney is scored using electrocautery as during the open procedure.

Laparoscopic ultrasound is also used to guide and monitor both cryoablation and radiofrequency ablation of renal masses.

The position of the mass, as determined by preoperative imaging and any history of prior retroperitoneal or abdominal surgery, is the information used to determine the laparoscopic approach. Once the kidney is mobilized and fat excised for pathological analysis, the tumor and remainder of the kidney are imaged with ultrasound. The mass is biopsied and then punctured with the ablative probe under ultrasound guidance. The probe is visualized as an echogenic line that casts an acoustic shadow.

The critical steps of cryoablation are rapid freezing, slow thawing, and repetition of the freeze-thaw cycle (30,31). The cryoprobe tip is advanced to the deep margin of the mass. The probe tip defines the deep margin of the ablation zone. Cryoablation, unlike radiofrequency ablation, creates a distinct margin of the ablated tissue on ultrasound. The deep margin of the tumor is most at risk for incomplete ablation (32). As cryoablation progresses, an iceball is seen as hyperechoic arc with posterior shadowing (Fig. 17).

Ultrasound findings correlate well with the actual size and location of the iceball at surgery. Scanning from the surface opposite the cryotherapy probe ensures that

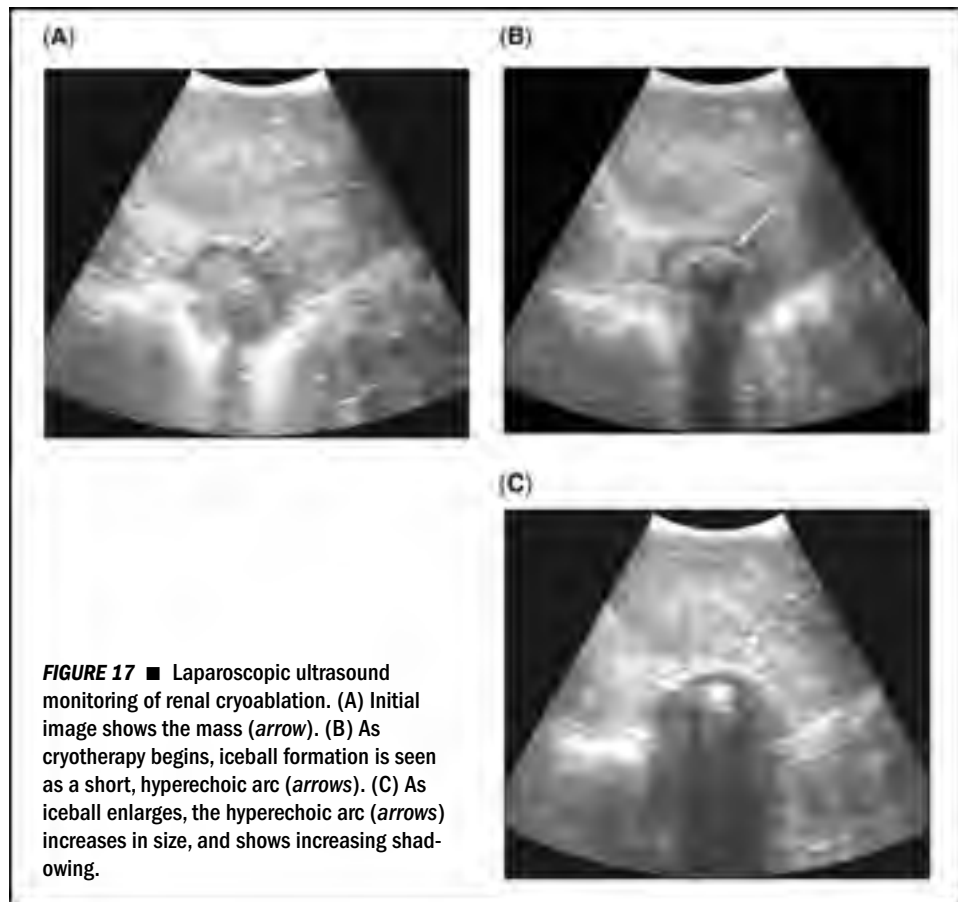
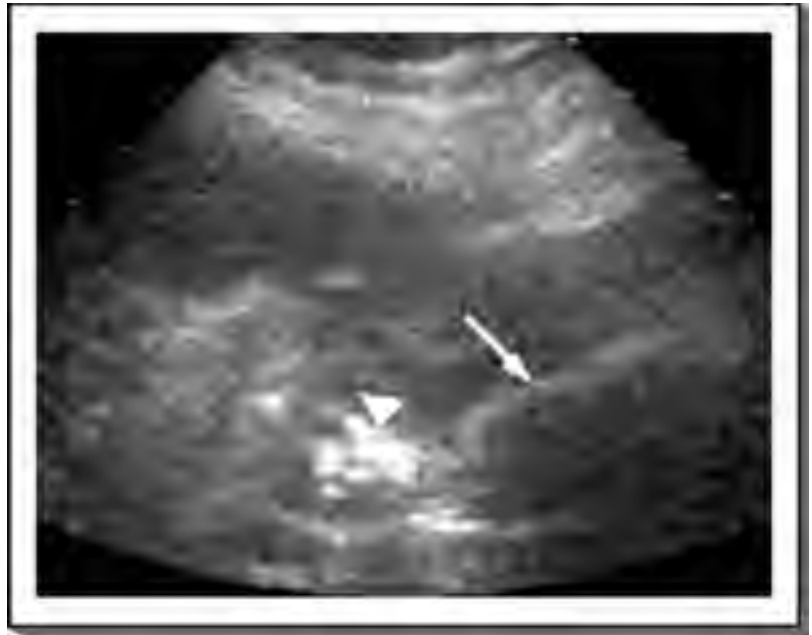

FIGURE 17 ■ Laparoscopic ultrasound monitoring of renal cryoablation. (A) Initial image shows the mass (arrow). (B) As cryotherapy begins, iceball formation is seen as a short, hyperechoic arc (arrows). (C) As iceball enlarges, the hyperechoic arc (arrows) increases in size, and shows increasing shadowing.

FIGURE 18 ■ Percutaneous ultrasound guidance for renal radiofrequency ablation. The radiofrequency ablation electrode is seen as a linear echogenic structure (arrow). As the procedure continues, additional bright echoes (arrowhead) obscure the renal mass.



During radiofrequency ablation, the extent of coagulation cannot accurately be predicted, and postprocedural imaging is necessary in order to assess the success of the ablation.

Patients are seen at four to six weeks after open partial nephrectomy for routine follow-up and have a physical examination, a serum creatinine level check, and an excretory urogram. Imaging with computed tomography or ultrasound is performed earlier in any patient who has clinical signs or symptoms of abscess, hematoma, urinary leak, or fistula.

shadowing does not obscure deep margin and protects the probe from the cryoablation (33). Using multiple probe positions (i.e., rotating and translating the probe along the renal surface) may be necessary to ensure complete ablation. Extension of the iceball more than 3 mm beyond the tumor margin ensures adequate freezing of the lesion for cell death (34).

During radiofrequency ablation, an electrical current flows from the tip of a needle electrode into the surrounding tissue toward grounding pads placed on the patient's thighs, and produces heat and coagulative necrosis (35). Adequate tissue treatment temperature is 70°C. When monitoring the ablation, increasing bright echoes are visualized from the electrode tip on ultrasound due to microbubble formation (Fig. 18). This provides a rough estimate of the size of the treatment area (36). Larger lesions require the use of multiple overlapping treatment zones to achieve adequate coverage for complete ablation.

During radiofrequency ablation, the extent of coagulation cannot accurately be predicted, and postprocedural imaging is necessary in order to assess the success of the ablation.

POSTOPERATIVE IMAGING

As laparoscopic techniques are newer than open ones, guidelines for postoperative imaging are less well established.

Patients are seen at four to six weeks after open partial nephrectomy for routine follow-up and have a physical examination, a serum creatinine level check, and an excretory urogram (37). Imaging with computed tomography or ultrasound is performed earlier in any patient who has clinical signs or symptoms of abscess, hematoma, urinary leak, or fistula.

Generally, a computed tomography scan with intravenous contrast is performed, and if a urine leak is of concern, delayed images should be obtained.

Postoperative surveillance for recurrent disease should be tailored to the initial pathological tumor stage (37).

- All patients are evaluated annually with a review of history, physical examination, and blood tests including serum calcium, alkaline phosphatase, liver function tests, BUN, serum creatinine levels, and electrolytes.
- Patients with T1 tumors do not require early postoperative imaging because there is a low risk of recurrent malignancy (38,39).
- A yearly chest radiograph is recommended for patients with T2 or T3 tumors because the lung is the most common site of metastasis; low-dose chest computed tomography may also be used.
- Patients with T2 tumors should have computed tomography every two years.
- Patients with T3 tumors have a higher risk of developing local recurrence, especially during the first two postoperative years, and they should have a computed tomography every six months for two years, then at two-year intervals, if there is no documented tumor recurrence.

The effectiveness of renal tumor ablation and laparoscopic partial nephrectomy has not yet been proven in long-term follow-up studies, and therefore, imaging protocols following the procedure are not standardized, varying among institutions. In our opinion, conservative surveillance is appropriate.

- Patients who have had laparoscopic partial nephrectomy undergo follow-up abdominal and pelvic computed tomography and chest X-ray at six months, one year, and then at yearly intervals.
- Patients who have had cryoablation undergo postoperative magnetic resonance imaging at one day, one month, six months, one year, and annually thereafter.
- Contrast-enhanced computed tomography is the test of choice to search for tumor recurrence in those patients with a normal serum creatinine (40).

In patients who underwent nephron-sparing surgery and have compromised renal function, magnetic resonance imaging is a reasonable alternative to computed tomography, because the gadolinium contrast used does not pose a risk to renal function in patients with renal insufficiency.

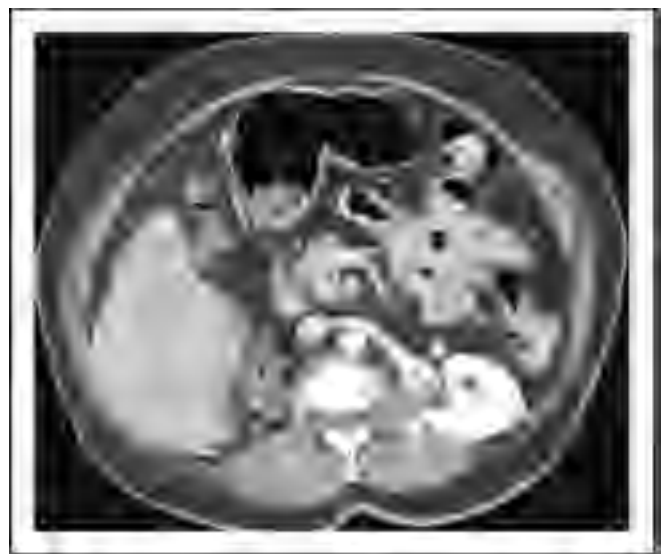Contrast enhancement is important in detecting visceral organ metastases and local recurrence, but there is a risk of nephrotoxicity from iodinated computed tomography contrast in those patients who have had nephron-sparing surgery and have compromised renal function. magnetic resonance imaging is not generally used as a screening examination.

In patients who underwent nephron-sparing surgery and have compromised renal function, magnetic resonance imaging is a reasonable alternative to computed tomography, because the gadolinium contrast used does not pose a risk to renal function in patients with renal insufficiency.

Local recurrence after nephron-sparing surgery manifests as an enhancing mass at the resection site in the residual kidney (Fig. 19). Early on, postsurgical changes are significant after both laparoscopic partial nephrectomy and ablation and should not be confused for residual disease. These postsurgical changes can include perinephric fluid, fat necrosis, urine leak, scarring, or a defect at the operative site (Figs. 20 and 21). Hemostatic agents such as oxidized cellulose (Surgicel[®]) may be present (41) and can mimic abscess formation (Fig. 22). After ablation, the mass progressively decreases in size over time (42,43) and eventually is seen as only a cortical defect (Fig. 23). Incomplete ablation is seen as a residual enhancement at the site of the mass. In our experience, enhancement or mass-like contour change suggests recurrent disease (44).

Metastatic disease can occur in regional lymph nodes or in distant sites. Lung, mediastinal, bone, liver, contralateral kidney, adrenal gland, and brain metastases are common, but metastatic disease can also be seen in the small bowel and peritoneal cavity (45). In this event, imaging reverts to the role of monitoring the treatment of metastatic disease.

FIGURE 19 ■ Recurrence at site of open partial nephrectomy. A 62-year-old woman had left open partial nephrectomy and right radical nephrectomy 2.5 years previously. Contrast-enhanced computed tomography shows round soft-tissue mass (arrow) abutting surgical clips and left renal vein (arrowhead).



^aJohnson and Johnson, Arlington, TX.

FIGURE 20 ■ Postoperative urine leak following partial nephrectomy. If entry into the collecting system is not identified and repaired at surgery, urine leaks can result. This patient has a perinephric fluid collection (A, arrow) after partial nephrectomy that fills in with contrast on a delayed scan (B).

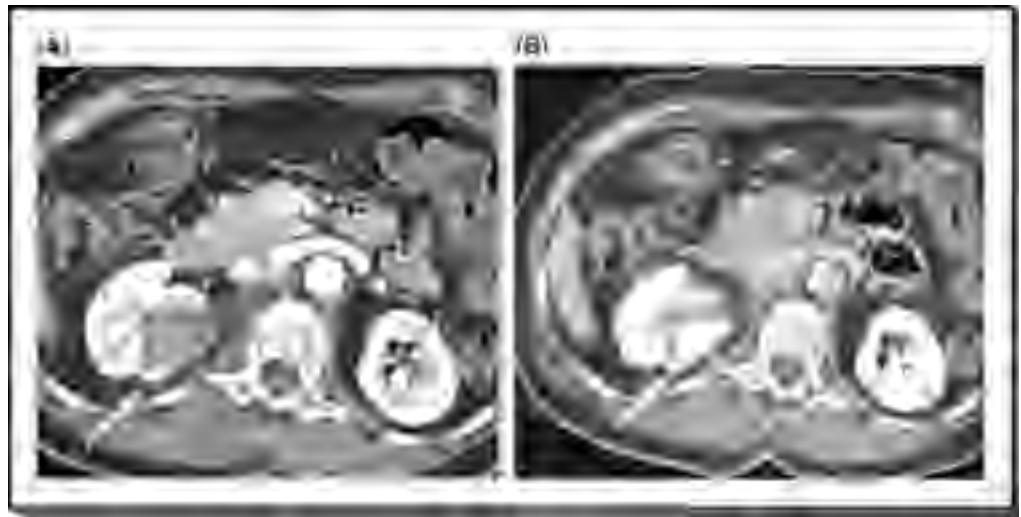


FIGURE 21 ■ Postoperative hemorrhage following partial nephrectomy. The mass (arrow) in (A) was resected laparoscopically; the patient complained of left flank pain following the surgery and had a low hemoglobin concentration. Postoperative, unenhanced computed tomography scan (B) shows a perinephric hematoma (thin arrows).

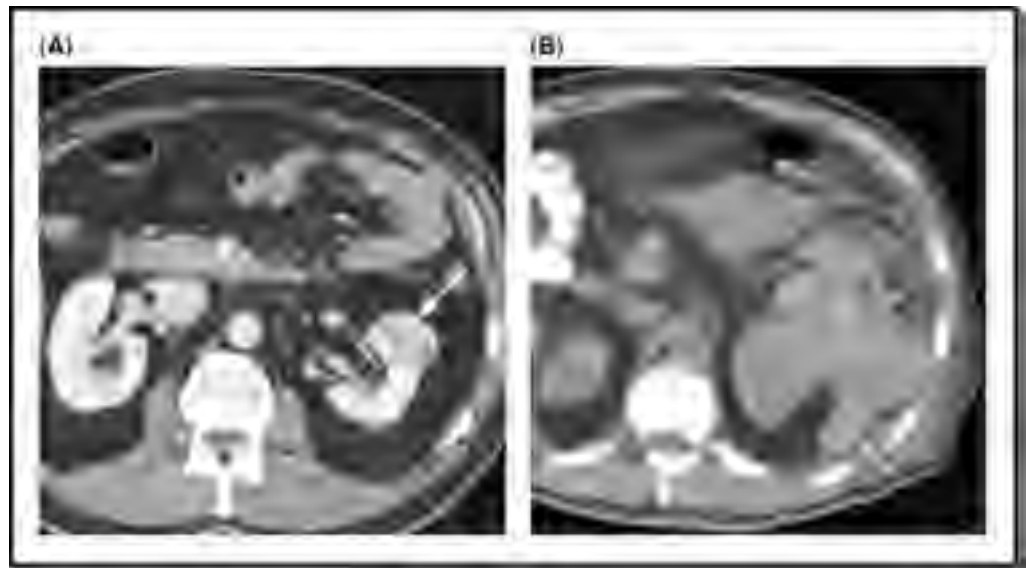
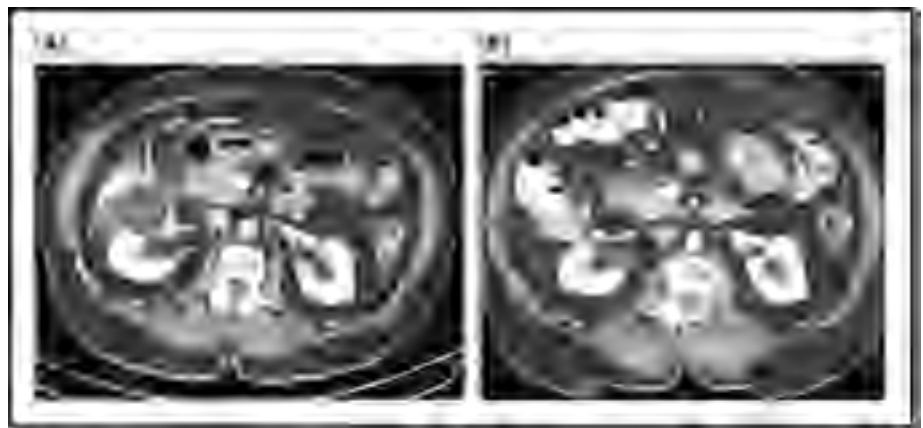

FIGURE 22 ■ Oxidized cellulose (Surgicel®) mimics abscess at laparoscopic partial nephrectomy site. This patient presented to emergency department with flank pain after laparoscopic partial nephrectomy and had a normal white blood cell count. (A) Contrast-enhanced computed tomography demonstrates ovoid collection with scattered gas foci at partial nephrectomy site (arrow). No intervention was performed. (B) Computed tomography six months later shows resolution of collection with minimal residual low attenuation (arrow).



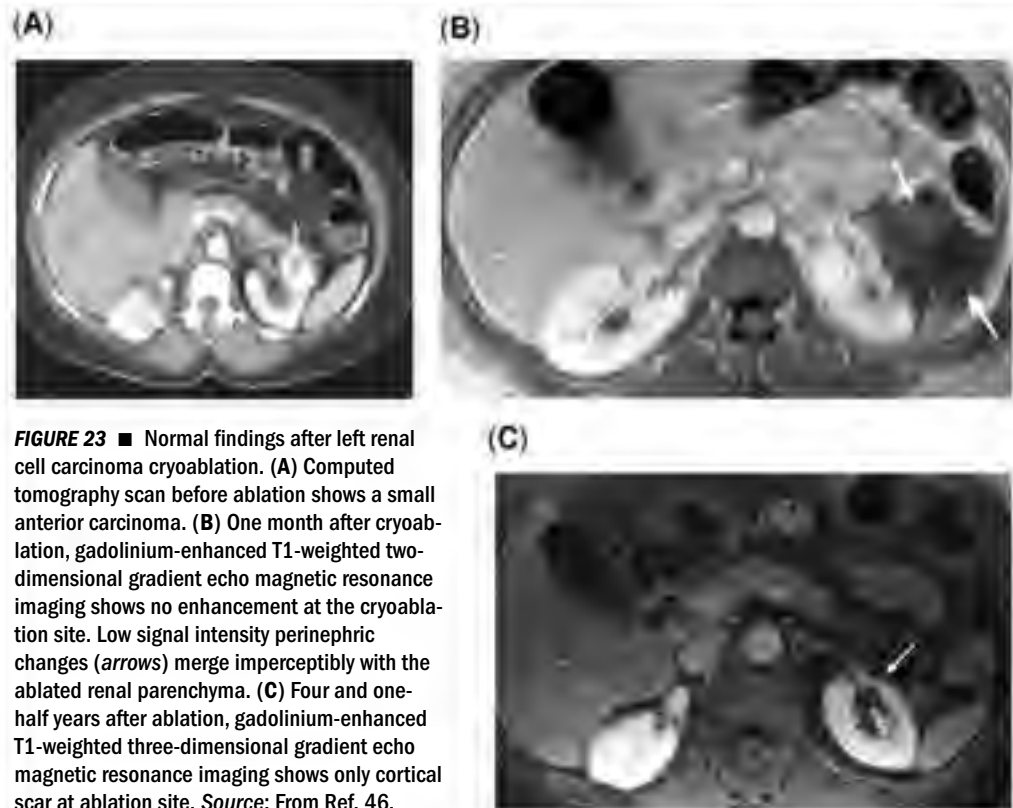


FIGURE 23 ■ Normal findings after left renal cell carcinoma cryoablation. (A) Computed tomography scan before ablation shows a small anterior carcinoma. (B) One month after cryoablation, gadolinium-enhanced T1-weighted two-dimensional gradient echo magnetic resonance imaging shows no enhancement at the cryoablation site. Low signal intensity perinephric changes (arrows) merge imperceptibly with the ablated renal parenchyma. (C) Four and one-half years after ablation, gadolinium-enhanced T1-weighted three-dimensional gradient echo magnetic resonance imaging shows only cortical scar at ablation site. Source: From Ref. 46.

SUMMARY

- The development of multislice computed tomography scanners that can rapidly obtain thin slice image data, advancements in magnetic resonance imaging software design and coil technology, the emergence of sophisticated three-dimensional rendering methods, and the development of laparoscopic ultrasound probes have now allowed the radiologist to participate in the planning of laparoscopic surgery, guiding its performance, and then following patients for possible complications or tumor recurrence.
- The laparoscopic urologist must have an accurate understanding of the renal parenchymal and vascular anatomy and tumor location to preserve normal renal tissue and, thus, preserve renal function.
- Accurate surgical planning information helps to minimize postoperative complications, such as urinary leak or renal infarct, and to maximize preserved renal parenchyma.
- Computed tomography is considered the gold standard for detection, diagnosis, and staging of renal cell carcinoma.
- Magnetic resonance is reserved for problem solving or for those patients with renal insufficiency or a history of severe allergy to iodinated contrast.
- Three-phase computed tomography protocols are the state-of-the-art for imaging the kidneys and provide all the necessary information for surgical planning for laparoscopic surgery. Thin slices are employed.
- A thorough discussion between the radiologist and the referring urologist regarding their surgical approach and surgical planning needs is recommended.
- The ability of intraoperative ultrasound to localize a renal mass during laparoscopic partial nephrectomy is invaluable.
- Guidelines for postoperative imaging after laparoscopic procedures are still evolving.
- Magnetic resonance imaging is a reasonable alternative to computed tomography for the postoperative follow-up of patients with compromised renal function.

CONCLUSION

Radiologic imaging plays an increasingly important role for the diagnosis and treatment of renal cell carcinoma. Imaging is no longer solely restricted for the detection and

characterization of renal tumors. It is now critical for surgical planning and monitoring of surgical and ablative therapies, both during and after these technically demanding, minimally invasive procedures.

REFERENCES

1. Novick AC. Current surgical approaches, nephron-sparing surgery, and the role of surgery in the integrated immunologic approach to renal-cell carcinoma. *Semin Oncol* 1955; 22:29–33.
2. Butler BP, Novick AC, Miller DP, Campbell SA, Licht MR. Management of small unilateral renal cell carcinomas: radical versus nephron-sparing surgery. *Urology* 1955; 45:34–40; discussion 40–41.
3. Coll DM, Uzzo RG, Herts BR, Davros WJ, Wirth SL, Novick AC. 3-dimensional volume rendered computerized tomography for preoperative evaluation and intraoperative treatment of patients undergoing nephron sparing surgery. *J Urol* 1999; 161:1097–1102.
4. Coll DM, Herts BR, Davros WJ, Uzzo RG, Novick AC. Preoperative use of 3D volume rendering to demonstrate renal tumors and renal anatomy. *Radiographics* 2000; 20: 431–438.
5. Wunderlich H, Reichelt O, Schubert R, Zermann DH, Schubert J. Preoperative simulation of partial nephrectomy with three-dimensional computed tomography. *BJU Int* 2000; 86: 777–781.
6. Chernoff DM, Silverman SG, Kikinis R, et al. Three-dimensional imaging and display of renal tumors using spiral computed tomography: a potential aid to partial nephrectomy. *Urology* 1994; 43: 125–129.
7. Zagoria RJ, Dyer RB. The small renal mass: detection, characterization, and management. *Abdom Imaging* 1998; 23: 256–265.
8. Bosniak MA. The small (less than or equal to 3.0 cm) renal parenchymal tumor: detection, diagnosis, and controversies. *Radiology* 1991; 179: 307–317.
9. Birnbaum BA, Jacobs JE, Ramchandani P. Multiphasic renal computed tomography: comparison of renal mass enhancement during the corticomedullary and nephrographic phases. *Radiology* 1996; 200: 753–758.
10. Szolar DH, Kammerhuber F, Alziebler S, et al. Multiphasic helical computed tomography of the kidney: increased conspicuity for detection and characterization of small (<3-cm) renal masses. *Radiology* 1997; 202: 211–217.
11. Cohan RH, Sherman LS, Korobkin M, Bass JC, Francis IR. Renal masses: assessment of corticomedullary-phase and nephrographic-phase computed tomography scans. *Radiology* 1995; 196: 445–451.
12. Bosniak MA. The current radiological approach to renal cysts. *Radiology* 1986; 158: 1–10.
13. Bosniak MA. Diagnosis and management of complicated cystic lesions of the kidneys. *AJR* 1997; 169: 819–821.
14. Israel GM, Bosniak MA. Follow-up computed tomography of moderately complex cystic lesions of the kidney (Bosniak category IIF). *AJR* 2003; 181: 627–633.
15. Curry NS, Bissada NR. Radiologic evaluation of small and indeterminate renal masses. *Urol Clin North Am* 1997; 24: 493–505.
16. Davidson AJ, Hartman DS, Choyke PL, Wagner BJ. Radiologic assessment of renal masses: implications for patient care. *Radiology* 1997; 202: 297–305.
17. Warshauer DM, McCarthy SM, Street L, et al. Detection of renal masses: sensitivities and specificities of excretory urography/linear tomography, ultrasound, and computed tomography. *Radiology* 1988; 169: 363–365.
18. Jamis-Dow CA, Choyke PL, Jennings SB, Linehan WM, Thakore KN, Walther MM. Small (< or = 3-cm) renal masses: detection with computed tomography versus ultrasound and pathologic correlation. *Radiology* 1996; 198: 785–788.
19. Silverman SG, Lee BY, Seltzer SE, Bloom DA, Corless CL, Adams DF. Small (< or = 3-cm) renal masses: correlation of spiral computed tomography features and pathologic findings. *AJR* 1994; 163: 597–605.
20. Aspelin P, Aubry P, Fransson SG, et al. Nephrotoxic effects in high-risk patients undergoing angiography. *NEJM* 2003; 348: 491–499.
21. Mahadevappa M. Search for isotropic resolution in computed tomography from conventional through multiple-row detector. *Radiographics* 2002; 22: 949–962.
22. Herts BR, Coll DM, Lieber ML, Streem SB, Novick AC. Triphasic helical computed tomography of the kidneys: contribution of vascular phase scanning in patients before urologic surgery. *AJR* 1999; 173: 1273–1277.
23. Pretorius ES, Siegelman ES, Ramchandani P, Cangiano T, Banner MP. Renal neoplasms amenable to partial nephrectomy: MR imaging. *Radiology* 1999; 212: 28–34.
24. Lee VS, Rofsky NM, Krinsky GA, Stemberman DH, Weinreb JC. Single-dose breath-hold gadolinium-enhanced three-dimensional MR angiography of the renal arteries. *Radiology* 1999; 211: 69–78.
25. Rofsky NM, Lee VS, Laub G, et al. Abdominal MR imaging with a volumetric interpolated breath-hold examination. *Radiology* 1999; 212: 876–884.
26. Johnson PT, Heath DG, Bliss DF, Cabral B, Fishman EK. Three-dimensional computed tomography: real-time interactive volume rendering. *AJR* 1996; 167: 581–583.
27. Calhoun PS, Kuszyk BS, Heath DG, Carley JC, Fishman EK. Three-dimensional volume rendering of spiral computed tomography data: theory and method. *Radiographics* 1999; 19: 745–764.
28. Lee VS, Flyer MA, Weinreb JC, Krinsky GA, Rofsky NM. Image subtraction in gadolinium-enhanced MR imaging. *Am J Roentgenol* 1996; 167: 1427–1432.
29. Choyke PL, Daryanani K. Intraoperative ultrasound of the kidney. *Ultrasound Q* 2001; 17: 245–253.
30. Gage AA, Baust J. Mechanisms of tissue injury in cryosurgery. *Cryobiology* 1998; 37: 171–186.
31. Lee FT Jr, Mahvi DM, Chosy SG, et al. Hepatic cryosurgery with intraoperative 2ultrasound guidance. *Radiology* 1997; 202: 624–632.
32. Gill IS, Novick AC, Soble JJ, et al. Laparoscopic renal cryoablation: initial clinical series. *Urology* 1998; 52: 543–551.

33. Remer EM, Hale JC, O'Malley CM, Godec K, Gill IS. Sonographic guidance of laparoscopic renal cryoablation. *AJR* 2000; 174: 1595–1596.
34. Campbell SC, Krishnamurthi V, Chow G, Hale J, Myles J, Novick AC. Renal cryosurgery: experimental evaluation of treatment parameters. *Urology* 1998; 52: 29–33; discussion 33–34.
35. Wood BJ, Ramkaransingh JR, Fojo T, Walther MM, Libutti SK. Percutaneous tumor ablation with radiofrequency. *Cancer* 2002; 94: 443–451.
36. Pavlovich CP, Walther MM, Choyke PL, et al. Percutaneous radio frequency ablation of small renal tumors: initial results. *J Urol* 2002; 167: 10–15.
37. Novick AC. Nephron-sparing surgery for renal cell carcinoma. *Ann Rev Med* 2002; 53: 393–407.
38. Hafez KS, Novick AC, Campbell SC. Patterns of tumor recurrence and guidelines for follow-up after nephron sparing surgery for sporadic renal cell carcinoma. *J Urol* 1997; 157: 2067–2070.
39. Saidi JA, Newhouse JH, Sawczuk IS. Radiologic follow-up of patients with T1–3a,b,c or T4N+M0 renal cell carcinoma after radical nephrectomy. *Urology* 1998; 52:1000–1003.
40. Newhouse JH, Amis ES Jr, Bigongiari LR, et al. Follow-up of renal cell carcinoma. American College of Radiology. ACR Appropriateness Criteria. *Radiology* 2000; 215(suppl):761–764.
41. Oto A, Remer EM, O'Malley CM, Tkach JA, Gill IS. MR characteristics of oxidized cellulose (Surgicel). *AJR* 1999; 172: 1481–1484.
42. Gill IS, Novick AC, Meraney AM, et al. Laparoscopic renal cryoablation in 32 patients. *Urology* 2000; 56: 748–753.
43. Remer EM, Weinberg EJ, Oto A, O'Malley CM, Gill IS. MR imaging of the kidneys after laparoscopic cryoablation. *AJR* 2000; 174: 635–640.
44. Brady PS, Remer EM, Gill IS. magnetic resonance imaging after renal cryoablation: findings at 1–2 year follow-up. *Radiology* 2000; 217(P):581.
45. Scatarige JC, Sheth S, Corl FM, Fishman EK. Patterns of recurrence in renal cell carcinoma: manifestations on helical computed tomography. *AJR* 2001; 177:653–658.
46. Herts BR, Remer EM, Veniero JV. Digital imaging for nephron-sparing surgery. In: Morcos SK and Cohan RH. *New techniques in Uroradiology*. New York: Taylor & Francis; 2006: 101–131.

SECTION

II

EQUIPMENT

Mihir M. Desai

Section of Laparoscopic and Minimally Invasive Surgery, Glickman Urological Institute, Cleveland Clinic Foundation, Cleveland, Ohio, U.S.A.

■ INTRODUCTION	Glues, Bioadhesives and Hemostatic Agents
■ LAPAROSCOPIC INSTRUMENTATION	Aspiration/Irrigation Instruments
Instruments for Laparoscopic Access	System for Visualization
Laparoscopic Trocars	■ OPERATING ROOM SETUP
Grasping Instruments	Patient Positioning and Draping
Cutting Instruments	Placement of Operative Team and Equipment
Energy Sources for Laparoscopic Surgery	■ CONCLUSION
Clips and Staplers	■ REFERENCES
Suturing and Knot Tying	

INTRODUCTION

There has been an exponential increase in laparoscopic urologic surgery, reconstructive and ablative, in the treatment of a variety of benign and malignant conditions affecting the urinary tract. Advances in instrumentation and technology have played a pivotal role in expanding the application of laparoscopic surgery. Proper understanding of instrumentation and certain basic principles of laparoscopic surgery is fundamental to the safe and effective practice of minimally invasive surgery. This chapter will highlight the fundamental and practical aspects of laparoscopic instrumentation and techniques common to most laparoscopic urological procedures.

LAPAROSCOPIC INSTRUMENTATION

Instruments for Laparoscopic Access

Transperitoneal Access

Closed Access Using the Veress Needle

During closed transperitoneal access, a Veress needle is initially placed percutaneously into the peritoneal cavity, usually through one of the subsequent trocar sites (1). The standard reusable Veress needle is a metallic needle with a retractable protective blunt tip. The blunt tip retracts exposing the sharp end when the tip of the Veress needle is pushed against a tough structure such as fascia. Once the needle has penetrated the layers of the abdominal wall and enters the peritoneal cavity, the blunt tip springs back into place, thereby protecting the abdominal viscera from injury likely to be caused by the sharp edge. The Veress needle has a valve-operated port for initial peritoneal insufflation.

The Veress needle is available as a disposable or a reusable instrument. The 2-mm Minisite trocar^{TMa}, a modified Veress-type device, is the author's instrument of preference for obtaining closed peritoneal access. The Minisite trocar has a retractable blunt tip similar to a standard Veress needle, and can also be used as a 2-mm cannula by removing the inner trocar needle. In cases where the correct position of the needle is questionable, a 1.9/2.0 mm telescope can be passed through the Minisite cannula to confirm intraperitoneal position.

For pelvic laparoscopic procedures, the patient is typically supine with a slight Trendelenburg tilt, and the Veress needle is introduced through a subumbilical incision. The needle is directed toward the pelvis in order to avoid injury to the great vessels. For upper tract laparoscopic procedures, the patient is generally in the flank position, and the Veress needle is placed through the iliac fossa in order to minimize inadvertent

^aU.S. Surgical Corp., Norwalk, CT.

Many laparoscopic surgeons prefer the open Hass on approach to obtain initial transperitoneal laparoscopic access.



FIGURE 1 ■ A Hasson cannula.



FIGURE 2 ■ PDB™ balloon dilator.
Source: Courtesy of Autosuture.



FIGURE 3 ■ An inflated balloon dilator.

injury to the bowel, which typically gravitates medially toward the umbilicus. It is preferable to avoid a Veress needle puncture in the vicinity of a previous abdominal scar. The tactile feedback of the Veress needle passing through the various layers of the abdominal wall is critical in ensuring optimal positioning. Typically one feels two distinct “pops” each at the level of the external oblique/rectus fascia, and at the level of the transversalis fascia/peritoneum. The disposable Veress needles have a ball that visually confirms the “pops.” After insertion, the Veress needle is aspirated to rule out the presence of blood or bowel content. The correct placement of the needle is further confirmed by injecting a few drops of saline, and demonstrating the rapid drop of the meniscus. Final confirmation is obtained by documenting a low opening intra-abdominal pressure after initiating insufflation at a low flow (1 L/min). Once the correct intra-abdominal position of the needle has been confirmed, insufflation flow rate can be increased to the maximum. Once the abdomen has been insufflated adequately (intra-abdominal pressure 15–20 mmHg), the primary trocar is placed. This author prefers to initially insufflate the abdomen up to 20 mmHg prior to inserting the first trocar. This keeps the abdomen tense and reduces the chances of inadvertent visceral injury during the first “blind” trocar placement. It is important to make a generous skin incision for the initial port-site to reduce the gripping of the skin on the trocar. Additional trocars are subsequently inserted under direct laparoscopic visualization thereby minimizing the risk of inadvertent visceral or vascular injury.

Open Access Using the Hasson Technique

Many laparoscopic surgeons prefer the open Hasson approach to obtain initial transperitoneal laparoscopic access (2). Herein, primary access is obtained through a 1 inch incision made at one of the port-sites. The incision is carried down through the various abdominal wall layers to reach the peritoneum. The peritoneum is then grasped between hemostats and sharply incised. A finger is introduced through the incision to confirm presence within the peritoneal cavity.

With the open access system, it is of critical importance to obtain an airtight seal at the site of entry through the abdominal wall in order to minimize gas leak of the insufflate. A Hasson cannula may be used for this purpose (Fig. 1). The Hasson blunt-tip cannula is inserted into the peritoneal cavity and secured in place with fascial sutures. The author prefers to use a blunt-tip balloon cannula (vide infra) in lieu of the Hasson cannula since, in my opinion, the seal provided by the balloon port is better.

Retroperitoneal Access

Retroperitoneal access is obtained by an open technique (3). The primary incision is placed below the tip of the 12th rib. The skin, subcutaneous tissue, and external oblique fascia are incised sharply. The fibers of the internal oblique and transverses are separated bluntly with the index finger up to the level of the dorsolumbar fascia, which is divided sharply to gain entry into the retroperitoneal space. The retroperitoneal position is confirmed by palpating the psoas muscle posteriorly and the lower pole of the kidney superiorly. Initially, the retroperitoneal space is developed with the help of the finger. A variety of devices have been used for subsequent rapid development of the initial working space during retroperitoneoscopy. Simple contraptions such as rubber catheters attached to a latex glove or condom though inexpensive, in our opinion, are not very efficient. We prefer to use the PDB™ balloon dilator^b to balloon dilate the retroperitoneal space for several reasons (Fig. 2). First, the balloon dilator has a rigid shaft, thereby enabling optimal positioning of the balloon in the retroperitoneum. Second, the balloon dilator has a transparent cannula and balloon through which a 10 mm laparoscope can be introduced to confirm proper positioning. Visualization of the psoas muscle inferiorly and the perinephric fat superiorly confirms the correct balloon position between the kidney and the posterior abdominal wall. Occasionally, other retroperitoneal structures, such as the ureter, gonadal vein, and inferior vena cava may be identified through the transparent balloon. Third, since the balloon lies entirely in the retroperitoneum, inflating the balloon does not widen the initial incision made through the skin and abdominal wall. The balloon dilator is incrementally inflated up to 800 cc (each pump delivers approximately 20 cc air) (Fig. 3).

Subsequently, a 10 mm blunt tip balloon trocar is inserted through the incision (Fig. 4). The balloon port provides optimal sealing of the abdominal wall, thereby minimizing leak of CO₂ and subcutaneous emphysema. This is of critical importance, given the already limited working space in the retroperitoneum (3).

^bU.S. Surgical Corp., Norwalk, CT.



FIGURE 4 ■ Blunt tip trocar.

Laparoscopic Trocars

Types of Trocars

Trocars are either disposable or reusable and are available in various sizes (2, 5, 10, 12, and 15 mm). The obturator tip may be bladed or blunt; bladed trocars are available with or without (usually reusable trocars) a safety shield. The larger (10, 12, 15 mm) trocars have a valve and reducer system at the proximal end to allow instruments of various sizes to be passed without causing an air leak. The blunt-tip trocars may be associated with a lower incidence of injury to abdominal wall vessels and intraperitoneal structures, and are the preferred trocars at the author's institute. Longer trocars are also available for use in the morbidly obese population.

Sites for Trocar Placement

Procedure-specific trocar placement is described in detail with each individual operative procedure. However, certain general principles govern correct trocar placement. The camera port ideally should be in line with and at a 45° angle to the principal structure of interest (e.g., renal hilum during laparoscopic nephrectomy). The right- and left-hand working ports should be on either side of and at an adequate distance from the primary camera port creating a triangulation. Proper trocar arrangement is ideal for creating optimal orientation and angles of the rigid laparoscopic instruments.

Technique of Trocar Insertion

The primary trocar insertion has been described earlier. Secondary trocars must be inserted under direct laparoscopic visualization to avoid inadvertent visceral injury. The proposed site of trocar placement on the abdominal wall is pressed with a finger, and the indentation made is viewed internally via the laparoscope. We prefer to localize the site of trocar placement by puncturing the abdominal wall with a hypodermic needle attached to a syringe. The skin incision is made commensurate with the size of trocar to be inserted. The trocar is firmly grasped against the palm of the hand and inserted perpendicular to the abdominal wall. Tangential skewing of the trocar through the abdominal wall results in limited mobility of the port and instrument, additionally, as the procedure progresses the trocar hole tends to progressively enlarge, leading to gas leakage around the trocar. We prefer to fix all trocars to the skin using a 0-Vicryl suture.

Grasping Instruments

A variety of laparoscopic grasping instruments, disposable and reusable, are currently available. The grasping instruments may be traumatic or atraumatic, or locking or nonlocking, have a single or double action jaw, and be available in various sizes (2–12 mm). Atraumatic graspers generally have serrated tips that are gentle on visceral tissues. The traumatic graspers have toothed tips that offer a firm grasp on rigid fascial or similar nonvital structures. Typically, the reusable instruments are modular, wherein different tips can be attached to different handles using varying shaft lengths.




FIGURE 5 ■ Electroscurgical scissors.

Cutting Instruments

Monopolar electroscurgical instruments are generally used for cutting tissues during laparoscopic surgery. Straight or curved scissors (Fig. 5) and electroscurgical electrodes of various tip configurations (Fig. 6) are available for laparoscopic tissue cutting. Usually a setting of 55 W for coagulation and 35 W for cutting is employed. The shaft of these instruments is insulated to prevent thermal damage to adjacent structures. Keeping the tissues on stretch allows for precise and rapid cutting using monopolar electroscurgical instruments.



FIGURE 6 ■ Electroscurgical electrode tip.

Energy Sources for Laparoscopic Surgery

Apart from monopolar and bipolar electrocautery, a variety of different energy sources have been introduced for tissue cutting and/or hemostasis that can be used laparoscopically. These include ultrasonic energy, LigaSure,^c hydrodissector, and argon beam coagulator.

Ultrasonic energy has been successfully used for tissue dissection and hemostasis during laparoscopic procedures (4). The commercially available ultrasonic generators provide a variety of effector tips (5 and 10 mm) for laparoscopic surgery. With ultrasonic

^cValleylab, Boulder, CO.

TABLE 1 ■ Efficacy of Various Energy Sources in Laparoscopic Surgery

Energy source	Vessel size ^a	Collateral spread (mm)
LigaSure	Artery: 6 mm Vein: 12 mm	1-3
Ultrasonic	3 mm	0-1
Bipolar	Unreliable	1-6

^aMaximum diameter of the vessel that was reliably occluded.
Source: From Ref. 6.

energy, tissue cutting and coagulation is achieved at lower temperatures (50–100°C) as compared to electrocautery. This reduces the lateral scatter, charring, and smoke production. Disadvantages of the ultrasound dissection include equipment cost and decreased speed of dissection compared to conventional electrocautery.

The LigaSure system is designed for providing hemostatic sealing of blood vessels up to 7 mm in diameter (5). Specific to urologic surgery, the LigaSure has been used for securing blood vessels, such as the lumbar, gonadal, and adrenal vein in select cases in lieu of surgical clips. The LigaSure technology combines compression pressure and thermal energy to cause denaturation of the vessel wall collagen and secure vessel occlusion. A feedback mechanism regulates the amount of energy to be delivered and gives an audible signal to the surgeon when effective vessel occlusion has been achieved. The LigaSure system is thought to produce less charring and tissue sticking compared to conventional bipolar coagulators. Landman et al. compared the relative efficacy of ultrasonic energy versus bipolar cautery versus LigaSure in the laboratory and found that LigaSure had the best hemostatic efficacy and ultrasonic shears had the least collateral scatter (Table 1) (6).

Argon beam coagulation provides excellent superficial hemostasis for superficial bleeding surfaces (7). It is particularly helpful for controlling mild oozing from parenchymal bleeding surfaces, such as liver, spleen, kidney, and muscle. Additionally, the argon beam coagulator does not produce any forward scatter. The use of the argon beam coagulator during laparoscopic surgery may cause a precipitous rise in intra-abdominal pressure; therefore, one of the trocars should be continuously vented during its use.


Clips and Staplers

Surgical clips and staplers are predominantly used for securing medium and large caliber vessels during laparoscopic surgery. Surgical clips may be either titanium (Fig. 7) or polymer-plastic and are available in various sizes. Titanium clips can be applied through manual loading (reusable applicator) or automatic self-loading (disposable) applicators. The titanium clips may fall off during subsequent dissection and manipulation and hence multiple clips should be applied, especially during ligation of larger caliber blood vessels. The clips should be evenly spaced and should not cross each other in order to be effective. It is also important to leave a sufficient vessel stump after the last clip to ensure safety of the clip ligation.

The locking plastic clips have significantly improved the security of surgical clips (Fig. 8). These clips are applied such that the entire clip encircles the vessel and once fired, locks into place. The clips are available in 5, 10, and 16 mm sizes. The 5 mm clip also has a disposable, automatically reloading applicator. These clips are generally more reliable than titanium clips and are currently our preferred method of securing medium to large vessels such as the renal artery and venous tributaries. Although various reports have supported the use of such clips on the main renal vein, we currently reserve tissue staplers for that purpose. The availability of the 16 mm Hem-O-Lok™^d clip may lead to the routine use of the Hem-O-Lok technology for renal vein control.

Endoscopic stapling devices are generally employed for securing hemostasis for large vascular structures such as the renal vein and rapid division of tissues. Typical endoscopic staplers are of a linear GIA type and lay six staggered rows of staples and cut between rows 3 and 4. The latest generation of endoscopic stapling devices can both articulate and reticulate allowing an increased range of angles for soft tissue and vascular stapling. The stapling cartridges are available in various lengths (30, 45, and 60 mm) and various staple heights (2, 2.5, and 3 mm). The 2 mm stapling loads are typically used for

Surgical clips and staplers are predominantly used for securing medium and large caliber vessels during laparoscopic surgery.

**FIGURE 7 ■ Titanium surgical clip.****FIGURE 8 ■ Locking plastic surgical clip.**

^dWeck Closure System, Research Triangle Park, NC.

hemostatic vascular stapling. The 3.5 mm loads are typically used for soft tissue stapling wherein vascularity of the stapled edges needs to be preserved (e.g., bowel anastomosis). Certain precautions need to be taken to ensure safety of endoscopic staplers. First, the correct load of staples must be used as per the type and thickness of tissue to be stapled. Second, care must be taken not to fire staplers over clips. However, staples can be safely fired over previous staple lines.

Suturing and Knot Tying

Suturing and knot tying are critical skills for the advanced laparoscopic surgeon (8).

The Endoloop^{TM e} consists of a preformed loop of suture with a slipknot at the end of a plastic knot pusher. This device may be used for ligating tubular organs such as the appendix.

Extracorporeal knotting involves formation of the knot by a longer suture outside the cavity and pushing it through the port with the help of one of the many available knot pushers. Intracorporeal suturing and knot tying is the author's preferred method of laparoscopic reconstruction. The needle can be easily inserted through a laparoscopic port by grasping the suture about 3 cm from the needle. The trocar sleeve valve should be kept in an open position while the suture is being inserted. The size of the needle determines the trocar size required. Although a 10–12 mm port is preferred, certain smaller needles may be passed through a 5 mm trocar. The suture is generally cut to a length of 7–10 cm for intracorporeal knot tying. A longer suture may be used for certain applications that require continuous suturing. In general, the longer the suture, the more difficult it is to handle in the laparoscopic environment. The long end of the suture is looped two to three times around the tip of the needle driver and to complete the first throw of the surgeon's knot. The second and the third throws complete a square knot. Suturing can be performed in interrupted or running fashion. A variety of needle drivers with varying tip and handle configurations and locking mechanisms are currently available. A novice laparoscopist may consider starting out with a self-righting needle-driver, although the non self-righting devices afford the greatest versatility for the more experienced surgeon. Our personal preference is the Ethicon needle driver E705R (Fig. 9).

A variety of specialized suturing devices is available to facilitate laparoscopic intracorporeal suturing and knot tying. These include Endostitch^{TM f} and SewRight^{TM g}. Although these devices may facilitate the beginner laparoscopist, in our opinion, they lack the finesse of freehand suturing. Additionally, with these specialized devices, the laparoscopic surgeon is limited in terms of the type of suture and needle configurations available. In contrast, with freehand laparoscopic suturing, the surgeon can use the full array of suture available for open surgery.



FIGURE 9 ■ Ethicon needle driver.

Glues, Bioadhesives and Hemostatic Agents

Details of various biological hemostatic and tissue agents are detailed elsewhere in the text. Closure of laparoscopic port-site incisions with skin adhesives such as octylcyanoacrylate has been found to be as effective as subcuticular suturing with the advantage of requiring less operative time (9). Although there are other adhesives such as *N*-butyl-2-cyanoacrylate, only octylcyanoacrylate has the approval of the Food and Drug Administration. octylcyanoacrylate has to be applied to dry, well-approximated incisions and the product must not be allowed to come in contact with subcutaneous tissues as a vigorous foreign body reaction resembling an infection often ensues.

Aspiration/Irrigation Instruments

A variety of suction-irrigation systems is currently available (Fig. 10). The aspirator, which is connected to a suction system, consists of a 5 or 10 mm metal or plastic tube, with suction controlled by either a one-way stopcock or a spring-controlled trumpet valve. The irrigation channel is also operated by the same mechanism. The irrigation may be pressurized to adequately clear blood clots for optimal visualization. Usually normal saline or lactated Ringer solution is used as irrigation fluid. Heparin (5000 U/L) may be added to prevent clots from forming in the surgical field. Furthermore, a broad-spectrum antibiotic may be added to the irrigant fluid in situations where infection may be a concern.



FIGURE 10 ■ A suction-irrigation system.

^eEthicon, Inc., Somerville, NJ.

^fU.S. Surgical Corp., Norwalk, CT.

^gLSI Solutions, Victor, NY.

Instrumentation for Port-Site Closure

The simplest method is retracting the skin with retractors, grasping the fascia with Kocher's clamps, and suturing it with sutures. However, external suture of 1 cm port-site incisions may be extremely difficult especially in the obese population.

Several specialized devices for secure port-site closure have been introduced (10–13). The Carter-Thomason Needlepoint Suture PasserTM^h consists of a 10-mm metal cone that has two cylindrical openings located diagonally opposite each other. The Carter-Thomason needle grasper is used to insert one end of the suture loop through one of the cylinders within the cone, thereby traversing the full thickness of the abdominal wall. The end of the suture within the peritoneal cavity is grasped with a 5-mm grasper via one of the other ports by the assistant. The Carter-Thomason needle grasper is reintroduced through the diagonally opposite cylinder of the metal cone. The intraperitoneal end of the suture is fed to the needlepoint grasper and pulled out of the abdomen. The metal cone is slid off both ends of the suture. Subsequently, the suture is tied after desufflating the abdomen to provide adequate fascial closure. Alternatively, the Carter-Thomason needle grasper may be used without the cone using finger guidance. In general, it is our recommendation to close all 10 mm or larger port sites.

Insufflant System

The insufflant system (i.e., insufflator, tubing, and insufflant gas) is essential for establishing a pneumoperitoneum, or pneumoretroperitoneum, as the case may be. Insufflation is commenced after either closed (i.e., Veress needle) or open (i.e., Hasson cannula) access to the desired cavity is optimally established.

Most commonly, CO₂ is used as the insufflant because it does not support combustion and is highly soluble in blood (14). However, in patients with chronic respiratory disease, CO₂ may accumulate in the blood stream to dangerous levels. In such cases, helium may be used for insufflation once the initial pneumoperitoneum has been established with CO₂. The drawback of helium is that it is much less soluble in blood than CO₂ but may be useful in avoiding hypercarbia. Other gases, such as room air, oxygen, and nitrous oxide are no longer routinely used owing to their potential side effects (e.g., air embolus, intra-abdominal explosion, potential to support combustion). "Noble gases" such as xenon, argon, and krypton are inert and nonflammable but are not routinely used for insufflation owing to their high cost and poor solubility in blood.

Initially, insufflator pressure is set at 20 mmHg with a rate of gas flow of 1 L/min. Once safe entry into the peritoneal cavity has been achieved, the flow can be increased to maximum.

The insufflated CO₂ is typically cold (21°C) and is unhumidified. This results in minimal systemic hypothermia and likely contributes to problems of fogging of the endoscope during the procedure. Accessory devices for insufflators that warm and humidify CO₂ to physiologic conditions are available. However, the benefit of this technology is largely of an anecdotal nature. Indeed, warming the insufflant by itself may be of no benefit or even detrimental.

System for Visualization

Four components are required to obtain an image during laparoscopic surgery: laparoscopic telescope, light source with cable, Endovisionⁱ camera, and monitor. Laparoscopes that are most commonly used have 0° or 30° lenses (range, 0–70°) and a size of 10 mm (range, 2.7–12 mm). Image transmission uses an objective lens, a rod-lens system with or without an eyepiece, and a fiberoptic cable. The advantage of the larger laparoscopes is that they are able to provide a wider field of view, better optical resolution, and a brighter image. From the eyepiece, the optical image is magnified and transferred to the camera and onto the monitor. Light is transmitted from the light source through the fiberoptic cable onto the light post of the laparoscope. A special variant is the offset "working laparoscope," which includes a working channel for passage of basic laparoscopic instrumentation. Use of this type of laparoscope enables the surgeon to work in direct line with the image and may allow a reduction in the number of trocars needed to accomplish a particular procedure. However, the working channel occupies space that would otherwise be used for the optical system; hence, the resulting image is usually of lesser quality compared with that of laparoscopes without this feature.

^hInlet Medical Inc., Eden Prairie, MN.

ⁱEndovision Pty Ltd., Camberwell, Australia.

The camera system consists of a camera and a video monitor. Earlier, cameras could not be sterilized; hence, a sterile plastic camera wrap had to be passed over the camera and the eyepiece of the laparoscope. The camera wrap was then affixed to the shaft of the laparoscope with wire ties. Fortunately, all currently made cameras can be gas sterilized or soak sterilized, thereby facilitating their use and avoiding a possible source of intraoperative contamination. The camera is attached directly to the end of the laparoscope and transfers the view of the surgical field through a cable to the camera box unit. After reconstruction of the optical information, the image is displayed on one or two video monitors.

A wide variety of cameras is currently available: single-chip, single-chip/digitized, three-chip, three-chip/digitized, interchangeable fixed-focus lenses, zoom lenses, beam splitter, and direct coupler. Direct couplers are superior to beam splitters, in which light and image are shared between monitor and eyepiece and in which the surgeon may view the area of interest directly through the laparoscope. Three-chip cameras are superior to single-chip cameras in that they provide a higher-quality image with superior color resolution.

To obtain a “true” upright image of the surgical field on the monitor, the camera’s orientation mark must be placed at the 12 o’clock position. With 0° laparoscopes, the camera is locked to the eyepiece in the true position. In contrast, with the 30° laparoscope, the camera is loosely attached to the eyepiece of the laparoscope so the laparoscope can be rotated. Accordingly, the assistant must hold the camera in the true upright position with one hand while rotating the laparoscope through a 360° arc to peer over and around vascular and other intra-abdominal structures; the 30° lens thus provides the surgeon with a more complete view of the surgical field than does a 0° lens.

The most vexing problem with the laparoscope is fogging of the lens. To prevent fogging of the laparoscope after insertion into the warm intraperitoneal cavity, it is advisable to initially warm the laparoscope in a container holding warm saline before it is passed into the abdomen. In addition, wiping the tip with a commercial defogging fluid or with povidone-iodine solution is also recommended. Should moisture buildup occur between eyepiece and camera, both components must be disconnected and carefully cleansed with a dry gauze pad.

Video monitors are available in 13- or 19-inch sizes. A larger monitor does not produce a better picture; indeed, given the same number of lines on both monitors, a higher-resolution image is obtained with the smaller screen. To obtain a better image, more lines of resolution are needed. High-resolution monitors with 1125 lines of resolution must be matched with a camera system of similar capability.

Light sources use high-intensity halogen, mercury, or xenon vapor bulbs with an output of 250–300 W. Xenon, 300 W lamps are currently preferred. In addition to manual control of brightness, some units have automatic adjustment capabilities to prevent too much illumination, which may result in a “washed-out” image. Any breakage of fibers in the fiberoptic cable, which may occur during sterilization and/or improper handling, results in decreased light transfer from the light source to the laparoscope, and hence to the operating field.

To prevent fogging of the laparoscope warm the laparoscope in a container holding warm saline before it is passed into the abdomen.

OPERATING ROOM SETUP

The operating room should be large enough to accommodate all necessary personnel and the technologic equipment required by both the laparoscopist and the anesthesiologist. Positioning of equipment, surgeon, assistants, nurses, anesthesiologist, and other support staff should be clearly defined and established for each standard laparoscopic case. Generally, ceiling mounted beams are preferred for placing the necessary optical, insufflation, and electrocautery instruments over floor standing towers. All equipments must be fully functional and in operating condition before any laparoscopic procedure is started. A separate tray with open laparotomy instruments must be ready for immediate use in the event of complications or problems necessitating open incisional surgery.

Patient Positioning and Draping

Positioning of the patient depends upon the laparoscopic procedure to be performed. Most pelvic laparoscopic procedures are performed with the patient in a supine, low-lithotomy position with the arms secured at the sides of the body. In contrast, upper tract laparoscopic procedures are performed with the patient in the flank position.

In the lateral position, all bony prominences must be carefully padded. The patient is securely fastened on the operating table by two to three circumferential wraps of a 6 inch cloth adhesive tape and a belt. In the lateral position, the bottom leg is flexed

approximately 45° while the upper leg is kept straight; two to three pillows are placed between the legs as a cushion and also to elevate the upper leg so that it is on the same level as the flank, thereby obviating any undue stretch on the sciatic nerve. Similarly, an axillary roll is positioned below the dependant axilla to prevent brachial plexus injury. The head and upper extremities are placed in a neutral position. We prefer the use of a double arm board for positioning the upper extremities. Application of active warming systems may prevent hypothermia should a lengthy laparoscopic procedure be anticipated. Similarly, use of pneumatic compression stockings is helpful in minimizing postoperative thromboembolic events. Previous incisions and scars and the surface anatomy is clearly marked prior to surgical preparation, and draping is commenced.

Before major laparoscopic procedures, a naso- or orogastric tube and a Foley catheter are usually placed to decompress the stomach and bladder, respectively, thereby decreasing the chance of injury of abdominal contents during insertion of the Veress needle and the initial trocar.

Proper positioning of equipment and personnel is essential for the smooth performance of most laparoscopic procedures.

Placement of Operative Team and Equipment

Proper positioning of equipment and personnel is essential for the smooth performance of most laparoscopic procedures.

The monitor, insufflator, light source should be preferably placed on a ceiling-mounted boom. The monitors (preferably two) should be diagonally opposite to the primary surgeon and the assistant surgeon at the direct eye-level. The insufflator and light source should also be within the surgeon's field of view to keep a constant monitoring of the intra-abdominal pressure.

For upper tract laparoscopic surgery, the surgeon and first assistant (camera person) usually stands opposite the area of surgical interest and the second assistant stands on the contralateral side of the table. During pelvic laparoscopic procedures, the surgeon and second assistant stand on the left side of the patient and the first assistant on the right side of the patient. Incoming lines from insufflator, suction/irrigation, and electrosurgical devices are properly secured to a part of the surgical drape so that they do not entangle with each other and do not interfere with the free flow of laparoscopic instrument exchange. Optional technology (e.g., harmonic scalpel, argon beam coagulator) must be arranged in an orderly fashion using either preexisting or improvised pockets of the surgical drape. Additional technology (e.g., high-speed electrical tissue morcellator, laparoscopic ultrasound probe) may be moved to the operating table depending on the surgeon's needs and the availability of space.

Modern laparoscopic operating room systems now integrate all equipment (optics, insufflant) that can be centrally controlled by a touch screen or by voice activation and make operating room logistics smoother. These systems also integrate digital image and video capture and additional technology such as electrocautery, ultrasound energy, etc. Moreover, they involve the use of high-resolution flat screen liquid crystal display monitors that are ergonomically superior.

A checklist ensuring that all essential equipments are present and operational should be completed just before initiating the pneumoperitoneum.

A checklist ensuring that all essential equipments are present and operational should be completed just before initiating the pneumoperitoneum. Specifically, this list should include (i) light cable on the table, connected to the light source and operational; (ii) laparoscope connected to the light cable and to the camera, with an image that is white balanced and focused on a gauze sponge; (iii) operational suction and irrigation functions of the irrigator/aspirator; (iv) insufflator tubing connected to the insufflator, which is turned on to allow the surgeon to see that there is proper flow of CO₂ through the tubing as kinking of the tubing would result in an immediate increase in the pressure recorded by the insufflator, with concomitant cessation of CO₂ flow; (v) an extra tank of CO₂ in the room; and (vi) a Veress needle, checked to ensure that its tip retracts properly and that, when it is connected to the insufflator tubing, the pressure recorded with 2-L/min CO₂ flow through the needle is less than 2 mmHg.

CONCLUSION

In recent years, urologic laparoscopy has breached new frontiers and has evolved into a specialized discipline in itself. Procedures that until recently were considered beyond the scope of laparoscopic surgery are now being increasingly performed safely and effectively by laparoscopic surgeons all over the world. The foundation of successful laparoscopic surgery lies in the strict adherence to age-old, established surgical principles, proper training of personnel in laparoscopic skills, and good equipment. In this

chapter we have covered the practical fundamentals of laparoscopic urology, which go a long way in ensuring a successful outcome for the patient and surgeon alike.

REFERENCES

1. Florio G, Silvestro C, Polito DS. Periumbilical veress needle pneumoperitoneum: technique and results in 2126 cases. *Chir Ital* 2003; 55(1):51–54.
2. Barwijnuk AJ, Jakubiak T, Dziag R. Use of the Hasson technique for creating pneumoperitoneum in laparoscopic surgery. *Ginekol Pol* 2004; 75(1):35–38.
3. Gill IS, Rassweiler JJ. Retroperitoneoscopic renal surgery: our approach. *Urology* 1999; 54(4):734–738.
4. Todorov G, Baev S, Velev G. Dissection with an ultrasonic dissector during laparoscopic cholecystectomy. *Khirurgiia (Sofia)* 1997; 50(2):43–44.
5. Romano F, Caprotti R, Franciosi C, et al. The use of LigaSure during pediatric laparoscopic splenectomy: a preliminary report. *Pediatr Surg Int* 2003; 19(11):721–724.
6. Landman J, Kerbl K, Rehman J, et al. Evaluation of a vessel sealing system, bipolar electrosurgery, harmonic scalpel, titanium clips, endoscopic gastrointestinal anastomosis vascular staples and sutures for arterial and venous ligation in a porcine model. *J Urol* 2003; 169:697–700.
7. Kwon AH, Matsui Y, Inui H, Imamura A, Kamiyama Y. Laparoscopic treatment using an argon beam coagulator for nonparasitic liver cysts. *Am J Surg* 2003; 185(3):273–277.
8. Eswar C, Badillo FL. Vascular control of the renal pedicle using the hem-o-lok polymer ligating clip in 50 consecutive hand-assisted laparoscopic nephrectomies. *J Endourol* 2004; 18(5):459–461.
9. Matin SF. Prospective randomized trial of skin adhesive versus sutures for closure of 217 laparoscopic port site incisions. *J Am Coll Surg* 2003; 196(6):845–853.
10. Gill IS, Kerbl K, Meraney AM, Clayman RV. *Campbell's Urology*. 8th ed. 3471–3473.
11. Carter JE. A new technique of fascial closure for laparoscopic incisions. *J Laparoendosc Surg* 1994; 4:143–148.
12. Elashry OM, Wolf JS Jr, Nakada SY, et al. Comparative clinical study of port closure techniques following laparoscopic surgery. *J Am Coll Surg* 1996; 183:335–344.
13. Garzotto MG, Newman RC, Cohen MS, et al. Closure of laparoscopic trocar sites using a spring-loaded needle. *J Urol* 1995; 45:310–312.
14. Leighton TA, Liu SY, Bongard FS. Comparative cardiopulmonary effects of carbon dioxide versus helium pneumoperitoneum. *Surgery* 1993; 113:527–531.

AUDIOVISUAL EQUIPMENT AND THE OPERATING ROOM OF THE FUTURE

James O. L'Esperance

Department of Urology, Naval Medical Center, San Diego, California, U.S.A.

Glenn M. Preminger

Division of Urologic Surgery, Comprehensive Kidney Stone Center, Duke University Medical Center, Durham, North Carolina, U.S.A.

- INTRODUCTION
- DIGITAL IMAGING
 - Analog vs. Digital Imaging
 - Endoscopic Camera Systems and Charged Coupled Device
- VIDEO ENDOSCOPY (AKA "CHIP ON A STICK")
 - Future Developments in Endoscopic Imaging
- DIGITAL IMAGING, VIDEO DOCUMENTATION, AND EDITING
- ILLUMINATION
- IMAGE DISPLAY SYSTEMS AND HIGH-DEFINITION VIDEO SYSTEMS
- THREE-DIMENSIONAL VIDEO ENDOSCOPIC/LAPAROSCOPIC SYSTEMS
- VIRTUAL REALITY
- ENDOSCOPIC/LAPAROSCOPIC SIMULATION
- INTERNET AND TELEMEDICINE
 - Laparoscopic Applications
- THE OPERATING ROOMS OF THE FUTURE—TODAY
- CONCLUSION
- SUMMARY
- REFERENCES

INTRODUCTION

Exposure remains one of the keys to success in both open and laparoscopic surgery.

Exposure remains one of the keys to success in both open and laparoscopic surgery.

In open surgery, the incision and retraction dictates the quality of exposure. In laparoscopy, high-quality optics are absolutely essential to provide the necessary exposure for a successful surgical intervention. Imaging, with particular emphasis on newer digital cameras and monitor technology, will be discussed in this chapter.

Other key features of the operating room of the future include documentation, education, and training. The ability to readily capture both video and still images is essential to all of these goals. The current technology allows the surgeon to capture entire procedures or just still images in either digital or analog form. However, management and manipulation of the data can be quite cumbersome and complex. Future developments will certainly be instrumental in allowing for more user-friendly interfaces.

Most current operating rooms were designed targeting the open surgery needs. As minimally invasive endoscopic procedures have gained favor, adjustments were made to accommodate laparoscopic and minimally invasive technology. More recent operating room designs address the fundamental differences between open and laparoscopic surgery. As a result, specialized rooms are being developed and are much more conducive to consistent and trouble-free laparoscopy and endourology.

DIGITAL IMAGING

Analog vs. Digital Imaging

In the 1980s, when video endoscopy was first introduced, intraoperative video and still images were captured and recorded using conventional analog cameras.

Despite universal availability and low cost, analog technology has several limitations and drawbacks when compared to the much improved digital systems commonly employed today.

Besides inferior image quality, analog photos and video recordings tend to lose resolution and degrade over time. In addition, storage of these analog images, in the form of video libraries, occupies extensive space.

Despite universal availability and low cost, analog technology has several limitations and drawbacks when compared to the much improved digital systems commonly employed today.

Analog images transmitted through individual fiberoptic bundles during various endourologic procedures are translated into continuous voltage waveforms to be viewed on an analog video monitor. Such analog image signals, susceptible to degradation during the translation process, typically lack the detail necessary to identify subtle pathologic processes. This limitation may be due to specific aspects of the signal being misinterpreted by the analog circuitry and results in the introduction of electronic noise (1,2). In some circumstances, subtle differences in exposure and visibility can also compromise recognition of important but delicate anatomical structures (Fig. 1).

Endoscopic Camera Systems and Charged Coupled Device

The current generation of endoscopic cameras employs the charge coupled device chip. The digital image is captured on a charge coupled device using either a digital still or a digital video camera. Photoreceptors, within the charge coupled device, rapidly assess the different light intensities that make up the endoscopic image. The charge coupled device generates pixels by converting unique light intensities within an image into corresponding electronic signals, which are then transmitted to a storage element on the chip (3).

Digital cameras are classified according to the amount of resolution determined by the number of pixels and the number of charge coupled device chips. The average charge coupled device resolution of single-chip camera ranges between 400,000 and 440,000 pixels, whereas three-chip cameras exceed 450,000 pixels. Display resolution of the cameras ranges between 350 to 450 and 700 horizontal lines for single-chip and three-chip cameras, respectively (4).

The development of the three-chip camera that contains three individual charge coupled device chips for the primary colors—red, green, and blue—represented a significant improvement in charge coupled device camera technology (Fig. 2).

In addition to composite super video home system and component signals, the three-chip cameras also provide an “uncoded” red, green, and blue signal. Color separation is achieved using a prism system overlying the chips (5). This three-chip camera design provides improved color fidelity and enhanced image resolution. Moreover, three-chip cameras produce less “noise” due to the pure red, green, and blue signals (6,7). A digital converter capturing each voltage signal as an image translates the voltage values into discrete numbers, either as 0 or 1. The encoded numbers for each image element or pixel include information on color, light intensity, and contrast. These variables can then be modified using image-processing software within the camera (8).

Theoretically, three-chip cameras produce better quality images than single-chip cameras. Despite the apparent advantages of three-chip cameras, some clinical comparisons have favored one-chip systems. Using normal video monitors, previous studies have implied that the resolution between the two cameras did not alter the visual perception of an image. For endoscopic imaging, digital contrast enhancement is a feature more important than the number of camera chips.

Three-chip cameras appeared to have no advantage over well-designed single-chip systems (1,5,9). However, this apparent limitation may change with the introduction of high-resolution digital monitors and high-definition television, because the amount of image information and the degree of perception are increased with these digital-imaging modalities (10).

For endoscopic imaging, digital contrast enhancement is a feature more important than the number of camera chips.



FIGURE 1 ■ Schematic representation of analog vs. digital video systems. Abbreviation: CCD, charge coupled device.



FIGURE 2 ■ Three charge coupled device system as opposed to one charge couple device. Red, green, and blue sent to three separate charge couple devices by a prism. Abbreviation: CCD, charge coupled device.

The development of the digital video endoscope has been a major advance in the endoscopic systems.

Digital videoendoscopes have fewer interfaces. The digital information is directly transmitted to an image display unit, with minimal image loss, interference, and distortion.

The replacement of smaller caliber laparoscopes with an integrated digital videoendoscope can be expected in the near future.

VIDEO ENDOSCOPY (AKA “CHIP ON A STICK”)

The development of the digital video endoscope has been a major advance in the endoscopic systems. As shown in Figure 3, miniaturization of chip technology, now allows a charge couple device chip to be incorporated at the distal end of the endoscope (chip on a stick or EndoEye™^a).

Instead of relaying optical images from the objective lens at the distal end of the scope to a camera attached to the eyepiece, the image is immediately captured by the charge couple device chip, digitized, and converted into electrical signals for transmission.

Digital video endoscopes have fewer interfaces. The digital information is directly transmitted to an image display unit, with minimal image loss, interference, and distortion (11,12).

The creation of true video endoscopes especially benefits the flexible laparoscope and the videoscope (Fig. 4).

For the first time in laparoscopy, the absence of internal optics in the long and flexible shafts of such instruments allows durable deflection mechanisms and increases the durability of flexible endoscopes (3,13,14). With no need to attach a camera head to the eyepiece of the scope, the videoscope cable can be secured to the light cord connecting to the video system. As a result, the setup is more lightweight and convenient. To date, this technology has been incorporated only into larger, rigid endoscopes (laparoscopes) and some flexible endoscopes (colonoscopes, bronchoscopes, and cystoscopes) (15–17). However, recent technological advances have now allowed miniaturization of charge couple device chips.

The replacement of smaller caliber laparoscopes with such an integrated digital video endoscope can be expected in the near future.

Another development in digital camera technology includes the use of a single-monochrome charge couple device chip using alternating red, green, or blue illumination to form a color image rather than using three chips with three separate color filters. This design reduces the volume of the instrument while taking advantage of established high-resolution monochrome charge couple device chip technology (11). This technology design, currently utilized in a digital videocystoscope, has been recently incorporated into digital laparoscopes as well.

Future Developments in Endoscopic Imaging

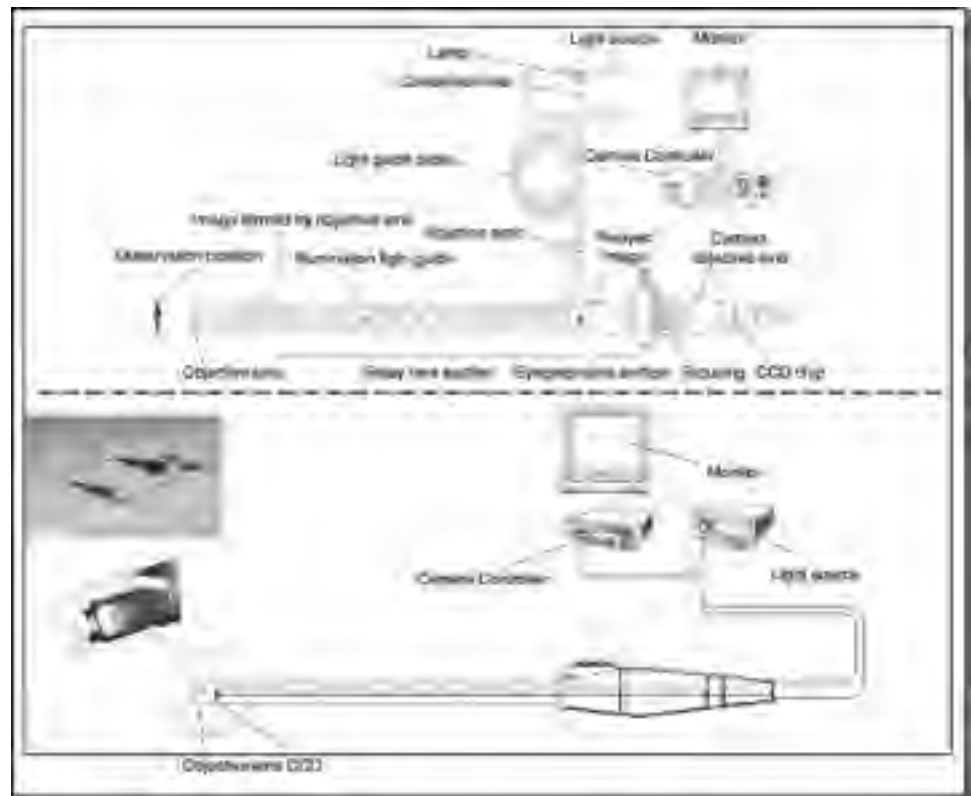
The reflected white light used to produce an endoscopic image can also be absorbed, scattered, or cause “autofluorescence.” Such additional light–tissue interactions are being explored for advanced imaging technologies. Endoscopic imaging may be improved by incorporating an optical magnification lens system at the tip of the endoscope (magnification) or by utilizing other light–tissue interactions (spectroscopy). Magnifying or zoom endoscopes consist of a lens system built into the tip of instrument, which can be used to magnify small areas up to 100-fold. During optical spectroscopy, different spectra can be identified, depending on the wavelength of the light used, and various tissue properties.

FIGURE 3 ■ “Chip on a stick” or EndoEye™ technology. This technological advance allowed for the development of the flexible laparoscope. Abbreviation: CCD, charge coupled device. Source: Courtesy of Olympus America.



^aOlympus America, Melville, NY.

FIGURE 4 ■ Videoscope technology vs. traditional rod and lens technology.
 Abbreviation: CCD, charge coupled device.
 Source: Courtesy of Olympus America.



Highly tissue-specific spectra may be used to identify areas of ischemia, inflammation, and, most importantly, nonapparent malignancy.

Highly tissue-specific spectra may be used to identify areas of ischemia, inflammation, and, most importantly, nonapparent malignancy.

With this technique, multiple "optical biopsies" can be taken from suspicious areas, instead of conventional histological biopsies (11,18). Although still investigational, these techniques are attractive options for future laparoscopic and endourologic evaluation of the urinary tract.

DIGITAL IMAGING, VIDEO DOCUMENTATION, AND EDITING

Over the last few years, digital imaging has slowly revolutionized the field of video endoscopy.

Over the last few years, digital imaging has slowly revolutionized the field of video endoscopy.

Images captured initially in the analog format could later be converted digitally using a digital camera or scanner. However, the introduction of digital still cameras has taken image documentation and editing to a new level. Currently, the newest surgical video systems have integrated digital image capture system, allowing immediate capturing of still images from endoscopic procedures (Fig. 5) (3). Alternatively, a less-expensive digital still image capture adapter can be connected to endoscopic camera systems (6). Digital still images can usually be recorded in Joint Photographic Experts Group or JPEG, tagged image file format or TIFF, or bitmap formats. These digital images can be edited and optimized on the computer using various graphic software packages.

Incorporating medical images into the patient's record as well as creation of an image library can enhance urologic practice (19,20).

The quality of the digital image required depends upon its purpose. Low-resolution images, in the range of one to two megapixels, can be used for email attachments or Power Point™ presentations. However, a higher quality image, between three to four megapixels, is more useful if a printed image is required. In cases where storage is not an issue, the image should be obtained at its highest resolution, thereby allowing for future image manipulation.

Until recently, the majority of video recordings during endoscopic procedures could be performed with conventional analog video home system or SVHS formats, which could be digitally converted. The introduction of digital video-recording devices now allows direct recording of video footages into a digital format, such as digital video, Moving Picture Experts Group and audio video interlevel (Fig. 6). These video-capturing

Incorporating medical images into the patient's record as well as creation of an image library can enhance urologic practice.



FIGURE 5 ■ Still images and short video clips (depending on resolution) can be captured on a digital card. Direct digital video stream can be captured on a computer, digital camcorder, or digital recorder via an IEEE 1394 fire-wire connector on the back panel. *Source:* Courtesy of Olympus America.



FIGURE 6 ■ Digital capture is possible and increasingly flexible, offering the ability to store directly to DVD in all forms of Moving Picture Experts Group or AVI. Also offering ethernet connectivity providing video conferencing capability. Video capture directly to an 80-gigabyte hard drive is also possible or streaming to computer or video camera via SVIDEO, IEEE-1394, serial port, or parallel port is also possible. *Source:* Courtesy of Stryker Endoscopy.

Storage of large numbers of digital files remains a big issue. Picture archiving and communication systems are under development to play an important role in “filmless” medical imaging in the near future.

systems can be part of an expensive commercial integrated video system, digital video camera, digital versatile disk recorder, or a low-cost personal computer with digital video capture card (21). digital video editing may be performed on a personal computer using various editing programs, e.g., Adobe® Premiere or Movie Maker.

Small still digital images can be stored on different digital storage media (SmartMedia, Compact Flash, Secure Digital, MultiMedia card, or Memory Stick) up to 1 gigabyte, depending on the media used. Zip disk (up to 750 megabytes), CD-ROM (700 MB), and, lately, digital versatile disk or DVD (17 GB) can be utilized for larger files, especially video clips.

Storage of large numbers of digital files remains a big issue. Picture archiving and communication systems are under development to ultimately play an important role in “filmless” medical imaging in the near future (22–24).

ILLUMINATION

Illumination of the operative field is an integral part of laparoscopic surgery. High-intensity light sources, usually halogen and xenon, are currently employed the most. However, halogen sources produce a slightly yellow light requiring compensation with white balancing of the endoscopic camera system. Xenon sources provide a more natural white light. Fiberoptic bundles contain either glass fiber or special fluid run through the endoscope and permit rapid transmission of light to the operative field and digital information in a small space. Although less efficient in light transmission due to a fiber mismatch at the junctions of the light cable and endoscope, the glass fiber bundles are more flexible, and therefore more widely used (12).

Modern light sources often have an automatic light-sensing feature, which quickly adjusts the light output as required by the camera. This automatic light adjust-

Shadows play an important role in depth perception and spatial orientation. Endoscopic task performance significantly improves with video systems providing proper illumination and appropriate shadows in the operative field.

The development of high-quality image display systems has become essential during endoscopic surgery.

Current applications of high-definition television in medicine include diagnostic and therapeutic maneuvers during endoscopic surgery. The increased resolution and clarity have been shown to greatly facilitate surgical performance.

ment feature is particularly helpful during endoscopic procedures, as the endoscope may be rapidly moved throughout different parts of the urinary tract with variable levels of illumination. Light intensity is automatically adjusted to maintain a preset level. Similarly, some digital camera systems are equipped with an “automatic iris” system, which electronically increases or decreases the “aperture” of the camera shutter. Automatic intensity-adjusting light source is not required if the camera system is equipped with such a light-sensing feature (2). Newer charge couple device or image sensor-based endoscopic cameras feature electronic exposure. This system varies the effective exposure period (i.e., light gathering time) of the charge couple device as the live image is captured. Typical charge couple device exposure periods range from approximately 1/60 of a second to 1/10,000 of a second under very bright conditions. This electronic process can be used to maintain the brightness of the image. When the image brightness must be reduced to improve picture clarity, the image signal exposure period can be reduced electronically instead of adjusting the iris of the light source.

Shadows play an important role in depth perception and spatial orientation. Endoscopic task performance significantly improves with video systems providing proper illumination and appropriate shadows in the operative field (25).

Many of the current endoscopes employ a simple frontal illumination technique that produces an optically flat and shadowless image with resultant poor contrast. Using a single-point or multipoint illumination system, newer illumination and imaging technologies provide shadow-inducing systems. One of these techniques employs the use of two independent illumination fiber bundles, with one fiber bundle ending at the front lens, as designed in conventional endoscopes, and the other fiber bundle ending behind the tip of endoscope. This configuration results in an improved image with better contrast due to shadow formation. Spatial orientation and perception between anatomical structures are considerably enhanced (4).

IMAGE DISPLAY SYSTEMS AND HIGH-DEFINITION VIDEO SYSTEMS

The development of high-quality image display systems has become essential during endoscopic surgery.

Previous studies have demonstrated that the inherent optical quality of most endoscopes and charge couple device camera exceeds the display resolution of standard television (26). Because of the limited resolution of current analog National Television Standards Committee, phase-alternation-by-line, and sequential color and memory monitors, there is a demand for higher resolution image display systems. One such digital display system is the high-definition television. The most common high-definition television formats used in the United States are 720p and 1080i. The “p” represents progressive scanning, meaning that each scan includes every line for a complete picture, whereas the “i” signifies interlaced scanning, with each scan including alternate lines for half a picture. These scan rates translate into a frame rate of up to 60 frames per second, doubling the frame rate of conventional television monitors. High-definition television offers greatly enhanced picture quality with improved image resolution. High-definition television pixel number ranges from one to two millions, compared to National Television Standards Committee, phase-alternation-by-line, or sequential color and memory’s pixel number ranging from 300,000 to 1,000,000 pixels (Table 1).

The other significant feature of the high-definition television format is its wider aspect ratio (the width-to-height ratio of the screen) of 16:9 as compared with National Television Standards Committee, phase-alternation-by-line, and sequential color and memory screens, which have an aspect ratio of 4:3. The wider aspect ratio provides more information for the viewer, thereby enhancing both diagnostic and therapeutic interventions (6,27).

Current applications of high-definition television in medicine include diagnostic and therapeutic maneuvers during endoscopic surgery. This increased resolution and clarity have been shown to greatly facilitate surgical performance (6).

The extremely high-resolution image afforded by high-definition television may resemble a three-dimensional (3-D) video image. Although not a true three-dimensional image, the increased video information provides the perception of depth.

The future application of high-definition imaging technology based on charge couple device chips would improve endoscopic image resolution. The European standard high-definition imaging chip resolution is 2,340,250 pixels, resulting in 1250 horizontal lines. High-definition imaging has the advantage of resolution enhancement for image brilliance and the augmentation of secondary depth clues such as shadows. Other techniques under development for image resolution enhancement include

TABLE 1 ■ Broadcast Formats

Format	Lines of resolution	Cycles/sec	Aspect ratio
National Television Standards Committee	525	60	4:3 (standard screen)
Phase-alternation-by-line/sequential color and memory	525	50	4:3
HDTV — United States	1125	60	16:9 (wide screen)
HDTV — Europe	1250	50	16:9

Abbreviation: HDTV, high-definition television.

Improved resolution and color separation of high-definition imaging provides better diagnosis and enhances the effect of secondary spatial cues, resulting in easier orientation, particularly if the images are combined with improved illumination.

Stereoscopic vision is essential for precise surgical performance and operative safety during laparoscopic and endoscopic surgery.

the use of complementary metal oxide semiconductor technology to replace the charge couple device sensors (4). Both complementary metal oxide semiconductor and charge couple device imagers are manufactured in a silicon foundry; and the equipment used is similar. However, alternative manufacturing processes and device architectures make the imagers quite different in both capability and performance. Although not cost-effective, the use of a charge couple device processor to integrate other camera functions, like the clock driver and signal processing, is technically feasible. Such functions are normally implemented into secondary chips. Thus, most charge couple device cameras contain several chips. One of the major benefits of complementary metal oxide semiconductor cameras over the charge couple device design lies in the high level of product integration that can be achieved through virtually all of the electronic camera functions onto the same chips. Typically, complementary metal oxide semiconductor processor allows lower power usage and lower system cost.

Improved resolution and color separation of high-definition imaging provides better diagnosis and enhances the effect of secondary spatial cues, resulting in easier orientation, particularly if the images are combined with improved illumination.

Despite its current high cost, the price of high-definition television cameras and monitors will continue to decline as newer high-definition television products come onto the consumer market. With further optimization of size and weight of the camera system, high-definition television can become a standard feature for endoscopic imaging and display during endoscopic and laparoscopic procedures.

THREE-DIMENSIONAL VIDEO ENDOSCOPIC/LAPAROSCOPIC SYSTEMS

Stereoscopic vision is essential for precise surgical performance and operative safety during laparoscopic and endoscopic surgery.

However, most current video endoscopic systems provide a two-dimensional, flat image. Recent advances in imaging technology allow the application of three-dimensional video techniques to laparoscopic surgery (Fig. 7). Most of the current three-dimensional video systems have four basic principles of stereoendoscopic image processing in common: (i) image capture, (ii) conversion of 60 to 120 Hz images, (iii) presentation of left and right images on a single monitor, and (iv) separation of the left and right eyes images (29,30). A three-dimensional video endoscopic system captures two slightly different images of the operative field, which are then transmitted to the monitor so that the images of the right and left cameras are alternatively displayed (sequential display procedure) with a frequency of 100/120 Hz. Several image-capturing methods have been employed, including the dual-lens system, single-lens systems, electronic video endoscopic system, and a system of single rod lenses with two beam paths. The three-dimensional imaging display may be achieved by two methods, either active liquid crystal display glasses or polarizing glasses. In both instances, the brain fuses the right- and left-sided images on the appropriate imaging site. This technology is based on the physiology of retinal image persistence and is quite different from normal stereoscopic imaging (5). The presentation of the two images independently to the left and right eye is an alternative to dual projection. This technology is currently available as part of the *da Vinci*[®] Robotic System^b. Head-mounted display technology may offer another means of delivering separate images to each eye without dual projection.

^bIntuitive Surgical, Sunnyvale, CA.

FIGURE 7 ■ Three-dimensional stereoendoscope. Schematic diagram of three-dimensional video imaging system. The two images are projected on a screen, and the glasses bring the two together, giving the impression of a three-dimensional image. Alternatively, the separate images can be presented separately to the left and right eye through a head set. This is currently available as a part of the *da Vinci*® robotic system and can theoretically be developed via a head-mounted display. *Abbreviation:* 3D, three-dimensional. *Source:* From Ref. 28.



Comparisons of two-dimensional and three-dimensional video systems have offered conflicting results in experimental and clinical practice. Despite the benefits of enhanced depth perception provided by three-dimensional systems demonstrated in various studies, three-dimensional endoscopic technology has not been widely used due to its high cost and relative lack of availability. Moreover, some studies have demonstrated no evidence of improved performance while using three-dimensional systems during endoscopy and suggest that a higher-resolution video system might be more advantageous than the three-dimensional endoscopic imaging (27,31,32). The three-dimensional imaging systems are currently used for true stereoscopic imaging during robot-assisted laparoscopic procedures (33–35).

Endourologic procedures require specific training to achieve competency.

Advances in virtual reality simulation offer a practical tool for urologists to practice various endourologic procedures from the basic to the most complex in an inanimate, but dynamic, life-like environment without risk for the patients or ethical issues.

VIRTUAL REALITY ENDOSCOPIC/LAPAROSCOPIC SIMULATION

Endourologic procedures require specific training to achieve competency.

Often, there are reduced training opportunities for residents due to a limited number of clinical cases. Moreover, ethical and cost issues may further limit the use of animal or cadaver models for training purposes (36–38). Hands-on training using bench models can successfully teach the novice laparoscopic skills, but lack the ability to simulate clinical conditions (39). Moreover, inanimate simulators lack the realistic feedback of living tissue.

Advances in virtual reality simulation offer a practical tool for urologists to practice various endourologic procedures from the basic to the most complex in an inanimate, but dynamic, life-like environment without risk for the patients or ethical issues.

A realistic virtual reality surgical simulation consists of accurate reproduction of anatomic structures, appropriate tactile feedback, and spatial cues.

Because endourologic procedures require little in the way of complex anatomic and tactile feedback, one of the earliest simulators in urology was a virtual reality ureteroscopy simulator^c (36,37,40). This simulator allowed urologists to explore the ureter and kidney to identify pathologic processes, e.g., stones and tumors. However, this early simulator was limited by the lack of true anatomical representation and inadequacy in computer graphics. Virtual cystoscopy and ureteroscopy using either rigid or flexible endoscopes can be performed using a new endoscopic simulator^d built, applying the most recent advances in computing power, virtual reality graphics, and physical modeling techniques.

Real-time fluoroscopy with simulation of C-arm control and viewing of fluoroscopic images of injected contrast can also be simultaneously combined with simulated endoscopic procedures. Several endourologic procedures including cystoscopy, retrograde pyelography, insertion of guide wire, ureteral stenting, ureteroscopy, stone fragmentation, and fragment removal using various tools can be realistically simulated.

^cImmersion Medical, Gaithersburg, MD.

^dURO Mentor System, Symbionix, Tel Aviv, Israel.

Recent studies have demonstrated that, using this virtual reality simulator, urologic trainees acquired ureteroscopic skills more rapidly.

Recent studies have demonstrated that, using this virtual reality simulator, urologic trainees acquired ureteroscopic skills more rapidly (41–44).

In fact, the use of both laparoscopic and ureteroscopic simulators has led to a significant reduction in the learning curves of both routine and complex endoscopic procedures. Endourologic skills can also be validated using virtual reality simulation (38,45).

Due to further advances in computer and software technology, virtual reality simulation has become more realistic for the performance of laparoscopic procedures (46–49). Similar to the aviation industry, virtual reality simulation will likely be incorporated into the training, testing, and credentialing of endourologists and laparoscopic surgeons over the next 5 to 10 years.

INTERNET AND TELEMEDICINE

In recent years, telemedicine, defined as the use of electronic information and communication technologies to provide and support health care from a distance, has become an important aspect in patient care. Advances in digital imaging, high-speed computer connections, and the widespread availability of the Internet have allowed a steady growth of telemedicine within urology (50). Digital images obtained from various sources such as a digital still or video camera, scanner, computed tomography, and magnetic resonance imaging can be exchanged over the Internet at high speed. Current transmission modalities includes the integrated services digital network transmitting 128 kilobits per second, T1 lines transmitting 1.54 megabits per second (Mbps), coaxial cable (up to 6 Mbps), asymmetric digital subscriber line (1 to 3 Mbps) (6,8,19).

Two types of telemedicine systems are currently available. One is the synchronous, real-time video conferencing. In general, real-time motion requires that images are generated at a speed of 30 frames per second (51).

The advantage of “live” video teleconferencing consists of real-time interaction between physicians and patients with full motion audiovisual images, allowing a true physician–patient relationship.

The advantage of “live” video teleconferencing consists of real-time interaction between physicians and patients with full motion audiovisual images, allowing a true physician–patient relationship.

In addition, several medical centers can be linked with the teleconferencing facility to promote tele-education and teleconsultation. With proper equipment, digital images including endoscopic pictures, pathologic slides, and radiologic images can also be transmitted in real time. The high cost of real-time telemedicine systems and communication networks has currently prevented the widespread use of this technology. For example, a teleconferencing system can cost more than US\$80,000 and that does not include the connection fee which can be as high as US\$800 per month (52). Recent studies have demonstrated that one could provide high-quality high-definition television image-orientated telemedicine via integrated services digital network lines or communication satellites. However, the minimum set-up cost, greater than US\$1,000,000, is still prohibitive (53).

Alternatively, telemedicine can also be accomplished using an asynchronous or “store and forward” system, whereby the information is transmitted via email or the Internet. The recipients can review and respond to the information transmitted at their convenience, as the data are stored in a locally accessible, computerized data storage and retrieval system. Many surgical disciplines, including urology, are increasingly utilizing this technology. Current store and forward technology are also progressively improving with better software development and secure transmission of encrypted data over the Internet (19). Despite lack of real-time interaction, these systems remain very effective and useful tools for medical care and endourologic training (8).

Standardization of input devices for image data exchange is essential for telemedicine. There is an urgent need for future standardization and integration of telemedicine hardware (53).

Standardization of input devices for image data exchange is essential for telemedicine. There is an urgent need for future standardization and integration of telemedicine hardware.

Although the digital imaging and communications in medicine standard exists for radiological images, there is no standard for other digital images such as endoscopic still pictures or video clips.

The upcoming challenge for telemedicine lies within the decisions made as regards physician licensing requirements, regulation of telemedicine, reimbursement of consultations, and protection of patient confidentiality.

Laparoscopic Applications

Despite the shortcomings outlined above, telemedicine and even telesurgery have become a reality. Kavoussi and coworkers in 1994 demonstrated their initial laboratory experience in telerobotic-assisted laparoscopic surgery (54–59). Recently, urologic

As one looks forward into the 21st century, the future of telemedicine looks brighter.

Technological improvements lowering the cost of imaging devices and the cost of utilizing specialized telecommunications lines will make telemedicine systems even more affordable than they are today and greatly enhance the performance of laparoscopic procedures in urology.

Several studies have identified significant stressors to the surgeon induced by laparoscopy, including monitor placement, camera holding, trocar placement, and table position and height.

Robotics and head-mounted displays are other recent advancements effecting surgeon comfort.

The development of laparoscopic instruments with endowrist capabilities will further bridge the gap between robotics and pure laparoscopy.

laparoscopic telesurgery has been performed in a clinical setting. In this study, five patients in Rome, Italy, underwent laparoscopic procedures in a center where laparoscopy was only recently introduced (60). Nine thousand kilometers away in Baltimore, United States, a more experienced team oversaw the procedures in real time, offered advice, provided quality control, and even operated instruments remotely. The cases performed included a laparoscopic nephrectomy. This revolutionary approach to telemedicine has opened the door for more widespread applications of laparoscopic techniques, enhanced training, and improved patient care.

As one looks forward into the 21st century, the future of telemedicine looks brighter. Advances in digital imaging resolution and improvements in transmission bandwidth will make telesurgery and decision-making through telemedicine more accurate.

Technological improvements lowering the cost of imaging devices and the cost of utilizing specialized telecommunications lines will make telemedicine systems even more affordable than they are today and greatly enhance the performance of laparoscopic procedures in urology (54,59,61,62).

THE OPERATING ROOMS OF THE FUTURE—TODAY

Most current operating rooms were designed with open surgery needs in mind. As endourology and laparoscopy have gained favor, adjustments were made to accommodate advanced imaging techniques and additional minimally invasive technology. More recent operating room designs address the fundamental differences between open and laparoscopic surgery. Thus, specialized rooms were developed to be much more conducive to the consistent, trouble-free performance of laparoscopic and endourologic procedures.

The development of endoscopic carts containing video monitors, cameras, video recording equipment, insufflation devices, and carbon dioxide tanks facilitated laparoscopy. As mobile units, these carts may be transported from room to room, allowing for laparoscopic capabilities in rooms otherwise designed for open surgery. The quality of the component parts of these systems can be variable and subject to limitations introduced by any of the individual parts. In addition, the mobility of these complex systems introduces further potential for malfunction or inconsistent performance. The potential for carbon dioxide, and therefore surgical exposure, running out during key portions of procedures is another disadvantage of these systems.

Another issue relating to suboptimal operating room design is the effect of imperfect ergonomics on surgeon comfort from a musculoskeletal standpoint.

Several studies have identified significant stressors to the surgeon induced by laparoscopy, including monitor placement, camera holding, trocar placement, and table position and height (63–66).

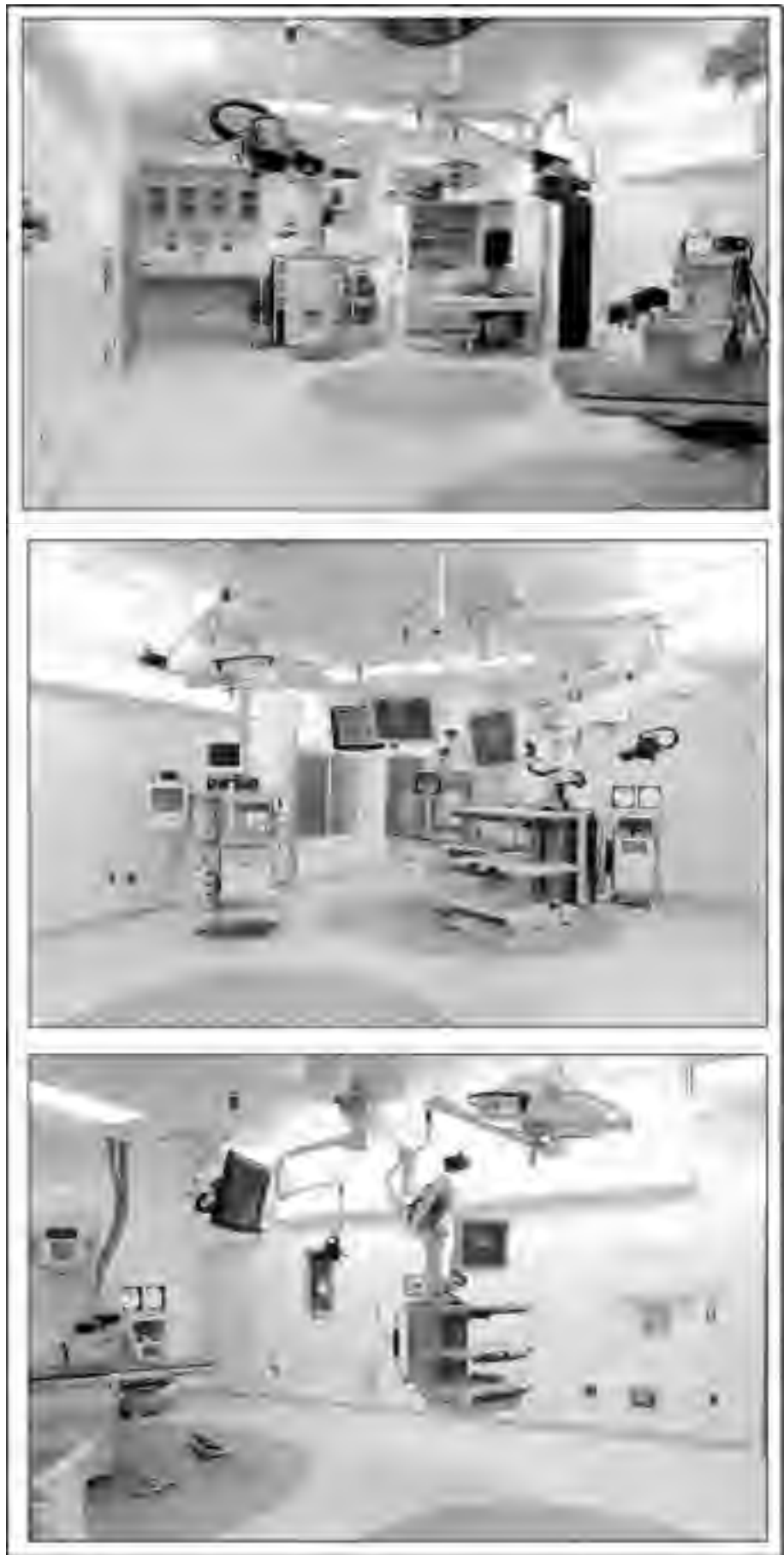Ceiling-mounted monitors and designs focused on the laparoscopic surgeon represent operating room updates, increasing versatility in the ergonomics surrounding laparoscopy (Fig. 8). Carbon dioxide delivered to the room constantly through a wall connector obviates the problem of tank turnover at vital points during procedures. Whether or not these specially designed operating rooms improve upon musculoskeletal complications in surgeons remains to be determined, even if some studies showed encouraging results in this regard and improved overall operating room efficiency (67,68).

Robotics and head-mounted displays are other recent advancements effecting surgeon comfort.

Robotics can take the form of either automating some portion of the operation or assisting during the entire operation. Automating the act of camera holding has been shown to be advantageous in terms of ergonomics and procedural efficiency. (69–71) The procedural advantages of robotic assistance to the surgeon are becoming more apparent as robotic surgery further penetrates the operating room. These advantages include three-dimensional stereoscopic vision totally controlled by the operating surgeon, increased instrument range of motion, and markedly improved comfort for both the surgeon and assistants. Immature published data show a potential translation of technical advantages into improved patient outcomes. Head-mounted display may represent an advance providing ergonomic advantages to the surgeon (Fig. 7). The introduction of three-dimensional vision available to the laparoscopic surgeon may bridge the gap between robotic and laparoscopic surgery. However, results regarding the true advantages of such technology are still conflicting (72,73).

The development of laparoscopic instruments with endowrist capabilities further bridging the gap between robotics and pure laparoscopy may be anticipated in the near future.

FIGURE 8 ■ Current (future) endoscopic/laparoscopic operating room. Ceiling-mounted flat panel monitors. Built-in endoscopy table with adequate room for laparoscopic applications. Ceiling-mounted camera for external footage. Touch panel control allowing for routing of different source images on different monitors. Wall plug in for C-arm integration with room monitors. Wall panel-integrating operating room with audiovisual center allowing for video capture, integration with conference rooms, and teleconferencing.



A central concern in the operating room of the future will continue to be the adequate training necessary to surgeons to safely perform laparoscopy. Video conferencing technology has still several limitations, thereby leaving room for further improvements. As this technology becomes more reliable, remote surgical mentorship will become more feasible. Although scant studies addressed the feasibility of such a concept, the progressive growth of remote laparoscopic training accompanying technology improvements seems reasonable.

The reduction of patients morbidity associated with minimally invasive procedures will continue to drive improvements of endoscopic technology. Tremendous progress, especially in the realm of optics and digital image processing, has occurred in the past decade. It is also clear that over the next few years, high-definition digital processing and high-definition television monitor technology will almost certainly provide even further enhancements. The field of ergonomics and surgeon comfort has also recently become a focus as data accrues regarding musculoskeletal complications in surgeons. The future will certainly see the continued development of operating rooms equipped with instrumentation providing advantages to both surgeon and patient. Undoubtedly, these advantages will include further improvements in digital imaging technologies, more streamlined room design, and ergonomic optimization.

CONCLUSION

The introduction of technological advances such as high-definition television, three-dimensional laparoscopy, and further miniaturization of high-resolution digital video cameras should enhance laparoscopic surgical proficiency, and further broadening of laparoscopic applications in urology. These enhancements, coupled with the recent advances in telemedicine and surgical simulation, should also improve laparoscopic training and skill acquisition, decrease operative times and costs, minimize morbidity, and overall improve patient care. Furthermore, the integration of all of these technological advancements within specially designed operating rooms should maximize the application of each individual advance and allow for improved ergonomic performance of minimally invasive urologic procedures.

SUMMARY

- Exposure remains one of the keys to success in both open and laparoscopic surgery.
- In laparoscopy, high-quality optics are absolutely essential to provide the necessary exposure for a successful surgical intervention.
- The development of the digital video endoscope has been a major advance in the endoscopic systems.
- The replacement of smaller caliber laparoscopes with integrated digital video endoscope can be expected in the near future.
- Over the last few years, digital imaging has slowly revolutionized the field of video endoscopy.
- Incorporating medical images into the patient's record and creating an image library can enhance urologic practice.
- High-quality display systems are essential during endoscopic surgery.
- Advances in virtual reality simulation offer a practical tool to practice endourologic procedures in an inanimate but dynamic, life-like environment.
- Endourologic operative skills may be acquired more rapidly using virtual reality simulators.
- Technological improvements lowering the cost of imaging devices and the cost of utilizing specialized telecommunications lines will make telemedicine systems more affordable and greatly enhance the performance of laparoscopic procedures in urology.
- Robotics and head-mounted displays effect surgeon comfort.
- The integration of technologic advancements within specially designed operating rooms allow for improved ergonomic performance of minimally invasive urologic procedures.

REFERENCES

1. Aslan P, Kuo RL, Hazel K, Babayan RK, Preminger GM. Advances in digital imaging during endoscopic surgery. *J Endourol* 1999; 13: 251–255.
2. Preminger GM. Video imaging and documentation. In: Smith AD, Badlani GH, Bagley DH, et al., eds. *Smith's Textbook of Endourology*. St. Louis: Quality Medical Publishing, Inc., 1996.
3. Auge BK, Preminger GM. Digital Cameras and Documentation in Urologic Practice. *AUA Update Series* 2002; Volume XXI.
4. Schurr MO, Kunert W, Arezzo A, Buess G. The role and future of endoscopic imaging systems. *Endoscopy* 1999; 31: 557–562.

5. Hanna G, Cuschieri A. Image display technology and image processing. *World J Surg* 2001; 25:1419–1427.
6. Kuo RL, Preminger GM. Current urologic applications of digital imaging. *J Endourol* 2001; 15:53–57.
7. Weinberg DS. Digital imaging as a teaching tool for pathologists. *Clin Lab Med* 17:229–244.
8. Kuo RL, Delvecchio FC, Babayan RK, Preminger GM. Telemedicine: recent developments and future applications. *J Endourol* 2001; 15:63–66.
9. Berci G, Wren SM, Stain SC, Peters J, Paz-Partlow M. Individual assessment of visual perception by surgeons observing the same laparoscopic organs with various imaging systems. *Surg Endosc* 1995; 9:967–973.
10. Preminger GM, Delvecchio FC, Birnbach JM. Digital image recording: an integral aspect of video endoscopy. *Stud Health Technol Inform* 1999; 62:268–274.
11. Boppart SA, Deutsch TF, Rattner DW. Optical imaging technology in minimally invasive surgery. Current status and future directions. *Surg Endosc* 1999; 13:718–722.
12. Cuschieri A. Technology for minimal access surgery. *BMJ* 1999; 319:1304.
13. Afane JS, Olweny EO, Bercowsky E, et al. Flexible ureteroscopes: a single center evaluation of the durability and function of the new endoscopes smaller than 9Fr. *J Urol* 2000; 164:1164–1168.
14. Levisohn PM. Safety and tolerability of topiramate in children. *J Child Neurol* 2000; 15(suppl 1): S22–S26.
15. Knyrim K, Seidlitz H, Vakil N. Current developments in electronic endoscopy. *Endoscopy* 1992; 24(suppl 2):502–505.
16. Niwa H, Kawaguchi A, Miyahara T, Koyama H. Clinical use of new video-endoscopes (evis 100 and 200). *Endoscopy* 1992; 24:222–224.
17. Pelosi MA, Kadar N, Pelosi MA 3rd ed. The electronic video operative laparoscope. *J Am Assoc Gynecol Laproscopists* 1993; 1:54–57.
18. Fockens P. Future developments in endoscopic imaging. *Best Pract Res Clin Gastroenterol* 2002; 16:999–1012.
19. Kuo RL, Aslan P, Dinlenc CZ, et al. Secure transmission of urologic images and records over the Internet. *J Endourol* 1999; 13:141–146.
20. Kuo RL, Delvecchio FC, Preminger GM. Use of a digital camera in the urologic setting. *Urology* 1999; 53:613–616.
21. Wurnig PN, Hollaus PH, Wurnig CH, Wolf RK, Ohtsuka T, Pridun NS. A new method for digital video documentation in surgical procedures and minimally invasive surgery. *Surg Endosc* 2003; 23:232–235.
22. Arenson RL, Andriole KP, Avrin DE, Gould RG. Computers in imaging and health care: now and in the future. *J Digit Imaging* 2000; 13:145–156.
23. Fujino MA, Ikeda M, Yamamoto Y, et al. Development of an integrated filing system for endoscopic images. *Endoscopy* 1991; 23:11–15.
24. Martinez R, Cole C, Rozenblit J, Cook JF, Chacko AK. Common object request broker architecture (CORBA)-based security services for the virtual radiology environment. *J Digit Imaging* 2000; 13:59–70.
25. Emam TA, Hanna G, Cuschieri A. Ergonomic principles of task alignment, visual display, and direction of execution of laparoscopic bowel suturing. *Surg Endosc* 2002; 16:267–271.
26. von Orelli A, Lehareinger Y, Rol P, Niederer P, Doswald D, Felber N. High-definition true-colour television for use in minimally invasive medical procedures. *Technol Health Care* 1999; 7(1):75–84.
27. van Bergen P, Kunert W, Buess GF. The effect of high-definition imaging on surgical task efficiency in minimally invasive surgery: an experimental comparison between three-dimensional imaging and direct vision through a stereoscopic TEM rectoscope. *Surg Endosc* 2000; 14:71–74.
28. www.stereo3d.com.
29. Durrani AF, Preminger GM. Three-dimensional video imaging for endoscopic surgery. *Comput Biol Med* 1995; 25:237–247.
30. Tan YH, Preminger GM. Advances in video and imaging in ureteroscopy. *Urol Clin North Am* 2004; 31:33–42.
31. Herron DM, Lantis JC, Maykel J, Basu C, Schwaitzberg SD. The 3-D monitor and head-mounted display. A quantitative evaluation of advanced laparoscopic viewing technologies. *Surg Endosc* 1999; 13:751–755.
32. Hofmeister J, Frank TG, Cuschieri A, Wade NJ. Perceptual aspects of two-dimensional and stereoscopic display techniques in endoscopic surgery: review and current problems. *Semin Laparosc Surg* 2001; 8:12–24.
33. Chang L, Satava RM, Pellegrini CA, Sinanan MN. Robotic surgery: identifying the learning curve through objective measurement of skill. *Surg Endosc* 2003; 17:1744–1748.
34. Dakin GF, Gagner M. Comparison of laparoscopic skills performance between standard instruments and two surgical robotic systems. *Surg Endosc* 2003; 17:574–579.
35. Renda A, Vallancien G. Principles and advantages of robotics in urologic surgery. *Curr Urol Rep* 2003; 4:114–118.
36. Kuo RL, Delvecchio FC, Preminger GM. Virtual reality: current urologic applications and future developments. *J Endourol* 2001; 15:117–122.
37. Preminger GM, Babayan RK, Merrill GL, Raju R, Millman A, Merrill JR. Virtual reality surgical simulation in endoscopic urologic surgery. *Stud Health Technol Inform* 1996; 29:157–163.
38. Shah J, Mackay S, Vale J, Darzi A. Simulation in urology—a role for virtual reality? *BJU Int* 2001; 88:661–665.
39. Matsumoto ED, Hamstra SJ, Radomski SB, Cusimano MD. The effect of bench model fidelity on endourological skills: a randomized controlled study. *J Urol* 2002; 167:1243–1247.
40. Merrill JR, Preminger GM, Babayan RK, Roy RT, Merrill GL. Surgical simulation using virtual reality technology: design, implementation and implications. *Surg Technol Int* 1994; III:53–60.

41. Jacomides L, Ogan K, Cadeddu JA, Pearle MS. Use of a virtual reality simulator for ureteroscopy training. *J Urol* 2004; 171:320–323; discussion.
42. Johnson DB, Kondraske GV, Wilhelm DM, et al. Assessment of basic human performance resources predicts the performance of virtual ureterorenoscopy. *J Urol* 2004; 171:80–84.
43. Watterson JD, Beiko DT, Kuan JK, Denstedt JD. Randomized prospective blinded study validating acquisition of ureteroscopy skills using computer based virtual reality endourological simulator. *J Urol* 2002; 168:1928–1932.
44. Wilhelm DM, Ogan K, Roehrborn CG, Cadeddu JA, Pearle MS. Assessment of basic endoscopic performance using a virtual reality simulator. *J American College of Surgeons* 2002; 195:675–681.
45. Shah J, Darzi A. Virtual reality flexible cystoscopy: a validation study. *BJU Int* 2002; 90:828–832.
46. Adrales GL, Park AE, Chu UB, et al. A valid method of laparoscopic simulation training and competence assessment. *J Surg Res* 2003; 114:156–162.
47. Gettman MT, Kondraske GV, Traxer O, et al. Assessment of basic human performance resources predicts operative performance of laparoscopic surgery. *J Am Coll Surg* 2003; 197:489–496.
48. Gor M, McCloy R, Stone R, Smith A. Virtual reality laparoscopic simulator for assessment in gynaecology. *BJOG Int J Obstet Gynaecol* 2003; 110:181–187.
49. Schijven MP, Jakimowicz J. The learning curve on the Xitact Is 500 laparoscopy simulator: profiles of performance. *Surg Endosc* 2004; 18:121–127.
50. McFarlane N, Denstedt J. Imaging and the Internet. *J Endourol* 2001; 15:59–61.
51. Goldberg MA. Teleradiology and telemedicine. *Radiol Clin North Am* 1996; 34:647–664.
52. Crump WJ, Pfeil T. A telemedicine primer: an introduction to the technology and an overview of the literature. *Arch Family Med* 1995; 4:796–803.
53. Takeda H, Minato K, Takahasi T. High quality image oriented telemedicine with multimedia technology. *Int J Med Inform* 1999; 55:23–31.
54. Byrne JP, Mughal MM. Telementoring as an adjunct to training and competence-based assessment in laparoscopic cholecystectomy. *Surg Endosc* 2000; 14:1159–1161.
55. Janetschek G, Bartsch G, Kavoussi LR. Transcontinental interactive laparoscopic telesurgery between the United States and Europe. *J Urol* 1998; 160:1413.
56. Lee BR, Bishoff JT, Janetschek G, et al. A novel method of surgical instruction: international tele-mentoring. *World J Urol* 16:367–370.
57. Lee BR, Cadeddu JA, Janetschek G, et al. International surgical telemonitoring: our initial experience. In: Westwood JD, Hoffman HM, Stedney D, Weghorst SJ, eds. *Medicine Meets Virtual Reality: Art, Science, Technology: Healthcare (R)Evolution*. Amsterdam: IOS Press, 1998:41–47.
58. Moore RG, Adams JB, Partin AW, Docimo SG, Kavoussi LR. Telementoring of laparoscopic procedures: initial clinical experience. *Surg Endosc* 1996; 10:107–110.
59. Rosser JC Jr, Herman B, Giammaria LE. Telementoring. *Semin Laparosc Surg* 2003; 10:209–217.
60. Micali S, Vespasiani G, Finazzi-Agro E, et al. Feasibility of telesurgery between Baltimore, USA and Rome, Italy: the first five cases. *J Endourol* 1999; 13:A145.
61. Lee BR, Png DJ, Liew L, et al. Laparoscopic telesurgery between the United States and Singapore. *Ann Acad Med Singapore* 2000; 29:665–668.
62. Link RE, Schulam PG, Kavoussi LR. Telesurgery. Remote monitoring and assistance during laparoscopy. *Urol Clin North Am* 2001; 28:177–188.
63. Berguer R, Forkey DL, Smith WD. The effect of laparoscopic instrument working angle on surgeons' upper extremity workload. *Surg Endosc* 2001; 15:1027–1029.
64. Berguer R, Rab GT, Abu-Ghaida H, Alarcon A, Chung J. A comparison of surgeons' posture during laparoscopic and open surgical procedures. *Surg Endosc* 1997; 11:139–142.
65. Hemal AK, Srinivas M, Charles AR. Ergonomic problems associated with laparoscopy. *J Endourol* 2001; 15:499–503.
66. Nguyen NT, Ho HS, Smith WD, et al. An ergonomic evaluation of surgeons' axial skeletal and upper extremity movements during laparoscopic and open surgery. *Am J Surg* 2001; 182:720–724.
67. Herron DM, Gagner M, Kenyon TL, Swannstrom LL. The minimally invasive surgical suite enters the 21st century. A discussion of critical design elements. *Surg Endosc (Online)* 2001; 15:415–422.
68. Kenyon TA, Urbach DR, Speer JB, et al. Dedicated minimally invasive surgery suites increase operating room efficiency. *Surg Endosc* 2001; 15:1140–1143.
69. Aiono S, Gilbert JM, Soin B, Finlay PA, Gordan A. Controlled trial of the introduction of a robotic camera assistant (endoassist) for laparoscopic cholecystectomy. *Surg Endosc* 2002; 16:1267–1270.
70. Gillette JC, Quick NE, Adrales GL, Shapiro R, Park AE. Changes in postural mechanics associated with different types of minimally invasive surgical training exercises. *Surg Endosc* 2003; 17:259–263.
71. Kondraske GV, Hamilton EC, Scott DJ, et al. Surgeon workload and motion efficiency with robot and human laparoscopic camera control. *Surg Endosc* 2002; 16:1523–1527.
72. Brown SI, Frank TG, El Shallaly G, Cuschieri A. Comparison of conventional and gaze-down imaging in laparoscopic task performance. *Surg Endosc* 2003; 17:586–590.
73. Cheah WK, Lenzi JE, So J, Dong F, Kum CK, Goh P. Evaluation of a head-mounted display (HMD) in the performance of a simulated laparoscopic task. *Surg Endosc* 15:990–991.

Andrew B. Joel

*Department of Urology, Georgetown University Hospital,
Washington, D.C., U.S.A.*

Marshall L. Stoller

*Department of Urology, University of California San Francisco,
San Francisco, California, U.S.A.*

- INTRODUCTION
- HEMOSTASIS
 - Vascular Factors
 - Platelets
 - Plasma
- TOPICAL BIOLOGIC AGENTS: PHARMACOLOGIC
 - Fibrin Sealant
 - Fibrin-Sealant Variant
 - Gelatin Matrix and Thrombin
 - Thrombin and Gelatin
- TOPICAL BIOLOGIC AGENTS: PHYSICAL
 - Microfibrillar Collagen
 - Oxidized Cellulose
 - Gelatin
- UROLOGIC LAPAROSCOPIC APPLICATIONS
 - Laparoscopic Nephrectomy
 - Laparoscopic Partial Nephrectomy
 - Retroperitoneal Lymph-Node Dissection
 - Ureteral Anastomosis, Pyeloplasty, and Prostatectomy
 - Laparoscopic Injuries
- POTENTIAL COMPLICATIONS
 - Allergic
 - Infectious
- TOPICAL SYNTHETIC AGENTS
 - Cyanoacrylate Sealants
 - Hydrogels (Polyethylene Glycol Polymers)
- CONCLUSIONS
- SUMMARY
- REFERENCES

INTRODUCTION

The use of bioadhesive technology in laparoscopic urologic surgery dates back to the mid-1990s; however, Bergel first used dry plasma to establish hemostasis in 1909.

The use of bioadhesive technology in laparoscopic urologic surgery dates back to the mid-1990s (1); however, Bergel first used dry plasma to establish hemostasis in 1909 (2).

Fibrin patches to establish hemostasis during cerebral surgery (3) and to manage bleeding from battlefield parenchymal organ injuries were introduced subsequently. The adhesive properties of fibrin sealant were first recognized experimentally and then clinically in 1942, when investigators performed microsurgical peripheral nerve anastomoses (4). The quality of fibrin sealant during this time was poor because of low in vivo concentrations of fibrinogen and fibrin. A significant advance was made in 1944, when researchers attempted to accelerate the formation of fibrin clot by mixing fibrinogen with bovine thrombin (5). However, the adhesive properties remained inadequate because the fractionation techniques required to prepare concentrated fibrinogen were still not perfected. The use of fibrin sealant was therefore limited to applying dry fibrin to bleeding surfaces. In the 1970s, purification and fractionation techniques grew more sophisticated and high concentrations of freeze-dried fibrinogen became available. Gradually, high concentrations of fibrinogen and other components such as thrombin and factor VIII became commercially available. Europe saw the first commercial, multidonor fibrin-sealant products in the late 1970s, yet the United States was more reluctant to embrace a product that had the potential of viral contamination (6). In fact, licenses for the clinical use of fibrinogen substrates were revoked in the United States in 1978, and further purification and viral detection methods had to be developed before commercially available fibrin-sealant products could be employed clinically (7). Because of the potential benefits of fibrin sealant, American surgeons turned to fibrin preparations, either autologous or obtained from single-donor cryoprecipitates. Although the risk of disease transmission was theoretically prevented, the preparation of such products was time consuming and the fibrinogen concentration, critical to the sealant's tensile strength, was variable and unreliable. Despite the availability of several commercial

Today's fibrin sealants have excellent rheological properties that make them excellent additions to standard methods of tissue approximation and help secure hemostasis.

The hemostatic process depends upon the integrated activity of vascular, platelet, and plasma factors in combination with the regulatory mechanisms of anticoagulation, which are necessary to stabilize the fibrin clot and prevent accumulation of platelets and fibrin in areas of noninjury.

Regional vasoconstriction and extrinsic compression of damaged blood vessels by extravasated blood contribute to hemostasis on a purely mechanical level. Temporary arterial occlusion during laparoscopic partial nephrectomy can help achieve the same goal by intentionally decreasing the blood flow to the cut surface of the renal parenchyma.

fibrin-sealant preparations in Europe, Canada, and Japan, the U.S. Food and Drug Administration did not approve Tisseel^{TMa} until 1998.

Today's fibrin sealants have excellent rheological properties (elasticity, tensile strength, and adhesiveness) that make them excellent additions to standard methods of tissue approximation and help secure hemostasis.

Fibrin sealant is the only agent truly considered a "bioadhesive." However, gelatin matrix, thrombin, collagen, and cellulose products are available for enhancing hemostasis. All can be applied laparoscopically by either directly passing the agent through a laparoscopic port or using long applicator devices.

HEMOSTASIS

Hemostasis is achieved with the production of a fibrin clot that seals a site of injury, or a damaged blood vessel.

The hemostatic process depends upon the integrated activity of vascular, platelet, and plasma factors in combination with the regulatory mechanisms of anticoagulation, which are necessary to stabilize the fibrin clot and prevent accumulation of platelets and fibrin in areas of noninjury.

More specifically, the coagulation cascade can be activated by exposure of blood to foreign surfaces, tissue factors, or by platelet activation.

Vascular Factors

Regional vasoconstriction and extrinsic compression of damaged blood vessels by extravasated blood contribute to hemostasis on a purely mechanical level. Temporary arterial occlusion during laparoscopic partial nephrectomy can help achieve the same goal by intentionally decreasing the blood flow to the cut surface of the renal parenchyma.

This allows for better visualization that ultimately helps in achieving more permanent hemostasis after vascular clamp removal. Most likely, the extravasated blood helps hemostasis by a tamponade-like effect.

Platelets

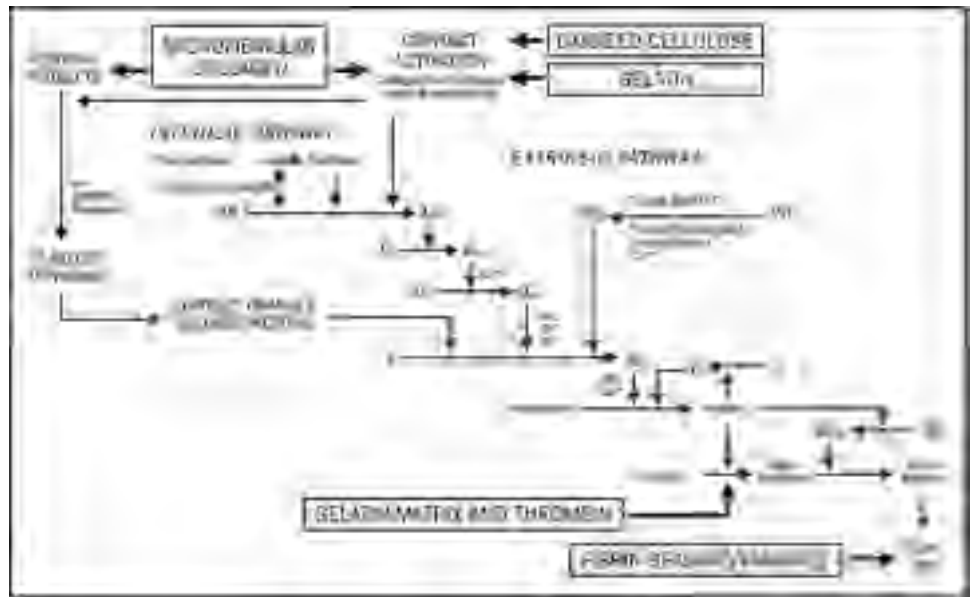
Platelets are integral to efficient hemostasis because they adhere and aggregate to the sites where tissue factors is exposed by disruption of the vascular endothelial lining. After endothelial cell damage and loss, adhesive glycoproteins such as collagen, thrombin, and von Willebrand factor are exposed in the subendothelial tissue. Receptors on the platelets mediate binding to the glycoproteins, thus causing platelet adhesion to the particular area of vessel injury. An activation process leading to a conformational change in specific glycoproteins enables the platelets to bind multivalent adhesive proteins such as fibrinogen and von Willebrand factor (8). Platelet aggregation occurs through the interaction of adhesive glycoprotein cross-binding two different platelets. The aggregation process continues until the platelets create a hemostatic plug. Activation of platelets leads to (i) increased vasoconstriction through serotonin and thromboxane A₂, (ii) vessel wall repair, and (iii) formation of enzyme/cofactor complexes by providing surface membranes upon which blood coagulation complexes can occur (8). Platelets also secrete platelet factor V, a key component of the enzyme/cofactor complex responsible for thrombin production. Thrombin activates more platelets and stimulates further coagulation by initiating fibrin deposition. The fibrin strand deposition reinforces the platelet plug and serves as a site for more von Willebrand factor deposition (9).

Plasma

The second crucial element of hemostasis—the fibrin clot—is the result of a complex interaction of many plasma proteins, proenzymes, and cofactors (10). The fibrin clot, the end product of the coagulation cascade, arises from and anchors the hemostatic plug. The cascade model of coagulation involves the activation of one of two pathways, the intrinsic pathway and the extrinsic pathway (Fig. 1). When these pathways were studied, it was thought that all the factors in the intrinsic pathway were within the vascular system, and that the tissue factors necessary to activate the extrinsic pathway were found outside the vascular space. Furthermore, it was believed that the two pathways were activated independently of one another. The current understanding of hemostasis helps appreciate that the intrinsic and extrinsic pathways are very much intertwined and that

^aOriginally, Immuno, Vienna, Austria; now Baxter Healthcare Corporation, Deerfield, IL.

FIGURE 1 ■ Cascade model for coagulation.



Converting fibrinogen to fibrin, thrombin plays an extremely critical role in the process of fibrin clot development.

In the presence of ionized calcium, thrombin activates factor XIII to XIIIa. Factor XIIIa converts the noncovalent bonds between the fibrin fibers into covalent bonds and creates stable and insoluble fibrin clot by cross-linking the fibrin molecules.

Fibrin sealant may be produced from pooled sources or a single donor. The use of pooled blood products is the current basis for the commercially available fibrin sealant. The single-donor blood can be allogenic or autologous.

The primary component of all synthetic fibrin sealants is highly concentrated human fibrinogen mixed with factor XIII and fibronectin. Human thrombin concentrate and an antifibrinolytic constitute the remaining components. Fibrinogen and thrombin are solubilized with antifibrinolytic and calcium chloride solutions, respectively.

all clotting factors are in some way interrelated. Nevertheless, each pathway, including that initiated by platelets, results in the conversion of factor X to activated factor X. Factor Xa as well as activated factor V (Va) converts prothrombin to thrombin. Converting fibrinogen to fibrin, thrombin plays an extremely critical role in the process of fibrin clot development.

Fibrinogen, a soluble blood component, comprising 0.2% of whole blood volume is a glycoprotein comprising three pairs of polypeptide chains called A α , B β and γ . The central domains of the fibrinopeptide A and B are cleaved from their respective A α and B β chains by the serine protease thrombin. This enzymatic cleavage forms the fibrin monomers due to a change in the charge and conformation of fibrinogen (6). Hydrogen bonds and electrostatic reactions polymerize the fibrin monomers into unstable and soluble fibrin fibers.

In the presence of ionized calcium, thrombin activates factor XIII to XIIIa. Factor XIIIa converts the noncovalent bonds between the fibrin fibers into covalent bonds and creates stable and insoluble fibrin clot by cross-linking the fibrin molecules (11).

TOPICAL BIOLOGIC AGENTS: PHARMACOLOGIC

Fibrin Sealant

Fibrin sealant may be produced from pooled sources or a single donor. The use of pooled blood products is the current basis for the commercially available fibrin sealant. The single-donor blood can be allogenic or autologous.

Nine fibrin sealants are currently available to urologists worldwide: (i) Tisseel^{TMb}; (ii) Crosseal^{TMc}; (iii) Hemaseel^{TMd}; (iv) Quixil^{TMe}; (v) Beriplast P^{TMf}; (vi) Bolheal^{TMg}; (vii) Biocol^{TMh}; (viii) VIGuard F.S.^{TMi}; and (ix) CoStasis^{TMj}. Tisseel, Crosseal, Hemaseel, VIGuard F.S., and Costasis have Food and Drug Administration approval for sale in the United States.

The primary component of all synthetic fibrin sealants is highly concentrated human fibrinogen mixed with factor XIII and fibronectin. Human thrombin concentrate and an antifibrinolytic constitute the remaining components. Fibrinogen and thrombin are solubilized with antifibrinolytic and calcium chloride solutions, respectively (6).

^bBaxter Healthcare Corporation, Deerfield, IL.

^cAmerican Red Cross, Washington, D.C.

^dHaemacure Corp., Montreal, Quebec, Canada.

^eOmrix Biopharmaceuticals S.A., Rhode St Genesé, Belgium.

^fAventis Behring, Marburg, Germany.

^gKaketsuken Pharmaceuticals, Kumamoto, Japan.

^hLFB-Lille, France.

ⁱitex: VI Technologies, Inc., Watertown, MA.

^jAngiotech Pharmaceuticals, Inc., Vancouver, British Columbia.

Fibrin sealants do not rely on the intrinsic/extrinsic clotting pathways and actually function also in the presence of systemic coagulation defects.

Tranexamic acid has caused neurologic symptoms including trembling, involuntary head movements, and clonic contractions in rabbits.

When the two components are mixed in the presence of ionized calcium, the last step in the coagulation cascade is reproduced beginning with thrombin cleavage of fibrinopeptides A and B from the fibrinogen molecule. Thrombin also activates factor XIII, which stabilizes fibrin cross-linkage and promotes the formation of an insoluble, nonfriable clot. The addition of fibronectin helps to cross-link fibrin, and to stimulate cellular migration (12) and fibroblastic growth in the areas where the fibrin sealant was applied.

Fibrin sealants do not rely on the intrinsic/extrinsic clotting pathways and actually function also in the presence of systemic coagulation defects.

An antifibrinolytic, which is a variable ingredient in the fibrin-sealant preparation, is intended to slow the rate of fibrinolysis and thereby preserve the integrity of the fibrin clot. In Tisseel and Hemaseel, aprotinin is the antifibrinolytic agent. Alternatively, the antifibrinolytic in Crosseal is tranexamic acid. Aprotinin, derived from bovine lung, inhibits a number of serine proteases including trypsin, chymotrypsin, kallikrein, elastase, urokinase, thrombin, and plasmin (13). Tranexamic acid, a synthetic analogue of the amino acid lysine, prevents the binding of plasminogen and plasmin to fibrinogen and fibrin by competing with lysine for binding sites, and thus helps to suppress fibrinolysis (14). Tranexamic acid also offers a theoretical advantage because it is not bovine derived. In fact, anaphylactic reactions reported in bovine aprotinin did not occur with tranexamic acid (15–20). Crosseal eliminates the risk of bovine spongiform encephalopathy transmission and immunologically mediated coagulopathy.

Tranexamic acid has caused neurologic symptoms including trembling, involuntary head movements, and clonic contractions in rabbits (21,22).

Tisseel VH contains four separate vials and its preparation requires approximately 20 minutes prior to reconstitution—all four vials have to be warmed (37°C) using the Fibrinotherm heating and stirring device or a water bath. The bovine aprotinin is aspirated and injected into the fibrinogen vial. This solution is mixed in a magnetic stirring well for one to four minutes depending on the volume of the kit. The calcium chloride is added to the thrombin vial before agitation and further warming of the mixture. Once the preparation process is completed, the Tisseel is best used within four hours. The two components of the fibrin sealant may be applied sequentially or simultaneously. The most common method of application relies on a double-barreled Duploject™ Preparation and Application System^k enabling simultaneous and equal application of the fibrinogen and thrombin solutions through a blunt-tipped needle. A laparoscopic applicator is also available. Conversely, Crosseal can be prepared in less than one minute and does not require a warming process provided the solutions have been previously thawed (21). Like Tisseel, Crosseal can be applied with a laparoscopic applicator. Both brands of fibrin sealant should be applied with individual drops to the target area. The drops should be allowed to separate from one another and from the applicator tip. Fibrin sealants also can be applied using a source of forced sterile gas (35–45 lb/inch²) to spray equal portions of the solutions onto a desired surface.

- Proper application is essential for optimal adhesive function.
- After the sealant application, the two surfaces should be brought into contact prior to polymerization of the sealant.
- Once polymerization has occurred on one surface, it will act as an antiadhesive and prevent the two surfaces from adhering (23,24).
- Fibrin sealant is most effective in a “dry” operative field because it does not rely on the presence of blood to develop the fibrin clot.

To avoid the possibility of thromboembolic complications, fibrin sealant should be applied with caution and should not be injected directly into large blood vessels.

This differs from other hemostatic agents such as Floseal™^k or Gelfoam™^l, which require blood for optimal hemostasis.

To avoid the possibility of thromboembolic complications, fibrin sealant should be applied with caution and should not be injected directly into large blood vessels (24).

Two additional preparations of fibrin, the absorbable fibrin adhesive bandage and the hemostatic fibrin-sealant powder have been described and utilized in a porcine model. The absorbable fibrin adhesive bandage^m is made of a concentrated mixture of lyophilized fibrinogen and thrombin on an absorbable Vicryl backing (25). Cornum et al. (25) applied the absorbable fibrin adhesive bandage to porcine kidneys after lower-pole heminephrectomy; by comparing this method of hemostasis to conventional methods of partial nephrectomy bed repair, the authors found significantly less bleeding and

^kBaxter Healthcare Corporation, Deerfield, IL.

^lPfizer, New York, NY.

^mAmerican Red Cross, Washington, D.C.

shorter operative and ischemia times in the absorbable fibrin adhesive bandage group. The same team employed the absorbable fibrin adhesive bandage for the management of grade-4 renal stab wounds in a porcine model and found that the bandage had a promising role in the renal trauma setting (26). However, such a fibrin preparation is not currently applicable to laparoscopy because the bulky nature of the bandage prohibits placement through laparoscopic ports. Furthermore, placement through a handport would be difficult because it will adhere to any moist surface that it comes into contact with. The other additional fibrin preparation, hemostatic fibrin-sealant powder,ⁿ consists of lyophilized human fibrinogen and thrombin. Bishoff et al. evaluated the ability of hemostatic fibrin-sealant powder to achieve hemostasis and seal the collecting system of porcine kidneys after laparoscopic heminephrectomy (27). In this study, hemostatic fibrin-sealant powder applied alone with regional ischemia was compared to conventional intracorporeal suturing with vascular control. Follow-up computed tomography was performed at 48 hours and six weeks. Although at 48 hours there were more urinomas in the hemostatic fibrin-sealant powder group, at six weeks there was no evidence of urinoma or hematoma in either group. Unlike the absorbable fibrin adhesive bandage preparation, the hemostatic fibrin-sealant powder preparation holds promise as a possible addition to the laparoscopic armamentarium of hemostatic agents.

Fibrin-Sealant Variant

Costasis, a fibrin-sealant variant that combines autologous fibrinogen with bovine thrombin and collagen, is prepared by drawing the patient's blood into a plasma-collecting system. The blood is centrifuged and the plasma is separated. The autologous plasma is mixed with thrombin using a dual syringe applicator. This product, unlike Tisseel or Crosseal, does not contain an antifibrinolytic such as aprotinin or tranexamic acid. Although Costasis has been used in cardiac, general, and orthopedic surgical fields, there are no reports in the urologic literature regarding its use or efficacy.

The primary advantage of Costasis is that the autologous source of fibrinogen eliminates the potential risks of viral transmission. However, both the risk of bovine spongiform encephalopathy and allergic reaction to bovine thrombin remain.

Gelatin Matrix and Thrombin

Flo seal is a Food and Drug Administration-approved gelatin-matrix hemostatic sealant that has been well described in open cardiac, vascular, spine, and ear-nose-throat surgery (28–32).

Cross-linked gelatin granules comprise the gelatin matrix component of Flo seal. The granules are manufactured after (i) extraction of collagen from bovine corium, (ii) gelatinization of the collagen, (iii) cross-linking and stabilization with glutaraldehyde, and (iv) grinding of the gelatin into 500 to 600 µm particles (33). Thrombin is bovine derived and similar to that used in the fibrin-sealant systems (Table 1). Hemostasis is achieved when the granules conform and swell by 10% to 20% upon contact with blood or body fluids (33). The outcome is blood flow restriction and a tamponade effect. Additionally, the presence of high concentrations of thrombin promotes long-term hemostasis by augmenting clot formation.

The primary advantage of Costasis is that the autologous source of fibrinogen eliminates the potential risks of viral transmission. However, the risk of bovine spongiform encephalopathy and allergic reaction to bovine thrombin remain.

Flo seal is a Food and Drug Administration-approved gelatin-matrix hemostatic sealant that has been well described in open cardiac, vascular, spine, and ear-nose-throat surgery.

TABLE 1 ■ Characteristics of Pharmacologic and Physical Hemostatic Agents

Hemostatic agent	Manufacturer	Available preparations	Bovine derived	Intact coagulation pathway
Gelatin matrix and thrombin— <i>Flo seal</i>	Baxter Healthcare Corp.	Matrix	Yes	Partially (circulating fibrinogen)
Microfibrillar collagen— <i>Avitene</i>	C.R. Bard, Inc.	Powder, sponge, and film	Yes	Yes
Oxidized cellulose— <i>Surgicel</i>	Johnson & Johnson	Fabric-like sheet	No (plant based)	Yes
Oxidized cellulose— <i>Oxycel</i>	Ethicon	Fabric-like sheet	No (plant based)	Yes
Gelatin— <i>Gelfoam</i>	Pfizer	Powder, sponge	Yes	Yes
Gelatin— <i>Surgifoam</i>	Johnson & Johnson	Powder, sponge	Yes	Yes

ⁿAmerican Red Cross, Washington, D.C.

Floseal works in cases of fairly active bleeding, whereas fibrin sealants and physical agents are better suited for diffuse bleeding or oozing.

Floseal, unlike fibrin sealants, is not an adhesive and therefore should not be used to seal the urinary collecting system.

- In contrast to the fibrin sealants, Floseal relies on endogenous fibrinogen to supply fibrin for clot formation.
- It is ineffective in fibrinogenemic patients.
- Some degree of bleeding is necessary for Floseal to function, whereas fibrin sealants require a relatively dry surface.

The gelatin granules are manually mixed with the thrombin prior to delivery of the slurry with a laparoscopic applicator. The slurry is somewhat thick and requires an applicator with a sufficient diameter for deployment. Furthermore, the slurry ought to be mixed just prior to delivery to insure even viscosity and prevent applicator clogging. After slurry delivery, the slurry remaining caught in the “deadspace” of the applicator may be utilized by injecting air (one syringe) into the applicator. Once completely delivered, pressure should be gently applied for several minutes, to allow the formation of fibrin clot.

Floseal works in cases of fairly active bleeding, whereas fibrin sealants and physical agents are better suited for diffuse bleeding or oozing. This most likely accounts for the common use of Floseal in urologic laparoscopy as a hemostatic adjunct during laparoscopic partial nephrectomy (34–36).

Floseal, unlike fibrin sealants, is not an adhesive and therefore should not be used to seal the urinary collecting system.

Thrombin and Gelatin

The combination of thrombin and gelatin, either GelfoamTM or SurgifoamTM, is commonly used to establish hemostasis. To ultimately form a fibrin clot, the thrombin has to interact with an in vivo circulating fibrinogen, which is required for this method of hemostasis. In general, during laparoscopic surgery, the thrombin is delivered to the desired area by saturating gelatin sponges. By routinely using a thumb portion of a sterile surgical glove as a delivery bag to place the thrombin-soaked sponges through the laparoscopic ports, we prevent the fragmentation of the sponge and its premature contact with blood prior to final application. This method of hemostasis has been widely utilized during laparoscopic partial nephrectomy. In addition to a delivery mechanism for thrombin, the bulk of the gelatin within the parenchymal defect may provide compression on the surgical bed and aid in hemostasis.

TOPICAL BIOLOGIC AGENTS: PHYSICAL

Microfibrillar Collagen

Collagen is the main protein component of skin, tendon, bone, and blood vessels. Vascular injury exposes collagen fibrils in the subendothelial layer. Platelets bind to the exposed collagen either directly or via the von Willebrand factor. Manufactured collagen products, prepared as sheets or a loose fluffy powder, enhance platelet aggregation in the area of bleeding and clot formation by prompting localization of endogenous coagulation factors and by stimulating fibrin deposition. Collagen further adds to hemostasis by activating the intrinsic pathway.

Hemostatic action of collagen requires an intact coagulation system with functional platelets and clotting factors (Table 1). Therefore, collagen has little effect in patients with inactivated platelets (e.g., aspirin) or compromised clotting pathways (e.g., heparin and coumadin).

Avitene sheets of bovine-derived collagen^q are cumbersome laparoscopically because of being brittle and difficult to deliver into the insufflated abdomen. As such, the use of collagen sheets is limited. The powdered collagen preparation is more amenable laparoscopically because it can be blown through a large diameter catheter. EndoAvitene^{TMq} is a novel product specifically designed for laparoscopic use. The preloaded collagen can be applied through a 5 mm port and may be used in conjunction with thrombin, which can be dripped or sprayed over the deposited collagen.

Oxidized Cellulose

Oxidized cellulose, an absorbable knitted fabric prepared by the controlled oxidation of regenerated cellulose (Table 1), is free from risks associated with human/bovine

^oPfizer, New York, NY.

^pJohnson & Johnson, New Brunswick, NJ.

^qC.R. Bard, Inc., Murray Hill, NJ.

The hemostatic action of cellulose requires a functional clotting cascade and the presence of all clotting factors.

Cellulose has no adhesive properties and is only used to better establish hemostasis. In urologic laparoscopy, cellulose generally is applied after nephrectomy to control persistent bleeding from the raw edge of a spared adrenal gland or during partial nephrectomy for packing the newly created divot in the renal parenchyma.

Because the acidity of oxidized cellulose inactivates thrombin, thrombin and cellulose should not be used together.

Furthermore, gelatin will only enhance hemostasis if the clotting pathway is functional and if all the clotting factors are present.

The use of agents designed to augment standard methods for optimizing hemostasis is warranted during several urologic and laparoscopic procedures.

All sorts of hemostatic agents have been experimented with and documented during laparoscopic partial nephrectomy.

contaminant transmission and enhances hemostasis by contact activation of the intrinsic coagulation pathway. Also, its swollen gelatinous mass may hold clotting factors in the region of bleeding and augment clot formation. The cellulose is completely absorbed with time (7–14 days) without significant tissue reaction.

The hemostatic action of cellulose requires a functional clotting cascade and the presence of all clotting factors.

SurgicelTM and Oxycel^S are available in varying-sized cloth-like sheets that can be passed easily through laparoscopic ports. Because cellulose will adhere strongly to any moist tissue, careful maneuvering is required to place it precisely on the desired location.

Cellulose has no adhesive properties and is only used to better establish hemostasis. In urologic laparoscopy, cellulose generally is applied after nephrectomy to control persistent bleeding from the raw edge of a spared adrenal gland or during partial nephrectomy for packing the newly created divot in the renal parenchyma (37).

When used as a bolster over which to suture the renal capsule, the cellulose can be rolled up and held in position with a 4.0 Vicryl suture at either end. The swelling of the cellulose upon contact with blood allows it to generate a tamponade effect similar to gelatin. Caution should be taken in situations where a confined space is involved. Several cases of neurologic injury, such as acute paraplegia, have been reported after application of cellulose. It was postulated that the migration of the cellulose into the epidural space caused spinal cord compression. Conceivably, overly enthusiastic application near the ureter or renal vessels could result in obstruction.

Because the acidity of oxidized cellulose inactivates thrombin, thrombin and cellulose should not be used together.

Gelatin

Gelatin, similar to collagen and cellulose, initiates the intrinsic pathway of the clotting cascade through contact activation. Gelfoam and Surgifoam^f are the two available bovine-derived gelatin products (Table 1). Generally, neither product is utilized alone but rather is combined with thrombin (see the section entitled “Thrombin and Gelatin”).

Furthermore, gelatin will only enhance hemostasis if the clotting pathway is functional and if all the clotting factors are present.

UROLOGIC LAPAROSCOPIC APPLICATIONS

Hemostatic agents are routinely utilized in many areas of urologic surgery (24). Urologic laparoscopy has become more complex as procedures grow and evolve to duplicate their open-surgery counterparts. Increased complexity correlates with increased chances for complications due to inadequate hemostasis.

The use of agents designed to augment standard methods for optimizing hemostasis is warranted during several urologic and laparoscopic procedures.

Laparoscopic Nephrectomy

Hemostatic agents are not routinely used for laparoscopic radical nephrectomy for a number of reasons: (i) bleeding is usually kept to a minimum because of insufflation pressures; (ii) significant-sized blood vessels are controlled with vascular clips or staplers; and (iii) the urinary collecting system is routinely controlled at the level of the ureter. Nevertheless, hemostatic agents have been utilized for varying degrees of bleeding encountered during laparoscopic nephrectomy.

Laparoscopic Partial Nephrectomy

During laparoscopic partial nephrectomy transection of intra-renal blood vessels and violation of urinary collecting system account for the two major complications, e.g., delayed hemorrhage and urinoma. Even with hilar control, laparoscopic suturing of the interlobar arteries and opened calyces can be challenging due to suboptimal visualization and/or difficult angles. All sorts of hemostatic agents have been experimented with and documented during laparoscopic partial nephrectomy.

^fJohnson & Johnson, New Brunswick, NJ.

^SEthicon, Somerville, NJ.

Initially, oxidized cellulose, gelatin, and collagen were used either alone or in conjunction with a hemostatic energy source such as an argon beam coagulator. Kletscher et al. evaluated the efficacy of both Gelfoam and Avitene to control parenchymal hemorrhage during laparoscopic anatomic nephrolithotomy in a porcine model (38). Gelfoam and Surgicel were welded to the cut and outer surface of the kidney using an argon beam coagulator. Since this early report, cellulose, gelatin, and collagen have all been utilized for hemostasis in laparoscopic partial nephrectomy Stifelman et al. (37) performed 11 hand-assisted laparoscopic partial nephrectomies (mean tumor size 1.9 cm) and applied Surgical, Avitene, or fibrin-soaked Gelfoam activated by thrombin to the renal defects. Vascular hilar control was not obtained prior to excision of the renal lesion. The authors experienced no major complications and only two minor complications other than postoperative hemorrhage. Cellulose in conjunction with fibrin sealant for hemostasis has also been employed during laparoscopic partial nephrectomy Jeschke et al. (39) performed 51 laparoscopic partial nephrectomies for small (2.0 cm) exophytic renal tumors and covered the renal defect with oxidized cellulose and 2 mL fibrin sealant. Vascular hilar control was not performed and the integrity of the collecting system was not tested intraoperatively. One patient required reoperation for hemorrhage on postoperative day 1, and three developed urinary fistulas on postoperative days 3 to 4.

Floseal also has been used to enhance hemostasis during laparoscopic partial nephrectomy (34–36). Richter et al. (34) performed 10 laparoscopic partial nephrectomies for tumors (median tumor size 2.8 cm) and applied Floseal after tumor resection and before reperfusion of the kidney. Immediate hemostasis was obtained and maintained even after kidney reperfusion. No postoperative hemorrhage occurred and no significant perirenal hematoma was detected with follow-up ultrasonography at 24 hours and 10 days postoperatively. Bak et al. (35) reported similar results after six laparoscopic partial nephrectomies performed for 2 to 5 cm exophytic lesions (median size: 2.5 cm). Also in this study, hemostasis was achieved immediately upon application of Floseal on the moist surface of partial nephrectomy bed, and clinically evident postoperative hemorrhage did not occur.

During laparoscopic partial nephrectomy, we routinely obtain vascular control, and test the integrity of the collecting system with dilute methylene blue injected via a retrograde catheter. Any disruption of the collecting system is closed with intracorporeal figure-of-eight suturing. Tisseel is dripped over the areas of the collecting system and Floseal is applied on the moist surface of the cut renal parenchyma. Gelfoam bolsters are placed under the slightly tightened capsular sutures. Lastly, the remainder of the Tisseel is applied over the entire repair prior to removing the vascular clamp. No postoperative hemorrhage or urinary leak occurred in our experience.

Retroperitoneal Lymph-Node Dissection

During laparoscopic retroperitoneal lymph-node dissection, fibrin sealant can be applied to the lymph-node bed, in addition to the routine use of laparoscopic clips. However, lymphatic leaks may occur despite proper attempts to ligate all major lymphatic channels. Although no randomized, prospective trials evaluating the benefit of fibrin glue in this setting have been reported, fibrin glue has been used selectively during lymph-node dissections performed by European teams (40) and to aid the treatment of chylous ascites occurring after a donor nephrectomy (41).

Ureteral Anastomosis, Pyeloplasty, and Prostatectomy

Oxidized cellulose, gelatin, collagen, and gelatin matrix/thrombin combination are not considered sealants or adhesives and should not be used to close any part of the collecting system. Therefore, only fibrin sealant should be employed for controlling urinary leakage after planned or traumatic disruption (42) of the collecting system.

Several investigators have utilized porcine models to attempt closure of the urinary tract with fibrin sealant. After performing laparoscopic ureteral transection in five pigs, McKay et al. approximated the ureter with two transmural sutures and sealed the anastomosis with fibrin sealant. Outcomes were compared to those of conventional ureteral anastomosis. Although renal pelvis perfusion tests were higher (12.6 cm H₂O vs. 3 cm H₂O) in the fibrin-sealant group at eight weeks, the values were within normal range for the porcine model. The authors concluded that laparoscopic ureteral anastomosis using fibrin preparations was feasible (43).

Wolf et al., using a porcine model to compare the efficacy of fibrin sealant for closure of five linear ureterotomies with laser-assisted anastomosis, mechanical suturing

Oxidized cellulose, gelatin, collagen, and gelatin matrix/thrombin combination are not considered sealants or adhesives and should not be used to close any part of the collecting system. Therefore, only fibrin sealant should be employed for controlling urinary leakage after planned or traumatic disruption of the collecting system.

Wolf et al., using a porcine model to compare the efficacy of fibrin sealant for closure of five linear ureterotomies with laser-assisted anastomosis, mechanical suturing device, and conventional laparoscopic suturing, concluded that fibrin sealant yielded more favorable radiographic findings, flow characteristics, and histology.

device, and conventional laparoscopic suturing, concluded that fibrin sealant yielded more favorable radiographic findings, flow characteristics, and histology (44).

Anidjar et al. attempted to approximate porcine ureters using only fibrin sealant after laparoscopic segmental ureterectomy. The ureteral ends were held together for five minutes after the sealant was applied. No immediate anastomotic disruption occurred, and patency of all 10 anastomoses with no leakage in eight and minimal leakage in two was documented with fluoroscopy. Two pigs representing the chronic arm of the study died because of massive urinoma on postoperative days 6 and 8, respectively. Histologic examination revealed no significant coaptation of the ureteral ends.

Performing ureteral anastomoses with fibrin glue alone and no stay sutures is not recommended (45).

In another series, the combination of fibrin sealant and sutures applied in three patients with traumatic ureteral injuries was successful (42). To our knowledge, no other human studies of fibrin sealant for ureteral anastomosis are available.

Experimental and clinical data indicate that the sole use of fibrin sealant for ureteral anastomosis is unsafe. However, fibrin sealant applied with a limited number of approximating sutures may achieve results comparable to those of sutured anastomosis while decreasing operative time.

To determine the efficacy of fibrin-sealant-assisted ureteral anastomosis, additional clinical trials, with a larger number of patients, are awaited.

Fibrin sealant has been also used to complete the ureteropelvic anastomosis during a laparoscopic ureteropelvic junction obstruction repair (1). Eden et al. successfully performed eight retroperitoneal laparoscopic dismembered pyeloplasties by first approximating the ureteropelvic anastomosis with stay sutures, and subsequently sealing the anastomosis with fibrin glue. Patients were followed up with diuretic renography performed at three months and yearly thereafter. At one to two years follow-up, all patients had satisfactory upper-tract drainage. However, further clinical studies with larger numbers of patients are necessary to evaluate this technique.

We do not rely on the fibrin sealant for closure of the ureteropelvic anastomosis during laparoscopic junction obstruction repair. Rather, we perform running or interrupted suturing of the anastomosis and occasionally apply fibrin glue to suture lines. Although suturing is more time consuming than simply applying fibrin sealant, we still believe that the water-tightness of the anastomosis is better achieved with traditional closure.

Laparoscopic prostatectomy is another field of application for hemostatic agents even if the magnified visualization and the insufflation pressures already facilitate the control of the oozing frequently seen during open prostatectomy.

We do not routinely use any of the hemostatic agents and would likely use fibrin sealant if needed because of its potential to help seal the urethral anastomosis. To date, there are no reports describing the routine application of any of the hemostatic agents to laparoscopic prostatectomy, and we are unaware of any clinical trials upon which to base the efficacy of any of these agents in this particular setting.

Laparoscopic Injuries

Injuries to intestine, vascular structures, spleen, and diaphragm are known complications of laparoscopic urologic surgery. Hemostatic agents have been used to repair some of these injuries. During a right laparoscopic radical nephrectomy, Bhayani et al. applied gelatin matrix with thrombin (FloSeal) to a 1 cm tear in the diaphragm (46). A Babcock clamp was used to approximate the diaphragm, and the omentum was used to cover the repair. While preferring formal suture repair for large diaphragmatic injuries, the authors recommended the use of FloSeal to treat small diaphragmatic injuries.

Fibrin sealant has also been used for repair of splenic injuries. Canby-Hagino et al. described utilizing fibrin sealant to manage conservatively a splenic laceration caused by upper-pole dissection during transperitoneal laparoscopic nephrectomy. Splenectomy was not necessary (47).

Performing ureteral anastomoses with fibrin glue alone and no stay sutures is not recommended.

Experimental and clinical data indicate that the sole use of fibrin sealant for ureteral anastomosis is unsafe. However, fibrin sealant applied with a limited number of approximating sutures may achieve results comparable to those of sutured anastomosis while decreasing operative time.

Laparoscopic prostatectomy is another field of application for hemostatic agents even if the magnified visualization and the insufflation pressures already facilitate the control of the oozing frequently seen during open prostatectomy.

- All hemostatic agents have the potential to be a useful adjunct to traditional means of controlling intraoperative laparoscopic complications.
- Any complication should be managed with definitive measures that also prevent the development of additional complications.
- There are no prospective trials specifically addressing the use of hemostatic agents for the management of complications occurring during urologic laparoscopic procedures. Bioadhesive/hemostatic agents may be used alone to manage a complication only in select cases.

The use of hemostatic agents implies potential risks of allergic reactions because bovine thrombin is immunogenic. Sudden and severe hypotension resulting in death has been reported after applying bovine thrombin to a deep hepatic wound, and immune-mediated coagulopathy from bovine thrombin is a well-recognized complication.

Careful donor selection strategies and screening plasma units intended for sealant production are another factors reducing the risk of viral transmission.

Although no case of viral transmission using bovine thrombin has been reported, bovine spongiform encephalopathy is a theoretical risk. The risk of prion transmission is thought to be very low but cannot be entirely eliminated.

POTENTIAL COMPLICATIONS

Allergic

The use of hemostatic agents implies potential risks of allergic reactions because bovine thrombin is immunogenic. Sudden and severe hypotension resulting in death has been reported after applying bovine thrombin to a deep hepatic wound (48), and immune-mediated coagulopathy from bovine thrombin is a well-recognized complication (49–51).

Exposure to bovine thrombin may result in the formation of antbovine thrombin immunoglobulin E antibodies. Upon reexposure, such antibodies may cross react with human thrombin and cause anaphylaxis, coagulopathy, or hypercoagulability (52,53).

- Recent commercial preparations have replaced bovine thrombin with human thrombin (Tisseel and Crosseal).
- Some products still contain bovine thrombin (Costasis, Floseal) or bovine-derived materials such as aprotinin (Tisseel) or collagen (Floseal).
- To avoid adverse outcomes, products containing bovine protein should be contraindicated in patients with known allergy hypersensitivity reactions.

Infectious

- Commercially available fibrin sealant carries a theoretical risk of viral contamination because it is manufactured from pooled human-plasma components.
- Advances in viral inactivation technology have significantly reduced the risk of hepatitis A, B, and C, and HIV transmission.

Various viral inactivation techniques including vapor heating, steam treatment, pasteurization, irradiation, solvent detergent extraction, and nanofiltration have been utilized (6).

Careful donor selection strategies and screening plasma units intended for sealant production are another factors reducing the risk of viral transmission.

To avoid viral transmission, Tisseel is prepared from plasma donated from screened donors, and tested for viral contaminants. Furthermore, Tisseel manufacturing includes a two-step vapor-heated method for viral inactivation (Table 2) (54). In addition to donor screening and plasma testing human immuno deficiency virus, hepatitis A, B, and C, and parvovirus B19, both solvent detergent and pasteurization for viral inactivation can be used to produce Crosseal (Table 2) (21). Although Costasis prevents viral transmission altogether by collecting a patient’s own blood as a source of autologous fibrinogen, it relies on bovine thrombin. Four cases of parvovirus B19 transmission have occurred in Japan (55,56). None of these preparations was approved by Food and Drug Administration and there are no reports of such a transmission in Europe or the United States so far.

Although no case of viral transmission using bovine thrombin has been reported, bovine spongiform encephalopathy is a theoretical risk (6). The risk of prion transmission is thought to be very low but cannot be entirely eliminated.

TABLE 2 ■ Characteristics of Available Fibrin Sealants and a Fibrin-Sealant Variant

Fibrin sealant	Manufacturer	Viral inactivation method	Human derived	Bovine derived	Intact coagulation pathway required	Preparation time (min)
Tisseel	Baxter Healthcare Corporation	Two-step vapor heating	Yes	Yes	No	20
Crosseal	American Red Cross, Inc.	Solvent/detergent, pasteurization	Yes	No	No	1
Hemaseal	Haemacure Corp.	two-step vapor heating	Yes	Yes	No	20
ViGuard	Vitex: VI Technologies	Solvent/detergent, ultraviolet C light	Yes	Yes	No	
Biocol	LFB-Lille	Solvent/detergent	Yes	Yes	No	
Quixil	Omx Biopharmaceuticals	Solvent/detergent, pasteurization/nanofiltration	Yes	Yes	No	
Beriplast	Aventis Behring	Pasteurization	Yes	Yes	No	
Bolheal	Kaketsuken Pharmaceutical	Dry heat	Yes	Yes	No	
Costasis	Angiotech Pharmaceuticals Inc.	Not available	Autologous	Yes	No	>20

Nanofiltration appears to be the best technique to improve the safety of fibrin-sealant components because the Creutzfeld-Jakob agent can be filtered from infected brain extracts of mice using a 35 nm pore size filter membrane (57).

TOPICAL SYNTHETIC AGENTS

Cyanoacrylates are synthetic monomers that have generally been applied externally for the closure of lacerations, wounds, and incisions. Although stronger than fibrin sealants, they are not bioabsorbable and, if not used topically, behave as any other foreign body causing inflammation, tissue necrosis, or infection.

Cyanoacrylate Sealants

Cyanoacrylates are synthetic monomers that have generally been applied externally for the closure of lacerations, wounds, and incisions. Although stronger than fibrin sealants, they are not bioabsorbable and, if not used topically, behave as any other foreign body causing inflammation, tissue necrosis, or infection.

Dermabond[†], a synthetic 2-octylcyanoacrylate adhesive approved in the United States, is for topical use only. It may be applied to small lacerations and surgical skin incisions, lasts 7 to 10 days, and requires no dressing because it is waterproof. Sebesta and Bishoff performed a randomized, prospective trial comparing Dermabond (118) to standard subcuticular skin closure (110) of laparoscopic port sites (58). Dermabond was not only rapid and effective but also yielded a decrease in cost and operative time. No other laparoscopic application for cyanoacrylates has been described.

Hydrogels (Polyethylene Glycol Polymers)

- Polyethylene glycol polymers are hydrogels that can be used for tissue sealing and adhesion.
- Polyethylene glycol polymers, completely synthetic and bioabsorbable, are particularly desirable as tissue sealants because inflammatory potential and risk of viral transmission are eliminated.
- Intact coagulation pathways or the presence of active bleeding are not required to achieve successful hemostasis or tissue sealing.

Two products are Food and Drug Administration approved. Focalseal-L[‡] is a polyethylene glycol-lactide that requires photoactivation with xenon light. The eosin-polyethylene glycol-lactide mixture is first applied as a primer before a macromere of polyethylene glycol-lactide is applied. The latter is photoactivated with high-intensity xenon light. The only experience with the use of polyethylene glycol polymers in laparoscopic urology was a feasibility trial performed by Ramakumar et al. in a porcine laparoscopic partial nephrectomy model (59). After renal hilar control using a laparoscopic Satinsky clamp and wedge resection in either the upper or the lower pole, Focalseal-L was laparoscopically applied to five kidneys. After the removal of the vascular clamp, a control wedge resection was made in the opposite pole in order to confirm viability and perfusion. The authors found that (i) the polyethylene glycol polymer was adherent to the underlying tissue surface; (ii) the bleeding was significantly less in the polyethylene glycol-treated group; and (iii) no urinary leakage occurred during ex vivo retrograde perfusion studies performed at pressures as high as 100 mmHg.

Coseal[§] is another polyethylene glycol polymer combination that received Food and Drug Administration approval in 2003. Unlike Focalseal-L, Coseal does not require photoactivation and therefore makes its application potentially less cumbersome. The material forms a flexible, watertight seal that is reabsorbed within 30 days of its application (60).

Until prospective clinical trials are performed, the efficacy of Coseal and Focalseal-L in urologic laparoscopy remains uncertain. Nevertheless, synthetic sealants are advantageous because allergic and viral transmission risks are nonexistent and because intact clotting pathways are unnecessary.

CONCLUSION

Biologic and synthetic hemostatic agents have contributed and will continue to contribute significantly to all surgical fields. The hemostatic and sealing properties of bioadhesives make them particularly applicable to urology because nephrectomies, partial nephrectomies, and reconstructive renal surgeries are now the mainstays of urologic laparoscopy. The number of commercially available fibrin sealants has risen dramatically

Until prospective clinical trials are performed, the efficacy of Coseal and Focalseal-L in urologic laparoscopy remains uncertain. Nevertheless, synthetic sealants are advantageous because allergic and viral transmission risks are nonexistent and because intact clotting pathways are unnecessary.

[†]Ethicon, Inc., Somerville, NJ.

[‡]Focal, Inc., Lexington, MA.

[§]Baxter Healthcare Corporation, Deerfield, IA.

Ultimately, we are responsible to our patients and we must therefore navigate through the marketing machines and the latest trends to identify the products that are the safest, most effective, easiest to apply, and the most cost effective.

over the last several years and breakthroughs in bioengineering and recombinant technology will likely propel further development of bioadhesives that are safer, more effective, and easier to use. It is important to remember that in the realm of surgery, bioadhesive agents are still new. Likewise, compared to time-tested traditional means of establishing hemostasis and closure of the urinary collecting system, current and future bioadhesive agents will need further evaluation in large, prospective clinical trials.

Ultimately, we are responsible to our patients and we must therefore navigate through the marketing machines and the latest trends to identify the products that are the safest, most effective, easiest to apply, and the most cost effective.

SUMMARY

- Biologic hemostatic agents have the potential to be a useful adjunct to traditional means in controlling intraoperative laparoscopic complications.
- The use of hemostatic agents implies potential risks of allergic reactions because bovine thrombin is immunogenic. Products containing bovine protein should be contraindicated in patients with known allergy hypersensitivity reactions.
- Due to their excellent rheological properties (elasticity, tensile strength, and adhesiveness), fibrin sealants are excellent additions to standard methods of tissue approximation and help secure hemostasis.
- To avoid thromboembolic complications, fibrin sealant should not be injected directly into large blood vessels.
- Tranexamic acid is contraindicated during any surgical procedures with possible exposure to the cerebrospinal fluid or the dura mater because it can cause neurologic symptoms including trembling, involuntary head movements, and clonic contractions in rabbits.
- Fibrin-sealant variants combining autologous fibrinogen with bovine thrombin and collagen have no risk of viral transmission. However, risk of bovine spongiform encephalopathy and allergic reaction remains.
- Relying on endogenous fibrinogen, gelatin matrix hemostatic sealants are ineffective in fibrinogenemic patients. They are not adhesive and should be not used for collecting system sealing.
- Gelatin matrix hemostatic sealants can work in cases of fairly active bleeding, whereas fibrin sealants and physical agents are better suited for diffuse bleeding or oozing.
- Experimental and clinical data indicate that the sole use of fibrin sealant for ureteral anastomosis is unsafe.
- Synthetic sealants are advantageous because allergic and viral transmission risks are nonexistent and because intact clotting pathways are unnecessary.

REFERENCES

1. Eden CG, Sultana SR, Murray KH, et al. Extraperitoneal laparoscopic dismembered fibrin-sealant pyeloplasty: medium-term results. *Br J Urol* 1997; 80:382.
2. Bergel S. Über wirkungen des fibrins. *Dtsch Med Wochenschr* 1909; 35:633.
3. Grey E. Fibrin as a hemostatic in cerebral surgery. *Surg Gynecol Obstet* 1915; 21:452.
4. Seddon HJ. Fibrin sutures of human nerves. *Lancet* 1942; II:87.
5. Cronkite EP, Lozner EL, Deaver JM. Use of thrombin and fibrinogen in skin grafting. *JAMA* 1944; 124:976.
6. Radosevich M, Goubran HI, Burnouf T. Fibrin sealant: scientific rationale, production methods, properties, and current clinical uses. *Vox Sang* 1997; 72:133–143.
7. Gible JW, Ness PM. Fibrin sealant: the perfect operative sealant? *Transfusion* 1990; 30:741.
8. Parise LV, Smyth SS, Collier BS. Platelet morphology, biochemistry and function. In: Beutler E, Collier BS, Lichtman MA, Kipps TJ, Seligsohn U, eds. *Williams Hematology*. 6th ed. New York: McGraw-Hill, 2001:1357–1408.
9. Loscalzo J, Inbal A, Handin RI. von Willebrand protein facilitates platelet incorporation into polymerizing fibrin. *J Clin Invest* 1986; 78:1112.
10. Mosesson MW. Fibrin polymerization and its regulatory role in hemostasis. *J Lab Clin Med* 1990; 116:8–17.
11. Hermans J, McDonagh. Fibrin: structure and interactions. *Semin Thromb Hemostat* 1982; 8:11–24.
12. Matras H. Fibrin seal: the state of the art. *J Oral Maxillofac Surg* 1985; 43:605–611.
13. Busuttill RW. A comparison of antifibrinolytic agents used in hemostatic sealants. *J Am Coll Surg* 2003; 197:1021–1028.
14. Levy JH. Hemostatic agents and their safety. *J Cardiothorac Vasc Anesth* 1999; 13(suppl):6–11.
15. Beierlein W, Scheule AM, Antoniadis G, Braun C, Schosser R. An immediate, allergic skin reaction to aprotinin after reexposure to fibrin sealant. *Transfusion* 2000; 40:302–305.

16. Scheule AM, Beierlein W, Wendel HP, Eckstein FS, Heinemann MK, Ziemer G. Fibrin sealant, aprotinin, and immune response in children undergoing operations for congenital heart disease. *J Thorac Cardiovasc Surg* 1998; 115:883–889.
17. Scheule AM, Beierlein W, Lorenz H, Ziemer G. Repeated anaphylactic reactions to aprotinin in fibrin sealant. *Gastrointest Endosc* 1998; 48:83–85.
18. Scheule AM, Beierlein W, Wendel HP, Jurmann MJ, Eckstein FS, Ziemer G. Aprotinin in fibrin tissue adhesives induces specific antibody response and increases antibody response of high dose intravenous application. *J Thorac Cardiovasc Surg* 1999; 118:348–353.
19. Orsel I, Guillaume A, Feiss P. Anaphylactic shock caused by fibrin glue. *Ann Fr Anesth Reanim* 1997; 16:292–293.
20. Kon NF, Masumo H, Nakajima S, Tozawa R, Kimura M, Maeda S. Anaphylactic reaction to aprotinin following topical use of biological tissue sealant. *Masui* 1994; 43:1606–1610.
21. Crosseal fibrin sealant, <http://www.crosseal.com>, April 9, 2004.
22. Crosseal Fibrin Sealant (Human) Package Insert. Washington, D.C.: American Red Cross, 2003.
23. Mankad PS, Codispoti M. The role of fibrin sealants in hemostasis. *Am J Surg* 2001; 182:12S–28S.
24. Shekarraz B, Stoller ML. The use of fibrin sealant in urology. *J Urol* 2002; 167:1218–1225.
25. Cornum RL, Morey AF, Harris R, et al. Does the absorbable fibrin adhesive bandage facilitate partial nephrectomy? *J Urol* 2000; 164:864–867.
26. Morey AF, Anema JG, Harris R, et al. Treatment of grade 4 renal stab wounds with absorbable fibrin adhesive bandage in a porcine model. *J Urol* 2001; 165:955–958.
27. Bishoff JT, Cornum R, Perahia B, et al. Laparoscopic heminephrectomy using a new fibrin sealant powder. *Urol* 2003; 62:1139–1143.
27. Oz M, Cosgrove DM III, Badduke BR, et al. Fusion Matrix Study Group: controlled clinical trial of a novel hemostatic agent in cardiac surgery. *Ann Thorac Surg* 2000; 69:1376–1382.
29. Reuthebach O, Lachet ML, Vogt P, Schurr U, Turina M. Floseal: a new hemostytic agent in peripheral vascular surgery. *Vasa* 2000; 29:204–206.
30. Weaver FA, Hood DB, Zatiria M, Messina LM, Badduke B. Gelatin-thrombin-based hemostatic sealant for intraoperative bleeding in vascular surgery. *Ann Vasc Surg* 2002; 16:286–293.
31. Renkens KL Jr., Payner T, Leipzig TJ, et al. Multicenter, prospective, randomized trial evaluating a novel hemostatic agent in spinal surgery. *Spine* 2001; 26:1645–1650.
32. Jacobs JB. Use of Floseal in endoscopic sinus surgery: operative techniques in otolaryngology. *Head Neck Surg* 2001; 12:83–84.
33. Oz MC, Rondinone JF, Shargill NS. Floseal matrix: new generation of topical hemostatic agent. *J Card Surg* 2003; 18:486–493.
34. Richter F, Schnorr D, Deger S, et al. Improvement of hemostasis in open and laparoscopically performed partial nephrectomy using a gelatin matrix-thrombin tissue sealant (Floseal). *Urology* 2003; 61:73–77.
35. Bak JB, Singh A, Shekarraz B. Use of a gelatin matrix thrombin tissue sealant as an effective hemostatic agent during laparoscopic partial nephrectomy. *J Urol* 2003; 171:780–782.
36. User HM, Nadler RB. Applications of floseal in nephron-sparing surgery. *Urology* 2003; 62:342–343.
37. Stifelman MD, Sosa RE, Nakada SY, Shichman SJ. Hand-assisted laparoscopic partial nephrectomy. *J Endourol* 2001; 15:161–164.
38. Kletscher BA, Lauvetz RW, Segura JW. Nephron-sparing laparoscopic surgery: techniques to control the renal pedicle and manage parenchymal bleeding. *J Endourol* 1995; 9:23–30.
39. Jeschke K, Peschel R, Wakonig J, Schellander L, Bartsch G, Henning K. Laparoscopic nephron-sparing surgery for renal tumors. *Urology* 2001; 58:688–692.
40. Janetschek G, Hobisch A, Peschel R, Bartsch G. Laparoscopic retroperitoneal lymph node dissection. *Urol* 2000; 55:136–140.
41. Molina WR, Desai MM, Gill IS. Laparoscopic management of chylous ascites after donor nephrectomy. *J Urol* 2003; 170:1938.
42. Kram HB, Ocampo HP, Yamaguchi MP, Nathan RC, Shoemaker WC. Fibrin glue in renal and ureteral trauma. *Urology* 1989; 33:215–218.
43. McKay TC, Albala DM, Gehrin BE, Castelli M. Laparoscopic ureteral reanastomosis using fibrin glue. *J Urol* 1994; 152:1637–1640.
44. Wolf JS Jr., Soble JJ, Nakada SY, et al. Comparison of fibrin glue, laser weld, and mechanical suturing device for the laparoscopic closure of ureterotomy in a porcine model. *J Urol* 1997; 157:1487–1492.
45. Anidjar M, Desgrandchamps F, Martin L, et al. Laparoscopic fibrin glue ureteral anastomosis: experimental study in the porcine model. *J Endourol* 1996; 10:51–56.
46. Bhayani SB, Grubb III, Andriole GL. Use of gelatin matrix to rapidly repair diaphragmatic injury during laparoscopy. *Urology* 2002; 60:514i–514ii.
47. Canby-Hagino ED, Morey AF, Jatoi I, Perahia B, Bishoff JT. Fibrin sealant treatment of splenic injury during open and laparoscopic left radical nephrectomy. *J Urol* 2000; 164:2004–2005.
48. Martinowitz U, Saltz R. Fibrin sealant. *Curr Opin Hematol* 1996; 3:395.
49. Banninger H, Hardegger T, Tobler A, et al. Fibrin glue in surgery: frequent development of inhibitors of bovine thrombin and human factor V. *Br J Haematol* 1993; 85:528–532.
50. Ortel TL, Charles LA, Keller FG, et al. Topical thrombin and acquired coagulation factor inhibitors: clinical spectrum and laboratory diagnosis. *Am J Hematol* 1994; 45:128–135.
51. Rapaport SI, Zivelin A, Minow RA, Hunter CS, Donnelly K. Clinical significance of antibodies to bovine and human thrombin and factor V after surgical use of bovine thrombin. *Am J Clin Pathol* 1992; 97:84–91.
52. Lawson JH, Pennell BJ, Olson JD, Mann KG. Isolation and characterization of an acquired antithrombin antibody. *Blood* 1990; 76:224–2257.
53. Zehnder JL, Leung LL. Development of antibodies to thrombin and factor with recurrent bleeding in a patient exposed to topical bovine thrombin. *Blood* 1990; 76:2011–2016.

54. Tisseel VH fibrin sealant, <http://www.tissuesealing.com/us/products/biological/> monograph. cfm, April 9, 2004.
55. Hino M, Ishiko O, Honda K, et al. Transmission of symptomatic parvovirus B19 infection by fibrin sealant used during surgery. *Br J Haematol* 2000; 108:194–195.
56. Morita Y, Nishii O, Kido M, Tutsumi O. Parvovirus infection after laparoscopic hysterectomy using fibrin glue hemostasis. *Obstet Gynecol* 2000; 95:1026.
57. Tateishi J, Kitamoto T, Ishikawa G, Manabe SI. Removal of causative agent of Creutzfeld-Jakob disease (CJD) through membrane filtration method. *Membrane* 1993; 18:101–110.
58. Sebesta MJ, Bishoff JT. Octylcyanoacrylate skin closure in laparoscopy. *J Endourol* 2003; 17:899–903.
59. Ramakumar S, Roberts WW, Fugita OE, et al. Local hemostasis during laparoscopic partial nephrectomy using biodegradable hydrogels: initial porcine results. *J Endourol* 2002; 6:489–494.
60. Coseal, <http://www.baxter.com>, April 9, 2004.

Akshay Bhandari

Vattikuti Urology Institute, Henry Ford Health System, Detroit, Michigan, U.S.A.

Lee Richstone

Brady Urologic Health Center, Weill Medical College of Cornell University, Ithaca, New York, U.S.A.

Ashutosh Tewari

Robotic Prostatectomy and Urologic Oncology Outcomes, Weill Medical College of Cornell University, Ithaca, New York, U.S.A.

<ul style="list-style-type: none"> ■ INTRODUCTION ■ HISTORY OF ROBOTICS ■ ROBOTICS IN SURGERY <ul style="list-style-type: none"> Why Employ Robots in Surgery? Robotic Surgical Applications ■ ROBOTICS IN UROLOGY <ul style="list-style-type: none"> Transurethral Resection of Prostate Image-Guided Percutaneous Procedures Prostate Biopsy Laparoscopy Surgeon-Driven Robotic Systems Automated Endoscopic System for Optimal Positioning 	<ul style="list-style-type: none"> Stanford Research Institute Advanced Robotics and Telemanipulator System for Minimally Invasive Surgery <i>da Vinci</i> Surgical System Zeus System ■ TELESURGERY ■ VIRTUAL REALITY ■ LIMITATIONS OF ROBOTIC SURGERY ■ FUTURE ROBOTIC SURGERY SYSTEMS ■ SUMMARY ■ REFERENCES
---	---

In the past century, advances in science and technology have brought dramatic changes that have transformed the practice of medicine and surgery.

INTRODUCTION

In the past century, advances in science and technology have brought dramatic changes that have transformed the practice of medicine and surgery. Such advances have led to the development of more accurate diagnostics as well as more effective, less morbid, treatments that have been the highlight of modern medicine. The field of robotics has emerged as one such discipline with great potential to transform medicine. Although robotics has found common and useful applications in industry, agriculture, space, and aviation, robotics has been harnessed for application in the field of medicine only recently. Ranging from simplistic laboratory robots to highly complex surgical robots, which can aid a human surgeon or even execute operations by themselves, the robot has many potential roles in 21st century medicine. Manifold advantages including speed, accuracy, repeatability, and reliability may be gained from a robot.

The Laws of Robotics:

- Law Zero: A robot may not injure humanity, or, through inaction, allow humanity to come to harm.
- Law One: A robot may not injure a human being, or, through inaction, allow a human being to come to harm, unless this would violate a higher-order Law.
- Law Two: A robot must obey the orders given to it by human beings except where such orders would conflict with a higher-order Law.
- Law Three: A robot must protect its own existence as long as such protection does not conflict with a higher-order Law.

HISTORY OF ROBOTICS

The term robot, taken from the Czech word *robota*, meaning forced labor, was coined by the Czech playwright Karel Capek in 1921 in his play *Rossum's Universal Robots*. Since then, man has had a fascination with "the robot." The robot conjures up many, and often contradictory, images. The robot is at the same time a symbol of the future of technological advancement and limitless possibilities as well as the subservient machine performing menial, repetitive tasks. The robot alternatively liberates man, as worker and friend, or enslaves him, with the sinister possibility of robots rising up against their makers.

Such a conception of robots is reflected in the work of Isaac Asimov, first coining the phrase "robotics" in 1941 in a short story called "Runaround." As both a scientist and a writer of science fiction, he proposed three laws of robotics, to which he added a "zeroth" law later (1).

The Laws of Robotics:

- Law Zero: A robot may not injure humanity, or, through inaction, allow humanity to come to harm.

Key attributes of current robots:

- Programmability, implying computational or symbol-manipulative capabilities, which a designer can combine as desired (a robot is a computer);
- Mechanical capability, enabling it to act on its environment rather than merely function as a data-processing or computational device (a robot is a machine); and
- Flexibility, in that it can operate using a range of programs to manipulate and transport materials in a variety of ways.

Robots have many attributes that can aid the modern surgeon. Although humans are clearly superior to robots with regard to clinical judgment, decision making, and flexibility, robots offer precision, stamina, strength, lack of tremor, and reproducibility.

Robotic surgery also offers the well-described benefits of minimally invasive surgery and laparoscopy.

Overcoming the disadvantages inherent to conventional laparoscopy, and expanding the benefits of minimally invasive surgery are major aims of surgical robotics.

- Law One: A robot may not injure a human being, or, through inaction, allow a human being to come to harm, unless this would violate a higher-order Law.
- Law Two: A robot must obey the orders given to it by human beings except where such orders would conflict with a higher-order Law.
- Law Three: A robot must protect its own existence as long as such protection does not conflict with a higher-order Law.

In contrast to this imaginative code of “ethics” of robotics, the robots of today possess three key attributes, which serve as a more useful definition. As currently defined, robots exhibit the following attributes:

Key attributes of current robots:

- Programmability, implying computational or symbol-manipulative capabilities, which a designer can combine as desired (a robot is a computer);
- Mechanical capability, enabling it to act on its environment rather than merely function as a data-processing or computational device (a robot is a machine); and
- Flexibility, in that it can operate using a range of programs to manipulate and transport materials in a variety of ways.

With the merging of computers, telecommunications networks, robotics, distributed systems software, and the multiorganizational application of the hybrid technology, the distinction between computers and robots has become increasingly arbitrary.

Westinghouse first designed actual robots in 1940, with the creation of “Sparko,” a motorized dog that barked and stood on its hind legs, and dancing to “Elektra.” The first practical application of robots was during 1962, when General Motors used industrial robots for the first time. Since then, robotics has flourished. The benefits of modern robotics, including precision, reliability and speed of operation, have been widely employed to relieve humans of mundane work and dangerous tasks in industries and researches. Although robotics has been widely embraced outside of medicine, its acceptance in the field of medicine has been gradual.

ROBOTICS IN SURGERY

Why Employ Robots in Surgery?

Robots have many attributes that can aid the modern surgeon. Although humans are clearly superior to robots with regard to clinical judgment, decision making, and flexibility, robots offer precision, stamina, strength, lack of tremor, and reproducibility. This has led to a role for robots in a variety of surgical tasks including instrument positioning, trajectory planning, cutting, drilling, and milling. Robotic surgery also offers the well-described benefits of minimally invasive surgery and laparoscopy.

Like conventional laparoscopy, the incisions used during robotic surgery are smaller. This translates clinically to quicker convalescence, shorter hospital stays, diminished postoperative pain, and narcotic requirements, as well as a diminished risk of infections and better cosmesis (2,3). However, conventional laparoscopy has several limitations. These are largely technical and mechanical issues, stemming from the nature of standard laparoscopic equipment. The standard endoscope forces the surgeon to work looking at a video monitor instead of looking at his/her hands, thus disturbing the surgeon’s hand–eye coordination. Conventional endoscopes use two-dimensional vision, thus limiting the depth of perception of normal binocular vision. In addition, there is loss of haptic feedback, referring to both the force feedback and tactile feedback used routinely in open surgery. Decreased haptic feedback makes tissue manipulation heavily dependent on visual feedback. Laparoscopic instruments work through ports placed within the body wall. With the port acting as a pivot, the direction of the instrument tip is reversed from that of the instrument handle, leading to counterintuitive motion. This also leads to a compromise in dexterity because the port at the body wall constrains the motion of the instrument in two directions. The result is that the tip of the conventional laparoscopic instrument has only four degrees of freedom, in contrast to the human hand having seven degrees of freedom. Finally, physiological tremors of the surgeon’s hands are transmitted through the length of rigid instruments. These limitations make delicate dissection and the creation of complex anastomoses very challenging to the conventional laparoscopist.

Overcoming the disadvantages inherent to conventional laparoscopy, and expanding the benefits of minimally invasive surgery are major aims of surgical robotics.

Robotic Surgical Applications

Surgical robotics was pioneered in the 1980s in the field of neurosurgery and later in the field of orthopedics (4,5). Robotic “registration,” the ability of the robot to be oriented with respect to the anatomy of the patient, and to transform coordinates from one system, such as an imaging study, to the actual “coordinates” of a patient with perfect alignment is one of the challenges of robotic surgery. Registration is somewhat simplified in neurosurgery and orthopedics because of the relatively fixed anatomic landmarks and bony structures available.

Robots have been employed in the field of neurosurgery to facilitate such procedures as brain biopsy, tumor resection, and stereotactic surgery. For example, in 1985, Kwoh et al. employed the PUMA 560 robot^a to perform neurosurgical biopsies with greater precision (6). Similarly, another robot, the NeuromateTM, has a well-established track record in stereotactic functional neurosurgery. In the field of orthopedic surgery, robots have a growing role in such procedures as hip and knee arthroplasty. The ROBODOC[®] surgical system^b is a modified industrial robot, which is used for several of orthopedic procedures. Designed to address potential human errors in performing cementless total-hip replacement, the ROBODOC surgical system employs a motorized arm with the capacity to drill a precise hole in the femur during hip-replacement surgery (7).

Additional pioneering work in the development of robotic-assisted surgery was the result of a joint collaboration in the United States between the National Aeronautics and Space Administration, the Jet Propulsion Laboratory, and MicroDexterity Systems, a private interest. As part of the Jet Propulsion Laboratory’s Telerobotics Program, these interests formed the Robot-Assisted MicroSurgery project in the early 1990s. The purpose of this program was to build the technology and workstations necessary to improve robotic dexterity and enable microsurgical procedures to advance to the point where they could be applied to procedures of the eyes, ear, nose, throat, face, hand, and brain. By 1994, the Robot-Assisted MicroSurgery project had successfully developed a robotic arm measuring 2.5 cm in diameter and 25 cm in length, which was capable of six degrees of motion. In the following year, a system of kinematics and high-level control, which included an electronic safety system, was added. This technology was successfully tested at the Cleveland Clinic Foundation in the late 1990s during a simulated-eye microsurgery. Subsequent work produced a dual-arm telerobotic microsurgery workstation capable of microsurgical suturing.

The United States Army became interested in the possibility of “bringing the surgeon to the wounded soldier—through telepresence” (7). A system was thus devised whereby a wounded soldier could be transferred to the nearest Mobile-Activated Surgical Hospital, a vehicle with robotic surgical equipment, within which a wounded soldier could be operated on remotely by a surgeon. Although successfully tested in animal models, this system has yet to be implemented in an actual battlefield setting.

Robots designed to hold and manipulate instruments, such as cameras or retractors, have been a tremendous success. In 1994, Computer Motion, Inc.^c developed the automated endoscopic system for optimal positioning (AESOP 1000). The AESOP 3000, which features a voice-activated robotic arm that holds the camera and endoscope assembly for the surgeon during an endoscopic procedure and moves it with seven degrees of freedom, was introduced in 1998.

Intuitive Surgical^{®d} made an important advancement in robotic surgical instrumentation with the introduction of the *da Vinci*TM Surgical System, which received Food and Drug Administration approval in July 2000. Based on the same concept, Computer Motion, Inc. introduced the Zeus[®] surgical system soon after the *da Vinci* system. In both systems, the surgeon sits comfortably at a master console and controls the “slave” robotic instruments using a pair of master manipulators resembling joysticks. Separately, cameras are inserted into the patient’s body to give a three-dimensional view of the body interior. Multiple specialties have employed these systems for a wide variety of operations.

Although not yet commonplace, robots are revolutionizing surgery, and urology is no exception. In fact, urologists have been leaders in the development and application of surgical robotics.

ROBOTICS IN UROLOGY

Although not yet commonplace, robots are revolutionizing surgery, and urology is no exception. In fact, urologists have been leaders in the development and application of surgical robotics.

^aProgrammable Universal Machine for Assembly, Staubli Unimation, Duncan, SC.

^bIntegrated Surgical Supplies Ltd., Sacramento, CA.

^cComputer Motion, Inc., Goleta, CA.

^dIntuitive Surgical, Sunnyvale, CA.

Genitourinary surgical procedures, including radical prostatectomy, cystoprostatectomy, and pyeloplasty are examples of the complex operations being performed and perfected with the aid of robotic systems.

Early work focused on utilizing robots to perform transurethral resection of the prostate as well as prostatic biopsies. Other applications involve percutaneous renal access and surgery. More recently, a surge of interest in “urobotics” has accompanied the introduction of the *da Vinci* and Zeus systems (5,8).

Challenging genitourinary surgical procedures, including radical prostatectomy, cystoprostatectomy, and pyeloplasty are examples of the complex operations that are being performed and perfected with the aid of robotic systems.

Transurethral Resection of Prostate

Robotic surgical systems used for soft-tissue operations, such as those performed in urology, require very sophisticated robotic responsiveness and computer control to adapt to the deformability and mobility of the organs. Procedures performed on fixed bony structures or within the skull have the advantage of having relatively fixed points of reference to aid in robot registration.

In 1988, Davies demonstrated the feasibility of the robotic transurethral resection of the prostate using the PUMA 560 (9). The Surgeon-Assistant Robot for Prostatectomy, consisting of a small cutting blade rotating at 40,000 r.p.m., was derived from a six-axis PUMA robot to perform transurethral resection of the prostate. After further development at the Imperial College from 1993 to 1995, the Surgeon-Assistant Robot for Prostatectomy was renamed PROBOT (a robot for prostatectomy) and specifically designed to perform transurethral resection of the prostate. Studies showed that the entire resection could be successfully completed with good hemostasis (10). The major limitation of this technique was the inaccuracy in determining prostatic dimensions using transrectal ultrasound (10).

Needle access required for percutaneous renal surgery is a challenging art. A steep learning curve characterizes the acquisition of skill necessary to gain access safely and routinely.

Image-Guided Percutaneous Procedures

Needle access required for percutaneous renal surgery is a challenging art. A steep learning curve characterizes the acquisition of skill necessary to gain access safely and routinely.

It is presently performed by manually inserting the needle under single-view fluoroscopic radiological guidance. To improve on this approach, several researchers have investigated the use of robotic systems in assisting in the needle placement.

Potamianos et al. have proposed a stereopair of two X-ray views registered to a common fiducial system with a five-degrees-of-freedom passive linkage that is equipped with position encoders to position a passive needle guide (11,12). Bzostek et al. used an active robot, LARS, for a similar application. Although these robotic systems successfully address the issues of image-to-robot registration and provide a very convenient means of defining target anatomy, they are expensive and their large size makes them cumbersome for routine use in the operating room. Stoianovici et al., from Johns Hopkins University, developed the simple, noncomputerized system—Percutaneous Access of the Kidney—for this purpose (13,14). Percutaneous Access of the Kidney is a radiolucent needle driver actuated by an electrical motor. The surgeon manually orients the driver and therefore the needle using the technique of “superimposed needle registration” (13). Percutaneous Access of the Kidney is then locked into the desired orientation and needle insertion is manually controlled by a joystick. Using the Percutaneous Access of the Kidney device in nine patients, percutaneous access to the desired calyx was attained in the first attempt in each case. Percutaneous Access of the Kidney appeared to be safe and effective, with no perioperative complications attributable to needle access, and even offered a reduction in procedure time (15). Encouraged by these preliminary results, the same group later reported the development of a remote center of motion actuator module called the “MINI-remote center of motion.” This module is reported to integrate both with Percutaneous Access of the Kidney and a wide variety of additional end effectors, which are under development. The idea is to simplify the orientation procedure, increase accuracy, reduce radiation exposure, and to achieve Percutaneous Access of the Kidney’s compatibility with computerized tomography. The MINI-remote center of motion is an extremely compact robot that utilizes the remote center of motion principle of the LARS robot (16).

Prostate Biopsy

An image-guided robot system has been developed and employed for transperineal prostate biopsies.

The surgeon selects the biopsy site using transrectal ultrasound images and the robot obtains the sample from that location with a precision of 1 to 2 mm in needle position. This procedure was found to be quicker, more precise than the conventional

An image-guided robot system has been developed and employed for transperineal prostate biopsies.

Two alternative robotic projects enabling automated harvesting of prostate biopsy samples have been recently developed.

techniques, and very reliable as the robot maintains its own position (17). An SR 8438 Sankyo Scara robot is used to perform this operation. It is remote controlled, i.e., via tele-robotics, and requires accurate positioning in known points of three-dimensional space with a high degree of precision (18).

Two alternative robotic projects enabling automated harvesting of prostate biopsy samples have been recently developed.

In the projects proposed by the group at Johns Hopkins University, prostate biopsies are taken using a modified Percutaneous Access of the Kidney robot. In fact, current Percutaneous Access of the Kidney drive system is not strong enough to drive the needle into prostatic tissue, and also requires instrumentation to provide feedback regarding the needle position. In the modified Percutaneous Access of the Kidney system, a computerized tomography-image set is used to target the prostate and register the robot, and the biopsy needle is inserted through the skin rather than through the rectum. A second approach has been pursued by a group at Politecnico di Milano, Italy, where an industrial robot is being used directly to insert biopsy needles through the skin using a telerobotic approach. Biopsy site may be localized by computerized tomography, stereotactic fluoroscopy, or ultrasound. However, the two systems described above are relatively expensive because they require additional computerized tomography-based imaging of the prostate.

Laparoscopy

As in all fields of surgery, laparoscopy/minimally invasive surgery has had a significant impact on urology. The manifold benefits of laparoscopy, including smaller incisions, diminished blood loss, lesser pain, quicker recovery, and shorter hospital stay, have been well substantiated by several studies (19,20). On the other hand, the technically demanding nature of laparoscopy, the lack of haptic feedback, and limited dexterity, among other issues, are significant obstacles. This is particularly true when performing complex pelvic surgery.

Certain urologic procedures are very challenging for conventional laparoscopic surgeons due to either complex anatomy or the need for extensive intracorporeal suturing. Examples include radical prostatectomy, radical cystectomy, and pyeloplasty.

Certain urologic procedures are very challenging for conventional laparoscopic surgeons due to either complex anatomy or the need for extensive intracorporeal suturing. Examples include radical prostatectomy, radical cystectomy, and pyeloplasty.

Surgeon-Driven Robotic Systems

Several *surgeon-driven robots* are being used in performing urologic laparoscopy. In contrast to *image-guided robots*, which automatically manipulate instruments under the prescription of the physician based on digital imaging, surgeon-driven systems continuously take the surgeon's input and, in real time, translate it to corresponding instrument manipulation.

Surgeon-driven robots augment the manipulation capabilities of the physician above and beyond the surgeon's manual and visual capacity.

These systems can filter tremors and thus decrease them, scale motion, aid in manipulation of tissues in confined spaces, provide exceptional optics, and may even provide remote haptic feedback.

Surgeon-driven robots augment the manipulation capabilities of the physician above and beyond the surgeon's manual and visual capacity.

Automated Endoscopic System for Optimal Positioning

Designed by Computer Motion, Inc., AESOP is one of the simplest types of surgeon-driven systems. Its sole function is to hold and orient a laparoscopic camera under hand, foot, or voice control. The AESOP has six degrees of freedom, two of which are passive (positioned by hand and do not have motors actuating them). The robot has been used at several institutions and in many clinical areas, including urologic laparoscopy (21). Kavoussi et al. found that the camera was significantly steadier under robot versus direct human control, and neither operative setup nor breakdown time was increased with the use of the robotic assistant (22). The AESOP arm uses voice recognition software, which is prerecorded onto a voice card and inserted into the controller.

Computer Motion's National Aeronautics and Space Administration-funded research demonstrated that voice-controlled commands are preferable to alternatives such as eye tracking and head tracking, which control motion in response to movements of the surgeon's head.

Computer Motion's National Aeronautics and Space Administration-funded research demonstrated that voice-controlled commands are preferable to alternatives such as eye tracking and head tracking, which control motion in response to movements of the surgeon's head.

For voice control, the surgeon must wear a microphone and prerecord a voice card that covers the set of movements possible with AESOP.

In 1994, the AESOP 1000 system became the world's first surgical robot certified by the Food and Drug Administration in the United States. AESOP 2000, with the enhancement of voice control, and AESOP 3000, with seven degrees of freedom followed, within 1996 and in 1998, respectively. The redundancy of the AESOP 3000 provides more flexibility in endoscope positioning. Being simple to operate, reliable, and

safe, AESOP soon gained popularity and by 1999 over 80,000 surgical procedures had been performed using AESOP technology (23–27).

Stanford Research Institute

The first surgeon-driven instrument manipulation system was developed for open surgical procedures at the Stanford Research Institute in Menlo Park, California. This system, which is operated from a console, includes a two-arm, high-mobility robot instrumented with grippers. Cornum and Bowersox used the system for in vivo porcine nephrectomies and the repair of bladder and urethral injuries (28).

Advanced Robotics and Telem manipulator System for Minimally Invasive Surgery was the first system that provided instrument mobility with six degrees of freedom.

Advanced Robotics and Telem manipulator System for Minimally Invasive Surgery

The Advanced Robotics and Telem manipulator System for Minimally Invasive Surgery system was designed at the Institute of Applied Informatics in Tübingen University, Germany in 1992. It was the first system that provided instrument mobility with six degrees of freedom.

It integrated the Fips endoarm with a conventional technical telem manipulator, mastered by a joystick (29,30). The prototype reached the experimental phase, but was unable to proceed to commercial production or clinical application (31). The “Kinematic Simulation, Monitoring and Off-Line Programming Environment for Telerobotics” software was used in the Advanced Robotics and Telem manipulator System for Minimally Invasive Surgery system as a three-dimensional real-time simulation support tool.

da Vinci Surgical System

The *da Vinci* Surgical System is the most successful and most widely used surgeon-driven robot to date.

Since its introduction in Europe in 2000 by cardiovascular surgeons, its applications have been expanding to include a number of surgical procedures, such as Nissen fundoplication, cholecystectomy, hernia repair, gastropasty, appendectomy, and hysterectomy. The use of the *da Vinci* Surgical System in urologic surgery, including radical prostatectomy, radical cystectomy, adrenalectomy, pyeloplasty, donor nephrectomy, partial nephrectomy, and vasovasostomy is also rapidly evolving (32–37).

The *da Vinci* system consists of three major components—the surgeon’s console, the patient side cart, and the vision cart.

- **Surgeon’s Console:** The surgeon’s tool handles are serial link manipulators designated the masters. The masters act as (i) high-resolution input devices reading the position, orientation, and grip commands from the surgeon, and (ii) as haptic displays transmitting forces and torques to the surgeon in response to various measured and synthetic force cues. The console also consists of two medical grade cathode ray tube monitors that receive the image of the surgical site to display one image to each of the surgeon’s eyes. The user interface at the surgeon’s console consists of foot pedals and buttons, which allow the surgeon to control the system. This interface allows the surgeon to control the endoscope from the console itself, position the masters in the work space, focus the endoscope, control the cautery, and so on.

The surgeon’s console also consists of an electronic controller. It is a custom-designed control computer, with a peak computational power of 384 Mflops and a sustained processing power of 128 and 256 Mflops. Redundant sensors, hardware watchdogs, and real-time error detection ensure fail-safe operation of the controller in all its states.

- **Patient Side Cart:** The patient side cart consists of two instrument arms and a centrally located camera arm holding the endoscope. An optional fourth instrument arm has been recently added in an attempt to reduce one patient side assistant.

The instrument arms are designed to accurately deliver instruments with seven degrees of freedom into the body. Each instrument arm is fixed to the patient with the help of a cannula, which attaches to a cannula mount on the instrument arm with the help of cannula mount pins. To permit precise instrument tip movements, move the instrument arms position under the direction of the surgeon at the console. The surgeon’s hand movements at the masters are precisely replicated at the instrument tips. A wide range of custom-made instruments (Endowrist) are available. These Endowrist instruments are fully sterilizable and are attached interchangeably to the two-tool manipulators.

The *da Vinci* Surgical System is the most successful and most widely used surgeon-driven robot to date.

The camera arm is also fixed to the patient through a cannula, which attaches to the cannula mount on the camera arm with the help of a cannula mount camera clamp. The camera arm controls the position and movement of the three-dimensional endoscope from outside the patient's body.

The set up joints hold the instrument arms and the camera arm, and are used to position the surgical cart arms to achieve optimal approach to patient's anatomy.

- **Vision System:** Vision is provided by a high-resolution stereoendoscope that uses two independent optical channels, sampled by two independent three-chip charge-coupled device cameras. The image is relayed to the vision cart through a camera head attached to the endoscope. Left and right images are processed independently by the two camera control units, one each for the left and right optical paths. The vision cart also consists of two synchronizers, a focus controller, and a light source. The synchronizers process the operative image to maximize clarity and edge definition. The focus controller is operated via the foot switch on the surgeon console or two push buttons on the front panel of the focus controller. The light source provides the desired illumination during the operation and also heats the tip of the endoscope to minimize lens fogging during the operation. The distal tip of the endoscope may exceed 41°C when used, thus contact with skin and tissue may cause tissue damage.

The *da Vinci* system is designed to create an “immersive operating environment” for the surgeon by providing both high-quality stereovisualization and a man-machine interface, which directly connect the surgeon's hands to the motion of his surgical instrument tips inside the patient's body (38,39). The registration, or alignment, of the surgeon's hand motions to the motion of the surgical instrument tip is both visual and spatial. To restore hand-eye coordination and to provide a natural correspondence in motions, the system projects the image of the surgical site atop the surgeon's hands with the help of mirrored overlay optics. Moreover, the controller transforms the spatial motion of the tools into the camera frame of reference, so that the surgeon feels as if his hands were inside the patient's body. Lastly, the system restores the degrees of freedom lost in conventional laparoscopy by employing three degrees of freedom wrist, bringing a total of seven degrees of freedom to the movement of the instrument tip. The control system of the robot eliminates surgeon tremor, makes the instrument tip steadier than the unassisted hand, and allows for variable motion scaling from the masters to the slaves. Together with image magnification of 10X, motion scaling enables delicate motions easier to perform (40).

Zeus System

To introduce the AESOP robot, Computer Motion had already improved one element of minimally invasive surgery, namely support and positioning of endoscopic cameras. In the Zeus system, all the instruments were robotic. Similar to the *da Vinci*, the surgeon can sit comfortably at a master console and control the slave robotic instruments using a pair of master manipulators. Later, the Zeus system was integrated with the Hermes system^e, which is a platform for centralizing control of devices inside as well as resources outside the operating room. The system can be controlled by the surgeon using simple verbal commands or an interactive hand-held, touch screen pendant. Similar to the AESOP, the Hermes system recognizes the surgeon's voice through a prerecorded voice card that the surgeon inserts into the system prior to the start of surgery.

The camera, insufflator, light source, and other additional instruments are adjusted by voice or by a foot pedal. Three-dimensional vision is incorporated, but requires the use of goggles with shutter glasses.

The instruments used in the Zeus system closely resemble conventional surgical instruments.

The instruments used in the Zeus system closely resemble conventional surgical instruments.

TELESURGERY

In telesurgery, the actions of the robot are not predetermined, but controlled by the operating surgeon in real time through an interface.

Telesurgery involves a surgeon performing surgery from a remote location, be it a far away place or across the room.

Telesurgery involves a surgeon performing surgery from a remote location, be it a far away place or across the room.

^eStryker Endoscopy, San Jose, CA.

In telesurgery, the surgeon relies completely on the sensor data, which is transmitted by the robot at the remote location. The sensor data, therefore, must be very accurately transmitted.

Human-computer interface is one of the most complicated aspects of telesurgery. It has to be simple, intuitive, and efficient.

Because the surgeon is separated from the patient by distance, a robot, local to the patient, becomes the surgeon's hands, while an intricate interface helps the surgeon connect and communicate with the patient. Telesurgery is a part of robotic surgery because the robot is the one actually performing the surgery.

In telesurgery, the surgeon relies completely on the sensor data, which is transmitted by the robot at the remote location. The sensor data, therefore, must be very accurately transmitted.

Various schemes are used for this purpose. Fiducials are reference features, located on both the computer-based model and the anatomic object, and are used as a means of aligning the virtual image with the actual position of both the robot and the patient. In addition to that, infrared transmitters and receivers are used, as they offer very fast and very accurate registration.

Human-computer interface is one of the most complicated aspects of telesurgery. It has to be simple, intuitive, and efficient.

The virtual reality glove is one potential approach. The glove uses flex-controlled potentiometers or optical fibers, which can sense the position of the surgeon's hands with satisfactory speed and precision. This data is then transmitted to the robot, which follows the hand movement.

Telesurgery offers the advantages of minimally invasive surgery. In traditional surgery, hand size is a limiting factor when it comes to performing delicate movements or operating in hard-to-reach places. The robot can overcome this limitation because it can be as small as desired and can enter through a small opening and access any part of the body without the need for big incisions.

Additional potential benefits associated with telesurgery are:

- Reduced costs related to patients and specialist traveling.
- Remote treatment of patients by national and international specialists.
- Surgeon skills enhanced by a robotic interface.
- Robotic arms and controllers operating at an accuracy of approximately $\pm 5 \mu\text{m}$, computed with $\pm 50 \mu\text{m}$ for the best microsurgeons (41).
- Motion scaling and tremor filtering allowing tasks impossible to perform otherwise.

In spite of these potential advantages, there are several concerns about telesurgery. The initial financial investment in acquiring a telesurgical system is considerable. Moreover, there are also medicolegal concerns regarding liability. Due to the fact that telesurgery would involve a number of specialists, hospitals, and countries, jurisdiction conflicts may occur (42). However, the major concern about telesurgery relates to its safety. Current robotic surgical systems have a variety of built-in safety features such as manual override (43) and "safety freeze" (16). However, problems such as loss of communication between the surgeon and the operating room or failure of the telesurgical system may occur and require someone on site to take charge.

Virtual reality is a highly evolved technology with the potential to allow people to interact in a computer-generated three-dimensional environment in real time using their natural senses and skills.

The three-dimensional mapping of genomes in deoxy ribonucleic acid research introduced virtual reality into medicine.

VIRTUAL REALITY

Virtual reality is a highly evolved technology with the potential to allow people to interact in a computer-generated three-dimensional environment in real time using their natural senses and skills.

Although virtual reality is closely related to computer simulation, it has many unique features. Whereas simulation is a method useful for education and training, virtual reality implies a computer-generated environment that is much more life like. With the help of an interface device, the user becomes a part of a virtual environment within which he/she can move and manipulate objects.

Although the term virtual reality was first introduced by Jaron Lanier in 1989, the concept of virtual reality emerged long before in 1963, when Ivan Sutherland developed the head-mounted display, which heralded the theories and themes of modern immersive science (44). In the 1970s, various industries began to see the applications and implications of virtual reality. One of the more obvious applications of virtual reality was in the making of films like *Star Wars* that were studded with special effects.

The three-dimensional mapping of genomes in deoxy ribonucleic acid research introduced virtual reality into medicine.

The introduction of virtual reality into surgery began in the 1980s. Surgical training is one of the key applications of this technology. For the purpose of surgical training, simulation and virtual reality do not have to rely on detailed graphics (unlike complex

Surgical training is expensive, time consuming, and can be limited by the number of cases available at a particular institution. With virtual reality technology, surgical trainees would have the ability to sharpen their skills and broaden their experience by performing procedures repeatedly in a simulated environment outside the operating room.

professional flight simulators) and even moderately detailed surgical virtual reality systems could be effective in task training.

Surgical training is expensive, time consuming, and can be limited by the number of cases available at a particular institution. Ideally, surgical trainees would have the ability to sharpen their skills and broaden their experience by performing procedures repeatedly in a simulated environment outside the operating room. Virtual reality technology has the potential to provide surgeons with this type of optimal training environment.

A number of virtual reality training systems have been developed. For example, a venipuncture simulator proved to be effective in training health-care professionals. The system employs force feedback to simulate the feel of a cannula entering the skin and vein (45). There are a variety of more complex systems available for endoscopic procedures, including gastroscopy and colonoscopy to train gastroenterologists (45). Cardiac catheterization and angiography trainers are also available with real time modeling of physiological parameters and blood flow (45).

As computing power continues to advance, so will the capabilities of virtual reality systems. At present, virtual reality systems for surgery provide highly detailed models that are capable of fulfilling some of the training needs of surgeons. While still very expensive, it is estimated that with proper marketing and with the development of cheaper methods of production, the economics of virtual reality will become more favorable.

LIMITATIONS OF ROBOTIC SURGERY

Innovative and “cutting-edge” technology requires maturation and refinement, and inherently carries with it benefits and limitations. Robotic surgery is no exception. There is considerable room for improved kinematic configurations, as well as more compact and efficient actuator and transmission technologies. In terms of sensing and control, robots are driven by computers and share the same shortcomings, especially for autonomous operation. Robots follow instructions literally, and cannot use qualitative reasoning or exercise meaningful judgement. Increasing computational power may improve robot-control capabilities.

The loss of haptic feedback is a shortcoming of contemporary robotic systems. Haptic feedback comprises force feedback as well as texture, viscosity, temperature, and other characteristics, which provide the surgeon with much information. With further advancements in robotics, the technology necessary to provide haptic feedback may evolve.

Another obstacle to the widespread application of robotics is cost. Any new technology will fail unless there is a sufficient market to allow for the system to be mass produced, thereby reducing cost. The initial investment to acquire a robotic system may be prohibitive, and significant clinical benefit to patients needs to be demonstrated to justify this expenditure. Despite these challenges, surgical robotics is starting to thrive. In fact, medicine may prove to be one of the most fertile grounds for future robotic applications. Therefore, it is expected that as production and competition increase, the cost of robotics will go down significantly.

FUTURE ROBOTIC SURGERY SYSTEMS

As previously mentioned, one of the major points of criticism of robotic telemanipulators is the lack of haptic feedback from the operating instruments. While some surgeons using the current systems on a regular basis feel that this is partly compensated for by the superior three-dimensional visual feedback, others differ. Future robotic systems are likely to include improved haptic feedback data.

The enormous size of the systems compromises their proper positioning, thus either miniaturization or integration of the system into the design of the operating room by attachment to the ceiling may help in the future. The key to the future success of these systems lies in producing highly trained surgeons well versed with the robotic system. Because certain procedures are rarely performed, virtual reality training programs can be integrated into robotic systems for the purpose of “surgical-skills” training. The development of a telestrator may further help the experienced surgeon to instruct the trainee. The telestrator is a regular part of sports broadcasts and allows the announcer to draw lines and circles on screen showing how a play works and develops. Alternatively, a double-console concept would also serve the same purpose and would allow the experienced surgeon to adjust and correct the movements of the trainee. Similar to the concept of driving instructors, the second console would allow the tutor

The loss of haptic feedback is a shortcoming of contemporary robotic systems. Another obstacle to the widespread application of robotics is cost.

Future robotic systems are likely to include improved haptic feedback data.

As technology becomes more sophisticated, the concept of remote surgery will become more prevalent, extending the benefits of robotics to areas that lack similar services. This will allow the world's best surgeons to perform specialist procedures remotely using robotic control in any part of the world.

to take over the instruments when needed and demonstrate the correct maneuver, helping in the safe transfer of skills. This will also help in diminishing the learning curve in using the system.

As technology becomes more sophisticated, the concept of remote surgery will become more prevalent, extending the benefits of robotics to areas that lack similar services. This will allow the world's best surgeons to perform specialist procedures remotely using robotic control in any part of the world.

Moreover, the robotic systems of the future will be more cost effective and affordable, aiding in the dissemination of the technology.

Although the use of robotics in medicine and surgery is growing rapidly, the field is in its infancy. Just as laparoscopy represents a "revolution" in the art of surgery, the potential for robotics to transform surgical practice is enormous. Through continued technological innovation and human imagination, the robots of the future will help to improve the surgeon's precision and efficacy in and beyond the 21st century.

SUMMARY

- Although humans are clearly superior to robots with regard to clinical judgment, decision-making, and flexibility, robots offer precision, stamina, strength, lack of tremor, and reproducibility.
- Robotic surgery offers the benefit of minimally invasive surgery and laparoscopy.
- Robots are revolutionizing urology, and urologists have been leaders in the development of an application of surgical robotics.
- Robotic transurethral resection of the prostate is feasible.
- Robotic system can assist needle placement during percutaneous renal surgery.
- Robotic systems have been developed to overcome limitation and improve the benefits of conventional laparoscopy performed for challenging urologic procedures.
- Surgeon-driven robots augment the manipulation capabilities of the physician above and beyond the surgeon's manual and visual capacity.
- Voice-controlled commands are preferable to eye tracking or head tracking, which control motion in response to movements of the surgeon's head.
- The *da Vinci* Surgical System is the most successful and most widely used surgeon-driven robot.
- The robotic instruments used in the Zeus System closely resemble conventional surgical instruments.
- Reduction of some surgery-related costs, remote patient management, enhanced surgeon skills, accuracy, and capability to perform challenging procedures are advantages of telesurgery.
- Virtual reality might provide surgeons with optimal training environment.
- Loss of haptic feedback and cost are the major shortcoming of contemporary robotics. Continued technological innovation and increased market competition could overcome such limitations.

REFERENCES

1. Clarke R. Asimov's laws for robotics: implications for information technology. *Computer* January 1993;57–65. Part 1–2; December 1994:53–61.
2. Fuchs KH. Minimally invasive surgery. *Endoscopy* 2002; 34(2):154–159.
3. Allendorf JD, Bessler M, Whelan RL, et al. Postoperative immune function varies inversely with the degree of surgical trauma in a murine model. *Surg Endosc* 1997; 11(5):427–430.
4. Buckingham RA, Buckingham RO. Robots in operating theatres. *BMJ* 1995; 311(7018):1479–1482.
5. Shah J, Mackay S, Rockall T, Vale J, Darzi A. 'Urobotics': robots in urology. *BJU Int* 2001; 88(4): 313–320.
6. Kwok YS, Hou J, Jonckheere EA, Hayati S. A robot with improved absolute positioning accuracy for computerized tomography guided stereotactic brain surgery. *IEEE Trans Biomed Eng* 1988; 35(2):153–160.
7. Satava RM. Surgical robotics: the early chronicles: a personal historical perspective. *Surg Laparosc Endosc Percutan Tech* 2002; 12(1):6–16.
8. Stoianovici D. Urobotics—urology robotics at Johns Hopkins. *Comput Aided Surg* 2011; 6(6):360–369.
9. Davies B. A review of robotics in surgery. *Proc Inst Mech Eng* 2000; 214:129–140.
10. Nathan MS, Davies BL, Hibberd B, et al. Devices for automated resection of the prostate. *Proceedings of the First International Symposium on Medical Robotics and Computer Assisted Surgery* Pittsburgh, Pennsylvania, 1994:342–344.
11. Potamianos P, Davies BL, Hibberd RD. Intra-operative imaging guidance for keyhole surgery methodology and calibration. *Proceedings of the First International Symposium on Medical Robotics and Computer Assisted Surgery* Pittsburgh, PA, 1994:98–104.
12. Potamianos P, Davies BL, Hibberd RD. Intra-operative registration for percutaneous surgery. *Proceedings of the Second International Symposium on Medical Robotics and Computer Assisted Surgery*, Baltimore, MD, 1995:156–164.
13. Stoianovici D, Cadeddu JA, Demaree RD, et al. An efficient needle injection technique and radiological guidance method for percutaneous procedures. *Lecture Notes in Computer Science*. Vol 205. CVR Med-MRCAS: Springer-Verlag, 1997:295–298.

14. Stoianovici D, Cadeddu JA, Demaree RD, et al. A novel mechanical transmission applied to percutaneous renal access. *Proceeding of the ASME Dynamic System and Control Division, DSC-Vol. 61*, 1997:401–406.
15. Cadeddu JA, Stoianovici D, Chen RN, Moore RG, Kavoussi LR. Stereotactic mechanical percutaneous renal access. *J Endourol* 1998; 12(2):121–125.
16. Taylor RH, Funda J, Eldrige B, et al. A Telerobotic Assistant for Laparoscopic Surgery. *IEEE Engineering in Medicine and Biology Magazine*, 1995:279–287.
17. Rovetta A, Sala R, Wen Z, et al. Sensorization of a surgeon robot for prostate biopsy operation. *Proceedings of the First International Symposium on Medical Robotics and Computer Assisted Surgery*, Pittsburgh, PA, 1994:345.
18. Rovetta A. Tests on reliability of a prostate biopsy telerobotic system. *Stud Health Technol Inform* 1999; 62:302–307.
19. Soper NJ, Barteau JA, Clayman RV, Ashley SW, Dunnegan DL. Comparison of early postoperative results for laparoscopic versus standard open cholecystectomy. *Surg Gynecol Obstet* 1992; 174(2):114–118.
20. McMahon AJ, Russell IT, Baxter JN, et al. Laparoscopic versus minilaparotomy cholecystectomy: a randomised trial. *Lancet* 1994 15; 343(8890):135–138.
21. Rassweiler J, Frede T. Robotics, telesurgery and telementoring—their position in modern urological laparoscopy. *Arch Esp Urol* 2002; 55(6):610–628.
22. Kavoussi LR, Moore RG, Adams JB, Partin AW. Comparison of robotic versus human laparoscopic camera control. *J Urol* 1995; 154(6):2134–2136. Erratum in: *J Urol* 1997; 158(4):1530.
23. Partin AW, Adams JB, Moore RG, Kavoussi LR. Complete robot-assisted laparoscopic urologic surgery: a preliminary report. *J Am Coll Surg* 1995; 181:552–557.
24. Sackier JM, Wang Y. Robotically assisted laparoscopic surgery. From concept to development. *Surg Endosc* 1994; 8:63–66.
25. Kavoussi LR, Moore RG, Partin AW, Bender JS, Zenilman ME, Satava RM. Telerobotic assisted laparoscopic surgery: initial laboratory and clinical experience. *Urology* 1994; 44:15–19.
26. Kavoussi LR, Moore RG, Adams JB, Partin AW. Comparison of robotic versus human laparoscopic camera control. *J Urol* 1995; 154:2134–2136.
27. Bowersox JC, Cornum RL. Remote operative urology using a surgical telemanipulator system: preliminary observations. *Urology* 1998; 52:17–22.
28. Cornum RL, Bowersox JC. Telepresence: a 21st century interface for urologic surgery. *J Urol* 1996; 155(suppl 5):489A (abstract 715).
29. Ruurda JP, van Vroonhoven TJ, Broeders IA. Robot-assisted surgical systems: a new era in laparoscopic surgery. *Ann R Coll Surg Engl* 2002; 84(4):223–226.
30. Schurr MO, Buess G, Neisius B, Voges U. Robotics and telemanipulation technologies for endoscopic surgery. A review of the Advanced Robotics and Telemanipulator System for Minimally Invasive Surgery project. *Advanced Robotic Telemanipulator for Minimally Invasive Surgery*. *Surg Endosc* 2000; 14(4):375–381.
31. Cassack D. In vivo: the business and medicine report, Jan 2000:35–44.
32. Menon M, Tewari A. Vattikuti Institute Prostatectomy Team. Robotic radical prostatectomy and the Vattikuti urology institute technique: an interim analysis of results and technical points. *Urology* 2003; 61(4 suppl 1):15–20.
33. Menon M, Hemal AK, Tewari A, et al. Nerve-sparing robot-assisted radical cystoprostatectomy and urinary diversion. *BJU Int* 2003; 92(3):232–236.
34. Horgan S, Vanuno D, Sileri P, Cicalese L, Benedetti E. Robotic-assisted laparoscopic donor nephrectomy for kidney transplantation. *Transplantation* 2002; 73(9):1474–1479.
35. Gettman MT, Neururer R, Bartsch G, Peschel R. Anderson-Hynes dismembered pyeloplasty performed using the da Vinci robotic system. *Urology* 2002; 60(3):509–513.
36. Patel R, Taneja S, Stifelman MD, et al. da Vinci system assisted laparoscopic partial nephrectomy (abstract). *J Endourol* 16(suppl 1):A203.
37. Young JA, Chapman WH III, Kim VB, et al. Robotic-assisted adrenalectomy for adrenal incidentaloma: case and review of the technique. *Surg Laparosc Endosc Percutan Tech* 2002; 12(2):126–130.
38. Guthart GS, Salisbury JK. The Intuitive Telesurgery System: Overview and Application. *Proceedings of the 2000 IEEE International Conference on Robotics and Automation*, San Francisco, CA, April 2000.
39. Salisbury JK. The heart of microsurgery. *Mechanical Engineering Magazine, ASME Int* 1998; 120(2):47–51.
40. Falk V, McLoughlin J, Guthart G, et al. Dexterity enhancement in endoscopic surgery by a computer controlled mechanical wrist. *Min Inv Therapy Allied Technol* 1999; 8(4):235–242.
41. Falk V, Diegler A, Walther T, Autschbach R, Mohr FW. Developments in robotic cardiac surgery. *Curr Opin Cardiol* 2000; 15(6):378–387.
42. Marescaux J, Leroy J, Rubino F, et al. Transcontinental robot-assisted remote telesurgery: feasibility and potential applications. *Ann Surg* 2002; 235(4):487–492.
43. Stanberry B. Telemedicine: barriers and opportunities in the 21st century. *J Intern Med* 2000; 247(6):615–628.
44. Gorman P, Krummel T. Simulation and virtual reality in surgical education: real or unreal? *Arch Surg* 1999; 134: 1203–1208.
45. McCloy R, Stone R. Science, medicine, and the future. *Virtual reality in surgery. BMJ* 2001; 323(7318):912–915.

SECTION

III

LAPAROSCOPY: GENERAL TECHNIQUES

BASICS OF RETROPERITONEAL LAPAROSCOPY

Monish Aron, Benjamin Chung, and Inderbir S. Gill

Section of Laparoscopic and Robotic Surgery, Glickman Urological Institute, Cleveland Clinic Foundation, Cleveland, Ohio, U.S.A.

- | | |
|---|--|
| <ul style="list-style-type: none"> ■ INTRODUCTION ■ INDICATIONS ■ CONTRAINDICATIONS ■ PREOPERATIVE WORKUP <ul style="list-style-type: none"> Endocrine Preparation ■ SURGICAL TECHNIQUE <ul style="list-style-type: none"> Patient Positioning Retroperitoneal Access Balloon Dilation Port Placement Initial Dissection Technique for Radical Nephrectomy Technique for Adrenalectomy | <ul style="list-style-type: none"> ■ INTRAOPERATIVE TROUBLESHOOTING <ul style="list-style-type: none"> Proper Balloon Placement Problems with Orientation in the Retroperitoneum Inability to Locate the Renal Hilum Inadvertent Peritoneotomy ■ TIME MANAGEMENT ■ COMPLICATIONS ■ CONCLUSION ■ REFERENCES |
|---|--|

The retroperitoneum is a potential, not an actual, space.

INTRODUCTION

The retroperitoneoscopic approach to renal and adrenal surgery is less popular than the transperitoneal laparoscopic approach, primarily because of its limited working space and surgeons' relative unfamiliarity with the optimal operative technique. Other perceived drawbacks of performing surgery in the retroperitoneum include the abundance of fat and the paucity of easily recognizable anatomical landmarks.

Unlike the peritoneal cavity, the retroperitoneum is a potential, not an actual, space. To create a viable working area, the retroperitoneal space needs to be deliberately expanded. It was not until Gaur (1) described an atraumatic balloon dilation technique to expand the retroperitoneum in 1992 that retroperitoneoscopy became a viable approach to treat urological pathology.

During the past decade, increasing experience at various centers has led to the refinement of laparoscopic techniques that take advantage of the strengths of the retroperitoneal approach while overcoming its perceived disadvantages (2–9). At our institution, retroperitoneoscopy is a common approach for most renal and adrenal pathology. Presented herein are our current techniques of retroperitoneal laparoscopy (10–14).

INDICATIONS

Retroperitoneoscopy has been used for a variety of renal and adrenal procedures (Table 1). In patients with morbid obesity or peritoneal scarring from prior transabdominal procedures, retroperitoneoscopy allows a superior and more direct approach to the renal hilum. The equipment usually required for retroperitoneoscopic surgery is summarized in Table 2.

Laparoscopic radical nephrectomy (15) and adrenalectomy (16) can be performed efficiently and effectively by either the transperitoneal or the retroperitoneal approach. Control of the renal hilum may be quicker and total operative time shorter with the retroperitoneoscopic approach. Operative morbidity, postoperative complications, and pathological characteristics of the intact extracted specimen are similar with both approaches. As such, in most instances, the choice of approach depends on the comfort level, training, and preference of the individual surgeon.

CONTRAINDICATIONS

General contraindications for laparoscopic surgery include severe cardiopulmonary compromise, uncorrected coagulopathy, and intra-abdominal sepsis. Specific to

TABLE 1 ■ Procedures Amenable to the Retroperitoneoscopic Approach

Adrenal
Adrenalectomy
Adrenal cyst decortication
Renal
Simple nephrectomy
Radical nephrectomy
Nephroureterectomy
Renal tumor cryoablation
Pyeloplasty
Renal biopsy
Renal cyst deroofting
Living donor nephrectomy
Partial nephrectomy
Pyelolithotomy and extended pyelolithotomy
Anatrophic nephrolithotomy
Ureteral
Ureterolithotomy
Reconstruction for retrocaval ureter

TABLE 2 ■ Equipment Necessary for Retroperitoneal Laparoscopy

No. 15 or 11 scalpel blade (1)
S retractors (2)
Balloon dilator device
Laparoscopic trocars: Bluntip balloon port 10 mm (1), 12 mm (1-2), 5 mm (2), 2 mm (1) (if required)
Laparoscope (10 mm, 30°: 5 mm, 30°)
Electrosurgical scissors (5 mm)
Electrosurgical hook (5 mm)
Laparoscopic right-angle dissecting forceps (5 mm, 10 mm)
Laparoscopic grasping forceps (short straight clamp, small bowel clamp, locking grasping clamp, Maryland clamp)
Laparoscopic irrigation/suction probe (5 mm)
Laparoscopic clip applicators, for metal and plastic clips (5 mm, 10 mm)
Laparoscopic stapler with vascular cartridge
Endocatch bag (10 mm shaft, 15 mm shaft)
Bipolar forceps (5 mm)—optional
Harmonic scalpel—optional
Laparoscopic staplers

retroperitoneoscopy, relative contraindications include intense perirenal fibrosis secondary to xanthogranulomatous pyelonephritis, genitourinary tuberculosis, or recent open surgery of the retroperitoneum. However, a history of percutaneous renal surgery or biopsy does not preclude successful retroperitoneoscopic laparoscopy.

PREOPERATIVE WORKUP

Attention to the patient's cardiorespiratory status, bony or spinal abnormalities, coagulation studies, and history of prior surgery is imperative.

Attention to the patient's cardiorespiratory status, bony or spinal abnormalities, coagulation studies, and history of prior surgery is imperative. Preoperative bowel preparation includes two bottles of magnesium citrate on the afternoon before surgery, with clear liquids allowed until midnight.

A urinary catheter, compression stockings, and one dose of preoperative antibiotics are routine. An arterial line is mandatory in all patients with a pheochromocytoma.

Endocrine Preparation

Appropriate preparation from an endocrine standpoint is critical for successful adrenal surgical outcomes. At our institution, patients with a pheochromocytoma are pretreated with calcium-channel blockers and vigorous hydration, with alpha blockade being employed selectively. Patients with an aldosteroma are placed on the potassium-sparing diuretic spironolactone and oral potassium supplementation. Patients with Cushing's disease require perioperative stress doses of steroids.

SURGICAL TECHNIQUE

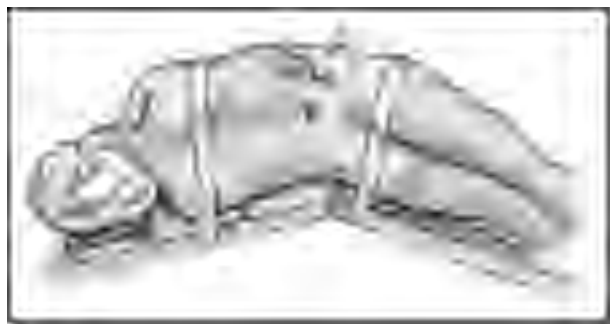Patient Positioning

The patient is placed in the standard lateral decubitus (full flank) position. Currently, we do not elevate the kidney bridge on the table, and the table is flexed to the least degree that will allow adequate separation of the costal margin from the iliac crest, the "access corridor" for retroperitoneoscopic surgery (Fig. 1). The surgeon and the assistant stand facing the back of the patient. Prolonged flank position has the potential to result in significant postoperative neuromuscular complications. All extremities must be placed in neutral positions and all pressure points meticulously padded with egg crate foam: head and neck, axilla, hip joint, knee, and ankle. We firmly secure the patient to the table with 3-inch adhesive cloth tape and a safety belt.

Retroperitoneal Access

An open technique is employed. A horizontal 2-cm transverse skin incision is made just below the tip of the last (12th) rib. S retractors are employed to separate the flank muscle fibers. The retroperitoneum is accessed by piercing the dorsolumbar fascia with the index finger or a hemostat. Using the index finger, gentle dissection is performed to

FIGURE 1 ■ Port placement and patient positioning during right retroperitoneal laparoscopy.



create a space for subsequent placement of the balloon dilator. It is important that the finger dissection be performed between the psoas muscle (and fascia) posteriorly and Gerota's fascia anteriorly. Proper entry into the retroperitoneum is important. The anterior surface of the psoas muscle is our primary anatomic landmark, during both the initial finger palpation and the subsequent intraoperative laparoscopic viewing. If the finger dissection is performed immediately along the anterior surface of the psoas muscle and fascia, it automatically stays posterior to, and outside of, Gerota's fascia.

Balloon Dilation

Additional working space in the retroperitoneum is created with a trocar-mounted balloon (Fig. 2) dilator. Initially, the balloon device is distended adjacent to the lower pole and mid-portion of the kidney (Fig. 3A). Approximately 800 cc of air (i.e., 40 pumps of the sphygmomanometer bulb device) are instilled to inflate the balloon. Thereafter, the balloon is deflated and manually advanced higher up along the psoas muscle into the retroperitoneum. The stiff shaft of the balloon dilator permits precise manual repositioning of the balloon dilator. This secondary cephalad balloon dilation of the upper retroperitoneum is performed in the vicinity of the adrenal gland and the undersurface of the diaphragm (Fig. 3B). Balloon dilation outside Gerota's fascia in the upper retroperitoneum effectively displaces the kidney anteromedially and opens up the potential retroperitoneal space, allowing access to the kidney and the adrenal, and exposes the entire anterior aspect of the psoas muscle, the primary anatomic landmark, during retroperitoneoscopy. The balloon is then deflated and removed. The dilation process can be monitored by inserting the laparoscope within the clear, transparent balloon to observe the following landmarks: psoas muscle (posteriorly), Gerota's fascia (anteriorly), and diaphragm (superiorly).

Port Placement

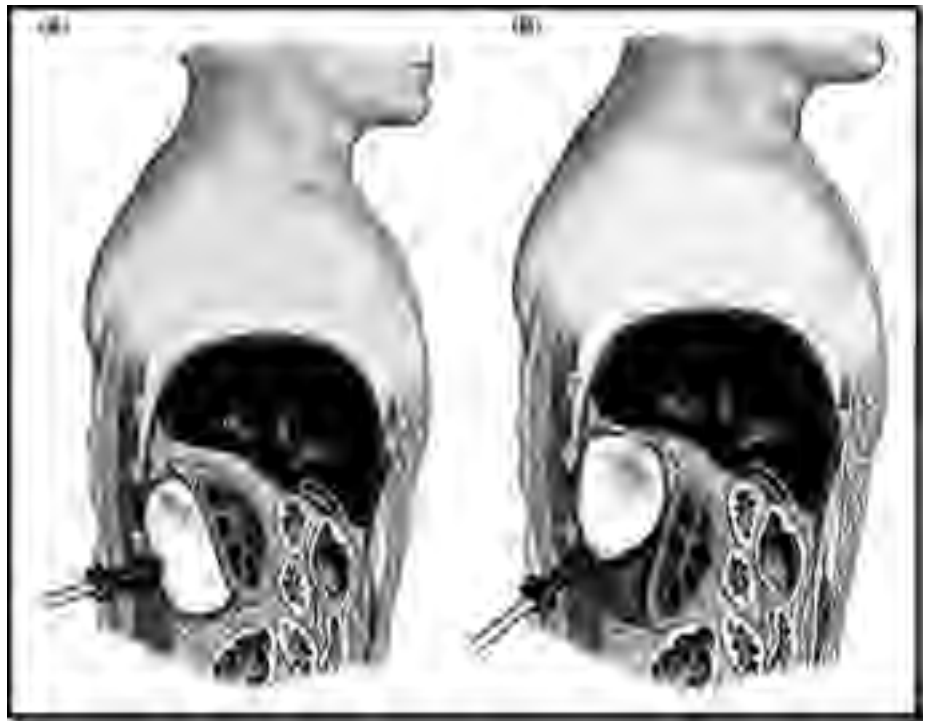
A 10 mm Bluntip trocar^{TM a} is placed as the primary port. This trocar has a doughnut-shaped, internal fascial retention balloon and an external adjustable foam cuff, which, when cinched down, creates an airtight seal at the primary port site. Easy to use, this device is an important factor in minimizing air leak and subcutaneous emphysema during retroperitoneoscopic procedures. CO₂ pneumoretroperitoneum is now established

FIGURE 2 ■ Balloon dilation of retroperitoneum. Positioned between psoas fascia posteriorly and Gerota's fascia anteriorly, distended balloon (800 cc air) displaces Gerota's fascia-covered kidney anteromedially, allowing straightforward access to renal vessels.



^aOrigin MedSystems, Menlo Park, CA.

FIGURE 3 ■ (A) Initial balloon dilation is performed posterior to lower pole and middle of kidney. (B) Secondary dilation is performed in more cephalad location along the undersurface of diaphragm.



(15 mmHg), and a 30° 10 mm laparoscope is inserted. Two or more retroperitoneal landmarks should be identifiable immediately: the psoas muscle, Gerota's fascia, lateral peritoneal reflection, ureter, renal artery pulsations, aortic pulsations (left side), and partially collapsed vena cava (right side). The psoas muscle and one or more of the following structures can be visualized with the following frequency: Gerota's fascia (100%), peritoneal reflection (83%), ureter and/or gonadal vein (61%), pulsations of the fat-covered renal artery (56%), aortic pulsations (left side; 90%), and the compressed, ribbon-like inferior vena cava (right side; 25%) (10). Usually two, and rarely three, secondary ports are placed. All ports are 12 mm for 3-port retroperitoneoscopy, although the port for the nondominant hand may be a 5 mm port. The anterior port is inserted near the anterior axillary line at least 3 cm cephalad to the iliac crest. A posterior port is inserted at the junction of the lateral border of the erector spinae muscle with the undersurface of the 12th rib. Commonly, this posterior port is inserted under laparoscopic control, although rarely, when this port is too close to the primary port to allow reliable endoscopic viewing, bimanual control may be employed. In the bimanual technique, the laparoscope and the Bluntip trocar are removed. For a right-handed surgeon, an S retractor, cradled by the surgeon's left index finger, is inserted within the retroperitoneum through the primary port site incision. The secondary port is inserted by the surgeon's right hand at the predesignated site at the lateral border of the erector spinae muscle and directed onto the S retractor. The S retractor protects the surgeon's left index finger from injury. Rarely, a fourth port (2 or 5 mm) may be required at the level of the primary port in the anterior axillary line for retraction of the adrenal gland and kidney anteriorly. This is sometimes required in the event of an inadvertent peritoneotomy, necessitating anteromedial retraction of the peritoneum. The three ports should be as far apart as possible. The anterior port should be 3 cm cephalad to the iliac crest; otherwise, the bone compromises its maneuverability. Clear laparoscopic observation during port placement is imperative to guard against injury to the peritoneum (anterior port), great vessels (posterior port), or pleura (the occasional fourth port).

Initial Dissection

With the kidney retracted or tented anterolaterally, a generous longitudinal incision is made in Gerota's fascia, parallel and close to the psoas muscle. This critical maneuver allows access to the renal hilar area. A search for vascular pulsations is initiated. Although gentle, undulating pulsations are characteristic of the inferior vena cava, sharp, well-defined pulsations reveal the location of the fat-covered renal artery or, on the left side, the aorta. Subsequent operative steps depend on the procedure being performed.

Technique for Radical Nephrectomy

Hilar Dissection

Hilar dissection commences with searching for renal arterial or aortic pulsations in the area of the renal hilum along the medial border of the psoas muscle. Blunt dissection in this area of loose areolar tissue is performed to identify renal arterial pulsations. The renal artery is circumferentially mobilized, clip occluded with locking plastic clips, and divided. The renal vein is mobilized and controlled with a gastrointestinal anastomosis vascular stapler (Fig. 4).

Adrenal Mobilization

Suprahilar dissection is performed along the medial aspect of the upper pole of the kidney and the adrenal vessels, including the main adrenal vein, precisely controlled. Dissection is next redirected towards the superolateral aspect of the specimen, including en bloc adrenal gland, which is readily mobilized from the underside of the diaphragm. In the areolar tissue in this location inferior phrenic vessels to the adrenal gland are often encountered and need to be controlled.

Specimen Mobilization

The anterior aspect of the specimen is mobilized from the undersurface of the peritoneal envelope. The ureter and gonadal vein are secured, and the specimen is completely freed by mobilizing the lower pole of the kidney. The entire dissection is performed outside Gerota's fascia, in keeping with standard oncological principles.

Entrapment and Exit

An Endocatch^b device is introduced through the right-hand port incision, and the specimen is entrapped (Fig. 5). Smaller specimens are entrapped within the Endocatch (10 mm shaft), whereas larger specimens require the Endocatch II device which (15 mm shaft) which is introduced directly through the port-site incision. For larger specimens, an intentional peritoneotomy is occasionally created strictly for specimen entrapment. Intact specimen extraction is performed through an appropriate muscle-splitting incision (Gibson or Pfannenstiel). Hemostasis is confirmed under lowered pneumoretroperitoneal pressure and ports are removed under direct vision. Fascial closure is performed for all 10 mm or larger port sites using a 0-Vicryl suture.

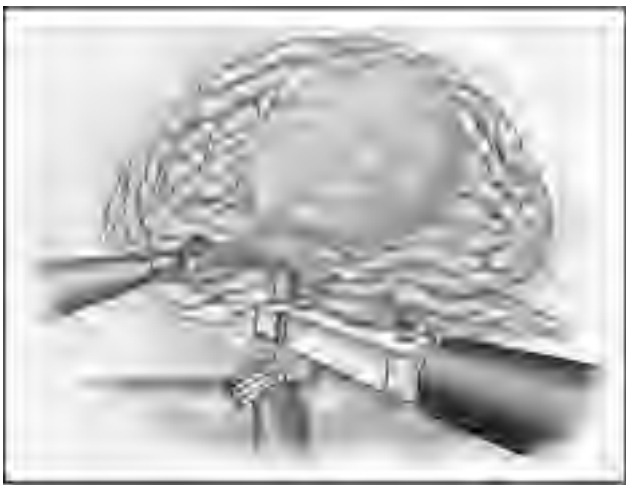

FIGURE 4 ■ Renal hilar control. Renal artery has been clip ligated and divided. Renal vein is circumferentially mobilized and controlled with gastrointestinal anastomosis stapler.



FIGURE 5 ■ Specimen entrapment in bag. Self-opening mouth of bag facilitates deployment of bag and subsequent specimen entrapment in restricted retroperitoneal space. After specimen entrapment, mouth of bag is detached from metallic ring and closed by pulling on built-in drawstring (inset).

^bU.S. Surgical Corp., Norwalk, CT.

Technique for Adrenalectomy

Incision of Gerota's Fascia Between the Upper Pole of the Kidney and the Adrenal Gland

The posterior aspect of Gerota's fascia is incised transversely at the level of the upper pole of the kidney (Fig. 6). The aim of the ensuing dissection is to circumferentially mobilize the upper pole and mid-region of the kidney and the covering Gerota's fascia. The upper pole is now dropped posteriorly onto the psoas muscle away from the adrenal gland. This dissection proceeds immediately adjacent to the parenchyma of the upper pole of the kidney. Care must be taken not to injure any accessory vessel entering the upper pole of the kidney. At this juncture, the unmobilized adrenal gland is still located in its normal position, attached anteriorly to the parietal peritoneum.

Control of Main Adrenal Vein—Left Adrenalectomy

Careful blunt and sharp dissection is performed toward the renal hilum, between the upper pole of the kidney posterolaterally and the adrenal anteromedially. The caudal limit of this dissection is the renal hilar vessels, usually, the superior branch of the renal artery. Multiple small renal hilar vessels supplying the adrenal gland are encountered in this location, which are securely clipped and divided. Dissection is now transversely continued medially along the renal vein or artery, and the main left adrenal vein may be identified (Fig. 7A) at this juncture and clipped (5 mm clips) and transected. If the main left adrenal vein cannot be identified at this stage, dissection is redirected toward the undersurface of the diaphragm. The adrenal gland is mobilized along its cephalad aspect, controlling the inferior phrenic branches. Multiple aortic branches to the adrenal gland may need to be controlled in this area. Continued dissection along the medial and inferomedial aspect of the adrenal gland will identify the main left adrenal vein as its sole remaining attachment. The left adrenal vein is longer than the right, arises from the inferomedial aspect of the left adrenal gland, and courses obliquely in an inferomedial direction to drain into the proximal left renal vein. The vein is then clipped and transected (Fig. 7B).

Control of Main Adrenal Vein—Right Adrenalectomy

The right main adrenal vein is shorter, horizontally located along the superomedial edge of the adrenal gland, and drains directly into the inferior vena cava. Dissection is carried cephalad along the lateral aspect of the inferior vena cava, between it and the adrenal gland, until the right adrenal vein is seen, circumferentially mobilized, clipped, and divided (Fig. 8). The adrenal gland is then mobilized from the undersurface of the diaphragm. The main right adrenal vein usually arises from the superomedial aspect of the right adrenal gland. Although multiple small renal hilar arteries and veins enter the adrenal gland along its inferior and inferomedial edge, the larger, more well-defined main right adrenal vein usually resides in a more cephalad location, beneath and along the posterior edge of the right lobe of the liver.

FIGURE 6 ■ Transverse incision in Gerota's fascia, with the aim of separating the upper renal pole from adrenal gland.



FIGURE 7 ■ (A) Left adrenalectomy: Dissection proceeds caudally immediately adjacent to parenchymal surface of medial aspect of upper pole of left kidney, which is retracted posterolaterally (*curved arrows*). Adrenal gland, surrounded by periadrenal fat, is retracted superomedially (*straight arrow*). Caudal endpoint of this dissection is renal hilar vessels. Main left adrenal vein may or may not be visible at this point in dissection. Curved broken line indicates subsequent plane of mobilization of adrenal gland from the undersurface of the diaphragm. **(B)** Left adrenalectomy: Control of main adrenal vein. Upper pole of left kidney has been dropped posteriorly onto psoas muscle. Adrenal gland has now been circumferentially freed. Main adrenal vein, arising from inferomedial aspect of left adrenal gland, is now clip ligated (5 mm clips) and divided.



Alternative Strategy

Instead of incising Gerota's fascia to enter the plane between the adrenal and the upper pole of the kidney as described above, an alternative technical strategy can be employed. After port placement, the Gerota's fascia-covered kidney is retracted anteromedially, exactly as one would during a radical nephrectomy. Gerota's fascia is incised longitudinally parallel and 1 to 2 cm anterior to the psoas muscle. Renal artery pulsations are identified, and dissection is initiated immediately cephalad to it. This dissection is performed in the cephalad angle between the renal artery and the inferior vena cava on the right side and between the renal artery and the aorta on the left side. Dissection proceeds superiorly along the anterolateral aspect of the inferior vena cava or aorta. Inferior adrenal vessels originating from the renal artery and vein are clip-secured at this location. Continued cephalad dissection between the adrenal gland and the ipsilateral great vessel reveals small middle adrenal vessels, arising from the aorta and vena cava, which are secured. On the right side, the main adrenal vein, draining into the inferior vena cava, is the next structure to be dissected, clipped, and divided. On the left side, the main adrenal vein may not be identifiable at this juncture and may require circumferential mobilization of the adrenal gland before it comes into view.

Circumferential Specimen Mobilization

After control of the adrenal vasculature has been secured, sequential blunt and sharp dissection of the remaining attachments frees up the adrenal gland. Inferior phrenic vessels are often encountered along the undersurface of the diaphragm. During specimen mobilization, one should be careful not to create an unintentional peritoneotomy. Although a peritoneotomy does not significantly compromise operative

FIGURE 8 ■ Retroperitoneoscopic right adrenalectomy. Dissection between adrenal gland and inferior vena cava reveals short, horizontal main right adrenal vein, which is controlled and transected. Remainder of mobilization of right adrenal gland is similar to that on left side.



exposure during a retroperitoneoscopic radical nephrectomy, a peritoneotomy during retroperitoneoscopic adrenalectomy may decrease the operative field in the vicinity of the undersurface of the diaphragm. In this circumstance, placement of a fourth port may be necessary for anterior retraction. A 2 mm port suffices for this purpose.

Entrapment and Exit

An Endocatch bag is introduced through the right-hand port and the excised specimen is entrapped and extracted intact through the primary port site. Hemostasis is confirmed by lowering the pneumoretroperitoneum for five minutes. Ports are removed under laparoscopic vision. The larger (10–12 mm) port site(s) is closed in fascial layers, and the smaller (5 mm) ports are closed with subcuticular sutures.

INTRAOPERATIVE TROUBLESHOOTING

Proper Balloon Placement

Finger dissection is performed anterior to the psoas muscle and fascia; the anterior aspect of the psoas muscle must be clearly palpable by the finger. The balloon dilator is then gently and precisely inserted into this location, and inflated posterior to and outside of Gerota's fascia. Laparoscopic visualization through the clear, transparent balloon confirms proper balloon placement.

Problems with Orientation in the Retroperitoneum

The camera should be oriented such that the psoas muscle is always absolutely horizontal on the video monitor. The psoas muscle can be identified most easily caudal to the kidney. At this stage of the procedure, the retroperitoneal space is small. Posterolateral traction on the primary trocar to elevate the abdominal wall or anteromedial retraction of the kidney serves to increase the retroperitoneal space.

Inability to Locate the Renal Hilum

If the renal hilum cannot be located, Gerota's fascia should be incised longitudinally, along the psoas muscle. The kidney should then be retracted anteriorly, placing the hilum on stretch. The laparoscope is then slowly advanced across the anterior surface of the psoas muscle from lateral to medial in a cephalad direction. With the laparoscope held steady, a search is made for pulsations along the medial border of the psoas. Gentle dissection directly toward the pulsations should reveal the underlying vessel. Alternatively, the ureter can be followed cephalad to the hilum. Finally, the surface of the kidney can be identified and traced medially to its hilum.

Inadvertent Peritoneotomy

A peritoneotomy does not necessarily mandate routine conversion to transperitoneal laparoscopy. Most commonly, the peritoneotomy is inconsequential. However, if operative exposure is compromised, a fourth port can be inserted to provide additional retraction, and the procedure can be successfully completed retroperitoneoscopically.

TIME MANAGEMENT

Two concerns about retroperitoneal laparoscopy have been difficulty in identifying various anatomic landmarks and a lack of a clear understanding of the sequential operative steps toward this end. Sung and Gill (10) employed a uniform database to record predetermined intraoperative parameters prospectively in 16 patients who underwent 18 retroperitoneoscopic radical nephrectomies. They documented the anatomic landmarks seen immediately after balloon dilation prior to any laparoscopic manipulations (*vide supra*). Additionally, they recorded the time taken to complete each specific part of the operation to create a realistic framework of its sequential operative steps. They found that port placement time ranged from 6 to 20 minutes, decreasing with experience. Hilar dissection time was impacted by specimen weight and whether four or more retroperitoneal landmarks could be identified immediately after balloon dilation. When specimen weight was greater than the median value of 436 g, the hilar dissection time was 78 minutes, compared with 47 minutes for those specimens weighing less than 436 g. When the initial balloon dilation resulted in visibility of four or more anatomic landmarks, hilar dissection time was significantly shorter (47 as against 82 minutes). Adrenal mobilization added a mean of 49 minutes (range, 20–68) to the radical nephrectomy procedure. In the analysis of surgical time

for the entire operation, specimen weight was again significant. In patients with a specimen weight greater than 436 g, the surgical time averaged 230 minutes compared with 176 minutes for specimens weighing less than 436 g. Specimen entrapment of large tumors could be a technically cumbersome operative step, given the confines of the retroperitoneal working space. Entrapment could be completed retroperitoneoscopically in 16 of 18 cases (89%). In two cases, for specimens weighing 867 g and 774 g, an intentional peritoneotomy had to be created at the end of the procedure solely for purposes of specimen entrapment (10).

COMPLICATIONS

At our center, vascular injuries were identified in 1.7% (7 of 404) and bowel injuries in 0.25% (1 of 404) of the patients undergoing major retroperitoneal laparoscopic renal and adrenal surgery between July 1997 and February 2001 (17). In five patients (63%), the injury could be controlled laparoscopically. Two patients required postoperative intensive care for one and three days, respectively. Of seven patients with vascular injuries, five required an average of 3.3 units of packed cells (range 1–8). Postoperatively ileus and atelectasis occurred in one patient and transient hypotension in another.

In an earlier multi-institutional review of 1043 retroperitoneoscopic/extraperitoneoscopic cases, Gill et al. (3) found that major complications occurred in 49 (4.7%) patients. Visceral injuries occurred in 26 (2.5%) patients and vascular injuries in 23 (2.2%). The commonest visceral injuries were pneumothorax ($n = 6$), pneumomediastinum ($n = 4$), and perforation of the urinary bladder ($n = 4$). Of note, of the 26 visceral injuries (2.5%), 7 (0.7%) were sustained by intraperitoneal organs: colon ($n = 3$), small bowel ($n = 2$), liver ($n = 1$), and spleen ($n = 1$). Of the vascular injuries (2.2%), the renal vein ($n = 6$) and inferior vena cava ($n = 4$) were the most frequently injured blood vessels. The retroperitoneoscopic/extraperitoneoscopic procedure was intraoperatively converted to transperitoneal laparoscopy in 56 (5.4%) patients. Conversion to open surgery was necessary in 69 patients (6.6%). Conversion to open surgery was performed in an elective manner in 41 patients (3.9%) and emergently in 28 patients (2.7%). Elective conversion to open surgery was most commonly indicated for significant adhesions or peritoneal tear ($n = 15$; 1.4%) or inadequate working space in the retroperitoneum ($n = 13$; 1.3%). Emergent open surgery was necessary to repair either visceral ($n = 16$; 1.5%) or vascular ($n = 12$; 1.2%) injuries.

CONCLUSION

Retroperitoneoscopy is our preferred technique for performing laparoscopic renal and adrenal surgery in most instances. The one exception is partial nephrectomy. Currently, our primary indications for transperitoneal laparoscopy include large renal and adrenal masses, cryoablation of anteriorly located renal tumors, partial nephrectomy for anterior and lateral tumors, pyeloplasty, and living donor nephrectomy. Compared with transperitoneal laparoscopy, retroperitoneoscopy is associated with a sharper learning curve. Meticulous attention during port placement is critical to ensure optimal positioning. Although the retroperitoneum initially affords a smaller working space than the peritoneal cavity, as the dissection proceeds, the retroperitoneal space can be readily enlarged and developed as necessary. Retroperitoneoscopy does offer potential advantages. Foremost is the facile exposure of the renal hilum. Because the bowel is not manipulated, paralytic ileus may be minimized. Inadvertent injury to peritoneal viscera is minimized, yet not eliminated, since intraperitoneal organs are separated only by the peritoneal membrane. The techniques discussed here have become an integral part of the training program in our department, and our experience to date indicates that the learning curve of retroperitoneoscopy will be significantly shorter for the subsequent generation of surgeons.

REFERENCES

1. Gaur DD. Laparoscopic operative retroperitoneoscopy: use of a new device. *J Urol* 1992; 148:1137–1139.
2. Rassweiler JJ, Henkel TO, Stock C, et al. Retroperitoneal laparoscopic nephrectomy and other procedures in the upper retroperitoneum using a balloon dissection technique. *Eur Urol* 1994; 25:229–236.
3. Gill IS, Clayman RV, Albala DM, et al. Retroperitoneal and pelvic extraperitoneal laparoscopy: an international perspective. *Urology* 1998; 52:566–571.

4. Rassweiler JJ, Seemann O, Frede T, et al. Retroperitoneoscopy: experience with 200 cases. *J Urol* 1998; 160:1265–1269.
5. Gill IS. Retroperitoneal laparoscopic nephrectomy. *Urol Clin North Am* 1998; 25:343–360.
6. Rassweiler JJ, Stock C, Frede T, et al. Nephrectomy: transperitoneal and retroperitoneal nephrectomy in comparison with conventional nephrectomy. *Urologe A* 1996; 35:215–222.
7. Gill IS, Hobart M, Soble JJ, et al. Retroperitoneal laparoscopic radical nephrectomy: comparison with open surgery [abstr.]. *J Urol* 1999; 161:166.
8. McDougall EM, Clayman RV. Laparoscopic nephrectomy for benign disease: comparison of the transperitoneal and retroperitoneal approach. *J Endourol* 1996; 10:45–49.
9. Ng CS, Gill IS, Sung GT, Whalley DG, Graham R, Schweizer D. Retroperitoneoscopic surgery is not associated with increased carbon dioxide absorption. *J Urol* 1999; 162:1268–1272.
10. Sung GT, Gill IS. Anatomic landmarks and time management during retroperitoneoscopic radical nephrectomy. *J Endourol* 2002; 16:165–169.
11. Hsu TH, Sung GT, Gill IS. Retroperitoneoscopic approach to nephrectomy. *J Endourol* 1999; 13:713–718.
12. Gill IS, Rassweiler JJ. Retroperitoneoscopic renal surgery: our approach. *Urology* 1999; 54:734–738.
13. Sung GT, Hsu TH, Gill IS. Retroperitoneoscopic adrenalectomy: lateral approach. *J Endourol* 2001; 15:505–512.
14. Gill IS, Schweizer D, Hobart MG, Sung GT, Klein EA, Novick AC. Retroperitoneal laparoscopic radical nephrectomy: the Cleveland Clinic experience. *J Urol* 2000; 163:1665–1670.
15. Desai MM, Strzempkowski B, Matin SF, et al. Prospective randomized comparison of transperitoneal versus retroperitoneal laparoscopic radical nephrectomy. *J Urol* 2005; 173:38–41.
16. Rubinstein M, Gill IS, Aron M, et al. Prospective randomized comparison of transperitoneal versus retroperitoneal laparoscopic adrenalectomy. *J Urol* 2005; 174:442–445.
17. Meraney AM, Samee AA, Gill IS. Vascular and bowel complications during retroperitoneal laparoscopic surgery. *J Urol* 2002; 168:1941–1944.

LAPAROSCOPIC SUTURING TECHNIQUES: GENERAL CONSIDERATIONS

Louis J. Giorgi, Jr.

Mercy Medical Group, Carmichael, California, U.S.A.

Michael E. Moran

Capital District Urologic Surgeons, Albany, New York, U.S.A.

- | | |
|---|---|
| <ul style="list-style-type: none"> ■ INTRODUCTION ■ LAPAROSCOPIC SUTURING TIME LINE ■ ESSENTIALS OF LAPAROSCOPIC SUTURING <ul style="list-style-type: none"> Basics Laparoscopic Hemostasis Laparoscopic Tissue Reapproximation and Healing Skill Development and Assessment Laparoscopic Training ■ LAPAROSCOPIC EXTRACORPOREAL KNOTTING | <ul style="list-style-type: none"> ■ LAPAROSCOPIC INTRACORPOREAL SUTURING AND KNOTTING <ul style="list-style-type: none"> Intracorporeal Suturing Difficulties Instrumentation and Skills Intracorporeal Needles Intracorporeal Sutures Other Intracorporeal Suturing Techniques Running Suturing ■ REFERENCES |
|---|---|

Suturing and knot tying in the closed confines of the peritoneum or retroperitoneum take mastery of laparoscopic dexterity to its maximum extent and clearly separates those with experience from the novice.

Laparoscopic training is evolving with the advent of sophisticated, high-end computer simulation equipment and these tools are just beginning to make inroads at academic centers.

INTRODUCTION

Laparoscopic suturing has been previously regarded as the “master technique” in endoscopic surgery. Suturing and knot tying in the closed confines of the peritoneum or retroperitoneum take mastery of laparoscopic dexterity to its maximum extent and clearly separates those with experience from the novice.

But as time stands still for no man, technology and the advancements of instruments and, particularly, robot-assisted technologies are beginning to level the playing field in modern laparoscopic centers. In the past, we could have written solely about laparoscopic suturing instruments, techniques of extra- or intracorporeal suturing and knotting, and the various nuances of suture materials and needles that augment laparoscopic techniques. Some mention of skill acquisition has always been necessary as well. This no longer suffices, however, as advanced laparoscopic urologic reconstructive procedures are proliferating rapidly with fully intracorporeal sutures and knotting techniques.

It is now imperative to adequately cover methods of suturing skill acquisition. Some of the most intriguing basic research in surgery currently centers around the investigation of surgical skill acquisition, evaluating whether surgical skills can be learned better by some individuals versus others and the more adept individuals selected for training programs, or if all surgeons are potentially capable of obtaining a minimum degree of required competency. There is a growing base of knowledge regarding psychomotor skills, of which laparoscopic suturing is still considered the cornerstone.

Laparoscopic training is evolving with the advent of sophisticated, high-end computer simulation equipment and these tools are just beginning to make inroads at academic centers.

The potential magnitude of these questions will now be emphasized in this discussion on laparoscopic suturing. The need to measure and quantify laparoscopic skills has never been so acute. In this era of open public scrutiny, we must self-question our own methods. Competence in newly trained surgeons typically involves testing and attestation by his/her peers and mentors. Although laparoscopic skills do not readily correlate with performance of the open surgical counterpart, detailed investigations have shown promising results in our ability to standardize training programs. Also, surgery itself has a very lofty target to likewise mentor in regard to competency, similar to the aviation industry. Commercial airline pilots must have a first class medical certificate every six months, must check out with a flight simulator at least once a year, and submit to random tests for substance abuse. In addition, they have demonstrated a well-known loss of cognitive ability with age and, therefore, it is required that all commercial airline pilots retire at the age of 60.

The fourth or current phase of urologic laparoscopy is the re-emergence of more complex laparoscopic urologic procedures. Technology is the driving force behind this re-emergence and possibly represents the inherent appeal of minimally invasive surgery to patients.

Patients who are given an option of a less-invasive alternative will in many instances opt for it, regardless of sufficient evidence to support that decision.

There is growing basic scientific evidence that the patients are really benefiting from being less cut upon. The nay-saying philosophy of "why work through a keyhole when you can just walk through the door" is being eroded.

"Thou shouldst draw together for him his gash with stitching," quotes the Edwin Smith surgical papyrus. Suturing has existed since prehistorical times.

Sakti Das quipped recently that laparoscopic urology has passed through four phases of progress. First was the phase of initial exposure where diagnostic laparoscopy was used to identify undescended testes. Second was the phase of initial exploration heralded by Ralph Clayman's first laparoscopic nephrectomy. The third phase was the decline in laparoscopic urologic surgery, thought by many to be secondary to limited benefits of certain "high volume" procedures such as pelvic lymph node dissection and varicocelectomy.

The fourth or current phase of urologic laparoscopy is the re-emergence of more complex laparoscopic urologic procedures (1). Technology is the driving force behind this re-emergence and possibly represents the inherent appeal of minimally invasive surgery to patients (2).

Proceeding with advances in laparoscopic urologic reconstructive techniques, the technology is rapidly progressing, especially in surgical robotics. One must fight the tendency to view such series with skepticism. However, the exact opposite extreme is, likewise, not necessarily true. Technologic surgery in its infancy arouses justifiable concerns, but some simple facts remain. Patients who are given an option of a less-invasive alternative will in many instances opt for it, regardless of sufficient evidence to support that decision.

Next is the continual availability of newer technologies (i.e., telerobotic surgical systems) that potentially can make even the most arduous reconstructive techniques widely available. Third is the fact that a new generation of surgeons who have been exposed to these technologies and the laparoscopic environment for their entire careers is now available. There are now fourth-year residents at epicenter programs of advanced technologic laparoscopic teaching who have never seen an open radical prostatectomy. At other programs, there are residents who have seen virtually no open renal surgery. It is little wonder that this field is exploding.

There is growing basic scientific evidence that patients are really benefiting from being less cut upon. The nay-saying philosophy of "why work through a keyhole when you can just walk through the door" is being eroded.

There are an increasing number of studies indicating that minimally invasive laparoscopic surgeries cause less catecholamine response, less catabolic insult, and fewer intra-abdominal adhesions than open surgery. There are real reasons that this type of surgery will continue to advance and expand. With the advent of high-end, computer-enhanced robot-sutured reconstructions, it is seriously being questioned whether endoscopic sutured repairs may actually be better than their open counterparts with fewer long-term complications. Time will tell.

LAPAROSCOPIC SUTURING TIME LINE

"Thou shouldst draw together for him his gash with stitching," quotes the Edwin Smith surgical papyrus. Suturing has existed since prehistorical times.

Ancient suture materials included flax, hair, linen, pig bristles, grasses, cotton, silk, and gut from animals. Ant mandibles were used as needles to draw the sutures through wounds. By the 18th century, wire had begun to be used in holding together tissues. Currently, in the United States, the *U.S. Pharmacopeia* sets the standards that are used by suture manufacturers. Each needle has a point, a body, and a swage (the connection of the suture to the needle). Sutures themselves can be absorbable (most commonly used in the genitourinary tract), nonabsorbable, monofilament, or braided (3).

The early history of laparoscopic surgery is dominated by the diagnostic endeavors of those interested in hepatobiliary and gynecologic pathology. The instruments and procedures were necessarily limited. With the advent of more complex operative tasks, the gynecologists became increasingly interested in the capability of reproducing what were previously open surgical interventions as laparoscopic procedures. The need to suture was clear as long ago as 1972, when Clarke described a series of instruments and techniques applicable to gynecologic surgery (4). Extracorporeal knots and the search for methods of placing ligatures followed (5). The adaptation of an otolaryngologist's suture ligature for tonsillectomies was incorporated into the routine practices of innovative laparoscopic gynecologic surgeons (6). The Roeder knot, fashioned after an extracorporeal knot used by otolaryngologists for tonsillectomies, was probably the first of a series of extracorporeally tied knots that could be slipped tightly so as to achieve hemostasis or tissue realignment (Fig. 1). Weston described several other variations, which are derived from fishing and sailing knots (Fig. 2) (7). However, all of the extracorporeal knots do not improve the endoscopic surgeon's ability to place sutures or perform an



FIGURE 1 ■ Roeder loop knot.

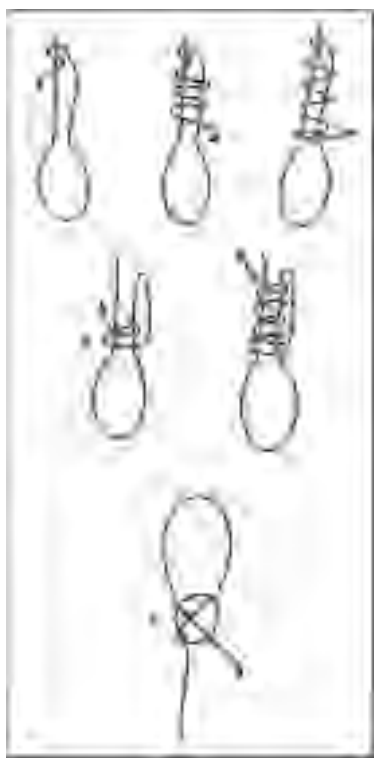


FIGURE 2 ■ Other types of extracorporeally tied slipknot configurations: (A) Roeder, (B) Duncan, (C) jamming loop knot.

Advancing technology, especially tele-robotic surgical systems are now poised to further diffuse these complex laparoscopic reconstructive methods into widespread application.

Laparoscopic urologic surgery is accomplishing the same fundamental operation as would an open incision, except with electronic imaging and small, fixed portals of access to the closed environment. The laparoscopic environment makes suturing and knotting a most difficult task.

entire anastomosis intracorporeally. Initially, following the general surgical adaptation to the laparoscopic cholecystectomy, urological and other advanced laparoscopic procedures associated with reconstruction were attempted. There were no specifically designed intracorporeal suturing instruments. The problem of making instruments designed to both gently reapproximate tissues and firmly grasp laparoscopic needles has been a difficult manufacturing goal. Such instruments are allowing endoscopic surgeons to rapidly reproduce even the most arduous urologic reconstructive procedures.

In the early 1990s, urologists at centers committed to advancing laparoscopic procedures persisted despite the “national decline” in urologic laparoscopy. Scheussler and Raboy pioneered reconstructive work on pyeloplasty and vesicourethral anastomoses, which laid the foundation for others to methodically begin investigations to improve instruments and methods. In 1991, our laboratories at University of California Davis began to systematically reevaluate all aspects of laparoscopic suturing, including needle design, suture types, suture colors, suturing techniques, knotting techniques, and instrument design. By 1993, we published the outcomes of some of these investigations in laparoscopic radical prostatectomy in a canine model (8). Rassweiler and coworkers have further augmented our knowledge of intracorporeal suturing and knotting, and continued to stress the need for “skill” development (9). Szabo and coworkers from the University of California San Francisco, began to develop instruments and methods of training endoscopic suturing. Their intent was to promote a wide range of endoscopic procedures. By the middle and late 1990s, instrument manufacturers were becoming increasingly aware that suturing instruments, in particular, needed to be designed to overcome the barriers limiting laparoscopic reconstructive surgery (10–14). Studies investigating the ergonomics of instruments and their effect on surgical performance were increasingly being published. Table height was evaluated and was shown to influence both the dexterity and efficiency of suturing (15). Finally, the methods themselves by which a surgeon learns have come under scientific scrutiny. How surgeons learn skills and how competence is measured has fostered many recent investigations of laparoscopic suturing. Perhaps some of the most exciting areas in all of surgical research currently are focusing upon methods of surgical skill acquisition (16).

Clinical series with advanced reconstructions include Kavoussi’s pyeloplasty and Guillonnet and Vallencein’s work on radical prostatectomy with sutured vesicourethral anastomosis. These techniques have had rapid proliferation in the urologic community, with a large number of secondary centers beginning to report on their own respective results. No longer are advanced laparoscopic techniques within the sole domain of the endourologists: urologic oncologists are rightly reclaiming some of these techniques as their own and fostering further clinical applications (17).

Advancing technology, especially tele-robotic surgical systems are now poised to further diffuse these complex laparoscopic reconstructive methods into widespread application (18).

In a recent review of the past decade’s experience with laparoscopic surgical procedures from a single “cutting edge” institution, Costi et al. have noted that the quality of laparoscopic surgery has improved. They reviewed 3022 consecutive patients undergoing 99 different laparoscopic procedures at the Institut Mutualiste Montsouris in Paris over the past decade. A complex database included the types of laparoscopic procedures, conversion of access, duration of the surgery, complications, further hospitalizations and reoperations, and duration of the hospital stay. General trends confirm more difficult laparoscopic surgery performed in the latter half of the decade and fewer easier procedures. In addition, evolution of the surgery itself was demonstrated by the development of new procedures. All of this was noted without a significant increase in the number of complications (19).

ESSENTIALS OF LAPAROSCOPIC SUTURING

Basics

Surgical knot tying is one of the first skills every medical student delights in mastering. One- and two-handed throws are next developed throughout the surgical residency for controlling hemorrhage or reapproximating tissues. Typically, surgical application of stapling devices follows mastery of basic suturing skills.

Laparoscopic urologic surgery is accomplishing the same fundamental operation as would an open incision, except with electronic imaging and small, fixed portals of access to the closed environment. The laparoscopic environment makes suturing and knotting a most difficult task (8,20).

Hemostasis in the closed environment imposed by minimal access surgery is one obstacle blocking progression to more complex intracorporeal techniques. The ability to maintain a clear surgical field allows complex tasks such as suturing to be performed.

It is for this reason that urologic reconstructive surgeries were, initially, only sporadically reported, and relied upon automated stapling technologies or short cuts with such instruments as the EndoStitchTM^a. Now large series typically utilize fully intracorporeal suturing and knotting strategies.

It is doubtful that a urologist would perform any of the operations we do if told from the outset that suturing or knot tying could not be accomplished. It has been stated that laparoscopic urologic reconstruction can only be facilitated if there are developed stapling devices that can rapidly reapproximate tissue margins. These statements are made despite our continuing experience with metallic staples and the accompanying litany of complications when these are used within the genitourinary tract (21,22). Laparoscopic suturing is being performed throughout the world now for virtually every urologic reconstructive procedure. This review section will delve into the details of this most difficult of laparoscopic tasks. All aspects that have an impact upon suturing in this environment will be discussed. The focus will undoubtedly reflect the author's bias, centering on intracorporeal, two-handed, highly choreographed methods. In addition, detailed review of the literature of the most recent trends, especially in running suturing will be reviewed. Also the realm of robot-assisted reconstructions will also be considered.

Laparoscopic Hemostasis

Hemostasis in the closed environment imposed by minimal access surgery is one obstacle blocking progression to more complex intracorporeal techniques. The ability to maintain a clear surgical field allows complex tasks such as suturing to be performed (23).

Some of the instruments discussed in this chapter are essential components to the surgeon's hemostatic armamentaria. There are five basic modalities at the surgeon's disposal for the augmentation of local hemostasis (Table 1). These are in addition to the methods of systemically altering the physiologic clotting parameters that might facilitate hemostasis.

Vascular pedicles have been safely ligated and divided by autostaplers for two decades (24,25). The concern for arteriovenous fistula development is certainly worth consideration, especially if both structures are taken en bloc (26). The vascular autostapling devices are theoretically designed to separate the artery and the vein prior to fixing into the staple delivery mode. The laparoscopic autostaplers have little clinical data yet to support their widespread applicability. Laboratory studies indicate that it is crucial to anticipate the trajectory necessary for delivering the 12 mm device to the targeted pedicle vasculature. The wrong approach results in untoward tension on the vessels during the engagement process. During transperitoneal laparoscopic nephrectomies, anterior axillary line portals both cranially or caudad to the laparoscope portal were effective to autostaple the renal artery and vein (27). Clip application during pedicle dissection has been addressed in the general surgical literature (28,29).

There are proponents for loop ligation and for titanium clipping. Urologically, the laparoscopic nephrectomy animal model indicated that clips were associated with more blood loss than autostapling techniques (31).

One investigation of the two major manufacturers of laparoscopic clip applicators studied the pressures necessary to dislodge each type of clip in vitro and in vivo (2). In detailed measurements on both axial and horizontal displacement, the Ethicon clips held more effectively than the U.S. Surgical clips. Both types had an unusually high rate of distractibility during the in vivo studies (33). A second study quantifying the force necessary to dislodge the newer generation of U.S. Surgical clips, EndoClip II, found them to be much more difficult to dislodge (34). Each study was funded by the manufacturer whose clip was thought to be better, so conclusions must be weighed carefully. The surgeon should be aware that these clips can become dislodged during the course of subsequent dissection if either radial or horizontal traction is applied near or at the clip. Metallic clips, and automated staplers have been described to secure the renal pedicle during laparoscopic nephrectomy and nephroureterectomy (26). On comparing these two modalities to open suture ligation of the renal pedicle in a porcine animal model, all three methods were found to be equally efficacious in preventing arterial leakage at physiological pressures. At superphysiologic pressures (average 1364 mmHg), five of six pigs had leakage from renal arteries secured with an EndoGIA 30TM (26). This multifire vascular stapler cuts between two triple-staggered rows of 2.5-mm staples. Application of three 9-mm titanium clips and suture ligation with a 2-0 silk stitch as well as a 0-silk free tie prevented leakage even at renal artery burst pressures (average, 1821 mmHg). Moran similarly found renal artery branch vessel ligation with three clips transversely placed in opposing directions and linear stapling to be equally

TABLE 1 ■ Methods of Laparoscopic Hemostasis Excluding Augmenting Peripheral Clotting Parameters

Mechanical
Pressure
Clamping
Thermal
Radiofrequency electrocautery
Monopolar
Bipolar
Endothermal
Argon beam coagulator
Lasers
Cryoprobes
Radiofrequency energy
Microwave energy
Chemical
Fibrin glue, calcium impregnated swabs, Endo-Avitene [®]
Suture/ligation
Stapling/clipping

There are proponents for loop ligation and for titanium clipping. Urologically, the laparoscopic nephrectomy animal model indicated that clips were associated with more blood loss than autostapling techniques.

^aU.S. Surgical Corp., Norwalk, CT.

Current practice recommendations are to use 9-mm titanium clips to secure renal vessels. A total of five clips, three placed proximally and two on the specimen side, placed transversely in opposing directions prior to vessel division is recommended.

The ability of the laparoscopic surgeon to reconstruct the genitourinary tract is fundamentally the same in the closed versus the open abdomen.

TABLE 2 ■ The Five Methods of Tissue Reapproximation

Suturing
Stapling
Crimping
Thermal welding (laser)
Gluing

Note: Each can be applied alone or in combination with the others.

Anastomosis and complex enteric-uroepithelial composite appositions are the rule for urologic reconstruction. A number of synthetic, autograft, and xenograft materials have been sought to further diminish the trauma of urologic reconstruction.

efficacious in a porcine animal model (27). En masse occlusion of the renal pedicle without separating the artery and vein, using a 12 mm vascular stapler has also been examined in animals. One of three animals followed for six months demonstrated an arteriovenous fistula on aortography (26). The true risk of arteriovenous fistula formation from en masse renal pedicle ligation may be even higher given previous studies documenting their formation 5 months to 40 years after surgery (32–34).

Current practice recommendations are to use 9-mm titanium clips to secure renal vessels. A total of five clips, three placed proximally and two on the specimen side, placed transversely in opposing directions prior to vessel division is recommended.

Finally, a case where a partial nephrectomy was performed utilizing a linear cutting stapler has been described (35). Despite the widespread application of clipping and stapling technologies, there still exists a role for the use of suture in the management of the vascular pedicles during laparoscopic surgery. The most tried and true method of hemostasis remains the surgical ligature; it is cost effective and almost always readily available.

Laparoscopic Tissue Reapproximation and Healing

The ability of the laparoscopic surgeon to reconstruct the genitourinary tract is fundamentally the same in the closed versus the open abdomen.

The five techniques available for tissue reapproximation are listed in Table 2. More than one modality can be combined as in Dr. Avant's end-to-end anastomotic device and tissue laser welding techniques (36). The surgical literature is replete with arguments for and against suturing versus stapling for gastrointestinal reconstruction (37–40). Much research has been fostered into the mechanisms of tissue healing following various reconstruction techniques (38). Suffice it to say that the integrity of the intrinsic blood supply is paramount to the ability of mucosa-to-mucosa sealing (38).

Anastomosis and complex enteric-uroepithelial composite appositions are the rule for urologic reconstruction. A number of synthetic, autograft, and xenograft materials have been sought to further diminish the trauma of urologic reconstruction (41).

Methods to reapproximate these and native bowel segments to the bladder laparoscopically are being investigated. Stapled and sutured bladder resections and closures have been described (42–45). Bladder diverticula have been removed and partial cystectomies with and without nephroureterectomy have been described (Fig. 42) (46–48). Both clinical study and animal work on the use of metallic autostapling instruments suggest that this technique is successful (49). Delayed complications, specifically incrustation on the foreign body nidus, have not been observed to date. This probably reflects the investigator's careful apposition methods, trying to keep the staple line from direct contact with the urine. Upper tract reconstructions have also been reported. Dismembered pyeloplasties (49), anterior pyelocaliceal diverticulectomy (Fig. 40) with omental patch (50), and partial nephrectomies (51,52) have all been performed. The reconstructions to date have been hampered by constraints of limited instrument technology, lack of stereoscopic imaging, and closed, fixed, operative access to the urologic areas of interest, but the tide is changing. The numbers of diverse, sutured reconstructions have been increasingly reported as would be expected once mastery of this environment becomes coupled with technologies that facilitate rather than hinder progress.

Skill Development and Assessment

The field of laparoscopic urologic surgery has experienced a period of rapid regrowth in the past four years (1). Despite the initial skepticism that should generally be expected by such technologically demanding surgical procedures, this resurgence of interest has made popular demands upon training courses at the national meetings, local academic centers, and at international courses. The urologist must initially have an interest in laparoscopic surgery. All the nuances associated with instrumentation are significant. If one is not exposed early to laparoscopic instrumentation, the breadth of information necessary can seem staggering. Once the instrumentation has been mastered, the physiologic consequences of operating on patients must next be addressed. Safe utilization of electronic, high-speed insufflators and specific problems associated with pneumoperitoneum must be always understood during these cases. In addition to all this background material, the surgeon must also become adept at utilizing complex instruments in the laparoscopic environment. The laparoscopic environment consists of limited, fixed portals of access, longer than normal surgical instruments, and angles of access that at times must cross over one another to work within a brightly illuminated but small focal area within a live patient. Also there is complete reliance on the electronic image. That is to say, the movements within the operative field are within the surgeon's control, but there are activities often occurring outside of the surgeon's

view, such as retraction. Finally, add to this a lack of “true” stereotactic, three-dimensional vision and little ability to utilize the sense of touch (in the laparoscopic environment, the surgeon cannot palpate an organ or feel for the pulsations of a nearby artery) and you have summed up the potential limitations of working laparoscopically. But there are advantages as well or dedicated laparoscopic urologic centers would not have evolved. The brightly illuminated, magnified surgical field is an enticing environment to perform surgery, rather akin to microsurgery. The precision capable in such an environment is unparalleled. In addition, following the greatest traditions in urology, the technology fostered by laparoscopic surgery is by itself attractive.

Research currently focuses upon methods of learning, measuring, teaching, and modifying the mental and motor abilities to accomplish complex laparoscopic surgery (53). This is one of the most exciting areas of research in all of surgery currently. How do surgeons learn? What makes one person recognize pathways to practical motor problems quickly whereas others need to be shown? Should we be able to pick those potential urologic residents who will be able to master complex laparoscopic procedures by testing certain aptitudes? Are all urologic surgeons capable of adapting to the laparoscopic environment and mastering the techniques necessary to safely apply these in their practice? What skills are essential and can they be modeled and practiced to increase proficiency? These are some of the basic questions and clinical research currently being investigated on psychomotor skills necessary to perform complex laparoscopic surgery.

Psychomotor Skills

Surgical education to date has relied upon the formal apprenticeship model exemplified by the doctrine, “see one, do one, teach one” (54). Laparoscopic surgery has been defined by degrees of difficulty, with increasingly complex procedures resulting in “steep learning curves.” These curves are usually, but not always, exemplified by the amount of time taken to accomplish the laparoscopic procedure, often comparing this to the open surgical equivalent (55). In addition, there are relatively few centers where advanced techniques are being used with regularity. On top of this, hospitals and regulatory agencies (particularly in the United States) are struggling with credentialing issues that surround “surgical proficiency.” It is no wonder that the number of laparoscopic, urologic, intracorporeal-sutured reconstructions have not proliferated to any great extent. But the envelope continually expands and small groups of investigators such as Clayman, Janeschek, Kavoussi, Gill, Gilloneou, Rassweiler, and others push us into rethinking the possibilities of this technology.

Paralleling the growing amount of research on laparoscopic suturing are investigations in the acquisition and development of psychomotor skills and skill evaluation. Derossis et al. from the McGill University evaluated 42 subjects to better understand how structured, objectively measured tasks could be utilized to improve performance during laparoscopic surgery. They demonstrated that the ability to develop suturing skills correlated with overall improvement in a wide variety of laparoscopic activities (56). Hanna et al. at the University of Dundee have investigated the differing abilities of right- and left-handed individuals to develop psychomotor skills for complex endoscopic manipulations. Utilizing a complex in vitro system, 10 right-handed and 10 left-handed individuals were evaluated for psychomotor aptitude, using both the dominant and nondominant hands.

They demonstrated that the right-handed surgeons performed fewer errors and exhibited better first-time accuracy than the left-handed individuals. In addition, accuracy definitely favored the dominant hand in both groups (57).

This same center reported upon the improvement of skill performance by optical axis manipulation. They noted that even small decreases in the viewing angle were attended by significant degradation in performance (58). Others have demonstrated this same phenomenon, such as Holden’s group from The Hadassah Hebrew University Medical Center. They demonstrated that changes in the either the camera’s position or the surgeon’s position profoundly disrupted the surgeon’s performance (59).

However, when the surgeon and camera positions were altered together, these detrimental effects could be altered and skilled performance could be regained. More specific to our topic at hand, endoscopic skills have been extensively evaluated by our group and others. Hanna again from Dundee evaluated the influence of direction of view, target-to-endoscope distance, and manipulation angles upon the efficiency of intracorporeal knot tying.

These authors confirmed our observations that the closer the endoscope is to the targeted reconstruction site, the more magnified the field of view and the more difficult will be the performance of the suturing task.

Hanna et al. demonstrated that the right-handed surgeons performed fewer errors and exhibited better first-time accuracy than the left-handed individuals. In addition, accuracy definitely favored the dominant hand in both groups.

Several authors confirmed our observations that the closer the endoscope is to the targeted reconstruction site, the more magnified the field of view and the more difficult will be the performance of the suturing task.

They specifically evaluated distances of 50, 75, 100, 125, and 150 mm from the targeted task. The 50-mm distance uniformly resulted in the longest times. In addition, the 60° manipulation angle had the shortest execution times compared to 30° and 90°. Finally, some recent investigations have sought how to minimize these problems utilizing a 90° laparoscope to achieve movement parallax. In this investigation, the authors report upon the theoretical advantages of manipulating the endoscopic image to the surgeon's advantage, essentially recapitulating all of the problems alluded to previously. By synchronizing a flexible laparoscope to the movement of a surgeon's head, movement parallax or compensated visual-enhanced movement is achieved (60). They note that a head-controlled flexible 90° laparoscope improves the surgeon's depth perception and hand-eye coordination. This has not been significantly reported for expensive three-dimensional imaging systems (61,62).

The primary problem with these types of investigations is that small study groups do not reflect the community of surgeons who will be attempting these procedures. In addition, the ability of a surgeon to perform a given task is a complex issue involving adaptive capacity, traits, and aptitudes that a person brings to any given situation. This is quite different from the skill of a surgeon. Skill is referred to when specific combinations of techniques are deftly employed to accomplish a given task (63). Numerous investigators have begun to focus the attention of their investigations on how surgical residents develop laparoscopic skills and on how best to foster this skill transfer? Reznick, at the University of Toronto, has written extensively regarding this issue. He summarizes the crucial nature of these research endeavors by stating that the teaching of technical skills is one of the most important tasks of surgical educators. He concludes by calling for adherence to simple principles: treat pupils as adult learners, set specific objectives, realize that operative skills are multidimensional, be there to observe, be patient, provide feedback, be positive, and seriously structure the assessment process (64). Many struggle with the notion that there are individuals who have an aptitude for performing innately difficult laparoscopic maneuvers deftly. This has found little documented validity and many cling to the notion that all interested surgeons who seek to be trained should avail themselves of advanced courses. In practice, however, there is increasing pressure on our specialty societies, hospitals, and governmental watchdogs that more scrutiny is warranted (65). Macmillan, also from the Dundee group, recently reported on a method of identifying individuals who appear to have an innate aptitude for performing complex dexterous laparoscopic tasks. They propose that if larger studies confirm these initial observations, selection of candidates for advanced laparoscopic training might be possible (66).

Laparoscopic Training

Theory

Surgical education has struggled with the methods to objectively scrutinize surgical performance of house staff for many years. The methods of formal education have had some limited application, but as the complexity of modern laparoscopic surgery has manifested itself, departments across the country and around the world have begun to evaluate how to assess competency, skill development, teaching methodologies, and communication skills (67). The complexity of this task has resulted in a surprising number of papers in the surgical literature on trends in education. Extensive lists are beginning to be generated on measurable psychomotor skills, but the ability of young surgeons to communicate is significantly important, especially for advanced laparoscopic procedures. Important aspects that deserve attention are psychomotor skills, cognitive decision making, incorporation of video-enhanced motor coordination, two-handed surgical maneuvering, and rhetorical ability. Students of advanced laparoscopic surgery are themselves independent learners. There are various approaches each will take to gaining laparoscopic skills. A whole host of research endeavors have begun to focus on the surgeon's ability to learn (68). At least four factors can be attributed to learning orientation: concrete experiences, abstract conceptualization, active experimentation, and reflective observation. D.A. Kolb is widely quoted in research regarding learning orientation. It is these orientations that help research investigators study learning. They identify four dominant learning styles: convergence, divergence, assimilation, and accommodation. The convergence learner stresses abstract conceptualization and active experimentation. These learners stress hypothetical-deductive reasoning to analyze their problems. Divergers rely upon contrasting orientations of concrete experience and reflective observation. Their information processing can thus be protracted and often do not feel impelled to act. Assimilators tend to use inductive

Kolb's learning styles have been used successfully to evaluate medical students and evaluate the educational environment for medical learning.

development of concepts such as unifying theories to explain their observations. They tend to focus on the soundness or fitness of ideas and thus are less concerned about the practical value of observations. Last are the accommodators who emphasize orientations of active experimentation and concrete experience (69).

Kolb's learning styles have been used successfully to evaluate medical students and evaluate the educational environment for medical learning.

In addition, this theory has also recently been applied to third-year medical students rotating on their general surgery clerkships at the University of Nebraska. They identified that the majority of the of third year students were convergers (45%), assimilators (26%), accommodators (21%), and divergers (8%). They were primarily interested in how best to evaluate the performance of the students and not to predict methods to better teach psychomotor skills. But applications of the modern learning theory are evident. They stated that clinical performance requires additional cognitive skills and abilities that need to be further quantified (69).

The ability to measure and impart laparoscopic psychomotor skills is another area undergoing intense scrutiny. The ability to ascertain those individuals who have innate ability should also be possible.

Factors recognized as crucial in laparoscopic surgery include muscle strength, speed, precision, dexterity, balance, spatial resolution, as well as poise and endurance. Kaufman et al. at the University of West Virginia have begun an active program focusing on three aspects of surgical education. First, can prospective surgeons be screened with regard to their psychomotor skills? Second, can the application of modern educational psychomotor concepts help in the development of advanced skills? Third, can evaluation methods of psychomotor skill proficiency adequately gauge the acquisition and performance of complex surgical tasks? Their methodology is complex, but applies a wide battery of psychomotor tests at the initiation of training, during training, and following training to better evaluate skill acquisition. Their tests include the following: McCarron assessment of neuromuscular development to measure motor function and fatigue, Purdue pegboard to assess fine motor control, Minnesota rate of manipulation test to measure speed and precision, Minnesota paper form board to measure spatial perception, haptic visual discrimination test to measure spatial perception, and California psychological inventory to measure poise, confidence, and relaxation. During preliminary evaluations, they have developed an equation that balances psychomotor ability with the acquisition of motor skill factoring in the time of training.

$$\text{Psychomotor ability} \times \text{Amount of practice} = \text{Motor skill proficiency (70)}$$

The United States Army represents another wealth of information regarding the ability to perform tasks and the ability to measure skill. Again, they have reported two major determinates for performance, length of time spent doing a given task, and aptitude. Using isoperformance curves, it is possible to explain the relationship between experience and aptitude mathematically. Now changes in the relationships can be measured and the effect of training can be calculated on isoperformance curves (71). As these studies continue, one can hope that directed methods of training will be possible for those interested in advanced laparoscopic surgery that will bring performance to a peak level and maintain it there (72–88).

Flight Simulators

The premise that the skill of the surgeons can be equated to the outcomes of the operations over time is a fundamental concept in modern surgery. Those surgeons who perform the most complex operations and have the lowest morbidity are encouraged. This concept is fundamental to other more intensively scrutinized professions as well, most notably commercial aviation. Flight simulation has a long and interesting history (89). Simulators have been attempted with surgical procedures such as laparoscopic cholecystectomy, laparoscopy-assisted vaginal hysterectomy, and laparoscopic inguinal hernia repair (Fig. 3) (73,77). But to date, they lack ability to function in the manner in which the aeronautics profession is capable. Current simulators are available in anesthesia, interventional radiology, and emergency medicine but these are far from clinical reality. Fidelity in haptic feedback has been an ongoing problem with surgical simulators. In addition, the ability of the computer to add nuances of human anatomical variability has not been achieved.

Computerized Education

The explosion in computer performance, hardware, and software has had profound effects on education, data management, communication, and entertainment. The impact

FIGURE 3 ■ Virtual reality laparoscopic reconstructive training (Karlsruhe Endoscopic Surgery Trainer).



of this modality on surgical education is just beginning to be felt (90). The “information age” has quietly crept into the surgical training programs throughout the country (91). It is no surprise to see that the house staff, familiar with computer technologies, gladly accept these methodologies. One recent study investigated the use of multimedia interactive computer programs to familiarize residents in laparoscopic skills. The comparative scales for the most effective method to familiarize and raise their knowledge regarding new laparoscopic procedures were as follows: textbook (4.7), lectures (5.1), videos (6.0), animal labs (7.3), and multimedia interactive computer programs (8.8). There are lots of problems with the more standard methods of surgical education when applied to laparoscopic surgery (91). First, with printed material such as this syllabus, there is no method of questioning the information unless those truly interested seek out references, read those, and synthesize their own opinions. Lectures provide the student with the possibility of real-time interaction through questioning and answering. The limitation of this modality is that it is entirely dependent upon the skill and knowledge of the lecturer. Couple with this the inherent problems of inhibitions in students in a large group, which can stifle potential educational interaction. Videos can be a very good reference but again, like textbooks, lack the ability to interact with questions and answers. Animal labs allow the student to experience live surgery, make mistakes, and correct them, and provide animate experience with such issues as tissue handling, bleeding, visual imaging problems, etc. These experiences are costly, limited in availability, and lack true educational values unless a skilled proctor is present continuously to provide feedback (92). Multimedia interactive computer programs can provide all of the aforementioned qualities necessary, and also provide interactive references to specific questions via “Help” commands. In addition, computer programs have been shown to increase retention of important facts and decrease the learning curves, can be scaled to individual performance abilities, are inexpensive compared to animal labs, and are mobile. The computer method of training can be self-directed, self-paced, as well as interactive. Rosser et al. at Yale University’s

Minimally Invasive Surgery group have developed a CD-ROM tutorial to aid in the transfer of cognitive knowledge thought to be essential for establishing laparoscopic skills. The tutorial was designed to provide surgeons with the knowledge base thought to be essential for acquiring basic laparoscopy skills originally designed for an intense two-day course (Yale Laparoscopic Boot Camp). The main menu consisted of eight main menus that could be taken in any sequence. They were as follows: dexterity drills, laparoscopic equipment, strategy of positioning, operating procedures, troubleshooting, clinical applications, and post-test statistical analysis. The tutorial requires almost no reading with audio prompts to a layered, regimented program with abundant illustrations and embedded videos. Using the embedded post-test and statistics package, they were able to show no difference in the post-test scores for students taking the two-day course versus the multimedia computerized tutorial (91).

Virtual Reality

Jaron Lanier introduced the term "virtual reality" in 1989, but the concept that computers would have enough power to interface with a human's sensory perceptions formed the basis of Ivan Sutherland's doctoral thesis from Massachusetts Institute of Technology in 1963. As with most things in the computer world, the first head-mounted display became a reality and a young entrepreneur, Morton Heiling, tried to sell "Sensorama," a simulated computerized motorcycle ride through a virtual city. Computational capacity has been the only limiting factor in the advance of these technologies. Gordon Moore, Intel Corporation's cofounder, is now best known for Moore's law, stating that a computer's power would double every 18 to 24 months. He has made this statement from observing trends for the past 35 years. In addition, the cost of that technology has almost halved in the same period of time. In other words, the supercomputer of 1990 that cost \$100,000 is today available in a \$150 Nintendo system. Randall Tobias, former vice-president of AT&T phone company is widely quoted as saying, "if we had similar progress in the automotive industry, a Lexus would cost \$2, it would travel at the speed of sound, and go 600 miles on a thimble full of gas" (93).

One of the first major advances in the development of virtual reality surgical systems came with the Visible Human Project. Sponsored by the National Library of Medicine, 1 mm cross-sectional anatomy was stored on a computer for three-dimensional reconstructive purposes. This database became the first available human subset for computer virtual reality programs (94).

Virtual reality surgery overcomes several of the limitations of education in an operating room. First, the teaching session in the operating room cannot always be well designed or orchestrated. The prime focus remains upon the patient. The scheduled case may not be well suited for the resident at that given time. The corollary to this is that the technical nuances of the particular case may be above or below the skills of the student, making the educational potential limiting. The execution of the surgical procedure may not be altered to satisfy an educational goal. Likewise, the dissection and exposure cannot always proceed in a fashion best structured for educational potential. Finally, the steps of the surgical procedure cannot be repeated. Errors that occur can be corrected, but they cannot be repeated (95). All of these shortcomings are nonexistent in the virtual operating room. In addition, there is more evidence that learning complex tasks is significantly impaired by increasing the amount of stress in the environment (96). An operating room is inherently filled with stress. Factors contributing to the high stress environment of the operating room include time constraints, technical difficulties, concern for the patient, equipment failures, interpersonal issues, handling telephone calls, and lack of rest. Investigators now are sure that the greatest levels of learning and performance occur in environments with moderate stress. The psychomotor tasks are learned in three ways, all facilitated in the virtual environment. In the cognitive phase of learning, the student attains a degree of understanding of the task. The second phase is the associative process. During the associative phase, the student practices the task and compares performance with an expert. The differences are considered errors and mastery is achieved by minimizing these errors. Finally comes the autonomous phase, where skill is performed without cognitive awareness (97-99).

Telementoring and Remote Surgery

Several factors are associated with altering the rules of surgical education. The hospital inpatient population is becoming more complicated and surgical therapy is potentially becoming more technologically complex. Insurance payers and, in particular, government watchdogs are requiring more supervision and less autonomy of the residents. The residents are being asked to learn the same or more material in fewer working

hours. Practicing urologists are facing the same phenomena, which is increasingly taxing the endurance to stay current. This is the scenario that is poised for the combinations of all of the just discussed technologies to merge with telecommunications and allow guided preceptorships remotely. If you throw in robotic surgery, then telementoring is not even necessary. The expert at one location can perform the surgery at another without physically being present (100).

Telementoring has already been performed for multiple surgeries as well as urologic laparoscopic cases. Dr. Kavoussi's group at Johns Hopkins has gained significant notoriety for this pioneering effort. In their initial studies, the surgeon mentor was located in a control room more than 1000 feet from the operating room. Fourteen advanced and nine basic laparoscopic procedures were performed. Telementoring was accomplished using real-time computer video images, two-way audio communication links, and a robotic arm to control the videoendoscope. Success was achieved in 22/23 cases, without increased operative times or complications. They then extended their investigations and distances between the Johns Hopkins Bayview Medical Center and the Johns Hopkins Hospital (distance = 3.5 miles) for 27 more telementoring laparoscopic procedures utilizing public phone lines. Finally, they have extended their novel surgical instruction capabilities to the international arena with one case in Innsbruck, Austria, and two cases in Bangkok, Thailand (101). Others have reported upon the technology necessary for successful telementoring. The U.S. Navy recently studied the feasibility of laparoscopic hernia repairs aboard the USS Abraham Lincoln while cruising the Pacific Ocean. Telementoring was possible from remote locations in Maryland and California (102). In a recent research investigation, Broderick et al. at the Virginia Commonwealth University reported that decreasing transmission bandwidth does not significantly affect laparoscopic image clarity or color fidelity as long as the laparoscopes are positioned and maintained at their optimal working distance (103).

Now for the ultimate in technophilia, a recent Internet study on the attitudes and practices of general surgeons was performed. Over two months, 459 surgeons were enrolled in a study on the World Wide Web. Those polled stated that the Internet was used to expand their knowledge of surgery in 74.5%, more than half of them stated that they favored more advances in technology such as robotics in the operating room (53%), and most (78%) favored the technology necessary for telementoring to learn new laparoscopic procedures (104).

Technology and advances in urologic surgery are being paralleled by research interests in the methods of acquiring skills and teaching. There is no doubt that computer-assisted methods of education will proliferate and that the classic methods for keeping current will be transitioned into a high-tech data stream of information. Telementoring is already a reality at those institutions that have been on the forefront of laparoscopic surgery. It is only a matter of time when an "off the shelf" package will be added to an operating room in your locale for furthering the training of interested surgeons. There are centers cropping up around the globe interested in expanding the envelope of technology on laparoscopic surgical education. Most of these centers currently come with a high price tag. But as seen so clearly with computerized systems, this too should become an integral part of surgical education at any institution interested in less invasive surgical technology. One such center (Center for Minimal Access Surgery in London, Ontario) has recently published its first paper on the establishment of a "state-of-the-art" multidisciplinary technological education and research center for minimally invasive surgical techniques. The technologies available for skill acquisition include high-fidelity Minimal Access trainers, Body Form Simulators, a virtual reality system, a computerized laparoscopic skills workstation, and a multimedia library of laparoscopic procedures. In addition, the Center for Minimal Access Surgery has started a videoconferencing system to be integrated with its various components to enhance education via telementoring (105). Advanced endoscopic suturing and knotting should be easily mastered in such environments.

LAPAROSCOPIC EXTRACORPOREAL KNOTTING

Extracorporeal knotting techniques have evolved for a diverse variety of laparoscopic purposes. First, they can be utilized to secure hemostasis of the anterior abdominal wall (106). Best described as a "sling suture" technique, the utility in stopping active hemorrhage from trocar sites has been demonstrated by several authors. The technique of



FIGURE 4 ■ EndoClose™ needle carrier can be used to sling or lift structures out of the field of view, close fascial defects, or stop bleeding from anterior abdominal wall vessels. *Source:* U.S. Surgical Corp., Norwalk, CT.

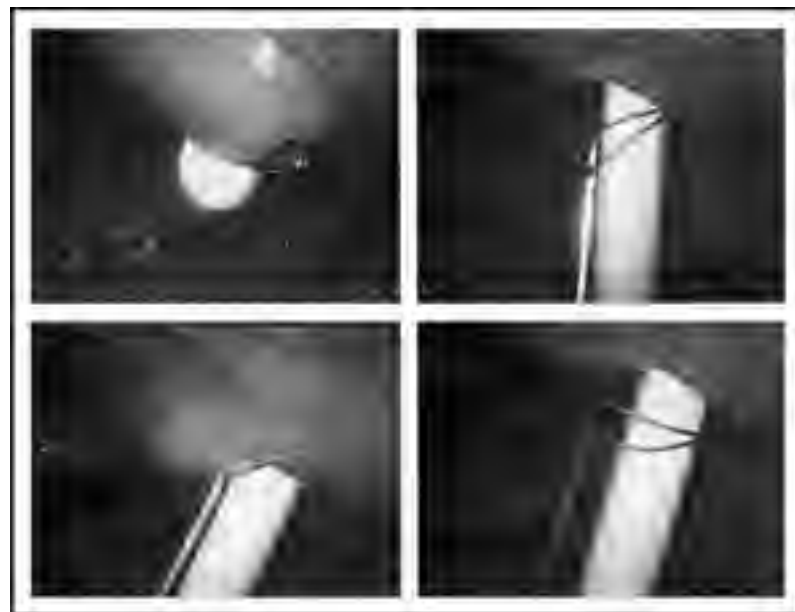
sling suturing extracorporeally, includes both straight and curved needles of various sizes (107). For control of anterior abdominal wall hemorrhage, a transverse ligature is necessary to encompass the area of the vessel. The first stitch should be below the vessel if the culprit is from a lower abdominal trocar injury and above if the injury is upper abdominal. The trocar should be removed only after the control of hemorrhage. Alternative maneuvers may be necessary to control trocar site bleeding, including, but not limited to, percutaneous fulguration (resectoscope), transportal placement of a Foley catheter for direct pressure application, and others. This extracorporeal knot can also facilitate intra-abdominal visualization by “slinging” obstructing structures out of the visual pathway. Nathanson and Cushierie utilized just such an extracorporeal knot as a “falciform lift,” and the same can be done with the urachus. Recently, several extracorporeal-assist mechanisms for passing these sling sutures have been marketed (Fig. 4). These instruments are primarily being marketed for use in visually-assisted fascial closures (Fig. 5).

Extracorporeal knotting has had its most common application with loop ligation techniques. A variety of loop knots are utilized and the laparoscopic surgeon can use pretied ligatures or tie one with standard sutures. Several knot configurations are also available and the surgeon can utilize fly-fishing knot variants or sailor’s knots for the same purpose (5). Clinically, the most commonly utilized loop ligation still employs the Roeder knot (108). The Roeder knot can be applied pretied as a loop ligature or can be tied after needle ligature intracorporeal placement and then synched (Fig. 6) (35,53). The only investigation on the safety of vessel occlusion reported that dry gut Roeder knots provide vascular occlusion up to 3-mm arteries (107). The other knot configurations that have also been successfully employed include the Duncan knot (with or without a half hitch), Fisherman’s clinch knot, jamming loop knot, and Weston’s configurations (Fig. 7) (67,111,112). Loop ligatures by design can incorporate any of these aforementioned slipknot modalities. Several manufacturers offer prepackaged, slipknot loop ligatures. Common features include a variable length pusher (usually 80 cm) over monofilament or braided sutures. Application of pretied slipknot loop ligatures has been simplified by disposable applicators. Chromic gut, plain gut, polydioxanone (PDS™ and PDSII™), silk, polyglactin (Vicryl™, Dexon™, or Polysorb™), and dacron (Surgidac™) are all clinically available laparoscopic suture materials.

The endoscopic loop ligation is passed backward through a reducer sleeve (3 mm) and then into the appropriate trocar (Fig. 8). The pushrod is then advanced until the loop is fully opened within the abdomen. A grasping instrument is passed through the loop and the targeted tissue is grasped. The back-end of the plastic pushrod is snapped and the rod advanced to tighten the slipknot. The synching suture is cut at least 2 cm from the knot.

Finally, extracorporeal knotting can be utilized with intracorporeal suturing when knot pushers are available (112). Various reports indicate that, with practice, these knots

FIGURE 5 ■ Visually-assisted fascial closure with through-and-through stitches. eXit™b puncture-closure device shown here. *Source:* Advanced Surgical, Princeton, NJ.



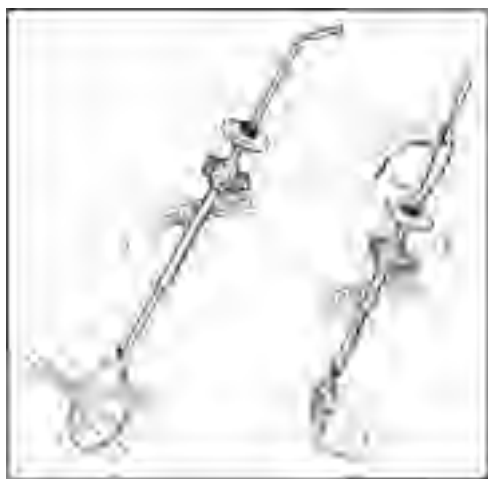


FIGURE 6 ■ Application of Roeder slipknot loops. (A) Technique of applying pretied loop ligatures. (B) Technique of tying Roeder slipknot extracorporeally. Completion of the extracorporeally tied Roeder knot.



FIGURE 7 ■ Other types of extracorporeal knots. (A) The Weston II. (B) The fisherman's clinch. The fisherman's clinch has also been utilized for throwing intracorporeal knots using straight needles or pin-vice needle drivers.

FIGURE 8 ■ Steps in successfully passing and applying endoscopic loop ligatures.

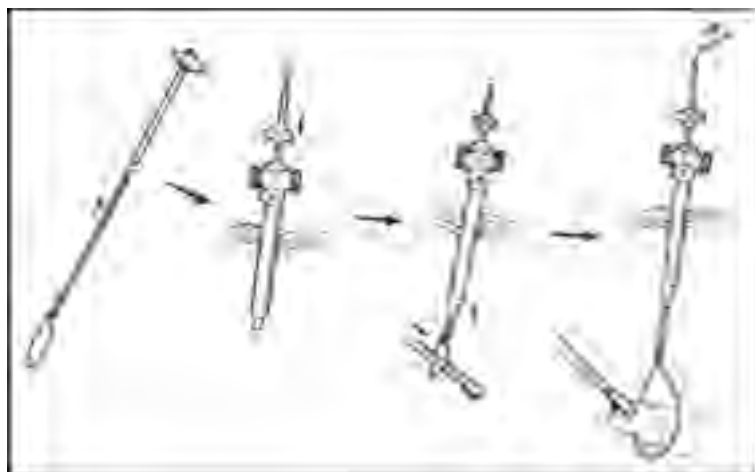


FIGURE 9 ■ Oko's operating room. Laparoscopic ligator. Allows extracorporeal knotting and nonderailing of sutures during trocar passage. Source: Courtesy of Dr. Oko and G.U. Manufacturing Co., London, U.K.

can be applied fairly quickly (less than five minutes) (109). Any available suture material can be utilized for these extracorporeal techniques, providing that adequate length is available to traverse the trocar (usually 80 cm). Various braided sutures do not slide as well as others if standard square knots are utilized, and should be avoided. Prepackaged endoscopic ligatures with variable needle configurations are available for this purpose from most manufacturers. One unique approach to this technique employs a specifically designed knotting instrument. Oko and Rosin report the ability to suture and place knots with almost any material and then adjust tension and knot position with their device (Fig. 9) (113). The same type of knotting technique was described by Puttick et al., utilizing a laparoscopic Babcock clamp (114). A multitude of manufacturers tout their knot pushers for ease of synching. The primary problem with all techniques of extracorporeal knotting includes the need to maintain long suture tails, multiple passages via trocars, no direct control of the sutures at the tissue while knots are being thrown, and the need to suture intracorporeally. Kennedy has shown that multiple extracorporeally tied knots can be sequentially thrown with the aid of a pusher, thus simplifying the reentry problems (115). Complex urinary reconstructions typically require end-to-end or layered closures, which are nearly impossible using extracorporeal techniques.

Prior to addressing intracorporeal suturing and knotting techniques, mention should be made to those who advocate clips to secure the intracorporeal suture or suture line. Although not an extracorporeal technique, the primary claims of those exploring this method of suture anchoring are avoiding the potential loosening of slipknot ties or the cumbersome multiple trocar passages required by extracorporeal knotting.

TABLE 3 ■ Barriers Limiting Rapid Mastery of Intracorporeal Suturing Skills

Environmental
Fixed access portals
Rigid access portals
Limited visual field by rigid laparoscopes
Lack of stereoscopic image
Bloodless field
Instrumentation
Skills (needle driving, suturing, knotting)
Control
Coordination
Choreography

Metallic and absorbable clips have been successfully used to secure intracorporeal sutures (116). Metallic sphere clips have likewise been devised to more securely maintain suture tension. There exists only one study evaluating the security of these differing modalities to secure a suture. Utilizing a tensiometer, distraction forces were measured following a standard three-throw knot versus titanium clips versus locking polyglactin clips versus malleable collars. No technique approximated the security of the standard three-throw knot. By doubly throwing the suture through the collar, the distraction force approached that of the knot [knot 4.9 kg (SD = 3.22) vs. doubly thrown collar 5.4 kg (SD = 3.22)] (116).

LAPAROSCOPIC INTRACORPOREAL SUTURING AND KNOTTING

Intracorporeal Suturing Difficulties

Laparoscopic urologic reconstruction continues to require intracorporeal suturing skills. Intracorporeal suturing and knotting represent the most difficult surgical techniques that the advanced laparoscopic surgeon can acquire. Reasons for the difficulty in performing intracorporeal suturing are multifactorial (Table 3). The closed operating environment represents the primary hindrance to mastering these techniques. Fixed portals of entrance limit the “approach” to the targeted suture site. The intra-abdominal viscera are rarely stationary and the ability to move a needle driver’s approach is limited by these fixed entrance portals. Specifically designed assisting instruments (Fig. 10, bottom flamingos) can manipulate nonfixed tissues for correct alignment and overcome the problem of fixed portal positioning. In addition, the camera site and the surgeon’s right and left hands also remain fixed. Adding an additional trocar is always possible, but it defeats the philosophical goal of minimal-access surgery. The camera position of choice when first attempting intracorporeal reconstructions should lie between the surgeon’s right and left hands. For maximum efficiency, the right- and left-hand portals should not be over an acute angle with each other. The optimal angle to work with is 80° to 110° and each trocar should be separated more than 8 cm at the surface skin sites to allow the maximal ability for the tips to interact. Another important factor to control in this closed, fixed environment is image stability (117). A stable image is readily obtainable by replacing the human camera assistant with a robotic arm. A wide variety of choices are available, ranging in price and complexity from simple mechanical devices to computer-controlled, servo-assisted systems (Fig. 11). These instruments allow for maximally stable images, even with close zooming with the laparoscope. An added bonus of these robotic arms is the free lateral space at the side of the operating room table allowed by the low profile of some of these assist systems.

Rigid portals are another hindrance to rapidly adapting suturing skills. Surgeons are used to suturing with fluid wrist movements that accentuate needle-driving forces, forming loops in the suture to facilitate knotting, and keeping tension on the swaged-end portion for secure running stitches. Rigid portals eliminate these finesse skills and magnify the perceived difficulties of intracorporeal suturing. Flexible trocar portals have been recently marketed (Fig. 12, Karl Storz, Tübingen, Germany) that may permit some degree of fine movement assistance currently lacking in endoscopic suturing. More appropriate and well known to microsurgeons are the utility of curved needle graspers.



FIGURE 10 ■ Szabo-Berci flamingo tissue grasper and the parrot-jawed needle driver. These represent the first set of intracorporeal instruments specifically designed to overcome many of the difficulties outlined in this chapter.



FIGURE 11 ■ Robotic arm-assisted laparoscopic surgery using AESOP system. Source: The Computer Motion Inc., Goleta, CA.

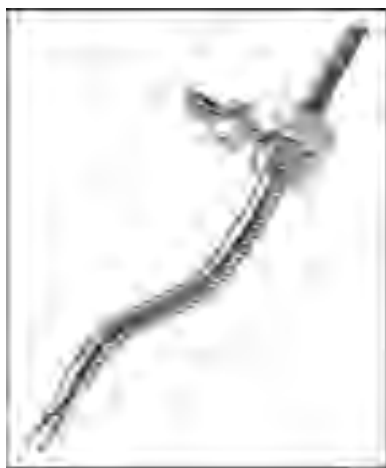

FIGURE 12 ■ Flexible trocars may allow instruments with more degrees of freedom to be passed intracorporeally to facilitate reconstructions. Source: Karl Storz, Culver CA.

Primarily employed because the curved instrument allows continuous visualization of the needle and driver's tip during all aspects of suturing in microsurgery, the curved needle driver also has advantages to overcome problems of fixed portals in intracorporeal suturing. By changing the orientation and position of the needle along the curved needle driver the same fine alignments can be achieved for entrance and exit bites during needle driving without reliance upon flexibility at the trocar site. It takes hours of practice with handling the needle under videolaparoscopic conditions to master these new skills, but mastery facilitates fluid intracorporeal suturing. Another way around fixed trocars is to have access to the region of interest with part or all of the surgeon's hand (118). Conventional suturing instruments could be utilized if requirements for pneumoperitoneum are abandoned, such as with gasless laparoscopy (119). The surgeon's hand need not be introduced at all if mechanical systems that provide the degrees of freedom necessary to overcome fixed portal insertion site limitations can be developed (120,121). In fact, an Olympus prototype needle driver with six degrees of freedom has been investigated, but remains a research tool at present.

Another limiting factor preventing rapid acquisition of endoscopic suturing skills is the limited visual field. Open surgeons take for granted the ability to lift tissues so as to allow visualization during all phases of suturing. Although the concept of atraumatic tissue handling during suturing is a fundamental skill, the tissue handling represents the key to visually controlled needle placement. The laparoscope brightly illuminates the visual field but does not allow unlimited circumferential views without repositioning or changing to a different angle. A flexible or semiflexible laparoscope would make these angled adjustments, but the degree of interaction with the surgeon would have to be such that anticipated needle path trajectories could be followed. The only current method of overcoming this problem is to have an assistant tissue grasper manipulate the targeted suture site for correct visual alignment toward the laparoscope.

Next on the list of environmental limitations to intracorporeal suturing is the lack of stereoscopic vision. This is a result of current imaging technology. Videolaparoscopic images are magnified and two dimensional. With time and practice, the feedback from both surgeons' hands and the interaction with hand-eye coordination make even the most difficult intracorporeal maneuvers possible. In a study of videolaparoscopic suturing over standard suturing, the degree of difficulty was approximated to be eight times greater. Developing a memorized systematic method of tying with both hands cooperating to minimize the movements necessary to tie can overcome this problem (Fig. 13) (8). This results in "economy of motion." The right and left hand develop orchestrated interactions very much like in microsurgery (8). Small motions result in faster, more fluid, magnified suturing skills. Of course stereoscopic videolaparoscopes could decrease the difficulty of intracorporeal suturing. Such systems are available on robot-assisted, computer-controlled surgical systems such as *da Vinci*® (Fig. 14) (122).

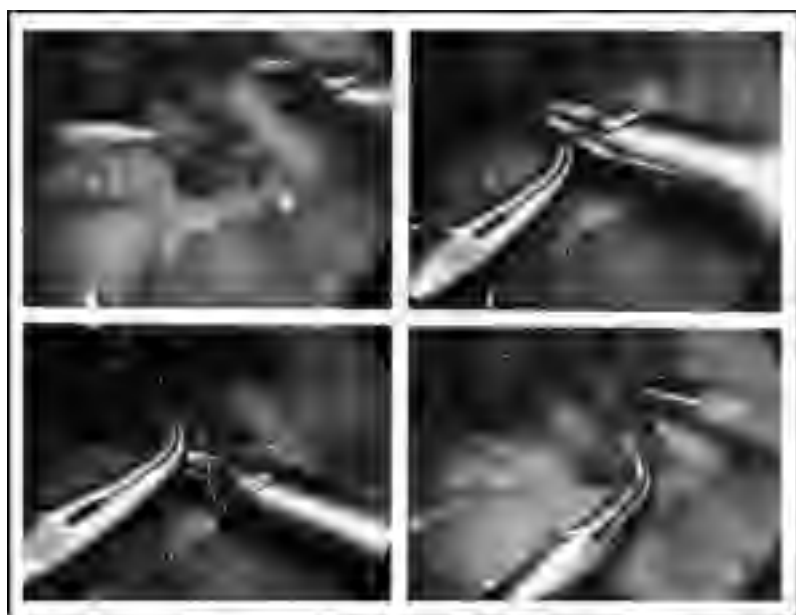

FIGURE 13 ■ Two-handed intracorporeal suturing facilitating bilateral vesicopsoas hitches.



FIGURE 14 ■ Voiding cystogram following laparoscopic radical prostatectomy and microsurgical vesicourethroplasty in a canine model.

The major anticipated drawback of these stereoscopic imaging systems is the purchase price (estimates approximate \$100,000) (122). As with any type of magnified endoscopy-assisted surgery, it is the surgeon who is highly trained and dexterous who performs flawlessly, even in difficult conditions. It may be expected, but is not proven, that the stereoscopic systems will benefit most those who have already mastered the difficulties of intracorporeal suturing. Better would be the utilization of less costly, but just as powerful, head-mounted 3-D displays. Such devices are already being utilized at nominal costs from the electronic gaming industry. High-end computerized head-mounted display systems eliminate the need for buying expensive high-definition monitors, allow the surgeon an almost unprecedented mobility, are increasingly lightweight and comfortable, and, most of all, are coming down in price. There should be no need for ceiling-mounted monitors, which often require structural reinforcement of the operating room ceiling. Head-mounted displays make each endoscopic operating room far more flexible and can be multitasked. The future imaging system would be a high-definition, lightweight, head-mounted system that is translucent and allows the surgeon to pick up "real" objects in his environment, as well as perceive the "virtual environment during the laparoscopy (123).

Finally, one last environmental limitation must be mentioned as a hindrance to intracorporeal suturing—hemorrhage. The closed environment of laparoscopic surgery imposes a formidable barrier to the maintenance of hemostasis. During intracorporeal suturing, bleeding even in small amounts can make identification of correct tissue planes an arduous or impossible task. Complex intracorporeal suturing requires a bloodless field to expedite the already difficult maneuvers mentioned previously. During the division of the viscera it is crucial to be able to achieve hemostasis without compromising the viability of the tissue to be reconstructed. In preliminary investigations, the argon beam coagulator demonstrated unique abilities for this specific purpose (Fig. 15) (23). Plasma from flowing argon gas molecules allows precise cauterization with very limited depth of penetration. The flowing gas also clears the targeted field, allowing the cautery to be more effective upon the bleeding vessels and decreases the time of thermal exposure. There are still risks of thermal necrosis from overzealous exposure to argon beam coagulators. This instrument probably has its greatest utility in its unique hemostatic effects for the reconstructive laparoscopist (124–139). Despite the potential merits and wide applicability of the argon beam coagulator, the downside should be mentioned. Argon gas is less soluble than carbon dioxide and fatal argon emboli have been reported (140,141).

Instrumentation and Skills

Closed environmental constraints aside, there are two other significant barriers limiting rapid mastery of intracorporeal suturing skills and instrumentation skills. Instrumentation initially relied upon adaptation of grasping instruments for the purpose of laparoscopic suturing. Limitations of general-purpose graspers are their inability to grasp and maintain the torque needed for driving needles through tissue. To overcome this problem, several manufacturers developed pin-vise-like needle drivers that would rapidly facilitate needle driving (Fig. 16). The torque problem was eliminated, but all the other problems discussed previously have not been addressed. The result is a perfectly good needle driver, but not a good intracorporeal suturing instrument.

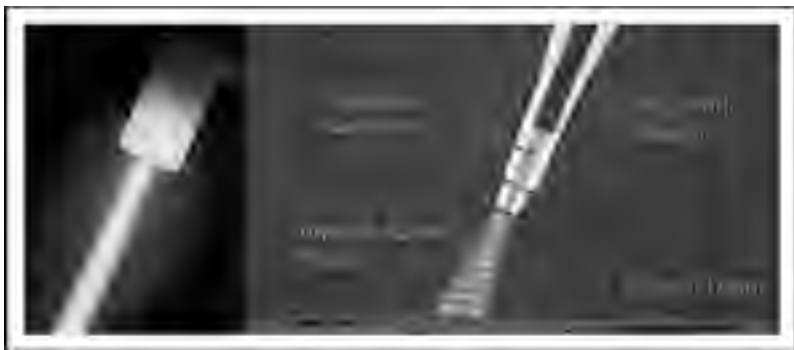


FIGURE 15 ■ Argon beam coagulation may allow more effective hemostasis with less tissue necrosis. Both are essential features for advancing intracorporeal reconstruction. Source: Birtcher Medical Systems, Irvine, CA.



FIGURE 16 ■ Pin-vise laparoscopic suturing instruments. The design limits utilization of these needle drivers for few other purposes.



FIGURE 17 ■ Various types of intracorporeal needle drivers. Each represents a unique design modification. What is common to all is the lack of finger rings that limit laparoscopic surgical dexterity.

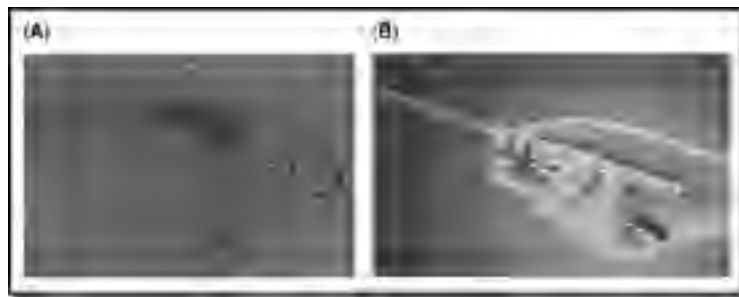


FIGURE 18 ■ (A) Classic finger-ringed instruments entrap the surgeon's hands. (B) Newer instruments allow fine manipulation of the instrument's tip without encumbering the hands.




FIGURE 19 ■ A unique laparoscopic needle driver's jaws: Endolap™ Inc., contour tip with rack & pinion power drive.



FIGURE 20 ■ The Szabo-Berci™ parrot-jaw needle driver and flamingo tissue grasper close-up.



FIGURE 21 ■ Intracorporeal passage of needles.

There is no other function that the driver can accomplish and the second hand of the surgeon must multitask to facilitate just the needle driving.

Brute force by the needle driver does not necessarily create an improved suture reconstruction. By forcing the needle along an inappropriate trajectory through the tissues, irregular spaced intervals, bunching of tissues, and inability to catch mucosa are all possible. Forceful needle drivers should not be allowed to replace surgical finesse. In a study of seven different needle drivers, the ergonomics of laparoscopic suturing was recently studied (142). Wide variability in the torque and flexion forces are obtainable. Specifically designed intracorporeal suturing instruments have been developed addressing many of the problems outlined previously (Fig. 17). The shorter the needle driver, the less magnification of small movements at the tip from the surgeon's hands. By removing finger rings, the surgeon's hands are no longer entrapped. Fine movements with the palm or with the thumb and index finger can be accomplished (Fig. 18). In addition, because of the complexity of intracorporeal suturing, removal of the finger rings greatly eases the cramping and paresthesias that develop when the fingers and thumb are fixed within an instrument for hours. Finally, the needle driver's jaws are another essential feature affecting performance. Although most instruments rely upon the standard open diamond jaw configuration to firmly grasp the needle, other variations are just beginning to emerge as effective alternatives (Fig. 19). The only intracorporeal suturing set that provides an assistant tissue grasper and a dedicated needle driver are the Szabo-Berci™ flamingo and parrot-jawed instruments (Fig. 20). Curved-tip instruments allow the surgeon to identify cut edges, invert edges, identify both the entrance and exit bites with the needle and allow the surgeon to adjust the tension of the suture. Many individuals painfully aware of the limitations of current suturing instruments are beginning to develop "prototypic" devices. Agarwal et al. describe a simple 10-mm instrument with a fixed needle at the tip of the driver to facilitate intracorporeal suturing (143).

The last barrier for accomplishing intracorporeal suturing is skill. Defined as the ability to do something well, intracorporeal suturing skill requires mastery of tasks surgeons use daily, but with much more attention to detail. This was referenced at length during our discussion of laparoscopic training. Intracorporeal suturing can be divided into three distinct tasks that can be practiced and mastered separately. These are needle driving, suturing, and knot tying.

Needle Driving

Laparoscopic intracorporeal needle driving requires successful, safe introduction of the needle and suture material through a trocar or through the anterior abdominal wall. This requires the knowledge of which needles will pass through a specific-sized trocar (144). The safest method to avoid inadvertent injury to the trocar's flapper valve mechanism and the patient's underlying viscera is to grasp the suture 2 to 3 mm behind the swage, open the valve, and begin passing the needle driver and suture simultaneously (Fig. 21) (145). Second, the needle and suture must be grasped by the needle driver and correctly aligned prior to beginning. Here, the assisting instrument grasps either the suture close to the needle or the needle itself, and then the needle is turned by both instruments close to the laparoscope until proper alignment is achieved. Needles are best held perpendicular to the jaws of the driver and in line with the proposed suture line. A curved needle is best grasped halfway along its circumference, whereas the ski-types

FIGURE 22 ■ The principles of intracorporeal needle driving. Movements should be slowed to the point of control and an understanding of the forces at the entrance and exit bites can prevent frustrating needle deflections.



can be grasped along the straight shaft. An assisting instrument is utilized for tissue alignment and countertraction. Correct alignment and needle handling is crucial to preventing deflection of the needle within the driver's jaws as the needle point enters the tissue for the entrance bite. The most common problems encountered during initial experiences with intracorporeal suturing are frustrating deflections during the entrance bite, needle advancement, or the exit bite. It is recommended that while mastering this skill, the surgeon slows the motions down to the point of control and think about each step while maintaining alignment of needle, driver, countertraction, and tissues (Fig. 22). At the exit bite, the assistant instrument provides countertraction, and the needle is released by the driver and regripped further back toward the swage and pushed through the tissues. At this point it can be regripped by the driver (145).

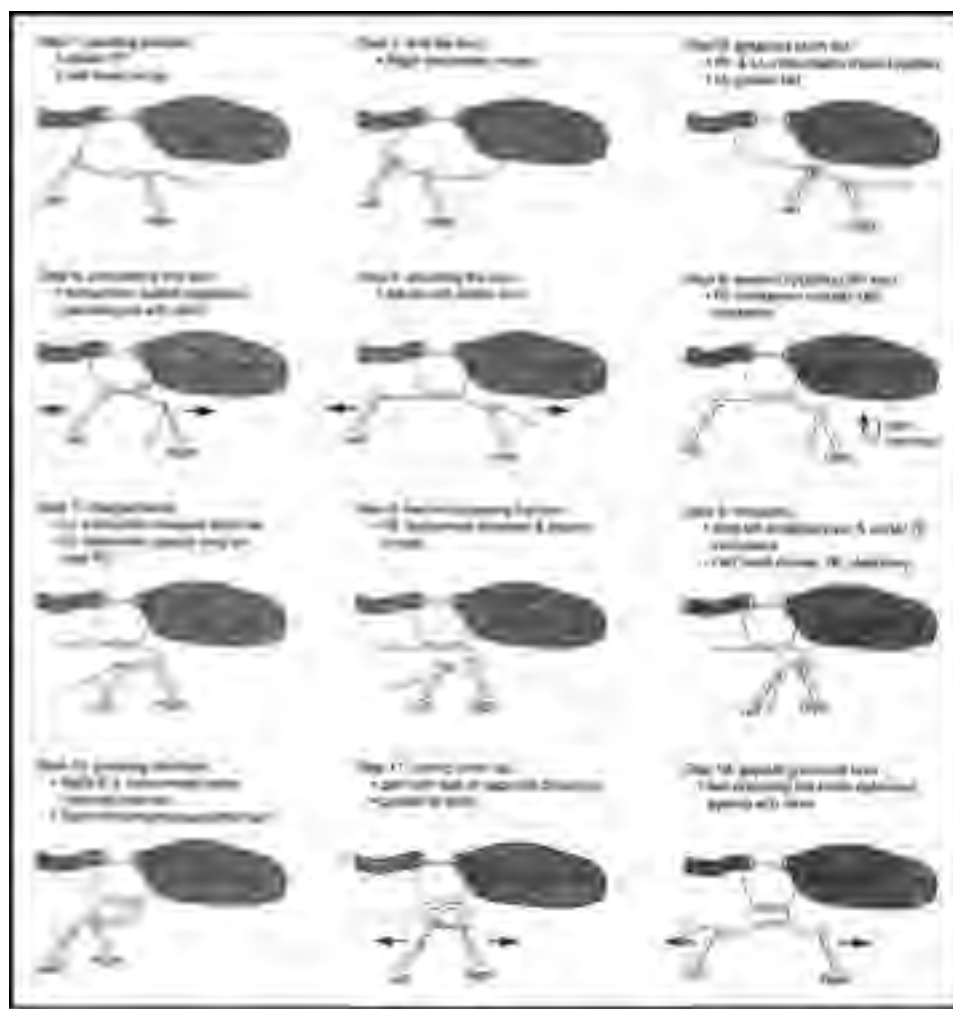
Suturing

Suturing is the next skill to be relearned for intracorporeal reconstruction. Simple stitches require only one pass through the tissues and one knot to be synched. The goal of the laparoscopic surgeon should be to achieve a perfect stitch: equally apposed entrance and exit bite sizes to avoid tension on one side of the anastomosis or the other (146). Suture length should be kept to the absolute minimum required for this purpose (147). During microsurgical laparoscopic suturing, 13 cm is adequate for simple stitches. This allows ample room for the loops necessary for knotting even in thick muscular bladder reconstructions. Urologic reconstruction can require the utilization of simple running, or running locking sutures on the bladder. These stitches require more length of intracorporeal suture material and careful attention to tension along the repair. A good rule of thumb is that twice the length of a linear incision in suture material is required (148). Here as the needle is driven through the tissues at each exit bite, the assistant grasper is utilized to aid in pulling the running stitch through for the given length and the desired tension, while the needle driver with the reloaded needle is utilized to provide counter pressure. Because the intracorporeal suturing is arduous, it behooves the surgeon to make sure the suture line is perfect the first time; even if this takes time, it is still better than redoing it. Attention to detail is paramount to an ideal suture. The running suture should start 2 to 3 mm proximal to the incision and run up to 2 to 3 mm beyond, prior to tying the end knot (145). Locking is not particularly difficult but should also be carefully orchestrated and not started until the suture line's tension has been rechecked. It is far easier to tighten a running line of suture before, rather than after, it has been locked intracorporeally. The suture should run at least one needle-driven point beyond the end of the incision. Knotting a running intracorporeal stitch can be more difficult than a simple suture. This will be discussed in the next section.

Knotting

Knot tying represents the final hurdle for proficiency in intracorporeal suturing. Were suturing and needle driving not difficult in themselves, one might say that extracorporeal knotting would certainly be the method of choice. But because the skills necessary for complex endosurgical reconstruction are all linked, knotting represents the last, most difficult task (149). In addition, once mastered, intracorporeal knots can be manipulated to the endoscopic surgeon's advantage for complex anastomoses, very much like in microsurgery (more on this later) (150). The key to successfully mastering intracorporeal knotting has been careful, small, orchestrated movements of the instruments in both of the surgeon's hands.

FIGURE 23 ■ The 12 steps in choreographing the right and left hands for accomplishing fluid intracorporeal suturing and knotting.



The intracorporeal knot having the most utility is the simple square knot. A square knot is two apposed half hitches, one atop the other. To orchestrate the movements necessary to tie such a knot and eliminate wasted motion, each key movement must be identified and the entire sequence practiced. We have previously discussed the 12 steps in tying an intracorporeal square knot (Fig. 23) (151). *Step 1* is the starting position. A “C” shape is made in the suture with the right hand grasping the swaged end of the suture and the left stabilizing the tail. *Step 2*, the right hand only moves to create a loop around the tip of the left instrument. *Step 3*, the right and left hands move together as the left instrument grasps the tail of the suture. *Step 4*, the instruments are pulled in opposite directions paralleling the pull with the suture. *Step 5*, the knot is adjusted to center the first half hitch directly above the laceration by placing more tension on the right or left hand grasp of suture. *Step 6*, sets up throwing the second half hitch. The right grasps the swaged end and is rotated 180° clockwise. *Step 7*, the left instrument releases the short tail and grasps the swaged end near the right grasper. *Step 8*, the right instrument releases the suture and is placed on top, directly in front of the left grasper. *Step 9*, the left hand moves to create a loop around the right, which remains stationary. *Step 10*, the right and left instruments move together toward the short tail, which the right then grasps. *Step 11*, both instruments are pulled in opposite directions parallel to the stitch. *Step 12*, the two opposing half hitches are tightened against each other. This concludes the exercises necessary to orchestrate fluid interaction and minimize wasted motions, thus limiting the surgical frustration.

Methods other than that described above can be utilized for laparoscopic intracorporeal knotting: by prefacing these techniques with the reminder that intracorporeal suturing is difficult, but with time, patience, and practice it can be mastered. Utilizing microsurgical principles adapted for the laparoscopic environment, knots and sutures can be manipulated to the surgeon’s advantage. This should be kept in mind when considering intracorporeal suturing techniques and taking short cuts (152).




FIGURE 24 ■ Pin-vise suturing technique.



FIGURE 25 ■ Pietrafitta's technique of stabilizing each half-hitch.



FIGURE 26 ■ Smiley face technique of intracorporeal knotting.



FIGURE 27 ■ Fly-casting method for intracorporeal knotting.

Depending upon the intracorporeal instruments utilized, a variety of intracorporeal knotting strategies can be performed. If a pin-vise needle driver is chosen, an intracorporeal “twist” technique can be performed (Fig. 24). Utilized by H.C. Topel^b and L. Sharpe^c, a sequence of twists (usually 2–3 cm) on the needle wrap the suture around the assistant grasper, keeping the needle curve parallel to the introducer. The free grasper helps release the needle and swage from the jaws, carefully maintaining the loops. Then the looped grasper can grasp the tail and the instruments move in opposite directions to tighten the half hitch. This “twisting” technique can be utilized for both curved and straight needles. Straight needles can be utilized with conventional laparoscopic instruments. Here, the needle is used to wrap the swaged end about the assistant grasper, as long as the instrument is oriented toward the assistant. The tail can then be grasped from the now “looped” grasper. Another technique reported to simplify intracorporeal knotting describes grasping both ends, forming a loop above the repair (153). The needle driver can then loop through either side to facilitate formation of each half hitch (Fig. 25). This technique hopes to eliminate “complicated, dextrous, simultaneous two-handed motions.” The “smiley face” technique is another method of promoting the intracorporeal formation of knots (Fig. 26). During intracorporeal suturing with this technique, emphasis is placed on manipulating both swage and tail segments with the needle. The needle is grasped mid-shaft with each end pointing upward, forming a “smiley face.” Each half hitch is then facilitated by wrapping the needle around the assisting instrument to form loops. This technique results in fixed orientation and a stable continuing starting place. Kozminski and Richards have recently described a fly-casting technique to aid intracorporeal knotting with interrupted sutures (154). The tail is grasped and held up in space, and next the swage is passed over the tail and allowed to drop by gravity. The swage is retrieved from the underside for the first half hitch (Fig. 27). Mirror-image repeat of this sequence results in a square knot. Finally, a prelooped needle and suture is available for intracorporeal stitching^d. Once introduced to the area of reconstruction, the needle is advanced and grasped by the driver. The needle is then passed through the preformed double loops and pulled in opposite directions. The applicator plunger is next pushed, pulling the tail and tightening the slipknot. A surgeon’s knot can be incorporated by placing two loops around the left grasper during the first half hitch. A surgeon’s knot adds to the security against slipping, especially with monofilament sutures such as polypropylene. If further modifications of the knot are required, then the surgeon’s knot should not be deployed.

Running sutures may require special intracorporeal knotting techniques. Depending on the type of suture material utilized, there is the need to maintain the tension on the trailing segment of the stitch. Because of the fixed point of exit from the incision, the tail’s end must be looped, causing a double-tailed segment that must



FIGURE 28 ■ Jamming loop knot (Dundee) shown previously can be used for extracorporeal knotting or starting a running stitch.



FIGURE 29 ■ Rollero's method of starting a running suture line.



FIGURE 30 ■ The Aberdeen knot (crochet) can be used to securely synch a running intracorporeal suture line if concern exists about crimping a monofilament suture.

be manipulated with the free swaged end. This double-stranded loop can result in increased demands upon the needle driver and assistant instrument to maintain tension on the suture line while performing intracorporeal knotting. Some monofilament sutures can fracture due to pressures applied by the instruments during knotting. Because of these problems, alternatives have been sought for running intracorporeal knotting. The jamming loop knot (Dundee jamming loop knot) can be thrown extra- or intracorporeally (Fig. 28). The running suture line can be initiated with the knot outside of the abdomen. The suture is then grasped along the swage and passed intracorporeally, usually with the aid of a reducing sleeve. The needle is then passed through the tissues and pulled until the loop approximates the tissues. The needle is then passed back through the loop, and the swage and tail ends are pulled in opposite directions jamming the knot (15,45). J.W. Rollero describes the use of a noose-like knot to start running intracorporeal suture lines (Fig. 29). The first two loops are made in a counter-clockwise fashion.

The tail crosses over the loop and is passed through the center. A third loop is formed by passing back through the center. The first running stitch is passed back through this third noose, anchoring it into place as the tension is applied. The Aberdeen (crochet) knot allows the intracorporeal completion of the running suture line (Fig. 30). Its major advantage over simple square knots is the avoidance of unequal lengths being manipulated intracorporeally and excessive force being applied to monofilament suture materials. Here the suture is first passed beneath the last running stitch before it is tightened to form a loop. A second loop through the first is fashioned, and then the swage with needle is passed through, tightening both the loop and synching the knot (155).

Recently, the interest in running sutured anastomosis has prompted resurgent interest in this technique, particularly, as it applies to the vesicourethral repair following laparoscopic radical prostatectomy. This running technique has attracted some significant research attention lately and will be addressed separately in the section entitled Running Suturing.

Intracorporeal Needles

Laparoscopic intracorporeal needle configuration has received limited attention by manufacturers to date (156). Because of the limitations of the closed working environment and difficulty of intracorporeal suturing, it might be expected that needle configurations should approximate those of microsurgery. Needles should be high-quality stainless steel or carbon steel. Carbon steel needles are harder but are more brittle, and "on-table" adjustments could result in weakening or breaking of the shaft. Homogenous stainless steel is preferred but more costly. The needle profile of choice has

not been rigorously investigated (146). In our study of intracorporeal bladder neck reconstructions, we identified three configurations that facilitated intracorporeal suturing (151). A curved 3/8 needle, a ski configuration, and an "S"-shaped profile were most helpful (Fig. 31). Needle points can be taper point, cutting, spatulated, or taper cut depending upon the tissue and resistance expected in suturing.

The spatial constraints limit the needle size, shape, and suture lengths needed to most expeditiously accomplish intracorporeal suturing. For urologic pelvic work on the urethra or bladder neck, the deep recesses of the retropubic space permit only a small 1/2 or 3/8 needle (RB-1 or TF) taper point configured needle to allow eversion of knots when reconstruction is performed. Some investigators have advocated straight needles (SC-1 Ethicon, TS-20 Davis & Geck, Endosuture™ WISAP, or ELW U.S. Surgical). These have primary advantage on surface structures or when intracorporeal suturing with straight needle graspers.

Intracorporeal Sutures

Suturing under laparoscopic conditions also produces other influences on the choice of suture materials. Surgical knots must hold and the choice of a woven or monofilament, absorbable versus nonabsorbable suture must be carefully chosen with this constraint foremost. For urological applications, intracorporeal suturing with plain or chromic gut and polydioxanone has advantage of allowing secure half hitch throws. Unfortunately, the coloring of each of these suture materials is such that if blood is present at the laceration site, specifying the ends, crucial for the orchestrated movements already discussed, becomes impossible. Blood has a tendency to adhere to these suture materials and strict attention to hemostasis is warranted. In addition, the coloration absorbs the light in all these materials except for the blue PDS™ (157). Because multiple untied sutures are placed but not tied as is required for complex end-to-end anastomoses, swage and tail ends become indistinct (Fig. 32; *left*). Brightly colored, optically fluorescent colors are required to overcome this problem. Currently, dye materials that have been investigated to enhance visibility when exposed to xenon light have also demonstrated carcinogenic properties. Despite this, colors most efficacious for laparoscopic suturing include pink, yellow, green, and purple (Fig. 32; *right*) (151).

The next problem for intracorporeal suturing is introducing the correct length of suture material. Available endoscopic suture materials that come prepackaged have no conception as to the requirements of the surgeon for the given task. Therefore, the sutures are often long (greater than 80 cm). For a simple stitch, the length required should be no more than 13 cm for a surface knot or 15 cm for deep stitches (158). Running sutures are more difficult to approximate, but as previously mentioned, a rule-of-thumb is to utilize approximately twice the length of the incision (159). Keeping the length to the minimum required results in less surgical frustration in manipulating long tail segments.

Other Intracorporeal Suturing Techniques

An enormous effort has been placed upon developing innovative methods of intracorporeal suturing to obviate the difficulties we have spent so much time outlining above



FIGURE 31 ■ Useful needle configurations for intracorporeal urologic reconstruction. 1. swage, 2. point, and 3. body. (A) 3/8 curve, (B) ski configuration, and (C) "S" shaped needle.



FIGURE 32 ■ Brightly colored sutures that fluoresce in xenon lighting. (*Left*) Multiple square knot simple sutures ready for conversion to suspension stitches. Each color identifies swage and tail segments necessary for complex end-to-end anastomoses. (*Right*) Close-up of sutures. (Studies from Ethicon indicate a potential carcinogenic property of certain dyes that fluoresce under xenon lighting.)

FIGURE 33 ■ A Suturescope® from Gomes da Silva. (A) The 8-mm outer sleeve (1), the suturing device (2), and the suture material (3). (B) A close-up of the suturing devices tip.


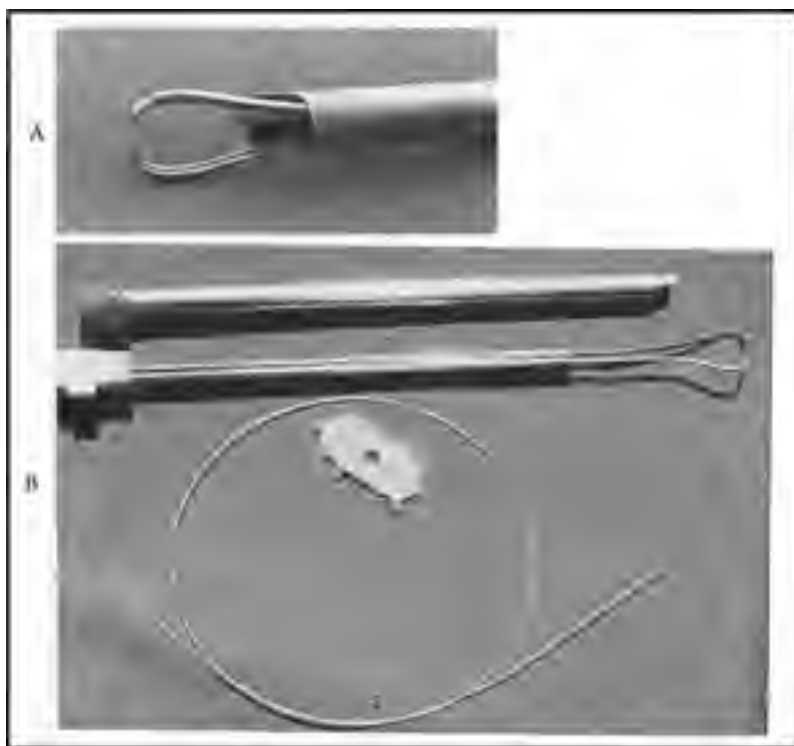


FIGURE 34 ■ EndoStitch™ is an automatic, loom-like, 10-mm intracorporeal suturing device. With practice knotting can also be facilitated with this instrument for simple and running sutures.

(158,160). Sheath systems that allow the needles and graspers to be positioned simultaneously have been described. Metal clips for replacing intracorporeal knots have been designed and marketed specifically for this purpose (24). Special techniques of tying that produce knots with straight pin-vice-type needle drivers have been reported (43). Mechanical devices are the latest devices that are attempting to reduce the difficulty of intracorporeal suturing and knotting. Stoller has described a simple device that will throw an intracorporeal knot automatically (161). A suture-scope has also been invented with a mechanism for aligning tissues and driving a long needle through two opposing tubular structures (Fig. 33) (162). Utilizing this device, an endoscopic ureteroneocystostomy has already been performed. The ultimate mechanical suturing device would be an automatic endoscopic sewing machine. Current work with such a device has been investigated and utilized clinically via a large colonoscope, by Buess and coworkers (163). The Auto Suture Company has introduced its automated, single-handed, 10-mm suturing instrument, EndoStitch for clinical application (Fig. 34). This device utilizes a loom-like mechanism to pass a straight needle back-and-forth through tissues from either end of its jaws. Controllable with a single hand, the needle can simply be reversed and regripped with a flick of the switch. Intended to be a single-patient use item, the EndoStitch device can be reloaded with the same or different suture materials. Suture materials are available currently in Polysorb (coated, braided, synthetic, polyglactin), Bralon™ (coated, braided nylon), Sof silk™ (coated, braided silk), and Surgidac™ (coated, braided polyester). The lengths of these preloaded sutures are 18 and 120 cm, with their size being dependent upon the suture material but ranging from 4-0 to 0 (U.S. Pharmacopeia sizing).

Other systems for automating anastomoses are coming from advanced work on endoscopic beating-heart surgery. An enormous amount of research in this particular field will undoubtedly lead to many innovative devices to augment intracorporeal suturing (164). In addition, the ability to complete a complex anastomosis such as aortic-venous or aortic-arterial grafting automatically might have applicability to uroenteric anastomoses. This rather technical approach to intracorporeal suturing just might allow urologists to take advantage of the brightly illuminated, magnified image from the video systems and apply the reconstructive advantages of microsurgery (8,112,163). This of course, mandates bringing the laparoscope in close proximity to the area of interest. Each move of the laparoscopic instrument's tips speeds up in equal magnitude to the degree of magnification (8). All of the intracorporeal skills discussed earlier must be precisely applied or this becomes an impossible task. Hemostasis is

even more crucial during laparoscopic microsurgical suturing (160). The ability to observe small movements of the suture material through tissues is fundamental to smoothly facilitate needle driving, suturing, and knotting. Complex urologic anastomoses have been accomplished utilizing microsurgical techniques, including vesicourethral reanastomosis, augmentation cystoplasties, and others (153). The degree of difficulty of microsurgical intracorporeal suturing is twice again as difficult as regular laparoscopic suturing (153). The advantages of microsurgical reconstruction in urology include less need for long-term urinary diversion or drainage, less infiltration with scar tissue, and visually secure suture placement (153). In addition, because of the magnification, special suturing techniques can be performed that make end-to-end anastomoses nearly foolproof (150). Suspension suturing is the technique of converting a square knot into a slipknot and back again on demand (Fig. 35). This can only be accomplished if magnification allows careful suture manipulation. With these techniques, spatial constraints and limited visual fields do not prevent the surgeon from even small anastomoses.

Running Suturing

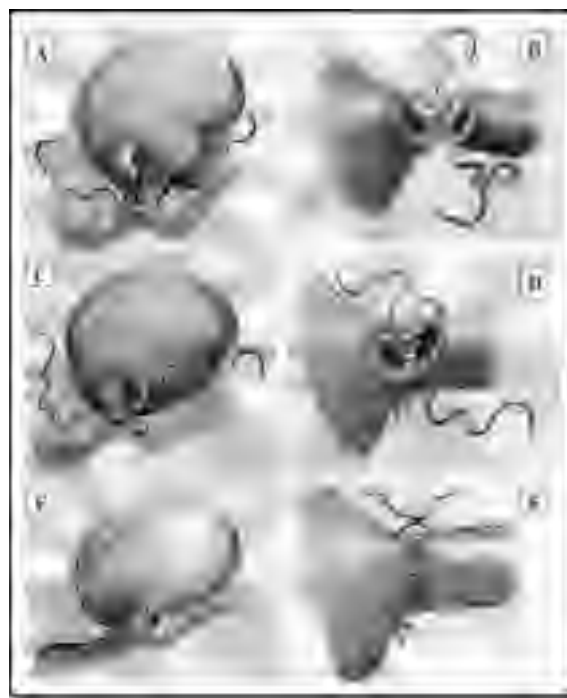
Despite considerable attention just given to suturing techniques, it is felt that one recent suturing method requires separate consideration. Initially Hoznek et al. described a simplified urethrovesical anastomosis using a two-hemicircle suture with three intracorporeal knots (165). Van Velthoven further simplified this technique by pretying two 6-inch, 3-0 polyglycolic acid sutures (one dyed and one undyed). Both needles are passed through the posterior bladder neck at the 6 o'clock position where the knot rests (Fig. 36). Sewing upward on either side of this results in a watertight closure. If a bladder discrepancy exists, the suture line can be run onto the anterior bladder neck forming a tennis-racket closure. Van Velthoven et al. report utilization in 122 laparoscopic and 8 robot-assisted radical prostatectomies with an average anastomotic time of 35 minutes. They have had no postoperative anastomotic leaks, and at short-term follow-up have reported no symptomatic bladder neck contractures (166). Menon's group has taken this technique and rapidly expanded its clinical application in the robot-assisted Vattakuti Institute Prostatectomy (Mani Menon, M.D.) series at Henry Ford Hospital. Now with over 500 consecutive cases presented, the mean operating time has dwindled to 150 minutes (167).

This technique is easily transposable to other urinary reconstructive procedures such as Anderson-Hynes dismembered pyeloplasty, ureteroureterostomy, ureteroneocystostomy, and ureteroenterostomy. Preliminary reports of this suturing methodology are beginning to accrue. Much has yet to be learned about this technique. But questions are numerous. Would a monofilament absorbable suture be better than the braided polyglycolic acid suture? Are two colors necessary? Are the two 6-inch lengths ideal? This sutured reconstruction technique appears to facilitate both free-hand as well as robot-assisted repairs and well may be a true advance in the technique of laparoscopic

FIGURE 35 ■ Suspension stitch technique for converting square knots to slipknots. Primary utility for end-to-end laparoscopic anastomoses. (A) Square knot opposing pulls to set. (B) Apposing tension to same side threads converts square knot to slipknot configuration. (C) Advancement of slip configuration. Finally, reversion to square knot by apposing pulls as in top right. Source: Modified from Ref. 150.

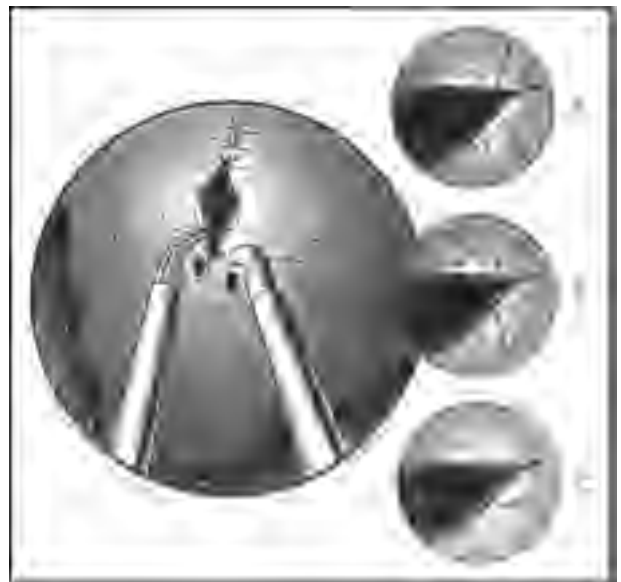

FIGURE 36 ■ Van Velthoven's method of running vesicourethral anastomosis with a single intracorporeal knot. Two 6-inch lengths are tied together extracorporeally with two different-colored absorbable sutures.



reconstructive urology. Basic research may yet solve some of the dilemmas such as the ideal length of a running suture (168).

REFERENCES

1. Das S. Urologic laparoscopy: the future is now. *Urol Clin NA* 2001; 28:1-3.
2. Carroll PR. Editorial: Laparoscopic urologic surgery: differentiating what should be done from what can be done. *J Urol* 1994; 151:1603-1604.
3. Moran ME, Kim Dh, Abrahams HM. Ideal suture characteristics. *Reconstructive laparoscopic surgery. J Endourol* 2001; 15:68.
4. Clarke HC. Laparoscopy-new instruments for suturing and ligation. *Fertil Steril* 1972; 23:274-277.
5. Ko S-T, Airan MC. Therapeutic laparoscopic suturing techniques. *Surg Endosc* 1992; 6:41-46.
6. Semm K. Pelvoscopic uterine surgery. *Surg Endosc* 1992; 6:23-31.
7. Marrero MA, Corfman RS. Laparoscopic use of sutures. *Clin Obstet Gynecol* 1991; 34:387-394.
8. Moran ME, Bowyer DW, Szabo Z. Laparoscopic suturing in urology: a model for vesicourethral anastomosis. *Minim Invasive Ther* 1993; 2:165-170.
9. Frede T, Stock C, Rassweiler JJ, Alken P. Retroperitoneoscopic and laparoscopic suturing: tips and strategies to improve efficiency. *J Endourol* 2000; 14:905-913.
10. Matern U, Waller P. Instruments for minimally invasive surgery. *Surg Endosc* 1999; 13:174-182.
11. den Boer KT, Herder JL, Sjoerdsma W, Meijer DW, Gouma DJ, Stassen HG. Sensitivity of laparoscopic dissectors. What can you feel? *Surg Endosc* 1999; 13:869-873.
12. Breedveld P, StassenHG, Meijer DW, Jakimowicz JJ. Manipulation in laparoscopic surgery: overview of impeding effects and supporting aids. *J Laparoendosc Advanc Surg Techniq* 1999; 9:469-480.
13. Emam TA, Frank TG, Hanna GB, Cuschieri A. Influence of handle design on the surgeon's upper limb movements, muscle recruitment, and fatigue during endoscopic suturing. *Surg Endosc* 2001; 15:667-672.
14. Mukherjee R, Minor M, Song G, Satava R. Optimisation of an articulated instrument for enhanced dexterity in minimally invasive therapy. *Minim Invasive Ther Allied Technol* 1998; 7:335-342.
15. Matern U, Waller P, Giebmeier ME, Ruckauer KD, Farthmann EH. Ergonomics: requirements for adjusting the height of laparoscopic operating room tables. *JSLs* 2001; 5:7-12.
16. Moran ME. Laparoscopic suturing and skills acquisition: methods to improve efficiency. *J Endourol* 2000; 14:913-914.
17. Gomella LG. Editorial: Laparoscopy and urologic oncology—I now pronounce you man and wife. *J Urol* 2003; 169:2057-2058.
18. Moran ME. Robotic surgery: urologic implications. *J Endourol* 2003; 17:695-708.
19. Costi R, Denet C, Sarli L, Perniceni T, Roncoroni L, Gayer B. Laparoscopy in the last decade of the millennium. Have we really improved? *Surg Endosc* 2003; 17:791-797.
20. Meilahn JE. The need for improving laparoscopic suturing and knot tying. *J Laparoendosc Surg* 1992; 2:267.
21. Bisson J, Vinson RK, Leadbetter GW. Urolithiasis from stapler anastomosis. *Am J Surg* 1989; 137:280.
22. Ravo B, Rosales C, Serino F, Castagneto M. The use of absorbable staples for construction of a bladder tube. *Surgery* 1991; 173:29.

23. Low RK, Moran ME. Argon beam coagulation: implications for reconstructive urology. *Minim Invasive Ther* 1993; 2:75–78.
24. Kirker-Head CA, Steckel RR, Schwartz A, Williams R. Evaluation of surgical staples for ligation of the renal pedicle during nephrectomy. *Urol Res* 1988; 16:63.
25. Sugarbaker DJ, Mentzer SJ. Improved technique for hilar vascular stapling. *Ann Thorac Surg* 1992; 53:165.
26. Kerbl K, Chandhoke PS, McDougall E, Clayman R, Marika Stone A, Hicks M. Laparoscopic clips and staples: vascular application. *J Endourol* 1992; 6:S142.
27. Moran ME. Theory of vascular pedicle hemostasis during laparoscopic nephrectomy. *Minim Invasive Ther* 1991; 1:A69.
28. Nathanson LK, Easter DW, Cuschieri A. Ligation of the structures of the cystic pedicle during laparoscopic cholecystectomy. *Am J Surg* 1991; 161:350.
29. Nathanson LK, Nathanson PDK, Cuschieri A. Safety of vessel ligation in laparoscopic surgery. *Endoscopy* 1991; 23:206.
30. Nelson MT, Nakashima M, Mulvihill SJ. How safe are laparoscopically placed clips? An in vitro and in vivo study. *Arch Surg* 1992; 127:718.
31. Beltran KA, Foresman PA, Rodeheaver GT. Quantitation of force to dislodge endoscopic ligation clips: EndoClip II vs. LigaClip ERCA. *J Laparoendosc Surg* 1994; 4:253–256.
32. Feldman SL, Presman D, Kandel GL. Renal arteriovenous fistula following nephrectomy. *Br J Urol* 1985; 57:592.
33. Goldstein AG, Delaurentis DA, Schwarz AJ. Post-nephrectomy arteriovenous fistula. *Br J Urol* 1967; 98:44.
34. Lacombe M. Renal arteriovenous fistula following nephrectomy. *Urology* 1985; 25:13.
35. Baniel J, Schein M. Partial nephrectomy using a linear stapling device. *Br J Urol* 1992; 69:218.
36. Avant LO, Starr GA. Vesicourethral reanastomosis by mechanical stapling and transurethral deep dorsal venous ligation: a new technique for radical retropubic prostatectomy. *J Endourol* (submitted).
37. Dziki AJ, Duncan MD, Harmon JW, et al. Advantages of handsewn over stapled bowel anastomosis. *Dis Col Rect* 1991; 34:442.
38. Jansson OK, Zilling TL, Walther BS. Healing of colonic anastomoses: comparative experimental study of glued, manually sutured, and stapled anastomoses. *Dis Col Rect* 1991; 34:557.
39. Moritz E, Achleitner D, Holbling N, Miller K, Speil T, Weber F. Single vs. double stapling technique in colorectal surgery. A prospective randomized trial. *Dis Col Rect* 1991; 34:495.
40. West of Scotland and Highland Anastomosis Study Group. Suturing or stapling in gastrointestinal surgery: a prospective randomized study. *Br J Surg* 1991; 78:337; Griffith DP, Gleeson MJ. The prosthetic bladder—perhaps the technology has arrived. *Scand J Urol Nephrol* 1992; 142:109.
41. Clayman RC, McDougall E, Chandhoke PS, Kerbl K, Marika Stone A. Laparoscopic ureteral reimplantation: laboratory studies. *J Endourol* 1992; 6:S144.
42. Chiu AW, Chen MT, Huang WJS, Juang GD, Lu SH, Chang LS. Case report: laparoscopic nephroureterectomy and endoscopic excision of bladder cuff. *Minim Invasive Ther* 1992; 1:299.
43. Das S. Laparoscopic removal of bladder diverticulum. *J Urol* 1992; 148:1837–1839.
44. Parra RO, Jones JP, Andrus CH, Hagood PG. Laparoscopic diverticulectomy: preliminary report of a new approach for the treatment of bladder diverticulum. *J Urol* 1992; 148:869.
45. Parra RO, Andrus CH, Jones JP, Boullier JA. Laparoscopic cystectomy: initial case report on a new treatment for the retained bladder. *J Urol* 1992; 148:1140.
46. Clayman RV, Kavoussi LR, Gigenshau RS, Chandhoke PS, Albala DM. Laparoscopic nephroureterectomy: initial case report. *J Laparoendosc Surg* 1991; 1:343.
47. Grainger DA, Meyer WR, DeCherney AH, Diamond MP. Laparoscopic clips: evaluation of absorbable and titanium with regard to hemostasis and tissue reactivity. *J Reprod Med* 1991; 36:493.
48. Schuessler WW, Vancaillie TG, Preminger GM. Laparoscopic dismembered pyeloplasty. *Minim Invasive Ther* 1992; 1(suppl):A68 (abstract B-30).
49. Kerbl K, Chandhoke PS, McDougall E, Figenshau RS, Stone AM, Clayman RV. Laparoscopic stapled bladder closure: laboratory and clinical experience. *J Urol* 1993; 149:1437.
50. Gluckman OR, Stoller M, Irby P. Laparoscopic pyelocaliceal diverticula ablation. *J Endourol* 1993; 7:315–317.
51. Levinson AK, Greskovich FJ, Swanson DA, Stephenson RA, Johnson DE, Lichtiger B. Fibrin glue for partial nephrectomy. *Urology* 1991; 38:314.
52. Winfield HN, Donovan JF, Godet AS, Clayman RV. Human laparoscopic partial nephrectomy: initial case report for benign disease. *J Endourol* 1993; 7:521–526.
53. Satava RM. Surgery 2001: a technologic framework for the future. *Surg Endosc* 1993; 7:111–113.
54. Halsted W. The training of the surgeon. *Bull Johns Hop Hosp* 1904; 15:267–276.
55. Rothschild JG. What alternatives has minimally invasive surgery provided the surgeon? *Arch Surg* 1998; 133:1156–1159.
56. Derossis AM, Fried GM, Abrahamowicz M, Sigman HH, Barkun JS, Meakins JL. Development of a model for training and evaluation of laparoscopic skills. *Am J Surg* 1998; 175:482–487.
57. Hanna GB, Drew T, Clinch P, et al. Psychomotor skills for endoscopic manipulations: differing abilities between right and left-handed individuals. *Ann Surg* 1997; 225:333–338.
58. Hanna GB, Cuschieri A. Influence of the optical axis-to-target angle on endoscopic task performance. *Surg Endosc* 1999; 13:371–375.
59. Holden JG, Flach JM, Donchin Y. Perceptual-motor coordination in an endoscopic surgery simulation. *Surg Endosc* 1999; 13:127–132.
60. Hanna GB, Shimi S, Cuschieri A. Influence of direction of view, target-to-endoscope distance and manipulation angle on endoscopic knot tying. *Br J Surg* 1997; 84:1460–1464.
61. Breedveld P, Stassen HG, Meijer DW, Stassen LPS. Theoretical background and conceptual solution for depth perception and eye-hand coordination problems in laparoscopic surgery. *Minim Invasive Ther Allied Technol* 1999; 8:227–234.

62. Kum CK, Goh P, Alexander DJ, Mochala S. Three-dimensional versus two-dimensional imaging for laparoscopic suturing. *Br J Surg* 1997; 84:35.
63. Barnes RW. Surgical handicraft: teaching and learning surgical skills. *Am J Surg* 1987; 153:422–427.
64. Reznick RK. Teaching and testing technical skills. *Am J Surg* 1993; 165:358–361.
65. Dent TL. Training and privileging for new procedures. *Surg Clin NA* 1996; 76:615–621.
66. Macmillan AIM, Cuschieri A. Assessment of innate ability and skills for endoscopic manipulations by the advanced Dundee endoscopic psychomotor tester: predictive and concurrent validity. *Am J Surg* 1999; 177:274–277.
67. Lang NP, Rowland-Morin PA, Coe NP. Identification of communication apprehension in medical students starting surgery rotation. *Am J Surg* 1998; 176:41–45.
68. Smith DM, Kolb DA. User's Guide for the Learning-Style Inventory. A Manual for Teachers and Trainers. Boston: McBer and Co., 1986.
69. Lynch TG, Woelfl NN, Steele DJ, Hanssen CS. Learning style influences student examination performance. *Am J Surg* 1998; 176:62–66.
70. Kaufman HH, Wiegand RL, Tunick RH. Teaching surgeons to operate—principles of psychomotor skills training. *Acta Neurochir* 1987; 87:1–7.
71. Jones MB, Kennedy RS. Isoperformance curves in applied psychology. *Human Factors* 1996; 38:167–182.
72. Melvin WS, Johnson JA, Ellison EC. Laparoscopic skills enhancement. *Am J Surg* 1996; 172:377–379.
73. Sammarco MJ, Youngblood JP. A resident teaching program in operative endoscopy. *Obstet Gynecol* 1993; 81:463–466.
74. Schirmer BD, Edge SB, Dix J, Miller AD. Incorporation of laparoscopy into a surgical endoscopy training program. *Am J Surg* 1992; 163:46–52.
75. Wolfe BM, Szabo Z, Moran ME, Chan P, Hunter JG. Training for minimally invasive surgery: need for surgical skills. *Surg Endosc* 1993; 7:112–114.
76. Heniford BT, Backus CL, Matthews BD, Greene FL, Teel WB, Sing RF. Optimal teaching environment for laparoscopic splenectomy. *Am J Surg* 2001; 181:226–230.
77. Anastakis DJ, Regehr G, Reznick RK, et al. Assessment of technical skills transfer from the bench training model to the human model. *Am J Surg* 1999; 177:167–170.
78. Ko CY, Whang EE, Karamanoukian R, Longmire WP, McFadden DW. What is the best method of surgical training? A report of America's leading senior surgeons. *Arch Surg* 1998; 133:900–905.
79. Martin JA, Regehr G, Reznick R, et al. Objective structured assessment of technical skill (OSATS) for surgical residents. *Br J Surg* 1997; 84:273–278.
80. Rosser JC, Rosser LE, Savalgi RS. Skill acquisition and assessment for laparoscopic surgery. *Arch Surg* 1997; 132:200–204.
81. Steele RJC, Walder C, Herbert M. Psychomotor testing and the ability to perform an anastomosis in junior surgical trainees. *Br J Surg* 1992; 79:1065–1067.
82. Medina M. Formidable challenges to teaching advanced laparoscopic skills. *JSLS* 2001; 5:153–158.
83. Macmillan AIM, Cuschieri A. Assessment of innate ability and skills for endoscopic manipulations by the advanced Dundee endoscopic psychomotor tester: predictive and concurrent validity. *Am J Surg* 1999; 177:274–277.
84. Francis NK, Hanna GB, Cuschieri A. Reliability of the Dundee endoscopic psychomotor tester (DEPT) for dominant hand performance. *Surg Endosc* 2001; 15:673–676.
85. Fried GM, Derossis AM, Bothwell J, Sigmann HH. Comparison of laparoscopic performance in vivo with performance measured in a laparoscopic simulator. *Surg Endosc* 1999; 13:1077–1081.
86. Rosser JC, Rosser LE, Savalgi RS. Objective evaluation of a laparoscopic surgical skill program for residents and senior surgeons. *Arch Surg* 1998; 133:657–661.
87. Derossis AM, Antoniuk M, Fried GM. Evaluation of laparoscopic skills: a 2-year follow-up during residency training. *Can J Surg* 1999; 42:293–296.
88. Olinger A, Pistorius G, Lindemann W, Vollmar B, Hildebrandt U, Menger MD. Effectiveness of a hands-on training course for laparoscopic spine surgery in a porcine model. *Surg Endosc* 1999; 13:118–122.
89. Meier AH, Rawn CL, Krummel TM. Virtual reality: surgical application — challenge for the new millennium. *J Am Coll Surg* 2001; 192:372–384.
90. Ramshaw BJ, Young D, Garcha I, et al. The role of multimedia interactive programs in training for laparoscopic procedures. *Surg Endosc* 2001; 15:21–27.
91. Rosser JC, Herman B, Risucci DA, Murayama M, Rosser LE, Merrell RC. Effectiveness of a CD-ROM multimedia tutorial in transferring cognitive knowledge essential for laparoscopic skill training. *Am J Surg* 2000; 179:320–324.
92. Rogers DA, Regehr G, Howdieshell TR, Yeh KA, Palm E. The impact of external feedback on computer-assisted learning for surgical technical skill training. *Am J Surg* 2000; 179:341–343.
93. Mann CC. The end of Moore's Law? *Technol Rev* 2000; 42–48.
94. Haluck RS, Krummel TM. Computers and virtual reality for surgical education in the 21st century. *Arch Surg* 2000; 135:787–792.
95. Krummel TM. Surgical simulation and virtual reality: the coming revolution. *Ann Surg* 1998; 228:635–637.
96. Marescaux J, Clement J-M, Tasseti V, et al. Virtual reality applied to hepatic surgery simulation: the next revolution. *Ann Surg* 1998; 228:627–634.
97. Trunkey DD, Botney R. Assessing competency: a tale of two professions. *J Am Coll Surg* 2001; 192:385–395.
98. Rosser JC, Murayama M, Gabriel NH. Minimally invasive surgical training solutions for the twenty-first century. *Surg Clin NA* 2000; 80:1607–1624.
99. Satava RM, Jones SB. Preparing surgeons for the 21st century. *Surg Clin NA* 2000; 80:1353–1365.
100. Moore RG, Adams JB, Partin AW, Docimo SG, Kavoussi LR. Telementoring of laparoscopic procedures: initial clinical experience. *Surg Endosc* 1996; 10:107–110.

101. Lee BR, Bishoff JT, Janetschek G, et al. A novel method of surgical instruction: international tele-mentoring. *World J Urol* 1998; 16:367–370.
102. Cubano M, Poulouse BK, Talamini MA, et al. Long distance telementoring. A novel tool for laparoscopy aboard the USS Abraham Lincoln. *Surg Endosc* 1999; 13:673–678.
103. Broderick TJ, Harnett BM, Merriam NR, Kapoor V, Doarn CR, Merrel RC. Impact of varying transmission bandwidth on image quality. *Telemed J E Health* 2001; 7:47–53.
104. Gandsas A, Draper K, Chekan E, et al. Laparoscopy and the internet. *Surg Endosc* 2001.
105. Durst L. The center for minimal access surgery—teaching for tomorrow. *J Telemed Telecare* 2000; 6:S14–S15.
106. Green LS, Loughlin KR, Kavoussi LR. Management of epigastric vessel injury during laparoscopy. *J Endourol* 1992; 6:99.
107. Nathanson LK, Cuschieri A. The falciform lift: a simple method for retraction of falciform ligament during laparoscopic cholecystectomy. *Surg Endosc* 1986; 4:1787.
108. Mettler L, Semm K. Pelviscopic uterine surgery. *Surg Endosc* 1992; 6:23.
109. Reich H, Clarke C, Sekel L. A simple method for ligating with straight and curved needles in operative laparoscopy. *Obstet Gynecol* 1992; 79:143.
110. Nathanson LK, Nathanson PDK, Cuschieri A. Safety of vessel ligation in laparoscopic surgery. *Endoscopy* 1991; 23:206.
111. Cuschieri A, Shimi S, Nathanson LK. Laparoscopic reduction, crural repair, and fundoplication of large hiatal hernia. *Am J Surg* 1992; 163:425.
112. McComb PF. A new suturing instrument that allows the use of microsuture at laparoscopy. *Fertil Steril* 1992; 57:936.
113. Oko M, Rosin RD. Extracorporeal knotting with a new instrument. *Minim Invasive Ther* 1993; 2:1–3.
114. Puttick MI, Nduka BA, Darzi A. Extracorporeal knot tying using an atraumatic Babcock clamp. *J Laparoendosc Surg* 1994; 4:339–341.
115. Kennedy JS. A technique for extracorporeal suturing. *J Laparoendosc Surg* 1992; 2:269–262.
116. Andrews S, Lewis JL. Minimal access suturing: an assessment of knot substitutes. *Minim Invasive Ther* 1992; 1:309.
117. Moran ME. Stationary and automated laparoscopically assisted technologies. *J Laparoendosc Surg* 1993; 3:221–227.
118. Tonietto G, Pintaldi S. Finger-assisted laparoscopic surgery. *J Laparoendosc Surg* 1994; 4:205–207.
119. Tan HL, Hutson JM. Case report: laparoscopically-assisted cysto-prostatectomy. *Minim Invasive Ther* 1994; 3:207–210.
120. Daum IW. 'EndoHand,' an manipulator for M.I.S. *Minim Invasive Ther* 1994; 3(suppl 1):7 (abstract O-86).
121. Schurr T, Melzer A, Dautzenberg P, Neisius B, Trapp R, Buess G. Development of steerable instruments for minimal invasive surgery in modular conception. *Acta Chir Belg* 1993; 63:73–77.
122. Durrani AF, Preminger GM. Advanced endoscopic imaging: 3-D laparoscopic endoscopy. In: Szabo Z, Kerstein MD, Lewis JE, eds. *Surgical Technology International II*. San Francisco, CA: Universal Medical Press Inc., 1994:141–147.
123. Calvano CJ, Moran ME, Tackett LD, Reddy PP, Boyle KE, Pankratov MM. New visualization techniques for in utero surgery: amnioscopy with a three dimensional head mounted display and a computer controlled endoscope. *J Endourol* 1998; 12:407–410.
124. Wolf JS Jr., Carrier S, Stoller ML. Gas embolism: helium is more lethal than carbon dioxide. *J Laparoendosc Surg* 1994; 4:173–177.
125. Henderson MR, Link WJ, Glover JL, Incropera FP. Gas transport resulting from plasma-scalpel surgery. *Med Biol Eng* 1974; 12:208–213.
126. Kozlowski PM, Winfield HN. Laparoscopic partial nephrectomy and wedge resection. *J Endourol* 2000; 14:865–870.
127. Jackman SV, Bishoff JT. Laparoscopic retroperitoneal renal biopsy. *J Endourol* 2000; 14:833–838.
128. Crabtree JH, Fishman A. Videoscopic argon beam coagulator treatment of large persistent lymphocele. *J Laparoendosc Surg Tech* 2000; 10:63–65.
129. Stifelman MD, Sosa RE, Nakada SY, Schichman SJ. Hand-assisted laparoscopic partial nephrectomy. *J Endourol* 2001; 15:161–164.
130. Hernandez AD, Smith JA Jr., Jeppson KG, Terreros DA. A controlled study of the argon beam coagulator for partial nephrectomy. *J Urol* 1990; 143:1062–1065.
131. Chan DY, Marshall FF. Partial nephrectomy for centrally located tumors. *Urology* 1999; 54:1088–1091.
132. Shapiro MJ, Minor CB Jr., Brems J, Hayek M. Argon beam coagulator hepatorrhaphy in potential donors. *Am Surg* 1992; 58:353–354.
133. Majeski J. Advances in general and vascular care of Jehovah's Witnesses. *Int Surg* 2000; 85:257–265.
134. Dunham CM. The role of the argon beam coagulator in splenic salvage. *Surg Gyn Obstet* 1991; 173:179–182.
135. Go PM, Goodman GR, Bruhn EW, Hunter JG. The argon beam coagulator provides rapid hemostasis of experimental hepatic and splenic hemorrhage in anticoagulated dogs. *J Trauma* 1991; 31:1294–1300.
136. Dowling RD, Ochoa J, Yousem SA, Peitzman A, Udekwu AO. Argon beam coagulation is superior to conventional techniques in repair of experimental splenic injury. *J Trauma* 1991; 31:717–720.
137. Stylianou S, Hoffman MA, Jacir NN, Harris BH. Sutureless hemisplenectomy. *J Ped Surg* 1991; 26:87–89.
138. Go PM, Bruhn EW, Garry SL, Hunter JG. Patterns of small intestinal injury with the argon beam coagulator. *Surg Gyn Obstet* 1990; 171:341–342.
139. Rusch VW, Schmidt R, Shoji Y, Fujimura Y. Use of the argon beam coagulator for performing pulmonary wedge resection. *Ann Thorac Surg* 1990; 49:287–291.
140. Stojeba N, Mahoudeau G, Segura P, Meyer C, Steib A. Possible venous argon gas embolism complicating argon gas enhanced coagulation during liver surgery. *Acta Anaesth Scand* 1999; 43:866–867.

141. Anonymous. Fatal gas embolism caused by over pressurization during laparoscopic use of argon enhanced coagulation. *Health Devices* 1994; 23:257–259.
142. Cartmill J, Patkin M, Graber JG, Schultz LS, Hickok DF, Isabel L. Ergonomics and needle holding ability of laparoscopic needle holders. *Surg Endosc* 1993; 128 (abstract 132).
143. Agarwal DK, Gaur DD, Agarwal M. A new concept of laparoscopic suturing. *Minim Invasive Ther* 1994; 227–29.
144. Moran ME, Calvano CJ, Reddy PP, Rahman SB, Melhaff BA. Laparoscopic needle passage: a chart for intracorporeal suturing. *J Endourol* 1996; 10:S189.
145. Cuschieri A, Szabo Z. *Tissue Approximation in Endoscopic Surgery*. Oxford: Isis Medical Media, 1995:90–94.
146. Waninger J, Kauffmann GW, Shah IA, Farthmann EH. Influence of the distance between interrupted sutures and the tension of sutures on healing of experimental colonic anastomoses. *Am J Surg* 1992; 163:319.
147. Abrahams HM, Kim DH, Moran ME. Intracorporeal interrupted suturing: the ideal length of suture material. *JLS* 2001; 5:383–384.
148. Desai PJ, Moran ME, Calvano CJ. Running suturing: the ideal suture length facilitates this task. *J Endourol* 1999; 13:A1.
149. Moran ME. Laparoscopic suturing skills acquisition: methods to improve efficiency. *J Endourol* 2001; 14:913–914.
150. Szabo Z, Rose EH, Ellis MS, Burch BH. Slip-knot suspension technique: a fail-safe microanastomosis for small-caliber vessels. *Microsurgery* 1992; 13:100–102.
151. Bowyer DW, Moran ME, Szabo Z. Laparoscopic suturing in urology: a model for the lower urinary tract. *J Endourol* 1992; 6:S142.
152. Szabo Z, Bowyer DW. Laparoscopic suturing: principles and techniques. In: Das S, Crawford ED, eds. *Urologic Laparoscopy*. Philadelphia PA: W.B. Saunders, 1994:225–244.
153. Pietrafitta JJ. A technique of laparoscopic knot tying. *J Laparoendosc Surg* 1992; 2:273–275.
154. Kozminski M, Richards WH III. Fly-fishing method of intracorporeal knot tying. *Urology* 1994; 44:577–578.
155. Cuschieri A. Tissue approximation. *Probl Gen Surg* 1991; 8:366–377.
156. Moran ME, Kim DH, Abrahams HM. Ideal suture characteristics. *Reconstructive laparoscopic surgery*. *J Endourol* 2001; 15:68.
157. Soper NJ, Hunter JG. Suturing and knot tying in laparoscopy. *Surg Clin NA* 1992; 72:1139–1152.
158. Bowyer DW, Moran ME, Szabo Z. Laparoscopic suture materials. Western Section AUA, 1st Prize Round Table, Kuau HI, October 1992.
159. Abrahams HM, Kim DH, Moran ME. Intracorporeal interrupted suturing: the ideal length of suture material. *JLS* 2001; 5:383–384.
160. Moran ME, Abrahams HM, Kim DH. Suture length is a key variable in suturing efficiency. *J Endourol* 2001; 15:A22, A1–P5.
161. Meizer A, Lirici MM, Reuthebuch O, Trapp R, Beuss G. New knotting, ligature, and purse string techniques. *Minim Invasive Ther* 1992; 1:74.
162. Gomes da Silva E. Suturescope: a new device that allows endoscopic sutures to be performed with traditional threads. *Surg Endosc* 1990; 4:220.
163. Saclarides TJ, Smith L, Ko S-T, Orkin B, Buess G. Transanal endoscopic microsurgery. *Dis Colon Rect* 1992; 35:1183–1191.
164. Szabo Z, Avery GJ II, Sandor A, Litwin DEM. Suturing and knotting techniques for thoracoscopic cardiac surgery. *Surg Clin NA* 2000; 80:1555–1574.
165. Hoznek A, Solomon L, Rabi R, et al. Vesicourethral anastomosis during laparoscopic radical prostatectomy: the running suture method. *J Endourol* 2000; 14:749–753.
166. Van Velthoven RF, Ahlering TE, Peltier A, Skarecky DW, Clayman RV. Technique for laparoscopic running urethrovesical anastomosis: the single knot method. *Urology* 2003; 61:699–702.
167. Menon M, Tewari A, Peabody JO. Vattikuti Institute prostatectomy: technique. *J Urol* 2003; 169:2289–2292.
168. Desai PJ, Moran ME, Parekh AR, Calvano CJ. Running suturing: the ideal suture length facilitates this task. *J Endourol* 2000; 14:191–194.

LAPAROSCOPIC SUTURING: PROCEDURE-SPECIFIC

Louis J. Giorgi, Jr.

Mercy Medical Group, Carmichael, California, U.S.A.

Michael E. Moran

Capital District Urologic Surgeons, Albany, New York, U.S.A.

■ LAPAROSCOPIC UROLOGIC SUTURED RECONSTRUCTION

Renal Reconstruction
Ureteral Reconstruction
Bladder Reconstruction
Vesicourethral Anastomosis

■ ROBOTIC RECONSTRUCTION

Introduction

General Application
Urologic Applications
Remote Telerobotic Surgery

■ CONCLUSION

■ PRACTICAL SKILLS ACQUISITION

EXERCISES

■ REFERENCES

LAPAROSCOPIC UROLOGIC SUTURED RECONSTRUCTION

As this textbook will attest, the number and complexity of urologic reconstructions is rapidly expanding. In 2003, for instance, only about 700 robotic prostatectomies were performed worldwide. In 2004, this number is expected to rise above 7000, representing a log growth in the number of sutured vesicourethral anastomoses (1). Over 500 laparoscopic pyeloplasties have been reported with sutured repair. Also emerging with larger series are laparoscopic radical cystectomy with either orthotopic or heterotopic sutured/stapled urinary diversion. The implications and abilities for the urologist to intervene and reconstruct the urinary tract are now widely being applied. In this section, each urinary organ will be isolated and discussed with a review of the relevant literature. Every aspect of urologic reconstruction has been attempted upon the kidney, ureter, bladder, bladder neck, urethra, and genitalia. Even the inferior epigastric artery has been isolated and harvested for reconstruction of the penile vasculature for impotence using laparoscopic techniques (2). Laparoscopic ileal vaginal reconstruction has been accomplished in a young woman with Mayer-Rokitansky-Kuster syndrome (3). Virtually every intersexual condition has now been reported to be successfully treated with the aid of laparoscopic reconstructive measures (4). We have pursued an endoscopic model of gracilis muscle flap harvesting with intracorporeal transposition to the bladder neck and isolation of the neurovascular pedicle in rabbits. The following discussion of the most recent series of laparoscopic urologic reconstructive surgeries with historical references when relevant. Emphasis will be upon the sutured nuances within these reports.

Renal Reconstruction

Literally every open procedure performed upon the kidney has now been done laparoscopically. Procedures include the following: pyeloplasty, partial nephrectomy for malignancy, partial nephrectomy for duplication anomalies, partial nephrectomy for fusion anomalies, lower pole partial nephrectomy for stones, ureterocalicostomy, pyelolithotomy, anastrophic nephrolithotomy, pyelocaliceal diverticulectomy, renovascular surgery, autotransplant, donor transplantation, and nephropexy. Here, the literature will be viewed from the standpoint of the laparoscopic reconstruction efforts. Attention will be particularly paid to those methods that the investigators are utilizing to repair the genitourinary tract, and their postoperative management and outcomes.

Laparoscopic Pyeloplasty

Of all the renal procedures currently being done, the most commonly performed short of nephrectomy is reconstruction for primary or secondary ureteropelvic junction obstructions (Fig. 1). The laparoscopic approach to the repair of this condition is so successful at some institutions that it has become the "method of choice" for repairing all patients

FIGURE 1 ■ Laparoscopic pyeloplasty.

presenting with ureteropelvic junction obstruction. Others argue that less invasive endopyelotomy approaches remain viable alternatives in selected patients with a high probability of success. Markovich et al. (4) recently reported on trends from 37 endourologists in North America. They found that 41% were still performing endopyelotomy, 51% were performing laparoscopic pyeloplasty, and about 50% were still performing open pyeloplasty. Of note, about 20% of those polled would now choose a laparoscopic pyeloplasty as first-line therapy (5). A single institution's comparison of laparoscopic pyeloplasty, Acucise endopyelotomy, and open pyeloplasty showed success rates of 94%, 54%, and 86%, respectively (6). It is easy to understand that the trend among endourologists is to consider laparoscopic pyeloplasty as first-line therapy.

Schuessler has reported his first six cases of laparoscopic dismembered pyeloplasty (6). All were performed with running 4-0 polyglactin sutures, two had reduction pyeloplasties, and all were drained postoperatively. He has subsequently reported upon six additional cases with operative times ranging from 180 to 420 minutes. Two additional laparoscopic pyeloplasties are reported using a 4-0 absorbable suture material. The largest single series has come from Johns Hopkins with 100 reported cases. Seventy-one of these 100 cases were Anderson-Hynes-dismembered pyeloplasties with sutured reconstruction. Their average operative time was 252 minutes (range, 120–480 minutes). The success rate is reported to be 96% at a mean follow-up of 32.4 months (7). Gaur et al. (8) described eight patients who underwent laparoscopic pyelolithotomy without closure of the pyelotomy incision (9). They have subsequently described a homemade intracorporeal suturing instrument to solve the problem of open drainage in order to reconstruct the pyelotomy. Laparoscopic pyeloplasty has also been utilized to synchronously extract calculi and repair the obstructed ureteropelvic junction. In the single largest cohort, 19 patients with 20 renal units underwent simultaneous interventions. Varying methods of laparoscopic reconstruction were used including the Anderson-Hynes, Y-V plasty, and Heineke-Mikulicz. Stone free status was 90% (17/19) and 90% had no obstruction at three months follow-up. Two of these patients have recurrent stones at follow-up for an 80% stone free rate (16/20) (10). Laparoscopic pyeloplasty has been evaluated for the treatment of secondary ureteropelvic junction obstructions (11). In a multi-institutional evaluation of 36 patients with an average of 1.3 prior procedures (range 1–4), the reported patency rate for a laparoscopic pyeloplasty is 89% and the reasonable objective response was 94% (11). In addition to salvage for secondary ureteropelvic junction, other reconstructive urologic procedures may be necessary in patients that have had previous surgery and long segmental defects affecting the ureteropelvic junction. Kaouk et al. reported the use of a dismembered tabularized flap repair in a 73 years old lady with a solitary kidney who had failed multiple prior procedures (12). In addition, a laparoscopic ileal ureter reconstruction was described by the same group from the Cleveland Clinic. An 87 years old with a solitary left kidney had a solitary proximal ureteral tumor and underwent a total ureterectomy and an ileal ureteral interposition (13).

One recent review used a decision tree analysis to compare the costs of each method of ureteropelvic junction repair at a single institution (14). A retrograde ureteroscopic endopyelotomy was the least costly (US\$3842). The Acucise endopyelotomy was next (US\$4427) followed by antegrade endopyelotomy (US\$5297), laparoscopic pyeloplasty (US\$7026) and open pyeloplasty (US\$7119) (14). The authors are quick to point out that the financial data are arbitrary to the decision, but in the current Health Care environment the failure to consider this is likewise unacceptable. In conclusion, patients with ureteropelvic junction obstructions, especially with crossing vessels, are increasingly being considered for laparoscopic pyeloplasty. The success of this operation is very good, rivaling those of its open alternative. The method of choice for the repair has yet to be answered, however, for patients with crossing vessels, the Anderson-Hynes-dismembered pyeloplasty appears to be the most reliable method with intracorporeally sutured anastomosis.

FIGURE 2 ■ Laparoscopic partial nephrectomy.



Partial Nephrectomy Reconstruction

As every other aspect of open renal surgery has been reproduced laparoscopically, it is important to consider the reconstructive aspects of partial nephrectomy (Fig. 2). Partial nephrectomies were previously anecdotal, now a MedLine™ search shows greater than 56 published articles on this primarily. Most partial nephrectomies are performed for malignancy. The largest series was reported at the 2003 American Urologic Association Meeting by Gill et al. They compared laparoscopic and open partial nephrectomies in 200 consecutive patients. Pyelocaliceal repair was performed in 63.9% of the laparoscopic cases versus 73.4% of the open cases ($p = 0.20$). Pyelocaliceal repair was performed utilizing suture-ligation of intrarenal vessels and renal parenchymal reconstruction (15). Another recent investigation of pure laparoscopic versus laparoscopic-assisted partial nephrectomy in a porcine animal model noted that surgeons rated suture placement and tying much easier in the pure laparoscopic technique over the assisted alternative (16). Most investigators have taken to covering their sutured repair with fibrin glue or modification with a Surgicel patch (fibrin glue-impregnated patch). A flap of extrarenal fat can likewise be swung and sutured for a layered covering. In addition, many papers reviewed also utilized stenting judiciously in order to decrease the risk of urinary leakage (17,18).

Laparoscopic Ureterocalicostomy

Two small series of investigations utilizing this technique have been reported, both in swine models. Cherullo et al. performed a laparoscopic lower pole nephrectomy by transverse amputation in 10 pigs. Next, a sutured ureterocalicostomy was carried out with interrupted absorbable sutures. All anastomoses were stented and the mean operative time was 165.3 minutes (range, 105–240 minutes) (19). The group at University of California Irvine is likewise investigating this complex reconstruction utilizing a similar porcine model but with a unique reconstructive twist. A novel nitinol tacker has been used for vascular anastomoses. Because previous reports by this same group have revealed little lithogenic potential for titanium during the use of an Endo-GIA™ for reduction of the renal pelvis during laparoscopic pyeloplasty, this device deserves further attention (20,21).

Laparoscopic Calicorrhaphy and Calicoplasty

Anatrophic nephrolithotomy has been the last bastion of open renal stone surgery (22). This has now been modeled in the porcine surgical research lab and brought into clinical practice at the Cleveland Clinic. Laparoscopic anatrophic nephrolithotomy was performed in 10 pigs and 11 kidneys using vascular pedicle clamping, contact surface kidney cooling, renal parenchymal incision laterally along the avascular plane, and sutured reconstruction. This group has reported upon the clinical application of this technique in two patients (23). Coupled with the methods of laparoscopic, intraoperative ultrasonography, it might be expected to expand to other applications such as the radial nephrotomy for obstructed calyces.

Laparoscopic Renal Vascular Surgery

Renal vascular surgery can be performed for nascent renovascular disease or during the reconstruction phase of renal transplantation and autotransplantation. In the former category, nascent renovascular disease, laparoscopic repair would of course have to compete with the less invasive alternative of percutaneous transluminal balloon catheter angioplasty with renal artery stenting (24). The Cleveland group has also evaluated laparoscopic renovascular reconstruction. In their preliminary animal series, five female swine underwent a seven-step renal artery repair (25). This group followed with a case report of a laparoscopic repair of a 3 cm sacular left renal artery aneurysm in a 57-year-old woman. A four-port transabdominal technique was utilized allowing circumferential

mobilization, Roummel tourniqueting of the main renal artery, bivalving of the aneurysm with excision, followed by 4-0 polypropylene sutured repair using an RB-1 needle. Total repair time was 31 minutes with an approximate 100 cc blood loss (26). Splenorenal bypass is another method for managing renal artery stenosis. This has been investigated in a canine model of six animals. In this laboratory model a spatulated, end-to-end anastomosis of the renal to the splenic artery was accomplished using 6-0 polypropylene sutures on an RB-2 needle. Mean anastomotic time was 71 minutes (SD = 8 minutes) (27). More distal vascular aneurysms are also approachable laparoscopically. This same group recently reported a 51-year-old male with a multilobulated intrarenal aneurysm from the upper pole branch of the renal artery. Laparoscopic Statinsky clamping controlled the renal hilum en bloc, the aneurysm was circumferentially mobilized, clipped and divided. They completed this using four ports with a total warm ischemia time of 39 minutes (28). Ming et al. have performed laparoscopic-assisted autotransplantation in patients with devastating ureteral and ureteropelvic junction injuries. The kidney is mobilized in much the same manner for a donor nephrectomy only a small separate lower quadrant incision is made for the autotransplant. Finally, the ultimate vascular reconstruction has been a robotic-assisted kidney transplantation where all anastomoses, both vascular and ureterovesical have been performed with the aid of the daVinci™ robot (29).

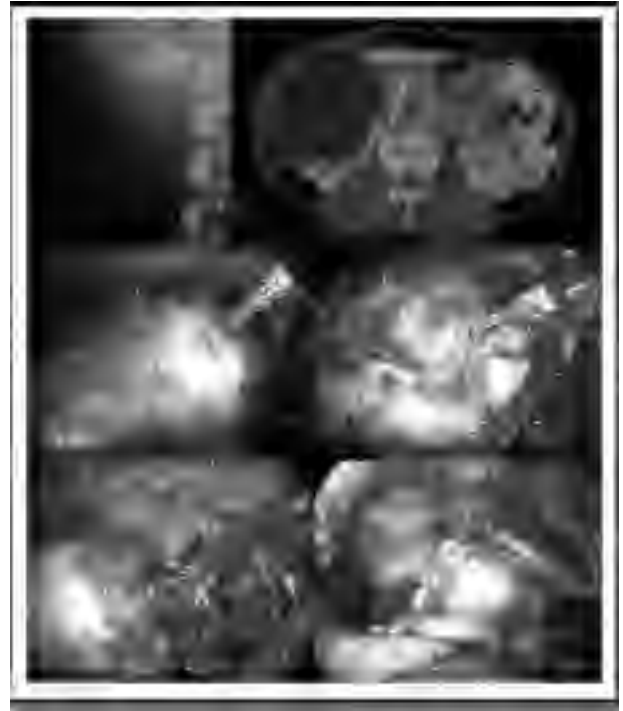
Pyelocaliceal Diverticulectomy

Gluckman first reported a laparoscopic ablation of a pyelocaliceal diverticulum by unroofing and ablation, but little was mentioned in the way of reconstruction (30). Two separate reports of pyelocaliceal diverticula ablations have been reported (31,32). In both cases, the anterior diverticula were incised and the linings marsupialized and fulgurated. Omentum was used in the first case and the colon in the second to isolate and cover the exposed raw surfaces. Since then, there have continued anecdotal reports of a case and one published small series representing five cases with detailed description of technique. In this series, a vertical incision was made over the thinnest avascular plane over the diverticulum. All stones or stone debris is removed into an endoscopic sack. Figure-of-8 3-0 polyglactin sutures were used to obliterate the ostium. An argon beam coagulator was used to obliterate the epithelial lining after thorough inspection to insure no inadvertent malignancies. Adjacent perirenal fat is mobilized and sutured into the diverticular defect. A Jackson-Pratt drain is placed prior to exiting. Stents were utilized routinely (32). A final series of four cases has been recently described on the management of type II pyelocaliceal diverticula (Fig. 3). Two of these four patients underwent laparoscopic repair in a similar fashion to that reported by Miller with excellent outcomes and functional recovery of the kidneys (33).

Nephropexy

Nephroptosis and the "floating kidney" are most commonly identified in thin, young females and preferentially involve the right side. It has an uncertain incidence in the modern era, but the correction of this condition resulted in large series published in the early modern surgical literature (34). With the advent of laparoscopic techniques, it is certainly possible to provide surgical fixation to these "floating kidneys." Urban first reported a laparoscopic nephropexy in 1993 using clip fixation techniques (35). Elashry et al. presented a group of six patients who underwent two methods of laparoscopic nephropexy: transperitoneal (4) and retroperitoneal (2). The nephropexy was performed using a vertical and horizontal row of 1-0 silk sutures through the renal capsule into the quadratus lumborum fascia. Mean operative time was four hours (range, 2.5–7 hours) (36). Larger series with longer follow-up is now available. Plas et al. (37) presented 30 patients who have had a transabdominal laparoscopic nephropexy since 1992; 17/30 have been followed for greater than five years and all are asymptomatic. In 10 completely evaluated patients, 8 have no nephroptosis but 2 (20%) have greater than 5 cm displacement. Their technique is decidedly different than the Washington University series. They describe fixation using a polypropylene mesh shaped like an ellipse to cover the sagittal aspect of the kidney during active cephalad displacement. Fascial staples are used to fix the mesh to the abdominal wall from the upper pole to the lower. The average operating time was 154 minutes (range 90–300 minutes) (37). A final series comes from Lubeck, reporting transperitoneal laparoscopic nephropexy in 22 women and 1 man. A round-bodied double-stranded No. 2 nonabsorbable polyester suture was passed via the abdominal wall and used to fixate the upper pole to the psoas or quadratus lumborum with a single simple stitch. A second suture is made to fix the convexity of the kidney laterally. They compared this procedure to 12 open nephropexies performed at their hospital showing previously.

FIGURE 3 ■ Laparoscopic type II pyelocaliceal diverticulum.

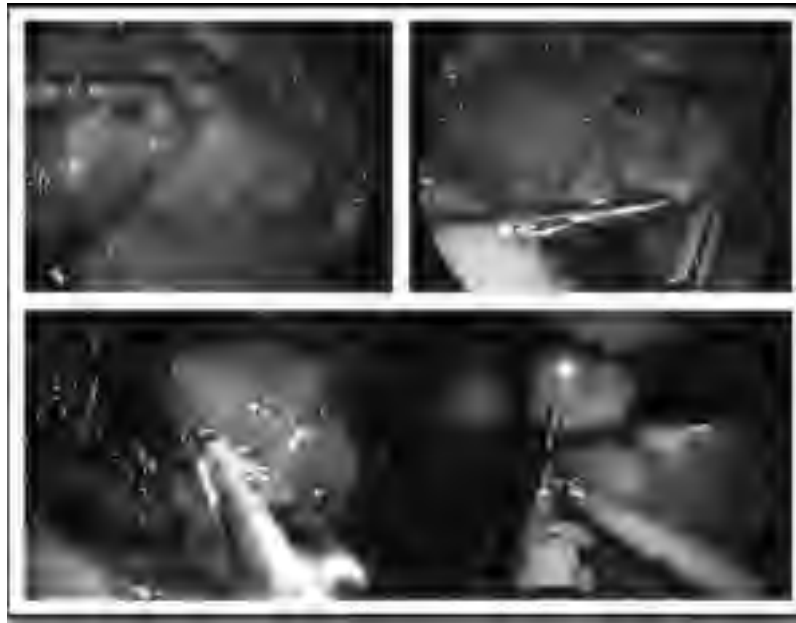

The mean operative time was 61 minutes (40–85) laparoscopic versus 49 minutes (28–70) for open nephropexy. Narcotic use, complications, hospital stay, and mean days to return to work all favored the laparoscopic approach. All patient in this series had correction of the nephroptosis by intravenous pyelogram at six weeks. There appears no definite method that reliably fixes the kidneys from these series, but the historical literature is replete with methods of renal fixation, well over 170 operative techniques. Szekely recently reported in a letter to the editor of the “Journal of Urology” that the same thing could be accomplished by placing a circle (U) nephrostomy tube for two weeks (38).

Ureteral Reconstruction

The ureter has been opened, repaired, or reconstructed predominately utilizing sutured techniques (39). Nezhat probably was the first to report a clinical application of intracorporeal-sutured reconstruction of a ureter obstructed by endometriosis. Excision of the involved segment and ureteroureterostomy was performed over 7 French catheter with four interrupted 4-0 absorbable sutures. A CO₂ laser was utilized for the bloodless dissection prior to reconstruction with an estimated surgical time of 117 minutes (40). Wichham explored and performed a laparoscopic ureterolithotomy without repair of the ureter in 1978 (41). Closure of the ureteral wall following ureterolithotomy was described utilizing a running 4-0 absorbable sutures® anchored on each end with absorbable clips (42). The procedure lasted approximately 180 minutes. We have recently resected a stenotic segment of ureter with an eroded proximal calculus and performed a Heineke-Mikulitz type of ureteroureterostomy with interrupted 4-0 chromic gut sutures intracorporeally tied over a stent (Fig. 4). A case of a right circumcaval ureter requiring transposition has also been reported (43). Retrograde dissection of the right ureter from the iliac vessels identified the post caval segment. Next, the middle third of the ureter was dissected until it passed behind the cava to the renal hilum. The renal pelvis was identified and dissected to the area of obstruction, divided, the distal ureter was spatulated and anastomosed with five 4-0 polyglactin interrupted sutures over a wire guide. This procedure was accomplished in 560 minutes and stented following the repair. Others have repeated the procedure of ureteral repair for retrocaval ureter, most now support a complete intracorporeal sutured repair (44). The laparoscopic approach and treatment of benign retroperitoneal fibrosis has been described (45). After mobilizing the ureter in a 15-year-old female, the ureter was secured within the abdomen with a biting clip applicator. The correction of vesicoureteral reflux using laparoscopic biting clips to reapproximate the muscularis over the distal ureter and create a nonrefluxing tunnel has been described in the porcine model (46). There are now several series in which retroperitoneal fibrosis has

FIGURE 4 ■ Laparoscopic ureteral exploration for an eroded proximal left ureteral calculus. Use of an arthroscopic hooked-blade knife is shown (*above left*), and stone extraction (*above right*). Sutured reconstruction over a stent with interrupted 4-0 chromic intracorporeal stitches is shown below.

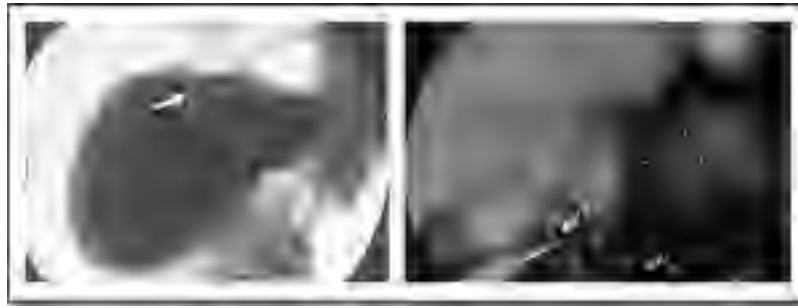


been explored, biopsied and peritonealization of the ureter has been accomplished. In fact, Puppo et al. have even reported upon the classic method of bilateral ureterolysis because of the risk of bilateral involvement (47). Finally, the ureter has been taken apart and reconstructed laparoscopically with intracorporeal suturing techniques for severe endometriosis in nine patients. Long-term follow-up for these laparoscopic ureteroureterostomies is available between two months and seven years. Only one patient developed a mild ureteric stricture that required balloon dilation (48).

Bladder Reconstruction

Most laparoscopic bladder reconstructions to date have been performed with linear cutting staplers. A growing number of sutured reconstructions include diverticulectomy, closure of traumatic cystorrhaphies, ureteroneocystostomy, ureterocystoplasty, augmentation cystoplasty, seromyotomy (autoaugmentation), and partial cystectomy (49). The bladder neck has been suspended and bladder neck slings have been placed with the aid of laparoscopic sutures. Das reported resecting a large bladder diverticulum and suturing the ostium with 3-0 polyglycolic acid in a continuous, double-layered fashion (50). Intracorporeal knotting was utilized and the procedure took 288 minutes. Most bladder diverticuli are posterior and tend to be eccentrically located at or near a ureteral orifice. We have used simultaneous flexible cystoscopy and ureteral illumination to aid in the dissection and sutured reconstruction (Fig. 5) (51). Laparoscopic sutured cystorrhaphy following an iatrogenic intraperitoneal bladder laceration has been reported (52). A 75-year-old male with a large intraperitoneal bladder perforation required laparoscopic two-layered running suture repair. Using 3-0 polyglycolic acid suture (first layer mucosa and muscularis and second muscularis and parietal peritoneum) all knots were tied intracorporeally. The entire procedure of laparoscopic cystorrhaphy lasted 27 minutes. Two cases of vesicoureteroplasty have been reported (53). A two-year-old boy and a five-year-old girl with grades III and IV vesicoureteral reflux underwent laparoscopic mobilization of the distal ureter for 3 to 4 cm. A 3 cm straight horizontal myotomy was then created as a tunnel with the ureter sutured in situ by four 3-0 polyglactin, interrupted sutures. Extracorporeal knotting was used in the first case and intracorporeal knotting in the later. The mean time for vesicoureteroplasty was 182.5 minutes (range 170–195 minutes). Seromyotomy or bladder autoaugmentation has been performed laparoscopically at several centers (54,55). Very little reconstruction is necessary following excising a portion of the detrusor muscle. Detrusor flaps were sutured to the pelvic sidewall at Cooper's ligament utilizing 1-0 polyglactin secured intracorporeally with clips. The time of surgery ranged from 70 to 330 minutes. Augmentation cystoplasty utilizing xenograft human lyophilized dura mater and collagen-impregnated polyglactin mesh were accomplished laparoscopically in beagles (56). The bladders of four animals were opened after the fashion of Blaivas and bilateral vesicopsoas hitches were performed utilizing 3-0 polyglactin sutures with intracorporeal knotting. This type of bladder

FIGURE 5 ■ Laparoscopic bladder reconstruction of the large bladder diverticulum containing a stone. In the cystogram on the left, the bladder is the smaller contrast-filled cavity and the stone is filling defect within the diverticulum. Endoluminal assistance was provided by the use of a intravesical flexible cystoscope and a ureteral illuminator. *Source:* Cook Urologic, Spencer, IN.



opening allowed onlay of the xenograft such that two simple suture lines could accomplish the cystoplasty (Fig. 6). Running 4-0 polyglactin sutures synched with intracorporeal knots allowed the cystoplasties to be water tight with an average time of surgery of 134 minutes. One case of laparoscopically assisted continent catheterizable cutaneous appendicovesicostomy has been accomplished (57). A 15-year-old female with an obliterated bladder neck from multiple previous surgeries underwent mobilization of her appendix laparoscopically utilizing a 12 mm linear cutting stapler. The cecum was reattached to the side wall with absorbable sutures tied intracorporeally. The appendix was anastomosed isoperistaltically to the bladder via a trocar passed transvesically. The base of the appendix was delivered through a predetermined stoma site via a 10 to 11 mm trocar and the appendicovesicostomy was finished using the Mitrofanoff principle with a 4 cm subepithelial tunnel through a small open cystotomy. The total operating time was 360 minutes. Finally, Anderson et al. described an animal model for laparoscopic continent urinary diversion in swine (58). In nine male swines, in situ ureterosigmoidostomy in a 5 to 6 cm detubularized rectosigmoid pouch was performed. A Boari flap for reconstruction of the distal ureter has been described by several investigators. The first case was done because of distal ureteral involvement by endometriosis (59). A series has been presented by the Johns Hopkins group. There were two left and one right sided distal ureteral obstructions with 6 to 8 cm of distal ureteral involvement. An anterior bladder flap was harvested from the bladder after dividing the superior and middle vesical arteries with the Endo-GIA. The ureter was anastomosed to the flap using interrupted 4-0 polyglactin suture (60).

Visually guided transvaginal techniques have been employed in seven women with types I and II genuine stress urinary incontinence (61). A formal intracorporeal Burch and Marshall–Marchetti–Krantz suspension has been performed in over 92 incontinent patients with a mean operative time of 65 minutes. One to two 2-0 nylon sutures are placed on either side of the bladder neck and then into Cooper's ligament or the pubic periosteum (Fig. 7) (62,63). Bladder neck suspensions for genuine stress urinary

FIGURE 6 ■ Laparoscopic augmentation cystoplasty in a canine model.

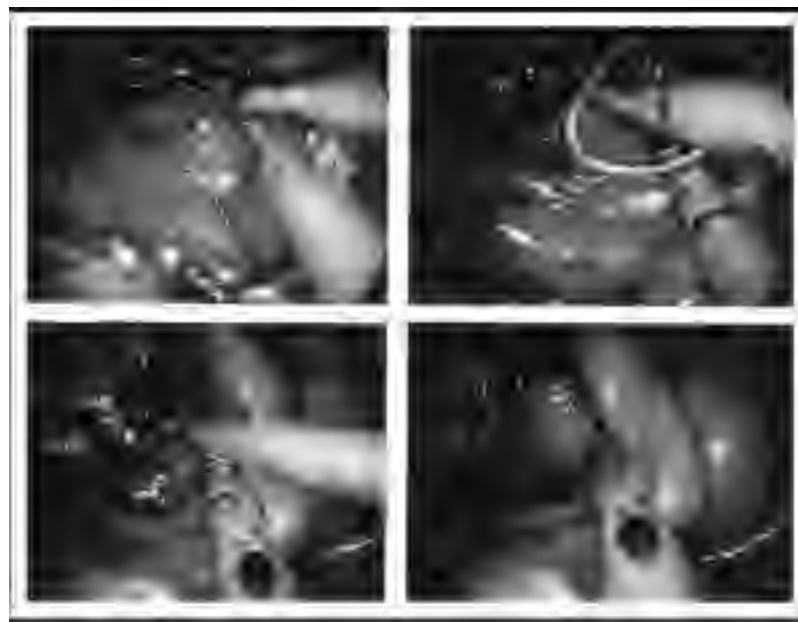


incontinence were being widely performed, but long-term follow-up investigations have failed to adequately demonstrate that laparoscopic colposuspension maintains continence (64,65). Some centers continue to persist in evaluating the potential for laparoscopy to treat stress urinary incontinence (66). Laparoscopic mesh fixations have been performed for severe pelvic prolapse syndromes in women. The "gold standard" sacrocolpopexy has now been performed laparoscopically. Of the vaginal restorative procedures, uterosacral ligament vault suspension, iliococcygeous and sacrospinous fixation each have their proponents. There is marked utilization of mesh materials to reconstruct these prolapse syndromes requiring suturing to these anatomic structures. All types of prosthetic mesh materials are being investigated and utilized (67).

The urachus is an unusual site for urologic disease, but it too has been successfully approached by laparoscopic maneuvers. Most commonly, urachal sinuses and cysts have been laparoscopically resected and ligated. More common in children, these occasionally present in adulthood. A case of a 34-year-old male underwent a laparoscopic resection of a 4 cm cyst from the urachus using a voice-controlled laparoscope (68). One series of pediatric management of urachal anomalies has been published. Four children ranging in age from 4 to 10 underwent laparoscopic radical excision of the urachus (69). Four adults have also been managed laparoscopically in a report by Cadeddu et al. In these cases the urachus, and medial umbilical ligaments were detached just caudal to the umbilicus and dissected caudad to the bladder dome. In three-fourth cases, a bladder cuff was taken with the specimen because of fibrotic attachments. The bladder defect in these cases was sewn in two layers with 2-0 polysorbate loaded on an EndoStitch® device (70).

Laparoscopic cystectomy represents the ultimate surgical site for laparoscopic urologic reconstruction. For purposes here, the radical prostatectomy portion that requires reanastomosis to the urethra will be considered separately and discussed later. Now, attention will focus upon methods of laparoscopic cystectomy and urinary diversion. Brief mention will also be placed upon laparoscopic efforts at urinary undiversion. Initially however, the first attempts at laparoscopic bladder reconstructive surgery focused upon bladder diverticula resection and repair. Automated staplers have a wide application for laparoscopic procedures involving the bladder. The multifire linear cutting stapler has been used to divide the vascular pedicles and urethra during a laparoscopic cystectomy in 27-year-old female with recurrent pyocystis and previous urinary diversion (50). The endostapler has also been used to close bladder defects following diverticulectomy and distal ureterectomy for upper tract transitional cell carcinomas (71,72). Parra et al. reported the first laparoscopic bladder diverticulectomy in an 87-year-old man with a superiorly positioned, narrow-necked diverticulum and chronic urinary tract infections. Adequate healing without urinary extravasation was documented by cystography, eight days after surgery (73). In addition to expediting surgery, automated staplers may have an added benefit during excision of bladder diverticula containing urothelial malignancies by preventing potential spillage of tumor cells into the peri-

FIGURE 7 ■ Laparoscopic Burch colposuspension with 2-0 nylon sutures placed and tied intracorporeally.



toneum. Neoplastic changes in the lining of diverticula occur in approximately 0% to 13.5% of cases (74-77). Laparoscopic division of a bladder cuff during nephroureterectomy and ureterectomy in porcine experiments and humans has been described by Kerbl et al. (78). After cystoscopically incising the ureteral orifice and submucosal tunnel, a 2 cm juxtaureteral bladder cuff is dissected laparoscopically. A linear cutting, multifire stapler is then utilized to close and excise the cuff of bladder (79).

Parra was the first to perform a laparoscopic cystectomy in a patient with pyocystitis. Porcine animal studies have been performed to evaluate methods of cystectomy and urinary diversion. Anderson and Clayman described a method of ureterosigmoidostomy (79). Kaouk et al. presented an animal model of orthotopic ileal neobladder (80). Baldwin described an attempt to simplify the laparoscopic reconstructive effort by using the "dunk" technique for ureteroileal anastomoses. In addition, they used Lapra-Ty suture clips^a to facilitate intracorporeal knotting. Two-thirds of the "dunked" ureters were partially or completely strictured. In addition, the short cut method of knot substitution resulted in Lapra-Ty migration and subsequent urinary obstruction by the foreign body in two animals (81). Now, laparoscopic radical cystoprostatectomy is becoming increasingly performed. Large series are beginning to accrue patients into the laparoscopic group. Simonato recently reported their technique in 10 patients using a five-port technique. The urinary reconstructive aspects included the orthotopic ileal neobladder in six, sigmoid ureterostomies in two, and cutaneous ureterostomy in two. The mean operating room time was 166 minutes (range, 150–180). Two patients have diffuse metastatic disease with eight are free of disease at a mean 12.3 months (range 5–18) (82). Another method has been utilized by Abdel-Hakim et al. Laparoscopic radical cystoprostatectomy was performed in nine patients. Here the authors removed the laparoscopic specimen through a 3 to 5 cm right iliac fossa incision through which a detubularized modified Camey II orthotopic neobladder was performed (83). Matin and Gill from Cleveland have detailed their method of completely intracorporeal urinary diversion following laparoscopic radical cystectomy. Here the authors performed a completely hand-sewn anastomosis of the orthotopic neobladder and the ureteroileal anastomoses (84). They have summarized the application of this technique in two patients using six ports with an average time of 9.5 hours (85). This same group previously published a series of five patients who had undergone a laparoscopic radical cystectomy with ileal conduit urinary diversion using a six-port technique (86). Another group has performed 11 laparoscopic radical cystectomies with intracorporeal construction of a continent urinary diversion (Mainz pouch II). Their average operating time was 6.7 hours (87).

Segmental bowel excision and reconstruction using automated staplers has been practiced during open surgery for many years. Bohm et al. described the technique of laparoscopic intestinal resection and intraperitoneal reanastomosis (88). After mobilization of the selected intestinal segment and isolation of the vascular pedicle, the linear cutting stapler is inserted into enterotomies on the antimesenteric border of afferent and efferent limbs of the future anastomosis. Two consecutive firings of the 3 or 6 cm stapler creates a 5 to 11 cm anastomosis. A cotton umbilical tape encircling the bowel close to the anastomosis provides countertraction and prevents spillage of intestinal contents into the peritoneum. Firing the linear stapler across both loops of bowel near the corner of the anastomosis transects the specimen and completes the anastomosis. Kozminski reported the first urologic application of automated stapling for laparoscopic bowel resection and intracorporeal ileal conduit formation (89). His initial clinical case involved performing the palliative supravescical diversion in an 83-year-old male for unresectable fibrosarcoma of the prostate. Intracorporeal ureteral and bowel mobilization was accomplished through six 10 to 12 mm trocars. Bowel resection and reanastomosis were performed extracorporeally with linear stapling devices after evacuating the pneumoperitoneum and pulling the bowel through the 12 mm port site. Once the resected bowel segment was mobilized the mesentery is closed intracorporeally with biting clips and the ureteral anastomoses were accomplished extracorporeally by suturing techniques after mobilizing the ureters. Securing the conduit to the retroperitoneum was again accomplished by biting clips applied intracorporeally. Two subsequent patients have had ileal loop diversion with entirely intracorporeal bowel resections and reanastomosis using these staplers (89). In all three patients, the ureteroileal anastomoses were sutured extracorporeally. This same technique has been repeated by others (90). Other applications for these techniques would be urologic reconstructions utilizing other gastrointestinal segments. Augmentation cystoplasty can be performed with harvested gastric, small bowel, or large

^aEthicon Cincinnati, OH.

bowel segments. Ureteral interposition or replacement could theoretically be performed. Finally, supravescical diversions with ileal conduits represent only one of many methods of noncontinent and continent heterotopic or orthotopic bladder replacement techniques. Automatic, linear cutting staplers have the potential to make such urologic reconstructions possible. The lithogenic properties of metallic staples used for urinary tract reconstruction are well known. Stone formation attributed to exposed steel staples occurs in 3.2% to 4.2% of patients with ileal conduits and 4.9% to 10% of patients with Kock pouches (91–94). The lithogenic potential of titanium staples exposed to human urine is not known. Kerbl et al. have used a linear titanium stapling device to excise a bladder cuff during nephroureterectomy in six adult humans (78). Three patients have been followed more than a year without complication and/or endoscopic evidence of staple exposure. Endoscopic verification of the lack of exposed staples and over sewing the staple line are recommended by some authors. Prototypic automated staplers using dissolvable staples are currently under study. Julian and Ravitch compared stone formation on exposed stainless steel and PolysorbTM^b absorbable staples used to close the bladder in dogs. Although staple exposure was much higher in bladders closed with absorbable staples (56% vs. 2%), crystal formation more commonly occurred on exposed stainless steel staples (25% vs. 7%) (95).

Laparoscopic augmentation cystoplasty has also been investigated. Early efforts attempted to use novel biomaterials such as intestinal submucosa (96). Others have utilized tissue expansion techniques to expand the native ureter and augment the bladder with this laparoscopically (97). The small bowel has been utilized during a transverse hemicystectomy with ileocystoplasty in the porcine model (98). Finally, Siqueria et al. described the synchronous correction of small bladder capacity by laparoscopically augmenting the bladder with ileum, but also performing a continent ileovesicostomy in the porcine model (99). The next step of course was clinical application. The first reported case of laparoscopic ileocystoplasty was Sanchez de Badajoz's case report of a patient with urinary tuberculosis. An isolated segment of ileum was taken using Endo-GIA staplers. The enterocystoplasty was performed with two firing of the Endo-GIA stapler plus the addition of holding sutures (100). Three patients were described by Gill et al. using different bowel segments in each of these cases. The functionally reduced bladder capacities were augmented using the ileum, the sigmoid, and the cecum and proximal ascending colon in these patients (101). In reporting the application of laparoscopic ileal cystoplasty, Elltiott et al. noted some important technical considerations. Important to this operation included (i) preoperative evaluation of compliance and videourodynamics; (ii) cystoscopic placement of externalized ureteral catheters; (iii) transperitoneal placement of trocars; (iv) identification of the cecum; (v) proximal mobilization of the ileum sufficient for pelvic placement; (vi) measurement of ileal length with segment of precut vessel loop; (vii) vertical cystostomy after incision of the peritoneum and entering the space of Retzius; (viii) ileal division and side-to-side anastomosis using Endo-GIA stapler; (ix) detubularization and freehand intracorporeal suturing into a U-shaped configuration; (x) fixing ileal patch at the 6 and 11 o'clock positions; (xi) completion of ileal-bladder anastomosis in quadrants with running sutures; (xii) irrigation of bladder and placement of a closed suction drain into the pelvis; and (xiii) cystogram at four weeks postoperatively (102). Because of the hazards associated with enterocystoplasty, the search for an ideal substitute continues even in the minimally invasive era. One recent investigation used a variety of different biodegradable grafts in an animal model. Thirty-one minipigs underwent transperitoneal laparoscopic partial cystectomy and augmentation cystoplasty using nothing (six controls), porcine bowel acellular tissue matrix (6), bovine pericardium (6), human placental membranes (6) or porcine small intestinal submucosa (6). All three grafts had only mucosal regeneration at 12 weeks postoperatively and all had contracted to between 60% and 75% of their original sizes (103).

The bladder has not only been the target of intense endourologic research interest, but it has finally been reconstructed in a variety of methods. This brings the discussion full circle, as is fitting. Wolf and Taheri have recently reported a laparoscopic undiversion. This was in a 25-year-old man who had undergone an open ileal conduit diversion and colostomy with mucous fistula for a gunshot wound 11 months prior to presentation. The colostomy and mucous fistula were taken down first and an extracorporeal bowel anastomosis was performed. Next laparoscopic trocars were positioned and the bladder dome and abdominal portion of the ileal conduit were mobilized. A single layered ileovesical anastomosis was performed using a 4-0 absorbable suture (104).

^bU.S. Surgical Corp, Norwalk, CT.

Vesicourethral Anastomosis

Laparoscopic reconstructive surgery has been applied to one of the most difficult repairs urologists perform, vesicourethral reanastomosis following radical prostatectomy. First attempted clinically in 1992, research work in animal models continues (105). In combined canine series of 20 animals, the radical retropubic prostatectomy and reconstruction was accomplished with a mean operative time of 294.5 minutes (106,107). In the study by Moran et al. the laparoscopic reconstruction was performed with the laparoscope closely approximated to the tissues for a microscopic repair. Six to eight fluorescently colored polyglactin intracorporeal sutures were placed utilizing microsurgical suspension techniques to convert square knots to slip configurations and back (Fig. 8) (106). No Foley catheters were positioned so as to evaluate the completeness of the microlaparoscopic repair (Fig. 9). One anastomotic leak occurred in six animals available for long-term follow-up. Minimal scarification was noted grossly or on trichrome stained sections in animals at necropsy (Fig. 10) (106).

Clinical application of laparoscopic repair of the vesicourethral anastomosis has been widely performed. There appears to be two basic approaches by review of the literature. There are those who favor an interrupted anastomosis and those who prefer a running anastomosis. There is no prospective randomized data to support either philosophy at present. Claims for almost any belief suggesting an advantage or disadvantage for each technique can be found. For instance, there are those who suggest that the running anastomosis simplifies and facilitates the repair. But there is a large series that argues the opposite (108). There are investigators that believe that the anastomosis capable laparoscopically is potentially better than its open counterpart. Large series are just beginning to be able to investigate this possibility. The complications from the vesicourethral anastomosis should be less. Urinary extravasation should be minimal. In one current series, Menon's group has now begun to leave no postoperative drains when they use a running anastomosis (109). Bladder neck contracture should likewise be lowered, but the exact incidence even in open series is not known (110). One such investigation noted contracture in 11% of radical prostatectomy patients (111). The data are not yet fully available, but there are groups suggesting that symptomatic bladder neck contractures are less following the laparoscopic repair. Is this due to the anastomotic technique or rather secondary to the method of prostatobladder neck division or to the method of mobilization of the bladder for performing a laparoscopic radical prostatectomy? Innovative investigations that might answer this question are beginning to emerge but follow-up remains short (112). A new semiautomatic suturing device has recently been reported from Yamada et al., called Maniceps. Using this device in 15 patients, the urethrovesical anastomosis was completed in 8.1 minutes (range 5–12). They report one bladder neck contracture at short followup (113). Another recent investigational method used 2-octyl cyanoacrylate adhesive for an in vivo canine study to glue the anastomosis in 12 dogs. Four anastomoses were performed with eight interrupted

FIGURE 8 ■ Suspension stitch technique for converting square knots to slipknots.






FIGURE 9 ■ Voiding cystogram following laparoscopic radical prostatectomy and microsurgical vesicourethroplasty in a canine model.




FIGURE 10 ■ Gross pathology of laparoscopic intracorporeal reconstruction eight weeks following radical prostatectomy.

sutures compared to eight using the adhesive. Only one of the adhesive animals anastomoses had leak pressures 70 mmHg or greater whereas all four control suture animals achieved this expected outcome (114). Laser welding has also been attempted in the canine model to facilitate this anastomosis. This was an open radical prostatectomy model, but four animals had a conventional eight interrupted suture technique while the experimental group had four support sutures followed by a diode laser welded anastomosis using a chromophore doped albumin solder. They noted superphysiologic leak pressures in all of these animals with no other differences in healing (115).

ROBOTIC RECONSTRUCTION

Introduction

The next generation of surgical robotics required the downsizing of mechanized instruments to reproduce the complex ability of the surgeon's arms and hands (116). Next, the surgical tools themselves needed to be added or subtracted from the devices so that surgical multitasking was possible. To control and coordinate the functions of the robot requires a computer. The computer is responsible for interpreting the surgeon's actions and transforming them into the movements of the robotic arms and hands. This requires incredible fidelity and incorporates a wide range of motion. The computer is translating the surgeon's movements into precise codes to smoothly and rapidly manipulate the robot (Fig. 11). Here the robot is in direct contact with the patient and the surgeon is removed to the controlling station. As with the laparoscopic surgery removing the surgeon from actually seeing the surgical field, the robotic hands are removing the laparoscopic instruments from actually touching and performing the surgery. The actual robotic tools, or end-effectors are located at the distal end of long instruments which are inserted into the patient through laparoscopic trocars. The movement of the instruments is controlled manually at the work station. To allow the end effector to be maximally effective at least six degrees of freedom are necessary.

A great deal of research effort has been applied to solve the problem of the actual surgical interface (117–119). That is what type of device is best for the surgeon to manipulate that will provide the computer with the information necessary to perform the surgery. Possibilities include scissor-like hand pieces that provide the computer with the data necessary to manipulate the end effector. Glove-like input devices have been proposed and view-directed controls utilizing the endoscopic image itself to be the frame of reference are being investigated. Some input devices are position controlled and others are direction controlled. In the former, the movement of the end-effector is coupled to the movement of the input device by the surgeon. A continuous movement of the input device is needed to achieve continuous movement of the end-effector. In the direction-controlled interface, the input device controls the velocity of the end-effector. Therefore, no continuous movement is necessary to achieve continuous movement of the end-effector. One study evaluating various input devices included a spacemouse, free-flying joystick, immersion probe, and head-tracking systems. Wapler suggested that for guiding the endoscope a head-tracking system would allow a more intuitive method of control (120). For manipulating the end-effector, the following requirement should be met: the manipulator must be compact enough to allow at least three systems to work independently without danger of collision, the patient should be manually accessible at all times, the insertion point must be kept invariant when moving the end-effector, allowance must be made for patient movements, all endoscopes and instruments must be manually controllable in case of manipulator failure, and the movement of the end-effector must not be self-locking. In addition, there are three options for supporting such a robotic system in the operating room, these include namely, a stand-alone system, a ceiling-mounted system, or a system that attaches to the operating room table. Both the stand-alone and ceiling mounted systems would require more room and have special precautions to ensure that no relative movement occur between the operating room table and the manipulator's base. At the beginning of surgery, the abdomen is prepped and draped in the same fashion for laparoscopic surgery. When the trocars have been positioned, the manipulators are attached to the operating room table. Each manipulator is manually brought into position such that the invariant point is exactly at the trocar. When all of the manipulators are in place, the actual surgical procedure is begun. Currently the surgeon has only visual feedback from the video-monitor. There are ongoing efforts to include force-feedback (i.e., haptic input) into the robotic manipulators so the surgeon can perceive subtle nuances of the laparoscopic environment (121).

FIGURE 11 ■ The *da Vinci*® Robotic Surgical Assist System.



There are two currently available laparoscopic robotic units in use, the Zeus® system and the *da Vinci*®^c system, however others are in the works. The Zeus system has recently been acquired by Intuitive Surgical and the systems may possibly merge, but the *da Vinci* system was approved in July, 2000 in the United States. The Zeus™ Robotic Surgical System has an ergonomic workstation with rather conventional appearing handles. The surgeon's movements are scalable to the surgeon's specifications. A ratio of 5:1 means that for every inch the surgeon moves the handles on the console, the robotic surgical instruments would move one-fifth of an inch. Tremors can be filtered out as well. The Zeus computer translates the surgeon's movements to the end effectors placed via trocars inside of the patient. The instruments themselves act similarly to conventional laparoscopic devices except that the surgeon does not actually touch them. The monitor on the Zeus system is a standard video image, the surgeon does have the option of wearing specialized binoculars to view the image in three-dimensional (3-D). The *da Vinci* company has the capability to add three-dimensional imaging full time without the need for the special glasses, but current research has not demonstrated a significant advantage for these image systems. The other robotic system is *da Vinci*. This robotic surgical system has an articulated wrist that allows six degrees of freedom during the performance of laparoscopic surgery (Fig. 11). This wrist addition allows for the two additional degrees of freedom and there is some basic evidence that that additional motion translates into more adaptive ability by skilled and nonskilled surgeons. The downside to the *da Vinci* instrument tips would be that they are more complex, necessitating the 8 mm trocar portals. The *da Vinci* surgeon console

^cIntuitive, Sunnyvale, CA.

does not approximate anything like standard laparoscopic instruments. The surgeon's hands, wrists, and fingers manipulate a patented articulated Endowrist™. This type of system is necessary to take advantage of the laparoscopic instruments' dexterity. The other major difference of the two surgical robotic systems lies in the *da Vinci*™ ergonomic viewing console (Fig. 11). The surgeon sits at the console which is designed to support the surgeon's head while viewing the three dimensional image and has a separate adjustable surface on which the surgeon can rest his/her arms. The vision system is fully three-dimensional and integrated in the performance of the two robotic arms. The *da Vinci* system is a stand-alone device that moves in toward and over the patient whereas the Zeus system is component and attaches to the sides of the operating room table as does the separate and independent AESOP™ arm. In both robotic systems, the fidelity of movement is superb and the time delay from surgeon's movement to the robotic instrument movement is imperceptible. The cost of each system is above US\$900,000 currently (121).

General Application

Numerous cardiothoracic, general surgical, gynecologic and urologic procedures have been attempted either in animate laboratories or clinically (Fig. 11) (122–133). Most of these studies have been case reports with series only available for evaluation of outcomes in cardiac surgery. A case report of computer-assisted robotic Heller myotomy in a 76-year-old female with progressive dysphagia was performed in Columbus, Ohio (123). The *da Vinci* system was utilized using four operative cannulas (5 mm liver retractor, two 10 mm working ports in the patient's midline and left midclavicular line, and one 5 mm port in the left anterior axillary line). An assistant surgeon stayed at the patient's bedside and controlled retraction and changed instruments on the robotic arm. The total operative time was 160 minutes and she was discharged the following day. Another case report again utilized the *da Vinci* system to perform a Nissen fundoplication on a 56-year-old female with longstanding gastroesophageal reflux (124). This was performed using five trocar ports; 12 mm supraumbilical 30° camera (used a robotic camera system), 10 mm right anterior axillary port for liver retraction (used a mobile table-mounted mechanical self-retaining device), and two 10 trocars for the right and left hands of the *da Vinci* robot. The patient's position was in low lithotomy position with the table in steep reverse Trendelenburg setting. The surgeon was approximately 10 ft away from the patient and the assistant was stationed between the patient's legs. The assistant performed the instrument changes and utilized a harmonic scalpel. There was no operative time listed but the patient was discharged from the hospital within 24 hours. The largest general surgical series has recently been reported from the group in Strasbourg, France on laparoscopic robotic cholecystectomy (125). These authors reported the laparoscopic, robotic cholecystectomy in 25 patients (16 women and 9 men) with a median age of 59 (range 28–81). They used the Zeus surgical robotic system with four laparoscopic trocar sites (one 10 mm umbilical camera port and three 5 mm ports for retraction and robotic surgery). The Zeus instruments were 3 mm in diameter and the surgeon was remote (4 m) from the patient and AESOP was used to voice control the camera. The assistant stayed at the operating room table to aid in retraction, clip application, and exchanging instruments. Completely robotic cholecystectomy was accomplished in 24/25 patients and one patient was completed with standard laparoscopic methods. The median time for the dissection was 25 minutes (range, 14–109 minutes). The median time to setup and take down the robotic system was 18 minutes (range, 13–27 minutes). An engineer was present in 22 of the cases making three minor technical adjustments (two nonfunctional graspers and one malfunctioning robotic arm sensor). Laparoscopic splenectomy, an extirpative surgical procedure has recently been accomplished with the *da Vinci* robot (126). A 69-year-old female was seen with idiopathic thrombocytopenia purpura. The patient was placed in steep reverse Trendelenburg position after placing one 11 mm camera port, two 8 mm robotic arm ports, and one 11 mm assistant port. The surgeon was 10 feet from the operating room table and used a hook dissector and Cadiere grasping forceps. Short gastric vessels were taken via the 10 mm trocar with an ultrasonic dissector. The spleen was 1000 g and was extracted via morcellation from the 10 mm site after entrapment. The procedure time was 65 minutes, operating room time was 90 minutes, and actual splenic dissection time was 31 minutes. Robotic setup and draping took just nine minutes. One final surgical case has also been reported, robotic pancreatic surgery (127). A 46-year-old female presented with a symptomatic 2.5 cm complex solid/cystic mass at the tail of her pancreas. The robotic surgery was performed in the modified lithotomy position using four laparoscopic ports. The total operating room time 275 minutes with the actual surgery

time of 185 minutes. The pathology was a benign neuroendocrine tumor and the patient left the hospital on postoperative day 2. Robotic bowel and vascular surgery is being investigated (128).

Gynecologic surgeons have also performed robotically assisted laparoscopic hysterectomies, adnexal surgeries, microsurgical tubal and uterine horn anastomosis. This gynecologic work has been performed at the Cleveland Clinic utilizing Zeus and AESOP in a series of porcine experiments (129–131). Both uterine and adnexal surgeries have been described including microscopic reanastomosis of the fallopian tubes (132). At the University of Texas Medical Branch in Galveston, 11 patients were enrolled into a laparoscopic, computer-enhanced robotic hysterectomy trial (133). Six patients had carcinoma in situ or well differentiated endometrial carcinoma, four had medically nonresponsive postmenopausal bleeding and one had unstaged ovarian cancer. The mean age was 55 (range, 27–77). Four trocars were utilized and operative times were 4/5 to 10 hours. Blood loss averaged 300 cc (range, 50–1500 cc). Hospital stay was two days (range, 1–3 days). There was one open conversion, the fifth patient in this series.

Just to push the envelope a little further, robotic surgery is beginning to be applied to pediatric surgery as well. Recent reports of robotic Nissan funduplications have been published (134). Eleven children with a mean age of 12 (range, 7–16 years) presented with gastroesophageal reflux. The mean operating time for the robotic fundoplication was 136 minutes (range, 105–180 minutes). Four ports were utilized including a 12 mm optical trocar, two 8 mm robotic trocars, and a 5 mm assistant port. There have been two children who have had robotic cholecystectomies with an average time of 137 minutes. Finally, one child has had a robotic bilateral salpingo-oophorectomy for gonadoblastoma taking 95 minutes.

Urologic Applications

Urologic applications have also begun (135–146). In work by Kavoussi's group at Johns Hopkins University, AESOP has been utilized for telementoring and teleproctoring advanced laparoscopic procedures (135). In 1998, Bowersox and Cornum first used a robotic surgical telemanipulator to perform an open urological surgery in swine (136). Sung et al. in 1999 performed robotic-assisted laparoscopic pyeloplasties in a porcine model utilizing the Zeus system (138). Guillonnet's group in Paris began a program in utilizing the Zeus system in the animate laboratory and started to accrue patients into clinical applications performing laparoscopic pelvic lymphadenectomies in 20 consecutive patients with stage T3MO disease (139). They noted no need for open conversions and the average operative time was 2.1 hours, one full hour longer than their usual laparoscopic times. They noted that the time for robotic setup was 30 minutes. Abbou et al. from Creteil, France have also been exploring urologic applications (140). They recently reported the use of the *da Vinci* robotic system to perform a laparoscopic radical prostatectomy in a 63-year-old man with Gleason's sum score of six prostatic adenocarcinoma, clinically staged T1c and a prostate specific antigen of 7 ng/mL. They utilized five trocars (one 12 mm umbilical camera port, two 8 mm trocars located at the lateral rectus sheath, and two lateral 5 mm trocars at the iliac position for the assistant). Robotic instruments used were the Cadiere and DeBakey forceps, two needle drivers, long and round tip forceps, scalpel, electrocautery, and a prototype bipolar forceps. The operating time was 420 minutes, well in excess of their standard operative times of 240 minutes. Assembly of the robot took 30 minutes and disengaging the unit took 15 minutes. The vesicourethral running 3-0 polyglactin suture anastomosis took 30 minutes. These authors mention that the three-dimensional imaging system and the full six degrees of freedom of the *da Vinci* robotic system made in vitro training on animals streamlined to the point that they could proceed to clinical applications quickly. Drawbacks of the system were pointed out to include, lack of tactile feedback, the high cost of the robotic equipment, the cost of disposables (US\$1800 for this radical prostatectomy case), and the time lost to replace the surgical instruments. Guillonnet and the Montsouris group have recently published the first case of robot-assisted laparoscopic nephrectomy (304). They utilized their Zeus™ robotic system in a 77-year-old female with a nonfunctioning, hydronephrotic right kidney secondary to a ureteropelvic junction obstruction. They performed a transabdominal nephrectomy utilizing three robotic arms (Zeus™ and AESOP™). A 10 mm trocar was placed at the right pararectal line for the camera port and AESOP™. Two 5 mm trocars in the right flank in a triangular fashion for the robotic instruments (mainly a forceps in the left and monopolar scissors in the right). A 5 mm trocar was placed at the umbilicus and a 12 mm trocar was placed in the right subcostal region for suction/irrigation, retraction, and application of clips and/or

endovascular gastrointestinal stapler. The operative time was 200 minutes, anesthesia time was 245 minutes, blood loss was less than 100 mL and the patient's postoperative course was uneventful (141).

The probable proliferation of computer-enhanced robotic surgery is beginning to materialize in urologic practice. From robotic-assisted adrenalectomies, retroperitoneal lymphadenectomies, to robotic sacrocolpoplasty; all urologic applications are beginning to be reported (142–144). As with surgical applications these are mostly anecdotal case reports. One group's pioneering efforts deserves special attention, from Creteil France. Hoznek et al. have been attempting to use the *da Vinci* robot to perform kidney transplant surgery (145). A 26-year-old male received a cadaver donor transplant performed with a hybrid open/robotic technique. The operative time was 178 minutes with a robotic vascular anastomosis time of 57 minutes. The authors present several interesting features of eliminating the surgeon from contact with the patient including reduction in the risk of infectious transmission to the surgeons.

There are two urologic surgeries that are begging the attention of the computer-enhanced robotic application, pyeloplasty and radical prostatectomy with urethrovesical reanastomosis. Guilloneau et al. first published on robotic techniques for pyeloplasty in 2000 (146). Currently series are beginning to be reported. Gettman et al. have presented preliminary work on nine patients using the *da Vinci* robotic system to perform four Anderson–Hynes and two Fengerplasty ureteropelvic junction repairs (147). The estimated blood loss was <50 cc, the mean overall operating room time was 140 minutes, and the mean suture times were 70 minutes. There were no open conversions. They have subsequently updated their Anderson–Hynes–dismembered pyeloplasty series to nine with a mean operating room time of 138.8 minutes (range, 80–215 minutes). The mean suturing time 62.4 minutes (range, 40–115 minutes) (148). Other groups with the available technology can be expected to rapidly follow with series (149). Radical prostatectomy with urethrovesical anastomosis is the next frontier. Abbou et al. first reported a case in 2001 as noted previously (140). They have expanded their series and have been performing the entire robotic surgery extraperitoneally. This prefaces the astounding data beginning to flow from the Vattikuti Urology Institute at Henry Ford Hospital in Detroit (150–152). The number of reported robotic radical prostatectomies is over 400 cases currently with rigid follow-up strategies for solving operative problems that are constantly associated with this surgery, incontinence, and impotence (152). The remarkable aspect of this experience is that innovations are already being reported that might enhance the operative technique even more, such as the single knot, two-color running suture (153). Ahlering et al. at University of California Irvine have shown that open surgical skills might be rapidly transferred into the laparoscopic environment with the use of the *da Vinci* robot (154). They report on 12 robotic radical prostatectomies all completed successfully with no open conversions and no blood transfusions. They have been able to equate this skill transfer to approximately the equivalent of a laparoscopic surgeon performing >100 laparoscopic radical prostatectomies. The questions remaining is how good can this operation be performed, what is the learning curve, can the complications of radical prostatectomy be minimized? All of these are approaching the event horizon. Menon's group has estimated that the operative time for a robotic radical prostatectomy is below 150 minutes (155). As their series expands and follow-up times accrue, data regarding impotence, incontinence, bladder neck contractions will all be reported. Others should be able to confirm these findings rapidly and the much anticipated results of brightly illuminated, magnified controlled environment will materialize (156). No one seriously should doubt these possibilities. It has been estimated that about 700 *da Vinci* robotic-assisted prostatectomies were performed in 2003. By the end of 2004, this number is anticipated to be 7000 or a logarithmic increase in the numbers of these cases.

Remote Telerobotic Surgery

It would appear from the previous discussion that most of the framework for operating on people with minimally invasive techniques could be accomplished from remote locations. The ethical, financial, and educational potential for this type of surgery is staggering. But as complex a scenario as this sounds, much basic groundwork is already being done for both research and clinical applications. The term telemedicine has become quite fashionable secondary to the world's rapid acceptance of computerized media and internet connectivity (157–165). Recall the significance of the year 1999, when computers outsold televisions in the United States. In fact, the U.S. government has been a strong supporter of pioneering efforts in the telemedicine field with research grants. The great potential for telecommunications is being realized in digital

radiology practices where the radiologist can view and comment upon clinical radiographs of patients at the hospital from his/her home. Robotic surgery as we have just seen is a technology based upon computer integration of a transducer station and the robotic instrument is the end-effector. The ability to combine these essentially digital computerized modalities is both obvious and possible (166–168). The first problem for interfacing telecommunications and robotic surgery is linking for real-time interaction. Several methods are possible including regular telephone lines, fiber optic cables, microwave transmission, satellite linkages, and broadband communication (integrated services digital network, local area networks, and dedicated T-1 lines). Recently the surgical group at Virginia Commonwealth University used regular internet connections to interact with surgeons in Ecuador and the Dominican Republic to perform six laparoscopic cholecystectomies (168). These surgeons used 33.6 to 64 kbps lines to transmit voice and video.

Telementoring has already been performed for multiple surgeries as well as urologic laparoscopic cases. Dr. Kavoussi's group at John's Hopkins has gained significant recognition for these pioneering efforts. In their initial studies, the surgeon mentor was located in a control room >1000 ft from the operating room; 14 advanced and 9 basic laparoscopic procedures were performed (135). Telementoring was accomplished using real-time computer video images, two-way audio communication links, and a robotic arm to control the videoendoscope. Success was achieved in 22/23 cases without increased operative times or complications. They then extended their investigations and distances between the Johns Hopkins Bayview Medical Center and the Johns Hopkins Hospital (distance, 3.5 miles) for 27 more telementoring laparoscopic procedures utilizing public phone lines. Finally, they have extended their novel surgical instruction capabilities to the international arena with cases in Austria, Italy, and Thailand. Others have reported upon the technology necessary for successful telementoring. The U.S. Navy recently studied the feasibility of laparoscopic hernia repairs aboard the USS Abraham Lincoln while cruising the Pacific Ocean (164). Telementoring was possible from remote locations in Maryland and California. In a recent research investigation, Broderick et al. at the Virginia Commonwealth University reported that decreasing transmission bandwidth does not significantly affect laparoscopic image clarity or color fidelity as long as the laparoscopes are positioned or maintained at their optimal working distance (169).

It was only a matter of time before the *da Vinci* or the Zeus systems, were linked to a remote surgical effector in another place and the actual surgery was performed with the aid of an assistant. The first laparoscopic cholecystectomy done remotely was done in the hall in Montreal, Canada. Kavoussi was the first to perform a surgery remotely from another hospital in the same town. Finally, a surgeon in New York City successfully removed the gallbladder of a patient in Strasbourg, France with a 155 msec time lag. The operation took one hour and 16 minutes. The robotic machines can with little doubt accomplish complex surgical interventions and function without fatigue. Because the surgeon already has given up all visual information to the technology of laparoscopic surgery, the next great step is passing the surgical dissection to the machines.

CONCLUSION

Urologic laparoscopic reconstructive surgery is rapidly expanding at numerous centers around the world. The ability to reconstruct every urologic organ by laparoscopic methods have been reported. The technology to accomplish these dextrous maneuvers is changing rapidly with logarithmic rises in the number of cases. Suturing technology and techniques are the leading methods that are fostering these reconstructions, but the skills and talents of innovators in this field cannot be denied. Mechanical-assist technologies certainly offer the capacity to potentiate or facilitate the complex laparoscopic reconstructions necessary for laparoscopic urologic surgery. In one recent report, Antiphon et al. describe the use of AESOP and another mechanical arm to perform complete solo laparoscopic radical prostatectomy (170). Robotic surgery offers the potential to rapidly integrate these skills to a much broader range of urologists, perhaps even bringing these now sophisticated techniques into the hands of all urologists. In one recent investigation on skill, performance between standard instruments and two surgical robotic systems was compared. It was noted that general task performance utilizing standard laparoscopic instruments is faster but with similar precision with either the *da Vinci* or the Zeus robots. In performing the more sophisticated reconstructive task of suturing, neither robotic system improved the efficiency (as measured by time to

complete the task) as compared to a trained laparoscopic surgeon. However, precision was improved by the addition of the robotic interface. In addition, knot tying, which involves even more intricate intracavitary manipulations noted an improvement in both efficiency and precision with only the *da Vinci* robotic system. These authors conclude that current robotic systems are not “cost” justifiable when compared to skilled, highly trained endoscopic surgeons (171). It therefore seems obvious that laparoscopic suturing skills, no matter how difficult to master, have merit. Almost everything in the operating environment at present for the urologic laparoscopist can be considered a barrier to the rapid acquisition of the skills necessary to master suturing. Yet the brightly illuminated, magnified view beckons for microsurgical reconstruction that may be better than our open counterparts can achieve without the routine use of loupes (156). Recently the group from Cleveland has used the *da Vinci* to perform a sural nerve graft during a laparoscopic radical prostatectomy with a mean operative time of 6.5 hours in three patients (172).

Unique opportunities exist for further continued improvement in reconstructive technologies. Several intriguing technologies will be reviewed for their potential application in the future. Starting with suture technology, it now appears possible that an absorbable suture can be manufactured that does not require knots at all. Medical textiles research has become increasingly aware of the limitations imposed by minimally invasive surgery. In 1967, McKenzie published a little-known technique of a multiple-barbed nylon suture to repair tendons with greater strength and less inflammatory reaction (173). Ruff from Duke University began work in 1992 of an absorbable barbed suture for cosmetic repairs (174). A barbed suture, in theory removes tension from the apposing suture line decreasing the foreign-body reaction. Further evolution of this suture is reported by Dattilo et al. with a barbed bi-directional absorbable monofilament suture (175). In this investigation, the authors used a unique suture of monofilament polydioxanone containing 78 barbs in a spiral pattern around the circumference of the suture. The bi-directional barbed nature of this suture does not require knots for adequate tissue strength (Fig. 12). The barbed configuration anchors the suture into the tissue and provides adequate apposition while the wound heals with minimal tension and pressure. Preliminary work suggests that the knotless suture material may result in less scar tissue formation.

In this era of rapid technologic advances and sophisticated computer-enhanced robotics that a simpler solution would be to develop a dextrous suturing instrument. Indeed, this has already been accomplished and such a prototype is being investigated by Olympus Medical⁸ (Fig. 13). With such a mechanical instrument, the dexterity lost by the fixed borders of the abdominal wall would be bypassed. The degrees of freedom lost by simple laparoscopic instruments would be restored by a “wrist-like” action. There would be no need for million dollar computer-enhanced master/slave robotic units when a \$1000 or \$1500 instrument could accomplish the exact same thing. Do not think that the future of complex surgery is not in the robotic realm. Just because the elimination of the current generation master/slave, computer-enhanced robotic systems could in theory be eliminated by a simpler mechanical system does not equate with the potential for a machine to outperform a human being. Rest assured in the fervent belief that the future robotic surgical systems will eclipse anything that we have seen thus far. The one thing that you can count on when it comes to the technologies of tomorrow is that change will occur at an ever accelerating pace. Robotic systems are just approaching their long-awaited capabilities secondary to the lack of computer horsepower. This shortcoming is just about to end, as the next generations of supercomputers are about to change the world in which we practice our craft. The best selling science writer, Gleick penned recently that “the last decade of the 20th century came as a surprise” in his book *What Just Happened* (176). In later sections of this textbook, several authors will more formally discuss advances in technology. But, suturing and reconstructive technologies are linked intimately with such progress and we have spent a great deal of time on these rapid changes. It is altogether fitting and proper that we should conclude with technology for technophiles. Entrepreneur, researcher, and inventor Kurzweil has become a major vocal proponent of the radical way that computer technologies will change the world in which we live and work (177). His web page introduces those who are fascinated by technology to trends that he has sought to follow-up on Moore’s Law. Here he graphically demonstrates using data readily available that, by about 2009, there will probably be a computer on this planet smarter than a human being (178). What might we accomplish with such computing power. No longer would we be expecting the robot surgeon, controlled by this intellect to respond in a master/slave fashion but complete the task of restoring normalcy of its own accord.



FIGURE 12 ■ Quill Medical Inc.'s bi-directional barbed suture material. Source: Quill Medical Inc., Research Triangle Park, NC.



FIGURE 13 ■ Innovative hand-held multi-degree-of-freedom suturing device prototype from Olympus.

PRACTICAL SKILLS ACQUISITION EXERCISES

Laparoscopic intracorporeal suturing represents a difficult task in experienced hands. How then can the average urologist hope to obtain these skills and apply them whenever the situation calls for intracorporeal placement of sutures? There are two alternatives. You can either practice utilization of laparoscopic suturing skills or utilize any of the included short cuts discussed in this chapter. If your goal is to obtain skills that can be used time and time again for increasingly complex laparoscopic intracorporeal reconstructions, your time is better spent learning how to suture without opting for short cuts. This can be accomplished by spending time and money at courses or you can utilize simple equipment and practice inanimately at home, the office, or in the operating room. It sounds ridiculous to memorize the 12 steps that we presented in the previous chapter. This only represents a starting place for you to master the choreographed utilization of both of your hands. To do this you will require a camcorder and tripod. A tennis ball will serve as the targeted "organ" for reconstruction. You may utilize any suturing instruments or a disposable grasper that is available, or contact your local manufacturer's representative to borrow one. Cut sutures to a prescribed length and you can precede. Slow down first and try to get a feel for the instrument's tips motions. Once you get proficient at handling the needle make things progressively more difficult by covering your camera and tennis ball with a blanket. Finally, add a pelvic trainer (again, obtainable from a manufacturer's representative), trocars, and a plastic human pelvis (scale models are obtainable from many biological supply houses for under US\$35). Your best bet is to keep both hands on either side of the camera, but as skills advance you should move to the side as is required for most animate applications. I have taken still photographs from a video recorder during just such a home-study course to demonstrate each step again. Every time you get frustrated, take a rest. Each time you start things should get easier. The hand-eye coordination to function in the videolaparoscopic environment will develop.

Katz recently described a simple method of training for performing the vesicourethral anastomosis using chicken skin. A model urethra and bladder neck are prepared by folding and tabularizing a 5 × 4 cm piece of skin over a 14 French catheter. Training again is performed in a pelvic trainer. The single knot method of van Velthoven can be easily adapted to this training technique. As described by the authors, the initial attempts require the longest times for neophytes (residents and urologists with minimal laparoscopic experience). Needle passage was easier, followed by knotting and suturing in terms of skill acquisition. They noted in 10 neophytes who followed their five-step regimen, that all were able to advance and perform complete, accurate urethrovesical anastomoses (179).

Good luck!

REFERENCES

1. Lund GO, Winfield HN, Donovan JF, Narepalem N. Laparoscopically-assisted penile revascularization for vasculogenic impotence [abstr V5124]. *J Endourol* 1994; 8:S64.
2. Jordan GH. Pediatric genitourinary laparoscopic surgery. *AUA Today* 1994; 7(11):14-15.
3. Denes FT, Mendonca BB, Arap S. Laparoscopic management of intersexual states. *Urol Clin NA* 2001; 28:31-42.
4. Markovich R, Jacobson A, Aldana JP, Lee BR, Smith AD. Practice trends in contemporary management of adult ureteropelvic junction obstruction. *Urology* 2003; 62:22-25.

5. Baldwin DD, Dunbar JA, Wells N, McDougall EM. Single-center comparison of laparoscopic pyeloplasty, acucise endopyelotomy, and open pyeloplasty. *J Endourol* 2003; 17:155–160.
6. Schuessler WW. Laparoscopic pyeloplasty. *AUA Today* 1994; 7(11):15.
7. Jarrett TW, Chan DY, Charambura TC, Fugita O, Kavoussi LR. Laparoscopic pyeloplasty: the first 100 cases. *J Urol* 1994; 151:1253–1256.
8. Gaur DD, Agarwal DK, Purohit KC, Darshane AS. Retroperitoneal laparoscopic pyelolithotomy. *J Urol* 1994; 151:927–929.
9. Agarwal DK, Gaur DD, Najarwar M. A new concept of laparoscopic suturing. *Min. Inv. Ther.* 1994; 227–29.
10. Ramakumar S, Lancini V, Chan DY, Parsons JK, Kavoussi LR, Jarrett TW. Laparoscopic pyeloplasty with concomitant pyelolithotomy. *J Urol* 2002; 167:1378–1380.
11. Sundaram CP, Grubb RL III, Rehman J, et al. Laparoscopic pyeloplasty for secondary ureteropelvic junction obstruction. *J Urol* 2003; 169:2037–2040.
12. Kaouk JG, Kuang W, Gill IS. Laparoscopic dismembered tabularized flap pyeloplasty: a novel technique. *J Urol* 2002; 167:229–231.
13. Gill IS, Savage JJ, Senagore AJ, Sung GT. Laparoscopic ileal ureter. *J Urol* 2000; 163:1199–1202.
14. Gettman MT, Lotan Y, Roerhborn CG, Cadeddu JA, Pearle MS. Cost-effective treatment for ureteropelvic junction obstruction: a decision tree analysis. *J Urol* 2003; 169:228–232.
15. Gill IS, Matin SF, Desai MM, et al. Comparative analysis of laparoscopic versus open partial nephrectomy for renal tumors in 200 patients. *J Urol* 2003; 170:64–68.
16. Klopukh BV, Shama S, Picken M, Turk TM. Comparison of laparoscopically-assisted partial nephrectomy using digital compression versus purely laparoscopic nephrectomy using vascular pedicle clamp in a porcine model. *J Endourol* 2003; 17:313–315.
17. Simon SD, Ferrigni RG, Novicki DE, Lamm DL, Swanson SS, Andrews PE. Mayo Clinic Scottsdale experience with laparoscopic nephron sparing surgery for renal tumors. *J Urol* 2003; 169:2059–2062.
18. Phelan MW, Perry KT, Gore J, Schulam PG. Laparoscopic partial nephrectomy and minimally invasive nephron-sparing surgery. *Curr Urol Rep* 2003; 4:13–20.
19. Cherullo EE, Gill IS, Ponsky LE, et al. Laparoscopic ureterocalicostomy: a feasibility study. *J Urol* 2003; 169:2360–2364.
20. Grubb RL 3rd, Sundaram CP, Yan Y, Chen C, McDougall EM, Clayman RV. Use of titanium staples during upper tract laparoscopic reconstructive surgery: initial experience. *J Urol* 2005; 173:225–229.
21. Vanlangendouch R, Clayman RV, et al. Laparoscopic ureterocalicostomy: development of a technique simplified by application of nitinol clips and a wet monopolar electrosurgery device. *J Endourol* 2005; 19: 225–229.
22. Kane CJ, Bolton DM, Stoller ML. Current indications for open stone surgery in an endourology center. *Urology* 1995; 45:218–221.
23. Kaouk JH, Gill IS, Desai MM, et al. Laparoscopic anastrophic nephrolithotomy: feasibility study in a chronic porcine model. *J Urol* 2003; 169:691–696.
24. Kuhlmann U, Gruntzug A, Vetter W, Lutolf U, Meier B, Siegenthaler W. Percutaneous transluminal dilation: a new treatment of renovascular hypertension? *Klinische Wochenschrift* 1978; 56:703–707.
25. Hsu THS, Gill IS, Sung GT. Laparoscopic aortorenal bypass: a feasibility study. *J Laparoendosc Adv Surg Tech* 2000; 10:55–58.
26. Gill IS, Murphy DP, Hsu THS, Fergany A, Fattouh HE, Meraney AM. Laparoscopic repair of renal artery aneurysm. *J Urol* 2001; 166:202–205.
27. Sung TS, Abreu JC, Gill IS, et al. Laparoscopic splenorenal bypass: survival study [abstr]. *J Urol* 2003; 169:500.
28. Ng CS, Abreu SC, Steinberg AP, et al. Laparoscopic management of intra-parenchymal renal artery aneurysm [abstr]. *J Urol* 2003; 169(4):500.
29. Hoznek A, Gettman M, Antiphon P, et al. Robot assisted kidney transplantation [abstr]. *J Urol* 2003; 169(4):499.
30. Gluckman GR, Stoller M, Irby P. Laparoscopic pyelocaliceal diverticula ablation. *J Endourol* 1993; 7:315–317.
31. Ruckle HC, Segura JW. Laparoscopic treatment of a stone-filled, caliceal diverticulum: a definitive, minimally invasive option. *J Urol* 1994; 151:122–124.
32. Miller SD, Ng CS, Strem SB, Gill IS. Laparoscopic management of caliceal diverticular calculi. *J Urol* 2002; 167:1248–1252.
33. White R, Rosenberg DJ, Moran ME. Type II pyelocaliceal diverticula: endourologic implications of this rare type of caliceal evagination. *J Endourol* 2003; 17: A147.
34. Moss SW. Floating kidneys: a century of nephroptosis and nephropexy. *J Urol* 1997; 158:699–702.
35. Urban DA, Clayman RV, Kerbl K, Figenshau RS, McDougall EM. Laparoscopic nephropexy for symptomatic nephroptosis: initial case report. *J Endourol* 1993; 6:147–150.
36. Elashry OM, Nakada SY, McDougall EM, Clayman RV. Laparoscopic nephropexy: Washington University experience. *J Urol* 1995; 154:1655–1659.
37. Plas E, Daja K, Riedl CR, Huber WA, Pfluger H. Long-term followup after laparoscopic nephropexy for symptomatic nephroptosis. *J Urol* 2001; 166:449–452.
38. Szekely JG. Letter to the editor. *J Urol* 1997; 157:266.
39. Kaynan AM, Rehman J, Hoenig DM. Laparoscopic ureteral surgery. *Sem Laparosc Surg* 2000; 7:166–175.
40. Nezhat C, Nezhat F, Green B. Laparoscopic treatment of obstructed ureter due to endometriosis by resection and ureteroureterostomy: a case report. *J Urol* 1992; 148:865–868.
41. Wichham JEA. The surgical treatment of renal lithiasis. In: *Urinary Calculous Disease*. New York: Churchill Livingstone, 1979:183–186.
42. Wuernschimmel E, Lipsky H. Laparoscopic treatment of an upper ureteral stone. *J Laparoendosc Surg* 1993; 3:301–307.

43. Baba S, Oya M, Miyahara M, Deguchi N, Tazaki H. Laparoscopic surgical correction of circumcaval ureter. *Urology* 1994; 44:122–126.
44. Ramalingam M, Selvarajan K. Laparoscopic transperitoneal repair of retrocaval ureter: report of two cases. *J Endourol* 2003; 17:85–87.
45. Kavoussi LR, Clayman RV, Brunt LM, Soper NJ. Laparoscopic ureterolysis. *J Urol* 1992; 147:426–429.
46. Atala A, Goldstein DS, Kavoussi LR, Retik AB, Peters CP. Laparoscopic correction of vesicoureteral reflux. *J Urol* 1993; 149:453A.
47. Puppo P, Carmignani G, Gallucci M, Ricciotti G, Perachino M. Bilateral laparoscopic ureterolysis. *Eur Urol* 1994; 25:82–84.
48. Nezhat CH, Nezhat F, Seidman D, Nezhat C. Laparoscopic ureteroureterostomy: a prospective follow-up of 9 patients. *Prim Care Update Ob Gyns* 1998; 5:200.
49. Reich H, McGlynn F. Laparoscopic repair of bladder injury. *Obstet Gyn* 1990; 76:909–910.
50. Das, S. Laparoscopic removal of bladder diverticulum. *Jurol* 1992; 1: 299.
51. Low RK, Moran ME. Laparoscopic use of the ureteral illuminator. *Urology* 1993; 42:455–457.
52. Parra RO. Laparoscopic repair of intracorporeal bladder perforation. *J Urol* 1994; 151:1003–1005.
53. Ehrlich RM, Gershman A, Fuchs G. Laparoscopic vesicoureteroplasty in children: initial case reports. *Urology* 1994; 43:255–261.
54. Ehrlich RM, Gershman A. Laparoscopic seromyotomy (autoaugmentation) for non-neurogenic neurogenic bladder in a child: initial case report. *Urology* 1993; 42:175.
55. McDougall EM, Clayman RV, Figenshau RS, Pearle MS. Laparoscopic retropubic auto-augmentation of the bladder. *J Urol* 1995; 153:123–126.
56. Bowyer DW, Moran ME, Szabo Z. Laparoscopic augmentation cystoplasty using two graft materials [abstr]. *J Urol* 1993; 149:452A.
57. Jordan GH, Winslow BH. Laparoscopically assisted continent catheterizable cutaneous appendicovesicostomy. *J Endourol* 1993; 7:517–520.
58. Anderson KR, Fadden PT, Kerbl K, McDougall EM, Clayman RV. Laparoscopic continent urinary diversion in a porcine model [abstr PXXII-11]. *J. Endourol* 1993; 7:S197.
59. Nezhat CH, Nezhat Fr, Freiha F, Nezhat CR. Laparoscopic vesicopsoas hitch for infiltrative ureteral endometriosis. *Fertil Steril* 1999; 71:376–379.
60. Fugita OD, Dinlenc C, Kavoussi L. The laparoscopic boari flap. *J Urol* 2001; 166:51–53.
61. Harewood LM. Laparoscopic needle colposuspension for genuine stress incontinence. *J Endourol* 1993; 7:319–322.
62. Vancaille TG, Schuessler WW. Laparoscopic bladder neck suspension. *J Laparoendosc Surg* 1991; 1:169–173.
63. Harden M, Vancaille TG. Laparoscopic bladder neck suspension. *Infect In Urol Sept/Oct* 1994;147–150.
64. Burton GA. A randomized comparison of laparoscopic and open colposuspension. *Neurourol Urodyn* 1994; 13:487–498.
65. McDougall EM, Portis A. The laparoscopic bladder neck suspension fails the test of time [abstr]. *J Urol* 1999; 161:105.
66. Seman EI, Cook JR, O'Shea RT. Two-year experience with laparoscopic pelvic floor repair. *J Am Assoc Gynecol Laparosc* 2003; 10:38–45.
67. Deval B, Haab F. What's new in prolapse surgery? *Curr Opin Urol* 2003; 13:315–323.
68. Yano H, Iwazawa T, Monden T. Excision of a urachal sinus with use of a voice-controlled laparoscope. *J Laparoendosc Adv Surg Tech A* 2003; 13:45–49.
69. Khurana S, Borzi PA. Laparoscopic management of complicated urachal disease in children. *J Urol* 2002; 168(4 Pt 1):1526–1528.
70. Cadeddu JA, Boyle KE, Fabrizio MD, Schulam PG, Kavoussi LR. Laparoscopic management of urachal cysts in adulthood. *J Urol* 2000; 164:1526–1528.
71. Chiu AW, Chen HT, Huang WJS, Juang GD, SH, Chang LS: Case Report: Laparoscopic nephroureterectomy and endoscopic excision of bladder cuff. *Min Invas Therap*-1992; 1:299.
72. Clayman RV, Kavoussi LR, Figenshau RS, Chandhoke PS, Albela DM: Laparoscopic nephroureterectomy: initial case report. *Jurol laparoendosc* 1991; 1: 303.
73. Parra RO, Jones JP, Andrus CH, Hagood PG: Laparoscopic diverticulectomy: preliminary report of a new approach for the treatment of bladder diverticulum. *Jurol* 1992; 148: 869.
74. Geridzen GR, Futter NG. Ten year review of vesicle diverticula. *Urology* 1982; 20:33.
75. Kelalis PP, Mclean P. The treatment of diverticulum of the bladder. *J Urol* 1967; 98:349.
76. Kutzmann AA. Diverticulum of the urinary bladder: an analysis of 100 cases. *Surg Gynec Obstet* 1933; 56:898.
77. Peterson LJ, Paulson DF, Glenn JF. The histopathology of vesical diverticula. *J Urol* 1973; 110:62.
78. Kerbl K, Chandhoke PS, McDougal E, Figenshau RS, Stone AM, Clayman RV: Laparoscopic stapled bladder closure: laboratory and clinical experience. *Jurol* 1993; 149: 1437.
79. Anderson KR, Clayman RV. Laparoscopic lower urinary tract reconstruction. *World J Urol* 2000; 18:349–354.
80. Kaouk JH, Gill IS, Desai MM, et al. Laparoscopic orthotopic ileal neobladder. *J Endourol* 2001; 15:131–142.
81. Baldwin DD, Herrell SD, Dunbar JA, et al. Simplified laparoscopic radical cystectomy with orthotopic ileal neobladder creation in a porcine model. *J Endourol* 2003; 17:307–312.
82. Simonato A, Gregori A, Lissiani A, Bozzola A, Galli S, Gaboardi F. Laparoscopic radical cystoprostatectomy: a technique illustrated step by step. *Eur Urol* 2003; 44:132–138.
83. Abdel-Hakim AM, Bassiouny F, Abdel Azim MS, et al. Laparoscopic radical cystectomy with orthotopic neobladder. *J Endourol* 2002; 16:377–381.
84. Matin SF, Gill IS. Laparoscopic radical cystectomy with urinary diversion: completely intracorporeal technique. *J Endourol* 2002; 16:335–341.

85. Gill IS, Kaouk JH, Meraney AM, et al. Laparoscopic radical cystectomy and continent orthotopic ileal neobladder performed completely intracorporeally: the initial experience. *J Urol* 2002; 168:13–18.
86. Guputa NP, Gill IS, Fergany A, Nabi G. Laparoscopic radical cystectomy with intracorporeal ileal conduit diversion: five cases with a 2-year follow-up. *BJU Int* 2002; 90:391–396.
87. Turk I, Davis JW, Deger S, et al. Laparoscopic radical cystectomy with intracorporeal creation of a continent urinary diversion. Future or present? *Urologe A* 2002; 41:107–112.
88. Bohm B, Milsom JW, Stolfi VM, Kitigo K. Laparoscopic intraperitoneal anastomosis. *Surg Endosc* 1993; 7:194.
89. Kozminski M, Partamian KO. Case report of laparoscopic ileal loop conduit. *J Endourol* 1992; 6:147–150.
90. Thorbeck CV, Sanchez de Badajoz S, Toscano R. Laparoscopic ileal conduit. *Surg Endosc* 1993; 2:257A.
91. Brenner M, Johnson DE. Ileal conduit calculi from stapler anastomosis: a long-term complication? *Urology* 1985; 26:537.
92. Ginsberg D, Huffman JL, Lieskovsky G, Boyd S, Skinner DG. Urinary tract stones: a complication of the Kock pouch continent urinary diversion. *J Urol* 1991; 145:956.
93. Lieskovsky G, Boyd SD, Skinner DG. Cutaneous Kock-pouch urinary diversion. *Prob In Urol* 1991; 5:268.
94. Myers RP, Rife CC, Barrett DM. Experience with the bowel stapler for ileal conduit urinary diversion. *Br J Urol* 1982; 54:491.
95. Julian TB, Ravitch MM. Closure of the urinary bladder with stainless steel and absorbable staples. *Ann Surg* 1986; 204:186.
96. Calvano CJ, Moran ME, Parekh AR, Desai PJ, Cisek LJ. Laparoscopic augmentation cystoplasty using novel biomaterial surgisis: small-intestinal submucosa. *J Endourol* 2000; 14:213–217.
97. Desai MM, Gill IS, Goel M, et al. Ureteral tissue balloon expansion for laparoscopic bladder augmentation: survival study. *J Endourol* 2003; 17:283–293.
98. Lifshitz DA, Beck SDW, Barret E. Laparoscopic transverse hemicystectomy with ileocystoplasty in a porcine model. *J Endourol* 2001; 15:199.
99. Siqueria TM Jr, Paterson RF, Kuo RL, Kaefer M, Cheng L, Shalhav AL. Laparoscopic ileocystoplasty and continent ileovesicostomy in a porcine model. *J Endourol* 2003; 17:301–305.
100. Sanchez de Badajoz E, Mate Hurtado A, Jimenez Garrido A, Gutierrez de la Cruz JM. Laparoscopic cystoplasty. *Arch Esp Urol* 1993; 46:615–619.
101. Gill IS, Rackley RR, Meraney AM, Marcello PW, Sung GT. Laparoscopic enterocystoplasty. *Urology* 2000; 55:178–181.
102. Elliott, SP, Meng MV, Anwar HP, Stoller ML. Complete laparoscopic ileal cystoplasty. *Urology* 2002; 59:939–943.
103. Portis AJ, Elbahnasy AM, Shalhav AL, et al. Laparoscopic augmentation cystoplasty with different biodegradable grafts in an animal model. *J Urol* 2000; 164:1405–1411.
104. Wolf JS Jr, Taheri PA. Laparoscopic urinary undiversion. *J Urol* 1998; 159:198–199.
105. Schuessler WW, Kavoussi LR, Clayman RV, Vancaille TG. Laparoscopic radical prostatectomy: initial case report [abstr 130]. *J Urol* 1992; 147:246A.
106. Moran ME, Bowyer DW, Szabo Z, Higgins RJ. Laparoscopic microsurgical reconstruction following radical prostatectomy [abstr 791]. *J Urol* 1993; 149:410A.
107. Price DT, Chari RS, Neighbors JD, Paulson DF, Preminger GM. Laparoscopic radical prostatectomy in the canine model [abstr O3–34]. *J Endourol* 1994; 8:S53.
108. Rassweiler J, Seemann O, Hatzinger M, Schulze M, Frede T. Technical evolution of laparoscopic radical prostatectomy after 450 cases. *J Endourol* 2003; 17:143–154.
109. Menon M, Tewari A, Peabody J. Vattikuti Institute prostatectomy: technique. *J Urol* 2003; 169:2289–2292.
110. Borboroglu PG, Sands JP, Roberts JL, Amling CL. Risk factors for vesicourethral anastomotic stricture after radical prostatectomy. *Urology* 2000; 56:96–100.
111. Kochakarn W, Ratana-Olam K, Viseshsindh V. Vesicourethral strictures after radical prostatectomy: review of treatment and outcome. *J Med Assoc Thai* 2002; 85:63–66.
112. Bhayani SB, Pavlovich CP, Hsu TS, Sullivan W, Su LM. Prospective comparison of short-term convalescence: laparoscopic radical prostatectomy versus open radical retropubic prostatectomy. *Urology* 2003; 61:612–616.
113. Yamada Y, Honda N, Nakamura K, et al. Vesicourethral anastomotic suture placement during radical prostatectomy using Maniceps. *Urol Int* 2003; 70:181–185.
114. Grummet JP, Costello AJ, Swanson DA, Stephens LC, Cromeens DM. Vesicourethral anastomosis with 2-octyl cyanoacrylate adhesive in an in vivo canine model. *Urology* 2002; 60:935–938.
115. Grummet JP, Costello AJ, Swanson DA, Stephens LC, Cromeens DM. Laser welded vesicourethral anastomosis in an in vivo canine model: a pilot study. *J Urol* 2002; 168:281–284.
116. Partin AW, Adams JB, Moore RG, Kavoussi LR. Complete robot-assisted laparoscopic urologic surgery: a preliminary report. *J Am Coll Surg* 1995; 181:552–557.
117. Rovetta A, Sala R, Wen X, Togno A. Remote control in telerobotic surgery. *IEEE Trans Syst Man Cybernet* 1996; 26:438–444.
118. Lazeroms M, Jongkind W, Honderd G. Telemanipulator design for minimally invasive surgery. *Proc Am Control Conf* June 1997; 2982–2986.
119. Dowler NJ, Holland SRJ. The evolutionary design of an endoscopic telem manipulator. *IEEE Robotics Automat* Dec 1996:38–45.
120. Wapler M. Medical manipulators—a realistic concept? *Min Invas Ther* 1995; 4:261–266.
121. Moran ME. Robotic surgery: urologic implications. *J Endourol* 2003; 17:695–707.
122. Prasad SM, Ducko CT, Stephenson ER, Chambers CE, Damiano RJ, Jr. Prospective clinical trial of robotically assisted endoscopic coronary grafting with 1-year follow-up. *Ann Surg* 2001; 233:725–732.

123. Melvin WS, Needleman BJ, Krause KR, Wolf RK, Michler RE, Ellison EC. Computer-assisted robotic Heller myotomy: initial case report. *J Laparoendosc Adv Surg Tech* 2001; 11:251–253.
124. Chapman WHH 3rd, Young JA, Albrecht RJ, Kim VB, Nifong LW, Chitwood WR, Jr. Robotic Nissen fundoplication: alternative surgical technique for treatment of gastroesophageal reflux disease. *J Laparoendosc Surg Adv Surg Tech* 2001; 11:27–30.
125. Marescaux J, Smith MK, Folscher D, Jamali F, Malassagne B, Leroy J. Telerobotic laparoscopic cholecystectomy: initial clinical experience with 25 patients. *Ann Surg* 2001; 234:1–7; comment in: *Ann Surg* 2001; 234:8–9.
126. Chapman III WHH, Albrecht RJ, Kim VB, Yong JA, Chitwood WR. Computer-assisted laparoscopic splenectomy with the da Vinci surgical robot. *J Laparoendosc Adv Surg Techn* 2002; 12:155–159.
127. Melvin WS, Needleman BJ, Krause KR, Ellison EC. Robotic resection of pancreatic neuroendocrine tumor. *J Laparoendosc Adv Surg Techn* 2003; 13:33–36.
128. Hollands CM, Dixey LN, Torma MJ. Technical assessment of porcine enteroenterostomy performed with ZEUS(TM) robotic technology. *J Pediatr Surg* 2001; 36:1231–1233.
129. Margossian H, Falcone T. Robotically assisted laparoscopic hysterectomy and adnexal surgery. *J Laparoendosc Adv Surg Tech A* 2001; 11:161–165.
130. Margossian H, Garcia-Ruiz A, Falcone T, Goldberg JM, Attaran M, Gagner M. Robotically assisted laparoscopic microsurgical uterine horn anastomosis. *Fertil Steril* 1998; 70:530–534.
131. Margossian H, Falcone T. Robotically assisted laparoscopic hysterectomy and adnexal surgery. *J Laparoendosc Surg Adv Surg Tech* 2001; 11:161–165.
132. Krapohl BD, Reichert B, Machens HG, Mailander P, Siemionow M, Zins JE. Computer-guided microsurgery: surgical evaluation of a telerobotic arm. *Microsurgery* 2001; 21:22–29.
133. Diaz-Arrastia C, Jurnalov C, Gomez G, Townsend Jr C. Laparoscopic hysterectomy using a computer-enhanced surgical robot. *Surg Endosc* 2002; 16:1271–1273.
134. Gutt CN, Markus B, Kim ZG, Meininger D, Brinkmann L, Heller K. Early experiences of robotic surgery in children. *Surg Endosc* 2002; 16:1083–1086.
135. Kavoussi LR, Moore RG, Partin AW, Bender JS, Zenilman ME, Satava RM. Telerobotic assisted laparoscopic surgery: initial laboratory and clinical experience. *Urology* 1994; 44:15–19.
136. Bowersox JC, Cornum RL. Remote operative urology using a surgical telemanipulator system. *Urology* 1998; 52:17.
137. Kavoussi LR, Moore RG, Adams JB, Partin AW. Comparison of robotic versus human laparoscopic camera control. *J Urol* 1995; 154:2134–2136.
138. Sung GT, Gill IS, Hsu TH. Robotic-assisted laparoscopic pyeloplasty: a pilot study. *Urology* 1999; 53:1099.
139. Guillonnet B, Cappele O, Martinez JB. Robotically assisted, laparoscopic pelvic lymph node dissection in humans. *J Urol* 2001; 165:1078.
140. Abbou CC, Hoznek A, Salomon L, et al. Laparoscopic radical prostatectomy with a remote controlled robot. *J Urol* 2001; 165:1964–1966.
141. Guillonnet B, Jayet C, Tewari A, Vallancien G. Robot assisted laparoscopic nephrectomy. *J Urol* 2001; 166:200–201.
142. Pautler SE, McWilliams GW, Harrington FS, Walther MM. An articulating retractor holder to facilitate laparoscopic adrenalectomy and nephrectomy. *J Urol* 2001; 166:198–199.
143. Dimarco DS, Chow GK, Gettman MT, Elliott DS. Robotic sacrocolpopexy [abstr V707]. *J Urol* 2005; 169(4):183.
144. Yohannes P, Gu Y. Combined robotic-assisted and manual laparoscopic left retroperitoneal lymph node dissection for nonseminomatous testicular cancer [abstr V1873]. *J Urol* 169(4):500.
145. Hoznek A, Zaki SK, Samadi DB, et al. Robotic assisted kidney transplantation: an initial experience. *J Urol* 2002; 167:1604–1606.
146. Guillonnet B, Cappele O, Bosco J. Pyeloplastie laparoscopique avec assistance robotisee: premier cas. *Prog Urol* 2000; 10:61A.
147. Gettman MT, Peschel R, Neururer R, Bartsch G. A comparison of laparoscopic pyeloplasty performed with a daVinci robotic system versus standard laparoscopic techniques: initial clinical results. *Eur Urol* 2002; 42:453–458.
148. Gettman MT, Neururer R, Bartsch G, Peschel R. Anderson-Hynes dismembered pyeloplasty performed using daVinci robotic system. *Urology* 2002; 60:509–513.
149. Yohannes P, Burjonrappa SC. Laparoscopic Anderson-Hynes dismembered pyeloplasty using the daVinci(TM) robot technical considerations. *J Endourol* 2003; 17:79–83.
150. Antiphon P, Hoznek A, Gettman M, et al. Extraperitoneal laparoscopic robot assisted radical prostatectomy. *J Urol* 2003; 169(4):249, V965.
151. Tewari A, Peabody J, Sarle R, et al. Technique of daVinci robot-assisted anatomic radical prostatectomy. *Urology* 2002; 60:569–572.
152. Tewari A, Peabody JO, Fischer M, et al. An operative and anatomic study to help in nerve sparing during laparoscopic and robotic radical prostatectomy. *Eur Urol* 2003; 43:444–454.
153. Van Velthoven RF, Ahlering TE, Peltier A, Skarecky DW, Clayman RV. Technique for laparoscopic running urethrovesical anastomosis: the single knot method. *Urology* 2003; 61:699–702.
154. Ahlering TE, Skarecky DW, Lee D, Clayman RV. Successful transfer of open surgical skills to a laparoscopic environment using a robotic interface: initial experience with laparoscopic radical prostatectomy [abstr]. *J Urol* 2003; 169(4):441, 1649.
155. Shrivastava A, Peabody JO, Menon M. Vattikuti institute prostatectomy: can we predict time taken for performing new procedures? [abstr DP24]. *J Urol* 2003; 169(4):344–345.
156. Moran ME, Bowyer DW, Szabo Z. Laparoscopic suturing in urology: a model for vesicourethral anastomosis. *Min Invas Therap* 1993; 2:165–170.
157. Healy JC. The global impact of telematics for health-care professionals. *Min Invas Ther Allied Technol* 1998; 7:105–109.
158. Huang HK. Telemedicine and teleradiology technologies and applications. *Min Invas Ther Allied Technol* 1997; 5/6:387–192.

159. Wilson D. Teleradiology at the 121st general hospital in Yongsan, Korea. *Min Invas Ther Allied Technol* 1997; 5/6:404–407.
160. Dayhoff R, Siegel E. Digital imaging among medical facilities. *Min Invas Ther Allied Technol* 1997; 5/6:408–415.
161. Lyche D. Telemedicine: technology versus the business case. *Min Invas Ther Allied Technol* 1997; 5(6):416–420.
162. Ecken BK, Harbick RF, Pease A. Uses and benefits of telemedicine. *Min Invas Ther Allied Technol* 1997; 5(6):444–447.
163. Crowe B. Establishing the costs of telemedicine services. *Min Invas Ther Allied Technol* 1997; 5/6:432–435.
164. Wooton R. Telemedicine: the current state of the art. *Min Invas Ther Allied Technol* 1997; 5(6):393–403.
165. Lemaster H, Meylor J, Meylor F. Internet technologies and requirements for telemedicine. *Min Invas Ther Allied Technol* 1997; 5(6):436–443.
166. Etter M, Feussner H, Siewert JR. Guidelines for teleconsultation in surgery. *Surg Endosc* 1999; 13:1254–1255.
167. Lirici MM, Papaspyropoulos V, Angelini L. Telerobotics in medicine and surgery. *Min Invas Ther Allied Technol* 1997; 5(6):364–378.
168. Marescaux J, Mutter D. Inventing the future of surgery. *Min Invas Ther Allied Technol* 1998; 7:69–70.
169. Broderick TJ, Harnett BM, Doam CR, Rodas EB, Merrell RC. Real-time internet connections: implications for surgical decision making in laparoscopy. *Ann Surg* 2000; 234:165–171.
170. Antiphon P, Hoznek A, Benyoussef A, et al. Complete solo laparoscopic radical prostatectomy: initial experience. *Urology* 2003; 61:724–729.
171. Dakins GF, Gagner M. Comparison of laparoscopic skills performance between standard instruments and two surgical robotic systems. *Surg Endosc* 2003; 17:574–579.
172. Kaouk JH, Desai MM, Abreu SC, Papay F, Gill IS. Robotic assisted laparoscopic sural nerve grafting during radical prostatectomy: initial experience. *J Urol* 2003; 170:909–912.
173. McKenzie AR. An experimental multiple barbed suture for long flexor tendons of the palm and fingers. Preliminary report. *J Bone Joint Surg Br* 1967; 49:440–447.
174. US patents 5,342,376 and 6,241,747 B1.
175. Dattilo PP Jr, King MW, Cassill NL, Leung JC. Medical textiles: application of an absorbable barbed bi-directional surgical suture. *J Text Appar Technol Manag* 2002; 2:1–5.
176. Gleick J. *What Just Happened. A Chronicle from the Information Frontier*. New York: Vintage Books, 2002:3.
177. Kurzweil R. The coming merging of mind and machine. In: Sandy Fritz, ed. *Understanding Artificial Intelligence*. New York: Warner Books, 2002:90–99.
178. www.kurzweilai.net
179. Katz R, Nadu A, Olsson LE, et al. A simplified 5-step model for training laparoscopic urethrovesical anastomosis. *J Urol* 2003; 169:2041–2044.

SECTION

IV

ADULT LAPAROSCOPY: BENIGN DISEASE

T. R. J. Gianduzzo and C. G. Eden

*Department of Urology, The North Hampshire Hospital,
Basingstoke, Hampshire, U.K.*

- INTRODUCTION AND BACKGROUND
- PATIENT SELECTION: INDICATIONS AND CONTRAINDICATIONS
 - Indications
 - Contraindications
- PREOPERATIVE PREPARATION
- TECHNIQUE
 - Options
- LATERAL TRANSPERITONEAL TECHNIQUE
 - Equipment and Theatre Set-Up
 - Steps
 - Postoperative Care and Follow-Up
- TECHNICAL CAVEATS
 - Hemostasis
 - Open Conversion
 - Organ Injury
- GENERAL TECHNICAL MODIFICATIONS
 - Procedural Modifications
 - Instrument Modifications
- ANTERIOR TRANSPERITONEAL TECHNIQUE
- LATERAL RETROPERITONEAL TECHNIQUE
 - Patient Positioning and Retroperitoneal Access
 - Port Placement
 - Control of the Main Adrenal Vein
 - Specimen Mobilization, Extraction, and Closure
- POSTERIOR RETROPERITONEAL TECHNIQUE
- OTHER TECHNIQUES AND MODIFICATIONS
 - Direct Supragastric Left-Sided Adrenalectomy
 - Hand-Assisted Laparoscopic Adrenalectomy
 - Needlescopic Laparoscopic Adrenalectomy
 - Thoracoscopic Transdiaphragmatic Adrenalectomy
 - Robotic Surgery
- CONCLUSION
- SUMMARY
- REFERENCES

INTRODUCTION AND BACKGROUND

Laparoscopic adrenalectomy has become the standard surgical approach for most surgically correctable benign disorders of the adrenal gland.

Laparoscopic adrenalectomy was initially performed, in 1991, for a case of adrenal hematoma (1). Gagner et al. first reported the procedure for neoplasia in October 1992 (2); however, Go et al. had begun a series of laparoscopic adrenalectomies in patients with primary aldosteronism in January 1992 (3), followed by Suzuki et al., who had also commenced a series in February the same year (4).

Laparoscopic adrenalectomy has become the standard surgical approach for most surgically correctable benign disorders of the adrenal gland.

No randomized controlled trials have been undertaken to compare laparoscopic adrenalectomy with traditional open surgery. However, on the basis of comparative studies, laparoscopic adrenalectomy has demonstrated superiority in terms of analgesic requirements, recovery, convalescence, length of stay, and cosmesis, whilst maintaining equivalent long-term operative efficacy (5–8).

Laparoscopic approaches to the adrenal gland may be performed via either transperitoneal or retroperitoneal routes and may be either unilateral or bilateral. Initially, the transperitoneal route was used, predominantly because of the familiarity of this approach with open surgery (9,10). However, following the development of retroperitoneal techniques by Gaur in 1992, lateral and posterior retroperitoneal approaches have also been adopted (11).

Further modifications have since been developed including the transthoracic approach (12), the supragastric approach for left-sided lesions (13,14), hand-assisted laparoscopic adrenalectomy (15), the use of needlescopic instruments (16,17), and, most recently, robotic laparoscopic adrenalectomy (18–20).

This chapter will describe the authors' preferred approach of transperitoneal laparoscopic adrenalectomy and also provide a review of the alternative methods that have been described.

Aldosteronomas may be considered as lesions of choice for surgeons early in the operative learning curve.

TABLE 1 ■ Indications for Laparoscopic Adrenalectomy

Functioning lesions	Aldosteronoma Adreno corticotrophic hormone-independent Cushing's syndrome (adenoma and hyperplasia) Adreno corticotrophic hormone-dependent Cushing's syndrome (pituitary adenoma refractory to treatment and nonlocalized ectopic adreno corticotrophic hormone source) Pheochromocytoma—benign/malignant Congenital adrenal hyperplasia ^a Cortical adenoma
Possible malignancy	Primary adrenal carcinoma ^a 3–5 cm lesions with suspicious imaging characteristics or progressive growth on serial imaging >5 cm lesion Metastasis ^b
Benign symptomatic lesions	Cyst Myelolipoma ^c

^aRole of laparoscopic adrenalectomy controversial.
^bRemove if primary controllable or if symptomatic.
^cLaparoscopic adrenalectomy indicated if lesions are greater than 4 cm in size or features suspicious of malignancy are present.

PATIENT SELECTION: INDICATIONS AND CONTRAINDICATIONS

Indications

As shown in Table 1, the indications for laparoscopic adrenalectomy can be categorized as:

- 1. Functioning lesions,
- 2. Suspicious malignant lesions of small size, and
- 3. Nonfunctioning benign lesions that are either symptomatic or have the potential to become symptomatic.

Functioning Lesions

The resection of aldosteronomas was one of the initial indications for laparoscopic adrenalectomy. These lesions are often small and the patient's body habitus favorable; therefore, they are particularly suited to the laparoscopic approach.

Aldosteronomas may be considered as lesions of choice for surgeons early in the operative learning curve (21).

Unilateral laparoscopic adrenalectomy is the treatment of choice for patients with Cushing's syndrome due to unilateral adrenal adenomas (22).

The preponderance of periadrenal fat in Cushing's syndrome cases may make adrenalectomy initially more difficult, particularly via retroperitoneal approaches (21,23). Cushing's disease refractory to primary pituitary treatment or cases of ectopic adreno corticotrophic hormone-dependent Cushing's syndrome where the ectopic source of adreno corticotrophic hormone production cannot be localized may require bilateral adrenalectomy (24). Bilateral laparoscopic adrenalectomy has also been proposed as an alternative treatment for select cases of congenital adrenal hyperplasia (25).

Subclinical Cushing's syndrome is present in up to 20% of cortical adenomas (26). It is characterized by loss of the normal cortisol circadian rhythm and resists suppression with dexamethasone, but may have normal 24-hour urinary cortisol levels (26,27). Such lesions may progress to clinical Cushing's syndrome or present with postoperative adrenal crises from unrecognized suppression and may therefore be better removed rather than monitored (24).

After initial controversy, laparoscopic adrenalectomy for pheochromocytoma is now well accepted as a standard indication for unilateral or bilateral disease (24,28–30).

Laparoscopic adrenalectomy for pheochromocytoma produces similar or milder hemodynamic effects, less surgical trauma, and is superior in terms of convalescence when compared to open surgery (28).

The quintessential objective during laparoscopic adrenalectomy is early control of the adrenal vein, and in this regard, pheochromocytomas are best suited to the transperitoneal approach (31).

Unilateral laparoscopic adrenalectomy is the treatment of choice for patients with Cushing's syndrome due to unilateral adrenal adenomas.

After an initial controversy, laparoscopic adrenalectomy for pheochromocytoma is now well accepted as a standard indication for unilateral or bilateral disease.

The quintessential objective during laparoscopic adrenalectomy is early control of the adrenal vein, and in this regard, pheochromocytomas are best suited to the transperitoneal approach.

The posterior retroperitoneal approach has also been utilized because it also allows early access to the adrenal vein, particularly for right-sided pathology (28).

Possible Malignancy

Laparoscopic management of possible adrenal malignancy has been an area of controversy. Firstly, size criteria for the removal of nonfunctioning incidental adrenal masses continue to evolve, and secondly, debate exists as to whether it is appropriate to manage potentially malignant adrenal lesions laparoscopically.

Adrenal carcinomas are larger than 6 cm in size in 92% of cases; however, because computed tomography scanning can underestimate the true size of a lesion, a limit of 5 cm has been used empirically.

Nonfunctioning Incidentalomas

Adrenal carcinomas are larger than 6 cm in size in 92% of cases; however, because computed tomography scanning can underestimate the true size of a lesion, a limit of 5 cm has been used empirically (32–34).

Other factors that require consideration include the patient's age and comorbidities, and the burden associated with ongoing monitoring of the lesion. Older patients are more likely to have nonfunctioning adenomas, whereas younger patients may require serial imaging for many years (24). The management of 3 to 6 cm nonfunctioning adrenal masses is controversial, but laparoscopic adrenalectomy is recommended if the lesion has suspicious features on imaging, demonstrates growth on serial imaging, or if the patient is young and fit (24).

Adrenal Malignancy

Another matter of debate is the oncological safety of laparoscopic adrenalectomy for primary adrenocortical carcinoma and metastatic disease. Opinion varies from absolute contraindication (35–37) to acceptance as a form of treatment for large, potentially malignant lesions up to 15 cm in diameter, provided that the lesion is not locally invasive (38,39). Sung and Gill recommend open adrenalectomy if the mass is larger than 10 cm in size, is locally invasive, or has tumor thrombus (6). Smaller, discrete, solitary metastases or primary carcinomas may, however, be suitable for laparoscopic resection (6). Although successful laparoscopic management of primary and metastatic adrenal masses has been reported (38–40), case reports of local recurrence following laparoscopic adrenalectomy for carcinoma have been described (41–44).

It is now generally considered reasonable to perform laparoscopic adrenalectomy for organ-confined disease if the tumor is not locally invasive and if the surgeon is experienced (5,39,40).

Masses demonstrating local organ invasion or venous tumor thrombus are not suitable for laparoscopic resection, because the ability to achieve an adequate en-bloc resection is extremely difficult in this setting (7,8,34,45). Hand-assisted techniques, however, may overcome this (7,45,46).

In contrast to primary adrenocortical carcinomas, metastatic lesions are generally small and confined to the adrenal gland, and thus amenable to laparoscopic resection (8). Laparoscopic adrenalectomy for metastatic disease may be indicated provided that the primary cancer is controlled or controllable, other metastatic diseases, if present, are resectable, and the patient is fit enough to tolerate general anesthesia (8,40).

Symptomatic Lesions

Benign but nonfunctioning lesions may also require laparoscopic adrenalectomy for control of local symptoms. Myelolipomas larger than 4 cm in size should be considered for resection because of the potential for life-threatening hemorrhage (47).

Masses demonstrating local organ invasion or venous tumor thrombus are not suitable for laparoscopic resection, because the ability to achieve an adequate en-bloc resection is extremely difficult in this setting. Hand-assisted techniques, however, may overcome this.

TABLE 2 ■ Contraindications for laparoscopic adrenalectomy

	Absolute contraindications	Relative contraindications
General	Severe cardiopulmonary disease Uncorrected coagulopathy	Pregnancy ^a Prior intra-abdominal or retroperitoneal surgery ^b
Specific	Uncontrolled pheochromocytoma Invasive carcinoma or tumor thrombus	Primary carcinoma ^c Malignant pheochromocytoma ^c Mass >6 cm ^c

^aPerform in second trimester if clinically required.
^bMay be performed via an alternative approach.
^cControversial.

Contraindications

The contraindications for laparoscopic adrenalectomy are summarized in Table 2.

Absolute

There are few absolute contraindications for laparoscopic adrenalectomy. General contraindications for surgery such as severe cardiopulmonary disease and uncontrolled coagulopathy also apply to laparoscopic adrenalectomy.

Specifically, pheochromocytomas should be medically controlled with alpha- and beta-adrenergic blockade prior to surgery to avoid intraoperative hypertensive crises. As discussed above, invasive carcinoma and carcinoma with tumor thrombus are considered to be contraindications at present.

Relative

Pregnancy is a relative contraindication for laparoscopic adrenalectomy, and the procedure is best deferred until after delivery when possible, especially if the adrenal lesion is diagnosed in the third trimester. However, clinical circumstances may mandate surgery during pregnancy. Shalhav et al. (48) summarized the important points of performing laparoscopic adrenalectomy during pregnancy as follows:

- Perform surgery during the second trimester, because surgery in the first trimester carries a risk of spontaneous abortion and congenital abnormalities, while surgery in the third trimester carries a higher risk of premature labor.
- Open access is preferred to avoid insufflation of the uterus with resultant CO₂ embolism. As an alternative, closed pneumoperitoneum can be created with the subcostal passage of a Veress needle.
- The pneumoperitoneum should be ≤ 12 mmHg.
- Fetal monitoring should be performed throughout the procedure.

Obesity may make laparoscopic surgery more challenging; however, the obese patient has much to gain from a laparoscopic approach. In obese patients, laparoscopic adrenalectomy has been shown to be more effective than open surgery because it offers significant benefits in terms of postoperative recovery and convalescence (49).

Extensive previous intra-abdominal surgery may preclude a transperitoneal laparoscopic approach; however, the retroperitoneal route may be used (8). Conversely, a transperitoneal approach may be preferable in cases of previous retroperitoneal surgery. In rare cases of extensive previous surgery in both the peritoneal cavity and the retroperitoneum, a transthoracic approach has been described as an option (8). The issue of primary and metastatic adrenal disease is controversial as discussed in the preceding section. Similarly, the upper limit for safe resection with respect to size is also debatable. A maximum of 6 cm was previously recommended (35,50). However, lesions of up to 15 cm have been resected (22,38).

The upper size limit that may be safely resected is not an absolute, arbitrarily defined number, but rather relates to the surgeon's experience, size of the lesion, patient body habitus, surrounding anatomy, and, because right-sided tumors may be intimately associated with the inferior vena cava, the side of the lesion (45).

Gill recommends that laparoscopic adrenalectomy may not be advisable for lesions greater than 10 to 12 cm in diameter (8). At least initially, it would not be unreasonable to use 6 cm as an upper limit for resectability because larger lesions are technically more demanding (34). Age per se is not a contraindication. Laparoscopic adrenalectomy has been well described in pediatric patients via both transperitoneal and retroperitoneal approaches, although the transperitoneal approach may be preferable because of the smaller working space in children (24,51).

The upper size limit that may be safely resected is not an absolute, arbitrarily defined number, but rather relates to the surgeon's experience, size of the lesion, patient body habitus, surrounding anatomy, and, because right-sided tumors may be intimately associated with the inferior vena cava, the side of the lesion.

PREOPERATIVE PREPARATION

The preoperative preparation encompasses the general preparation of a patient for any major abdominal surgery, and, additionally, the optimization of specific metabolic and endocrine abnormalities imposed by the pathology.

Informed consent should warn the patient of the risks of conversion to open surgery, adjacent organ injury, hemorrhage, and blood transfusion. Blood should be cross-matched, and the patient fasted for six hours prior to surgery. The operative side should be confirmed with the patient prior to admission to the operating theatre and marked on the patient's abdomen away from the operative site to avoid tattooing the skin. All imaging should be placed on the viewing screens in the operating theatre and reviewed prior

to the commencement of surgery. Antithromboembolism stockings and pneumatic compression devices should be applied and subcutaneous heparin administered on induction as part of deep venous thrombosis prophylaxis. Antibiotic prophylaxis with an intravenous cephalosporin should be administered on induction. Bowel preparation is not routinely administered, because the incidence of bowel injury is extremely low.

Specific electrolyte and metabolic abnormalities are corrected in close liaison with an endocrinologist. Patients with aldosteronomas may have hypokalemia requiring correction with potassium supplements or potassium-sparing diuretics. Pheochromocytomas require preoperative blood pressure control, initially with alpha-adrenergic blockade, followed by beta-adrenergic blockade if reflex tachycardia occurs. An arterial line and central venous cannula are placed for intraoperative monitoring.

TECHNIQUE

Options

The primary approaches to the adrenal gland are via either the transperitoneal or retroperitoneal route (Table 3). The transperitoneal route may be anterior, with the patient in a supine or semilateral position, or lateral, with the patient in the lateral decubitus position. The retroperitoneal approach may also utilize the lateral decubitus position or alternatively, the patient may be placed in the prone jack-knife position and the adrenal gland approached from the posterior aspect. More recently, a transthoracic approach has also been described (12). The advantages and disadvantages of each of the transperitoneal and retroperitoneal routes have been extensively addressed in the literature and are summarized below in Table 3.

Lateral Transperitoneal Approach

In this approach, the lateral decubitus position allows the viscera to fall medially with gravity, facilitating access to the adrenal gland (45). This contrasts the anterior approach in which the adrenal lies in the most dependent part of the operative field (45).

Early access to the adrenal vein prior to manipulation of the adrenal gland or periadrenal tissue is the main advantage of the lateral transperitoneal route (31).

This is not only of particular importance in cases of pheochromocytoma (31), but, in accordance with basic oncological principles, is also important to achieve early vascular control to minimize the risk of tumor cell embolism in cases of suspected malignancy (61).

Mobilization of the colon is rarely required on the right side; however, mobilization of the splenic flexure and descending colon are required to gain access to the left adrenal vein.

Other advantages of this approach include the familiarity of intraperitoneal landmarks and a large working space (5,46). It is therefore a useful approach for less-experienced surgeons and for larger lesions.

Early access to the adrenal vein prior to manipulation of the adrenal gland or periadrenal tissue is the main advantage of the lateral transperitoneal route.

Mobilization of the colon is rarely required on the right side; however, mobilization of the splenic flexure and descending colon are required to gain access to the left adrenal vein.

TABLE 3 ■ Advantages and Disadvantages of Transperitoneal and Retroperitoneal Routes

Approach	Advantages	Disadvantages
Transperitoneal lateral	Early venous control Large working space Familiar landmarks Adrenal exposure facilitated by gravity	Mobilization of viscera (liver, spleen and descending colon) Repositioning if bilateral
Transperitoneal anterior	Early venous control Large working space Familiar landmarks No repositioning if bilateral	Mobilization of viscera (liver, spleen and descending colon) Difficult exposure
Retroperitoneal lateral	Peritoneal cavity avoided	Difficult access to vein Small working space Unfamiliar landmarks Repositioning if bilateral
Retroperitoneal posterior	Peritoneal cavity avoided Early venous control No repositioning if bilateral	Small working space Unfamiliar landmarks Jack-knife position

Source: From Refs. 5,7,21,23,24,28,30,31,45, 46,51–60.

The potential disadvantages are an increased risk of adjacent organ injury and slower convalescence (5,23,52). However, as discussed below, the literature comparing transperitoneal and retroperitoneal approaches does not consistently demonstrate significant differences between the two.

Anterior Transperitoneal Approach

The anterior transperitoneal approach, utilizing either the supine or semilateral position, was used initially but has now largely fallen out of favor because of the difficulty associated with accessing the adrenal (5,7,62). The visceral contents do not fall away with the effects of gravity, and the adrenal lies in a dependent position in the operative field (46). Blood therefore tends to pool around the adrenal, and multiple ports and retractors are required to facilitate exposure of and access to the adrenal gland (46,63).

This approach may be useful in cases requiring bilateral resection because it avoids intraoperative repositioning of the patient (51), but given the advantages in exposure with the lateral approach, our preference is to reposition the patient after the first side has been completed.

Lateral Retroperitoneal Approach

The lateral retroperitoneal approach allows more direct access to the adrenal gland and therefore may potentially facilitate convalescence and decrease morbidity. In particular, select patients with morbid obesity or a history of extensive intra-abdominal surgery may benefit from the lateral retroperitoneal approach (53).

Disadvantages include a smaller working space, lack of familiar anatomical landmarks, difficulty in identifying the adrenal gland in the retroperitoneal fat, and the need for intraoperative repositioning in cases of bilateral resection (5,24,46). For these reasons, this approach is not recommended for lesions more than 5 to 6 cm or inexperienced laparoscopists (23,29,51). Laparoscopic ultrasound has been advocated as a useful adjunct to dissection in order to help overcome these difficulties (6,64–66). Although early control of the adrenal vein has been reported with this technique (53), extensive dissection is usually required in order to achieve vascular control (31) and it is therefore not recommended for pheochromocytoma (30).

Select patients with morbid obesity or a history of extensive intra-abdominal surgery may benefit from the lateral retroperitoneal approach.

The posterior retroperitoneal approach utilizes the prone jack-knife position. Besides the advantages and disadvantages of the retroperitoneal approach, it also allows access to both glands for bilateral procedures.

Posterior Retroperitoneal Approach

The posterior retroperitoneal approach utilizes the prone jack-knife position. In addition to the above advantages and disadvantages of the retroperitoneal approach, it also allows access to both glands for bilateral procedures (51,54).

Early venous control can also be achieved by this approach, particularly on the right where the adrenal vein tends to run in a slightly retrocaval course (21,55). The main disadvantages of this route are problems caused by the prolonged jack-knife position along with the small working space (21,55). Therefore, this approach is not recommended for lesions greater than 5 to 6 cm in diameter (54,55).

Transperitoneal vs. Retroperitoneal Approaches

One of the primary controversies currently surrounding laparoscopic adrenalectomy relates to transperitoneal versus retroperitoneal approaches (Table 4). Comparative studies to date have not found significant differences between the two approaches in terms of surgical efficacy and convalescence.

Initial series suggested that the transperitoneal route was associated with longer operative times (56,63,75); however, these studies compared retroperitoneal access with the anterior transperitoneal approach, which is known to involve more difficult adrenal exposure than the lateral transperitoneal approach. Latter studies comparing transperitoneal and retroperitoneal routes have shown either no difference in operative times (57,68,70,72–74,76) or shorter operative times for the lateral transperitoneal approach (52,67,69,71). Lezoche et al. found that for left-sided adrenalectomies, operative times were longer for the transperitoneal approach than the retroperitoneal approach, but for right-sided lesions, there was no difference between the two (61).

Similarly, earlier studies demonstrated greater blood loss with the anterior transperitoneal route (56,63,75); however, later studies examining the lateral transperitoneal approach have not reproduced this finding (52,67–71,73).

Comparative studies to date have not found significant differences between the transperitoneal and retroperitoneal approaches in terms of surgical efficacy and convalescence.

TABLE 4 ■ Comparison of Transperitoneal and Retroperitoneal Approaches (Significant Differences Indicated)

Author	Approach	Number	Size	Operative time (min/hr)	Blood loss (mL)	Analgesia	Oral intake (day/hr)	Ambulation (day)	Length of stay (day/hr)	Convalescence (day)	Conversions	Complications
Giger et al. (67)	LTA (R)	9	4.9 cm	79	49				4.7			1
	LRA (L)	11	4.5 cm	114	73				5		2	1
	LTA (bilateral)	3	4.9 cm	223	110				6			
	ATA	28	<6 cm	202	113		1.4	1.4	9	20.8	4	
Naya et al. (68)	RPA	22	<6 cm	221	192		1.3	1.3	9.5	21.9	3	
	ATA	77	4.5 cm ^a	91 (R)		NS			2.8			1
Lezoche et al. (61)	LTA	72	4.7 cm ^a	117 (L)		NS					1	1
				94 (R)					2.9			
				98 (L)								
Liao et al. (69)	PRA	67	3.0 cm ^a	89 (R)		NS			3.4		3	2 + 1 death
				109 (L)								
Liao et al. (69)	LTA	15	3.5 cm	166 ^b	57	50 mg	26		5.3			3
	LRA	16	2.4 cm	244 ^b	86	40 mg	31		4.4		2	1
	Open	21	2.6 cm	123 ^c	124 ^c	120 mg ^c	2.5 ^c		7.6 ^c			
	ATA	16	2.53 cm	174.7 ^d	80.6		2.4 ^e	1.7 ^e		4.7	2	4
Suzuki et al. (52)	LTA	25	2.48 cm	118.1 ^d	49.2		1.5 ^e	1.3 ^e		4.8	2	6
	LRA	36	2.32 cm	176.1 ^d	58.4		1.4 ^e	1.3 ^e		4.2	2	4
Takeda (70)	ATA	52	NA	203	115.6		1.9	1.4			1	
	LRA	24	NA	257	141.6		1.1	1.4			1	
	Open	57		143 ^f	214 ^f		2.5 ^f	2.4 ^f				
	LTA	8	2.5 cm	129 ^g	42		1.2	1.2			0	1
Yoneda et al. (71)	PRA	8	1.2 cm	269 ^g	88		1.3	1.3			1	2
Fernandez-Cruz et al. (72)	LTA (unilateral)	16		88.75	160	3.25 doses			3	12.5	2	
	LRA (unilateral)	14		105.0	180	3.5 doses			2.75	12.25	2	
	LTA (bilateral)	6		271.66	406.66	7.16 doses			6	19.66		
	LRA (bilateral)	6		305.0	370	6.0 doses			6.66	19.33		
Sung et al. (73)	LTA	13	49.6 g	156.4	52.9	15.2 mg			25		1	
Chee et al. (74)	LRA	11	65.4 g	142.3	60.2	4.0 mg			27.5		1	
Miyake et al. (56)	LTA	8		136	NS	NS				NS		NS
	LRA	6		132	NS	NS				NS		NS
Miyake et al. (56)	ATA ⁱ	17	1.92 cm	423 ^h	406 ⁱ	2.9 doses	1.8	2.3			0	4
	LRA	12	1.96 cm	300 ^h	164 ⁱ	2.3 doses	1.4	1.9			0	2

(Continued)

TABLE 4 ■ Comparison of Transperitoneal and Retroperitoneal Approaches (Significant Differences Indicated) (Continued)

Author	Approach	Number	Size	Operative time (min/hr)	Blood loss (mL)	Analgesia	Oral intake (day/hr)	Ambulation (day)	Length of stay (day/hr)	Convalescence (day)	Conversions	Complications
Baba et al. (75)	ATA	33	2.71 cm	252 ^j	101 ^j	35 mg			6.1		3	5
	LRA	5	2.86 cm	194 ^j	22 ^j	27 mg			5.6		0	1
	PRA	13	2.79 cm	142 ^j	32 ^j	30 mg			5.6		1	1
Bonjer et al. (63)	ATA	9	3 cm	150 ^k	150 ^l	20 mg ^m			6 ^m		2	2
	LRA	12	4 cm	75 ^k	20 ^l	6 mg ^m			4 ^m		1	0
	Open	9	3 cm	60 ^k	175 ^l	34 mg ^m			6 ^m			2
Takeda et al. (57)	ATA	27	10.5 g ⁿ	231.8	155.3		1.41	1.82			0	
Duh et al. (76)	LRA	11 ^o	15.0 g ⁿ	248.3	151.4		1.55	2			1	7
	LTA	23	5.3 cm	3.76					2.2		0	4 + 1 death
	PRA	14	2.6 cm	3.36					1.4		0	

^aSignificantly larger in the transperitoneal groups compared to PRA.^bLRA significantly longer than LTA.^cOpen approach significantly different from laparoscopic approaches.^dLTA significantly faster than ATA and LRA.^eOral intake and ambulation faster for LRA than ATA but not different from that of LTA.^fSignificant differences compared to both laparoscopic groups.^gLTA involves significantly shorter operative time than PRA.^hLeft-sided ATA significantly longer than right-sided ATA and left-sided LRA, but right-sided ATA not significantly different from right-sided LRA.ⁱATA involves significantly more blood loss than LRA.^jATA involves significantly longer and more blood loss than LRA and PRA.^kATA involves significantly longer operative time compared to LRA and open approach.^lLRA involves significantly lesser blood loss compared to ATA and open approach.^mLRA involves significantly lesser analgesic use compared to ATA and open approach and shortest hospital stay.ⁿSignificantly greater gland weight in the LRA group.^oThree converted to transperitoneal approach because of intraoperative difficulties.

Abbreviations: ATA, anterior transperitoneal laparoscopic adrenalectomy; LTA, lateral transperitoneal laparoscopic adrenalectomy; LRA, lateral retroperitoneal laparoscopic adrenalectomy; PRA, posterior retroperitoneal laparoscopic adrenalectomy; RPA, Retroperitoneal adrenalectomy; NS, Not significant

Reported series have not consistently demonstrated significant differences in analgesic requirement, time to oral intake, ambulation, length of stay, convalescence, conversion rates, and complication rates between the transperitoneal and retroperitoneal approaches.

Tumor size, obesity, and the learning curve are the most important factors influencing operative outcome .

Overall, reported series have not consistently demonstrated significant differences in analgesic requirement, time to oral intake, ambulation, length of stay, convalescence, conversion rates, and complication rates between the two approaches.

Surgical experience and body mass index independently predict operative times (52,61,68), whereas blood loss has also correlated with operative experience and tumor size (52). Tumor size, obesity, and the learning curve are the most important factors influencing operative outcome (52).

Overall, these studies have not consistently shown significant beneficial differences between the retroperitoneal and transperitoneal approaches. Rather than the approach used, surgeon experience, patient habitus, and size of the lesion affect operative outcome measures. Given the lack of evidence demonstrating any advantage of the retroperitoneal technique, in conjunction with the advantages of the lateral transperitoneal approach, particularly with regard to early venous control, we routinely use the latter approach as our preferred method of laparoscopic adrenalectomy. However we concur with the statements of Sung et al., who indicate that surgeons should be familiar with both transperitoneal and retroperitoneal approaches because individual case characteristics may dictate the use of one approach in preference to the other (73).

LATERAL TRANSPERITONEAL TECHNIQUE

Equipment and Theatre Set-Up

Tables 5 and 6 list the equipment used. The operating table is placed obliquely in the operating theatre with the anesthetic equipment at the head of the table and the camera stack system, containing the insufflator, monitor, light source, and camera system, at the foot (Fig. 1). In this position, the scrub nurse can easily view the monitor. The diathermy machine is placed next to the stack system. Because we prefer to operate with a larger image, we use a 5-foot projector screen placed in the far corner of the operating theatre, with a projector placed on the opposite side to the surgeon close to the head of the table. If available, a plasma screen is also suitable. The patient is placed in the lateral decubitus position. The surgeon stands in front of the patient with the assistant on the surgeon's left and the Mayo table on his/her right. The Mayo table is useful to place frequently used instruments such as the clip applicator, hook diathermy, and diathermy scissors in easy reach of the surgeon. The scrub nurse's tables are on the opposite side to the surgeon adjacent to the diathermy machine. It is useful for the nurse to be seated so as not to block the surgeon's view of the screen. Similarly, it is useful for either the assistant to be seated or to stand on a platform, or the surgeon to stand on a platform; this places the surgeon's arms and assistant's arms at different levels to avoid clashing.

TABLE 5 ■ Standard Laparoscopic Equipment

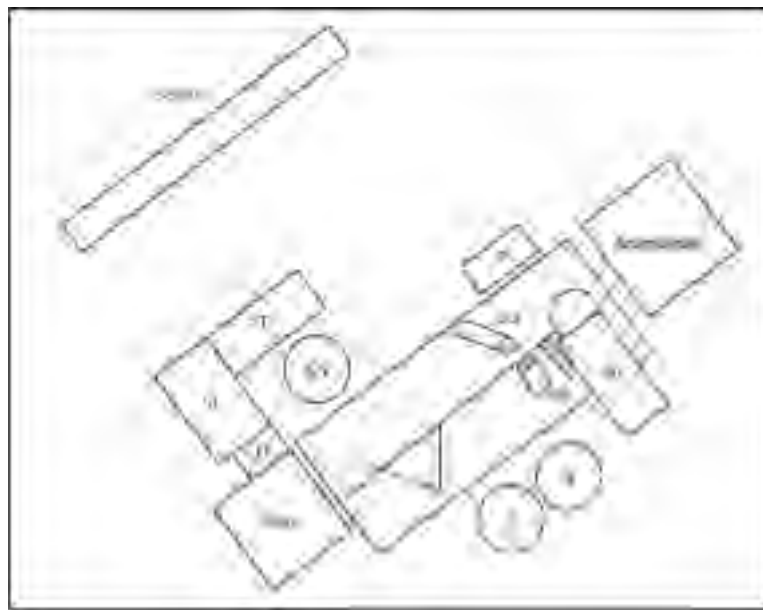
Olympus SX2-3 chip camera
Eschmann MR operating table
Warming mattress
Gel mattress
Bair hugger
Urology stack system with insufflator, light source, and monitor
Valley lab diathermy

TABLE 6 ■ Specific Laparoscopic Adrenalectomy Equipment

No. 11 scalpel blade
2 Langenbeck retractors
0° Laparoscope
4 × 5-11 Autosuture Versaseal ports with spring grip (Tyco Healthcare, Mansfield, U.S.A.)
5 mm Electrosurgical scissors
5 mm Electrosurgical hook
10 mm Autosuture Endoretract^a
10 mm ML Endoclip^a
10 mm Endocatch^a bag
Tonsil swabs
5 mm laparoscopic suction probe
Camera sleeve
Sterile flask filled with hot water to warm laparoscope
Endo-GIA 30 with reloads
Projection screen and projector
Mayo table
5 mm Maryland dissecting forceps
2 × Laparoscopic needle holders
3/0 Prolene vascular suture on a round-bodied needle
Have available—laparotomy set with vascular clamps and 4 × small bulldog clips

^aU.S. Surgical Corp., Norwalk, CT.

FIGURE 1 ■ Operating theatre set-up for right-sided laparoscopic adrenalectomy. Abbreviations: D, diathermy; ST, scrub table; SN, scrub nurse; P, projector; A, assistant; S, surgeon; MT, Mayo table; LQ, long quiver for sucker; SQ, short quiver for hand-held diathermy.



Steps

The steps involved in transperitoneal laparoscopic adrenalectomy include:

1. Patient positioning
2. Access and port placement
3. Exposure
4. Control of the adrenal vein
5. Mobilization of the adrenal gland
6. Removal and closure

Patient Positioning

Following induction, the patient is catheterized with a 16 French urethral catheter. A nonsteroidal analgesic suppository is then placed if there is no contraindication. A nasogastric tube is placed to deflate the stomach. The patient is placed in a standard lateral decubitus position with the table broken, a padded lumbar support behind the patient's upper back, both elbows flexed with the upper forearm supported on a padded arm rest, and the upper leg straight and the lower leg flexed at the knee and thigh. The patient lies on a gel mattress with a pillow placed between the legs and padding applied to lower knee and ankle. Broad adhesive tape is applied across the hips and the diathermy pad is placed on the thigh or buttock of the upper leg.

The operative field is prepared with aqueous povidone-iodine and draped with possible open conversion in mind. The diathermy leads, light leads, inflow tubing, and suction tubing run to the video stack and diathermy machines at the foot of the table, and are covered with another drape. A large clear adhesive film is used to secure the drapes and isolate the operative field. A long scabbard for the sucker is placed on the opposite side to the surgeon toward the head, and a short scabbard for the hand-held diathermy is placed on the same side.

Right Side

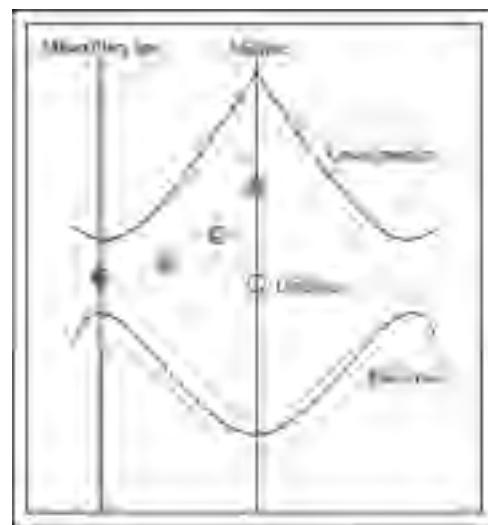
The aim of a right-sided laparoscopic adrenalectomy is to remove the adrenal gland with early ligation of the adrenal vein. It is essentially a dissection of the inferior vena cava.

Access and Port Placement. Four 5-11 Versaport™^a disposable ports are used (Fig. 2). The first port is placed between the umbilicus and the tip of the ninth rib using an open access technique, close to the inferior epigastric artery. The two working ports are placed under direct vision on either side of the first port parallel to the costal margin approximately in the midline and the anterior axillary line. The fourth port is placed superior to the iliac crest in the midaxillary line and is used for the fan retractor. We prefer to

The aim of a right-sided laparoscopic adrenalectomy is to remove the adrenal gland with early ligation of the adrenal vein. It is essentially a dissection of the inferior vena cava.

^aU.S. Surgical Corp., Norwalk, CT.

FIGURE 2 ■ Port positions for right-sided transperitoneal laparoscopic adrenalectomy.



use a 0° laparoscope because it is easier for the assistant to orient the image correctly. The gas flow is commenced on high flow with a pressure limit of 15 mmHg.

Exposure. Following port placement, the operative field is inspected, noting particularly whether the adrenal lesion is visible and also the relationship of the adrenal to the surrounding structures: the hepatic flexure, the right lobe of the liver, the inferior vena cava, and also the duodenum. The inferior vena cava lies just behind the peritoneum, and thus the hepatic flexure and duodenum do not usually require mobilization. However, in some cases, these maneuvers may be necessary.

A fan retractor is passed through the most lateral port to elevate the right lobe of the liver, and the assistant holds this gently in position. Alternatively, an adjustable fixed table retractor may be used (77). We find a combination of sharp and blunt dissection with scissors and hook to be the most expedient mode of dissection. Others have found the harmonic scalpel to be of particular value in reducing operative time (78). We prefer diathermy because we find it more expedient, but this is largely a matter of individual preference.

The inferior leaf of the right coronary ligament is incised to allow superior retraction of the liver with the fan retractor. For large lesions, it may be necessary to incise the right triangular ligament. The peritoneum over the inferior vena cava is incised and the inferior vena cava traced superiorly and inferiorly using a combination of sharp and blunt dissection.

In accordance with general vascular principles, it is safer to dissect close to the vena cava to avoid troublesome small-vessel bleeding from the adjacent tissue and also to minimize the risk of injury to the cava.

Vascular Control. Once the adrenal vein is identified, it is clipped twice on the inferior vena cava side and once on the specimen side, and then divided. Extreme caution must be exercised when dissecting the adrenal vein because bleeding from this may be extremely difficult to control due to its position in the hepatorenal pouch and its drainage into the vena cava.

It is not necessary to dissect fully around behind the vein, and such dissection behind the vein may result in bleeding that is difficult to access and control. It is therefore safer to clip the vein once it has been exposed to a reasonable degree. Because this vein is short, it is important to place the two cava-side clips as close as possible to each other, thereby exposing a reasonable segment of the vein between the two sets of clips to divide with scissors. Occasionally, the adrenal vein may be wide and require division using an Endo-GIA^{TMb}. In such instances, the right hand working port will need to be exchanged for a 5-12 port to accommodate the instruments.

Mobilization of the Gland. Once the adrenal vein has been divided, the vein is grasped with dissecting forceps and elevated. The hook diathermy is used to mobilize the medial aspect of the gland off the posterior abdominal wall.

In accordance with general vascular principles, it is safer to dissect close to the vena cava to avoid troublesome small-vessel bleeding from the adjacent tissue and also to minimize the risk of injury to the cava.

Extreme caution must be exercised when dissecting the adrenal vein because bleeding may be extremely difficult to control due to its position in the hepatorenal pouch and its drainage into the vena cava.

^bU.S. Surgical Corp., Norwalk, CT.

The inferior aspect of the gland is mobilized from the upper pole of the kidney; dissecting a few millimeters away from the surface of the adrenal, taking care not to cut or tear the gland, will minimize small-vessel bleeding.

The aim of a left-sided laparoscopic adrenalectomy is to remove the adrenal gland and periadrenal fat with early ligation of the adrenal vein. It is essentially a dissection of the left renal vein.

The aim is to identify the renal vein and dissect along its superior aspect to locate the adrenal vein draining into it.

Because the medial aspect of the gland is mobilized, it is important to be aware of the tail of the pancreas and the splenic vein, which are in close proximity. The pancreatic tail may be confused with the adrenal gland; however, the characteristic golden appearance of the adrenal is a useful guide.

The superior, inferior, and lateral aspects of the gland are sequentially mobilized, and the superior, middle, and inferior adrenal arteries are controlled with clips as they are encountered. The exact order of dissection is not important and may vary between cases; however, we generally mobilize the lateral aspect of the gland last because the lateral attachments aid stability of the gland.

The inferior aspect of the gland is mobilized from the upper pole of the kidney; dissecting a few millimeters away from the surface of the adrenal, taking care not to cut or tear the gland, will minimize small-vessel bleeding.

Removal and Closure. Once the gland has been fully mobilized, it is placed in an Endocatch I^{®c} bag and left in the abdomen while hemostasis is checked. Surgicel^{®d} is placed to control any minor venous ooze, and the specimen is removed through the primary port site. A drain is not routinely placed. The wounds are closed with one PDS for the muscle, 2/0 Monocryl for the superficial fascia, and 4/0 Monocryl for the skin. The wounds are infiltrated with 0.25% plain marcan. The nasogastric tube is removed.

Left Side

The aim of a left-sided laparoscopic adrenalectomy is to remove the adrenal gland and periadrenal fat with early ligation of the adrenal vein. It is essentially a dissection of the left renal vein.

In contrast to right-sided laparoscopic adrenalectomy, the descending colon and splenic flexure require medial mobilization to identify the left adrenal vein.

Access, Port Placement, and Exposure. Port placement is the mirror image of the right-sided approach. Using a combination of sharp and blunt dissection with the dissecting forceps and the diathermy scissors, the line of Toldt is incised, and the plane between the posterior peritoneum and the anterior aspect of Gerota's fascia is developed to reflect the colon medially. Careful sharp dissection of any adhesions to the spleen is required to prevent avulsing segments of the splenic capsule.

Control of the Adrenal Vein. Once the colon has been reflected medially, attention is focused on the renal hilum. The fan retractor is passed through the most lateral port and is used to displace the kidney upward. The aim is to identify the renal vein and dissect along its superior aspect to locate the adrenal vein draining into it.

The inferior phrenic vein courses along the medial border of the adrenal and may be used as a landmark to the left adrenal vein (13,79). However, we find the renal vein to be more readily identifiable and reliable than the inferior phrenic vein. Once the adrenal vein has been identified, it is clipped and divided in a similar fashion as the right side.

Mobilization, Removal, and Closure. The adrenal vein is used to lift the gland up and develop the plane along the posterior abdominal wall. The gland is mobilized superiorly, inferiorly, and laterally using a combination of sharp and blunt dissection with the hook diathermy.

Because the medial aspect of the gland is mobilized, it is important to be aware of the tail of the pancreas and the splenic vein, which are in close proximity. The pancreatic tail may be confused with the adrenal gland; however, the characteristic golden appearance of the adrenal is a useful guide.

The superior, middle, and inferior adrenal arteries are controlled with clips as they are encountered. The plane between the upper pole of the kidney and adrenal is developed to mobilize the inferior aspect of the adrenal, and the leinorenal ligament is divided to free the superior aspect from beneath the spleen. The fan retractor is used to retract the spleen superiorly to facilitate dissection. The lateral attachments of the spleen to the diaphragm may require division in order to expose the superior aspect of the adrenal. Once fully mobilized, the specimen is removed and the wounds closed in the usual manner.

Postoperative Care and Follow-Up

Cases of pheochromocytoma are monitored in the high dependency unit on the first night. Patients are allowed to sip 30 mL water per hour. Thromboembolism prophylaxis with subcutaneous heparin or Clexane in conjunction with pressure stockings is continued. A regular nonsteroidal anti-inflammatory and paracetamol are prescribed, and intravenous narcotic via a patient-controlled analgesia pump is used overnight.

^cU.S. Surgical Corp., Norwalk, CT.

^dJohnson & Johnson, Somerville, NJ.

Antibiotics are not routinely continued. On the first day, the patient-controlled analgesia and urethral catheter are removed, and the patient is upgraded to a fluid and then full diet as tolerated. The patient is usually discharged on the second or third postoperative day. The postoperative stay may be longer in cases of functioning lesions, where hormonal and metabolic factors need to be corrected in coordination with the endocrinologist. Steroid replacement if required is continued. Potassium and other electrolytes are monitored daily, and potassium supplements withdrawn as required. Following discharge, the patient is reviewed at four to six weeks to check the surgical sites and general convalescence.

TECHNICAL CAVEATS

Hemostasis

Absolute hemostasis is essential for a successful procedure. The physiological impact of minor blood loss is minimal; however, by staining tissues, masking tissue planes, and darkening the image through light absorption, it can make the procedure technically more demanding. It is best to operate slowly and achieve good hemostasis rather than accept minor bleeding and “push on.” Invariably, the more slowly but deliberately one operates the faster the operation progresses overall.

Typically, troublesome bleeding may occur from:

- The adrenal vein as it enters the inferior vena cava or renal vein on the right and left sides, respectively;
- Small vessels in the periadrenal fat, particularly when developing the plane between the upper pole of the kidney and the adrenal;
- The inferior phrenic vein tributary to the left adrenal vein as it courses along the medial aspect of the gland;
- Tributaries of the main renal veins that may be at risk from traction injury;
- An inadvertent breach of the adrenal gland itself;
- The left lumbar and gonadal veins that may be at risk of avulsion from traction as they enter into the left renal vein complex;
- The superior, middle, and inferior adrenal arteries; and
- Lumbar veins entering the inferior vena cava that, particularly with large lesions, may be at risk during medial mobilization. However, in most cases, these vessels are well medial to the line of dissection.

There are several methods available to control bleeding, ranging from diathermy to conversion. If the bleeding point is small and easily seen, then simple diathermy with the diathermy scissors may suffice. A useful maneuver is to attach the diathermy lead to the dissecting forceps in the left hand and the sucker in the right hand. The sucker is used to clear the field of blood, and the bleeding vessel is then grasped and diathermied with the dissecting forceps. An endoclip may alternatively be applied. A left-handed surgeon may find the opposite easier.

If the bleeding source is difficult to identify, a tonsil swab may be pressed down onto the bleeding area before definitive hemostasis is undertaken.

Depending on the experience of the surgeon, the application of bulldog clips to gain proximal and distal control of a larger bleeding vessel such as a renal vein branch may be useful. These clips can be passed down a 10 mm port with a large toothed grasper. Similarly, direct intracorporeal suturing may be required; however, this may be difficult because the working space at the site of bleeding may be quite cramped. These latter methods require considerable laparoscopic experience and inexperienced practitioners would be best served converting to open surgery to control significant hemorrhage.

At all times, patient safety is paramount, and it is essential that the practitioner has a low threshold for open conversion to control significant hemorrhage.

At all times, patient safety is paramount, and it is essential that the practitioner has a low threshold for open conversion to control significant hemorrhage.

Open Conversion

In some cases, intraoperative conversion may be required. Our indications for intraoperative conversion are:

- Uncontrollable hemorrhage,
- Obvious contiguous organ invasion that necessitates en-bloc resection, and
- Failure to progress

Regarding failure to progress, we do not set an absolute time limit. As long as the procedure is proceeding safely, it is often better to finish the operation laparoscopically

We generally set a time limit of five hours for all laparoscopic procedures before conversion because in our experience, the risks of nerve compression increase significantly after this time.

On the left side, the tail of the pancreas may be confused with the adrenal, but it lacks the characteristic color of the adrenal. If it does not look like the adrenal, it is probably not the adrenal!

By applying the general principles of careful hemostasis, and careful, deliberate dissection to positively identify the relevant anatomy, the risk to adjacent organs is minimized.

rather than have the patient incur the morbidity of an open operation superimposed on a long laparoscopic procedure.

We generally set a time limit of five hours for all laparoscopic procedures before conversion because in our experience, the risks of nerve compression increase significantly after this time.

Organ Injury

Direct injury to the adrenal gland may cause troublesome bleeding and may also compromise the oncological safety of the procedure. This is best avoided by dissecting the periadrenal fat and the adrenal gland within the superior packet of Gerota's fascia as a whole rather than dissecting the gland itself.

On the left side, the tail of the pancreas may also be confused with the adrenal, but it lacks the characteristic color of the adrenal. If it does not look like the adrenal, it is probably not the adrenal!

Similarly, the spleen is at risk during left-sided procedures. Attachments to the spleen should be divided sharply to avoid avulsion of part of the splenic capsule. Incising the leinorenal ligament allows the spleen to be retracted superiorly and medially away from the operative site.

The diaphragm and colon are at risk on both sides, whereas the duodenum and liver are at risk on the right. Dividing the inferior coronary ligament to allow gentle superior retraction of the liver away from the adrenal minimizes hepatic injury.

By applying the general principles of careful hemostasis, and careful, deliberate dissection to positively identify the relevant anatomy, the risk to adjacent organs is minimized.

At times, the operative view may be compromised by camera fogging, poor lighting, or poor image quality. A detailed discussion of these issues is beyond the scope of this chapter; however, in such instances, it is imperative to stop and correct the problem rather than continue in suboptimal circumstances.

GENERAL TECHNICAL MODIFICATIONS

Procedural Modifications

The technique of lateral transperitoneal laparoscopic adrenalectomy is quite consistent in most accounts. Port positions differ slightly according to the surgeon's preference. Generally, four ports are required, with one camera port, two working ports, and one additional port for retractor placement. Most reports describe a subcostal arrangement along the line of the costal margin (24,35,37,45,50,80); however, they may also be placed in a quadrangular arrangement beneath the costal margin (81).

The primary camera port may be placed in the midline at a supraumbilical site (45) and may also be moved among the ports to aid vision (50,81). Some authors describe mobilizing or defining the adrenal prior to securing the adrenal vein (7,50,82). For the reasons stated, we do not believe that this is consistent with achieving an optimal surgical outcome.

Instrument Modifications

A variety of instrument modifications that aid in dissection of the adrenal gland have been described. The harmonic scalpel may be of particular use in reducing operative time (58,78).

Laparoscopic ultrasound probes with frequencies in the order of 5 to 7.5 MHz may be useful in identifying the adrenal gland and vein, confirming the presence or absence of an abnormality on the affected and contralateral sides, determining the resectability of large masses, facilitating partial resection, and identifying pathology in adjacent organs (6,64–66). However, data pertaining to the usefulness of this modality has been conflicting. Lucas et al. found laparoscopic ultrasound particularly useful in identifying the adrenal vein on the left when it is obscured by large amounts of retroperitoneal fat (66); in contrast, Brunt et al. found that laparoscopic ultrasound identified the vein in only 21% of cases (65). Laparoscopic ultrasound may be of particular benefit in retroperitoneal approaches where the landmarks may not be as readily apparent and the adrenal is more difficult to identify. This modality has also been used to localize extra-adrenal pheochromocytoma (83).

Ultrasonic aspirator systems have been used to aid in the dissection of the inferior vena cava and renal hilum to dissect the adrenal from the surrounding fat (84). Suzuki et al. found that the operative time was shorter and blood loss less with its use (84), whereas conversely, Takeda et al. found no differences in these parameters (85).

The argon beam coagulator has been described as useful for some right-sided lesions with attachments to the liver (85). Atraumatic suction graspers have been associated with shorter operative times and aim to facilitate gentle handling of the adrenal, allowing better exposure of the vessels by enabling retraction of the gland (86). Obermeyer et al. described administering intravenous methylene blue in five mini-Hanford pigs to aid in adrenal identification (87).

ANTERIOR TRANSPERITONEAL TECHNIQUE

As discussed previously, this approach has been largely superseded by the lateral transperitoneal approach. Typically, the patient is placed in either the supine or the semilateral position (9,58,88). Ports are generally placed in a subcostal arrangement (9,58,88). On the right side, the liver is retracted superiorly, and the paracaval posterior peritoneum is incised to achieve direct access to the inferior vena cava and therefore the adrenal vein (9,58,88). Once the vein has been divided, the adrenal is then mobilized (9,58,88). On the left side, the splenic flexure is mobilized medially and access to the adrenal achieved by reflecting the stomach and pancreatic tail medially (9,88). The adrenal vein is identified and divided, and the adrenal gland is then mobilized and removed (9,58,88).

LATERAL RETROPERITONEAL TECHNIQUE

Lateral retroperitoneal laparoscopic adrenalectomy is the main alternative to the lateral transperitoneal approach. This procedure is well described by Sung et al. and a summary is provided here (73).

Patient Positioning and Retroperitoneal Access

The lateral decubitus position is utilized. The first port is placed via an open access technique just below the tip of the 12th rib. The flank muscle fibers are separated bluntly, and the thoracolumbar fascia pierced with a hemostat or fingertip. The posterior pararenal space is developed initially with the index finger and further developed with a balloon dilator.

In our experience of retroperitoneoscopy for pyeloplasty and nephrectomy, we have found that when this space is first developed with the index finger, it is important not to sweep the finger anteriorly because this can tear the peritoneum.

Sung et al. (53) also state that it is important to finger dissect along the psoas and therefore stay outside of Gerota's fascia. The authors describe balloon dilation using a commercially available trocar-mounted balloon dilator. We use a similar system for extraperitoneal laparoscopic radical prostatectomy; however, for retroperitoneoscopy, to provide maximal protection to the peritoneum, we utilize the middle finger of a number 8 glove secured with a silk tie to the tip of an 18 French urethral catheter and instill, depending on the patient's body habitus, 500 to 700 mL of saline into the catheter.

Port Placement

A 10 mm trocar is placed as the primary port, and CO₂ pneumoretroperitoneum is created to 15 mmHg. A 30° laparoscope is inserted, and the psoas identified as the primary landmark. An anterior 5 mm port is placed in the anterior axillary line 3 cm cephalad to the iliac crest. A posterior 5 mm port is positioned at the junction of the lateral surface of the erector spinae with the inferior surface of the 12th rib. A fourth 2 mm port may also be required at the level of the primary port in the anterior axillary line for retraction of the kidney and the adrenal gland.

Control of the Main Adrenal Vein

Gerota's fascia is incised transversely at the level of the upper pole of the kidney. The upper renal pole is mobilized and allowed to fall posteriorly away from the adrenal.

On the left side, dissection continues between the upper pole of the kidney and the adrenal to the renal hilar vessels. The dissection continues medially along the renal artery or vein until the adrenal vein is identified and then clipped and divided. If the adrenal vein cannot be identified, the dissection is recommenced laterally and superiorly to free the adrenal from the diaphragm. The dissection then continues around the inferomedial aspect of the gland where adrenal vein will be identified.

On the right side, the dissection is carried superiorly along the lateral aspect of the vena cava until the adrenal vein is seen. The vein is divided, and the gland mobilized.

In our experience of retroperitoneoscopy for pyeloplasty and nephrectomy, we have found that when this space is first developed with the index finger, it is important not to sweep the finger anteriorly because this can tear the peritoneum.

Instead of incising Gerota's fascia to enter the plane between the upper pole of the kidney and the adrenal, an alternative strategy is to lift the kidney medially and anteriorly and incise Gerota's fascia just anterior to the psoas muscle and then identify the renal hilum. The dissection then continues along the lateral aspect of the vena cava on the right or aorta on the left superior to the renal hilum. On the right, the adrenal vein is encountered during this medial dissection but on the left, it may not be seen and may require circumferential mobilization of the gland before it is identified.

Specimen Mobilization, Extraction, and Closure

Following control of the adrenal vein, the gland is mobilized in a circumferential manner with meticulous hemostasis. Once mobilized, a 5 mm laparoscope is inserted through the anterior 5 mm port, a 10 mm retrieval bag is inserted through the primary port, and the specimen is retrieved. The wounds are closed after hemostasis has been checked and secured.

POSTERIOR RETROPERITONEAL TECHNIQUE

This technique is well described by Baba et al. (10,21,55,75). The patient is placed prone with the lumbar area flexed on a jack-knife table. Open Hasson cannulation is employed at the primary port site 2 cm below the tip of the 12th rib. Once the posterior pararenal space is entered, it is further developed with balloon dissection. Three ports are generally used: a 12 mm trocar 3 cm below the 12th rib on the lateral edge of sacrospinalis, a 5 mm trocar on the posterior axillary line in the 11th intercostal space, and a 12 mm trocar placed through the primary port site. If retraction of the kidney is necessary, then a further 5 mm port may be placed in the posterior axillary line above the iliac crest.

Gerota's fascia is incised along its medial aspect along quadratus lumborum and the crus of the diaphragm. The incision is continued transversely over the adrenal gland. The middle adrenal arteries are controlled as they emerge from the crus. The renal pedicle is then identified. On the right side, the inferior vena cava is observed below the level of the adrenal arteries along the crus of the diaphragm. The right adrenal vein runs in a retrocaval direction and therefore is easily dissected from the dorsal side. The vein is clipped and transected, Gerota's fascia is incised transversely, and the inferior aspect of the adrenal is mobilized from the upper pole of the kidney and the inferior adrenal vessels are controlled. The dissection then continues laterally and superiorly, and the superior vessels are controlled.

Siperstein et al. describe a similar approach but state that the position of the adrenal gland and kidney relative to the 12th rib is variable and therefore utilize transcutaneous ultrasound prior to skin preparation to mark out the position of the kidney and the adrenal gland (54). All three ports are placed below the 12th rib posteriorly. The balloon dissection is performed within Gerota's fascia. A 12 mm Optivue®^e trocar with a 0° laparoscope is used to create the primary port site inferior to the 12th rib and enter into Gerota's fascia at the upper pole of the kidney. Balloon dissection is performed, and two additional 12 mm ports are inserted on either side of the primary port. Laparoscopic ultrasound is used to confirm the position of the adrenal and the lesion. The harmonic scalpel is used for dissection, and the atraumatic suction grasper to manipulate the gland. The adrenal is mobilized initially superiorly and then laterally and inferiorly. The medial dissection is performed last, and the vein transected. The specimen is then placed in a retrieval bag and removed.

OTHER TECHNIQUES AND MODIFICATIONS

Direct Supragastric Left-Sided Adrenalectomy

Basso et al. initially described direct left-sided supragastric laparoscopic adrenalectomy (13). With the patient in the lithotomy position, the gastrophrenic ligament and one or two short gastric vessels are divided, thereby allowing displacement of the gastric fundus inferiorly and exposure of the diaphragmatic crus. The constant tributary from the inferior phrenic vein, the so-called "diaphragmatic-adrenal-renal channel," is identified and divided and traced to the adrenal vein, which is then transected. All six procedures in this series were successfully completed.

Vereczkei et al. described a similar approach wherein initial access to the adrenal gland is afforded by incising the leinodiaphragmatic ligament laterally from the left diaphragmatic crus, allowing the spleen to be retracted inferiorly and laterally.

^eEthicon, Cincinnati, OH.

The gland is dissected along its medial and then inferior aspects, and the main adrenal vein then identified and divided (14). In this series of 23 cases, however, three required conversion owing to intraoperative hemorrhage, and one case of pheochromocytoma was complicated by intraoperative hypertension secondary to gland manipulation prior to venous control.

Both of these approaches aim to minimize visceral mobilization and allow direct access to the adrenal gland; however, because the adrenal vein is accessed only after dissection of a large part of the tumor, these approaches are not suitable for removal of pheochromocytomas (5).

Hand-Assisted Laparoscopic Adrenalectomy

This technique, described by Bennett and Ray, is reported to be associated with short operative times and has the advantage of introducing tactile feedback in locating the adrenal gland. This technique utilizes the Handport^{®f}, which is placed in the upper midline for left-sided lesions and via an oblique right lower subcostal incision for right-sided procedures. The procedure then follows the same dissection as for open surgery with Kocherization of the duodenum on the right prior to control of the adrenal vein, whereas on the left, the greater omentum is divided, and the adrenal gland and vein accessed through the lesser sac (15).

In this series, three procedures were performed successfully with operative times of 55 to 90 minutes. Hand-assisted laparoscopic adrenalectomy may offer an alternative to cases where an open procedure is being considered, such as with large or potentially malignant lesions, or where conversion from a laparoscopic adrenalectomy may be required (15).

Needlescopic Laparoscopic Adrenalectomy

Gill et al. described the initial series of needlescopic transperitoneal laparoscopic adrenalectomy (16). In this series, 15 patients underwent needlescopic laparoscopic adrenalectomy using three subcostal ports (two 2mm ports and one 5mm port) and one 10 to 12 mm umbilical port through which the specimen was ultimately removed. The needlescopic group had less blood loss, a shorter operative time, shorter hospital stay, and more rapid convalescence compared to standard laparoscopy. Needlescopic instruments are however more flimsy and less reliable than standard laparoscopic instruments, and therefore, considerable laparoscopic experience is required for their use (17). Chueh et al. described transperitoneal laparoscopic adrenalectomy using needlescopic instruments and a clipless technique in which the adrenal vein was controlled with bipolar diathermy using mini bipolar forceps to diathermy the vein over a distance of 6 mm in two to three sequential applications (17). The authors found that convalescence and pain scores were improved but operative time was longer compared to standard laparoscopy (17). Concern has been expressed regarding the sole use of diathermy to control the adrenal vein, particularly on the right side (17).

Thoracoscopic transdiaphragmatic adrenalectomy is a procedure that may be of particular use in patients who have had extensive surgery both in the peritoneal cavity and the retroperitoneum.

Thoracoscopic Transdiaphragmatic Adrenalectomy

Thoracoscopic transdiaphragmatic adrenalectomy is a procedure that may be of particular use in patients who have had extensive surgery both in the peritoneal cavity and the retroperitoneum.

Initially described by Pompeo et al. in a porcine model (89), this approach was further developed and the initial clinical series described by Gill et al. (12). In this series, the procedure was performed initially on four cadavers to develop the technique and then on three patients, all of who had significant abdominal scarring and prior ipsilateral renal surgery. After the placement of a double-lumen endotracheal tube, the patient is placed prone and a four-port transthoracic approach without pneumoinflation is used. Real-time laparoscopic ultrasound is used to identify the adrenal gland transdiaphragmatically. The diaphragm is incised, and the adrenal gland dissected. There were no intraoperative or postoperative complications, operative times ranged from 2.5 to 6.5 hours, and blood loss ranged from 50 to 500 mL (12).

Robotic Surgery

Because technology has improved, robotic applications to laparoscopic adrenalectomy have been reported. Use of the automated endoscopic system for optimal patient

^fSmith and Nephew, Sydney, Australia.

An experienced human assistant familiar with the *modus operandi* of the primary surgeon will provide a dynamic view of the object of interest in a much more expedient fashion than a voice-activated robot, particularly during complex maneuvers such as intracorporeal suturing.

positioning voice-controlled robot has been well described, and is reported to provide a steadier, more reliable picture with fewer camera smears when compared to human assistance, while allowing the assistant more freedom to assist the primary surgeon actively (10,90).

An experienced human assistant familiar with the *modus operandi* of the primary surgeon is able to provide a dynamic view of the object of interest in a much more expedient fashion than a voice-activated robot, particularly during complex maneuvers such as intracorporeal suturing.

More recently, the *daVinci* and Zeus master–slave robot systems have been developed and used in clinical practice (18–20). Proposed advantages include absence of tremor, up to seven degrees of freedom, a relaxed working position at the console, and a minimal learning curve (18). Overall, the major advantage with these systems is that they enable surgeons with little prior laparoscopic experience to perform minimally invasive procedures. The major disadvantage at this stage, however, is cost. Sung and Gill compared the *daVinci* and the Zeus systems for laparoscopic adrenalectomy and laparoscopic nephrectomy and felt that the intraoperative technical movements were more intuitive with the *daVinci* system but that the procedures were feasible with both units (91).

CONCLUSION

Since its inception in 1992, laparoscopic adrenalectomy has evolved as the procedure of choice for the vast majority of surgical pathologies of the adrenal gland and has clear benefits when compared to open surgery. Procedural advancements have resulted in the development of new approaches to the adrenal, from the initial anterior transperitoneal approach, to the lateral transperitoneal approach, posterior and lateral retroperitoneal approaches, and more recently the thoracoscopic approach. Comparative studies to date have not demonstrated significant differences in outcome measures between transperitoneal and retroperitoneal routes. We prefer the lateral transperitoneal approach because of its particular advantage in allowing early control of the adrenal vein.

SUMMARY

- Laparoscopic adrenalectomy has become the standard surgical approach for most surgically correctable disorders of the adrenal gland.
- Aldosteronomas may be considered as lesions of choice for surgeons early in the operative learning curve.
- Unilateral laparoscopic adrenalectomy is the treatment of choice for patients with Cushing's syndrome due to unilateral adrenal adenomas.
- After initial controversy, laparoscopic adrenalectomy for pheochromocytoma is now well accepted as a standard indication for unilateral or bilateral disease.
- The quintessential objective during laparoscopic adrenalectomy is early control of the adrenal vein and in this regard, pheochromocytomas are best suited to the transperitoneal approach.
- Masses demonstrating local organ invasion or venous tumor thrombus are not suitable for laparoscopic resection because the ability to achieve an adequate en-bloc resection is extremely difficult in this setting.
- Early access to the adrenal vein prior to manipulation of the adrenal gland or periadrenal tissue is the main advantage of the lateral transperitoneal route.
- The posterior retroperitoneal approach utilizes the prone jack-knife position. In addition to the advantages and disadvantages of the retroperitoneal approach, it also allows access to both glands for bilateral procedures.
- Tumor size, obesity, and the learning curve are the most important factors influencing operative outcome.
- The aim of a right-sided laparoscopic adrenalectomy is to remove the adrenal gland with early ligation of the adrenal vein. It is essentially a dissection of the inferior vena cava.
- The aim of a left-sided laparoscopic adrenalectomy is to remove the adrenal gland and periadrenal fat with early ligation of the adrenal vein. It is essentially a dissection of the left renal vein.
- At all times, patient safety is paramount, and it is essential that the practitioner has a low threshold for open conversion to control significant hemorrhage.

REFERENCES

1. Snow LL. Endoscopic general surgery: an update. *Laser Highlights* 1991; 2(1):1–3.
2. Gagner M, Lacroix A, Bolte E. Laparoscopic adrenalectomy in Cushing's syndrome and pheochromocytoma. *N Engl J Med* 1992; 327(14):1003–1006.
3. Go H, Takeda M, Takahashi H, et al. Laparoscopic adrenalectomy for primary aldosteronism: a new operative method. *J Laparoendosc Surg* 1993; 3(5):455–459.
4. Suzuki K, Kageyama S, Ueda D, et al. Laparoscopic adrenalectomy: clinical experience with 12 cases. *J Urol* 1993; 150(4):1099–1102.
5. Higashihara E, Nutahara K, Kato M. Laparoscopic adrenalectomy: alternative or new standard? *Curr Urol Rep* 2002; 3:172–178.
6. Sung GT, Gill IS. Laparoscopic adrenalectomy. *Semin Lap Surg* 2000; 7(3):211–222.
7. Jossart GH, Burpee SE, Gagner M. Surgery of the adrenal glands. *Endocrinol Metab Clin North Am* 2000; 29(1):57–68.
8. Gill IS. The case for laparoscopic adrenalectomy. *J Urol* 2001; 166:429–436.
9. Lezoche E, Guerrieri M, Paganini AM, et al. Laparoscopic adrenalectomy by the anterior transperitoneal approach: results of 108 operations in unselected cases. *Surg Endosc* 2000; 14:920–925.
10. Baba S, Ito K, Yanaihara H, et al. Retroperitoneoscopic adrenalectomy by a lumbodorsal approach: clinical experience with solo surgery. *World J Urol* 1999; 17:54–58.
11. Gaur DD. Laparoscopic operative retroperitoneoscopy: use of a new device. *J Urol* 1992; 148(4):1137–1139.
12. Gill IS, Meraney AM, Thomas JC, et al. Thoracoscopic transdiaphragmatic adrenalectomy: the initial experience. *J Urol* 2001; 165:1875–1881.
13. Basso N, De Leo A, Fantini A, et al. Laparoscopic direct supragastric left adrenalectomy. *Am J Surg* 1999; 178:308–310.
14. Vereczkei A, Horvath OP, Papp A, Nemes J. Suprasplenic, transperitoneal approach for laparoscopic adrenalectomy on the left side. *Langenbeck's Arch Surg* 2000; 385:467–469.
15. Bennett IC, Ray M. Hand-assisted laparoscopic adrenalectomy: an alternative minimal invasive surgical technique for the adrenal gland. *ANZJ Surg* 2002; 72:801–805.
16. Gill IS, Soble JJ, Sung GT, et al. Needlescopic adrenalectomy—the initial series: comparison with conventional laparoscopic adrenalectomy. *Urology* 1998; 52(2):180–186.
17. Chueh S, Chen J, Chen S, et al. Clipless laparoscopic adrenalectomy with needlescopic instruments. *J Urol* 2002; 167:39–43. Comment 42–43.
18. Bentas W, Wolfram M, Bräutigam R, Binder J. Laparoscopic transperitoneal adrenalectomy using a remote-controlled robotic surgical system. *J Endourol* 2002; 16(6):373–376.
19. Undre S, Munz Y, Moorthy K, et al. Robot-assisted laparoscopic adrenalectomy: preliminary UK results. *BJU Int* 2004; 93:357–359.
20. Desai MM, Gill IS, Kaouk JH, et al. Robotic-assisted laparoscopic adrenalectomy. *Urology* 2002; 60(6):1104–1107.
21. Baba S, Iwamura M. Retroperitoneal laparoscopic adrenalectomy. *Biomed Pharmacother* 2002; 56:113s–119s.
22. Kebebew E, Siperstein AE, Duh Q. Laparoscopic adrenalectomy: the optimal surgical approach. *J Laparoendosc Adv Surg Tech Part A* 2001; 11(6):409–413.
23. Suzuki K. Laparoscopic adrenalectomy: retroperitoneal approach. *Urol Clin North Am* 2001; 28(1):85–95.
24. Lal G, Duh Q. Laparoscopic adrenalectomy—indications and technique. *Surg Oncol* 2003; 12:105–123.
25. Gmyrek GA, New MI, Sosa RE, Poppas DP. Bilateral laparoscopic adrenalectomy as a treatment for classic congenital adrenal hyperplasia attributable to 21-hydroxylase deficiency. *Pediatrics* 2002; 109(2):E28.
26. Reincke M. Subclinical Cushing's syndrome. *Endocrinol Metab Clin North Am* 2000; 29(1):43–56.
27. Kloos RT, Gross MD, Francis IR, et al. Incidentally discovered adrenal mass. *Endocr Rev* 1995; 16(4):460–484.
28. Matsuda T, Murota T, Oguchi N, et al. Laparoscopic adrenalectomy for pheochromocytoma: a literature review. *Biomed Pharmacother* 2002; 56:132s–138s.
29. Guazzoni G, Cestari A, Montorsi F, et al. Eight-year experience with transperitoneal laparoscopic adrenal surgery. *J Urol* 2001; 166:820–824.
30. Janetschek G. Surgical options in adrenalectomy: laparoscopic versus open surgery. *Curr Opin Urol* 1999; 9:213–218.
31. Janetschek G, Neumann HPH. Laparoscopic surgery for pheochromocytoma. *Urol Clin North Am* 2001; 28(1):97–105.
32. Beldegrun A, Hussain S, Seltzer SE, et al. The incidentally discovered adrenal mass: a therapeutic dilemma—BWH experience 1976–1983. *Surg Gynecol Obstet* 1986; 163:203.
33. Cerfolio RJ, Vaughan ED Jr, Brennan TG, Hirvela ER. Accuracy of computed tomography in predicting adrenal tumor size. *Surg Gynecol Obstet* 1993; 176:307.
34. Kumar U, Albala DM. Laparoscopic approach to adrenal carcinoma. *J Endourol* 2001; 15(4):339–342. Comment 342–343.
35. Hamilton BD. Transperitoneal laparoscopic adrenalectomy. *Urol Clin North Am* 2001; 28(1):61–70.
36. Godellas CV, Prinz RA. Surgical approach to adrenal neoplasms: laparoscopic versus open adrenalectomy. *Surg Oncol Clin North Am* 1998; 7(4):807–817.
37. Barresi RV, Prinz RA. Laparoscopic adrenalectomy. *Arch Surg* 1999; 134(2):212–217.
38. Gagner M, Pomp A, Heniford BT, et al. Laparoscopic adrenalectomy: lessons learned from 100 consecutive procedures. *Ann Surg* 1997; 226:238–247.
39. Henry JF, Defechereux T, Gramatica L, Raffaelli M. Should laparoscopic approach be proposed for large and/or potentially malignant adrenal tumors? *Langenbeck's Arch Surg* 1999; 384:366–369.
40. Heniford BT, Arca MJ, Walsh RM, Gill IS. Laparoscopic adrenalectomy for cancer. *Semin Surg Oncol* 1999; 16:293–306.

41. Foxius A, Ramboux A, Lefebvre Y, et al. Hazards of laparoscopic adrenalectomy for Conn's adenoma: when enthusiasm turns to tragedy. *Surg Endosc* 1999; 13:715–717.
42. Suzuki K, Ushiyama T, Mugiya S, et al. Hazards of laparoscopic adrenalectomy in patients with adrenal malignancy. *J Urol* 1997; 158:2227.
43. Iacconi P, Bendinelli C, Miccoli P, Bernini GP. Re: Re: a case of Cushing's syndrome due to adrenocortical carcinoma with recurrence 19 months after laparoscopic adrenalectomy. *J Urol* 1999; 161(5):1580–1581.
44. Hamoir E, Meurisse M, Defechereux T. Is laparoscopic resection of a malignant corticoadrenaloma feasible? Case report of early, diffuse and massive peritoneal recurrence after attempted laparoscopic resection. *Ann Chir* 1998; 52(4):364–368.
45. Del Pizzo JJ. Transabdominal laparoscopic adrenalectomy. *Curr Urol Rep* 2003; 4:81–86.
46. Schichman SJ, Herndon CDA, Sosa RE, et al. Lateral transperitoneal laparoscopic adrenalectomy. *World J Urol* 1999; 17:48–53.
47. Porcaro AB, Novella G, Ficarra V, et al. Incidentally discovered adrenal myelolipoma. Report on three operated patients and update of the literature. *Arch Ital Urol Androl* 2002; 74(3):146–151.
48. Shalhav AL, Landman J, Afane J, et al. Laparoscopic adrenalectomy for primary hyperaldosteronism during pregnancy. *J Laparoendosc Adv Surg Tech* 2000; 10(3):169–171.
49. Fazeli-Matin S, Gill IS, Hsu TH, et al. Laparoscopic renal and adrenal surgery in obese patients: comparison to open surgery. *J Urol* 1999; 162:665–669.
50. Winfield HN, Hamilton BD, Bravo EL. Technique of laparoscopic adrenalectomy. *Urol Clin North Am* 1997; 24(2):459–465.
51. Guazzoni G, Cestari A, Montorsi F, et al. Current role of laparoscopic adrenalectomy. *Eur Urol* 2001; 40:8–16.
52. Hansen P, Bax T, Swanstrom L. Laparoscopic adrenalectomy: history, indications, and current techniques for a minimally invasive approach to adrenal pathology. *Endoscopy* 1997; 29:309–314.
53. Suzuki K, Kageyama S, Hirano Y, et al. Comparison of 3 surgical approaches to laparoscopic adrenalectomy: a non randomized, background matched analysis. *J Urol* 2001; 166:437–443.
54. Siperstein AE, Berber E, Engle KL, et al. Laparoscopic posterior adrenalectomy: technical considerations. *Arch Surg* 2000; 135:967–971.
55. Baba S. Laparoscopic adrenalectomy: posterior approach. *Biomed Pharmacother* 2000; 54 (suppl 1):161–163.
56. Miyake O, Yoshimura K, Yoshioka T, et al. Laparoscopic adrenalectomy: comparison of the transperitoneal and retroperitoneal approach. *Eur Urol* 1998; 33:303–307.
57. Takeda M, Go H, Watanabe R, et al. Retroperitoneal laparoscopic adrenalectomy for functioning adrenal tumors: comparison with conventional transperitoneal laparoscopic adrenalectomy. *J Urol* 1997; 157:19–23.
58. Matsuda T, Murota T, Kawakita M. Transperitoneal anterior laparoscopic adrenalectomy: the easiest technique. *Biomed Pharmacother* 2000; 54 (suppl 1):157–160.
59. Nakagawa K, Murai M. Laparoscopic adrenalectomy: current status with a review of Japanese literature. *Biomed Pharmacother* 2002; 56:107s–112s.
60. Otto M, Szostek G, Nazarewski S, et al. Laparoscopic operative technique for adrenal tumors. *JSLs* 2000; 4:125–129.
61. Lezoche E, Guerrieri M, Feliciotti F, et al. Anterior, lateral and posterior retroperitoneal approaches in endoscopic adrenalectomy. *Surg Endosc* 2002; 16:96–99.
62. Bonjer HJ, Lange JF, Kazemier G, et al. Comparison of three techniques for adrenalectomy. *BJs* 1997; 84:679–682.
63. Sung GT, Hsu THS, Gill IS. Retroperitoneoscopic adrenalectomy: lateral approach. *J Endourol* 2001; 15:505–511. Comments 511–512.
64. Heniford BT, Iannitti DA, Hale J, Gagner M. The role of intraoperative ultrasonography during laparoscopic adrenalectomy. *Surgery* 1997; 122(6):1068–1074.
65. Brunt LM, Bennett HF, Teefey SA, et al. Laparoscopic ultrasound imaging of adrenal tumors during laparoscopic adrenalectomy. *Am J Surg* 1999; 178:490–495.
66. Lucas SW, Spitz JD, Arregui ME. The use of intraoperative ultrasound in laparoscopic adrenal surgery: the Saint Vincent experience. *Surg Endosc* 1999; 13:1093–1098.
67. Giger U, Vonlanthen R, Michel JM, Krähenbühl L. Trans- and retroperitoneal endoscopic adrenalectomy: experience in 26 consecutive adrenalectomies. *Dig Surg* 2004; 21:28–32.
68. Naya Y, Nagata M, Ichikawa T, et al. Laparoscopic adrenalectomy: comparison of transperitoneal and retroperitoneal approaches. *BJU Int* 2002; 90:199–204.
69. Liao C, Chen J, Chueh S, et al. Effectiveness of transperitoneal and trans-retroperitoneal laparoscopic adrenalectomy versus open adrenalectomy. *J Formos Med Assoc* 2001; 100(2):186–191.
70. Takeda, M. Laparoscopic adrenalectomy: transperitoneal vs retroperitoneal approaches. *Biomed Pharmacother* 2000; 54 (suppl 1):207–210.
71. Yoneda K, Shiba E, Watanabe T, et al. Laparoscopic adrenalectomy: lateral transabdominal vs posterior retroperitoneal approach. *Biomed Pharmacother* 2000; 54 (suppl 1):215–219.
72. Fernandez-Cruz L, Saenz A, Taura P, et al. Retroperitoneal approach in laparoscopic adrenalectomy: Is it advantageous? *Surg Endosc* 1999; 13:86–90.
73. Sung GT, Gill IS, Hobart M, et al. Laparoscopic adrenalectomy: prospective randomized comparison of transperitoneal vs retroperitoneal approaches. *J Urol* 1999; 161(4 suppl):Abst 69.
74. Chee C, Ravinthiran T, Cheng C. Laparoscopic adrenalectomy: experience with transabdominal and retroperitoneal approaches. *Urology* 1998; 51(1):29–32.
75. Baba S, Miyajima A, Uchida A, et al. A posterior lumbar approach for retroperitoneoscopic adrenalectomy: assessment of surgical efficacy. *Urology* 1997; 50(1):19–24.
76. Duh Q, Siperstein AE, Clark OH, et al. Laparoscopic adrenalectomy: comparison of the lateral and posterior approaches. *Arch Surg* 1996; 131:870–875. Discussion 875–876.
77. Pautler SE, McWilliams GW, Harrington FS, Walther MM. An articulating retractor holder to facilitate laparoscopic adrenalectomy and nephrectomy. *J Urol* 2001; 166:198–199.

78. Valeri A, Borrelli A, Presenti L, et al. The influence of new technologies on laparoscopic adrenalectomy: our personal experience with 91 patients. *Surg Endosc* 2002; 16:1274–1279.
79. Toniato A, Piotto A, Pagetta C, et al. Technique and results of laparoscopic adrenalectomy. *Langenbeck's Arch Surg* 2001; 386:200–203.
80. Gagner M. Laparoscopic adrenalectomy. *Surg Clin North Am* 1996; 76(3):523–537.
81. Schell SR, Talamini MA, Udelsman R. Laparoscopic adrenalectomy. *Adv Surg* 1997; 31:333–350.
82. Zografos GC, Karaliotas K, Loisos A, et al. Laparoscopic adrenalectomy for benign adrenal tumours: a modified approach. *J Surg Oncol* 2000; 75:275. Comment 276.
83. Kercher KW, Heniford BT, Marroum M, Greene FL. Laparoscopic intraoperative ultrasonic localisation and resection of an extra-adrenal pheochromocytoma. *J Laparoendosc Adv Surg Tech* 1999; 9(6):511–515.
84. Suzuki K, Fujita K, Ushiyama T, et al. Efficacy of an ultrasonic surgical system for laparoscopic adrenalectomy. *J Urol* 1995; 154:484–486.
85. Takeda M, Go H, Imai T, Komeyama T. Experience with 17 cases of laparoscopic adrenalectomy: use of ultrasonic aspirator and argon beam coagulator. *J Urol* 1994; 152:902–905.
86. Gentili S, Ferrero A, Velardocchia M, Garavoglia M. Laparoscopic adrenalectomy: advantages of an atraumatic suction grasper. *Surg Laparosc Endosc* 1998; 8(5):335–337.
87. Obermeyer RJ, Knauer EM, Millie MP, et al. Intravenous methylene blue as an aid to intraoperative localisation and removal of the adrenal glands during laparoscopic adrenalectomy. *Am J Surg* 2003; 186:531–534.
88. Filipponi S, Guerrieri M, Arnaldi G, et al. Laparoscopic adrenalectomy: a report on 50 operations. *Eur J Endocrinol* 1998; 138:548–553.
89. Pompeo E, Coosemans W, De Leyn P, et al. Thoracoscopic transdiaphragmatic left adrenalectomy: an experimental study. *Surg Endosc* 1997; 11(4):390–392.
90. Hubens G, Ysebaert D, Vaneerdeweg W, et al. Laparoscopic adrenalectomy with the aid of the AESOP 2000 robot. *Acta Chir Belg* 1998; 98:125–129.
91. Sung GT, Gill IS. Robotic laparoscopic surgery: a comparison of the DaVinci and Zeus systems. *Urology* 2001; 58(6):893–898.

Günter Janetschek

Department of Urology, KH der Elisabethinen, Teaching Hospital of University of Innsbruck, Linz, Austria

- | | |
|---|---|
| <ul style="list-style-type: none"> ■ INTRODUCTION ■ RELEVANT ANATOMIC DETAILS ■ INDICATIONS AND CONTRAINDICATIONS ■ THERAPEUTIC CONCEPTS <ul style="list-style-type: none"> Aldosteronoma Cushing's Syndrome Pheochromocytoma Incidentaloma ■ PREOPERATIVE INVESTIGATION ■ PREOPERATIVE OPTIMIZATION ■ PHEOCHROMOCYTOMA: POTENTIAL SURGICAL RISKS | <ul style="list-style-type: none"> ■ ANESTHETIC MANAGEMENT ■ SURGICAL TECHNIQUE <ul style="list-style-type: none"> Transperitoneal Approach Retroperitoneal Approach ■ RESULTS ■ LAPAROSCOPIC PARTIAL ADRENALECTOMY FOR RECURRENT PHEOCHROMOCYTOMAS ■ SUMMARY ■ REFERENCES |
|---|---|

INTRODUCTION

The applications of laparoscopy in urology have expanded immensely in the last decade. Procedures that initially appeared to be immensely challenging are increasingly becoming routine. Undoubtedly, the era of minimally invasive surgery is now upon us. Laparoscopy has become the standard of care for benign surgical adrenal disease, due to its minimal invasiveness, equivalent operative time, shorter hospital stay, and faster convalescence. This is borne out of a number of retrospective and case control studies even though prospective, randomized trials are lacking (1–5). The surgical community has evolved from performing radical extirpative surgery to organ- and function-preserving surgery, without compromising the primary therapeutic goal. Such advances have occurred in many abdominal and thoracic solid organ systems, and recently in adrenal surgery. The concept of laparoscopic partial adrenalectomy or adrenal-sparing surgery includes the preservation of the functioning adrenal cortex to obviate the need for hormonal replacement therapy and its attendant, undesired consequences. The initial laparoscopic partial adrenalectomies were performed by Janetschek et al. for aldosterone-producing adenoma (6) and pheochromocytoma (7) and by Walz et al. for Cushing's adenoma (8). However, at the onset, it is clearly stated that partial adrenalectomy has limited application in highly selected patients, and, at this writing, is not an accepted treatment for the majority of surgical adrenal diseases.

RELEVANT ANATOMIC DETAILS

The arterial supply of adrenal gland is derived from three sources, namely the inferior phrenic artery, the aorta, and the renal artery. Adrenal vessels subdivide into minute branches prior to entering the adrenal cortex, where they further branch into capillaries ending in venous plexii within the adrenal medulla (9). On the right side, a single right adrenal vein emerges from the right adrenal apex and drains into the inferior vena cava. On the left side, a single left adrenal vein emerges from the middle portion of the gland and drains into the left renal vein. The left inferior phrenic vein, usually not easy to identify and typically communicating, can be injured during the dissection along the medial edge of the left gland due to its medial course. Hence, delicate dissection is essential to preserve the periadrenal vascular plexus, and the fibro-areolar tissue attachment of the remaining portion of adrenal gland.

Its rich vascular supply makes the adrenal a highly vascularized organ. Its segmental arterial supply enables partial adrenalectomy. If the main adrenal vein needs to be sacrificed during the surgical procedure, the adrenal venous drainage gets diverted

The rich vascular supply of the adrenal makes it a highly vascularized organ. Its segmental arterial supply enables partial adrenalectomy. If the main adrenal vein needs to be sacrificed during the surgical procedure, the adrenal venous drainage gets diverted through the venae comitantes, ensuring viability of the remnant gland.

through the venae comitantes, which accompany the artery, ensuring viability of the remnant gland.

INDICATIONS AND CONTRAINDICATIONS

Indications of Laparoscopic Partial Adrenalectomy

- Pheochromocytoma—hereditary von Hippel-Lindau, multiple endocrine neoplasia
- Adrenal adenoma
- Aldosterone-producing adenoma—bilateral or unilateral
- Cushing's adenoma

Contraindications of Laparoscopic Partial Adrenalectomy

- Aldosteroma—concentric lesions, multiple ipsilateral tumors
- Adrenal carcinoma (or clinical suspicion, i.e., incidentaloma)
- Malignant pheochromocytoma
- Uncorrected coagulopathy

Technically, a solitary, peripheral adrenal lesion located at some distance from the main adrenal vein is preferable for partial adrenalectomy. laparoscopic partial adrenalectomy must be avoided in multiple aldosterone-producing adenomas, although laparoscopic partial adrenalectomy in the presence of two pheochromocytomas in the same adrenal gland has been reported (10).

The main adrenal vein may be sacrificed if needed, although every effort to preserve it should be made.

Main adrenal vein ligation does not compromise the postoperative function. However, adrenal functional recovery could be delayed in patients with pheochromocytoma, and temporary adrenal replacement may be needed. Previous abdominal surgery and morbid obesity are not absolute contraindications but may necessitate consideration of the retroperitoneal laparoscopic approach.

The main adrenal vein may be sacrificed if needed, although every effort to preserve it should be made.

THERAPEUTIC CONCEPTS

Complete removal of the tumor is the primary goal of adrenal surgery. In the past, this almost routinely meant complete adrenalectomy. In case of bilateral tumors, bilateral adrenalectomy resulted in adrenal insufficiency necessitating for life-long hormonal replacement therapy. The hormonal replacement often consists of fixed dosage schedule, without respect for the physiological diurnal circadian rhythm. This may lead to overtreatment with increased incidence of osteoporosis, hypertension, diabetes, and other adverse effects of steroid replacement therapy. These patients are also at risk for undertreatment during periods of stress. Hypoandrogenism in females and Addisonian crisis have been reported in 25% to 33% of cases (11,12). The quality of life is also significantly affected because 30% of patients experience significant fatigue and 48% consider themselves disabled (13). Hence, the concept of organ- and function-preserving surgery—partial adrenalectomy—was developed to address these concerns.

Aldosteronoma

The most common cause of hyperaldosteronism is an aldosterone-producing adenoma. Aldosteromas are rarely bilateral. Other causes of hyperaldosteronism include hyperplasia and, very rarely, carcinoma. Total adrenalectomy is the standard of care for unilateral adenomas, because the function is preserved by contralateral adrenal hypertrophy. Partial adrenalectomy was initially proposed for bilateral aldosteroma. Nakada et al. (14) compared the functional outcome of open unilateral partial versus total adrenalectomy in 48 patients. Despite adequate hormone levels and the lack of replacement therapy, patients who underwent unilateral total adrenalectomy demonstrated suboptimal response to stress. Conversely, patients undergoing tumor enucleation (partial adrenalectomy) had better functional reserve. Further, there were no tumor recurrences in either group over a mean follow-up of five years. As a result, indications for adrenal-sparing surgery have been expanded by select groups to include unilateral aldosteromas. Estimated incidence of malignancy in adrenal lesions smaller

than 6 cm in diameter is low—1 in 10,000 (15–17). However, micro- or macronodularity in an adjacent area of the gland is present in 7% to 38% of aldosteromas, a circumstance that is a clear contraindication for partial adrenalectomy (18).

Cushing's Syndrome

The major cause of Cushing's syndrome is adrenal hyperplasia. A small percentage of patients with Cushing's syndrome have a radiologically well-defined adenoma amenable to partial adrenalectomy. Cushing's adenomas are usually larger in size (several centimeters) than aldosteromas, and the adjacent adrenal parenchyma and the contralateral adrenal gland are often atrophic. laparoscopic partial adrenalectomy is technically more challenging in such cases. Because of this, the remnant adrenal recovers slowly, with the need for temporary steroid substitution.

Pheochromocytoma

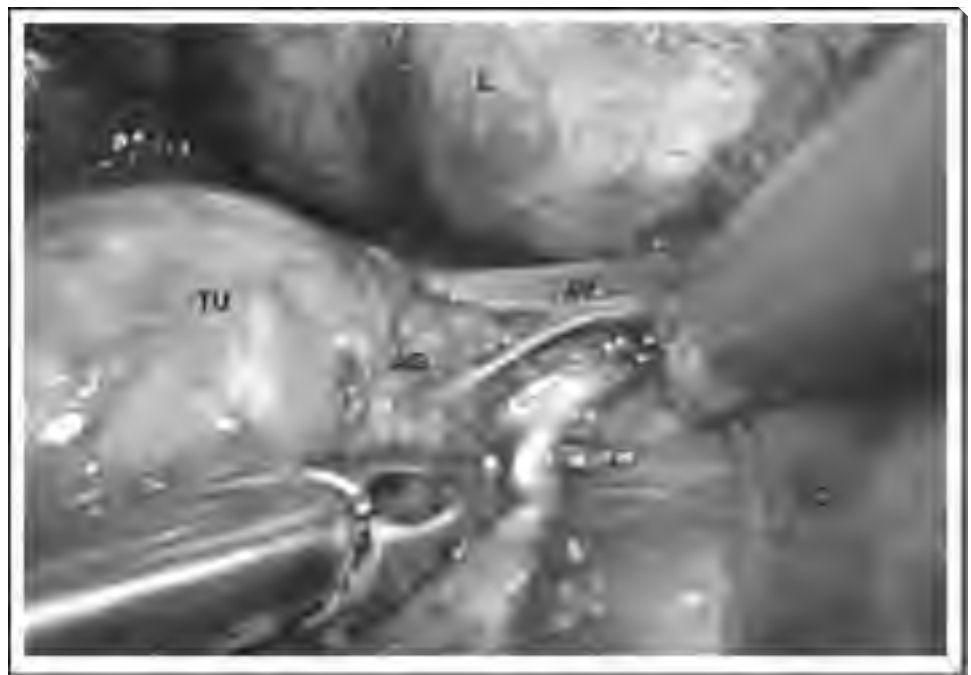The least controversial indication for partial adrenalectomy is hereditary pheochromocytoma.

Pheochromocytoma is inherited in an autosomal dominant pattern and can be occasionally associated with different syndromes, including von Hippel-Lindau disease, multiple endocrine neoplasia type 2 (multiple endocrine neoplasia 2A/B), and neurofibromatosis type 1. In this specific subset of patients, an increased incidence of multifocal tumors, risk of delayed relapse over the long term, and detection of asymptomatic tumors on screening patients with known syndrome or relatives of a proband patient are not infrequent. Bilateral total adrenalectomy followed by hormonal replacement has been the standard treatment so far. Patients with hereditary unilateral or bilateral pheochromocytomas are candidates for partial adrenalectomy because of a definite risk of contralateral metachronous tumors formation. In this specific setting, open partial adrenalectomy has achieved encouraging results (19–23). The major drawback of partial adrenalectomy is the risk of recurrent tumors in the adrenal remnant due to medullary cells inevitably remaining within the spared cortex. Such tumor recurrence is, in fact, due to genetic predisposition rather than residual tumor from incomplete resection (Fig. 1). Hence, it is essential to weigh the benefits of adrenal function preservation against the risk tumor reoccurrence. The risk of reoccurrence after open partial resection for pheochromocytoma in patients with von Hippel-Lindau has been assessed in two large series. Walther et al. reported recurrent tumor in 1 of 13 patients after a median follow-up of 18 months (20). Neumann et al. noted one ipsilateral recurrence out of 29 patients undergoing partial adrenalectomy at a mean follow-up of six years (19). Patients with multiple endocrine neoplasia 2 have a 0% to 33% risk of developing

The least controversial indication for partial adrenalectomy is hereditary pheochromocytoma.

FIGURE 1 ■ Recurrent right pheochromocytoma after dissection. Note the clear distinction between tumor-containing adrenal gland and normal adrenal gland, and the adrenal vein could be spared after ligating the small venous tributary draining the tumor.

Abbreviations: L, liver; TU, tumor mass; AG, normal adrenal gland; AV, adrenal vein; VC, vena cava.



recurrence over a median follow-up of 54 to 88 months (22,23). Considering the available evidence, partial adrenalectomy appears to be well justified, given the rarity of malignant tumors in inherited pheochromocytoma (10). Subtotal adrenalectomy has been advocated (23–25), but this does not necessarily remove all medullary tissue and hence the risk of recurrence remains with the additional disadvantage of removing an excessive amount of cortical tissue, thus compromising the adrenal function.

Incidentaloma

Partial adrenalectomy for nonfunctioning incidentaloma has been performed by some authors (26). The main indication for surgical treatment of incidentaloma is the suspicion of malignancy. This is assessed based on tumor size greater than 5 cm, functional status (nonfunctioning), and high signal intensity on T2-weighted magnetic resonance imaging images. Watchful waiting is well accepted for lesions smaller than 3 cm. Lesions between 3 and 5 cm represent the main area of controversy. However, despite the majority of these lesions ultimately proving to be benign on final pathology, malignancy can occur occasionally (27). Hence, unilateral total adrenalectomy still remains the gold standard treatment for patients with a normal contralateral adrenal gland, with no predisposition for multiple tumors, and with suspected malignant lesions.

PREOPERATIVE INVESTIGATION

Preoperative investigations include radiological imaging to study the anatomical details and endocrinological investigation to determine the functional status. Elevated plasma or urinary aldosterone level indexed against urinary sodium excretion, and measured after sodium loading in combination with previously demonstrated low peripheral renin activity during sodium depletion, is the biochemical hallmark of hyperaldosteronism. Pre- and post-contrast computed tomography scan is the most accurate imaging modality. Conversely, small adrenal lesions are often not well visualized with adrenal magnetic resonance imaging (28). Twenty-four hour urine cortisol and plasma cortisol levels and adrenocorticotrophic hormone after dexamethasone suppression test are the cornerstone of biochemical diagnosis of cortisol-hypersecreting Cushing's adenoma. A 24-hour urine analysis for norepinephrine, epinephrine, and vanillylmandelic acid is mandatory whereas serum norepinephrine and epinephrine levels are less sensitive in diagnosing pheochromocytoma (29).

Combination of computed tomography, magnetic resonance imaging, and ^{131}I metaiodo-benzylguanidine scintigraphy allows accurate localization of virtually all pheochromocytomas (30). The authors use surface- and volume-rendered three-dimensional spiral computed tomography datasets for preoperative planning of laparoscopic partial adrenalectomy. Interactive visualization of volume-rendered computed tomography images are helpful for preoperative planning and successful performance of the procedure, whereas color-coded surface-rendered computed tomography datasets are more accurate and convenient for intraoperative reference.

PREOPERATIVE OPTIMIZATION

Patients with hyperaldosteronism should have adequate control of blood pressure and correction of hypokalemia and other electrolyte abnormalities. Alpha-blockers, namely phenoxybenzamine, and beta-blockers are administered in patients with pheochromocytomas to control reflex tachycardia when needed. The authors initiate administering these drugs three to four weeks prior to surgery and assess their efficiency by monitoring the improvement of symptoms, stabilization of blood pressure, and the presence of mild orthostatic hypotension. Following this concept, the mortality of patients with pheochromocytoma has declined to 1% (31). A different approach to manage hypertension using calcium channel blockers started as late as 24 hours prior to surgery has shown good results (32).

PHEOCHROMOCYTOMA: POTENTIAL SURGICAL RISKS

Long-standing hypertension can produce end-organ damage resulting in heart failure, catecholamine-induced cardiomyopathy, stroke, and retinal damage. Such patients with pheochromocytoma constitute a high-risk group. Intraoperative manipulation of the tumor may induce excess catecholamine release resulting in life-threatening hypertensive crisis. Although it has been speculated that pneumoperitoneum may induce a hypertensive crisis owing to hypercapnia or positive pressure, available evidence

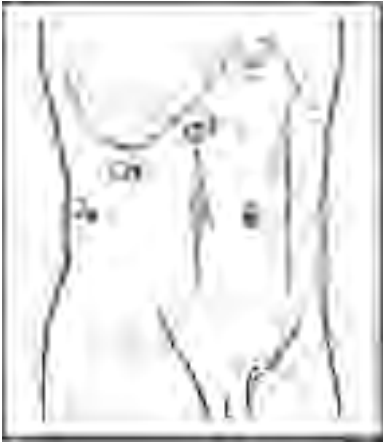


FIGURE 2 ■ Typical trocar positions for right-side transperitoneal approach.

suggests to the contrary (33,34). In the author's experience, severe hypertension was triggered only by direct manipulation of the adrenal gland and not by pneumoperitoneum. Hence, laparoscopic tissue dissection is kept to a minimum, and a direct transperitoneal approach to the adrenal vein is preferred (Fig. 2) (7). Interestingly, when performing partial adrenalectomy without clamping or dividing the adrenal vein, no major problem was encountered in authors' series (7) owing to effective alpha blockade.

Because patients are often volume depleted, there is a potential danger of hypotension after removal of the tumor. This risk is best avoided by adequate preemptive fluid replacement with crystalloids preoperatively.

ANESTHETIC MANAGEMENT

Patients with pheochromocytoma need expert intraoperative care by experienced anesthesiologists. Invasive, continuous monitoring of arterial blood pressure and close monitoring of partial pressure of arterial carbon dioxide are essential. Hypertensive crises are treated with sodium nitroprusside, nitroglycerin, labetalol, esmolol, urapidil, or magnesium sulphate depending upon the specific patient condition.

SURGICAL TECHNIQUE

Laparoscopic approaches to the adrenal gland can be transperitoneal, retroperitoneal lateral, or retroperitoneal posterior. Although each of these approaches have their own advantages and disadvantages, the choice of approach depends on surgeon's experience and preference. The transperitoneal approach is the most popular, because of easier orientation. However, delayed bowel function and adhesion formation can possibly occur. The retroperitoneal approach is gaining popularity because it allows direct access to the adrenal gland without interfering with intra-abdominal organs. However, with this approach, the working space is limited and anatomical landmarks may be difficult to recognize especially for the beginner laparoscopist. The only randomized, prospective study on this topic documented equivalent patient outcomes between transperitoneal and retroperitoneal adrenalectomy (35). The authors prefer the transperitoneal approach because it allows direct approach to the adrenal vein especially on the right side where the adrenal gland is just posterior to the peritoneal sac. This is particularly important in pheochromocytoma. Walz et al. and Baba et al. popularized the retroperitoneal posterior approach for adrenalectomy (36,37). Sasagawa et al. have successfully performed laparoscopic partial adrenalectomy through this approach (26).

Transperitoneal Approach

Following general anesthesia, a nasogastric tube and a urinary catheter are placed. The patient is positioned in the modified 45° flank position with minimal flexion of the table. All the pressure points are well padded. Once strapped to the table by a wide tape across the hips, the patient is rotated toward the surgeon for another 30° to 40° to facilitate spontaneous, gravity-induced displacement of the bowel off the kidney. A 12-mmHg pneumoperitoneum is created, and the CO₂ is prewarmed with a heat exchanger integrated in the insufflation tubing to prevent catecholamine release due to cold stress. The primary port (10 mm) is placed pararectally 5 cm above the umbilicus on the affected side. Two secondary ports (5 or 10 mm) are placed in the ipsilateral subcostal area to form an equilateral triangle. Three trocars are usually sufficient on the left side. An optional fourth trocar can be placed if necessary, especially on the right side. The authors routinely use a robotic arm (AESOP 3000^{®a}) to hold the camera and to provide a steady good quality picture. On the right side, after retracting the liver anteriorly, a vertical incision is performed on the posterior peritoneum along the inferior vena cava and continued laterally at a right angle, parallel to the lower margin of liver (Fig. 3). Because the adrenal gland lies directly under the peritoneum, this maneuver usually exposes the gland without the need to mobilize the colon or the duodenum. The right main adrenal vein has a consistent location lateral to the inferior vena cava. The left adrenal gland requires wider mobilization of the descending colon and the spleen. As such, the peritoneum is incised along the line of Toldt and the incision is continued upward along the spleen to allow medial descent of the spleen away from the adrenal gland. The splenocolic ligament may be incised as needed. After adequate exposure the adrenal gland, intraoperative laparoscopic color Doppler ultrasound

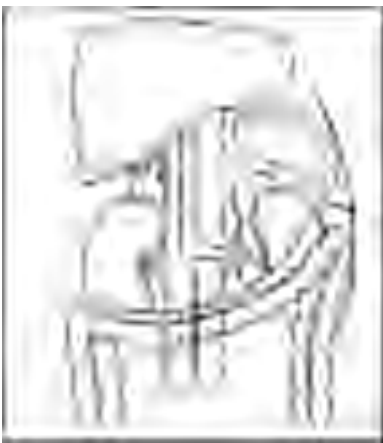
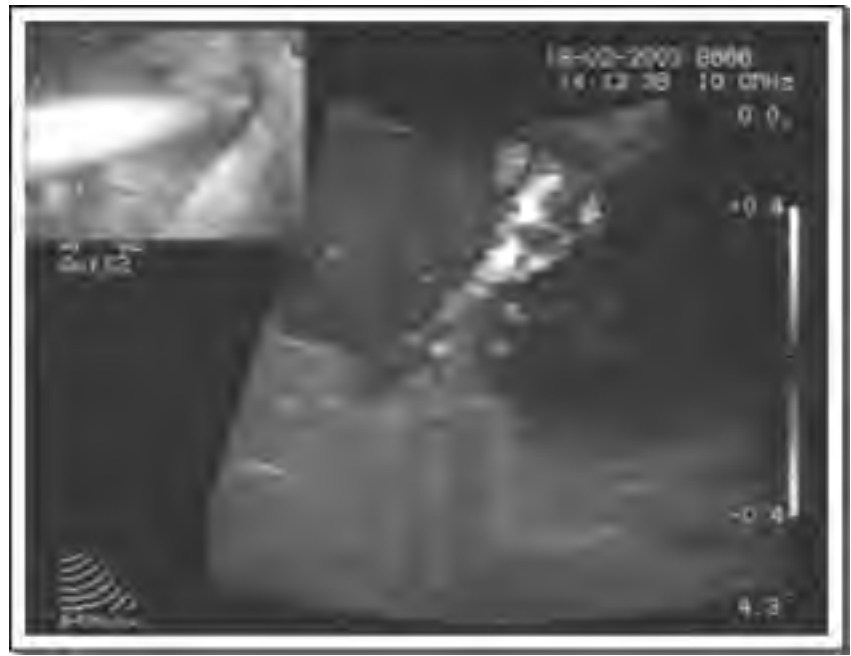
FIGURE 3 ■ Line of incision of the peritoneum on the right and left side to achieve optimum exposure.

^aComputer Motion, Goleta, CA.

FIGURE 4 ■ Intraoperative ultrasound showing the liver and solitary tumor mass and adrenal vein. Abbreviations: L, liver; AG, adrenal gland.



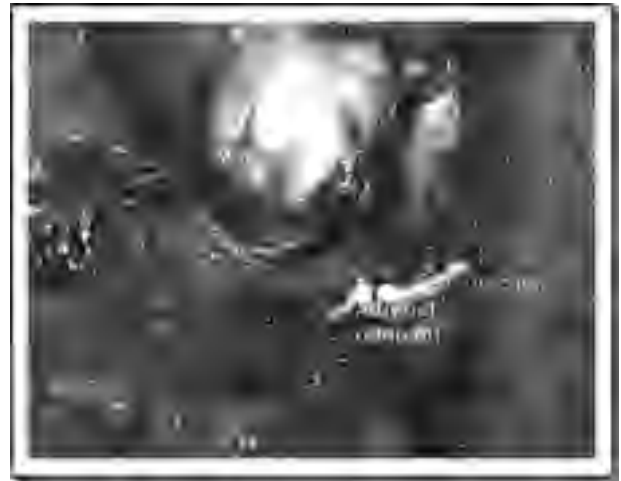
The cortex attached to the surrounding connective tissue via a wide strip of undisturbed tissue containing small arteries and veins is spared.

with 7.5-MHz transducer is a valuable adjunct to image the gland, the tumor, and the adrenal vein (Fig. 4) (38). The dissection of the tumor depends on its location and relationship to the vein. The tumor margin has to be identified and partial removal of the adipose tissue surrounding the tumor may be necessary to clearly delineate the tumor. The tumor is dissected with a small rim of normal adrenal gland to achieve an oncologically safe removal. The adrenal gland parenchyma should not be directly grasped, because of easy friability leading to bleeding. Various techniques of dissection have been proposed. However, the authors prefer preliminary bipolar coagulation along the intended line of dissection and cutting with endoscissors, which allows precise dissection. Harmonic scalpel is also an effective tool to divide the adrenal gland while securing hemostasis (39). The use of a vascular stapler, although feasible (40), does not allow precise dissection. Suture ligation has been used by Walther et al. (41). Every possible effort to spare the adrenal vein should be made, although it can be sacrificed if it is deemed necessary for definitive tumor clearance.

The cortex attached to the surrounding connective tissue via a wide strip of undisturbed tissue containing small arteries and veins is spared. The cut surface is covered with fibrin glue or similar hemostatic agents as a precautionary measure to avoid secondary bleeding. The postoperative viability of adrenal remnants after main adrenal vein division has been elegantly shown with ^{131}I iodosterol scintigraphy by Ikeda et al. (42). The tumor is entrapped in an impermeable retrieval bag system and extracted through the primary port. All port sites are closed with fascial and subcuticular sutures after leaving an optional drain at the discretion of the surgeon.

Retroperitoneal Approach

Comparing the lateral and posterior retroperitoneal approaches for total adrenalectomy, Baba et al. (37) found that the retroperitoneal posterior approach allowed direct access to the main vascular supply prior to gland manipulation. Sasagawa et al. (26) reported their experience of partial adrenalectomy using a posterior retroperitoneoscopic approach. The patient is positioned in low jackknife position with the trunk–thigh hinge of the table used as a flexion point to open the relevant posterior lumbar area between the 12th rib and iliac crest. A 20-mm transverse muscle splitting incision is made below the tip of 12th rib for the primary port. The retroperitoneal space is accessed by digital dissection. The use of a commercially available balloon dilator is optional. After creating the space, two 10-mm trocars are placed 2 to 3 cm medial and lateral to the first port by finger guidance. A blunt-tip trocar is inserted as the primary port and fixed with sutures to avoid gas leak. CO_2 is insufflated into the retroperitoneum. Dissection begins by incising the Gerota's fascia from just below the diaphragm to the level of renal pedicle along the medial crus of the diaphragm. On the left side, adrenal arteries including middle adrenal artery need to be clipped before isolating the main adrenal vein and inferior phrenic vein cranial to

FIGURE 5 ■ Removed tumor mass.

the renal pedicle. On the right side, multiple adrenal arteries are encountered before reaching the inferior vena cava and main adrenal vein. Further steps of dissection depend on the location of the tumor and are akin to the transperitoneal approach (Fig. 5).

RESULTS

Following the demonstration of the feasibility of laparoscopic partial adrenalectomy (6), several authors have reported on short-to-medium term follow-up results of small series of patients with aldosterone adenoma. Al-Sobhi et al. deemed transperitoneal laparoscopic partial adrenalectomy in seven patients with aldosterone-producing adenomas as effective and safe—six patients had normalization of blood pressure and no recurrence at a median follow-up of 12 months (43). Jeschke et al., who employed a transperitoneal approach in 13 patients with aldosterone-producing adenoma, were able to remove the tumor (mean tumor size, 2.1 cm) with negative margins. The mean operative time was 99 minutes, and blood loss was 78 mL. Mean hospital stay was 4.3 days (range, 2–6 days). Normal blood pressure, serum electrolytes, and aldosterone and no local recurrence were observed at a median follow-up of 39 months (44). The same transperitoneal approach was used by Ishikawa et al. in 11 patients with benign adrenal tumors. Operative time for laparoscopic partial adrenalectomy was shorter compared to total adrenalectomy (92 vs. 154 minutes, respectively) (45). Kok and Yapp prospectively reviewed eight patients who underwent laparoscopic partial adrenalectomy for aldosterone-producing adenoma (seven by enucleation and one by vascular stapler). At a mean follow-up of 25 months, hypertension was cured in seven patients and medication requirement significantly reduced in one patient (46). Ikeda's experience in seven patients with aldosterone-producing adenomas and three patients with pheochromocytoma showed no correlation between adrenal vein preservation and the functional status of the adrenal gland, as assessed by postoperative ¹³¹I adosterol scintigram (42). At a mean follow-up of 24 months for aldosterone-producing adenoma patients and 33 months for pheochromocytoma patients, the hormone levels returned to normal. Munver et al. employed this technique successfully in two patients and reviewed worldwide experience (47). Imai et al. effectively used vascular staplers during laparoscopic partial adrenalectomy in five patients with lesions located at the adrenal poles (48). Meria et al. reported a large series of laparoscopic management of primary hyperaldosteronism in 212 consecutive patients, including 20 cases of transperitoneal laparoscopic partial adrenalectomy (49). At a mean follow-up of 44 months, the longest reported to date, hypokalemia was cured in all patients and hypertension was cured or significantly improved with reduction of medication requirements.

The safety and efficacy of laparoscopic partial adrenalectomy for hereditary pheochromocytoma was shown by Janetschek et al. (7). Six patients, two with bilateral disease, successfully underwent laparoscopic partial adrenalectomy. The feasibility of laparoscopic partial adrenalectomy in the presence of more than one tumor in the gland, tackling both adrenal glands, and managing the extra-adrenal pheochromocytoma at the same time was assessed. Blood pressure and urine catecholamines returned to normal and none of the patients required steroid supplementation. After a mean follow-up of

13.5 months (range, 3–18 months), no recurrence was noted. Walther et al. used silk suture ligation and harmonic scalpel in three patients, among whom one had bilateral disease, and removed seven tumors by laparoscopic partial adrenalectomy. During short follow-up, there was no need for steroid supplementation and no tumor recurrence.

Sasagawa et al. (26) performed partial adrenalectomy by the posterior retroperitoneoscopic approach in 13 patients with aldosterone-producing adenoma, 10 with Cushing's adenoma, three with pheochromocytoma, two with myelolipoma, one with ganglioneuroma, and 18 with a nonfunctioning tumor larger 3 cm (total, $n = 47$). Mean operative time was 198 minutes, blood loss 40.8 mL, and open conversion rate 2.1%. Due to the impact of the learning curve, significant operative time reduction was noted in the 26 most recent cases compared to initial cases. Walz et al. reported their experience with laparoscopic management of pheochromocytomas and paraganglionoma, including partial adrenalectomy in 19 patients (50). A retroperitoneal approach was predominantly used and a combination of electrocoagulation, harmonic scalpel, and clips was employed as needed. In seven patients with bilateral disease, partial adrenalectomy was performed, at least unilaterally. All patients had normalization of their biochemical profiles and had no recurrence after a mean follow-up of 34 months. Only one patient in the bilateral group needed cortisol replacement (10 mg hydrocortisone). Interestingly, the main adrenal vein could not be spared in any of these seven patients because of tumor location. Neumann et al. meticulously evaluated the functional result of laparoscopic partial adrenalectomy in four patients with pheochromocytoma (51). Two to 24 months following surgery, all patients were normotensive, had normal sodium, glucose, aldosterone, rennin, and serum cortisol concentrations, and a normal 24-hour excretion of nor-epinephrine, epinephrine, and vanillylmandelic acid. Imaging failed to disclose any recurrence. Adreno corticotrophic hormone stimulation test showed normal cortisol responses.

LAPAROSCOPIC PARTIAL ADRENALECTOMY FOR RECURRENT PHEOCHROMOCYTOMAS

The author reported the first case of laparoscopic partial adrenalectomy for recurrent pheochromocytoma in the literature (52). Walz et al. demonstrated successful laparoscopic surgical treatment of three locally recurrent pheochromocytomas following open transperitoneal surgery, including one case of partial resection (50). They noted limited scarring around the recurrent tumors allowing clear and rapid identification of landmarks and neoplasm, and recommended endoscopic surgery for recurrent pheochromocytomas in experienced hands. In the author's personal experience, laparoscopic partial adrenalectomy was attempted on seven recurrent tumors in five patients with hereditary pheochromocytoma and was successful in five (71%). Total laparoscopic adrenalectomy was necessary in two cases (Table 1).

TABLE 1 ■ Patient Demographics and Tumor Characteristics

No.	Age	Sex	Syndrome	Pheochromocytoma	Previous surgery	Laparoscopic surgery
1	60	F	VHL	R: 2.5, L: 2.0 L retroperitoneum lateral to inferior mesenteric artery 3.5, aortic bifurcation 1.0	L: OPA, R: open exploration ileocolic Area: open exploration	L: TA, R: LPA, excision of paragangliomas
2	20	M	VHL	L: 4.0, 2.0	L: OPA	L: LPA
3	24	F	MEN 2B	L: 1.5	R: OPA, subsequent TA L: two open explorations	L: LPA Subsequent recurrence—lap TA
4	18	M	VHL	L: 4.0, 2.0	Bilateral: OPA	L: LPA
5	12	M	VHL	R: 2.5	Bilateral: LPA	R: LPA

Note: The procedure is easier if the previous surgery had been laparoscopic as well, as it is associated with lesser adhesion formation.

Abbreviations: R, right; L, left; M, male; F, female; MEN, multiple endocrine neoplasia; VHL, von Hippel-Lindau; OPA, open partial adrenalectomy; LPA, laparoscopic partial adrenalectomy; TA, total adrenalectomy.

Source: From Ref. 53.

SUMMARY

- The concept of laparoscopic partial adrenalectomy or adrenal-sparing surgery includes the preservation of the functioning adrenal cortex to obviate the need for hormonal replacement therapy and its attendant, undesired consequences.
- Partial adrenalectomy has limited application in highly selected patients, and, at the time of writing, it was not accepted treatment for the majority of surgical adrenal diseases.
- Micro- or macronodularity in an area of the gland adjacent to an aldosteronoma is a clear contraindication for partial adrenalectomy.
- Laparoscopic partial adrenalectomy of large-sized Cushing's adenomas is technically challenging.
- The least controversial indication for partial adrenalectomy is hereditary pheochromocytoma. Patients with unilateral or bilateral pheochromocytomas are candidates for partial adrenalectomy because a definite risk of contralateral metachronous tumor formation exists.
- Partial adrenalectomy has limited application in highly selected patients, and, at the time of writing, it was not an accepted treatment for the majority of surgical adrenal diseases.

REFERENCES

1. Gagner M, Lacroix A, Prinz RA, et al. Early experience with laparoscopic approach for adrenalectomy. *Surgery* 1993; 114:1120–1126.
2. Prinz RA. A comparison of laparoscopic and open adrenalectomies. *Arch Surg* 1995; 130: 489–494.
3. Guazzoni G, Montorsi F, Bocciardi A, et al. Transperitoneal laparoscopic versus open adrenalectomy for benign hyperfunctioning adrenal tumours: a comparative study. *J Urol* 1995; 153: 1597–1600.
4. Janetschek G, Altarac S, Finkenstedt G, et al. Technique and results of laparoscopic adrenalectomy. *Eur Urol* 1996; 30: 475–479.
5. Thompson GB, Grant CS, van Heerden J, et al. Laparoscopic vs. open posterior adrenalectomy. A case control study of 100 patients. *Surgery* 1997; 6:132–136.
6. Janetschek G, Lhotka K, Gasser R, et al. Adrenal sparing laparoscopic surgery for aldosterone producing adenoma. *J Endourol* 1997; 11:145–148.
7. Janetschek G, Finkenstedt G, Gasser R, et al. Laparoscopic surgery for pheochromocytoma: adrenalectomy, partial resection, excision of paragangliomas. *J Urol* 1998; 160:330–334.
8. Walz MK, Peitgen K, Saller B, Giebler RM, et al. Subtotal adrenalectomy by the posterior retroperitoneoscopic approach. *World J Surg* 1998; 22:621–627.
9. Dobbie JW, Symington T. The human adrenal gland with special reference to the vasculature. *J Endocr* 1966; 34:479.
10. Janetschek G, Neumann HPH. Laparoscopic surgery for pheochromocytoma. *Urol Clin North Am* 2001; 28(1):97–105.
11. Oelkers W. Adrenal insufficiency. *N Eng J Med* 1996; 335:1206–1212.
12. Zeilssen PM, Croughs RJM, Van Rijk PP, et al. Effect of glucocorticoid replacement therapy on bone mineral density in patients with Addison disease. *Ann Intern Med* 1994; 120:207–210.
13. Telenius-Berg M, Ponder MA, Berg B, Ponder BAJ, Werner S. Quality of life after bilateral adrenalectomy in multiple endocrine neoplasia 2. *Henry Ford Hosp Med* 1989; 37:160–163.
14. Nakada T, Kubota Y, Sasagawa I, et al. Therapeutic outcome of primary aldosteronism: adrenalectomy versus enucleation of aldosterone-producing adenoma. *J Urol* 1995; 153:1775–1780.
15. Ross NA, Aron DC. Hormonal evaluation of the patient with an incidentally discovered adrenal mass. *N Eng J Med* 1990; 323:1401–1405.
16. Thompson NW, Cheung PSY. Diagnosis and treatment of functioning and non-functioning adrenocortical neoplasms including incidentalomas. *Surg Clin North Am* 1987; 67:423–436.
17. Aso Y, Homma Y. A survey on incidental adrenal tumors in Japan. *J Urol* 1992; 147:1479–1481.
18. Ito Y, Fujimoto Y, Obara T, Kodama T. Clinical significance of associated nodular lesions of the adrenal in patients with aldosteronoma. *World J Surg* 1990; 14:330–334.
19. Neumann HPH, Bender BU, Reinicke M, et al. Adrenal sparing surgery for pheochromocytoma. *Br J Surg* 1999; 86:94–97.
20. Walther MM, Keiser HR, Choyke PL, Rayford W, Lyne JC, Linegan WM. Management of hereditary pheochromocytoma in von Hippel–Lindau kindreds with partial adrenalectomy. *J Urol* 1999; 161:395–398.
21. Lee JE, Curley SA, Gagel RF, Evans DB, Hickey RC. Cortical sparing adrenalectomy for patients with bilateral pheochromocytoma. *Surgery* 1996; 120:1064–1070.
22. Giordano WC. Preservation of adrenocortical function during surgery for bilateral pheochromocytoma. *J Urol* 1981; 127(1):100–102.
23. Albanese computed tomography, Wiener ES. Routine total bilateral adrenalectomy is not warranted in childhood familial pheochromocytoma. *J Ped Surg* 1993; 28:1248–12451.
24. Okamoto T, Obara T, Ito Y, et al. Bilateral adrenalectomy with autotransplantation of adrenocortical tissue or unilateral adrenalectomy: treatment options for pheochromocytomas in multiple endocrine neoplasia type 2A. *Endocrinol J* 1996; 43(2):169–175.
25. van Heerden JA, Sizemore GW, Carney JA, et al. Bilateral subtotal adrenal resection for bilateral pheochromocytomas in multiple endocrine neoplasia type IIa: case report. *Surgery* 1985; 98:363–366.
26. Sasagawa I, Suzuki Y, Itoh K, Miura M, Suzuki H, Tomita Y. Posterior retroperitoneoscopic partial adrenalectomy: clinical experience in 47 procedures. *Eur Urol* 2003; 43:381–385.

27. Vaughan ED Jr, Blumenfeld JD, Del Pizzo J, Schichman SJ, Sosa RE. In: Walsh PC, Retik AB, Vaughan ED Jr, Wein AJ, eds. *The Adrenals*. Campbell's Urology. 8th ed. Saunders, 2002; 2360–2398.
28. Newhouse JH. magnetic resonance imaging of the adrenal gland. *Urol Radiol* 1990; 12(1):1–6.
29. Neumann HPH, Berger DP, Sigmund G, et al. Pheochromocytomas, multiple endocrine neoplasia type 2 and von Hippel–Lindau disease. *N Engl J med* 1993; 329: 1531–1538.
30. Pattou FN, Combemale FP, Poirrette JF, et al. Questionability of the benefits of routine laparotomy as the surgical approach for pheochromocytoma and abdominal paragangliomas. *Surgery* 1996; 120(6):1006–1011.
31. Orchard T, Grant CS, van Heerden JA, et al. Pheochromocytoma—continuing evaluation of surgical therapy. *Surgery* 1993; 114:1153–1159.
32. Ulchaker JC, Goldfarb DA, Bravo EL, et al. Successful outcomes in pheochromocytoma surgery in the modern era. *J Urol* 1999; 161:764–767.
33. Mann C, Millat B, Boccara G, et al. Tolerance of laparoscopy for resection of pheochromocytoma. *Brit. J Anesth* 1996; 77:795–797.
34. Fernández- Cruz L, Taurà P, Sàenz A, et al. Laparoscopic approach to pheochromocytoma: hemodynamic changes and catecholamine secretion. *World J Surg* 1996; 20:762–768.
35. Sung GT, Gill IS, Hobart M, et al. Laparoscopic adrenalectomy: prospective, randomised comparison of transperitoneal versus retroperitoneal approaches. *J Urol* 1999; (suppl 161):21, abstract 69.
36. Walz MK, Peitgen K, Hoermann R, et al. Posterior retroperitoneoscopy as a new minimally invasive approach for adrenalectomy: results of 30 adrenalectomies in 27 patients. *World J Surg* 1996; 20:769–774.
37. Baba S, Miyajima A, Uchida A, et al. A posterior lumbar approach for retroperitoneoscopic adrenalectomy: assessment of surgical efficiency. *Urology* 1997; 50(1):19–24.
38. Pautler SE, Choyke PL, Pavlovich CP, et al. Intraoperative ultrasound aids in dissection during laparoscopic partial adrenalectomy. *J Urol* 2002; 168:1352–1355.
39. Suzuki K, Sugiyama T, Saisu K, et al. Retroperitoneoscopic partial adrenalectomy for aldosterone producing adenoma using an ultrasonically activated scalpel. *Br J Urol* 1998; 82:138–139.
40. Sasagawa I, Suzuki H, Tateno T, et al. Retroperitoneoscopic partial adrenalectomy using an endoscopic stapling device in patients with adrenal tumor. *Urol Int* 1998; 61:101–103.
41. Walther MM, Herring J, Choyke PL, Linehan WM. Laparoscopic partial adrenalectomy in patients with hereditary forms of pheochromocytoma. *J Urol* 2000; 164:14–17.
42. Ikeda Y, Takami H, Tajima G, et al. Laparoscopic partial adrenalectomy. *Biomed Pharmacother* 2002; 56:126–131.
43. Al-Sobhi S, Peschel R, Bartsch G, et al. Partial laparoscopic adrenalectomy for aldosterone-producing adenoma: short and long term results. *J Endourol* 2000; 14(6):497–499.
44. Jeschke K, Janetschek G, Peschel R, et al. Laparoscopic partial adrenalectomy in patients with aldosterone producing adenomas: indication, technique and results. *Urology* 2003; 61(1):69–72.
45. Ishikawa T, Inaba M, Nishiguchi Y, et al. Laparoscopic adrenalectomy for benign adrenal tumors. *Biomed Pharmacother* 2000; 54(suppl 1):183s–186s.
46. Kok KY, Yapp SK. Laparoscopic adrenal-sparing surgery for primary hyperaldosteronism due to aldosterone producing adenoma. *Surg Endosc* 2002; 16:108–111.
47. Munver R, Del Pizzo J, Sosa RE. Adrenal preserving minimally invasive surgery: the role of laparoscopic partial adrenalectomy, cryosurgery and radio-frequency ablation of the adrenal gland. *Curr Urol Rep* 2003; 4(1):87–92.
48. Imai T, Tanaka Y, Kikumori T, et al. Laparoscopic partial adrenalectomy. *Surg Endosc* 1999; 13(4):343–345.
49. Meria P, Kempf BF, Hermieu JF, et al. Laparoscopic management of primary hyperaldosteronism: clinical experience with 212 cases. *J Urol* 2003; 169:32–35.
50. Walz MK, Peitgen K, Neumann HPH, et al. Endoscopic treatment of solitary, bilateral, multiple and recurrent pheochromocytomas and paragangliomas. *World J Surg* 2002; 26:1005–1012.
51. Neumann HPH, Reincke M, Bender BU, Elsner R, Janetschek G. Preserved adrenocortical function after laparoscopic bilateral adrenal sparing surgery for hereditary pheochromocytoma. *J Clin Endocrinol Metab* 1999; 84(4):2608–2610.
52. Al-Sobhi S, Peschel R, Zinac C, Bartsch G, Neumann H, Janetschek G. Laparoscopic partial adrenalectomy for recurrent pheochromocytoma after open partial adrenalectomy in Von Hippel–Lindau disease. *J Endourol* 2002; 16(3):171–174.
53. Pattaras JG, Moore RG, Landman J, et al. Incidence of postoperative adhesion formation after transperitoneal genitourinary laparoscopic surgery. *Urology* 2002; 59(1):37–41.

LAPAROSCOPIC SURGICAL MANAGEMENT OF EXTRA-ADRENAL PHEOCHROMOCYTOMA

Ashish Behari and McClellan M. Walther

National Institute of Health, Bethesda, Maryland, U.S.A.

- INTRODUCTION
- EMBRYOLOGY
- CLINICAL PRESENTATION AND DIAGNOSIS
- SURGICAL TECHNIQUE
- DISCUSSION
- CONCLUSION
- SUMMARY
- REFERENCES

Pheochromocytomas are tumors of chromaffin cells located in the paraganglionic system and can occur in the adrenal glands or in the sympathetic chain.

INTRODUCTION

Pheochromocytomas are tumors of chromaffin cells located in the paraganglionic system and can occur in the adrenal glands or in the sympathetic chain.

It has been estimated that one in two million people in the United States is affected each year by extra-adrenal pheochromocytoma. Sporadic pheochromocytoma has been found in 0.002% to 0.13% of the population, and is the sole cause of hypertension in less than 1% (1,2) of all newly diagnosed hypertension. In 15% to 50% of hereditary causes, of which von Hippel-Lindau disease and multiple endocrine neoplasia type 2 are the most common types, pheochromocytoma is present (3). About 10% of pheochromocytomas are extra-adrenal, although recent reports suggest that as many as 18% may occur in extra-adrenal locations (4,5).

EMBRYOLOGY

The paraganglion system comprises several groups of structures of neural crest origin, characterized by the presence of granule-storing chief cells. The classification of the extra-adrenal paraganglion system is based on the anatomic distribution, innervation, and microscopic structure into branchiomic, intravagal, aorticosympathetic, and visceroautonomic paraganglia (6). Branchiomic and intravagal paraganglia most commonly refer to chemoreceptors of the carotid bodies and aortic arch as well as the paraganglia of the head, neck, and superior mediastinum. Pheochromocytomas in these locations are called carotid body and glomus jugulare tumors. Tumors arising from these bodies are referred to as paragangliomas, and when functional are referred to as extra-adrenal pheochromocytomas or functional paragangliomas (7,8). Visceroautonomic paraganglia are found in the atrial septa, liver hilum, and bladder submucosa and associated with mesenteric vessels (6).

CLINICAL PRESENTATION AND DIAGNOSIS

Clinical manifestations of paraganglioma are varied and related to tumor function. Micturitional headaches have been reported with functional bladder pheochromocytoma (9).

Functional tumors can cause classic paroxysmal hypertension, tachycardia, hypovolemia, and flushing. Nonfunctioning tumors may only be diagnosed when symptoms from local growth develop, i.e., palpable mass or abdominal pain.

Patients with hereditary pheochromocytoma typically present at younger ages, in the second to third decades, than sporadic tumors. Hereditary pheochromocytoma syndromes include von Hippel-Lindau disease, multiple endocrine neoplasia type 2, neurofibromatosis type 1, and familial carotid body tumors. Tumors in von Hippel-Lindau disease patients identified by screening tend to be less symptomatic, smaller, and less functional when compared to sporadic pheochromocytoma (10).

Biochemical assays testing for elevated plasma and urine catecholamines have been the mainstay in screening for pheochromocytoma. These assays have their limitations,

Functional tumors can cause classic paroxysmal hypertension, tachycardia, hypovolemia, and flushing. Nonfunctioning tumors may only be diagnosed when symptoms from local growth develop, i.e., palpable mass or abdominal pain.

Measurements of plasma-free metanephrines have been shown to be a more sensitive biochemical assay for the detection of pheochromocytoma.

Localization of a suspected pheochromocytoma or paraganglioma can occasionally be challenging because these tumors can occur anywhere along the sympathetic chain from the carotid bodies to the adrenergic plexus of the bladder.

Laparoscopy is now used to remove adrenal and extra-adrenal pheochromocytoma, leaving open exploration as a less-used option for patients with bulky, invasive tumors or many sites of metastases.

Patients are evaluated two to three months after surgery with imaging and catecholamine studies to confirm removal of all tumors. Metaiodobenzylguanidine scanning along with cross-sectional imaging is used as clip artifact, and postoperative changes can decrease the sensitivity of computed tomography and magnetic resonance imaging if used as the sole postoperative-imaging modality.

Patients undergo pharmacologic blockade before surgery to avoid the complications of catecholamine excess.

A transperitoneal laparoscopic approach to the retroperitoneum similar to that employed during laparoscopic retroperitoneal lymphadenectomy for testicular germ cell tumors is suitable for most extra-adrenal pheochromocytoma.

because catecholamines are normally produced by sympathetic nerves and adrenal medulla; elevated catecholamine levels are not specific to pheochromocytoma. In addition, some pheochromocytomas secrete catecholamines at low levels or episodically leading to false-negative results.

Measurements of plasma-free metanephrines have been shown to be a more sensitive biochemical assay for the detection of pheochromocytoma. Metanephrines and normetanephrines are the *o*-methylated metabolites of catecholamines, and the measurement of plasma metanephrines has been shown to have greater than 97% sensitivity compared to 63% to 85% for other tests (11–13).

Conversion of norepinephrine to epinephrine requires the enzyme phenylethanolamine-*N*-methyltransferase. This enzyme is found only in the adrenal medulla and organ of Zuckerkandl; theoretically extra-adrenal pheochromocytoma should present with symptoms of excess norepinephrine and with elevated plasma normetanephrines, although exceptions have been seen in tumors arising in the organ of Zuckerkandl (4,14).

Localization of a suspected pheochromocytoma or paraganglioma can occasionally be challenging because these tumors can occur anywhere along the sympathetic chain from the carotid bodies to the adrenergic plexus of the bladder (6,7).

Paraganglioma are most commonly found in the para-aortic region near the renal vessels; the next most common location is at the aortic bifurcation or organ of Zuckerkandl. Bladder, thoracic cavity, and neck are less common locations (4,15). While up to 18% of pheochromocytoma will have an extra-adrenal location, 15% to 24% of these patients will have multiple tumors and such incidence is even greater in patients with hereditary syndromes (4,14,16).

As a result of the multifocality of these tumors, historical surgical approaches mandated exploratory laparotomy, with careful abdominal and retroperitoneal exploration for occult disease. Modern preoperative imaging has replaced the need for full open exploration of the abdomen, allowing minimally invasive procedures to be used.

Laparoscopy is now used to remove adrenal and extra-adrenal pheochromocytoma, leaving open exploration as a less-used option for patients with bulky, invasive tumors or many sites of metastases.

A combination of functional and anatomic imaging provides the most accurate localization for suspected disease. Computed tomography and magnetic resonance imaging have sensitivities reaching 90% in detecting extra-adrenal disease; however, specificity is in the 30% to 50% range (17,18). Small lymph nodes or retroperitoneal tumors can be identified with computed tomography imaging. The most widely studied functional imaging study for pheochromocytoma is the I31-metaiodobenzylguanidine scan. Metaiodobenzylguanidine imaging complements cross-axial imaging, in that it provides specificity approaching 100% and a sensitivity of 83% to 90% (18,19). Recently, positron emission tomography scanning has been utilized as an adjunct in patients with positive biochemical markers and negative metaiodobenzylguanidine imaging (18,19). Clinically, metaiodobenzylguanidine imaging will detect pheochromocytoma, whereas cross-axial imaging will provide detailed anatomic relationships between the tumor and surrounding structures to allow for preoperative planning. Figure 1 outlines an imaging algorithm for patients who have suspected disease after positive biochemical testing.

Patients are evaluated two to three months after surgery with imaging and catecholamine studies to confirm removal of all tumors. Metaiodobenzylguanidine scanning along with cross-sectional imaging is used as clip artifact, and postoperative changes can decrease the sensitivity of computed tomography and magnetic resonance imaging if used as the sole postoperative-imaging modality.

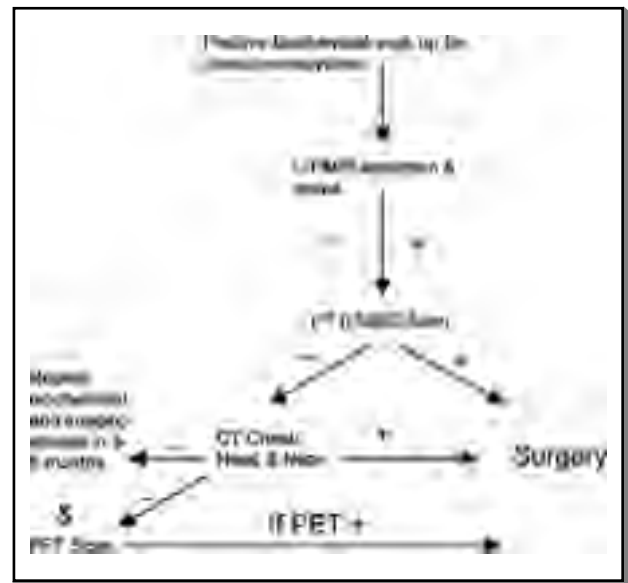
SURGICAL TECHNIQUE

Patients undergo pharmacologic blockade before surgery to avoid the complications of catecholamine excess.

Preoperative blockade consisted of metyrosine 250 mg t.i.d. and phenoxybenzamine 10 mg b.i.d. for two weeks; the dose of metyrosine is increased to 500 mg t.i.d. as tolerated. The night before surgery patients receive 50 mg phenoxybenzamine and 500 mg of metyrosine and are hydrated aggressively.

A transperitoneal laparoscopic approach to the retroperitoneum similar to that employed during laparoscopic retroperitoneal lymphadenectomy for testicular germ cell tumors is suitable for most extra-adrenal pheochromocytoma.

FIGURE 1 ■ Algorithm for localization of pheochromocytoma.
 Abbreviations: CT, computed tomography; MRI, magnetic resonance imaging; PET, positron emission tomography; MIBG, metaiodobenzylguanidine.



Briefly, after the induction of general anesthesia, the patient is placed in the lateral decubitus position. A 10 mm Hassn port is initially placed near the level of the umbilicus along the lateral border of the rectus muscle and used to insufflate the abdomen. Lateral port placement allows good visualization behind the great vessels. Using a 30° lens laparoscope, two (5 or 10 mm) working ports are placed in the ipsilateral abdomen in a triangular shape. Patients with small tumors not requiring many 10 mm clips may be treated using 5 mm ports. In patients with right-side paragangliomas (inter-aorta-caval or right renal hilar tumor), an additional port is placed in the midline caudal to the xyphoid for liver retraction as needed.

For right-sided tumors below the renal vein, the ascending colon and duodenum are mobilized and retracted medially to expose the entire retroperitoneum. Left-sided tumors are visualized after mobilizing the colon medially to the aorta. The full flank position usually allows the overlying structures to fall medially after mobilization. An additional port for retraction can be added if visualization is not adequate. The inferior vena cava and right renal vein are identified, and borders carefully defined using sharp and blunt dissections in the area of the tumor. The right gonadal vein and ureter are isolated and retracted away from the tumor as necessary. Care is taken at the insert of the right gonadal vein to prevent avulsion requiring suturing of the vena cava.

For left-sided tumors, the descending colon, distal transverse colon, spleen, and distal pancreas are mobilized as needed and allowed to be retracted medially by gravity. The lateral margin of the aorta is identified in the location of the tumor found on preoperative imaging. The renal hilum can be defined and the right renal artery traced proximally to its aortic origin to define and preserve this structure if tumors are located in this area. At the inferior pole of the kidney, the ureter is found just lateral to the gonadal vein and isolated laterally for safety.

After the retroperitoneum is opened adequately and inspected visually, we perform ultrasonography to better examine the surgical field.

Intraoperatively, a 7.5 MHz flexible laparoscopic ultrasound probe is used to look for other retroperitoneal masses possibly not seen on preoperative imaging or visible inspection.

Once the paraganglioma is located and its margins defined, the tumor can be mobilized away from the great vessels and the renal vein.

Unlike the adrenal gland in which a well-defined anatomy is usually consistent and predictable, there is no set pattern of venous drainage or arterial supply in paraganglioma. Any tumor vessel of substantial size is isolated and doubly clipped before its division.

Once the tumor is freed from its neighboring large blood vessels, the remaining dissection is performed using harmonic scalpel or clips. Care should be taken to occlude

Intraoperatively, a 7.5 MHz flexible laparoscopic ultrasound probe is used to look for other retroperitoneal masses possibly not seen on preoperative imaging or visible inspection.

Unlike the adrenal gland in which a well-defined anatomy is usually consistent and predictable, there is no set pattern of venous drainage or arterial supply in paraganglioma. Any tumor vessel of substantial size is isolated and doubly clipped before its division.

any lymphatic tissue to prevent a postoperative leak. A formal lymph-node dissection is not routinely performed, but tried to remove all tissue in the area of the tumor, skeletonizing the great vessels and prevertebral fascia. The surgical field is also carefully examined for any enlarged lymph nodes. The finding of pheochromocytoma metastases on frozen section could lead to a wider excision, either laparoscopic or open. The tumor is placed into an Endocatch^{®a} bag and removed through an enlargement of the camera port. After hemostasis is evaluated at low pneumoperitoneum pressure, the surgical area is reinspected visually and with ultrasound for any tumor remnant. Port sites are closed in the standard fashion.

DISCUSSION

Extra-adrenal pheochromocytoma is an uncommon manifestation of a rare disease, and historical series have reported open surgical techniques to achieve cure. As biochemical testing and radiographic imaging have improved, minimally invasive procedures have been introduced into the management of these patients.

The advent of laparoscopy, combined with the development of sensitive biochemical assays and improved imaging, required reevaluation of all the aspects of the management of pheochromocytoma, including extra-adrenal tumors.

Review of the literature reveals a limited number of series evaluating results of laparoscopic management of extra-adrenal pheochromocytoma (20–22). Table 1 summarizes the data from those series.

Size of tumor has not been a contraindication to a minimally invasive approach, as our last patient had a 6.7 cm tumor successfully resected. Review of laparoscopic series shows that of 24 paragangliomas resected in 17 patients, 23/24 were = 4 cm in size. Sixteen of these 17 patients underwent successful laparoscopic or retroperitoneoscopic resection of tumors. One conversion in our series occurred in a patient who had significant adhesion between the paraganglioma, the aorta, and the renal hilum. Postoperative complications are infrequent and are related to pulmonary and positional issues, with one patient from the National Cancer Institute series developing a gluteal hematoma and lower-extremity lymph edema which resolved with conservative management. Noteworthy, one patient in Janetscek’s series developed self-limiting lymph ascites, which resolved after four weeks (22).

Vigilant monitoring and control of intra-operative blood pressure are critical in patients with pheochromocytoma. Intraoperative hypertensive crisis can be avoided with adequate preoperative blockade.

The National Cancer Institute series had only one of seven patients with a systolic blood pressure greater than 200 mmHg, whereas Walz had only 4 of 52 patients undergoing laparoscopic surgery for adrenal or extra-adrenal pheochromocytoma with a systolic blood pressure greater than 200 mmHg (20,21).

Paragangliomas have been linked to more aggressive pathologic behaviors with malignancy rates up to 50% in some series (15,23,24). Neither Walz nor Janetscek reported any evidence of local recurrence in their respective series, although noted a

The advent of laparoscopy, combined with the development of sensitive biochemical assays and improved imaging, required reevaluation of all the aspects of the management of pheochromocytoma, including extra-adrenal tumors.

Vigilant monitoring and control of intra-operative blood pressure are critical in patients with pheochromocytoma. Intraoperative hypertensive crisis can be avoided with adequate preoperative blockade.

TABLE 1 ■ Review of Laparoscopic Extra-Adrenal Literature

Series	n	Hereditary	Surgical approach	Concurrent adrenalectomy (no. of patients)	Tumor size (cm)	Operating room time (min)	Estimated blood loss (cc)	Multiple paraganglioma (no. of patients)	No. converted
NCI-Walther	7	4	Transperitoneal	1-Unilateral 1-Bilateral	1.8–6.7	296	314	1	1
Janetscek	4	4	Transperitoneal	4-Bilateral	2.0–3.5	390–600	100–340	2	0
Walz	6	2	4-Transperitoneal 2-Retroperitoneal	2-Unilateral	1.0–4.0	75–600	NR	3	0

Abbreviations: NCI, National Cancer Institute; NR, Not recorded.
Source: From Refs. 20–22.

^aU.S. Surgical Corp., Norwalk, CT.

Pheochromocytomas of the bladder are rare, with mostly case reports in the literature. Management of these tumors should parallel the approach to extra-adrenal pheochromocytoma.

Transurethral resection bladder tumor has been utilized in select case reports. However, partial cystectomy should be the initial approach to treat pheochromocytoma of the bladder. Although laparoscopic cystectomy and partial cystectomy are still in their infancy, they are a viable approach to all tumors of the bladder.

short follow-up interval. In their series, with a follow range of 6 to 48 months, the authors have not detected any local or distant recurrences.

Pheochromocytomas of the bladder are rare, with mostly case reports in the literature. Management of these tumors should parallel the approach to extra-adrenal pheochromocytoma.

Once the tumor is localized, adequate preoperative blockade is performed prior to any manipulation. Cystoscopically, these tumors tend to be submucosal with occasional mucosal ulceration (10,25–27).

Kozlowski et al. reported a case of successful laparoscopic partial cystectomy for extra-adrenal pheochromocytoma using a combination of endoscopic and laparoscopic excision (25). Endoscopically, a Collin's knife was used to excise the intravesical component while a standard four-diamond laparoscopic port placement, using ultrasonic shears, was used to complete the extravesical mobilization and excision of the tumor. A laparoscopic sac was used to remove the specimen. The defect was then repaired using interrupted 2-0 polyglactin sutures placed free hand and with an EndoStitch^{®b} device (25).

Transurethral resection bladder tumor has been utilized in select case reports (10,27). However, partial cystectomy should be the initial approach to treat pheochromocytoma of the bladder. Although laparoscopic cystectomy and partial cystectomy are still in their infancy, they are a viable approach to all tumors of the bladder.

CONCLUSION

Pheochromocytomas and paragangliomas present multiple challenges to urologic surgeons in terms of diagnosis, localization, and appropriate surgical management. Laparoscopy has obvious advantages for patients including shorter convalescence time, decreased pain, and improved cosmesis. From the surgeon's standpoint, laparoscopy combined with ultrasound allows for complete exploration of the abdominal cavity and increased magnification. Reported series, although small and from centers with extensive laparoscopic experience, indicate that laparoscopy is indeed a safe and technically feasible approach for the treatment of extra-adrenal pheochromocytoma.

SUMMARY

- Functional extra-adrenal tumors can cause classic paroxysmal hypertension, tachycardia, hypovolemia, and flushing. Non-functioning tumors may only be diagnosed when symptoms from local growth develop, i.e., palpable mass or abdominal pain.
- Laparoscopy is now used to remove adrenal and extra-adrenal pheochromocytoma, leaving open exploration as a less used option for patients with bulky, invasive tumors or many sites of metastases.
- Patients must undergo pharmacologic blockade before surgery to avoid the complications of catecholamine excess.
- A transperitoneal laparoscopic approach to the retroperitoneum similar to that employed during laparoscopic retroperitoneal lymphadenectomy for testicular germ cell tumors is suitable for most extra-adrenal pheochromocytoma.
- Intraoperatively, a 7.5 MHz flexible laparoscopic ultrasound probe is used to search for other retroperitoneal masses possibly not seen on preoperative imaging or visible inspection.
- Pheochromocytomas of the bladder are rare, with mostly case reports in the literature. Management of these tumors should parallel the approach to extra-adrenal pheochromocytoma.

REFERENCES

1. Sheps SG, Jiang N-S, Klee GG. Diagnostic evaluation of pheochromocytoma. *Endocrinol Metab Clin North Am* 1988; 17:397–414.
2. Sutton MG, Sheps SG, Lie JT. Prevalence of clinically unsuspected pheochromocytoma: review of a 50-year autopsy series. *Mayo Clin Proc* 1981; 56:354–360.
3. Linehan WM, Walther MM. Molecular genetic abnormalities associated with pheochromocytoma. In: Pacak K, moderator. *Recent Advances in Genetics, Diagnosis, Localization, and Treatment of Pheochromocytoma*. *Ann Intern Med* 2001; 134:316–317.
4. Whalen RK, Althausen AF, Daniels GH. Extra-adrenal pheochromocytoma. *J Urol* 1992; 147:1–10.
5. Moulton JS, Moulton JS. CT of the adrenal glands. *Sem Roentgen* 1988; 23:288.

^bAutosuture Corp., Norwalk, CT.

6. Glenner GG, Grimely PM. Tumors of the extra adrenal paraganglion system. In: Atlas of Tumor Pathology. Washington, D.C.: Armed Forces Institute of Pathology, 1973, fasc. 9.
7. Coupland RE. Post-natal fate of the abdominal para-aortic bodies in man. *J Anat* 1954; 88(4):455–464.
8. Coupland RE. Pre-natal development of the abdominal para-aortic bodies in man. *J Anat* 1952; 86(4):357–372.
9. Doran F, Varinli S, Bayazit Y, Bal N, Özdemir S. Pheochromocytoma of the urinary bladder. Case report. *APMIS* 2002 110:10, p. 733.
10. Walther MM, Reiter R, Keiser HR, et al. Clinical and genetic characterization of pheochromocytoma in von Hippel-Lindau families: comparison with sporadic pheochromocytoma gives insight into natural history of pheochromocytoma. *J Urol* 1999; 162:659–664.
11. Eisenhofer G. Biochemical diagnosis of pheochromocytoma. In: Pacak K, moderator. Recent Advances in Genetics, Diagnosis, Localization, and Treatment of Pheochromocytoma. *Ann Intern Med* 2001; 134:316–317.
12. Goldstein DS, Eisenhofer G, Flynn JA, Wand G, Pacak K. Diagnosis and localization of pheochromocytoma. *Hypertension* 2004; 43(5):907–910.
13. Lenders JW, Pacak K, Walther MM, et al. Biochemical diagnosis of pheochromocytoma: which test is best? *JAMA* 2002; 287:1427–1434.
14. Goldfarb DA, Novick AC, Bravo EL, Straffon RA, Montie JE, Kay R. Experience with extra-adrenal pheochromocytoma. *J Urol* 1989; 142:931.
15. O'Riordain DS, Young WF, Grant CS, Carney JA, van Heerden JA. Clinical spectrum and outcome of functional extra adrenal paragangliomas. *World J Surg* 1996; 20:916–922.
16. Melicow MM. One hundred cases of pheochromocytoma at the Columbia-Presbyterian Medical Center, 1926–1976: a clinicopathologic analysis. *Cancer* 1977; 40(5):1987–2004.
17. Ilias I, Pacak K. Current approaches and recommended algorithm for the diagnostic localization of pheochromocytoma. *J Clin Endocrinol Metab* 2004; 89(2):479–491.
18. Maurea S, Cuocolo A, Reynolds JC, et al. Iodine-131-metaiodobenzylguanidine scintigraphy in preoperative and postoperative evaluation of paragangliomas: comparison with CT and MRI. *J Nucl Med* 1993; 34:173–179.
19. Pacak K, Goldstein DS. Advances in Diagnostic Localization of Pheochromocytoma In: Pacak K, moderator. Recent Advances in Genetics, Diagnosis, Localization, and Treatment of Pheochromocytoma. *Ann Intern Med* 2001; 134:316–317.
20. Hwang J, Shoaf G, Uchio EM, et al. Laparoscopic management of extra-adrenal pheochromocytoma. *J Urol* 2004; 171(1):72–76.
21. Walz M, Peitgen K, Neumann H, Janssen O, Philipp T, Mann K. Endoscopic treatment of solitary, bilateral, multiple, and recurrent pheochromocytomas and paragangliomas. *World J Surg* 2002; 26:1005–1012.
22. Janetschek G, Reissigl A, Peschel R, Hobisch A, Bartsch G. Laparoscopic retroperitoneal lymph node dissection for clinical stage I nonseminomatous testicular tumor. *Urology* 1994; 44:382.
23. Linnoila RL, Keiser HR, Steinberg SM, Lack EE. Histopathology of benign versus malignant sympathoadrenal paragangliomas: clinicopathologic study of 120 cases including unusual histologic features. *Hum Pathol* 1990; 21(11):1168–1180.
24. Glenn F, Gray GF. Functional tumors of the organ of Zuckerkandl. *Ann Surg* 1976; 183(5):578–586.
25. Kozlowski PM, Mihm F, Winfield HN. Laparoscopic management of bladder pheochromocytoma. *Urology* 2001; 57(2):365.
26. Kato H, Suzuki M, Mukai M, Aizawa S. Clinicopathological study of pheochromocytoma of the urinary bladder: immunohistochemical, flow cytometric and ultrastructural findings with review of the literature. *Pathol Int* 1999; 49(12):1093–1099.
27. Onishi T, Sakata Y, Yonemura S, Sugimura Y. Pheochromocytoma of the urinary bladder without typical symptoms. *Int J Urol* 2003; 10(7):398–400.

LAPAROSCOPIC ADRENALECTOMY FOR BENIGN DISEASE: CURRENT STATUS

David S. Wang

*Department of Urology, Boston University School of Medicine,
Boston, Massachusetts, U.S.A.*

Howard N. Winfield

*Department of Urology, University of Iowa Hospitals and Clinics,
Iowa City, Iowa, U.S.A.*

- INTRODUCTION
- DIAGNOSIS
- ALDOSTERONOMAS
- CUSHING'S SYNDROME
- PHEOCHROMOCYTOMA
- INDICATIONS FOR LAPAROSCOPIC ADRENALECTOMY
- RESULTS OF LAPAROSCOPIC ADRENALECTOMY FOR BENIGN DISEASE
- SUMMARY
- REFERENCES

INTRODUCTION

The adrenal glands are known to harbor a variety of benign and malignant tumors. Due to the small size and location of the adrenals, lesions of the adrenal gland are rarely detected due to local symptoms. Instead, most adrenal tumors are diagnosed either incidentally or because of impaired hormonal activity.

Hormonally active adrenal lesions, tumors suspicious for carcinoma, or nonfunctioning adrenal lesions 5 cm or greater in size are suitable for surgical removal.

Traditionally, surgical procedures involving the adrenal gland were performed through an open incision with a variety of approaches. In 1992, the laparoscopic approach to adrenalectomy was introduced (1), offering a less invasive alternative to open adrenalectomy.

Parallel to the growth of experience with laparoscopic adrenalectomy, the indications for laparoscopic adrenalectomy have expanded while the absolute contraindications have diminished. Indeed, laparoscopic adrenalectomy has become a standard of care and the technique of choice for most benign surgical adrenal lesions.

The basic diagnosis and hormonal evaluation, indications, pre-operative considerations, and results of laparoscopic adrenalectomy for benign tumors of the adrenal gland are discussed in this chapter.

DIAGNOSIS

Adrenal lesions historically were diagnosed secondary to clinical manifestations of endocrinopathies. However, widespread use of abdominal ultrasound, computed tomography scanning, and magnetic resonance imaging has led to the not infrequent finding of the incidental adrenal mass. Figures 1 and 2 show typical examples of adrenal lesions diagnosed on computed tomography and magnetic resonance imaging. The differential diagnosis of an incidental adrenal mass is extensive and includes the benign nonfunctioning adenoma, hormonally active cortical tumor, myelolipoma, pheochromocytoma, adrenocortical carcinoma, and metastatic lesion.

Tumors diagnosed incidentally on computed tomography scan or magnetic resonance imaging are managed according to size and hormone functional status.

Patients with hormonally active adrenal tumors, such as aldosteronoma, Cushing's syndrome, cortisol-secreting tumors, or pheochromocytoma should generally undergo surgical removal (2,3).

Thorough hormonal evaluation of these patients is critical because pre- and post-operative considerations regarding hypertensive control, electrolyte imbalances, and fluid shifts are paramount to ensure good surgical outcomes and minimize complications.

Hormonally active adrenal lesions, tumors suspicious for carcinoma, or nonfunctioning adrenal lesions 5 cm or greater in size are suitable for surgical removal.

Indications for laparoscopic adrenalectomy have expanded while absolute contraindications have diminished. laparoscopic adrenalectomy has become a standard of care and the technique of choice for most benign surgical adrenal lesions.

Tumors diagnosed incidentally on computed tomography scan or magnetic resonance imaging are managed according to size and hormone functional status.

Thorough hormonal evaluation of these patients is critical because pre- and post-operative considerations regarding hypertensive control, electrolyte imbalances, and fluid shifts are paramount to ensure good surgical outcomes and minimize complications.

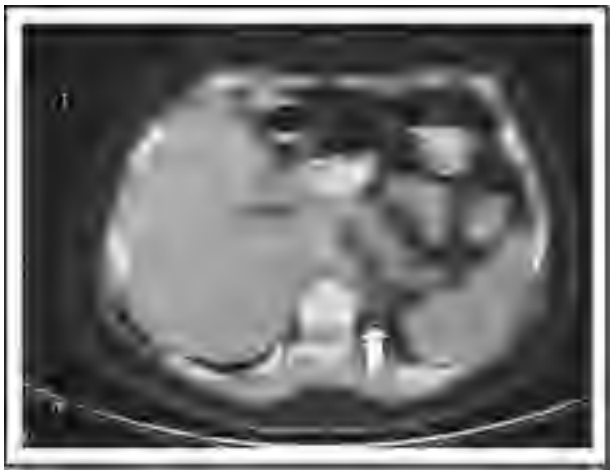

FIGURE 1 ■ An adrenal lesion on computed tomography.

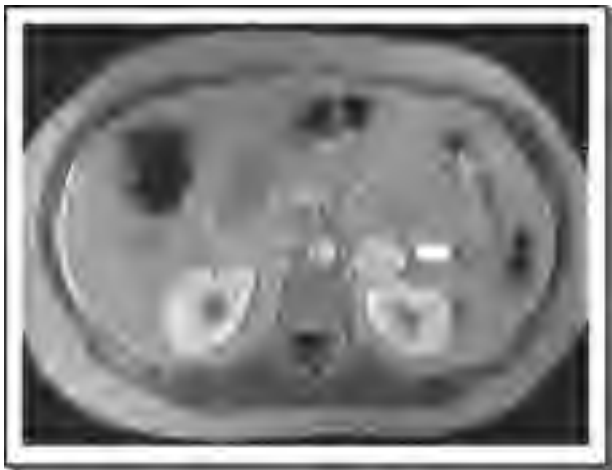

FIGURE 2 ■ An adrenal lesion on magnetic resonance.

A summary of standard laboratory tests in the evaluation of an adrenal lesion is listed in Table 1.

Occasionally, medical management of aldosteronomas may be satisfactory to circumvent the need for surgical management, particularly in patients who are poor surgical candidates (4). However, side effects of pharmacotherapy may become intolerable. Hormonally inactive tumors have traditionally been managed according to size.

- Hormonally inactive tumors less than 3 cm in size are almost always benign adenomas and generally require no further treatment unless an increased in size or clinical signs of hormonal activity are detected.
- Nonfunctional lesions between 3 and 5 cm in size generally require close follow-up with serial imaging studies every six months. These lesions should be removed if tumors demonstrate interval change in appearance or develop endocrine activity.
- Hormonally inactive tumors greater than 6 cm in size are worrisome for adrenocortical carcinomas, and thus surgical excision is recommended given the aggressive nature of adrenal cancer (5).

In one meta analysis, 105 of 114 adrenocortical carcinomas measured 6 cm or greater in diameter (6).

TABLE 1 ■ Routine Laboratory Tests Useful in the Evaluation of Adrenal Lesions

Laboratory test	Frequency of usage
Cushing's syndrome	
24-hr urine cortisol	Common
Plasma ACTH and plasma cortisol	Common
Low-dose dexamethasone suppression test	Occasional
High-dose dexamethasone suppression test	Occasional
Metapyrone stimulation test	Rare
Petrosal sinus ACTH measurement	Extremely rare
Hyperaldosteronism	
Unprovoked hypokalemia	Common
Plasma aldosterone level	Common
Urinary aldosterone level	Common
Aldosterone-to-renin ratio	Common
Postural stimulation test	Rare
Adrenal vein sampling of aldosterone	Extremely rare
Pheochromocytoma	
Plasma catecholamines	Common
Urine catecholamines	Common
Clonidine suppression test	Occasional
Adrenal vein sampling of catecholamines	Extremely rare

Abbreviation: ACTH, adrenocorticotrophic hormone.

- All lesions which are 5 cm or greater in size on computed tomography scan should be removed because computed tomography scan tends to underestimate the size of lesions by as much as 1 cm (7).
- Open radical adrenalectomy with possible en bloc resection of adjacent organs is the preferred approach whenever adrenal carcinoma with local extension into adjacent organs such as the kidney, colon, or spleen, is a concern (8,9).

More recently, improvements in radiologic imaging techniques such as unenhanced and delayed enhanced computed tomography with densitometry, chemical-shift magnetic resonance imaging, and NP-59 scintigraphy have further assisted in differentiating benign from malignant neoplasms (10).

ALDOSTERONOMAS

Primary hyperaldosteronism (Conn's syndrome) is a rare etiology of hypertension (<1%). Other clinical manifestations of Conn's syndrome arise from an increased total body sodium content and a deficit in total body potassium. Symptoms include urinary urgency or frequency, nocturia, muscle weakness, paresthesias, or visual disturbances (4,11). Computed tomography scan or magnetic resonance imaging can detect adrenal adenomas as small as 1 cm in size. Laboratory manifestations include hypokalemia, elevated plasma and urinary aldosterone level, elevated serum aldosterone-to-renin ratio, and suppressed plasma renin activity (4,11). Once an important part of the evaluation, adrenal vein sampling is currently rarely used to confirm and localize the lesion.

Once the diagnosis is confirmed, medical control of hypertension and correction of hypokalemia should be instituted at least several weeks prior to adrenalectomy. The most effective medication for management of hyperaldosteronism is spironolactone, a competitive antagonist of the aldosterone receptor (4). Side effects of spironolactone include hyperkalemia, sexual dysfunction, gynecomastia, gastrointestinal disturbances, and metabolic acidosis (12). Alternative medications include potassium sparing diuretics, calcium channel blockers, or converting enzyme inhibitors (11). Adrenalectomy improves or cures hypertension in approximately 90% of patients (13).

CUSHING'S SYNDROME

Cushing's syndrome comprises the symptom complex resulting from excess circulating glucocorticoids, regardless of etiology (3). Non-adrenal causes of hypercortisolism include pituitary adenomas, ectopic corticotrophin production, and exogenous steroid use. The urologist is most often confronted with an adrenal lesion as the etiology of Cushing's syndrome.

Cushing's syndrome manifests with a variety of well recognized clinical features, including hypertension, truncal obesity, moon facies, easy bruising, and mood disorders. Diagnosis is confirmed by laboratory testing (3). Hypercortisolism is best diagnosed by 24-hour urinary cortisol measurement. The low-dose dexamethasone suppression test can be used to further diagnose Cushing's syndrome if urinary cortisol measurement is equivocal. Abdominal computed tomography scan and magnetic resonance imaging can identify adrenal adenomas or bilateral adrenal hyperplasia.

PHEOCHROMOCYTOMA

Pheochromocytomas can be challenging tumors to treat because of the unique manifestations of chronic and acute catecholamine excess. In general, catecholamine excess results in hypertension, tachycardia, and a host of clinical manifestations. Laboratory diagnosis is made by elevated levels of catecholamines in the blood and urine. Radiographic diagnosis is achieved with either computed tomography scan or magnetic resonance imaging. Magnetic resonance imaging classically demonstrates a bright image on a T2-weighted study. Additionally, metaiodobenzylguanidine nuclear medicine scanning can help confirm and localize pheochromocytomas. The treatment of choice for most pheochromocytomas is surgical excision.

Successful surgical management of pheochromocytoma requires close collaboration among the surgeon, endocrinologist, and anesthesiologist.

It is essential to have an anesthesiologist familiar with pheochromocytoma, able to adequately manage blood pressure intra-operatively, and knowledgeable about which anesthetic agents to avoid.

Successful surgical management of pheochromocytoma requires close collaboration among the surgeon, endocrinologist, and anesthesiologist.

It is essential to have an anesthesiologist familiar with pheochromocytoma, able to adequately manage blood pressure intra-operatively, and knowledgeable about which anesthetic agents to avoid.

With increasing worldwide experience with laparoscopic adrenalectomy, pheochromocytoma is no longer considered a contraindication to laparoscopic surgery.

In the past, all pheochromocytomas were treated through an open approach, with early control of the adrenal vein. With increasing worldwide experience with laparoscopic adrenalectomy, pheochromocytoma is no longer considered a contraindication to laparoscopic surgery. In fact, laparoscopic adrenalectomy for pheochromocytomas has now been performed successfully at many centers of laparoscopic excellence and reported in several series (14–16).

Regardless of the surgical approach chosen, preoperative medical preparation is essential, and includes optimal control of blood pressure with alpha blockade or calcium channel antagonists (2). Beta-blockers may be used to control reflex tachycardia after initiation of alpha blockade. In addition, aggressive fluid expansion is necessary to increase circulating plasma volume and prevent postoperative hypotension. Close intra-operative monitoring includes careful attention to blood pressure, central venous pressure, and urinary output. An arterial line and central venous line are routinely used, and occasionally a Swan-Ganz catheter is employed. Severe hypertension can be controlled with sodium nitroprusside or phentolamine, and hypotension controlled with fluid resuscitation and norepinephrine.

INDICATIONS FOR LAPAROSCOPIC ADRENALECTOMY

The indications for laparoscopic adrenalectomy have expanded as more surgeons have become proficient with the technique and the advantages of this approach have become apparent. In many centers, laparoscopic adrenalectomy has become the surgical procedure of choice for the management of functional tumors less than 6 cm in size. Although the presence of pheochromocytoma was a relative contraindication for laparoscopic adrenalectomy in the past, it is clear that the procedure can be performed safely as long as the same precautions are taken as those for open surgery (14). The current indications for performing a laparoscopic adrenalectomy are listed in Table 2.

Patients who may not tolerate an open operation are generally poor candidates for laparoscopic adrenalectomy.

There are few contraindications to laparoscopic adrenalectomy. Absolute contraindications to laparoscopic adrenalectomy include uncorrectable coagulopathy and severe cardiopulmonary disease precluding general anesthesia. Patients who may not tolerate an open operation are generally poor candidates for laparoscopic adrenalectomy.

Relative contraindications to laparoscopic adrenalectomy include previous abdominal surgery or significant morbidity. Lesions greater than 8 cm in size, even if not suspected to be primary adrenal carcinomas, should be approached cautiously because of the increased risk of hemorrhage and injury to surrounding viscera.

With increasing experience in performing laparoscopic adrenalectomy, relative contraindications become less of a factor. In addition, a variety of approaches to laparoscopic adrenalectomy, including transperitoneal and retroperitoneal, have further decreased some of the relative contraindications. It is generally felt that a known or suspected primary adrenal carcinoma, particularly with extension into surrounding organs, should be removed by an open technique. Given the aggressive nature of the disease, the open approach allows for en bloc resection and potential removal of surrounding organs (8).

RESULTS OF LAPAROSCOPIC ADRENALECTOMY FOR BENIGN DISEASE

Worldwide experience with laparoscopic adrenal surgery has increased since its original description in 1992. Several centers have reported large series documenting the decreased blood loss, shortened hospital stay, and faster return to normal activity. Selected recent series in the literature are summarized in Table 3.

Gagner et al. reported on 100 consecutive laparoscopic adrenalectomy procedures performed using the transperitoneal approach (31). The lesions removed included pheochromocytomas, aldosteronomas, Cushing’s lesions, and others. Mean operative time was 123 minutes, and estimated blood loss 70 cc. In this series, the open conversion

TABLE 2 ■ Indications for Laparoscopic Adrenalectomy for Benign Disease

Aldosterone secreting adrenal gland, adenoma, or unilateral hyperplasia
Cushing’s syndrome secondary to adrenocortical adenoma
Nonfunctional adrenal mass ≤8 cm with negative metastatic workup
Nonfunctional adrenal mass ≤8 cm with progressive growth on CT or MRI
Adrenal pheochromocytoma (benign) ≤8 cm
Abbreviations: CT, computed tomography; MRI, magnetic resonance imaging.

TABLE 3 ■ Selected Laparoscopic Adrenalectomy Series

Author	No. of cases	Age	Approach	OR time (min)	EBL (cc)	Hospital stay (day)	Conversion/rate	Complications
Prager (17) (2004)	102	-	Transperitoneal	-	-	-	5/102	2 Blood transfusion, 1 ventral hernia, 1 Peri renal hematoma
MacGillivray (18) (2002)	60	-	Transperitoneal	183	63	2	0/60	
Valeri (19)	91	-	Transperitoneal	92-148	-	3.5	2/91	2 Postoperative hemorrhage, 1 port site bleed
Kebebew (20) (2001)	176	-	Transperitoneal	168	-	1.7	0/176	1 UTI, 1 death from myocardial infarction
Lezoche (21) (2001)	216	45.9	149 Transperitoneal 67 Retroperitoneal	100	-	-	4/216	5.1% 1 Death, 1 hemoperitoneum, 1 wound infection
Salamon (22) (2001)	115	49.3	115 Retroperitoneal	118	77	4	1/118	3.5% Intraoperative 12.1% Postoperative
Guazzoni (23) (2001)	161	39.4	Transperitoneal	160	-	2.8	4/161	5.5%
Suzuki (24) (2001)	118	51.7	78 Transperitoneal 40 Retroperitoneal	171	96.3	-	6/118	2 Paralytic ileus 4 Shoulder tip pain
Soulie (25) (2000)	52	46.9	52 Retroperitoneal	135	80	5	1/52	5.7% Intraoperative 11.5% Postoperative
Mancini (26) (1999)	172	-	Transperitoneal	132	-	5.8	12/172	8.7% 2 Deaths
Schichman (27) (1999)	50	54	Transperitoneal	219	142	3	0/50	10%
Winfield (28) (1998)	21	52.2	Transperitoneal	219	183	2.7	0/21	1 Subcutaneous bleed 2 Pneumothorax
Yoshimura (29) (1998)	28	42	11 Transperitoneal 17 Retroperitoneal	375	370	2.7	0/28	1 Pulmonary edema 4 Blood transfusion 4 Subcutaneous emphysema 2 Postoperative bleeding 1 Pneumonia
Chee (30) (1998)	14	46.2	8 Transperitoneal 6 Retroperitoneal	135	Min	3	0/14	
Gagner (31) (1997)	100	46	Transperitoneal	123	70	3	3/100	12% 3 DVT, 2 pulmonary embolus
Gasman (32) (1997)	23	49.6	23 Retroperitoneal	97	70	3.3	0/23	1 Postoperative hematoma
Terachi (33) (1997)	100	-	Transperitoneal	240	77	-	3/100	-
Rutherford (34) (1996)	67	54	Transperitoneal	124	-	5.1	0/67	3 DVT, 2 pulmonary emboli 1 Port site hernia, 1 postoperative bleed
Average		47.1		153.5	98.6		41/1669 (2.5%)	

Abbreviations: OR, operating room; UTI, urinary tract infection; DVT, deep vein thrombosis; EBL, estimated blood loss.

rate was 3%, average length of hospital stay was three days or less, and postoperative morbidity was experienced by 12% of patients.

In the largest reported series, a combined experience of surgeons in Italy and the Netherlands by Lezoche et al. (21), a total of 216 laparoscopic adrenalectomies were performed using the anterior transperitoneal, lateral transperitoneal, or the posterior retroperitoneal approaches. The average operating time of all approaches was 100 minutes with a conversion rate of only 1.9%. Average hospital stay for all approaches was three to four days.

Studies comparing laparoscopic and open adrenalectomy have been conducted to determine if there are significant benefits provided by the laparoscopic approach (28,29,34–40). Overall, laparoscopic surgery requires longer operative time, particularly early in the learning curve. However, operative time decreases with increasing surgeon experience. In addition, the laparoscopic approach provides less blood loss, significantly less postoperative narcotic use, overall shorter hospital stay, and a faster return to normal activity. In one study, the costs of a laparoscopic and open adrenalectomy were comparable (41).

SUMMARY

- Unquestioned advantages of the laparoscopic approach include shorter hospitalization and convalescence. In addition, even hormonally active lesions such as pheochromocytomas can be safely approached laparoscopically.
- Relative contraindications to the laparoscopic approach include very large benign lesions and primary adrenal carcinomas.
- Both the transperitoneal and retroperitoneal techniques yield satisfactory results.
- Laparoscopic adrenalectomy has been shown to be a safe and effective approach to many forms of adrenal pathology. It should be considered the standard of care in the management of benign lesions of the adrenal gland that require surgical removal.

REFERENCES

1. Gagner M, Lacroix A, Bolte E. Laparoscopic adrenalectomy in Cushing's syndrome and pheochromocytoma. *N Engl J Med* 1992; 327:1033.
2. Walther MM, Keiser HR, Linehan WM. Pheochromocytoma: evaluation, diagnosis, and treatment. *World J Urol* 1999; 17:35–39.
3. Goldfarb DA. Contemporary evaluation and management of Cushing's syndrome. *World J Urol* 1999; 17:22–25.
4. Blumenfeld JD, Vaughan ED Jr. Diagnosis and treatment of primary aldosteronism. *World J Urol* 1999; 17:15–21.
5. Murai M, Baba S, Nakashima J, et al. Management of incidentally discovered adrenal masses. *World J Urol* 1999; 17:9–14.
6. Beldegrun A, Hussain S, Seltzer S, et al. Incidentally discovered mass of the adrenal gland. *Surg Gynecol Obstet* 1986; 163:203–208.
7. Cerfolio RJ, Vaughan ED Jr, Brennan TG Jr, et al. Accuracy of computed tomography in predicting adrenal tumor size. *Surg Gynecol Obstet* 1993; 176:307–309.
8. Schulick RD, Brenna MF. Adrenocortical carcinoma. *World J Urol* 1999; 17:26–34.
9. Vaughan ED Jr. Surgical options for open adrenalectomy. *World J Urol* 1999; 17:40–47.
10. Teeger S, Papanicolaou N, Vaughan ED Jr. Current concepts in imaging of adrenal masses. *World J Urol* 1999; 17:3–8.
11. Ferriss JB, Beevers DG, Brown JJ, et al. Clinical, biochemical and pathological features of low-renin ("primary") hyperaldosteronism. *Am Heart J* 1978; 95:375–388.
12. deGasparo M, Whitebread SE, Preiswerk G, et al. Antialdosterones: Incidence and prevention of sexual side effects. *J Steroid Biochem* 1989; 32(1B):223–227.
13. Blumenfeld JD, Sealey JE, Schluskel Y, et al. Diagnosis and treatment of primary aldosteronism. *Ann Intern Med* 1994; 121:877–885.
14. Edwin B, Kazaryan AM, Mala T, et al. Laparoscopic and open surgery for pheochromocytoma. *BMC Surg* 2001; 1:2.
15. Salomon L, Rabii R, Soulie M, et al. Experience with retroperitoneal laparoscopic adrenalectomy for pheochromocytoma. *J Urol* 2001; 165:1871–1874.
16. Gotoh M, Ono Y, Hattori R, et al. Laparoscopic adrenalectomy for pheochromocytoma: morbidity compared with adrenalectomy for tumors of other pathology. *J Endourol* 2002; 16:245–249.
17. Prager G, Heinz-Peer G, Passler C, et al. Applicability of laparoscopic adrenalectomy in a prospective study in 150 consecutive patients. *Arch Surg* 2004; 139:46–49.
18. MacGillivray DC, Whalen GF, Malchoff CD, et al. Laparoscopic resection of large adrenal tumors. *Ann Surg Oncol* 2002; 9:480–485.
19. Valeri A, Borrelli A, Presenti L, et al. The influence of new technologies on laparoscopic adrenalectomy. *Surg Endosc* 2002; 16:1274–1279.
20. Kebebew E, Siperstein AE, Duh QY. Laparoscopic adrenalectomy: the optimal surgical approach. *J Laparoendosc Adv Surg Tech A* 2001; 11:409–413.

21. Lezoche E, Guerrieri M, Feliciotti F, et al. Anterior, lateral, and posterior retroperitoneal approaches in endoscopic adrenalectomy. *Surg Endosc* 2002; 16:96–99.
22. Salomon L, Soulie M, Mouly P, et al. Experience with retroperitoneal laparoscopic adrenalectomy in 115 procedures. *J Urol* 2001; 166:38–41.
23. Guazzoni G, Cestari A, Montorsi F, et al. Eight-year experience with transperitoneal laparoscopic adrenal surgery. *J Urol* 2001; 166:820–824.
24. Suzuki K, Kageyama S, Hirano Y, et al. Comparison of 3 surgical approaches to laparoscopic adrenalectomy: a nonrandomized, background matched analysis. *J Urol* 2001; 166:437–443.
25. Soulie M, Mouly P, Caron P, et al. Retroperitoneal laparoscopic adrenalectomy: clinical experience in 52 procedures. *Urology* 2000; 56:921–925.
26. Mancini F, Mutter D, Peix JL, et al. Experience with adrenalectomy in 1997. Apropos of 247 cases: a multicenter prospective study of the French-speaking Association of Endocrine Surgery. *Chirurgie* 1999; 124:368–374.
27. Shichman SJ, Herndon CD, Sosa RE, et al. Lateral transperitoneal laparoscopic adrenalectomy. *World J Urol* 1999; 17:48–53.
28. Winfield HN, Hamilton BD, Bravo EL, et al. Laparoscopic adrenalectomy: the preferred choice? A comparison to open adrenalectomy. *J Urol* 1998; 160:325–329.
29. Yoshimura K, Yoshioka T, Miyake O, et al. Comparison of clinical outcomes of laparoscopic and conventional open adrenalectomy. *J Endourol* 1998; 12:555–559.
30. Chee C, Ravinthiran T, Cheng C. Laparoscopic adrenalectomy: experience with transabdominal and retroperitoneal approaches. *Urology* 1998; 51:29–32.
31. Gagner M, Pomp A, Heniford BT, et al. Laparoscopic adrenalectomy: lessons learned from 100 consecutive procedures. *Ann Surg* 1997; 226:238–246.
32. Gasman D, Droupy S, Koutani A, et al. Laparoscopic adrenalectomy: the retroperitoneal approach. *J Urol* 1998; 159:1816–1820.
33. Terachi T, Matsuda T, Terai A, et al. Transperitoneal laparoscopic adrenalectomy: experience in 100 patients. *J Endourol* 1997; 11:361–365.
34. Rutherford JC, Stowasser M, Tunny TJ, et al. Laparoscopic adrenalectomy. *World J Surg* 1996; 20:758–760.
35. Schell SR, Talamimi MA, Udelsman R. Laparoscopic adrenalectomy for nonmalignant disease: improved safety, morbidity, and cost-effectiveness. *Surg Endosc* 1999; 13:30–34.
36. Vargas HI, Kavoussi LR, Bartlett DL, et al. Laparoscopic adrenalectomy: a new standard of care. *Urology* 1997; 49:673–678.
37. Bolli M, Oertli D, Staub J, et al. Laparoscopic adrenalectomy: the new standard? *Swiss Med Wkly* 2002; 132:12–16.
38. Hazzan D, Shiloni E, Golijanin D, et al. Laparoscopic vs open adrenalectomy for benign adrenal neoplasm. *Surg Endosc* 2001; 15:1356–1358.
39. MacGillivray DC, Schichman SJ, Ferrer FA, et al. A comparison of open vs laparoscopic adrenalectomy. *Surg Endosc* 1996; 10:987–990.
40. Miccoli P, Raffaelli M, Berti P, et al. Adrenal surgery before and after the introduction of laparoscopic adrenalectomy. *Br J Surg* 2002; 89:779–782.
41. Ortega J, Sala C, Garcia S, et al. Cost-effectiveness of laparoscopic vs open adrenalectomy: small savings in an expensive process. *J Laparoendosc Adv Surg Tech A* 2002; 12:1–5.

LAPAROSCOPIC SIMPLE NEPHRECTOMY: TECHNIQUE

Simon V. Bariol and David A. Tolley

Scottish Lithotripter Centre, Western General Hospital, Edinburgh, U.K.

■ INTRODUCTION	Stay Suture
■ PATIENT SELECTION	Fourth Trocar
Indications	Harmonic Scalpel
Contraindications	Maximizing Use of Endovascular
■ PREOPERATIVE PREPARATION	Stapler Device
Specific Investigations	Rolling the Patient
Upper Urinary Tract Drainage	Obese Patients
Bowel Preparation	Specimen Retrieval
Informed Consent	Ribbon Gauze
■ TECHNIQUE	■ COMPLICATIONS
Description	Intraoperative Complications
Technical Modifications	Postoperative Complications
■ POSTOPERATIVE CARE	Avoiding Complications
■ TECHNICAL TIPS	■ REFERENCES
Preoperative Upper Tract Drainage	■ BIBLIOGRAPHY

Laparoscopic nephrectomy for benign disease is now a simple procedure but may prove to be very challenging, depending on the indication for surgery.

INTRODUCTION

Laparoscopic nephrectomy for benign disease is now a simple procedure but may prove to be very challenging, depending on the indication for surgery.

Although most cases of benign disease can be managed by simple nephrectomy, inflammation or previous surgery, especially in the obese patient, may obliterate normal dissection planes, and radical ablative surgery in these circumstances may be more judicious. This chapter describes the technique of laparoscopic simple nephrectomy for benign disease in detail, including a number of practical tips designed to facilitate the procedure, based on the authors' experience of over 500 procedures.

PATIENT SELECTION

Indications

Laparoscopic simple nephrectomy is indicated in the management of benign renal disease associated with significant loss of function or that contributes to patient morbidity. This includes chronic pyelonephritis, obstructive nephropathy, renovascular hypertension, cystic disease (congenital or acquired), nonfunction due to stone disease and reflux nephropathy.

Contraindications

Untreated infection and coagulopathy are the only absolute contraindications to laparoscopic nephrectomy. Complication and conversion rates are highest in patients undergoing laparoscopic nephrectomy for severe inflammatory conditions of the kidney (e.g., xanthogranulomatous pyelonephritis, pyonephrosis) and should be regarded as relative contraindications for the inexperienced laparoscopist (1–4). Renal tuberculosis can be dealt with safely by laparoscopy, although operating times are longer compared with nephrectomy for other benign conditions (5). Obesity and previous abdominal surgery do not preclude a laparoscopic approach (6,7).

PREOPERATIVE PREPARATION

Specific Investigations

Preoperative evaluation includes full history and physical examination, routine blood tests, including group and save, and anesthetic assessment. It should be appreciated

that despite the many advantages of the laparoscopic approach to the patient, laparoscopic nephrectomy is a major procedure with significant mortality. Abdominal contrast computed tomography provides information regarding the size of the kidney and renal pelvis, the presence of stones or inflammation, vascular anatomy, and the state of the contralateral kidney. A nuclear renogram and diethylenetriaminepenta-acetic acid scan provides important functional information to determine whether ablative surgery is appropriate. Ultrasound performed immediately prior to surgery, to re-assess the size of the renal pelvis and renal movement with respiration (as a marker of perirenal fibrosis) may also be helpful.

Upper Urinary Tract Drainage

A grossly enlarged hydronephrotic kidney, especially in the presence of infection should be drained, either with stent or preferably nephrostomy tube placement, at least 4 weeks prior to ablative surgery. The resulting reduction in size facilitates dissection. A delay of at least six weeks in the infected kidney will permit much of the associated inflammation to settle, thus facilitating the dissection. Urine from the obstructed kidney, collected at the time of drainage, should be sent for culture, and antibiotics commenced as appropriate. Mid-stream specimen of urine test is unreliable as a predictor of upper urinary tract infection in the presence of upper urinary tract obstruction (8). Uncomplicated hydronephrosis may be drained with a ureteric catheter at the time of laparoscopic nephrectomy to decompress the kidney and facilitate ureteric identification (9), however this maneuver is not essential (10).

Bowel Preparation

This is not performed routinely for laparoscopic nephrectomy for benign diseases. If preoperative imaging is suggestive of xanthogranulomatous pyelonephritis, full bowel preparation is recommended in case bowel injury occurs or bowel resection is required.

Informed Consent

Patients must be warned of the (small) risk of conversion to open surgery, particularly those with inflammatory conditions in which the risk is even greater. The kidney to be removed should be confirmed with the patient, and the patient is marked with indelible ink. Side should be indicated clearly on the operating list and the patient's consent form.

TECHNIQUE

Description

Anesthetic Considerations

Laparoscopic nephrectomy requires general anesthesia with muscle relaxation and endotracheal intubation (Table 1).

Patient Positioning

An indwelling urethral catheter is inserted. The patient is placed in a modified lateral decubitus position with the umbilicus over the break of the operating table. The table is flexed as required. Lumbar and thoracic supports with padding are placed behind the patient to secure the position. The arm on the ipsilateral side is flexed with the shoulder at 90° to the chest in an armrest, with padding over bony prominences; the contralateral arm is similarly flexed and protected (Fig. 1). A peripheral warming blanket is applied.

After the patient's skin is prepared and draped, the surgeon and scrub nurse stand facing the patient. The camera stack is moved to a comfortable position directly opposite the surgeon, and the assistant sits to the side of the operator.

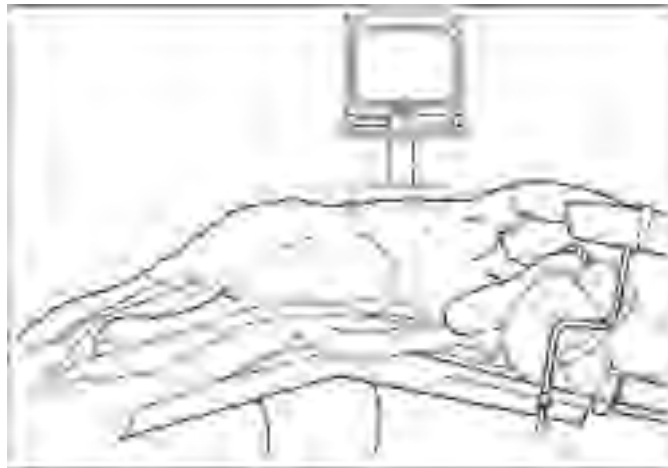Insufflation and Trocar Placement

The first port is placed at the lateral edge of the rectus muscle, between the level of the umbilicus and the transpyloric plane (which lies approximately half-way between the xiphisternum and umbilicus, Fig. 2). The peritoneum is entered under vision with sharp and blunt dissection. In patients with a history of previous abdominal surgery, particular care should be taken when opening the peritoneum, and the surgeon should introduce their index finger into the peritoneal cavity to sweep any abdominal wall adhesions prior to introducing the trocar.

CO₂ insufflation is commenced at low flow (less than 2 L/min) after introducing a blunt (Hasson) 12 mm trochar. The intraabdominal pressure should be no more than

TABLE 1 ■ Technique of Laparoscopic Simple Nephrectomy

Anesthetic	General anesthesia with muscular relaxation and endotracheal intubation
Patient positioning	Modified lateral decubitus position with umbilicus over break of operating table
Insufflation and trocar placement	Hasson or Veress needle technique; three to four trocars in triangle or diamond formation, secured with silk sutures
Initial assessment	Visual inspection of the upper abdomen and division of adhesions
Initial dissection	Colon mobilized medially by incising its lateral attachment
Identification of the lower pole	Lower pole elevated while dividing medial tissue advancing in the direction of the pedicle
Pedicle control	Elevate lower pole; blunt dissection using right-angled forceps and the sucker-irrigator tip; avoid excessive use of clips close to main vein; artery clipped with laparoscopic clips and divided, followed by ligation and division of the vein using Endo-GIA
Mobilization of the upper pole	Dissection continued close to the kidney avoiding hilum; combination of sharp and blunt dissection; consider using clips, harmonic scalpel or endo-GIA for perforating vessels
Ureteric division	Ligated with Liga clips and divided; final step before specimen retrieval
Specimen retrieval	Kidney grasped with heavy laparoscopic forceps; inspection for hemostasis; kidney removed in laparoscopic catchment bag in tact or after morcellation
Wound closure	Consider drain; retrieval site closed in two layers using continuous 0 PDS; 12 mm port sites closed with 0 Vicryl on a J needle; skin closed with clips or subcuticular suture

FIGURE 1 ■ Patient position for laparoscopic simple nephrectomy.

4 or 5 mmHg at this stage. A sudden increase in pressure during initial insufflation signals incorrect trocar placement. In this situation, insufflation is stopped and the reason for the problem identified. After insufflation of 1 to 1.5 L of gas, flow can be increased to a high rate (approximately 6 L/min) and intraabdominal pressure maintained at 12 to 15 mmHg. Rapid initial insufflation occasionally results in a severe bradycardia.

For right nephrectomy, two other main ports are inserted under laparoscopic control: a 5- to 12-mm port inferior to the costal margin and a 5-mm port at the level of the umbilicus, both in the anterior axillary line and roughly equidistant from the camera port; so the three ports form an isosceles triangle. For left nephrectomy, the 5- and 12-mm ports are reversed in position so that the larger port is always on the surgeon's right. This is to permit passage of 10-mm clip appliers and linear cutting/stapling devices. A fourth 5- to 12-mm port, if required for retraction, may be inserted in a lateral position, in line with the camera port near the tip of the 12th rib (Fig. 3). The trocars are secured using silk sutures through the skin.

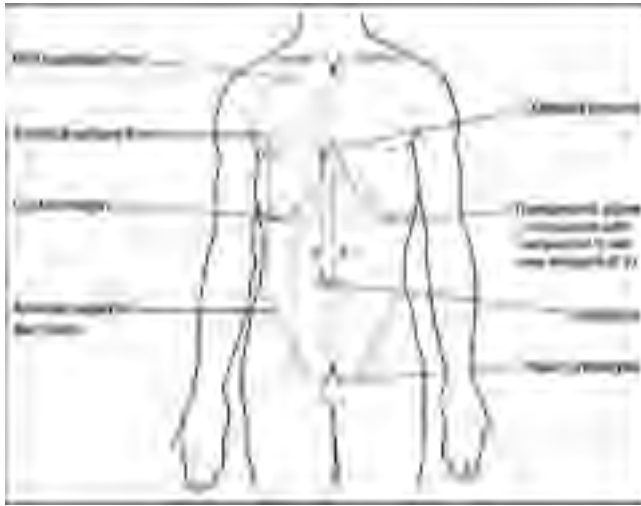


FIGURE 2 ■ Surface anatomy.

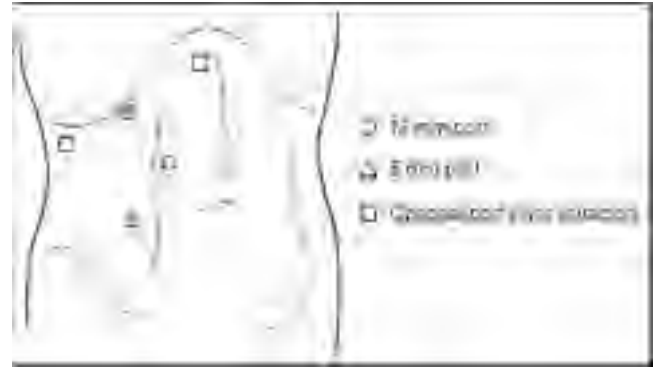


FIGURE 3 ■ Transperitoneal laparoscopic nephrectomy trocar placement.

Initial Assessment

Visual inspection of the upper abdomen is performed, and any adhesions are divided. Dissection is performed using laparoscopic scissors or the ultrasonic scalpel. The kidney is then identified, lying in the retroperitoneum behind the colon.

Initial Dissection

The colon is mobilized medially 4 to 5 cm below the lower pole by incising its lateral attachment; on the left side this corresponds with the white line of Toldt. Care should be taken during this mobilization: maintaining a safe distance from the colon to prevent diathermy injury and preserving the colonic mesentery. The different appearance of the fat associated with colonic mesentery (dark yellow/orange) and Gerota's fascia (pale yellow) is a useful guide to determining the correct plane. The mobilization should be carried caudally to expose the lower pole of the kidney. On the left side, mobilization should be extended cranially, sufficient to allow the spleen and tail of pancreas to fall medially and expose the hilum. On the right side, the colon should be mobilized above the hepatic flexure and the right triangular ligament incised. The duodenum, which lies immediately deep to the hepatic flexure, should also be mobilized medially.

Identification of the Lower Pole

After mobilization of the colon, Gerota's fascia is seen covering the renal outline. Using sharp and blunt dissection through Gerota's fascia in a craniocaudal direction, the lower pole is identified overlying the psoas muscle. The left-hand instrument is used to retract the lower pole in a lateral direction (that is, toward the abdominal wall), thus stretching the overlying tissue that is then divided by the right-hand instrument while advancing in the direction of the pedicle. A large window is opened up between the lower pole, psoas, and the kidney's medial attachments.

Occasionally, the surgeon encounters severe perinephric inflammatory reaction. In this case, the plane outside Gerota's fascia is often the better plane of dissection, and a radical excision may be the safest and easiest procedure, irrespective of the nature of the pathology.

Pedicle Control

Elevation of the lower pole of the kidney places the renal vessels "on the stretch" and facilitates identification (Fig. 4). Blunt dissection of the vessels using right-angled forceps and/or the sucker-irrigator tip is performed. The renal vein, lying more anterior, is normally identified first. On the left side, the renal vein may receive gonadal, adrenal, and lumbar branches that may require individual clipping.

The preoperative computed tomography scan may provide clues as to the position of the renal artery in relation to the vein; otherwise, further blunt dissection cranial, caudal, and deep to the vein, while observing for arterial pulsation, will clarify the vascular anatomy. The artery is clipped with laparoscopic clips (three on the "stay" side and two on the "go" side) and divided; this is followed by division of the renal vein

using an endovascular gastrointestinal anastomosis stapler, which fires four rows of clips before cutting the vein. It is important to ensure that the path of the stapling device is clear of any clips, because their inadvertent inclusion in the closed jaws of the instrument will result in a misfire of the linear cutting/stapling device.

Arterial division may occasionally be postponed until after division of the vein if necessary, although the authors strongly recommend that this is a maneuver of last resort because it may result in considerable swelling of the renal vein and oozing from the hilum, which can hamper dissection. A far safer approach when space is limited is to place a single clip on the artery first and to complete its dissection once the vein has been divided.

In general, dissection of the renal artery and vein medially, as close to the great vessels as possible, is simpler because lateral dissection close to the hilum will result in more bleeding, and dissection of the branches of the renal artery and tributaries of the renal vein is also more likely.

Mobilization of the Upper Pole

After ligation of the renal artery and vein, dissection is carried along the medial aspect of the kidney, maintaining a safe distance from the renal hilum. At the upper pole, the anterior layer of Gerota's fascia is entered and dissection continued close to the kidney to preserve the adrenal gland. The upper pole can be dissected using a combination of sharp and blunt dissection. The use of clips, harmonic scalpel, or endo-gastrointestinal anastomosis is encouraged, as capsular vessels are common at the upper pole. Dissection is then carried to the lateral aspect of the kidney, where blunt dissection is usually sufficient to free the kidney of all attachments except for the ureter.

Ureteric Division

The ureter is now identified, clipped, and divided. If a stent was placed preoperatively, the ureter is first incised longitudinally and the stent removed with right-angled graspers via the 5- to 12-mm port, prior to clipping and division. Division of the ureter should be the final step before specimen retrieval, because the relatively fixed position of the ureter allows it to be used as an anchor, which prevents rotation of the kidney during the final stages of the dissection. This significantly reduces operating time.

Specimen Retrieval

The kidney is grasped with heavy laparoscopic forceps (Babcock forceps introduced through the fourth port, if present, are ideal). The specimen is held away from the renal bed, which is then inspected for bleeding. This inspection should always be performed at low intra-abdominal pressure, to ensure that venous bleeding is not masked. Swabbing the renal bed with a gauze roll (mastoid swab) will demonstrate any small vessels that require control. The pneumoperitoneum is reestablished, and a laparoscopic entrapment bag is inserted through the inferior port and the specimen carefully placed within it. The bag is withdrawn and the specimen removed by extending the trocar site or morcellation.

Wound Closure

A drain should be placed if there is concern about excessive ooze following extensive dissection for removal of a large kidney or if leakage of potentially infected material from the specimen has occurred. The extended trocar site is closed in two layers using continuous 0 Polydioxone, while the other 12-mm port sites can be closed with 0 Vicryl on a J needle. Five-millimeter port sites do not need muscle closure, nor do those placed on the costal margin. Skin is closed with clips or subcuticular suture, and local anesthetic (bupivacaine 0.5%) is injected into the port sites.

Technical Modifications

Veress needle insufflation is the preferred technique for establishing pneumoperitoneum in some institutions, with the Hasson technique reserved for difficult cases. Blind trocar insertion following this method of insufflation carries an increased risk of bowel or vascular injury that does not occur when all trocars are introduced under vision. The needle is inserted level with the umbilicus and lateral to the rectus muscle. Intra-abdominal pressure is increased to 20 mmHg prior to initial trocar placement and then maintained at 8 to 15 mmHg for the duration of the operation.

The retroperitoneal laparoscopic approach to nephrectomy, for benign and malignant conditions, is widely practiced. Hsu et al. (6) described the Cleveland Clinic

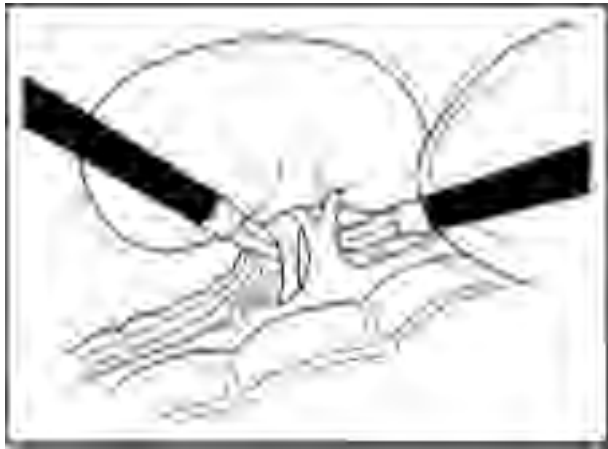

FIGURE 4 ■ Elevation of lower pole of kidney.




FIGURE 5 ■ Retroperitoneoscopic nephrectomy trocar placement.

technique in detail. The major technical considerations are (i) retroperitoneal access by an open method at the tip of the 12th rib, gently piercing the anterior thoracolumbar fascia with finger tip or artery forceps after blunt dissection through the flank muscles; (ii) balloon dilation of the retroperitoneum using a trocar-mounted balloon device, which displaces the kidney anteromedially and facilitates identification of the renal artery; (iii) secondary port placement under laparoscopic or bimanual control, so that the three trocar sites are placed along the line of a conventional subcostal incision (Fig. 5); (iv) identification and control of the renal artery and vein; (v) kidney mobilization including clipping and division of the ureter; (vi) entrapment and piecemeal removal. Retroperitoneoscopy offers a number of advantages, avoiding adhesions in patients who have had previous abdominal surgery, and reducing the risk of bowel injury. On the other hand, operating in the more confined space of the retroperitoneum is a disadvantage, and orientation may be difficult.

Hand-assisted laparoscopic nephrectomy involves introducing the surgeon's or assistant's hand into the insufflated abdomen. It appears to have few advantages over standard or "pure" laparoscopy, but some authors claim safer retraction, reduced operating times, and a shorter learning curve. The incision required is larger than that for a wholly laparoscopic approach with morcellation of the kidney but smaller than that necessary for conventional open surgery. The technique may simplify the laparoscopic approach to chronically inflamed or scarred kidneys and shorten operating time (11,12) but is more suited to those patients in whom a larger incision is necessary, especially those undergoing donor nephrectomy.

Mass ligation of the renal artery and vein with the endo-gastrointestinal anastomosis has been described for use in patients with severe perinephric reaction, to avoid the risk of vascular injury when dissecting between renal artery and vein. Although there is a theoretical risk of fistula creation, this has not so far been observed (13).

POSTOPERATIVE CARE

Patients receive patient-controlled analgesia, which can usually be discontinued on the first postoperative day, when the catheter is also removed. Diet is progressed as tolerated, and the patients can mobilize without restriction. Heavy lifting is avoided for six weeks to allow muscular healing.

TECHNICAL TIPS

Preoperative Upper Tract Drainage

Patients with a grossly dilated collecting system are best served by a minimum four-week period of drainage prior to nephrectomy. Occasionally this is necessary to check function following relief of obstruction, before recommending ablative surgery over reconstruction, but it is certainly of benefit from a technical point of view because a tense, grossly dilated pelvis may otherwise overlap the renal vessels and make their identification and control more difficult.

Stay Suture

A stay suture inserted through the abdominal wall and into the pelvis, to support it and identify those structures deep to it, is also helpful in a patient with a grossly hydronephrotic kidney. A similar technique can be used to display the ureter.

Fourth Trocar

The use of an extra port for retraction purposes is encouraged. This decision should be made early at the first sign that additional organ retraction is likely to be needed. This trocar may be inserted near the tip of the 12th rib (a 5 to 12 mm port), when operating on either side, or below the xiphoid (5 mm port) for hepatic retraction using a ratcheted grasper.

Harmonic Scalpel

This reduces bleeding during colonic reflection and mobilization of the kidney and facilitates dissection of inflammatory tissue. It can be used in close proximity to bowel and large vessels without risk of thermal injury.

Maximizing Use of Endovascular Stapler Device

The stiffness of laparoscopic endovascular staplers makes them very useful instruments for blunt dissection of the lateral attachments, after division of the pedicle and upper pole mobilization. Using a craniocaudal sweeping motion, and with the instrument closed, the kidney can be mobilized free of its lateral attachments very quickly.

Rolling the Patient

With the patient secured by lumbar and thoracic supports or surgical tape, the operating table may be tilted toward or away from the surgeon to facilitate exposure, in case the colon or adjacent organs fall into the operative field.

Obese Patients

Trocars should be positioned more laterally than usual. Consider using long trocars, and a purse string suture of the rectus sheath to facilitate closure at the end of the procedure.

Specimen Retrieval

This can be a surprisingly awkward step in the procedure, particularly when a larger catchment bag is used. Using a heavy grasping instrument (e.g., laparoscopic Babcock forceps, endo-gastrointestinal anastomosis) greatly improves the chances of success. The use of a Terumo guide wire to facilitate kidney entrapment when using the Lap Sac^{®a}, keeping the sac mouth stiff and open, has also been described (14).

Ribbon Gauze

Intracorporeal ribbon gauze strips can be used for temporary hemostatic control to absorb any blood or clot and to facilitate blunt dissection (15).

COMPLICATIONS**Intraoperative Complications**

The major intraoperative complications are bleeding (usually from the renal vein, adrenal vein, or accessory branches), visceral injury (spleen, liver, bowel, or omentum), and vascular injury (superior mesenteric artery, aorta, and inferior vena cava) (16–18). While these occur uncommonly, they can cause serious morbidity or death. Rapid conversion may be necessary, although the experienced laparoscopist may be able to deal with bleeding from the renal and adrenal vein by judicious use of compression and retraction. There are reports of the linear cutting/stapling device failing to fire. This almost inevitably necessitates rapid conversion, but if the device can be rapidly closed and maintained in position, it may be possible to insert a second device medial to the first through an extra port placed just medial to the one carrying the failed device.

Open conversion rates vary between institutions, ranging from 0% to 16% (3,11,19,20), however this is affected by the indication for surgery and surgical experience.

^aCook Surgical, Spencer, IN.

In an analysis of factors, which predict the outcome of the laparoscopic approach, positive urine culture and renographic clearance (more than 10 mL/min) were found to increase the likelihood of conversion of both trans- and retroperitoneal laparoscopic nephrectomy for benign disease. In addition, learning curve and large kidney size were risk factors for conversion for trans- and retroperitoneal approaches, respectively (21). Conversion rates are also higher for inflammatory conditions (2–4).

Postoperative Complications

Major complications are unusual following laparoscopic nephrectomy but can occur particularly in patients with severe inflammation of the kidney and surrounding tissue. These include hematoma, intra-abdominal abscess, pulmonary embolus, pneumothorax, wound infection, and incisional hernia (20,22). Diathermy or dissection injury to the bowel may cause delayed abdominal signs due to a perforated viscus.

Avoiding Complications

As with all laparoscopic procedures, meticulous attention to detail and observation of surgical landmarks, particularly the major vessels and colon, should avoid most dangerous complications. However a few specific recommendations for avoiding complications in laparoscopic simple nephrectomy can be made.

Avoid the Hilum

There is a tendency to dissect close to the kidney when radical extirpation is not required. However renal vascular anatomy is far less complicated closer to the great vessels, and so it is more judicious to dissect and ligate them away from the renal hilum. Entering the hilum risks having to ligate and divide multiple vessels, and increases the risk of injury and conversion due to suboptimal control of bleeding.

Caution with Diathermy

Awareness of bowel position when using electrocautery within the peritoneal space avoids potential bowel necrosis, which can lead to immediate or delayed bowel perforation. The colon and duodenum are at particular risk due to their close proximity to the kidney. The use of disposable, nonmetallic trocars and bipolar diathermy will also minimize the risk of diathermy injury.

Renal Vein Control

The excessive use of clips to divide the gonadal or adrenal vessels close to the main vein should be avoided, because they can disrupt the firing mechanism of the endovascular gastrointestinal anastomosis stapler and cause it to fail, resulting in catastrophic bleeding. If the endovascular stapler fails to fire, placement of a second device proximal to the first while it is still closed may avoid the necessity of conversion.

Organ Retraction

Special purpose organ retractors (e.g., Fan retractor) are less likely to cause solid visceral injury, but should still be used with care. Alternatively, intracorporeal ribbon gauze can be used to prevent forceps trauma to solid organs (15).

Do Not Morcellate Infected Kidneys

Infected kidneys, secondary to obstruction or infected cysts, may contaminate the trocar site through which they are retrieved causing wound infection. As such we recommend removing them intact within a laparoscopic catchment bag.

REFERENCES

1. Capelouto CC, Kavoussi LR. Complications of laparoscopic surgery. *Urology* 1993; 42:2–12.
2. Bercowsky E, Shalhav AL, Portis A, Eibahnasy AM, McDougall EM, Clayman RV. Is the laparoscopic approach justified in patients with xanthogranulomatous pyelonephritis? *Urology* 1999; 54:437–442.
3. Keeley FX, Tolley DA. A review of our first 100 cases of laparoscopic nephrectomy: defining risk factors for complications. *Br J Urol* 1998; 82:615–618.
4. Shekarriz B, Meng MV, Lu H-F, Yamada H, Duh Q-Y, Stoller ML. Laparoscopic nephrectomy for inflammatory renal conditions. *J Urol* 2001; 166:2091–2094.
5. Lee K-S, Kim HH, Byun S-S, Kwak C, Park K, Ahn H. Laparoscopic nephrectomy for tuberculous nonfunctioning kidney: comparison with laparoscopic simple nephrectomy for other diseases. *Urology* 2002; 60:411–414.
6. Hsu THS, Sung GT, Gill IS. Retroperitoneoscopic approach to nephrectomy. *J Endourol* 1999; 13:713–720.

7. Parsons JK, Jarrett TJ, Chow GK, Kavoussi LR. The effect of previous abdominal surgery on urological laparoscopy. *J Urol* 2002; 168:2387–2390.
8. Mariappan P, Loong CW. Midstream urine culture and sensitivity test is a poor predictor of infected urine proximal to the obstructing ureteral stone or infected stones: a prospective clinical study. *J Urol* 2004; 171: 2142–2145.
9. Ono Y, Katoh N, Kinukawa T, Matsuura O, Ohshima S. Laparoscopic nephrectomy via the retroperitoneal approach. *J Urol* 1996; 156:1101–1104.
10. Hemal AK, Wadhwa SN, Kumar M, Gupta NP. Transperitoneal and retroperitoneal laparoscopic nephrectomy for giant hydronephrosis. *J Urol* 1999; 162:35–39.
11. Wolf JR, Moon TD, Nakada SY. Hand assisted laparoscopic nephrectomy: comparison to standard laparoscopic nephrectomy. *J Urol* 1998; 160:22–27.
12. Anderson KR. Simple nephrectomy: managing the difficult case: xanthogranulomatous pyelonephritis and autosomal dominant polycystic kidney disease. *J Endourol* 2000; 14:799–803.
13. Eraky I. Editorial: Simple nephrectomy: transperitoneal approach (Kumar U, Albala D.). *J Endourol* 2000; 14:785–786 (779–786). Or Eraky paper 1994 *J Endosc*.
14. Sundaram CP, Ono Y, Landman J, Rehman J, Clayman R. Hydrophilic guide wire technique to facilitate organ entrapment using a laparoscopic sac during laparoscopy. *J Urol* 2002; 165:1376–1377.
15. Bariol SV, Heng CT, Lau HM. Intracorporeal ribbon gauze in laparoscopic surgery. *ANZ J Surg* 2004; 74:68.
16. Siqueira TM, Kuo RL, Gardner TA, et al. Major complications in 213 laparoscopic nephrectomy cases: the Indianapolis experience. *J Urol* 2002; 168:1361–1365.
17. Simon SD, Castle EP, Ferrigni RG, et al. Complications of laparoscopic nephrectomy: the Mayo Clinic experience. *J Urol* 2004; 171:1447–1450.
18. Gill IS, Kavoussi LR, Clayman RV, et al. Complications of laparoscopic nephrectomy in 185 patients: a multi-institutional review. *J Urol* 1995; 154:479–483.
19. Gaur DD. Laparoscopic operative retroperitoneoscopy: use of a new device. *J Urol* 1992; 148:1137.
20. Rassweiler J, Fornara P, Weber M, et al. Laparoscopic nephrectomy: the experience of the Laparoscopic Working Group of the German Urologic Association. *J Urol* 1998; 160:18–21.
21. Shoma AM, Eraky I, El-Kappany H. Laparoscopic nephrectomy: prediction of outcome in relation to the preoperative risk factors in two approaches. *J Endourol* 2001; 15:517–523.
22. Parsons JK, Varkarakis I, Rha KH, Jarrett TW, Pinto PA, Kavoussi LR. Complications of abdominal urologic laparoscopy: longitudinal five-year analysis. *Urology* 2004; 63:27–32.

BIBLIOGRAPHY

- Anderson KR. Simple nephrectomy: managing the difficult case: xanthogranulomatous pyelonephritis and autosomal dominant polycystic kidney disease. *J Endourol* 2000; 14:799–803.
- Bercowsky E, Shalhav AL, Portis A, Elbahnasy AM, McDougall EM, Clayman RV. Is the laparoscopic approach justified in patients with xanthogranulomatous pyelonephritis? *Urology* 1999; 54:437–442.
- Clayman RV, Kavoussi LR, Soper NJ, et al. Laparoscopic nephrectomy: initial case report. *J Urol* 1991; 146:278.
- Hsu THS, Sung GT, Gill IS. Retroperitoneoscopic approach to nephrectomy. *J Endourol* 1999; 13:713–720.
- Keeley FX, Tolley DA. A review of our first 100 cases of laparoscopic nephrectomy: defining risk factors for complications. *Br J Urol* 1998; 82:615–618.
- Kerbl K, Clayman RV, McDougall EM, et al. Transperitoneal nephrectomy for benign disease of the kidney: a comparison of laparoscopic and open surgical techniques. *Urology* 1994; 43:607–613.
- Nakada SY, Moon TD, Gist M, et al. Use of the Pneumo Sleeve as an adjunct in laparoscopic nephrectomy. *Urology* 1997; 49:612–613.
- Rassweiler J, Fornara P, Weber M, et al. Laparoscopic nephrectomy: the experience of the Laparoscopic Working Group of the German Urologic Association. *J Urol* 1998; 160:18–21.
- Shekarri B, Meng MV, Lu H-F, Yamada H, Duh Q-Y, Stoller ML. Laparoscopic nephrectomy for inflammatory renal conditions. *J Urol* 2001; 166:2091–2094.
- Siqueira TM, Kuo RL, Gardner TA, et al. Major complications in 213 laparoscopic nephrectomy cases: the Indianapolis experience. *J Urol* 2002; 168:1361–1365.

LAPAROSCOPIC SIMPLE NEPHRECTOMY: CURRENT STATUS

Moses Kim

Scott Department of Urology, Baylor College of Medicine, Houston, Texas, U.S.A.

Debora K. Moore and Robert G. Moore

*Minimally Invasive Urology of the Southwest, Las Palmas Medical Center,
El Paso, Texas, U.S.A.*

- INTRODUCTION
- INDICATIONS
- SPECIAL CONSIDERATIONS
 - Previous Procedures
 - Obesity
 - Renal Units with Chronic Infection

- Xanthogranulomatous Pyelonephritis
- Tuberculosis
- Autosomal Dominant Polycystic Kidney Disease
- SUMMARY
- REFERENCES

INTRODUCTION

Today laparoscopy has become the standard of care for most patients requiring a simple nephrectomy.

Laparoscopic nephrectomy, since first performed by Clayman, has been shown to have various advantages over open nephrectomy (1). These advantages include decreased post-operative pain medication requirement, shorter hospital stay, quicker convalescence time, and potentially lower complication rates (2–6). More recently, laparoscopic approaches have been successfully employed to manage more complex cases such as xanthogranulomatous pyelonephritis and autosomal dominant polycystic kidney disease.

Today laparoscopy has become the standard of care for most patients requiring a simple nephrectomy.

INDICATIONS

Laparoscopic simple nephrectomy is indicated in benign renal diseases where complete loss of the renal unit has occurred or is desired.

Laparoscopic simple nephrectomy is indicated in benign renal diseases where complete loss of the renal unit has occurred or is desired. Such conditions include but are not limited to:

- Renovascular hypertension,
- Obstructive or reflux nephropathy,
- Chronic inflammatory/infection conditions including xanthogranulomatous and tuberculosis pyelonephritis (these are technically challenging),
- Symptomatic ADPKD, and
- Posttransplantation hypertension.

Simple nephrectomy is most commonly performed for symptomatic (pain, hypertension, and infections) and nonfunctioning renal units. The etiology of functional loss may be due to calculi, obstructive nephropathy, reflux nephropathy, polycystic kidney, pyelonephritis, and others. Laparoscopic nephrectomy for benign conditions has gained wide acceptance and has become the standard of care in many institutions.

Benefits of laparoscopic simple nephrectomy over open nephrectomy include decreased need for pain medication, shorter hospital stay, and quicker convalescence time (2–6).

Complication rates are equivalent or, as some reports suggest, less than the rates commonly associated with open nephrectomy.

Gill et al. reviewed 185 cases of laparoscopic nephrectomy from five centers (7). Overall, 83% of cases were performed for a benign cause. Complication rate was 16% and conversion rate was 5.4%. Fornara et al. reported a retrospective single center study of 249 patients; open simple nephrectomy was performed in 118 patients and laparoscopic

Benefits of laparoscopic simple nephrectomy over open nephrectomy include decreased need for pain medication, shorter hospital stay, and quicker convalescence time. Complication rates are equivalent or, as some reports suggest, less than the rates commonly associated with open nephrectomy.

simple nephrectomy in 131 patients (3). The laparoscopic group experienced decreased pain medication requirement (12 mg vs. 20 mg morphine), shorter hospital stays (4 days vs. 10 days), and shorter time to convalescence (24 days vs. 36 days). Complication rate was 20.6% for the laparoscopic group and 25.4% for the open group, respectively. Open conversion rate during laparoscopy was 6.1%. In another comparison study in which 92 patients underwent open nephrectomy and 92 underwent laparoscopic nephrectomy, the laparoscopic group had shorter hospital stay (3.9 days vs. 5.9 days), shorter time to convalescence (12 days vs. 33 days), and lower complication rates (13% vs. 31%) (5). Open conversion rate during laparoscopic nephrectomy was 0.8%. Other studies have supported these findings (2,4,6).

SPECIAL CONSIDERATIONS

Previous Procedures

Care must be taken when approaching patients who have undergone prior abdominal surgeries. Veress needle placement should be as far from the previous incision site as possible.

Care must be taken when approaching patients who have undergone prior abdominal surgeries. These patients may have postsurgical adhesions, which increase the risk of bowel injury during Veress needle insertion, trocar placement, and dissection. In addition, the fibrosis secondary to prior surgery can make dissection more challenging. Veress needle placement should be as far from the previous incision site as possible.

In a series of 700 laparoscopic urologic procedures from a single center, comparison between patients with previous abdominal surgery (48%) and those with none (52%) revealed higher complication rates (9.4% vs. 4.8%) and higher open conversion rates (7.5% vs. 1.2%) in the previously operated patients. However, the differences were not statistically significant. The patients with prior surgery also had higher transfusion rates and slightly longer hospital stays, most likely due to higher medical comorbidity in this group (8).

Seifman et al. reported on 190 patients, of whom 40% had undergone previous abdominal surgery. The authors found that the group with prior abdominal surgery was associated with longer hospital stay (3.8 days vs. 2.6 days) and higher complication rates (16% vs. 5%). Specifically they reported that an upper midline and ipsilateral upper-quadrant scar were associated with a higher incidence of access complication (12% vs. 0%) (9).

In patients with a history of prior open abdominal surgery, an open Hassn trocar placement or a retroperitoneal approach should be considered (10).

In patients with a history of prior open abdominal surgery, an open Hassn trocar placement or a retroperitoneal approach should be considered.

Obesity

Obesity is not a contraindication for laparoscopic nephrectomy. Laparoscopic nephrectomy is both feasible and efficacious in the obese patient.

Obesity was initially believed to be a relative contraindication to laparoscopic surgery. An early multicenter series of 125 patients with a body mass index > 30 undergoing various laparoscopic procedures, including 14 laparoscopic nephrectomies, documented a complication rate of 22% intraoperatively and 26% postoperatively (11). With increased laparoscopic operative experience, more recent studies have shown otherwise (12). In a retrospective single center study involving 69 nonobese and 32 obese (body mass index > 30) patients undergoing laparoscopic nephrectomy, Fugita et al. reported equivalent operative times, complication rates, conversion rates, and postoperative recovery course (12). In another study involving 40 patients undergoing laparoscopic donor nephrectomy, outcomes and complication rates were similar between obese and nonobese patients (13).

Obesity is not a contraindication for laparoscopic nephrectomy. Laparoscopic nephrectomy is both feasible and efficacious in the obese patient.

Increased adipose tissue can make laparoscopic visualization more challenging. The increased distance to the kidney often necessitates the use of longer operative instruments and appropriate adjustments to trocar configuration.

Recommendations for operating upon obese patients include the use of higher insufflation pressures (20 mmHg) and repositioning of the midline trocars lateral to the rectus to improve visualization and dissection. The retroperitoneal laparoscopic approach for nephrectomy is particularly advantageous in the obese patient because of avoidance of pannus and direct access to the renal hilum.

Recommendations for operating upon obese patients include the use of higher insufflation pressures (20 mmHg) and repositioning of the midline trocars lateral to the rectus to improve visualization and dissection. The retroperitoneal laparoscopic approach for nephrectomy is particularly advantageous in the obese patient because of avoidance of pannus and direct access to the renal hilum.

Renal Units with Chronic Infection

Infectious conditions of the kidney provide significant challenges to laparoscopy. The inflammation causes the development of dense perinephric fibrosis around the kidney, with the possible involvement of the perihilar region. In such situations, a transperitoneal approach has been advocated over the retroperitoneal approach.

Open conversion should be strongly considered if the perirenal fibrosis is dense and the dissection during laparoscopic nephrectomy is particularly challenging and not progressing.

The transperitoneal approach provides better exposure and larger working space for this potentially difficult dissection. One study evaluated laparoscopic nephrectomy in 12 patients with inflammatory renal conditions, including chronic inflammation/fibrosis (eight), xanthogranulomatous pyelonephritis (three), and tuberculosis (one) (14). Outcomes were compared to those of nine patients undergoing laparoscopic nephrectomy for noninflammatory conditions. Operative time was longer (284 minutes vs. 226 minutes) and conversion rate was higher (16% vs. 0%).

Open conversion should be strongly considered if the perirenal fibrosis is dense and the dissection during laparoscopic nephrectomy is particularly challenging and not progressing.

Xanthogranulomatous Pyelonephritis

Xanthogranulomatous pyelonephritis is an atypical form of chronic renal infection, usually associated with obstructive nephrolithiasis. *Proteus* and *Escherichia coli* are the most common organisms isolated from these kidneys. Lysis of tissue and phagocytosis of lipid material by histiocytes result in sheets of lipid-laden macrophages (xanthoma). Treatment traditionally involves open nephrectomy due to the dense fibrosis/inflammatory process involving the affected renal unit, the surrounding perinephric structures, and occasionally the adjacent organs. Nevertheless, several cases of laparoscopic nephrectomy have been performed in such patients, e.g., nine cases (five laparoscopic, four open) reported by Bercowsky et al. Two patients, of whom one was converted open, were approached retroperitoneally, and three transperitoneally (15). Mean operative time was 360 minutes compared to 154 minutes for the open procedure, while hospital stay (6 days vs. 5.7 days) was similar. Complications occurred in three patients in the laparoscopic group, including ileus (1), ileus and a pulmonary embolism (1), and an open conversion (1). In another study of three cases of laparoscopic transperitoneal nephrectomy for xanthogranulomatous pyelonephritis, mean operative time was 213 minutes and open conversion was necessary in one patient (14).

Laparoscopic nephrectomy for xanthogranulomatous pyelonephritis is feasible. The scant available data suggest longer operative times and no clear advantage over open nephrectomy. Laparoscopic simple nephrectomy in xanthogranulomatous pyelonephritis cases should only be attempted by the very experienced laparoscopist.

Laparoscopic nephrectomy for xanthogranulomatous pyelonephritis is feasible. The scant available data suggest longer operative times and no clear advantage over open nephrectomy. Laparoscopic simple nephrectomy in xanthogranulomatous pyelonephritis cases should only be attempted by the very experienced laparoscopist.

Tuberculosis

Tuberculosis of the kidney is usually caused by hematogenously spread organisms. Initial treatment involves antituberculous drugs such as isoniazid, rifampin, pyrazinamide, and ethambutol. Nephrectomy is indicated in cases of nonfunctioning kidneys, with extensive disease involving the entire kidney, causing hypertension, uretero pelvic junction obstruction, or coexisting renal carcinoma. Lee et al. reported the largest series of laparoscopic nephrectomy for tuberculosis of the kidney (16). Outcomes of laparoscopic nephrectomy in 31 patients with nonfunctioning kidney secondary to tuberculosis were compared to those of 45 patients who underwent laparoscopic nephrectomy for other benign causes. In the tuberculosis group, 10 were performed using the transperitoneal approach and 21 via the retroperitoneal approach. On comparing the tuberculosis group and the nontubercular group, no difference was noted as regards operative time (206 minutes vs. 200 minutes), length of hospital stay (5.3 days vs. 5.7 days), and complication rates (13% vs. 7%). There was one open conversion in the tuberculosis group.

Laparoscopic nephrectomy for tuberculosis is safe and, with sufficient laparoscopic experience, appears to provide the same benefits as for other benign noninflammatory conditions.

Laparoscopic nephrectomy for tuberculosis is safe and, with sufficient laparoscopic experience, appears to provide the same benefits as for other benign noninflammatory conditions.

Autosomal Dominant Polycystic Kidney Disease

Autosomal dominant polycystic kidney disease, an inherited form of polycystic disease with nearly 100% penetrance, ultimately leads to renal failure requiring dialysis. The identified genes for polycystic kidney disease (*PKD1*) reside on the short arm of chromosome 16, which accounts for 85% to 90% of cases (17), and for *PKD2* on chromosome 4, which accounts for 5% to 10% of cases (18). Patients also have increased incidence of intracranial hemorrhages and hepatic and pancreatic cysts.

Patients may develop hypertension, back and flank pain, infection, intracystic hemorrhage, and malignancy. Laparoscopic cyst decortication has been shown to improve pain and hypertension with no compromise of renal function (19). Simple nephrectomy may provide dramatic relief to symptomatic patients with preexisting end-stage renal disease.

These patients generally have giant kidneys, which add unique challenges to the minimally invasive surgeon. Outcomes in 11 such patients undergoing laparoscopic nephrectomy showed a mean operative time of 6.3 hours, average hospital stay of three days, and convalescence time of five weeks (20). All patients had resolution of the preoperative pain at a mean follow-up of 31 months. In a comparison between 10 consecutive patients who underwent laparoscopic nephrectomy for autosomal dominant polycystic kidney disease and 10 consecutive patients who underwent open nephrectomy, the laparoscopic group had longer operative times (247 minutes vs. 205 minutes) but shorter mean hospital stay (2.6 days vs. 6.6 days) and lower complication rate (10% vs. 30%). In this study, the cysts were punctured and drained prior to hilar dissection in order to decrease the volume of the kidney and increase the working space. Preoperative embolization was necessary in only two cases. More importantly, all the patients had resolution of their preoperative pain at one-year follow-up (21). Laparoscopic bilateral simultaneous nephrectomy (22) and hand-assisted laparoscopic nephrectomy (23) in patients with autosomal dominant polycystic kidney disease showed similar results.

Although challenging, laparoscopic nephrectomy for autosomal dominant polycystic kidney disease is safe and efficient, and provides all the benefits associated with minimally invasive surgery.

Although challenging, laparoscopic nephrectomy for autosomal dominant polycystic kidney disease is safe and efficient, and provides all the benefits associated with minimally invasive surgery.

SUMMARY

- Laparoscopic simple nephrectomy for benign disease has become the standard of care.
- Almost all symptomatic benign renal diseases can be treated laparoscopically, given appropriate training and laparoscopic experience.
- Benefits of laparoscopic simple nephrectomy over open nephrectomy include decreased need for pain medication, shorter hospital stay, and quicker convalescence time.
- Complication rates are equivalent to or less than open surgery.
- Morbid obesity is not a contraindication for laparoscopic nephrectomy. Laparoscopic nephrectomy is both feasible and efficacious, and may actually be the preferred option in the obese patient.
- Laparoscopic simple nephrectomy in xanthogranulomatous pyelonephritis cases should only be attempted by the very experienced laparoscopist.
- Laparoscopic nephrectomy for tuberculosis and for autosomal dominant polycystic kidney disease is feasible and safe.

REFERENCES

1. Clayman RV, Kavoussi LR, Sopper NJ, et al. Laparoscopic nephrectomy: initial case report. *J Urol* 1991; 146(2):278–282.
2. Eraky I, el-Kappany HA and Ghoneim MA. Laparoscopic nephrectomy: Mansoura experience with 106 cases. *Br J Urol* 1995; 75(3):271–275.
3. Fornara P, Doehn C, Friedrich HJ, et al. Nonrandomized comparison of open flank versus laparoscopic nephrectomy in 249 patients with benign renal disease. *Eur Urol* 2001; 40(1):24–31.
4. Keeley FX, Tolley DA. A review of our first 100 cases of laparoscopic nephrectomy: defining risk factors for complications. *Br J Urol* 1998; 82(5):615–618.
5. Kercher KW, Heniford BT, Matthews BD, et al. Laparoscopic versus open nephrectomy in 210 consecutive patients: outcomes, cost, and changes in practice patterns. *Surg Endosc* 2003; 17(12):1889–1895.
6. Rassweiler J, Fornara P, Weber M, et al. Laparoscopic nephrectomy: the experience of the laparoscopy working group of the German Urologic Association. *J Urol* 1998; 160(1):18–21.
7. Gill IS, Kavoussi LR, Clayman RV, et al. Complications of laparoscopic nephrectomy in 185 patients: a multi-institutional review. *J Urol* 1995; 154(2 Pt 1):479–483.
8. Parsons JK, Jarrett TJ, Chow GK, et al. The effect of previous abdominal surgery on urological laparoscopy. *J Urol* 2002; 168(6):2387–2390.
9. Seifman BD, Dunn RL and Wolf JS Jr. Transperitoneal laparoscopy into the previously operated abdomen: effect on operative time, length of stay and complications. *J Urol* 2003; 169(1):36–40.
10. Hassan H. A modified instrument and method for laparoscopy. *Am J Obstet Gynecol* 1971; 110:886–887.
11. Mendoza D, Newman RC, Albala D, et al. Laparoscopic complications in markedly obese urologic patients (a multi-institutional review). *Urology* 1996; 48(4):562–567.
12. Fugita OE, Chan DY, Roberts WW, et al. Laparoscopic radical nephrectomy in obese patients: outcomes and technical considerations. *Urology* 2004; 63(2):247–252; discussion 252.
13. Kuo PC, Plotkin JS, Stevens S, et al. Outcomes of laparoscopic donor nephrectomy in obese patients. *Transplantation* 2000; 69(1):180–182.
14. Shekarriz B, Meng MV, Lu HF, et al. Laparoscopic nephrectomy for inflammatory renal conditions. *J Urol* 2001; 166(6):2091–2094.
15. Bercowsky E, Shalhav AL, Portis A, et al. Is the laparoscopic approach justified in patients with xanthogranulomatous pyelonephritis? *Urology* 1999; 54(3):437–442; discussion 442–443.

16. Lee KS, Kim HH, Byon SS, et al. Laparoscopic nephrectomy for tuberculous nonfunctioning kidney: comparison with laparoscopic simple nephrectomy for other diseases. *Urology* 2002; 60(3):411–414.
17. Reeders ST, Breuning MH, Davies KE, et al. A highly polymorphic DNA marker linked to adult polycystic kidney disease on chromosome 16. *Nature* 1985; 317(6037):542–544.
18. Peters DJ, Spruit L, Saris JJ, et al. Chromosome 4 localization of a second gene for autonomic dominant polycystic kidney disease. *Nat Genet* 1993; 5(4):359–362.
19. Lee DI, Andreoni CR, Rehman J, et al. Laparoscopic cyst decortication in autosomal dominant polycystic kidney disease: impact on pain, hypertension, and renal function. *J Endourol* 2003; 17(6):345–354.
20. Dunn MD, Portis AJ, Elbahnasy AM, et al. Laparoscopic nephrectomy in patients with end-stage renal disease and autosomal dominant polycystic kidney disease. *Am J Kidney Dis* 2000; 35(4):720–725.
21. Seshadri PA, Poulin EC, Pace D, et al. Transperitoneal laparoscopic nephrectomy for giant polycystic kidneys: a case control study. *Urology* 2001; 58(1):23–27.
22. Gill IS, Kaouk JH, Hobart MG, et al. Laparoscopic bilateral synchronous nephrectomy for autosomal dominant polycystic kidney disease: the initial experience. *J Urol* 2001; 165(4):1093–1098.
23. Rehman J, Landman J, Andreoni C, et al. Laparoscopic bilateral hand assisted nephrectomy for autosomal dominant polycystic kidney disease: initial experience. *J Urol* 2001; 166(1):42–47.

LAPAROSCOPIC RENAL BIOPSY: TECHNIQUE AND RESULTS

Christopher A. Warlick and David Y. Chan

The James Buchanan Brady Urological Institute, Johns Hopkins Medical Institutions, Baltimore, Maryland, U.S.A.

- INTRODUCTION
- SURGICAL TECHNIQUE
- RESULTS

- DISCUSSION
- SUMMARY
- REFERENCES

Indications for direct-vision renal biopsy include patients with bleeding diatheses, those on chronic anticoagulation medications, morbidly obese patients, patients with failed prior attempts at percutaneous biopsy, uncooperative patients, patients with a solitary kidney, patients with uncontrolled hypertension, and those patients with anomalous anatomy.

INTRODUCTION

Renal biopsy is an important diagnostic tool in the medical evaluation of renal insufficiency, hematuria, and proteinuria, and in the assessment of renal allograft dysfunction (1,2). Currently, most renal biopsies are performed percutaneously with a local anesthetic under ultrasound guidance using an 18-gauge spring-loaded biopsy gun (3–6). As greater experience with percutaneous biopsies has accumulated, several former absolute contraindications to percutaneous biopsy have devolved into relative contraindications (3,7). However, in select patients, renal biopsy under direct vision may still be preferred.

Indications for direct-vision renal biopsy include patients with bleeding diatheses, those on chronic anticoagulation medications, morbidly obese patients, patients with failed prior attempts at percutaneous biopsy, uncooperative patients, patients with a solitary kidney, patients with uncontrolled hypertension, and those patients with anomalous anatomy (3,8,9).

Direct-vision renal biopsy can be accomplished by either an open (10,11) or laparoscopic technique including both transperitoneal (12,13) and retroperitoneal approaches (8,14). Transperitoneal approaches offer the advantage of familiarity, because most laparoscopists are comfortable with transperitoneal landmarks and orientation. This may be particularly true in obese patients where the large amount of adipose tissue may obscure traditional landmarks in the retroperitoneum. The advantage of a retroperitoneal approach, however, includes an intuitive decreased risk of visceral injury and postoperative ileus because the colon is not mobilized and the peritoneal cavity is not insufflated.

SURGICAL TECHNIQUE

While both transperitoneal and retroperitoneal approaches for laparoscopic renal biopsy have been described, our preference is the retroperitoneal approach and will be the surgical technique described herein (Table 1). Preprocedure ultrasound or computed tomography imaging should be obtained to ensure normal anatomy or to determine if one kidney should be biopsied over the other. While biopsies can be obtained from either kidney, access to the left kidney may be simpler due to absence of the liver.

After consent is obtained, the patient is administered general endotracheal tube anesthesia. A Foley catheter and an orogastric or nasogastric tube are placed. The patient is placed carefully in a lateral decubitus position with the umbilicus over the break of the table. Care is taken to appropriately pad all pressure points, securing the patient to the table with wide cloth tape. The patient and the table are then flexed to maximize the distance and thus the working space between the iliac crest and the 12th rib. Prophylactic antibiotics are administered prior to the start of the procedure. The patient is prepped and draped in standard sterile fashion.

One 10-mm and one 5-mm port are required for the retroperitoneal approach. A small transverse incision just large enough to accommodate a 10-mm port is made equidistant between the 12th rib and the iliac crest in the posterior axillary line, just

TABLE 1 ■ Summary of Surgical Procedure

Place patient in lateral decubitus position
Place 10-mm port in posterior axillary line midway between 12th rib and iliac crest
Insufflate to 15 mmHg
Bluntly dissect retroperitoneal space with laparoscope
Place 5-mm port in anterior axillary line at level of first port under direct vision
Incise Gerota's fascia with scissors and clear perirenal fat from inferior pole of kidney
Using laparoscopic toothed cup biopsy forceps, obtain one to five biopsies
Obtain hemostasis with argon beam coagulator and Surgical
Desufflate to 5 mmHg and observe for bleeding
Evacuate all CO ₂ and remove ports
Close skin with absorbable suture

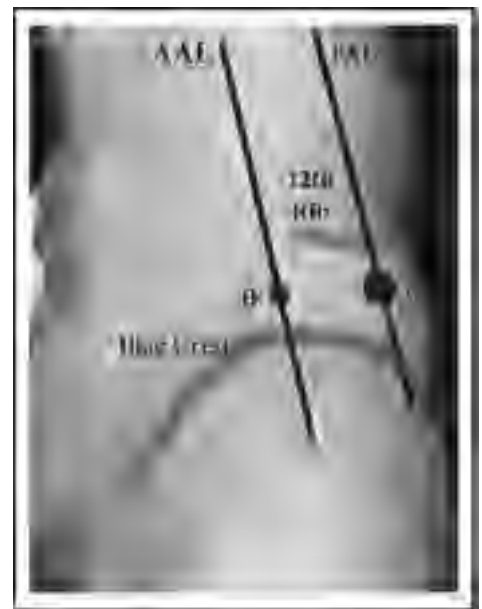
medial to the lateral border of the sacrospinalis muscle as indicated in Figure 1. Using the Visiport[®] introducer^a, the laparoscope is inserted through the incision and advanced sequentially through the fascial layers under vision. The tip of the scope should be maintained at an approximately 10° to 15° angle toward the umbilicus to achieve the correct trajectory to allow entrance into the retroperitoneum. An angle completely perpendicular to the body wall may result in an inadvertent penetration of the psoas muscle, while too dramatic of an angle may result in dissection of the layers of the abdominal wall musculature with the laparoscope and failure to enter the retroperitoneum. Once the retroperitoneum is entered, the Visiport device is removed, leaving the 10-mm trocar in place in the retroperitoneum. The trocar is then secured to the skin with sutures, and carbon dioxide insufflation is achieved to 15 mmHg. Blunt dissection with the laparoscope during insufflation may be necessary to further develop the retroperitoneal space anterior to the psoas muscle.

The technique for the placement of the first trocar described above is applicable to all patients, but is particularly useful in morbidly obese patients.

In fact, Chen et al. (15) described using this technique in conjunction with intraoperative transabdominal ultrasound to assist in the placement of the first trocar in patients in whom normal anatomic landmarks were obscured due to obesity, making placement of trocars dangerous. Ultrasound was used to identify bony landmarks such as the iliac crest and 11th and 12th ribs as well as the inferior pole of the kidney. Yap et al. (16) described a modification of the use of intraoperative ultrasound such that by obtaining transverse images through the liver, the authors were able to simultaneously view

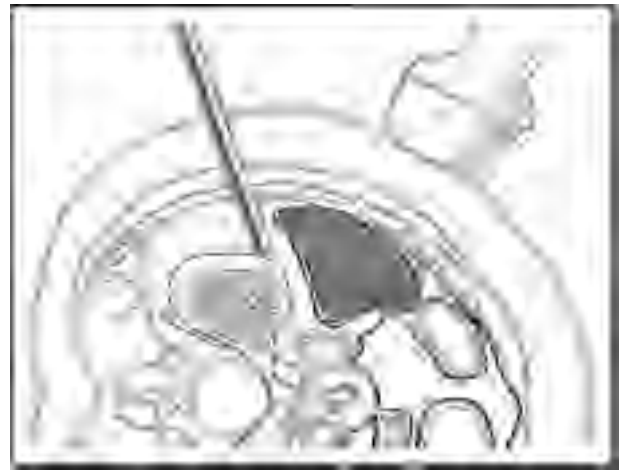The technique for the placement of the first trocar described here applicable to all patients, but is particularly useful in morbidly obese patients.

Figure 1 ■ Port placement for retroperitoneal laparoscopic renal biopsy. A, location of 10 mm port: midpoint between the 12th rib and iliac crest in the PAL; B, location of 5 mm port: AAL at similar level to 10 mm port. *Abbreviations:* PAL, posterior axillary line; AAL, anterior axillary line.



^aU.S. Surgical Corp., Norwalk, CT.

Figure 2 ■ Transverse ultrasound images obtained through the acoustic window provided by the liver allow the simultaneous localization of the Visiport® device and the kidney. *Source: From Ref. 16.*



the tip of the Visiport device during advancement through the abdominal wall and the outline of the kidney thus ensuring that the trocar was being placed correctly (Fig. 2).

In patients without morbid obesity, an alternative technique can be applied wherein the retroperitoneum is first insufflated using a Veress needle prior to the placement of the first trocar. Capelouto et al. (17) first placed a Veress needle in the posterior axillary line 1 cm above the iliac crest at a 5° to 10° angle, and insufflated the retroperitoneum after confirming correct placement of the needle. Following insufflation, the Veress needle was removed, and a 1 cm incision was made in that location and the laparoscope was introduced into the retroperitoneum followed by balloon dissection of the retroperitoneum. Current modifications of this access technique have abandoned the balloon dilation, and the Visiport device is used to introduce the laparoscope following insufflation. Additional working space in the retroperitoneum is created by blunt dissection with the laparoscope.

Once in the retroperitoneum and insufflation established, the laparoscope is used to bluntly dissect tissue in the retroperitoneum revealing Gerota's fascia overlying the kidney. After sufficient space has been created, a 5-mm port is placed under direct vision in the anterior axillary line between the level of the first port and the level of the iliac crest (Fig. 1) and secured to the skin with suture. In general, the 5-mm trocar is the working port. However, if a 5-mm laparoscope is also available, the 10-mm trocar can also serve as a working port.

After the kidney has been positively identified, Gerota's fascia is incised with laparoscopic scissors and the perinephric fat dissected away to reveal the inferior pole of the kidney.

Proper identification of the kidney can sometimes be challenging, particularly if there is a large amount of perinephric fat. In these cases, intraoperative laparoscopic ultrasound using a 10-mm probe can be used to help identify the kidney prior to harvesting the biopsies (8). If intraoperative ultrasound is used, a 5-mm laparoscope is placed medially in the working port and the ultrasound probe is placed in the 10-mm trocar.

After positive identification of the surface of the kidney, laparoscopic biopsy forceps (Fig. 3) are used to obtain one to five cortical biopsies from the surface of the kidney taking care to avoid deep samples containing medullary tissue.

Frozen sections of the tissue are sent for pathological analysis to confirm renal origin of the biopsy sample and to determine adequacy of harvested tissue.

Bleeding from the biopsy sites is controlled under direct vision using a 5-mm argon beam coagulator and by packing the sites with oxidized cellulose.

When the argon beam coagulator is used, it is important to vent the retroperitoneum to avoid overinsufflation. While awaiting the results of the frozen sections, insufflation pressure should be decreased to 5 mmHg and the biopsy site observed for adequate hemostasis for 5 to 10 minutes. After acquiring confirmation that adequate renal samples were obtained and complete hemostasis achieved, the carbon dioxide gas is evacuated from the retroperitoneum and the ports removed. Fascia does not need to be closed in this location, thus only the skin is closed using an absorbable suture. The patient is then awakened and brought to the recovery room. Patients are observed overnight with the vast majority of patients discharged the following day.

After the kidney has been positively identified, Gerota's fascia is incised with laparoscopic scissors and the perinephric fat dissected away to reveal the inferior pole of the kidney.

After positive identification of the surface of the kidney, laparoscopic biopsy forceps are used to obtain one to five cortical biopsies from the surface of the kidney, taking care to avoid deep samples containing medullary tissue.

Bleeding from the biopsy sites is controlled under direct vision using a 5-mm argon beam coagulator and by packing the sites with oxidized cellulose.




Figure 3 ■ Laparoscopic cup biopsy forceps.

Laparoscopic ultrasound to positively identify the kidney can avoid the complication of inadvertent biopsy of nonrenal tissue. It is also important to take superficial biopsies of the cortex. Deeper bites may result in the acquisition of mainly medullary tissue, increased bleeding, increased risk of arteriovenous fistula formation, or inadvertent violation of the collecting system, which increases the risk of urinary leak and fistula formation.

While this procedure is safe and is associated with relatively few complications, several points should be kept in mind to minimize the risk of complications. As noted above, gaining access to the retroperitoneum can be challenging, particularly in obese patients. The use of intraoperative ultrasound to identify landmarks to facilitate the safe placement of trocars is invaluable. Using this technique, Chen et al. (15) reported successful biopsy in eight patients with a mean body mass index of 52.8 in a mean operative time of 118 minutes and with an estimated blood loss of 71 mL.

The use of laparoscopic ultrasound to positively identify the kidney in equivocal cases can avoid the complication of inadvertent biopsy of nonrenal tissue. It is also important to take superficial biopsies of the cortex. Deeper bites may result in the acquisition of mainly medullary tissue, increased bleeding, increased risk of arteriovenous fistula formation, or inadvertent violation of the collecting system, which increases the risk of urinary leak and fistula formation.

After obtaining hemostasis, it is prudent to decrease the insufflation pressure from 20 to 5 mmHg before removing the trocars to ensure that complete hemostasis has been achieved, because high insufflation pressures can mask bleeding.

RESULTS

Several authors have published reports on laparoscopic renal biopsy by both transperitoneal (12,13) and retroperitoneal (8,14,18–20) approaches, including biopsies in children involving minor technical modifications (21). The largest series is reported by Shetye et al. (8) in which 74 patients underwent retroperitoneal laparoscopic renal biopsy over a nine-year period from 1991 to 2000. These authors obtained adequate tissue in 96% of their cases, which is similar to 100% rates of recovery from other published series (13,14). Shetye et al. reported an overall complication rate of 13.5%, the most common complication being bleeding, which was observed in 3 of 74 (4%) patients (8). Only one bleed was significant, involving a 2000 mL blood loss. These authors also reported one death seven days following uneventful biopsy in a patient with a lupus flare who was treated with high-dose steroids after the renal biopsy and subsequently died of a perforated gastric ulcer after refusing transfusion or surgery to explore the source of her abdominal pain (8). Complication rates from other reported series range from 11.8% (14) to 50% (13) and include subcutaneous emphysema (13), transient postoperative gross hematuria (14), perinephric hematoma (not requiring transfusion) (8), initial biopsy of nonrenal tissue (8), and inability to obtain tissue (8). Caione et al. (21) reported a single intraoperative complication (5%) of a peritoneotomy and one open conversion in 20 pediatric patients. While most reported complications in the literature have been minor, there is one case report of pneumocephalus following retroperitoneal laparoscopic renal biopsy, which is hypothesized to have resulted from an inadvertent disruption of the dura mater along an intercostal nerve or the lumbar plexus, which presumably occurred during placement of the 5-mm trocar (22). In addition, this same patient also suffered new-onset right lower extremity numbness and paralysis following the procedure, which was believed to have resulted from positioning during the procedure. The patient's pneumocephalus resolved without further intervention, and her paralysis resolved following aggressive physical therapy (22).

Laparoscopic renal biopsy is generally well tolerated. The majority of patients return home within 24 hours, with most of the remaining patients being discharged within 48 hours. Most patients who remain longer than this duration do so secondary to medical comorbidities or to reinstitute anticoagulation (8,15).

DISCUSSION

Renal biopsy remains indispensable in the diagnosis of medical renal disease manifesting as proteinuria, hematuria, or renal failure. Most biopsies can be accomplished percutaneously with ultrasound guidance and a spring-loaded biopsy gun. Reported

Laparoscopic renal biopsy is generally well tolerated. The majority of patients return home within 24 hours, with most of the remaining patients being discharged within 48 hours.

complications rates with this procedure including postoperative bleeding (the most common complication) are between 11% (23) and 34.1% (24). Manno et al. (24) reported a major complication rate of 1.2% in their series of 471 patients including 1 nephrectomy. Rates might be expected to be higher among high-risk patients. In such cases where percutaneous biopsy is contraindicated, alternative methods must be employed to obtain the biopsy. Several other methods have been reported. Percutaneous computed tomography-guided biopsy (25,26) is an alternative to ultrasound-guided percutaneous biopsy, which, similar to ultrasound guidance, does not involve general anesthesia, but is not appropriate for extremely obese patients who do not fit in the scanner. Another option is transjugular kidney biopsy (27,28). While this procedure provides diagnostic biopsies approximately 90% of the time, it involves capsular perforations between 13.5% (28) and 73.9% (27) of the time, increasing the risk of bleeding into the retroperitoneum, or the collecting system. In the study by Fine et al. (28), 1 of 37 patients required transfusion, while in Thompson et al.'s report (27), 1 of 25 patients developed an arteriocalyceal fistula, and another patient developed a renal vein thrombosis (27). There is also a report of transureteral renal biopsy through an upper pole calyx accomplished with an 18-gauge needle sheathed in an 8 French catheter inserted through a 10 French transureteral catheter (29).

Open biopsy and laparoscopic biopsy are the two methods that allow direct vision both during biopsy and during subsequent achievement of hemostasis, which is important in patients who may be at high risk of bleeding. Laparoscopy has the advantage of being less invasive and less morbid than open biopsy.

Many patients who are candidates for laparoscopic renal biopsy have significant medical comorbidities. Shetye et al. (8) reported that 47 of 74 patients in their series had American Society of Anesthesiologists physical status scores of 3 or 4. Thus a disadvantage of laparoscopic renal biopsy compared to percutaneous biopsy is the need for general anesthesia. However, Micali et al. (30) reported the successful use of epidural anesthesia in a patient requiring laparoscopic renal biopsy with severe comorbidities that made him a poor candidate for general anesthesia. Therefore, general anesthesia may not be absolutely necessary for this procedure, particularly if it can be performed quickly thus minimizing the risk of hypercarbia.

Renal biopsy remains essential in the diagnosis of medical renal pathology. In most cases, this can be accomplished with image-guided percutaneous biopsy. However, in the rare instance that direct-vision biopsy is required, laparoscopic renal biopsy is a safe and minimally invasive technique for obtaining renal tissue in high-risk patients. Careful patient selection and counseling, with meticulous intraoperative hemostasis, and careful resumption of anticoagulation medication after the procedure help ensure a safe outcome following renal biopsy in what can be a challenging group of patients.

SUMMARY

- Renal biopsy remains indispensable in the diagnosis of medical renal disease manifesting as proteinuria, hematuria, or renal failure.
- Indications for direct-vision renal biopsy include patients with bleeding diatheses, those on chronic anticoagulation medications, morbidly obese patients, patients with failed prior attempts at percutaneous biopsy, uncooperative patients, patients with a solitary kidney, patients with uncontrolled hypertension, and those patients with anomalous anatomy.
- Open biopsy and laparoscopic biopsy are the two methods that allow direct vision both during biopsy and during subsequent achievement of hemostasis, which is important in patients who may be at high risk of bleeding. Laparoscopy has the advantage of being less invasive and less morbid than open biopsy.
- Laparoscopic renal biopsy is generally well tolerated. The majority of patients return home within 24 hours, with most of the remaining patients being discharged within 48 hours.

ACKNOWLEDGMENT

The authors thank Dr. Richard Link for help in constructing Figure 1.

REFERENCES

1. Morel-Maroger L. The value of renal biopsy. *Am J Kidney Dis* 1982; 1:244–248.
2. Manaligod JR, Pirani CL. Renal biopsy in 1985. *Semin Nephrol* 1985; 5:237–239.

3. Donovan KL, Thomas DM, Wheeler DC, Macdougall IC, Williams JD. Experience with a new method for percutaneous renal biopsy. *Nephrol Dial Transplant* 1991; 6:731–733.
4. Wiseman DA, Hawkins R, Numerov LM, Taub KJ. Percutaneous renal biopsy utilizing real-time ultrasonographic guidance and a semiautomated biopsy device. *Kidney Int* 1990; 38:347–349.
5. Dowd PE, Mata JA, Crow A, Culkin DJ, Venable DD. Ultrasound guided percutaneous renal biopsy using an automatic core biopsy system. *J Urol* 1991; 146:1216–1217.
6. Kim D, Kim H, Shin G, et al. A randomized, prospective, comparative study of manual and automated renal biopsies. *Am J Kidney Dis* 1998; 32:426–431.
7. Schow DA, Vinson RK, Morrisseau PM. Percutaneous renal biopsy of the solitary kidney: a contraindication? *J Urol* 1992; 147:1235–1237.
8. Shetye KR, Kavoussi LR, Ramakumar S, Fugita OE, Jarrett TW. Laparoscopic renal biopsy: a 9-year experience. *BJU Int* 2003; 91:817–820.
9. Bolton WK, Vaughan ED Jr. A comparative study of open surgical and percutaneous renal biopsies. *J Urol* 1977; 117:696–698.
10. Gill WB, Cole AT. Cup-forceps cortical renal biopsy. An improved technique of open renal biopsy. *J Urol* 1973; 109:538–540.
11. Nomoto Y, Tomino Y, Endoh M, et al. Modified open renal biopsy: results in 934 patients. *Nephron* 1987; 45:224–228.
12. Squadrito JF Jr., Coletta AV. Laparoscopic renal exploration and biopsy. *J Laparoendosc Surg* 1991; 1:235–239.
13. Healey DE, Newman RC, Cohen MS, Mars DR. Laparoscopically assisted percutaneous renal biopsy. *J Urol* 1993; 150:1218–1221.
14. Gaur DD, Agarwal DK, Khochikar MV, Purohit KC. Laparoscopic renal biopsy via retroperitoneal approach. *J Urol* 1994; 151:925–926.
15. Chen RN, Moore RG, Micali S, Kavoussi LR. Retroperitoneoscopic renal biopsy in extremely obese patients. *Urology* 1997; 50:195–198.
16. Yap RL, Chan DY, Fradin J, Jarrett TW. Intraoperative ultrasound guided retroperitoneal laparoscopic renal biopsy in the morbidly obese patient. *J Urol* 2000; 163:1197–1198.
17. Capelouto CC, Moore RG, Silverman SG, Kavoussi LR. Retro-peritoneoscopy: anatomical rationale for direct retroperitoneal access. *J Urol* 1994; 152:2008–2010.
18. Gimenez LF, Micali S, Chen RN, Moore RG, Kavoussi LR, Scheel PJ Jr. Laparoscopic renal biopsy. *Kidney Int* 1998; 54:525–529.
19. Keizur JJ, Tashima M, Das S. Retroperitoneal laparoscopic renal biopsy. *Surg Laparosc Endosc* 1993; 3:60–62.
20. Jackman SV, Bishoff JT. Laparoscopic retroperitoneal renal biopsy. *J Endourol* 2000; 14:833–838; discussion 838–839.
21. Caione P, Micali S, Rinaldi S, et al. Retroperitoneal laparoscopy for renal biopsy in children. *J Urol* 2000; 164:1080–1082; discussion 1083.
22. Ricchiuti VS, Seftel AD. Iatrogenic pneumocephalus after laparoscopic renal biopsy. *J Urol* 2001; 166:982–983.
23. Gonzalez-Michaca L, Chew-Wong A, Soltero L, Gamba G, Correa-Rotter R. Percutaneous kidney biopsy, analysis of 26 years: complication rate and risk factors; comment. *Rev Invest Clin* 2000; 52:125–131.
24. Manno C, Strippoli GF, Arnesano L, et al. Predictors of bleeding complications in percutaneous ultrasound-guided renal biopsy. *Kidney Int* 2004; 66:1570–1577.
25. Lee SM, King J, Spargo BH. Efficacy of percutaneous renal biopsy in obese patients under computerized tomographic guidance. *Clin Nephrol* 1991; 35:123–129.
26. Sateriale M, Cronan JJ, Savadler LD. A 5-year experience with 307 computerized tomography-guided renal biopsies: results and complications. *J Vasc Interv Radiol* 1991; 2:401–407.
27. Thompson BC, Kingdon E, Johnston M, et al. Transjugular kidney biopsy. *Am J Kidney Dis* 2004; 43:651–662.
28. Fine DM, Arepally A, Hofmann LV, Mankowitz SG, Atta MG. Diagnostic utility and safety of transjugular kidney biopsy in the obese patient. *Nephrol Dial Transplant* 2004; 19:1798–1802.
29. Leal JJ. A new technique for renal biopsy: the transurethral approach. *J Urol* 1993; 149:1061–1063.
30. Micali S, Jarrett TW, Pappa P, Taccone Gallucci M, Virgili G, Vespasiani G. Efficacy of epidural anesthesia for retroperitoneoscopic renal biopsy. *Urology* 2000; 55:590.

Lewis CH. Liew and Adrian D. Joyce

St. James's University Hospital, Leeds, U.K.

- INTRODUCTION
- PATIENT SELECTION AND DIAGNOSIS
- SURGICAL TECHNIQUE
 - Patient Preparation
 - Transperitoneal Approach

- Retroperitoneal Approach
- Postoperative Care
- RESULTS
- SUMMARY
- REFERENCES

Nephroptosis, also called hypermobile or floating kidney, is characterized by an abnormal caudal movement of the kidney by more than two vertebral bodies or 5 cm when the patient changes from the supine to the erect position.

INTRODUCTION

Nephroptosis, also called hypermobile or floating kidney, is characterized by an abnormal caudal movement of the kidney by more than two vertebral bodies or 5 cm when the patient changes from the supine to the erect position.

The condition was first described by Franciscus de Pedemantanus in the 14th century. Subsequently, Rayer described the characteristic symptoms attributable to a ptotic kidney in 1841(1). Historically, nephroptosis occurs more frequently in lean young females with a female-to-male ratio of about 5 to 10:1. The right kidney is affected in 70% of the cases. However, such data have to be evaluated cautiously because in approximately 20% of normal, asymptomatic females, the intravenous urogram was observed to have significant renal descent consistent with a diagnosis of nephroptosis (2,3). As such, from a practical standpoint, true symptomatic nephroptosis is a rare condition, and the diagnosis should be made with due circumspection.

The symptoms of nephroptosis usually include pain, which is exacerbated by sitting or standing. Sometimes, when the patient is upright, the kidney can be palpated in the lower abdomen. Nephroptosis may also present with pyelonephritis, renal calculi, hematuria, hypertension, and renal ischemia (2). The most severe presentation of nephroptosis is a syndrome of multiple symptoms including intermittent, severe colicky pain, nausea, tachycardia, oliguria, proteinuria, and/or hematuria, known as Dietl's crisis. On physical examination, the kidney may appear palpably enlarged and tender. The pain can be acutely relieved by upward manual reduction of the kidney into the renal fossa, with the patient in the supine position. Also the knee-chest or supine position assumed by the patient with the head down and feet elevated may help relieving the pain (4,5). Hypotheses for the pathogenesis of symptoms due to nephroptosis include kidney descent causing intermittent ureteral obstruction at the ureteropelvic junction with consequential hydronephrosis. Alternative explanations include traction on the renal pedicle combined with hilar vessel kinking leading to renal ischemia. Stretching of the peripelvic nerves is also considered to be a possible mechanism responsible for the pain.

Nephropexy, an organ-preserving modality, was first performed by Hahn in 1881 (6), and was technically refined, innovated, and popularized by Edebohls, a gynecologist.

Most of the proposed therapeutic options for nephroptosis are no longer popular because of their degree of invasiveness. In the 1870s, nephrectomy was advocated for the relief of symptomatic renal ptosis. However, such radical therapy was swiftly condemned due to its high mortality and lack of evidence of pathologic changes in the excised specimen (2).

Edebohls published a series of 12 cases in 1893, in which he described his technique comprising incision and back stripping of the renal capsule along the entire convexity of the kidney, and the placement of five or six deep sutures through the skin, the superficial fat, the tendons of the abdominal muscles, and the edges of the renal capsule and parenchyma (7).

Since then, a multitude of different procedures for symptomatic nephroptosis have been described including various "pexy" procedures, decapsulation of the kidney,

Nephropexy, an organ-preserving modality, was first per-formed by Hahn in 1881, and was technically refined, innovated, and popularized by Edebohls, a gynecologist.

and fixation of the kidney to the 12th rib. However, due to the lack of objective diagnostic studies and the lack of clear-cut indications for surgery, the diagnosis of nephroptosis and its surgical treatment have passed through cycles of intense popularity and equally intense disfavor during the past century (8).

In the last decade, the availability of laparoscopic surgery has led to a revival of interest in nephroptosis and nephropexy.

Urban et al. from the Washington University School of Medicine reported the initial laparoscopic nephropexy performed in a severely symptomatic woman with a palpable ptotic kidney and hydronephrosis in 1993 (9). Two years later, the same group updated their experience including five additional cases managed with laparoscopic nephropexy. The procedure was well tolerated with reported low morbidity, rapid recovery, and successful improvement of symptoms (10).

PATIENT SELECTION AND DIAGNOSIS

A history of flank or loin pain, relieved by lying down, is the most common symptom of patients with nephroptosis.

A history of flank or loin pain, relieved by lying down, is the most common symptom of patients with nephroptosis.

Sometimes, the full range of symptoms of Dietl's crisis may be seen as the initial presentation. Physical examination, especially with the patient in the upright position, usually reveals palpation of a mobile mass in the lower abdomen. Reduction of the mobile mass back to its normal position in the retroperitoneum with relief of symptoms is highly suggestive of the diagnosis.

Intravenous urography, usually performed in the supine and erect positions, has been the primary diagnostic tool for the assessment of nephroptosis. The ability to reproduce symptoms after the administration of a diuretic, with the patient upright, assists in confirming the diagnosis.

Erect and supine diuretic renography-documented renal obstruction, decreased renal perfusion, and/or changes in the degree of renal function has been used to identify patients with functional nephroptosis and has been recommended as the most definitive diagnostic study.

Erect and supine diuretic renography-documented renal obstruction, decreased renal perfusion, and/or changes in the degree of renal function has been used to identify patients with functional nephroptosis and has been recommended as the most definitive diagnostic study.

Retrograde pyelography in both supine and erect positions has also been used as an alternative diagnostic tool, but is more invasive than renography. Ultrasonography can also be used to confirm a mobile, ptotic kidney and can reveal hydronephrosis, with positional change. Recently, the use of ultrasound Doppler was proposed as a diagnostic tool for patient with nephroptosis by detection of changes in renal blood flow. The resistive index was measured in the segmental arteries, with the patient in both the supine and the erect position. In comparison with isotope renogram, resistive index measurement by Doppler ultrasound appears to be significantly more sensitive in detecting renal blood flow impairment (10).

SURGICAL TECHNIQUE

Patient Preparation

Patients may be typed and crossmatched for blood and are given a dose of broad-spectrum antibiotics before the procedure. No specific bowel preparation is required. Patients undergoing laparoscopic nephropexy, like all other laparoscopic surgery, should have a general endotracheal anesthetic, because controlled ventilation is necessary to ensure adequate oxygenation and to avoid hypercarbia. A nasogastric tube is placed to keep the stomach and bowels decompressed, and a Foley catheter is inserted to allow drainage of the bladder prior to commencement of the procedure. Pneumatic compression stockings are applied to both legs.

Transperitoneal Approach

Positioning

After intubation and placement of all appropriate tubes and lines, the patient is rolled onto the lateral decubitus position, allowing the torso to fall back to an angle of 70° from the horizontal, with the side of the lesion in the nondependent position. The operating table is flexed in order to help distract the kidney from the nearby structures. The bottom leg is flexed at the hip and knee, whereas the upper leg remains straight. It is important to fully pad all pressure points, including both the top and the bottom legs and to ensure the patient is adequately secured to the operating table.

Port Placement

Transperitoneal access can be obtained, and the primary port is inserted at the lateral border of the rectus muscle just above the level of the umbilicus. We prefer a 12-mm blunt tip trocar as our primary port. Carbon dioxide is insufflated to create a pneumoperitoneum up to 15 mmHg. A 10-mm 0° laparoscope is inserted, and the underlying bowel is inspected for any injury that may have occurred inadvertently during port placement. Subsequently, two additional 5-mm ports are placed under direct laparoscopic vision. A second port is placed 2 cm below the costal margin in the midclavicular line. The third port is placed in the anterior axillary line between the costal margin and iliac crest.

Step 1: Peritoneal Incision and Pararenal Dissection

The line of Toldt is incised, and the colon is reflected medially to expose the entire kidney. In general, the descending colon needs to be mobilized up to the aorta and the ascending colon up to the duodenum. At this point, the Gerota's fascia is incised and both the Gerota's fascia and the perinephric fat are reflected. The kidney is then completely mobilized, and the renal pelvis and ureter exposed. Blunt dissection is performed along the posterior wall of the retroperitoneum to expose the fascia overlying the psoas and quadratus lumborum muscles.

Step 2: Fixation of the Kidney

The patient is placed in a steep, Trendelenburg (head down) position, thereby facilitating cephalad displacement of the kidney. Using either the intra- or the extracorporeal knot-tying techniques, the kidney is fixed high on the posterior abdominal wall. According to surgeon preference, a vertical or horizontal row of sutures may be employed. Initially the upper pole of the kidney is affixed to the psoas or quadratus lumborum muscle with 2/0 nonabsorbable polyester suture on a round-bodied needle. Care must be taken to ensure that the suture only catches the renal capsule without penetrating the renal parenchyma.

Two to three further sutures are placed in the similar manner at the middle and lower pole of the kidney (Fig. 1). Once all the sutures are secured, intra-abdominal pressure is decreased to 5 mmHg for inspection of the operative field and port sites for bleeding. After hemostasis is achieved, the ports are removed and port sites closed.

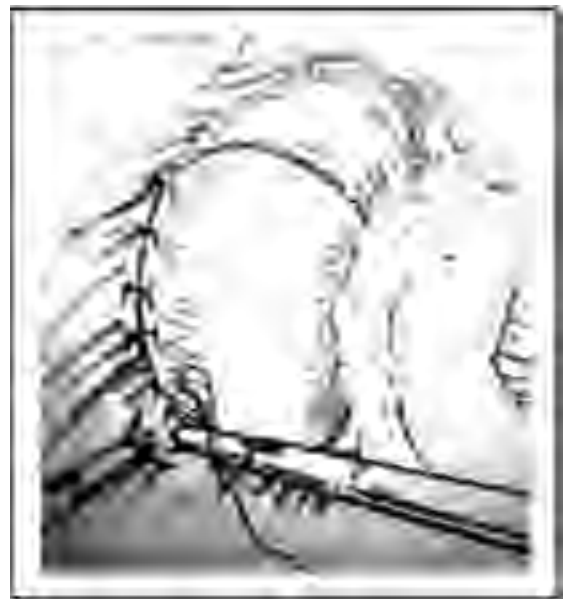Care must be taken to ensure that the suture only catches the renal capsule without penetrating the renal parenchyma

Retroperitoneal Approach

Positioning

The patient is put in a lateral decubitus position, with the operating table flexed. The bottom leg is flexed at the hip and knee, whereas the upper leg remains straight with a pillow between the legs. It is important to ensure all pressure points are fully padded and the patient is secured safely on the table.

FIGURE 1 ■ Kidney is pressed to the sidewall with non-absorbable sutures.



The laparoscope can be inserted within the inflated transparent balloon to confirm appropriate balloon placement and adequate expansion of the retroperitoneum.

During insertion of the third port, care must be taken to prevent breaching of the peritoneum. If required, the lateral reflection of the peritoneum can be further mobilized anteromedially before the port is inserted.

Port Placement

A 15-mm incision is made in the lumbar triangle between the 12th rib and the iliac crest. Using a hemostat, the tissue is bluntly spread away until the anterior thoracoabdominal fascia is exposed. A finger or hemostat is used to penetrate through this fascial layer as well as the lumbodorsal fascia to enter the retroperitoneum. Using the finger for blunt dissection, the retroperitoneal space is developed anterior to the psoas muscle and posterior to the Gerota's fascia. A balloon dilator device is inserted to create a working space in the retroperitoneum. Typically, about 800 to 1000 mL of air is instilled into the balloon to displace the kidney anteromedially.

The laparoscope can be inserted within the inflated transparent balloon to confirm appropriate balloon placement and adequate expansion of the retroperitoneum.

Following balloon dilation and removal, a 10-mm blunt tip trocar is placed as the primary port. After creation of pneumoretroperitoneum (15 mmHg) and the insertion of a 10-mm 30° laparoscope, the psoas muscle and Gerota's fascia are identified. Two secondary ports are placed under direct laparoscopic visualization. A 5-mm port is placed at lateral border of the erector spinae muscle just below the 12th rib (Fig. 2). Another 5-mm port is placed at the anterior axillary line 2 cm below the costal margin.

During insertion of the third port, care must be taken to prevent breaching of the peritoneum. If required, the lateral reflection of the peritoneum can be further mobilized anteromedially before the port is inserted.

Step 1: Kidney Mobilization

Gerota's fascia is incised longitudinally, and the kidney is dissected along its anterior, posterior, and lateral aspects. The kidney is fully mobilized after reflecting the perinephric fat. The posterior wall of the retroperitoneum is bluntly dissected to expose the fascia overlying the psoas and quadratus lumborum muscles.

Step 2: Fixation of the Kidney

The kidney is then fixed in an optimal position in the same manner described above. At the end of the surgery, hemostasis is confirmed under lowered retropneumoperitoneum pressure, and all the ports are removed under laparoscopic visualization. Fascial closure is performed for the 12-mm port site.

Postoperative Care

The patient is allowed to begin oral intake as tolerated from postoperative day 1. Intravenous ketorolac 15 mg is administered every six hours as required, and the patient is instructed to lie flat in bed for the initial three days. Antithrombotic stockings and low-molecular-weight heparin is given until the patient is ambulating. The average length of hospital stay is between three and five days. After discharge, the patient is followed up with an intravenous urogram at about three months.

RESULTS

Nephropexy is one of the oldest surgical procedures performed for symptomatic nephroptosis. Nevertheless, there is a continuing debate with regard to the indication and necessity of this procedure. Earlier, limited diagnostic studies prevented careful selection of patients with respect to the exclusion of other nonurological causes. With the advent of intravenous urography, a better understanding of this complex disorder

FIGURE 2 ■ Placement for the retroperitoneal approach.



TABLE 1 ■ Worldwide Experience with Laparoscopic Nephropexy

Study	Year	Number of patients	Approach	Fixation	Follow up (months)	Results
Hubner et al.	1994	10	Transperitoneal	Polygactin net	1-9	100% Asymptomatic
Elashry et al.	1995	6	Transperitoneal	Quadratus lumborum	2-30	100% Asymptomatic
Fornara et al.	1997	23	Transperitoneal	Psoas/quadratus lumborum	12-27	91% Asymptomatic
McDougall et al.	2000	14	Transperitoneal	Quadratus lumborum	4-75	80% Asymptomatic
Rassweiler et al.	2001	31	Retroperitoneal	Psoas muscle	24 (mean)	83% Asymptomatic
Plas et al.	2001	13	Transperitoneal	Polypropylene net	63-93	92% Asymptomatic
Chueh et al.	2002	23	Retroperitoneal	Psoas/quadratus lumborum	2-84	84% Asymptomatic
Ichikawa et al.	2003	5	Retroperitoneal	Psoas/quadratus lumborum	5-22	80% Asymptomatic

Overall, about 130 patients with symptomatic nephroptosis have been treated laparoscopically. The transperitoneal approach seems to be favored over the retroperitoneal approach.

Early postoperative results after laparoscopic nephropexy vary from 80% to 100% success rate after one year and complete relief of symptoms in most cases. Long-term results up to five years following laparoscopic nephropexy showed complete remission in the vast majority of patients.

with associated functional changes could be demonstrated. As a result, nephropexy became established as the treatment of choice for symptomatic nephroptosis.

Overall, about 130 patients with symptomatic nephroptosis have been treated laparoscopically. The transperitoneal approach seems to be favored over the retroperitoneal approach.

Laparoscopy has brought to the surgical realm a minimally invasive method of approaching surgical problems with certain advantages over conventional open surgery. With the advent of intracorporeal suturing, reconstructive procedures have begun to come into the realm of minimally invasive therapy. Various authors have reported their experiences with laparoscopic nephropexy over the last decade (11-20). Table 1 summarizes all the reported series of laparoscopic nephropexy in the English literature.

Success of the surgery is usually defined as resolution of the symptoms associated with nephroptosis. Postoperative intravenous urogram assessment should reveal minimal descent of the kidney in majority of the patients. In addition, the ureteral obstruction associated with the kidney ptosis should also be resolved.

Early postoperative results after laparoscopic nephropexy vary from 80% to 100% success rate after one year and complete relief of symptoms in most cases. Long-term results up to five years following laparoscopic nephropexy showed complete remission in the vast majority of patients (18,19).

Few cases of symptomatic recurrence were observed after the initial success (18). Nonabsorbable materials (suture or mesh) should be used for the fixation of the mobile kidney to the retroperitoneum muscles. After concluding that the use of absorbable polygactin mesh for fixation was responsible for the recurrences seen, the authors subsequently changed to nonabsorbable polypropylene mesh, and no further symptomatic recurrences were noted.

SUMMARY

- Symptomatic nephroptosis requires standard evaluation, including intravenous urogram assessment and isotope renogram with patients supine and upright.
- Nephropexy should only be offered in symptomatic patients with proven deterioration of split renal function at orthostasis.
- The good clinical outcome, minimal invasiveness, and rapid convalescence with long-term resolution of symptoms support the observation for laparoscopic nephropexy as the treatment of choice.
- Nonabsorbable materials (suture or mesh) should be used for the fixation of the mobile kidney to the retroperitoneum muscles.

REFERENCES

1. Young HH, Davis DM. Malformation and abnormalities of the urogenital tract. Chapter 9, Young's Practice of Urology. Vol. 2. Philadelphia: W.B. Saunders Co., 1926:1–36.
2. Burford CE. Nephroptosis with co-existing lesions. *J Urol* 1946; 55:220.
3. Braasch WF, Greene LF, Goyanna R. Renal nephroptosis and its treatment. *JAMA* 1948; 138:399–401.
4. Dietl J. Nerki wedrujace I ich uwiezuienie. *Przegl Lek (Krakow)* 1864; 3:225 (part i), 233(part ii), 241(part iii).
5. Dietl J. Wanderende Nieren und deren Einklemmung. *Wien Med Wschr* 1864; 14:563(part i), 579(part ii), 593(part iii).
6. Hahn E. Die operative Behandlung der beweglichen Niere durch Fixation. *Zentralbl Chir* 1881; 29:449.
7. Edebohls GM. Movable kidney: with a report of twelve cases treated by nephrorrhaphy. *Am J Med Sci* 1983; 105:247(part i), 417(part ii).
8. Harrison LH. Nephropexy. In: Glenn JF, ed. *Urological Surgery*. 3rd ed. Philadelphia: J.B. Lippincott Co., 1983:253–355.
9. Urban DA, Clayman RV, Kerbl K, Figenshau RS, McDougall EM. Laparoscopic nephropexy for symptomatic nephroptosis: initial case report. *J Endourol* 1993; 7:27.
10. Strohmeyer DM, Peschel R, Effert P, et al. Changes of renal blood flow in nephroptosis: assessment by color Doppler imaging, isotope renography and correlation with clinical outcome after laparoscopic nephropexy. *Eur Urol* 2004; 45(6):790–793.
11. Elashry OM, Nakada SY, McDougall EM, Clayman RV. Laparoscopic nephropexy: Washington University experience. *J Urol* 1995; 154:1655.
12. Hubner WA, Schramek P, Pfluger H. Laparoscopic nephropexy. *J Urol* 1994; 152(4):1184–1187.
13. Matsuda T, Uchida J, Ashida M, Mikami O. Laparoscopic nephropexy: a case report. *Int J Urol* 1996; 3(5):397–400.
14. Fornara P, Doehn C, Jocham D. Laparoscopic nephropexy: 3-year experience. *J Urol* 1997; 158(5):1679–1683.
15. McDougall EM, Afane JS, Dunn MD, Collyer WC, Clayman RV. Laparoscopic nephropexy: long-term follow-up—Washington University experience. *J Endourol* 2000; 14(3):247–250.
16. Rehman J, Hoenig DM. Laparoscopic nephropexy. *J Endourol* 2000; 14(10):881–887.
17. Rassweiler JJ, Frede T, Recker F, Stock C, Seemann O, Alken P. Retroperitoneal laparoscopic nephropexy. *Urol Clin North Am* 2001; 28(1):137–144.
18. Plas E, Daha K, Riedl CR, Hubner WA, Pfluger H. Long-term followup after laparoscopic nephropexy for symptomatic nephroptosis. *J Urol* 2001; 166(2):449–452.
19. Chueh SC, Hsieh JT, Chen J, Young YL, Chen SC, Tu YP. Retroperitoneoscopic nephropexy for symptomatic nephroptosis. *Surg Endosc* 2002; 16(11):1603–1607.
20. Ichikawa T, Yamada D, Takao A, Saegusa M, Aramaki K, Kumon H. Retroperitoneoscopic nephropexy for symptomatic nephroptosis. *J Endourol* 2003; 17(9):767–770.

LAPAROSCOPIC RENAL CYST ABLATION: TECHNIQUE AND RESULTS

Li-Ming Su

Brady Urological Institute, The Johns Hopkins University School of Medicine, Baltimore, Maryland, U.S.A.

■ INTRODUCTION	Cystoscopy and Ureteral Stent Placement
■ PATIENT SELECTION	Operative Steps
Radiographic Evaluation	■ POSTOPERATIVE CARE
Symptoms	■ MEASURES TO AVOID COMPLICATIONS
Indications and Contraindications	Intraoperative Complications
■ PREOPERATIVE PREPARATION	Postoperative Complications
Laboratory and Radiologic Tests	■ RESULTS
Bowel Preparation	Simple Renal Cysts
Informed Consent	Peripelvic Renal Cysts
Personnel and Equipment Configuration	Autosomal Dominant Polycystic
Patient Positioning	Kidney Disease
■ SURGICAL TECHNIQUE	■ SUMMARY
Instrumentation and Equipment	■ REFERENCES

INTRODUCTION

Renal cysts are common benign lesions of the kidney estimated to occur in at least 24% of individuals older than 40 years and 50% of individuals older than 50 years, who are evaluated by abdominal computed tomography for nonurologic indications (1). With the recent widespread and increase use of abdominal cross-sectional radiographic imaging, the incidence of asymptomatic renal cysts is likely higher than previous estimates. Although renal cyst may be congenital or acquired, most are simple, asymptomatic, and of unknown etiology. However, some patients develop abdominal and/or flank pain, hematuria, hypertension, recurrent infection, or obstructive uropathy as a result of a renal cyst (2).

Open surgical exploration and treatment of renal cysts have been reported since the early 1900s. One of the earliest formal reviews of the literature and descriptions of open surgical management of renal cysts was performed by Kretschmer in 1920 (3). Of 35 patients who were explored through flank or abdominal incisions, 18 underwent excision or resection of a renal cyst, 16 required nephrectomy, and in one patient the cyst was marsupialized. He concluded that surgical resection of the cyst should be performed when possible. Open renal cyst ablation, although effective, was not without morbidity. In 1967, Kropp et al. reported a 37% complication rate in 126 patients undergoing open renal exploration for cyst, including two patients dying in the postoperative period (4). Because the surgical treatment of a benign condition such as a renal cyst did not generally require organ extirpation but rather only excision of the cyst wall and evacuation of its fluid contents, less invasive means of treating symptomatic renal cysts without requiring a large flank or abdominal incision were searched. Open renal cyst ablation remained the gold-standard approach until the late 1980s when minimally invasive methods were introduced.

In 1989, Holmberg and Hietala described percutaneous puncture and drainage of peripheral renal cysts under local anesthesia followed by instillation of bismuth-phosphate sclerosant (5). Although short-term success was high, limitations of this technique included a high cyst recurrence rate (54%) and the risk of collecting system strictures as a result of scarring caused by the sclerosing agent, making this technique ill advised for cysts located in the peripelvic region. Percutaneous resection and fulguration was proposed to address symptomatic renal cysts not amenable to aspiration and sclerosis (6). However, this technique required high technical skill, a large nephrostomy tract with

Open renal cyst ablation remained the gold-standard approach until the late 1980s when minimally invasive methods were introduced.

The advantage of laparoscopic decortication of symptomatic renal cysts. Include the ability to address multiple, peripelvic, and bilateral renal cysts in a single operation, while minimizing incisional morbidity.

Since its description, both transperitoneal and retroperitoneal laparoscopic approaches have been evaluated with excellent success rates.

the need for multiple tracts to treat multiple renal cysts, the placement of a ureteral stent and was associated with the risk of electrolyte disturbances secondary to irrigant absorption. Finally, retrograde endoscopic marsupialization of renal cysts using a flexible ureteroscope was described. Limitations of this technique included technical difficulty, a secondary procedure required to remove an indwelling ureteral stent, and its indications restricted to the treatment of peripelvic cysts only (7). Although each of these three minimally invasive approaches was effective for selected unilateral cysts, none provided the ability to easily address all types of cysts or complex cysts (multiple, bilateral, and/or peripelvic cysts) in one setting.

Hulbert and coworkers presented the first description of The advantage laparoscopic decortication of symptomatic renal cysts in 1992 (8) this technique included the ability to address multiple, peripelvic, and bilateral renal cysts in a single operation, while minimizing incisional morbidity.

Since its description, both transperitoneal and retroperitoneal laparoscopic approaches have been evaluated with excellent success rates (9–16).

PATIENT SELECTION

Selecting a proper candidate for laparoscopic renal cyst ablation depends on the following criteria:

- Radiographic diagnosis of a renal cyst
- Presence of symptoms attributable to the renal cyst
- Specific indications and contraindications

Radiographic Evaluation

The radiologic diagnosis of renal cysts can be made by renal ultrasonography, computed tomography, or magnetic resonance imaging. Although intravenous pyelography with tomographic views may show splaying of the collecting system or rotation of the kidney about its normal axis suggesting the presence of a renal mass, further confirmation radiologic studies are required in order to differentiate cyst versus neoplasm.

Ultrasonography

Ultrasonographic appearance of simple renal cyst is that of a sonolucent, round lesion with thin walls, smooth contour, displaying through transmission (Fig. 1). The presence or absence of septations, calcifications, thickening of the cyst wall, and soft-tissue nodules can be assessed using ultrasonography.

Computed Tomography

With the increase in cross-sectional imaging studies, computed tomography has become a more reliable modality for diagnosing renal cysts and differentiating them from other renal lesions such as a solid neoplasm.

FIGURE 1 ■ Renal ultrasound of a patient with multiple simple renal cysts. Note the sonolucent nature of cysts displaying through transmission with thin walls, absence of nodules, septations, or calcifications.

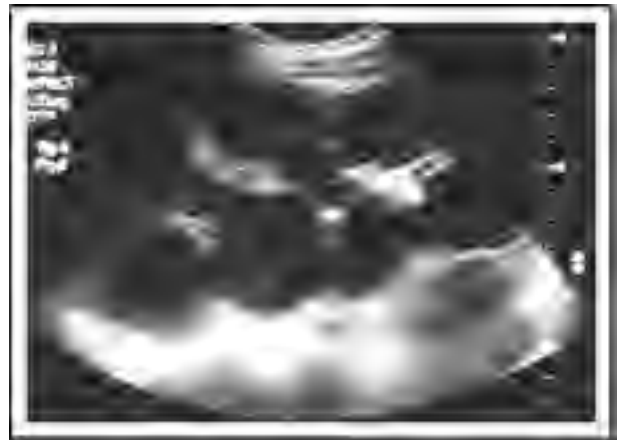
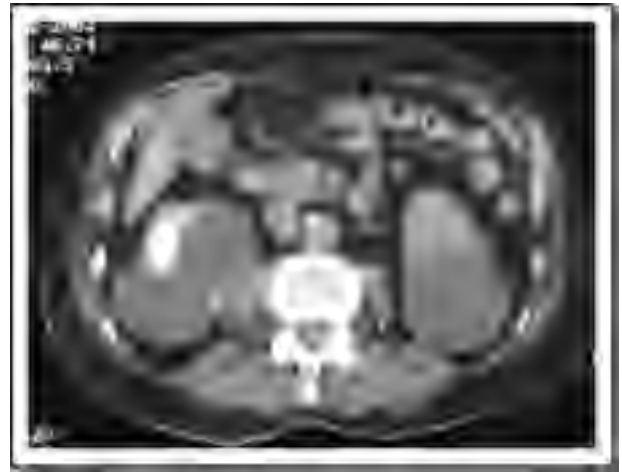
FIGURE 2 ■ Contrast enhanced computed tomographic image of a patient with left peripheral renal cyst and right peripelvic renal cysts. Note: The peripelvic cysts are causing compression and obstruction of the collecting system. No enhancement within these cysts was noted after intravenous contrast administration.



The computed tomography criteria for a simple renal cyst include

- Homogeneous appearance of near water density;
- Thin or imperceptible wall when the cyst projects beyond the renal outline;
- No enhancement with intravenous contrast; and
- A smooth cyst-parenchymal interface (Fig. 2).

Measurement of Hounsfield units within a simple renal cyst confirms the presence of water density (Hounsfield units of 0–20). Comparison of Hounsfield units prior to and following intravenous contrast is also helpful in differentiating a simple fluid-filled cyst (no significant enhancement postcontrast) from a hyperdense cyst (precontrast Hounsfield units higher than water density but no significant enhancement postcontrast) or a solid-enhancing mass (postcontrast enhancement difference of $> +10$ Hounsfield units). Like with ultrasound, computed tomography provides information regarding the presence or absence of septations, mural nodules, and calcifications. Bosniak classification makes use of this information for categorizing renal cystic lesions with respect to risk of malignancy (Table 1) (17). Such classification ranges from Bosniak I lesions (i.e., simple benign renal cyst) to Bosniak IV lesions (i.e., highly suspicious for cystic renal neoplasm). For patients with a known history of autosomal dominant polycystic kidney disease, von Hippel-Lindau syndrome, tuberous sclerosis, or acquired cystic renal disease, each cyst should be evaluated separately to determine the likelihood of malignancy. Two- and, more recently, three-dimensional computed tomography images provide excellent anatomic information of renal units as well as the proximity of the renal cyst(s) to surrounding structures (e.g., spleen, liver, lung, adrenal, small and large bowel, renal vessels, or collecting system). Review of such information can prove useful when planning therapeutic intervention such as percutaneous, laparoscopic, or open surgical drainage of a renal cyst.

Enhancement of a renal lesion following the administration of gadolinium suggests the likelihood of a solid neoplasm, whereas a simple renal cyst does not enhance and appears homogeneous with low signal on T1-weighted images and high signal on T2-weighted images.

Magnetic Resonance Imaging

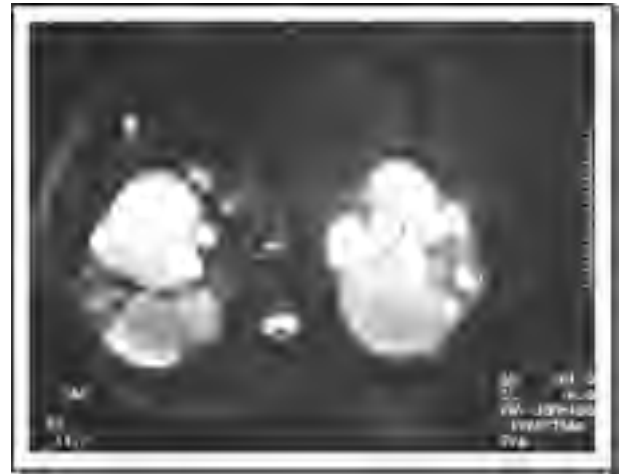
Magnetic resonance imaging with intravenous gadolinium can be used in patients who are unable to receive iodinated contrast due to renal insufficiency or dye allergy.

Enhancement of a renal lesion following the administration of gadolinium suggests the likelihood of a solid neoplasm, whereas a simple renal cyst does not enhance and appears homogeneous with low signal on T1-weighted images and high signal on T2-weighted images (Fig. 3).

TABLE 1 ■ Bosniak Criteria for Classification of Renal Cysts Based on Computed Tomographic Findings

Type	Calcifications	Septations	Wall	Enhancement
I	None	None	Thin	None
II	Minimal	Few	Thin	None
III	Moderate	Multiple	Increased thickness	None
IV	Coarse with nodules	Numerous and irregular	Thick	Yes

FIGURE 3 ■ T2-weighted magnetic resonance image of a patient with autosomal dominant polycystic kidney disease. Note: The cysts appear homogeneous and bright, consistent with fluid density similar to the cerebral spinal fluid. Note that virtually the entire renal parenchyma of both kidneys is replaced by numerous cysts of varying sizes. No enhancement was noted within these cysts after gadolinium administration.



Recent reports suggest that magnetic resonance imaging may in fact identify additional findings (e.g., septations, wall thickening, or enhancement) not seen on computed tomography, which may lead to an upgraded Bosniak classification and therefore affect clinical management (18).

Symptoms

The vast majority of renal cysts are asymptomatic and ordinarily do not require treatment. Renal cysts that grow and obstruct portions of the collecting system, compress normal renal parenchyma, stretch the renal capsule, or spontaneously hemorrhage can cause symptoms. These symptoms include flank or abdominal pain, hematuria, hypertension, infection, or obstructive uropathy (2). In cases of extremely large and/or multiple cysts, such as in patients with autosomal dominant polycystic kidney disease, a palpable abdominal mass may be appreciated on physical examination.

Laparoscopic renal cyst ablation is indicated in patients with symptomatic, simple renal cysts, who have failed medical management (i.e., analgesics, nonsteroidal anti-inflammatory agents, narcotics, etc.). An initial attempt at percutaneous drainage with or without sclerosis should be performed prior to laparoscopic exploration and ablation.

Assessing change in symptoms following the reduction of cyst volume: initial percutaneous aspiration of the renal cyst(s) also determines which patients are more likely to gain benefit from laparoscopic ablation if the cyst and symptoms recur.

Prior abdominal surgery is not an absolute contraindication, but rather the site of prior surgery may alter the route of laparoscopic access (transperitoneal vs. retroperitoneal) that is chosen.

Indications and Contraindications

Laparoscopic renal cyst ablation is indicated in patients with symptomatic, simple renal cysts, who have failed medical management (i.e., analgesics, nonsteroidal anti-inflammatory agents, narcotics, etc.). An initial attempt at percutaneous drainage with or without sclerosis should be performed prior to laparoscopic exploration and ablation.

Because of the high incidence of cyst recurrence following simple percutaneous drainage, multiple sclerosing agents have been proposed, including the use of alcohol, tetracycline, minocycline, or povidone-iodine with variable success (5,19,20). These sclerosing agents should, however, be avoided in parapelvic cysts as scarring and strictures of the collecting system have been reported (5).

Assessing change in symptoms following the reduction of cyst volume: initial percutaneous aspiration of the renal cyst(s) also determines which patients are more likely to gain benefit from laparoscopic ablation if the cyst and symptoms recur (11).

A suggested treatment algorithm for managing symptomatic peripheral and peripelvic renal cysts is shown in Figure 4.

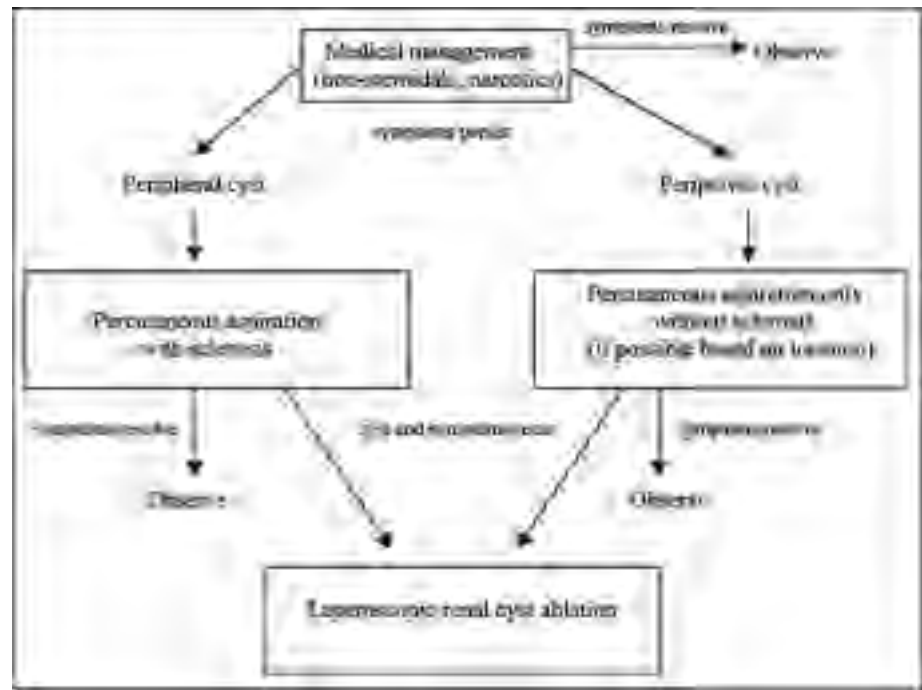
Patients with complex renal cystic disease such as autosomal dominant polycystic kidney disease, von Hippel-Lindau, acquired renal cystic disease, or tuberous sclerosis have a predisposition to malignancy. In addition, patients with autosomal dominant polycystic kidney disease frequently have flank/abdominal pain or worsening hypertension associated with enlargement of their renal cysts. Laparoscopy is an effective means of treating autosomal dominant polycystic kidney disease patients who suffer from painful renal cysts and evaluating indeterminate (Bosniak class II and III) renal cysts (21–24).

Laparoscopic renal cyst ablation is contraindicated in patients with uncorrectable bleeding diatheses and those with comorbid medical conditions that preclude general anesthesia.

Prior abdominal surgery is not an absolute contraindication, but rather the site of prior surgery may alter the route of laparoscopic access (transperitoneal vs. retroperitoneal) that is chosen.

Even in patients with a history of extensive prior abdominal surgery, a retroperitoneal access may be preferred as entry into and dissection within the peritoneal cavity is not necessary. Although extreme obesity may make transperitoneal

FIGURE 4 ■ Treatment algorithm for symptomatic simple peripheral and peripelvic renal cysts.



Laparoscopic renal cyst ablation should not be performed in the setting of an active urinary tract infection, pyelonephritis, or renal abscess.

access more difficult, often a retroperitoneal approach is still feasible because patients typically have relatively less fat along their retroperitoneum. Unlike with Bosniak class II or III (i.e., indeterminate lesions), Bosniak IV lesions (i.e., renal cystic lesion found radiographically to be highly suspicious for malignancy) should not be approached by laparoscopic ablation, but rather by laparoscopic or open, partial, or radical nephrectomy.

Laparoscopic renal cyst ablation should not be performed in the setting of an active urinary tract infection, pyelonephritis, or renal abscess.

PREOPERATIVE PREPARATION

Laboratory and Radiologic Tests

All patients should undergo routine laboratory testing including a complete blood count, platelet count, serum electrolytes, coagulation profile, urinalysis, and a type and screen. Any coagulopathy or urinary infection should be treated prior to proceeding with surgery. An electrocardiogram and chest radiograph should be obtained if indicated. All necessary radiologic tests (i.e., sonogram, computed tomography, and magnetic resonance imaging) should be made available for reference during the operation.

Special attention must be made to confirm the presence of a normal contralateral renal unit especially in cases where partial or radical nephrectomy may be required.

Patients should be instructed to discontinue all aspirin, ibuprofen, vitamin E, warfarin, and any other blood thinners at least 7 to 10 days prior to surgery.

Bowel Preparation

In cases of symptomatic simple renal cysts, no specific bowel preparation is required prior to surgery. However in patients with autosomal dominant polycystic kidney disease, the typically large-sized kidneys can at times occupy the majority of the peritoneal cavity. Therefore, use of a preoperative bowel preparation (e.g., citrate of magnesium) is advised to decompress the bowel and provide more working space during laparoscopy. Patients should partake of only clear liquids 24 hours prior to surgery and remain fasted after midnight the evening prior to surgery.

Informed Consent

Prior to performing laparoscopic renal cyst ablation, patients must be counseled on the possibility of bleeding, transfusion, anesthetic risks, infection, urinoma, adjacent organ injury (e.g., bowel, adrenal, liver, spleen, ureter, and renal vessels) as well as renal loss.

Special attention must be made to confirm the presence of a normal contralateral renal unit especially in cases where partial or radical nephrectomy may be required.

Patients must be aware of the possibility of failure to ablate all cysts, recurrence of cysts, and persistence of symptoms despite successful ablation of cyst(s). The possibility of partial or radical nephrectomy should be discussed, especially in cases of indeterminate renal cystic lesions in which the possibility of malignancy is suspected.

Patients must be aware of the possibility of failure to ablate all cysts, recurrence of cysts, and persistence of symptoms despite successful ablation of cyst(s). The possibility of partial or radical nephrectomy should be discussed with the patient especially in cases of indeterminate renal cystic lesions in which the possibility of malignancy is suspected.

As with any laparoscopic procedure, patients must understand the possibility of requiring conversion to an open surgery if deemed necessary.

Personnel and Equipment Configuration

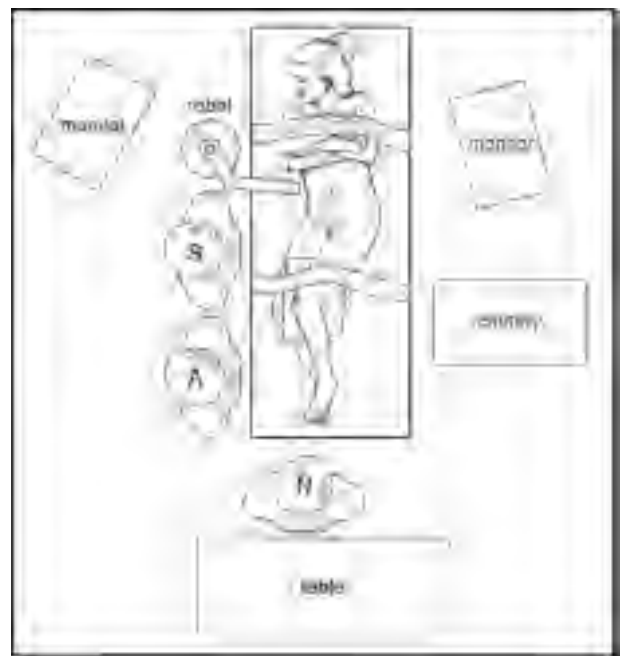
In addition to the operating surgeon, laparoscopic renal cyst ablation requires the following personnel: a surgical assistant, scrub technician, circulating nurse, and anesthesia team. During the transperitoneal approach, both the operating surgeon and the assistant stand on the abdominal side of the patient, contralateral to the targeted kidney. A typical operating room configuration for a left transperitoneal laparoscopic renal cyst ablation is shown in Figure 5. The scrub nurse and equipment table are situated near the surgical team at the foot of the table. The operating table must be adjustable and allow for lateral rotation. Two towers or cabinets equipped with a color video monitor mounted at eye level, light source, and carbon dioxide gas insufflator are placed on either side near the head of the table to allow the operating surgeon, assistant, and scrub technician to view and continuously monitor the surgical procedure. A video camera is attached to the laparoscope and its display projected on both video monitors. A standard electrocautery unit is placed either in front or behind the operating surgeon. If the AESOP^{®a} robotic arm is employed to stabilize and control the laparoscope, it should be attached to the operating table on the side contralateral to the kidney of interest and at the level of the patient's shoulders, taking great care to ensure that it does not come in contact with the patient's hands, arms, or shoulder during maneuvering of the robotic arm.

During the retroperitoneal approach, the surgeon and assistant stand facing the posterior flank of the patient with the side of the kidney of interest facing upward (Fig. 6). An operating table equipped with a kidney rest and that allows for flexion is important for the retroperitoneal technique.

Patient Positioning

Prior to patient positioning, the entire operating table is padded to reduce the risk of neuromuscular injuries. Sequential compression stockings are placed on the lower

FIGURE 5 ■ Operating room configuration for left transperitoneal laparoscopic renal cyst ablation. *Abbreviations:* S, surgeon; A, assistant; N, scrub nurse/technician.



^aIntuitive Surgical, Inc., Sunnyvale, CA.

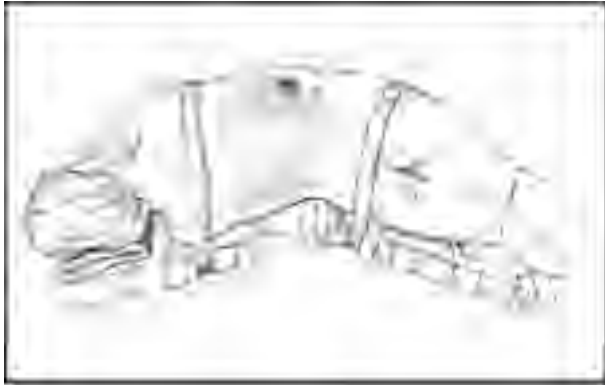

FIGURE 6 ■ Patient positioning and trocar configuration for right retroperitoneal laparoscopic renal cyst ablation. Note: X, 5-mm trocar; O, 10/12-mm trocar.

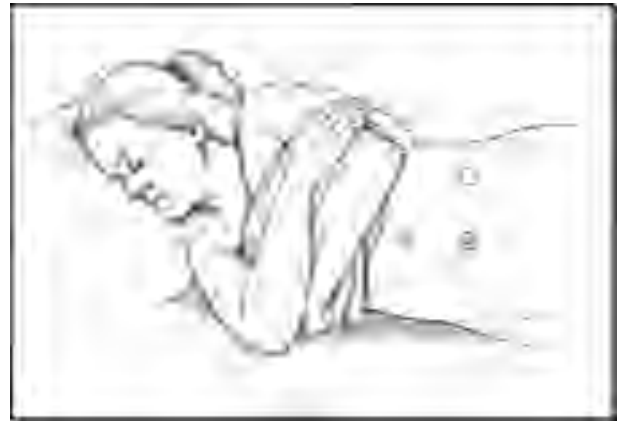

FIGURE 7 ■ Patient positioning and trocar configuration for left transperitoneal laparoscopic renal cyst ablation. Note: X, 5-mm trocar; O, 10/12-mm trocar.

extremities at the beginning of the operation and a single dose of intravenous cephazolin (1 g) is administered. Following induction of general endotracheal anesthesia, an orogastric tube and urethral catheter are placed to decompress the stomach and bladder, respectively.

Transperitoneal Approach

For the transperitoneal approach, the patient is placed in a modified flank position at an angle of 45° with the operating table, with the side of the kidney of interest facing upward. A sand bag is placed posterior to the ipsilateral flank for support. The arms are crossed over the chest and padded with egg crate padding or pillows (Fig. 7). This is to ensure that the patient's hands and arms do not rest upon the AESOP robotic arm. Alternatively if the AESOP robotic arm is not utilized, the arms can be kept outstretched on an arm board with sufficient padding placed between the arms. Neither an axillary roll nor flexion of the table is required.

The dependent leg is gently flexed at the knee, and pillows are placed between the legs. The patient is secured to the operating table with heavy cloth tape at the level of the shoulders and thighs. Additional egg crate sponge padding is placed over the shoulder and thighs to prevent abrasion and compression injuries as a result of the cloth tape. The operating room table is rotated to the extreme lateral limits to ensure that the patient is adequately secured to the table.

Retroperitoneal Approach

For the retroperitoneal approach, the patient is placed in a 90° full flank position, with the side of the targeted kidney facing upward. The patient's hips are positioned just below the break in the operating table. Flexion of the operating table at its break point is helpful in expanding the distance between the 12th rib and the iliac crest, thus providing the necessary room for trocar insertion. The kidney rest may also be elevated if needed (Fig. 6).

SURGICAL TECHNIQUE

Instrumentation and Equipment

Table 2 lists the laparoscopic instrumentation, equipment, and optional items recommended when performing laparoscopic renal cyst ablation.

Cystoscopy and Ureteral Stent Placement

Cystoscopy and ureteral stent placement is generally not required prior to laparoscopic cyst ablation of solitary, peripheral renal cysts. In patients with peripelvic cysts or autosomal dominant polycystic kidney disease, the location of the renal cyst(s) are often in close proximity to the collecting system in which case the ability to perform retrograde injection of indigo carmine or methylene blue–stained saline is useful to

In the transperitoneal approach, neither an axillary roll nor flexion of the table is required.

TABLE 2 ■ Recommended and Optional Instrumentation and Equipment for Laparoscopic Renal Cyst Ablation**Recommended:**

- 30° cystoscope lens, 20 French cystoscope sheath, and 5 French open-ended ureteral catheter (if cystoscopy and stent placement required)
- 7 French × 24 cm or 26 cm double pigtail ureteral stent
- Veress needle
- Visiport device^{TMa}
- 10/12-mm laparoscopic trocars (2 Nos.)
- 5-mm laparoscopic trocars (2 Nos.)
- 10-mm 0° and 30° laparoscopic lens
- Laparoscopic trocar-mounted dilator balloon
- Antifog lens solution and/or sterile hot water thermos
- 5-mm laparoscopic Debaquey forceps
- Laparoscopic suction/irrigator device and probe
- Laparoscopic monopolar electrocautery scissors
- Laparoscopic articulating ultrasound probe and unit
- 5-mm laparoscopic needle aspirator and 20–30 cc syringe
- 5-mm laparoscopic biopsy forceps
- 3-mm laparoscopic trocar and 2-mm blunt-tip grasper (for elevation of liver during right-sided transperitoneal technique)
- Laparoscopic argon beam electrocoagulator
- Oxidized cellulose gauze
- Fibrin glue sealant (in cases of collecting system injury)
- 10-mm laparoscopic vascular clip appliers
- Hand-held electrocautery device
- Carter-Thomason^{®b} fascial closure device
- 2-0, 3-0, 4-0, and 0-polyglactin suture (4-6)
- Steri-strips
- No. 15 scalpel blade
- 16 French urethral catheter
- 16 French orogastric tube
- Standard open nephrectomy tray and instrumentation with Bookwalter or Omni retractor (in case of open conversion)

Optional:

- 10-mm balloon-cuffed trocar
- 18-G spinal needle (for aspiration of renal cyst fluid)
- AESOP^{®c} Robotic Arm
- Electrocautery hook
- Bipolar electrocautery forceps
- Ultrasonic shears

^aUnited States Surgical Corporation, Norwalk, Connecticut, U.S.A.^bInlet Medical, Eden Prairie, Minnesota, U.S.A.^cIntuitive Surgical, Inc., Sunnyvale, California, U.S.A.

rule out entry into the collecting system. In such cases, an open-ended ureteral stent can be placed cystoscopically under fluoroscopic guidance prior to positioning the patient for laparoscopy.

Operative Steps

Left Transperitoneal Laparoscopic Technique

Table 3 lists the operative steps for a transperitoneal laparoscopic ablation of a simple renal cyst.

Step 1: Trocar Configuration and Insertion

Transperitoneal laparoscopic renal cyst ablation typically requires three trocars (5-mm, 10/12-mm, and 10/12-mm) as depicted in Fig. 7. After Veress needle insertion at the umbilicus and insufflation of the abdomen, a 10/12-mm trocar is placed at the umbilicus with the use of a Visiport^{®b} device and is utilized predominately for the laparoscope. Alternatively, an open Hasson technique can be used for initial trocar

^bU.S. Surgical Corp., Norwalk, CT.

TABLE 3 ■ Operative Steps for Transperitoneal Laparoscopic Renal Cyst Ablation

Step 1	Abdominal access and trocar placement
Step 2	Reflection of ipsilateral colon and exposure of kidney
Step 3	Exposure of renal cyst(s)
Step 4	Needle aspiration of renal cyst fluid
Step 5	Excision of renal cyst wall
Step 6	Biopsy of renal cyst base (if required) and coagulation of cyst base
Step 7	Packing of cyst defect
Step 8	Placement of retroperitoneal drain (if required)
Step 9	Retroperitonealization of kidney
Step 10	Exiting the abdomen and skin closure

insertion. Under laparoscopic view, a 5-mm trocar is placed below the xiphoid process in the abdominal midline, halfway between the umbilicus and xiphoid process. A second 10/12-mm trocar is placed just lateral to the rectus muscle at the level of the umbilicus to avoid injury to the epigastric vessels. These two trocars serve as the main working trocars. A 10-mm 30° laparoscopic lens is utilized during transperitoneal laparoscopic renal cyst ablation.

Step 2: Reflecting the Ipsilateral Colon and Exposure of the Kidney

With DeBakey forceps in the 5-mm trocar and laparoscopic electrocautery scissors placed in the left lower quadrant 10/12-mm trocar, the line of Toldt along the descending colon is sharply incised from the splenic flexure down to the pelvic inlet.

Electrocautery should be minimized during dissection of the colon in order to avoid accidental cautery injury to the bowel.

The colon and its associated mesentery are bluntly dissected with a suction irrigator device in a medial direction, exposing Gerota's fascia overlying the kidney. Great care must be taken to release the colorenal ligaments and develop the precise plane between Gerota's fascia and the mesentery of the colon.

Dissecting too close to the colonic mesentery can result in inadvertent injury to the mesenteric vessels and creation of a defect in the mesentery. If unrecognized or not repaired at the time of surgery, a mesenteric defect can result in an internal hernia in the postoperative period.

It may be necessary to divide the phrenocolic, lienorenal, and splenocolic ligaments in order to adequately expose the upper pole of the kidney and access superiorly located renal cysts. The operating table is maximally rotated toward the operating surgeon to allow the colon and small bowels to fall medial and away from the kidney, thus providing optimum exposure of the kidney and renal cyst(s) (Fig. 8).

When treating anteriorly located renal cysts, division of the lateral attachment of the kidney is not necessary and therefore these attachments should be maintained. For lateral or posteriorly located renal cysts, the lateral attachments of the kidney are released allowing the kidney to be rotated medially about its hilum. This provides the necessary exposure of the posterolateral surface of the kidney.

Alternatively, the retroperitoneal technique may be used for renal cysts located strictly at the posterior surface of the kidney (see the section entitled Retroperitoneal Laparoscopic Technique). Dissection and exposure of the renal vessels, pelvis, and ureter are typically not required during management of simple, nonhilar, peripheral renal cysts.

Step 3: Exposure of Renal Cyst(s)

For an exophytic renal cyst, the location of the cyst is often denoted by a bulge in the contour of the kidney. Gerota's fascia and perirenal fat overlying the renal cyst is excised sharply using electrocautery scissors, leaving an approximately 1-cm rim of exposed renal parenchyma around the cyst (Fig. 9).

For treatment of multiple renal cyst (e.g., autosomal dominant polycystic kidney disease), excision of most if not all of Gerota's fascia and perirenal fat may be required to expose all parenchymal surfaces and identify optimally all renal cysts.

For intraparenchymal cysts, intraoperative laparoscopic ultrasound may be required to identify their precise location.

Step 4: Needle Aspiration of Renal Cyst Fluid

For large renal cysts, needle aspiration of cyst fluid allows for decompression of the cyst and cytologic analysis of the aspirate. A 5-mm needle aspiration device is inserted and

Electrocautery should be minimized during dissection of the colon in order to avoid accidental cautery injury to the bowel.

Dissecting too close to the colonic mesentery can result in inadvertent injury to the mesenteric vessels and creation of a defect in the mesentery. If unrecognized or not repaired at the time of surgery, a mesenteric defect can result in an internal hernia in the postoperative period.

When treating anteriorly located renal cysts, division of the lateral attachment of the kidney is not necessary and therefore these attachments should be maintained. For lateral or posteriorly located renal cysts, the lateral attachments of the kidney are released allowing the kidney to be rotated medially about its hilum. This provides the necessary exposure of the posterolateral surface of the kidney.

For treatment of multiple renal cyst (e.g., autosomal dominant polycystic kidney disease), excision of most if not all of Gerota's fascia and perirenal fat may be required to expose all parenchymal surfaces and identify optimally all renal cysts.



FIGURE 8 ■ Mobilization of colon and exposure of Gerota's fascia and kidney. The contour of a small middle pole and large lower pole renal cyst can be seen.



FIGURE 9 ■ Excision of Gerota's fascia and perirenal fat overlying lower pole renal cyst.

Aspirated fluid from a benign renal cyst is typically straw colored and if bloody or purulent, the possibility of a malignancy or infection should be considered, respectively.

Only the anterior wall (i.e., extrarenal portion) of the cyst is generally excised, because efforts to remove the lining of the base of the cyst can result in parenchymal bleeding.

the fluid is aspirated using a 20 to 30 cc syringe (Fig. 10). Alternatively, an 18-G spinal needle may be placed percutaneously under laparoscopic view to drain the cyst.

Aspirated fluid from a benign renal cyst is typically straw colored and if bloody or purulent, the possibility of a malignancy or infection should be considered, respectively.

Step 5: Excision of Renal Cyst Wall

With the cyst decompressed, the exposed anterior wall of the renal cyst is excised sharply with electrocautery scissors at its junction with the renal parenchyma (Fig. 11). Point electrocautery may be required for hemostasis. The cyst wall is then sent for permanent histopathologic analysis.

Only the anterior wall (i.e., extrarenal portion) of the cyst is generally excised, because efforts to remove the lining of the base of the cyst can result in parenchymal bleeding.

Step 6: Biopsy and Coagulation of Renal Cyst Base

Following excision of the cyst wall, the base of the cyst should be inspected carefully for the presence of suspicious lesions or nodules. These regions may be biopsied

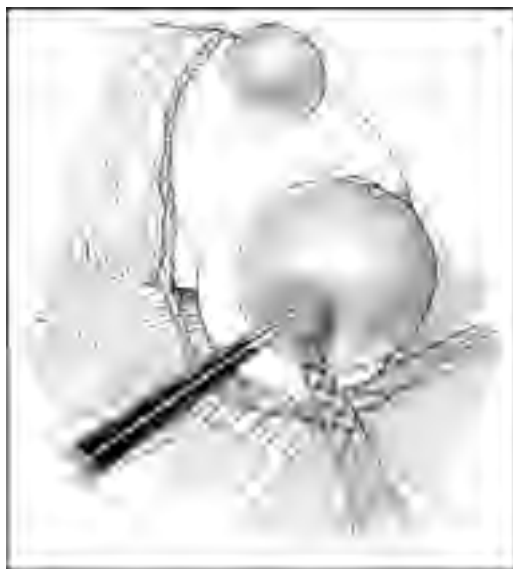


FIGURE 10 ■ Needle aspiration of renal cyst fluid.



FIGURE 11 ■ Excision of exposed renal cyst wall.

Great care must be taken to avoid entry into the collecting system when performing biopsies, especially in cysts in close proximity to the collecting system. If violation of the collecting system is suspected, retrograde instillation of methylene blue or indigo carmine–stained saline via a previously placed ureteral stent can be performed and the collecting system sutured closed with 2-0 or 3-0 polyglactin suture.

In cases where malignancy is noted on frozen section analysis, a partial or radical nephrectomy can be immediately performed either laparoscopically or by open surgery, depending on the skill and experience of the surgeon.

The kidney, ablated renal cyst(s), and drain are thus retroperitonealized, aiding in the containment and management of a postoperative urinoma or hematoma if one were to occur in the postoperative setting.

using a 5-mm laparoscopic biopsy forceps (Fig. 12) and sent for frozen section histopathologic analysis.

Great care must be taken to avoid entry into the collecting system when performing biopsies, especially in those cysts that are in close proximity to the collecting system. If violation of the collecting system is suspected, retrograde instillation of methylene blue or indigo carmine–stained saline via a previously placed ureteral stent can be performed and the collecting system sutured closed with 2-0 or 3-0 polyglactin suture.

If the collecting system defect is large, fibrin glue sealant may also be applied as a secondary measure following suture placement. In cases where collecting system entry is confirmed, a closed-suction drain is left at the conclusion of the operation and the open-ended ureteral stent is exchanged for an indwelling stent. Limited coagulation of the base of the renal cyst may be performed using either monopolar electrocautery or a laparoscopic argon beam coagulator (Fig. 13), avoiding direct fulguration of the collecting system.

In cases where malignancy is noted on frozen section analysis, a partial or radical nephrectomy can be immediately performed either laparoscopically or by open surgery, depending on the skill and experience of the surgeon.

Step 7: Packing of Renal Cyst Defect

Suture fixation of perirenal fat or omentum into the cyst cavity can act as a wick to prevent reaccumulation of cyst fluid. Alternatively oxidized cellulose gauze can be placed within the cyst defect (Fig. 14).

Step 8: Drain Placement

For large cysts, infected cysts, or if entry into the collecting system is suspected, a closed suction drain can be left in place for one to two days. The drain can be inserted through a preexisting 10/12-mm trocar and brought out through a separate posterolateral incision site. The drain holes should rest in a dependent position relative to the renal cyst (Fig. 14).

Step 9: Retroperitonealization of Kidney

Upon completion of the renal cyst ablation and after meticulous hemostasis is accomplished, the ipsilateral colon can be brought back over the kidney and reattached to the abdominal sidewall, reconstituting the line of Toldt. This can be accomplished using 2-0 polyglactin sutures (Fig. 15).

The kidney, ablated renal cyst(s), and drain are thus retroperitonealized, aiding in the containment and management of a postoperative urinoma or hematoma if one were to occur in the postoperative setting.



FIGURE 12 ■ Biopsy of lesion at cyst base using laparoscopic biopsy forceps.



FIGURE 13 ■ Argon beam coagulation of renal cyst base.

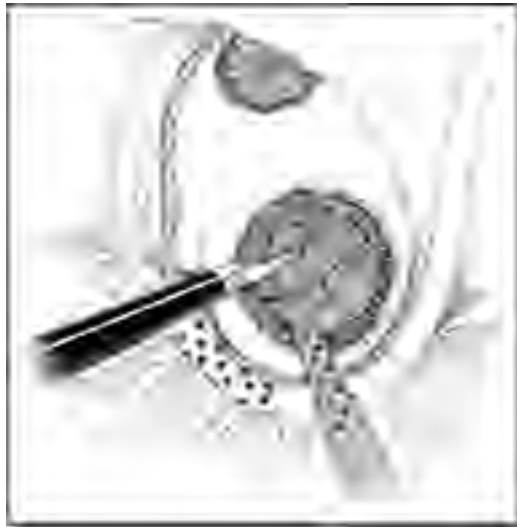

FIGURE 14 ■ Packing of renal cyst defect with oxidized cellulose gauze. The smaller midpole cyst has already been ablated and packed. A retroperitoneal drain can be placed medial and inferior to the kidney, if entry and repair of the collecting system are required.

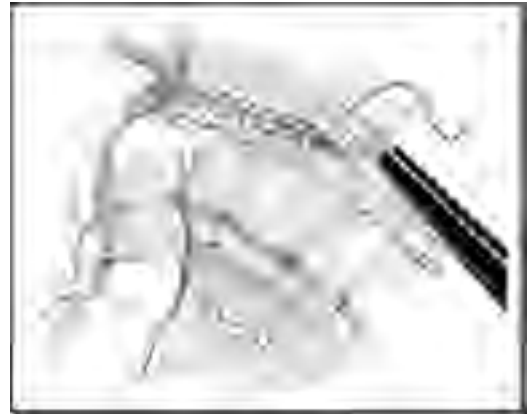

FIGURE 15 ■ Retroperitonealization of kidney and drain.

Step 10: Exiting the Abdomen and Skin Closure

Final inspection of the surgical site is performed under low insufflation pressures (e.g., 5–10 mmHg) to assess for residual bleeding. The 5-mm trocar is removed under laparoscopic view and all 10/12-mm trocar sites are closed using the Carter-Thomason^{®c} fascial closure device with 0-polyglactin suture. The skin incisions are closed with continuous 4-0 polyglactin subcuticular sutures followed by steristrips.

Right Transperitoneal Laparoscopic Technique

For a right-sided transperitoneal laparoscopic renal cyst ablation, trocar configuration is the mirror image of that used for a left-sided technique (i.e., the second 10/12-mm trocar is placed lateral to the right rectus muscle with all other trocars remaining the same). The ascending colon is reflected medially and for cysts located near the hilum, reflection of the duodenum may be required. A combination of blunt and sharp dissection of the attachments between the duodenum and kidney (Kocher maneuver) is performed with avoidance of electrocautery. For cysts located along the superior pole of the kidney, sharp release of the coronary ligament of the liver allows for anterior retraction of the right lobe of the liver for exposure to the upper pole of the kidney. A 3-mm or 5-mm additional trocar may be placed two to three fingerbreadths superior to the existing 5-mm trocar to allow for insertion of a laparoscopic instrument or grasper for liver retraction. The subsequent steps follow that of a left-sided dissection. Figure 16 demonstrates the computed tomography images of a patient with bilateral, multiple renal cysts causing hydronephrosis and symptoms of right flank pain, who underwent right laparoscopic renal cyst ablation of a parapelvic and large peripheral cyst with prompt resolution of obstruction and symptoms.

Retroperitoneal Laparoscopic Technique

The retroperitoneal technique requires the use of three trocars (5-mm, 10/12-mm, and 10/12-mm) and a 10-mm 0° laparoscopic lens. A 1.5-cm transverse incision is made just below the tip of the 12th rib using a No. 15-scalpel blade. After entry into the retroperitoneal space, blunt finger dissection can be used to sweep the peritoneum medially and retroperitoneal fat away from the tract in all directions. A 0° 10-mm laparoscopic lens loaded into a trocar-mounted balloon dilator device is inserted into the tract keeping anterior to the psoas muscle and posterior to Gerota's fascia. Approximately 800 to 1000 cc of air is inflated into the balloon (approximately

^cInlet Medical, Eden Prairie, MN.

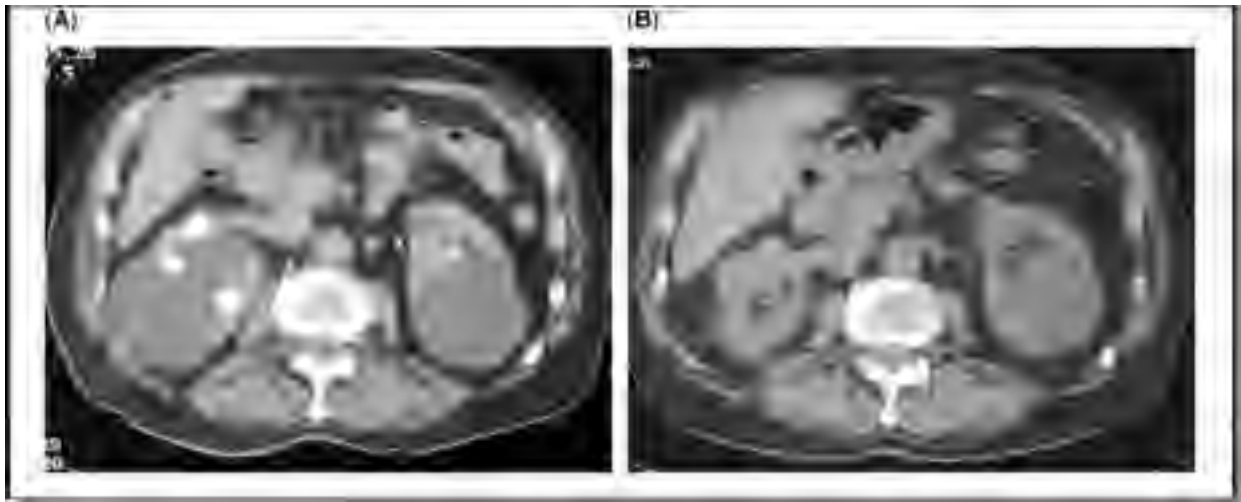


FIGURE 16 ■ Computed tomographic images before (A) and one month after (B) right laparoscopic renal cyst ablation of a peripelvic and large peripheral cyst causing obstruction and symptoms of right flank pain. Note complete ablation of right-sided cysts and resolution of obstruction. Left-sided cysts were left untreated because these were asymptomatic.

During the retroperitoneal approach, identification of as many of the retroperitoneal landmarks including the psoas and quadratus lumborum muscles, pulsations of the renal artery, ureter, vena cava (right-sided dissection), and aorta (left-sided dissection) is important to properly orient the surgeon to the location of the kidney and associated cysts.

40 pumps of the sphygmomanometer bulb) under laparoscopic view to develop the retroperitoneal working space. A second more cephalad inflation with the balloon dilator may be required to gain exposure and access upper-pole renal cysts. After removal of the balloon dilator, a 10-mm balloon-cuffed trocar can be inserted and inflated (30 cc air) snug beneath the abdominal fascia to prevent gas leakage during the operation. Alternatively, a standard 10/12-mm trocar may be inserted with 2-0 polyglactin sutures used to cinch the abdominal fascia snug with the trocar to minimize loss of pneumoperitoneum. A second 10/12-mm trocar is placed under laparoscopic view or alternatively digital guidance, along the anterior axillary line and three fingerbreadths cephalad to the iliac crest. One must be sure that the peritoneum has been adequately mobilized medially to prevent transperitoneal placement of this trocar. Lastly, a 5-mm trocar is placed at the junction of the lateral border of the erector spinae muscle and the underside of the 12th rib. The final trocar configuration is as shown in Fig. 6. The distance between trocars should ideally be at least three to four fingerbreadths to minimize trocar and instrument collision.

During the retroperitoneal approach, identification of as many of the retroperitoneal landmarks including the psoas and quadratus lumborum muscles, pulsations of the renal artery, ureter, vena cava (right-sided dissection), and aorta (left-sided dissection) is important to properly orient the surgeon to the location of the kidney and associated cysts.

As the working space is smaller and landmarks less distinct as compared to the transperitoneal technique, great care must be taken to avoid mistaking the liver (during right-sided dissection) or spleen (during left-sided dissection) for renal parenchyma. During the retroperitoneal technique, reflection of the colon is unnecessary and therefore following trocar placement and development of the retroperitoneal working space, the operative steps follow that are listed in Table 3 starting with Step 3.

Pros and Cons of Transperitoneal vs. Retroperitoneal Approach

The choice of the transperitoneal versus retroperitoneal approach relies on a number of factors including

1. The location and number of renal cyst(s)
2. History of prior abdominal surgery
3. Working space and familiarity with the surrounding anatomy
4. The surgeon's experience

Location and Number of Renal Cysts

The location of the renal cyst(s) is perhaps the most important factor in determining the surgical approach. The transperitoneal approach is best utilized for management of simple renal cysts located along the anterior surface of the kidney and peripelvic cysts.

Cysts located along the posterolateral surface of the kidney can be managed by the transperitoneal approach, but may be more efficiently approached by retroperitoneal access. For patients with multiple renal cysts (e.g., autosomal dominant polycystic kidney disease), exposure of the entire renal surface may be necessary and therefore the transperitoneal approach is preferred.

Prior Abdominal Surgery

In patients with a history of prior abdominal surgery, dense, complex adhesions may at times be encountered during transperitoneal dissection with difficulty in accessing and exposing the renal cysts as well as the potential for bowel injury. In such cases, a retroperitoneal approach may be advisable to avoid the need for intraperitoneal dissection and lysis of adhesions in a previously operated field.

Working Space, Familiarity with the Surrounding Anatomy, and Surgeon Experience

In general, the transperitoneal approach provides a larger working space as compared to that of retroperitoneoscopy. In addition, the transperitoneal approach may provide an operative view that is more familiar to most surgeons as compared to that of the retroperitoneal approach. However with experience, retroperitoneoscopy provides a more direct and rapid access especially to posteriorly located renal cysts, avoids violation of the peritoneum, and thus reduces the chances of intraperitoneal organ injury.

Technical Modifications for the Management of Complex Renal Cysts

The laparoscopic approach to ablating simple renal cysts is relatively straightforward; however for complex renal cystic lesions, there are technical modifications worthy of mention.

Peripelvic Renal Cysts

Although for peripelvic cysts both transperitoneal and retroperitoneal laparoscopic techniques are feasible, the transperitoneal approach provides optimum exposure of the renal hilum, a larger working space, and is therefore the approach of choice. Excision of Gerota's fascia and perirenal fat overlying the anteromedial aspect of the kidney is necessary to provide optimal visualization of the renal hilar structures.

Due to the close proximity of peripelvic cysts to the renal vasculature and collecting system, meticulous dissection must be carried out to avoid injury to these structures.

The branches of the renal vasculature and collecting system are often distorted and splayed by the peripelvic cysts, making them difficult to identify and differentiate from the cyst itself. Prior attempts at percutaneous drainage can also result in inflammation and scarring, making the tissue planes between the peripelvic cyst and hilar structures even less distinct. Placement of a ureteral catheter with retrograde injection of indigo carmine—or methylene blue—stained saline is useful in identifying the course of the splayed collecting system and for identification of collecting system injuries. Precise identification of renal vascular branches can be aided by the use of laparoscopic ultrasound with Doppler if available. Unlike with simple peripheral renal cysts, excision of the entire anterior cyst wall may not be feasible with peripelvic cysts. Overzealous attempts at cyst wall excision as well as cauterization of the cyst lining can lead to vascular and/or collecting system injury.

Only partial cyst wall excision is advisable with spot cauterization of the cyst edge. Suture fixation of a tag of perirenal fat, omentum, or polytetrafluoroethylene (Gore-Tex®) wick into the residual cyst cavity can encourage drainage and prevent reaccumulation of cyst fluid (9).

Autosomal Dominant Polycystic Kidney Disease

In patients with autosomal dominant polycystic kidney disease, kidney size is often large and can at times occupy the majority of the abdominal cavity, displacing adjacent organs.

A mechanical bowel preparation is recommended prior to cyst ablation in patients with autosomal dominant polycystic kidney disease to help decompress the bowels and optimize the already limited working space secondary to the large kidneys.

The transperitoneal approach provides the most exposure to the numerous cysts encountered in patients with autosomal dominant polycystic kidney disease and allows for access to cysts located both anteriorly and posteriorly; however success with retroperitoneal access has also been reported (21). Dissection of Gerota's fascia and perirenal fat off the entire renal surface and complete mobilization of the kidney are required to expose and gain access to as many cysts as possible.

Due to the close proximity of peripelvic cysts to the renal vasculature and collecting system, meticulous dissection must be carried out to avoid injury to these structures.

Only partial cyst wall excision is advisable with spot cauterization of the cyst edge. Suture fixation of a tag of perirenal fat, omentum, or polytetrafluoroethylene (Gore-Tex®) wick into the residual cyst cavity can encourage drainage and prevent reaccumulation of cyst fluid.

A mechanical bowel preparation is recommended prior to cyst ablation in patients with autosomal dominant polycystic kidney disease to help decompress the bowels and optimize the already limited working space secondary to the large kidneys.

- Large-to-medium cysts are punctured and drained, the exposed cyst wall excised, and the edge of the cyst cauterized. Through the defects of these unroofed cysts, deeper cysts that are identified are similarly unroofed and drained. The lining of the cyst cavities are not routinely cauterized or packed, but rather marsupialized with the peritoneal cavity.
- Small-to-tiny cysts can be merely incised, punctured, or cauterized.

The use of a laparoscopic ultrasound probe has proven very effective in facilitating the identification and treatment of deep-seated renal cysts, with one report citing a total of 635 cysts ablated in a single session.

All autosomal dominant polycystic kidney disease patients should undergo preoperative placement of a ureteral catheter with retrograde injection of dyed saline during and at the conclusion of cyst ablation to help identify any inadvertent entry into the collecting system.

Laparoscopic exploration offers a minimally invasive method of evaluating and treating renal cystic lesions. Patients must be aware of the possibility of requiring a partial or radical nephrectomy if malignancy is detected.

Transcutaneous ultrasound has been described to aid in intraoperative localization of deep-seated renal cysts in patients with autosomal dominant polycystic kidney disease. However, the pneumoperitoneum can interfere with the accuracy of cyst localization and therefore must first be decompressed (22).

The use of a laparoscopic ultrasound probe has proven very effective in facilitating the identification and treatment of deep-seated renal cysts, with one report citing a total of 635 cysts ablated in a single session (23).

In addition, intraoperative reference to preoperatively obtained imaging studies may be helpful in identifying and abating as many renal cysts as possible. Due to the large number of cysts located both peripherally and in proximity to the renal hilum, the risk of injury to the collecting system is increased.

All autosomal dominant polycystic kidney disease patients should undergo preoperative placement of a ureteral catheter with retrograde injection of dyed saline during and, at the conclusion of cyst ablation, to help identify any inadvertent entry into the collecting system.

Indeterminate Renal Cysts

With the use of contrast-enhanced cross-sectional imaging techniques, the vast majority of renal cystic lesions can be categorized radiographically as benign versus neoplastic. However, a small subset of lesions still remain indeterminate, making management difficult (24). As compared to the surgical management of most renal cysts, the management of indeterminate (i.e., Bosniak class II and III) lesions is more controversial with reports citing a 14% to 41% risk of malignancy (25,26).

Laparoscopic exploration offers a minimally invasive method of evaluating and treating these lesions. Patients must be aware of the possibility of requiring a partial or radical nephrectomy if malignancy is detected.

Fluid is aspirated from these indeterminate renal cysts during laparoscopic exploration and sent for cytologic analysis. Biopsies of suspicious regions (e.g., areas of discoloration, nodularity, or calcifications) along the base of the renal cyst are sent for frozen section histopathologic analysis. Partial or radical nephrectomy can be performed immediately if malignancy is detected on frozen section. A staged operative procedure may be required following receipt of final histopathologic analysis in cases where frozen section assessment is inconclusive. In the absence of malignancy, the cyst is managed similar to that of a simple cyst.

POSTOPERATIVE CARE

Patients are generally able to resume a clear liquid diet the evening of surgery and be advanced to a regular diet the following day. Antibiotic coverage can be maintained for a 24-hour period following surgery. Incisional pain may be controlled with intravenous narcotic medications and then switched to oral agents once a regular diet is started. Routine laboratory tests including a complete blood count and electrolytes may be drawn the first postoperative day with further blood test drawn only as needed on subsequent days. For uncomplicated cyst ablation cases, the urethral catheter is removed the day after surgery once the patient is fully ambulating and the patient discharged on postoperative day 2 or 3 once a regular diet is tolerated and pain is controlled with oral agents. In cases of a collecting system injury where placement of an internal ureteral stent and retroperitoneal drain were required at the time of surgery, the urethral catheter can be removed when the documented retroperitoneal drain output is minimal (usually by postoperative day 2 or 3), followed by removal of the retroperitoneal drain if its output does not subsequently increase. In the case of collecting system injury and repair, the ureteral stent is left in place for two to four weeks depending on the extent of injury and removed cystoscopically in the office.

In the rare case where the retroperitoneal drain output remains high, the urethral catheter should remain in place and the retroperitoneal drain taken off the bulb suction to discourage formation of a urinary fistula and to encourage antegrade drainage of urine with spontaneous closure of the collecting system. If stable, the patient may even be discharged home, and the drains subsequently managed in the office in one to two weeks.

In the case of collecting system injury and repair, the ureteral stent is left in place for two to four weeks depending on the extent of injury and removed cystoscopically in the office.

Repeat imaging studies (e.g., computed tomography) should be considered to confirm proper positioning of the ureteral stent within the collecting system in cases of persistent drainage despite the previously described maneuvers.

In the postoperative period, an urinoma and/or perinephric hematoma should be considered in the differential diagnosis in patients who exhibit persistent low-grade fevers ($>38.5^{\circ}\text{C}$), ileus, nausea and vomiting, and leukocytosis.

Repeat imaging studies (e.g., computed tomography) should be considered to confirm proper positioning of the ureteral stent within the collecting system in cases of persistent drainage despite the previously described maneuvers.

In the postoperative period, an urinoma and/or perinephric hematoma should be considered in the differential diagnosis in patients who exhibit persistent low-grade fevers ($>38.5^{\circ}\text{C}$), ileus, nausea and vomiting, and leukocytosis.

Contrast-enhanced computed tomography can be used to confirm the diagnosis. In cases of an unsuspected hematoma, conservative management with blood transfusion as needed is usually sufficient. Rarely is renal arteriography with selective embolization or reoperation required. In cases of a postoperative urinoma, a urethral catheter is reinserted as well as either an internal ureteral stent or percutaneous nephrostomy tube. For an undrained collection, percutaneous placement of a retroperitoneal drain may be required if one was not placed at the time of the initial operation.

If histopathologic and cytologic analysis of the cyst wall and fluid confirms the presence of malignancy, a staged partial or radical nephrectomy should be discussed with the patient. This can be performed either laparoscopically or through an open approach ideally within one week of the initial surgery.

MEASURES TO AVOID COMPLICATIONS

Intraoperative Complications

Bleeding during laparoscopic renal cyst ablation can occur during many steps of the operation including (i) mobilization and dissection of the kidney, (ii) cyst wall excision and fulguration, and (iii) dissection around the renal hilum.

During cyst wall excision, only the exposed, extrarenal portion of the cyst wall should be excised, because attempts at complete enucleation often result in bleeding from the underlying renal parenchyma. Following cyst wall excision, only limited coagulation of the base should be performed because deep fulguration can initiate bleeding from larger parenchymal vessels.

Bleeding

Bleeding during laparoscopic renal cyst ablation can occur during many steps of the operation including (i) mobilization and dissection of the kidney, (ii) cyst wall excision and fulguration, and (iii) dissection around the renal hilum.

Dissection of Gerota's fascia and perinephric fat and mobilization of the kidney, especially along the hilum and adrenal gland, can lead to bleeding. In cases of simple, solitary renal cyst, only limited dissection of Gerota's and perirenal fat should be performed, providing just enough exposure of the entire renal cyst and adjacent renal parenchyma. Extensive dissection of these tissues is unnecessary and can lead to unwanted bleeding. Only in cases of autosomal dominant polycystic kidney disease is complete, exposure of the renal surface generally required.

During cyst wall excision, only the exposed, extrarenal portion of the cyst wall should be excised, because attempts at complete enucleation often result in bleeding from the underlying renal parenchyma. Following cyst wall excision, only limited coagulation of the base should be performed because deep fulguration can initiate bleeding from larger parenchymal vessels.

Dissection of the renal hilum is generally not required except in cases of a peripelvic cyst or autosomal dominant polycystic kidney disease. Electrocautery and sharp dissection should be minimized during dissection around the renal hilum to avoid iatrogenic injury to the renal vessels. If bleeding from the renal vein occurs, temporary pressure applied to the point of bleeding often results in cessation of hemorrhage, if the site of injury is small. In the case of a large venous or arterial injury, pressure can be applied with prompt consideration for open conversion or nephrectomy if laparoscopic means (i.e., clips and sutures) fail to control the source.

Injury to the collecting system can occur during aggressive biopsy and fulguration of the base of the cyst wall or during attempts at cyst wall excision of a peripelvic or autosomal dominant polycystic kidney disease cysts.

The open-ended ureteral stent can be converted at the end of the case to an indwelling ureteral stent, which should be placed under fluoroscopic guidance to confirm proper positioning within the collecting system.

Collecting System Injury

Injury to the collecting system can occur during aggressive biopsy and fulguration of the base of the cyst wall or during attempts at cyst wall excision of a peripelvic or autosomal dominant polycystic kidney disease cysts.

When biopsy of the cyst base is indicated, only superficial samples should be taken especially in the case of peripelvic cysts or cysts located close to the collecting system. Reference to preoperative radiologic films may be helpful in assessing the depth of the cyst and its proximity to the collecting system. Direct coagulation of the collecting system should be avoided. As mentioned previously, placement of an open-ended ureteral stent at the start of the operation especially in the treatment of peripelvic or autosomal dominant polycystic kidney disease cysts can help identify the precise location of a collecting system injury and facilitate its repair.

The open-ended ureteral stent can be converted at the end of the case to an indwelling ureteral stent, which should be placed under fluoroscopic guidance to confirm proper positioning within the collecting system.

As in any laparoscopic renal procedure, injury to surrounding structures such as the bowel, spleen, liver, pancreas, pleura, and adrenals can occur.

If recognized, a small bowel injury may be repaired laparoscopically in multiple layers with interrupted 3-0 silk sutures; however, a bowel resection may be required.

Complications such as ileus, fever, urinary tract infection, urinary retention, atelectasis, pneumonia, cellulitis, renal insufficiency, neuromuscular injury, incisional hernia, transfusion, recurrence of cyst, persistence of pain, deep venous thrombosis, and pulmonary embolism can occur following laparoscopic renal cyst ablation.

To avoid the occurrence of urinoma, every attempt should be made to avoid inadvertent entry into the collecting system when performing renal cyst ablation and to repair overt injuries if they occur.

Persistence of pain following ablation of a solitary renal cyst may indicate an incorrect diagnosis as to the initial cause of pain. It is therefore recommended that patients undergo an initial trial of cyst aspiration with laparoscopic ablation reserved only for those patients whose cyst and symptoms recur.

Success of laparoscopic renal cyst ablation as defined by relief of symptoms (i.e., symptomatic success) averaged 97% when comparing all series, with 92% of patients showing no evidence of cyst recurrence on follow-up imaging studies (i.e., radiographic success).

Adjacent Organ Injury

As in any laparoscopic renal procedure, injury to surrounding structures such as the bowel, spleen, liver, pancreas, pleura, and adrenals can occur.

Use of a preoperative bowel preparation especially in more challenging cases such as autosomal dominant polycystic kidney disease can decompress the bowel, improve visualization, and reduce the chance of iatrogenic injury from laparoscopic instrumentation. During mobilization of the colon and small bowel, the use of electrocautery should be minimized to avoid accidental cautery injury to the bowel and subsequent delayed bowel perforation. During a right-sided procedure, great care must be taken during the dissection of the duodenum. Use of electrocautery or careless sharp dissection around the duodenum can result in duodenal injury and catastrophic consequences.

If recognized, a small bowel injury may be repaired laparoscopically in multiple layers with interrupted 3-0 silk sutures; however, a bowel resection may be required.

A general surgery consultation can be obtained to help assess the degree of injury and assist in its repair. Gentle blunt retraction of the liver and spleen is the rule to avoid laceration and bleeding from these organs. If bleeding occurs, a combination of pressure, argon beam coagulation, and oxidized cellulose gauze can manage most abrasion and laceration injuries to the liver and spleen.

Postoperative Complications

Complications such as ileus, fever, urinary tract infection, urinary retention, atelectasis, pneumonia, cellulitis, renal insufficiency, neuromuscular injury, incisional hernia, transfusion, recurrence of cyst, persistence of pain, deep venous thrombosis, and pulmonary embolism can occur following laparoscopic renal cyst ablation.

Two postoperative complications that are worthy of special mention are perinephric hematoma and urinoma. To reduce the occurrence of postoperative bleeding and hematoma, meticulous hemostasis should be confirmed at the conclusion of renal cyst ablation. As high carbon dioxide insufflation pressures can mask ongoing bleeding, the intra-abdominal carbon dioxide pressures should be reduced to 8 to 10 mmHg when assessing for bleeding points.

To avoid the occurrence of urinoma, every attempt should be made to avoid inadvertent entry into the collecting system when performing renal cyst ablation and to repair overt injuries if they occur.

Recurrence of a renal cyst can occur due to incomplete resection of the cyst wall due to surrounding anatomy (e.g., peripelvic cysts and autosomal dominant polycystic kidney disease) or incomplete ablation of all renal cysts. As mentioned previously, the use of intraoperative laparoscopic ultrasound can improve the safety and thoroughness of renal cyst ablation, even of deep-seated cysts. In addition, suture fixation of perirenal fat or a wick of omentum can prevent cyst fluid reaccumulation.

Persistence of pain following ablation of a solitary renal cyst may indicate an incorrect diagnosis as to the initial cause of pain. It is therefore recommended that patients undergo an initial trial of cyst aspiration with laparoscopic ablation reserved only for those patients whose cyst and symptoms recur (Fig. 4).

RESULTS

Simple Renal Cysts

As listed in Table 4, numerous series of laparoscopic ablation of symptomatic simple renal cysts can be found in the literature performed via both the transperitoneal and the retroperitoneal route (9–16,22,27,28). Most series, however, are limited due to a small number of patients with short follow-up. In those series with 10 or more patients, the mean operative time was 111 minutes (range, 75–164 minutes) and mean length of hospital stay was 3 days (range, 1.9–5.4) (9,10,12,14–16). A complication rate of 0% to 20% and a 0% mortality rate in these series compares favorably with a historical series of open renal cyst ablation reporting a complication rate of 37% and mortality rate of 1.6% (4). In a multi-institutional review of 139 laparoscopic renal cyst ablation cases, Fahlenkamp et al. found a total complication rate of 3.5% (28). Postoperative pain following laparoscopic renal cyst ablation is low with Rubenstein et al. finding that 67% of patients required no parenteral narcotics and 89% took five or fewer tablets of oral narcotics postoperatively (9). Median return to normal activity for their patients was seven days.

TABLE 4 ■ Results of Laparoscopic Ablation of Symptomatic Simple Renal Cysts

References	Cases	Access	OR time (min)	Complication rate (%)	LOS (day)	Follow-up (mo)	Symptomatic success (%)	Radiographic success (%)
Rubenstein et al. (9)	10 RP (1)	TP (9),	147	20	2.2	10	100	87
Guazzoni et al. (12)	20	TP	75	0	2.2	3–6	100	100
Okeke et al. (13)	7	TP	106	14.3	3.4	17.7	100	NA
Yoder and Wolf (11)	9	TP	145	22	2.3	55 (symptoms), 45 (radiologic)	78	89
Roberts et al. (10)	21	TP (13), RP (8)	164	14	1.9	15.8	100	95
Lifson et al. (27)	6	TP	137	15	2.2	33	100	NA
Ou et al. (15)	14	RP	78	7	4.2	8	100	93
Denis et al. (16)	10	TP (8), RP (2)	92	10	5.4	8.3	100	100
Wada et al. (14)	13	TP	NA	7.7	NA	3	NA	83
Brown et al. (22)	5	TP	147	0	2.0	12	80	80
Fahlenkamp et al. (28)	139	NA	NA	3.5	NA	NA	NA	NA
Average							97% (90/93)	92% (85/92)

Abbreviations: LOS, length of stay; OR, operating room; TP, transperitoneal; RP, retroperitoneal; NA, not available.

Success of laparoscopic renal cyst ablation as defined by relief of symptoms (i.e., symptomatic success) averaged 97% when comparing all series, with 92% of patients showing no evidence of cyst recurrence on follow-up imaging studies (i.e., radiographic success).

Interestingly, using strict criteria for symptomatic success by assessment with validated questionnaires and a visual analog pain scale, Yoder and Wolf found that only 78% of patients reported symptomatic relief of pain following laparoscopic renal cyst ablation (11).

From the limited series of laparoscopic management of peripelvic cysts reported in the literature, symptomatic and radiographic success rates averaged 89% and 75%, respectively.

Peripelvic Renal Cysts

The results of laparoscopic management of peripelvic cysts are somewhat lower than that reported with simple peripheral renal cysts (Table 5).

From the limited series of laparoscopic management of peripelvic cysts reported in the literature, symptomatic and radiographic success rates averaged 89% and 75%, respectively (10,11,29,30).

Roberts et al. reported on 11 patients with peripelvic cysts and found that operative time (233 minutes vs. 164 minutes, $p = 0.003$) and blood loss (182 mL vs. 98 mL, $p = 0.04$) were statistically greater than a concurrent group of 21 patients with peripheral renal cysts (10). There were no transfusions, open conversions, or radiographic recurrences in this series.

Taken together, these findings suggest that peripelvic cysts can be successfully treated by laparoscopic means; however, the longer operative time, greater blood loss, and lower symptomatic and radiographic success rates as compared to that of peripheral cysts are likely due to the more challenging location of peripelvic cysts lying in intimate association with the renal hilar structures.

Findings suggest that peripelvic cysts can be successfully treated by laparoscopic means; however, the longer operative time, greater blood loss, and lower symptomatic and radiographic success rates as compared to peripheral cysts, are likely due to the more challenging location of peripelvic cysts, lying in intimate association with the renal hilar structures.

TABLE 5 ■ Results of Laparoscopic Ablation of Symptomatic Peripelvic Renal Cysts

References	Cases	Access	OR time (min)	Complication rate (%)	LOS (day)	Follow-up (mo)	Symptomatic success (%)	Radiographic success (%)
Yoder and Wolf (11)	9	TP	163	0	2.3	45.9 (symptoms), 14.2 (radiologic)	78	55
Roberts et al. (10)	11	TP (7), RP (4)	233	9	2.7	22.4	100	100
Hoening et al. (29)	4	TP (3), RP (1)	338	25	2.75	13.5	75	50
Doumas et al. (30)	4	TP	155	25	2.7	23	100	75
Average							89% (25/28)	75% (21/28)

Abbreviations: LOS, length of stay; OR, operating room; TP, transperitoneal; RP, retroperitoneal; NA, not available.

TABLE 6 ■ Results of Laparoscopic Ablation of Symptomatic Autosomal Dominant Polycystic Kidney Disease

References	Cases	Access	OR time (min)	Complication rate (%)	LOS (day)	Follow-up (mo)	Symptomatic success (%)
Dunn et al. (23)	21	TP	330	33	3.2	26.4	87 (initial), 73 (at 2 yr)
Elashry et al. (21)	5	TP (1), RP (4)	207	0	2.4	9	90
Brown et al. (22)	8	TP	164	0	<2	12–28	75 (initial), 50 (at 16 mo)
Lifson et al. (27)	11	TP (10), RP (1)	137	9	2.2	26	90 (initial), 57 (at 2 yr)
Teichman and Hulbert (32)	6 RP (1)	TP (5),	180	33	3	6–40	83
Chehval and Neilsen (33)	3	TP	NA	0	2.3	16.7	100

Abbreviations: LOS, length of stay; OR, operating room; TP, transperitoneal; RP, retroperitoneal; NA, not available.

Autosomal Dominant Polycystic Kidney Disease

In patients with autosomal dominant polycystic kidney disease, flank and/or abdominal pain are the most common presenting symptom and have been noted in 60% of autosomal dominant polycystic kidney disease patients (31). These symptoms have been attributed to massive enlargement of the kidneys due to growth of a multitude of renal cysts with stretching of the renal capsule, traction on the renal pedicle, and/or obstruction of the collecting system. These cysts have also been associated with the development of hypertension. In the largest series of autosomal dominant polycystic kidney disease cases to date, Dunn et al. reported on 15 patients who underwent a total of 21 laparoscopic ablation procedures (23). Advocating aggressive and thorough identification and treatment of as many cysts at the time of surgery, an average of 204 cysts were treated per procedure with a range of 11 to 635 cysts. Eighty-seven percent of patients reported symptomatic relief immediately following surgery and with a mean follow-up of 2.2 years; 73% reported, on average, a 62% improvement in preoperative pain.

As shown in Table 6, cumulative results of laparoscopic ablation in patients with autosomal dominant polycystic kidney disease suggest an initial symptomatic success rate of 75% to 100% and 57% to 73% at two years follow-up (21–23,27,32,33).

Hypertension remained unchanged or improved in 67% and renal function remained stable in 94% of patients in the series reported by Dunn et al. (23). The authors concluded that with extensive, bilateral laparoscopic renal cyst ablation in patients with autosomal dominant polycystic kidney disease, improvement in both pain and hypertension could be realized without compromising renal function. Furthermore, their early results favored bilateral versus unilateral cyst ablation. Extensive cyst ablation, however, is time consuming with an average operative time of 330 minutes.

Cumulative results of laparoscopic ablation in patients with autosomal dominant polycystic kidney disease suggest an initial symptomatic success rate of 75% to 100% and 57% to 73% at two years follow-up.

SUMMARY

- Laparoscopic renal cyst ablation is a minimally invasive technique that can be offered to patients who suffer from symptomatic simple renal cysts and who have failed previous conservative management and a trial of percutaneous drainage.
- In patients with symptomatic peripelvic renal cysts, overzealous attempts at complete cyst wall excision should be avoided. Only a portion of the exposed cyst wall should be removed with meticulous dissection used to prevent injury to hilar structures. Fixation of perirenal fat or omentum within the cyst cavity can aid in preventing cyst fluid reaccumulation and recurrence.
- Complete exposure and mobilization of kidneys in autosomal dominant polycystic kidney disease patients suffering from painful cysts are necessary to identify and ablate as many cysts as possible. Use of an intraoperative laparoscopic ultrasound probe can help identify and treat deep-seated cysts. Simultaneous bilateral renal cyst ablation should be performed when possible in patients presenting with bilateral symptoms.
- Preoperative placement of a ureteral catheter with retrograde injection of dyed saline in complex renal cyst cases such as peripelvic cysts and autosomal dominant polycystic kidney disease can help identify the precise location of collecting system injuries and facilitate their repair.
- Cytologic analysis of aspirated cyst fluid and histopathologic analysis of intraoperative biopsies of suspicious areas within the cyst cavity should be performed, especially in cases of indeterminate renal cystic lesions (e.g., Bosniak class II and III), to rule out malignancy.

ACKNOWLEDGMENT

The author would like to give special thanks to Robert F. Morreale for his outstanding medical illustrations.

REFERENCES

1. Laucks SP, McLachlan MSF. Aging and simple cysts of the kidney. *Br J Radiol* 1981; 54:12–14.
2. Amar AD, Das S. Surgical management of benign renal cysts causing obstruction of the renal pelvis. *Urol* 1984; 14:429–433.
3. Kretschmer HL. Solitary cysts of the kidney. *J Urol* 1920; iv:567–583.
4. Kropp KA, Grahack JT, Wendel RM, Dahl DS. Morbidity and mortality of renal exploration for cyst. *Surg Gynecol Obstet* 1967; 125:803–806.
5. Holmberg G, Hietala SO. Treatment of simple renal cysts by percutaneous puncture and instillation of bismuth-phosphate. *Scand J Urol Nephrol* 1989; 23:207–212.
6. Hulbert JC, Hunter D, Young AT, Castaneda-Zuniga W. Percutaneous intrarenal marsupialization of a perirenal cystic collection — endocystolysis. *J Urol* 1988; 139:1039–1041.
7. Kavoussi LR, Clayman RV, Mikkelsen DJ, and Meretyk S. Ureteronephroscopic marsupialization of obstructing peripelvic renal cyst. *J Urol* 1991; 146:411–414.
8. Hulbert JC, Shepard TG, Evans RM. Laparoscopic surgery for renal cystic disease. *J Urol* 1992; 147(suppl):443 (abstract 882).
9. Rubenstein SC, Hulbert JC, Pharand D, Schuessler WW, Vancaillie TG, Kavoussi LR. Laparoscopic ablation of symptomatic renal cysts. *J Urol* 1993; 150:1103–1106.
10. Roberts WW, Bluebond-Langner R, Boyle KE, Jarrett TW, Kavoussi LR. Laparoscopic ablation of symptomatic parenchymal and peripelvic renal cysts. *Urol* 2001; 58:165–169.
11. Yoder BM, Wolf JS Jr. Long-term outcome of laparoscopic decortication of peripheral and peripelvic renal and adrenal cysts. *J Urol* 2004; 171:583–587.
12. Guazzoni G, Montorsi F, Bergamaschi F, et al. Laparoscopic unroofing of simple renal cysts. *Urol* 1994; 43:154–159.
13. Okeke AA, Mitchelmore AE, Keeley FX, Timoney AG. A comparison of aspiration and sclerotherapy with laparoscopic de-roofing in the management of symptomatic simple renal cysts. *Br J Urol* 2003; 92:610–613.
14. Wada T, Kamiryo Y, Tsuchida M, Kato M. Laparoscopic unroofing of a renal cyst. *Hinyokikyo Kiyo* 1995; 41:861–865.
15. Ou YC, Yang CR, Chang YY, Kuo JH, Wu HC. The clinical experience of gaseous retroperitoneoscopic and gasless retroperitoneoscopy-assisted unroofing of renal cyst. *Zhonghua Yi Xue Za Zhi* 1997; 59:232–239.
16. Denis E, Nicolas F, Ben Rais N, et al. Laparoscopic surgical treatment of simple cysts of the kidney. *Prog Urol* 1998; 8:195–200.
17. Bosniak MA. The current radiologic approach to renal cysts. *Radiology* 1986; 158:1.
18. Israel GM, Hindman N, Bosniak MA. Evaluation of cystic renal masses: comparison of CT and MR imaging by using the Bosniak classification system. *Radiology* 2004; 231:365–371.
19. Liatsikos EN, Siablis D, Karnabatidis D, et al. Percutaneous treatment of large symptomatic renal cysts. *J Endourol* 2000; 14:257–261.
20. Ohkawa M, Tokunaga S, Orioto M, et al. Percutaneous injection sclerotherapy with minocycline hydrochloride for simple renal cysts. *Int Urol Nephrol* 1993; 25:37–43.
21. Elashry OM, Nakada SY, Wolf JS Jr., McDougall EM, Clayman RV. Laparoscopy for adult polycystic kidney disease: a promising alternative. *Am J Kidney Dis* 1996; 27:224–233.
22. Brown JA, Torres VE, King BF, Segura JW. Laparoscopic marsupialization of symptomatic polycystic kidney disease. *J Urol* 1996; 156:22–27.
23. Dunn MD, Portis AJ, Naughton C, Shalhav A, McDougall EM, Clayman RV. Laparoscopic cyst marsupialization in patients with autosomal dominant polycystic kidney disease. *J Urol* 2001; 165:188–189.
24. Koga S, Nishikido M, Inuzuka S, et al. An evaluation of Bosniak's radiological classification of cystic renal masses. *Br J Urol* 2000; 86:607–609.
25. Wolf JS. Evaluation and management of solid and cystic renal masses. *J Urol* 1998; 159:1120–1133.
26. Santiago L, Yamaguchi R, Kaswick J, Bellman GC. Laparoscopic management of indeterminate renal cysts. *Urol* 1998; 52:379–383.
27. Lifson BJ, Teichman JMH, Hulbert JC. Role and long-term results of laparoscopic decortication in solitary cystic and autosomal dominant polycystic kidney disease. *J Urol* 1998; 159:702.
28. Fahlenkamp D, Rassweiler J, Fornara P, Frede T, Loenig SA. Complications of laparoscopic procedures in urology: experience with 2,407 procedures at 4 German centers. *J Urol* 1999; 162:765–771.
29. Hoenig DM, McDougall EM, Shalhav AL, Elbahnasy AM, Clayman RV. Laparoscopic ablation of peripelvic renal cysts. *J Urol* 1997; 158:1345–1348.
30. Doumas K, Skrepetis K, Lykounas M. Laparoscopic ablation of symptomatic peripelvic renal cysts. *J Endourol* 2004; 18:45–48.
31. Gabow PA. Autosomal dominant polycystic kidney disease. *N Engl J Med* 1993; 329:332–342.
32. Teichman JMH, Hulbert JC. Laparoscopic marsupialization of the painful polycystic kidney. *J Urol* 1995; 153:1105–1107.
33. Chehval MJ, Neilsen C. Laparoscopic cyst decompression I polycystic kidney disease. *J Endourol* 1995; 9:281–282.

LAPAROSCOPIC SURGERY FOR CALCULOUS DISEASE: TECHNIQUE AND RESULTS

Ashok K. Hemal

Department of Urology, All India Institute of Medical Sciences, New Delhi, India and Vattikuti Urology Institute, Henry Ford Health System, Detroit, Michigan, U.S.A.

- INTRODUCTION/BACKGROUND
- PATIENT SELECTION: INDICATIONS AND CONTRAINDICATIONS
- PREOPERATIVE PREPARATION AND PATIENT POSITION
- TECHNIQUE
 - Transperitoneal Access
 - Retroperitoneal Access
- PYELOLITHOTOMY
 - Approach
 - Identification of the Upper Ureter
 - Dissection of the Renal Pelvis
 - Pyelotomy
 - Retrieval of the Stone from the Renal Pelvis
 - To Stent, Not to Stent, and How to Stent
 - Closure of Pyelotomy
 - Removal of the Stone from the Body
 - Exit and Port Closure
 - Postoperative Management
- PYELOLITHOTOMY WITH CONCOMITANT PYELOPLASTY
- ROBOT-ASSISTED PYELOLITHOTOMY AND PYELOPLASTY
- ANATROPHIC NEPHROLITHOTOMY
- REMOVAL OF URACHOVESICAL CALCULUS
- URETEROLITHOTOMY
 - Indications and Contraindications
 - Technique
 - Laparoscopic Ureterolithotomy: Why?
- RETROPERITONEAL VS. TRANSPERITONEAL NEPHRECTOMY FOR NONFUNCTIONING KIDNEYS DUE TO CALCULOUS DISEASE
- RETROPERITONEOSCOPIC NEPHRECTOMY FOR HYDRONEPHROTIC KIDNEY DUE TO URETEROPELVIC JUNCTION OBSTRUCTION WITH STONES
- LAPAROSCOPIC NEPHRECTOMY FOR XANTHOGRANULOMATOUS KIDNEYS
- LAPAROSCOPIC NEPHRECTOMY FOR PATIENTS WITH HISTORY OF PREVIOUS STONE SURGERY OR PERCUTANEOUS NEPHROSTOMY
- RETROPERITONEOSCOPIC NEPHROURETERECTOMY FOR NONFUNCTIONING KIDNEYS DUE TO CALCULOUS DISEASE
- PARTIAL NEPHRECTOMY
- BLADDER DIVERTICULECTOMY WITH STONE REMOVAL
- RESULTS
 - Results of Laparoscopic Surgery for Urolithiasis
 - Results of Laparoscopic Ureterolithotomy
 - Results of Laparoscopic Pyelolithotomy
- COMPLICATIONS
- SUMMARY
- REFERENCES
- COMMENTARY: D. Assimos

INTRODUCTION/BACKGROUND

More than a million cases of urolithiasis occur each year in the United States. Renal stones are one of the most painful disorders that a human can experience, and indeed have been known for centuries. Stones have been found in 7000-year-old Egyptian mummies. The management of calculous disease has changed with the advent of extracorporeal shock wave lithotripsy, percutaneous nephrolithotripsy, ureteroscopy with use of different fragmentation devices, and, recently, laparoscopy in the armamentarium of urologist (1).

The natural corollary of technical development has been the steady decline of open surgery in the management of stone disease. However, despite ever-expanding indications, the new technologies have not been able to completely replace open surgery (2).

On the contrary, there still exist some situations where open surgery may be the treatment of choice. This is not to say that open surgery is the "only option" but probably the "most suitable option" and in order to avoid considering open surgery as a salvage procedure only, it is important to critically evaluate these cases of calculous disease for potential management with laparoscopic surgery (3).

Wickham et al. were the first to describe an attempted removal of a ureteral calculus using the laparoscope in the retroperitoneum (4). Since then several studies have been

The natural corollary of technical development has been the steady decline of open surgery in the management of stone disease. However, despite ever-expanding indications, the new technologies have not been able to completely replace open surgery.

Although laparoscopic removal of stones from kidney, ureter, and bladder can be performed by the transperitoneal or extraperitoneal approach, the latter approach may have certain advantages. The primary advantages of retroperitoneoscopy in calculous disease are rapid access to the diseased retroperitoneal organ and avoidance of urine spillage (which can vary from mild infection to frank pus) into the peritoneal cavity.

The indications for laparoscopic ureterolithotomy, pyelolithotomy, pyelolithotomy with repair of uretero pelvic junction obstruction, nephrectomy, or nephroureterectomy for calculous disease are similar to that for open surgery.

The indications for laparoscopic nephrectomy or nephroureterectomy in calculous disease are nonfunctioning kidneys due to renal stones, ureteric stones, megaureter with secondary stones, and uretero pelvic junction obstruction with stones.

reported on laparoscopic management of calculous disease including ureterolithotomy (3,5–9), pyelolithotomy (10–14) nephrectomy and nephroureterectomy (12,15), and anatomic nephrolithotomy (16). Successful laparoscopic management of calculous disease can be done for a variety of indications (Table 1). The indications have not been clearly defined and may vary from center to center depending on the available expertise.

Although laparoscopic removal of stones from kidney, ureter, and bladder can be performed by the transperitoneal or extraperitoneal approach, the latter approach may have certain advantages. The primary advantages of retroperitoneoscopy in calculous disease are rapid access to the diseased retroperitoneal organ and avoidance of urine spillage (which can vary from mild infection to frank pus) into the peritoneal cavity (12).

Laparoscopic simple nephrectomy for the removal of nonfunctioning kidneys due to stone disease is an established procedure (15). However, the role of laparoscopic ureterolithotomy and pyelolithotomy is still controversial. To date, few comparative studies between laparoscopic and open ureterolithotomy are reported with clear advantages for the laparoscopic approach (5,17). There is only one report in the literature, comparing laparoscopic pyelolithotomy and percutaneous nephrolithotripsy (14).

Recently, robotic assistance has also been reported for staghorn stones and in cases of pyelolithotomy with pyeloplasty in patients of uretero pelvic junction obstruction with secondary renal stones (18).

Initial procedural steps such as preoperative preparation, patient position, and approach (transperitoneal vs. retroperitoneal) are almost similar for laparoscopic ureterolithotomy, pyelolithotomy, pyelolithotomy with pyeloplasty, and nephrectomy or nephroureterectomy in calculous disease. Hence, these steps have been described in common rather than separately with each procedure.

PATIENT SELECTION: INDICATIONS AND CONTRAINDICATIONS

The laparoscopic approach should be utilized in patients who have failed extracorporeal shock wave lithotripsy, percutaneous nephrolithotripsy, and ureteroscopy or in patients with unusual anatomy such as pelvic kidney, stones with uretero pelvic junction obstruction, and renal stone resistant to fragmentation.

The indications for laparoscopic ureterolithotomy, pyelolithotomy, pyelolithotomy with repair of uretero pelvic junction obstruction, nephrectomy, or nephroureterectomy for calculous disease are similar to that for open surgery.

However, complex staghorn stone with multiple secondary calculi, and patients requiring multistage percutaneous nephrolithotripsy or anatomic nephrolithotomy may not be suitable for laparoscopic intervention at this point in time except in hands of highly skilled surgeons (16).

The indications for laparoscopic nephrectomy or nephroureterectomy in calculous disease are nonfunctioning kidneys due to renal stones, ureteric stones, megaureter with secondary stones, and uretero pelvic junction obstruction with stones.

TABLE 1 ■ Indications of Laparoscopic Surgery in Calculous Disease

		Kidney	Ureter	Bladder
Indications	Ablative	Nephrectomy, nephroureterectomy for nonfunctioning kidneys	Lower-ureteral calculi with nonfunctioning kidneys	
	Reconstructive	Pyelolithotomy—failure of endoscopic management Partial nephrectomy—nonfunctioning pole requiring partial nephrectomy; duplex system with one nonfunctioning moiety	Ureterolithotomy for large/impacted upper, middle, or lower ureteral calculi; and stones in megaureter	Stone retrieval with diverticulectomy
Contraindications		Xanthogranulomatous pyelonephritis		

For most surgeons, the only absolute contraindication for laparoscopic nephrectomy is xanthogranulomatous pyelonephritis.

Nephrectomy is also suitable for patients with endstage renal disease due to urolithiasis necessitating pretransplant nephrectomy. Nonfunctioning kidneys due to calculous pyonephrosis, infected pyelonephritic kidneys due to stone disease, and failed shock wave lithotripsy therapy for renal stones are relative contraindications for laparoscopic nephrectomy, because of dense peri-renal adhesions, scarring and fibrosis as a consequence of inflammatory procedure. Occasionally, in such cases laparoscopic subcapsular nephrectomy should be contemplated. Although these are not suitable cases for the novice surgeon, a substantial number of these cases can be dealt with by experienced and skilled laparoscopic surgeons.

For most surgeons, the only absolute contraindication for laparoscopic nephrectomy is xanthogranulomatous pyelonephritis. Various indications for laparoscopic surgery for calculous disease are summarized in Table 1.

PREOPERATIVE PREPARATION AND PATIENT POSITION

Anticoagulants, including aspirin, are discontinued five to seven days prior to surgery. Patients with mandatory indications for coumadin are hospitalized for intravenous heparin conversion prior to surgery. Antibiotic prophylaxis, typically with a first-generation cephalosporin is administered. Lower extremity sequential compression devices are placed just prior to the induction of general anesthesia. Bowel preparation is not necessary, however, a laxative is given the night before.

The patient is positioned in a flank position with the kidney-bridge elevated to flatten out the lumbar region, and is tilted varying from 45° to 60° for transperitoneal access. For the retroperitoneal approach, the patient is placed in standard lateral decubitus kidney position (90°). A slight anterior tilt helps the bowel to be displaced anteriorly by gravity.

TECHNIQUE

Transperitoneal Access

Initial steps are similar to any transperitoneal laparoscopic procedure performed on the kidney: (i) *Reflection of the colon*: The peritoneum is divided lateral to the ascending or descending colon in the line of Toldt using the monopolar scissors. (ii) *Dissection of the pelvis and the upper ureter*: Once the colon is reflected, the lower renal pole is visualized and minimal dissection is performed until identification of the ureter laying parallel to the gonadal vessels. The ureter is dissected upward proximally toward the uretero pelvic junction, maintaining generous periureteral fat to maintain its blood supply. The renal pelvis is mobilized posteriorly for pyelolithotomy and circumferentially for pyeloplasty in conjunction with pyelolithotomy.

Retroperitoneal Access

Creation of Retroperitoneal Space

The success of the technique depends, to a large extent, on the safe and effective creation of the retroperitoneal space. The technique for accessing the retroperitoneum has been described in Chapter 10.

PYELOLITHOTOMY

The steps of pyelolithotomy are described in Table 2.

Approach

The choice to perform laparoscopic transperitoneal or retroperitoneal pyelolithotomy is often arbitrary and depends on the surgeon's preference, available expertise, and advanced laparoscopic skills for intracorporeal suturing.

The choice to perform laparoscopic transperitoneal or retroperitoneal pyelolithotomy is often arbitrary and depends on the surgeon's preference, available expertise, and advanced laparoscopic skills for intracorporeal suturing.

Identification of the Upper Ureter

Identification of the upper ureter is the first step toward laparoscopic pyelolithotomy. Mostly, it can be seen as soon as the laparoscope is inserted, especially in a slender patient. The ureter is grasped in the endoBabcock and traced toward the renal pelvis with gentle dissection. Usually dissection is avascular and an attempt should be made to preserve ureteral vasculatures.

TABLE 2 ■ Steps of Pyelolithotomy

Patient selection
Preoperative preparation and patient positioning
Technique
Transperitoneal access
Retroperitoneal access (creation of retroperitoneal space)
Placement of ports
Common steps
Approach
Identification of the upper ureter
Dissection of the renal pelvis (intrarenal or extrarenal)
Incision of renal pelvis
Retrieval of the stone from the renal pelvis
To stent or not to stent
Closure of pyelotomy
Removal of stone from the body
Exit and closure of the ports
Postoperative management

If the stone gets migrated proximally into a calyx or if there are preexisting stones in the calyces, a flexible nephroscope, cystoscope, or ureteroscope may be inserted through a laparoscopic trocar to remove these calculi under direct vision.

Dissection of the Renal Pelvis

Renal pelvis dissection is easy if there are no adhesions or inflammation, otherwise hook electrode or endoscissors are used to take down this fibrous tissue. Care should be taken to perform gentle handling of the renal pelvis to prevent dislodgement of the calculus into the intrarenal calyces. Dissection close to renal pelvis helps in avoiding inadvertent injury to posterior segmental branch of renal artery or any aberrant vessel. Usually, the large stone can be felt (some degree of tactile sensation).

If the pelvis is intrarenal, further dissection of peripelvic fibrofatty and fascial tissue is required to expose the renal sinus with the help of grasping forceps and hook electrode. The right angle forceps or blunt spatula can be used to create the avascular space around the pelvis within the renal sinus.

Pyelotomy

In the setting of an intrarenal pelvis, an additional instrument is needed to retract the posterior lip of the sinus. The extrarenal pelvis, however, rarely requires any retraction for its exposure. The pyelotomy is made on the pelvis using a laparoscopic knife or scissors. Occasionally, a grating sensation of the underlying stone can be felt.

The incision can be either linear or curvilinear depending upon the stone size and configuration, and the shape, location (intra or extra), and exposure of the pelvis.

Retrieval of the Stone from the Renal Pelvis

- If the stone is not impacted and of a large size, which is the typical scenario, the stone is removed intact using a 10 mm right-angled or Babcock forceps.
- If the stone is impacted, a 5 mm right-angled dissector is employed to free the stone from the posterior wall of the renal pelvis. Then the anterior surface of the stone is freed from the renal pelvis after gently lifting it up at its lower end. The stone is then elevated and rotated to extract it from the pelvicalyceal system.

Sometimes, an intrarenal calyceal extension of the stone may prevent the stone removal. In this situation, the cautery J-hook can be used to drag the stone down and subsequently twist, rotate, and angulate it to disengage from the calyceal opening. If the stone still cannot be extracted, an infundibulotomy is created with the J-hook electrode to release the stone.

If the pelvis is of large size and the stone is not seen, or if the stone is located near the calyx, laparoscopic inspection after retraction of renal pelvis, exploration with right angle forceps, and flushing with saline may be of help.

If the stone gets migrated proximally into a calyx or if there are preexisting stones in the calyces, a flexible nephroscope, cystoscope, or ureteroscope may be inserted through a laparoscopic trocar to remove these calculi under direct vision.

It is not unusual to have excessive peripelvic inflammation, adhesions, and fibrosis leading to difficulty in dissecting the ureter or renal pelvis, especially in patients who have undergone multiple extracorporeal shock wave lithotripsy sessions. In such situations, fluoroscopy or intraoperative laparoscopic ultrasound may be helpful in locating the stone.

To Stent, Not to Stent, and How to Stent

J-stenting is not required in a routine case of pyelolithotomy. In patients where preoperatively J-stenting has been done, we do not change the stent and proceed with the status quo situation.

In patients without a J-stent wherein J-stenting is deemed necessary, this can be accomplished in an antegrade fashion. We have used the following different techniques for antegrade stenting during pyeloplasty, ureterolithotomy, or pyelolithotomy: (i) Alken's needle insertion through one of the ports: The needle is directed toward the site of pyelotomy and a straight guidewire is steered through it into the bladder and a 4.8 French stent is passed over this guidewire into the bladder; (ii) percutaneous placement of a 14 French intravenous cannula and insertion of a guide wire which is passed into the bladder followed by the double J-stent; (iii) direct passage of a guidewire through the port and its manipulation into the bladder (sometimes the placement of an extra port may be necessary); and (iv) insertion of a premounted stent over a guidewire and held with a 5 mm Hem-O-Lok clip, which is unlocked once the stent has reached into the bladder, allowing safe removal of the guidewire.

Closure of Pyelotomy

The stones are centrally placed in the retroperitoneum for later removal. The edges of the renal pelvis are cleaned of blood clot, stone dust, and freshened if irregular prior to suture repair. The pyelotomy incision is closed with interrupted 4.0 Vicryl. We do not advocate leaving the pyelotomy incision open, thus minimizing urine leak.

Removal of the Stone from the Body

The stone is retrieved at the end of the procedure from the primary port with 10-mm forceps and extracted through the port. If it is a larger stone, it is entrapped in a plastic bag and extracted through an enlarged port site. This step is monitored by the laparoscope inserted from other port.

Exit and Port Closure

The spilled fluid and urine are aspirated from the abdominal cavity, which is inspected for any bleeding, flushed-out stones, and clots. Copious irrigation with antibiotic solution is performed. Hemostasis is confirmed and a Jackson-Pratt drain is left and laparoscopic exit completed.

Postoperative Management

The patient is allowed to ambulate and take liquids orally the same evening. Oral analgesics are advised according to need. Antibiotics are continued until removal of the drain and catheter. Typically, the patient is discharged from the hospital the next day. However, if there is urine leakage, abdominal distension, pain, or discomfort, the hospital stay is extended as necessary.

PYEOLITHOTOMY WITH CONCOMITANT PYELOPLASTY

It is not uncommon to find coexisting secondary renal stones as a sequela of uretero pelvic junction obstruction. In such cases, the pyelotomy incision should be performed very carefully because it will eventually be incorporated in the flaps reconfigured for laparoscopic pyeloplasty (13,19). The line of incision in the pelvis can be marked and the pelvis incised with endoscissors. The pelvis is not disconnected from the ureter until all stones are cleared and the ureter is spatulated. Care should be taken if there is a prior placed stent, so that the stent is not damaged or dislodged.

Occasionally, stone removal with rigid laparoscopic instruments becomes difficult and in such a situation, a flexible nephroscope, cystoscope, or ureteroscope can be used to retrieve caliceal stones.

Occasionally, stone removal with rigid laparoscopic instruments becomes difficult. If such a situation, a flexible nephroscope, cystoscope, or ureteroscope can be used to retrieve caliceal stones.

ROBOT-ASSISTED PYEOLITHOTOMY AND PYELOPLASTY

Feasibility of robot-assisted pyelolithotomy and concomitant pyeloplasty was evaluated (18). After docking the robot, the ipsilateral colon is reflected off the kidney and uretero pelvic junction is dissected free all around. An appropriate pyelotomy is created for stone extraction and subsequent fashioning of the flaps for reconstruction. The pyelotomy is started by opening the entire length of the anterior wall of the pelvis, using the endoscissors, 3 cm away from the parenchymal edge of the renal sinus. The interior of the renal pelvis was explored to easily view the stone and remove it with the aid of long tip forceps. The removed stones are kept in a safe place in the abdominal cavity. At the end of the procedure, the stones are placed within the endocatch bag and removed through one of the port sites. The uretero pelvic junction is transected and the ureter spatulated laterally. The apex of the spatulated ureter is anastomosed to the most dependant part of the renal pelvis with interrupted intracorporeal suturing using 4-0 Vicryl suture 10 cm in length. Then the anterior half of the ureteropelvic anastomosis is performed using a running suture. The posterior wall is repaired using another 4-0 Vicryl suture 10 cm in length in the same manner. Lastly, the remaining part of the trimmed renal pelvis is closed by continuous suture. Some authors have also evaluated the feasibility of robotic extended pyelolithotomy for treatment of renal calculi as an effective treatment alternative to percutaneous nephrolithotomy.

ANATROPHIC NEPHROLITHOTOMY

A novel technique of anatomic nephrolithotomy has been described in the porcine model by Kaouk et al. Synthetic stone formation and laparoscopic anatomic

nephrolithotomy was successful in all ten animals including one that underwent staged bilateral anatrophic nephrolithotomy (16). These authors have since performed anatrophic nephrolithotomy clinically in three patients.

REMOVAL OF URACHOVESICAL CALCULUS

Urachal anomaly in an adult is rare, as the majority of urachal remnant obliterate shortly after birth. However, a rare case of urachal calculus may be encountered and the stone can be safely and effectively removed with laparoscopic excision of the urachus containing the stone (20).

URETEROLITHOTOMY

Indications and Contraindications

Indications of laparoscopic ureterolithotomy include large, impacted, upper/mid/lower ureteric stones leading to obstruction, where other minimally invasive treatments have failed.

These patients have typically required open ureterolithotomy in the past. Smaller calculi are managed by endourologic techniques. Classically, the ureter is identified by visualizing ureteric peristalsis. The stone location is identified by seeing the stone bulge. Small ureteric stones are difficult to locate as the stone bulge may not be visible and no tactile feedback is provided by the laparoscopic approach. In such situations, intraoperative fluoroscopy or laparoscopic ultrasound may be very useful for stone localization.

Technique

Laparoscopic ureterolithotomy can be performed either by transperitoneal or retroperitoneal approach. The steps of ureterolithotomy are described in Table 3.

Retroperitoneal Approach

After port placement, the ureter is dissected gently to prevent proximal migration of the stone. Usually, the calculus is large and can be easily dissected with blunt dissector or forceps in one port and an atraumatic clamp in the other. The ureter is held with a Babcock or atraumatic ring clamp above the stone and the periureteric tissue is cleared prior to incising. A longitudinal ureterotomy is performed using a laparoscopic knife or endoshears. Following stone retrieval, the ureterotomy is closed with interrupted, intracorporeal free hand suturing using 4/0-polyglactin suture. The stone is retrieved through one of the 10 mm ports.

In our modified technique, we use just one 10 mm port and two or three 5 or 3 mm ports instead of all 10 mm ports used in the classic procedure. The 10 mm port is used for the laparoscope and the 5 or 3 mm ports are used for dissection, suction, and retraction. The operative steps of the procedure are the same as in the standard procedure. However, we do not place the stent priorly. After stone removal and temporary stone placement in the retroperitoneum, the ureterotomy is closed as described above. A 5 mm laparoscope is then passed through one of the 5 mm ports to locate the stone and grasping forceps passed through the primary port (camera-10 mm port) and intact stone is removed by pulling the stone along with the port. A 14-French JP drain is placed in the retroperitoneal space through the 5 mm port site.

If the stone is in the lower ureter, an additional port is required medial to the anterior superior iliac spine for retraction. A 30° laparoscope is of great help in dissecting the lower end of ureter harboring the stone. Two secondary ports are enough for retroperitoneoscopic ureterolithotomy; however, a third port is needed in an obese patient for retracting the peritoneum and the retroperitoneal fat for intracorporeal suturing of ureterotomy site. We did not notice any increase in the duration of postoperative drainage in group of patients undergoing ureterolithotomy with modified technique without stenting.

Transperitoneal Approach

The patient is placed in the 45° to 60° flank position with the kidney-bridge elevated. The primary port is placed at the lateral edge of rectus muscle at the level of umbilicus. Two secondary ports are placed in the anterior axillary line below the costal margin, in the anterior axillary line in the iliac fossa and a fourth port is placed if required. The colon

Indications of laparoscopic ureterolithotomy include large, impacted, upper/mid/lower ureteric stones leading to obstruction, where other minimally invasive treatments have failed.

TABLE 3 ■ Steps of Ureterolithotomy

Patient selection
Preoperative preparation and patient positioning
Technique
Transperitoneal access
Retroperitoneal access (creation of retroperitoneal space)
Placement of ports
Common steps
Approach
Identification of the ureter
Incision of ureter (ureterotomy)
Retrieval of the stone from the ureter
To stent or not to stent
Closure of ureterotomy
Removal of the stone
Exit and closure of the ports
Postoperative management

is reflected medially and the ureter is identified by visualizing the ureteric peristalsis and the stone bulge. A vertical incision is made over the stone bulge to remove the stone. The ureterotomy is then closed with interrupted, intracorporeal free hand suturing using 4/0 Vicryl suture.

Role of Stenting

Typically, a double J ureteric stent or open ended ureteric catheter is placed cystoscopically, then the patient position is changed for the laparoscopic ureterolithotomy. The preplaced stent also helps in identification of the ureter. Alternatively, the stent can also be placed intraoperatively under laparoscopic vision antegradely through one of the ports as described for pyelolithotomy.

Sometimes the stone is impacted and it is impossible to preplace a stent. In this circumstance, the J stent with a guide wire or open-ended ureteric catheter is retrogradely advanced up to and underneath the stone in the ureter. After stone retrieval, the ureteric stent is advanced into the renal pelvis under laparoscopic guidance. In some of these patients, we experienced difficult negotiation of the stent due to down slipping of the stent during position changing of the patient. Therefore, at the end of the procedure these patients were repositioned in lithotomy and the stent was inserted under fluoroscopic guidance. Because of this problem, in several subsequent cases we placed an end-hole ureteric catheter through which a guide wire was inserted up to the stone. After retrieval of the stone, the guide wire was advanced into the renal pelvis under laparoscopic vision, and a stent was advanced over the guide wire. The guide wire was introduced into the ureter through the ureteric catheter, even though it had slipped down a little during the change of patient position.

With increasing experience, we modified our technique again to make the procedure minimally invasive and cost effective. In patients where there is no history of stone impaction or any other absolute indication such as infected hydronephrosis, we do not place a J stent into the ureter at all. The ureterotomy is closed with 4/0-Vicryl by interrupted, intracorporeal suturing. The advantages are shorter operating time, avoidance of fluoroscopy, cost reduction, and reduced invasiveness since an additional procedure, e.g., initial cystoscopy for J stent placement and, later, for its removal is avoided. No increase in the duration of drainage or complication rate was noticed after this technical modification.

Laparoscopic Ureterolithotomy: Why?

The management of ureteric stones has evolved from open surgery to minimally invasive procedures such as ureteroscopy, extracorporeal shock wave lithotripsy, and percutaneous antegrade removal. The results of ureteroscopy are best for lower- and mid-ureteric stones. Park et al. reported a success rate for ureteroscopic stone removal of 75%, 94.6%, and 86.4% for proximal-, mid-, and lower-ureteric stones (21). Extracorporeal shock wave lithotripsy is suitable for managing ureteric stones of less than 1 cm (22); however, as the stone size increases, the chances of clearance decreases and the chances of multiple procedure increases. Koch et al. reported that up to 36% of patients require multiple sessions of extracorporeal shock wave lithotripsy and 46% require auxiliary procedures in order to get patients stone free besides the need for stent insertion and removal at a later date (23). Park et al. reported that the stone-free rate decreased from 84% to 42% when the stone was greater than 1 cm (20).

Percutaneous removal is indicated in patients with large stones in the upper ureter, but it is sometimes difficult to manage ureteric stones below the inferior border of the kidney. The results of mid- and lower-ureteric stones are even more dismal (24). In a series of percutaneous removal of ureteric stone, a complication rate of 43% was reported and 22% of patients required a supracostal puncture (25). Percutaneous removal is indicated only as a salvage procedure in those patients where extracorporeal shock wave lithotripsy or ureteroscopy have failed.

Laparoscopic ureterolithotomy is indicated for large impacted ureteric stones preferably in upper- and mid-ureter, as the results of extracorporeal shock wave lithotripsy and ureteroscopy are poor and require multiple sittings and auxiliary procedures. By contrast, laparoscopic ureterolithotomy achieves complete stone clearance in a single operative session in a minimally invasive manner.

Keeley et al. suggested that the ideal stone location for laparoscopic ureterolithotomy is the section of the ureter between the lower border of the kidney and the common iliac vessels, as more proximal stones are better managed percutaneously and stones below the iliac vessels by ureteroscopy (7). We did not find any difficulty in the

Laparoscopic ureterolithotomy is indicated for large impacted ureteric stones preferably in the upper- and mid-ureter, as the results of extracorporeal shock wave lithotripsy and ureteroscopy are poor and require multiple sittings and auxiliary procedures. By contrast, laparoscopic ureterolithotomy achieves complete stone clearance in a single operative session in a minimally invasive manner.

management of upper- and mid-ureteric stones, and also lower-ureteric stones have been managed successfully but require experience, skill, and patience.

RETROPERITONEAL VS. TRANSPERITONEAL NEPHRECTOMY FOR NONFUNCTIONING KIDNEYS DUE TO CALCULOUS DISEASE

The initial approach, retroperitoneal or transperitoneal, is the same as described for pyelolithotomy or ureterolithotomy. Subtle differences vary with the degree of perinephric inflammation encountered. In the absence of significant adhesions, we prefer to place the balloon inside Gerota's fascia because this allows rapid and easy dissection of the kidney. The hilum is then approached and the vessels clipped. Past history of pyelonephritis, evidence of renal scarring, perinephric adhesions, and pyonephrosis predominantly lead to dense perinephric adhesions which preclude safe and easy dissection, as the kidney is densely adherent to the posterior abdominal wall. Open conversions typically occur due to excessive bleeding and poor intraoperative progress. Because the adhesions are perinephric, the space external to Gerota's fascia is still relatively clear. The hilar vessels are approached first to minimize bleeding during the subsequent dissection of the kidney. It is important to avoid puncturing the kidney during mobilization lest infected material soil the operating space. Although the spillage is confined to retroperitoneum, thoroughly irrigation with antibiotics solution is important (12). Rarely, due to severe fibrotic adhesions, one may intentionally or unintentionally enter within the renal capsule, and resort to retroperitoneal subcapsular nephrectomy to complete the operation.

RETROPERITONEOSCOPIC NEPHRECTOMY FOR HYDRONEPHROTIC KIDNEY DUE TO URETEROPELVIC JUNCTION OBSTRUCTION WITH STONES

Retroperitoneoscopic nephrectomy is the ideal procedure for patients with poorly functioning, hugely dilated, or giant hydronephrotic kidneys due to stone disease, irrespective of patient age and type of renal anomaly.

Retroperitoneoscopic nephrectomy is the ideal procedure for patients with poorly functioning, hugely dilated, or giant hydronephrotic kidneys due to stone disease, irrespective of patient age and type of renal anomaly (26).

In these cases, careful placement of the primary port is important so as to avoid puncturing the kidney. An initial 1.5 cm incision below and posterior to tip of the 12th rib is made and deepened down to the thoracolumbar fascia. Digital dissection or dissection with the help of Clutton's urethral dilator is done parallel to the dilated kidney to make space for placement of the balloon. The balloon itself may be placed within or outside Gerota's fascia as per the situation. The balloon should not be inflated over 400 to 500 mL. Retroperitoneal space can be created initially toward the upper pole, then toward the lower pole. Once the space is created, the kidney should be dissected first as the tense hydronephrotic sac helps in identification of the perirenal plane. With the distended renal sac keeping the renal parenchymal surface stretched, dissection can be performed with easy sweeping movements. After initial dissection, the kidney is deflated (often it gets punctured) and further dissection carried out after retracting the kidney anteriorly with a triflanged retractor. In these cases, usually renal vessels are attenuated and can be clipped with titanium clips or Hem-O-Lok plastic clips.

LAPAROSCOPIC NEPHRECTOMY FOR XANTHOGRANULOMATOUS KIDNEYS

Xanthogranulomatous pyelonephritic kidneys require the most difficult and cumbersome dissection, as they are almost plastered in the retroperitoneum. Dissection is time consuming and complicated. If such a condition is diagnosed preoperatively, it may be better to deal with conventional open surgery. In most instances, xanthogranulomatous kidneys constitute a contraindication to laparoscopic surgery (27).

LAPAROSCOPIC NEPHRECTOMY FOR PATIENTS WITH HISTORY OF PREVIOUS STONE SURGERY OR PERCUTANEOUS NEPHROSTOMY

These patients are difficult candidates for laparoscopic nephrectomy. After initial dissection, control of the renal vessels should be attempted first so as to prevent troublesome bleeding. However, gradual, slow, and careful dissection is the key to success in these cases. In patients who have an indwelling percutaneous nephrostomy, after initial dissection, the nephrostomy tract should be divided because this allows more room for further dissection (27). In a recent series (28), the authors presented their experience

with transperitoneal laparoscopic pyelolithotomy in pediatric patients in whom percutaneous renal access failed and the stone burden warranted open intervention. In this series, a transperitoneal laparoscopic approach was used for pyelolithotomy in eight patients, three months to ten years old (mean age four years). Percutaneous access failed secondary to a nondilated system and/or an occluding lower pole calculus. A posterior pelviotomy was made. Stones in the renal pelvis were removed with rigid graspers under direct laparoscopic vision. A flexible cystoscope was introduced through a port if caliceal stones were present. The renal pelvis was reconstructed. A watertight anastomosis was verified. Average operative time was 1.6 hours (range, 0.8–2.3). Mean hospital stay was 2.15 days (range, two to three days). A range of one to three stones (median of 1) were removed and the mean stone burden was 2.9 cm². No intraoperative complications were noted. Stone analysis revealed three patients with calcium oxalate stones, one with a calcium phosphate stone, and four with cysteine stones. Stones recurred in one patient at a mean follow-up of 12 months (range, 3–20 months). Overall long-term stone-free rate was 87.5%.

RETROPERITONEOSCOPIC NEPHROURETERECTOMY FOR NONFUNCTIONING KIDNEYS DUE TO CALCULOUS DISEASE

After the initial dissection, control of renal pedicle and mobilization of the kidney, the table is tilted posteriorly to make the patient partly supine and a fourth port inserted medial to the anterior superior iliac spine. The distal ureter is dissected downward till the ureterovesical junction or until obstructing stone is identified where it can be divided after applying a clip. This technique has been found to be superior to open approach (29).

PARTIAL NEPHRECTOMY

Partial nephrectomy in a kidney for nonfunctioning segment or pole due to stone disease is indicated because of recurrent infection, inability to remove the stones, hydronephrosis, and parenchymal atrophy. In these cases, the demarcation of the tissue to be removed is usually evident. The atrophic parenchyma lining the dilated system can be further delineated. After preserving a strip of renal capsule, the parenchyma is divided at the observed line of demarcation. There is usually minimal bleeding from the renal surface, and clamping of renal artery is not necessary. Then renal parenchyma is closed with interrupted sutures of 1-0 Vicryl over Surgicel; in addition fibrin glue may be used. Usually partial nephrectomy in these cases is easier in comparison to partial nephrectomy for tumor.

BLADDER DIVERTICULECTOMY WITH STONE REMOVAL

The presence of stone(s) in a bladder diverticulum can be a cause of recurrent urinary tract infection, or outflow of obstruction and may require diverticulectomy. In a large diverticulum, with history of infection or in a location close to ureter, bilateral ureteral catheterization or double J stenting is preferred. The dissection is started from the most prominent part of the diverticulum, proceeding toward the diverticulum neck. However, sometimes it is difficult to expose the diverticulum. Traction with a grasping forceps at the edge of the diverticulum mouth helps in subsequent dissection with the twist-and-roll technique. It should be kept in mind that course of the ureter is distorted, increasing chances of injury. Stones from inside the diverticular cavity are removed and diverticular wall is excised. The bladder is closed with interrupted intracorporeal 2-0 Vicryl sutures.

RESULTS

Results of Laparoscopic Surgery for Urolithiasis

During our initial experience (Table 4), laparoscopic retroperitoneal surgery was successful in 95 out of the 114 patients (12). Of the 40 patients undergoing retroperitoneoscopic ureterolithotomy, stones could be retrieved successfully in 30 patients with a mean operating time of 106.3 minutes (range, 40–275 minutes) and an estimated blood loss of 69.8 mL (range, 25–150 mL). There were 10 conversions to

TABLE 4 ■ Initial Experience of Laparoscopic Retroperitoneal Surgery in Calculous Disease

Procedure	No. of cases	Mean age (yr)	M:F	Previous procedures	Successful	Mean OR (min)	Mean estimated blood loss (mL)	Mean hospital stay (days)
Retroperitoneoscopic ureterolithotomy	40	48.5 (26–65) ^a	28:12	5 SWL; 9 URS	30 (75%)	106.3 (40–275)	69.8 (range 25–150)	3.76 (range 2–14)
Retroperitoneoscopic pyelolithotomy	7	37.5 (21–55)	5:2	–	5 (71.4%)	108.2 (45–150)	127.2 (range 60–200)	3.5 (range 3–8)
Retroperitoneoscopic nephrectomy	53	41.6 (19–68)	32:21	6 PCN	48 (90.5%)	99.7 (55–240)	135.6 (range 40–800)	2.86 (range 2–6)
Retroperitoneoscopic nephroureterectomy	14	44.4 (30–50)	7:7	1 PCN	12 (85.7%)	147 (70–210)	206.5 (range 70–400)	3.5 (range 2–6)

^aRanges are given in parentheses.

Abbreviations: SWL, shock wave lithotripsy; URS, ureterorenoscopy; PCN, percutaneous nephrostomy; M:F, male:female; OR, operating room.

open surgery, most of them during our initial learning curve. Of the seven cases of retroperitoneoscopic pyelolithotomy, there were two conversions. The mean operating time was 108.2 minutes (range, 45–150 minutes) and the estimated blood loss was 127.2 mL (range, 60–200 mL).

There were five open conversions out of 53 cases of retroperitoneoscopic nephrectomies for calculous disease due to nonfunctioning kidneys because of the multiple stones and chronic infection. The mean operating time was 99.7 minutes (range, 55–240 minutes) and the average blood loss was 135.6 mL (range, 40–800 mL).

Of the 14 retroperitoneoscopic nephroureterectomies, we were successful in 12. Average operating time was 147.0 minutes (range, 70–210 minutes) and average blood loss was 206.5 mL (range, 70–400 mL). Average hospital stay ranged from three to four days for various procedures. There were two major complications. One patient with dense perinephric adhesions suffered a colonic injury during dissection with the J hook, which was detected intraoperatively and repaired primarily. Another patient sustained injury to the external iliac artery during ureterolithotomy, which was also managed to open surgically. Minor complications encountered were peritoneal rents in seven patients, postoperative fever in two patients, surgical emphysema in two patients, and wound infection in two patients.

Patients undergoing ureterolithotomy and pyelolithotomy were followed with an intravenous urogram at three months. This could be done in 30 of the 40 patients following ureterolithotomy and all seven patients following pyelolithotomy. There was no evidence of any obstruction or residual fragment in any of the cases.

Results of Laparoscopic Ureterolithotomy

A prospective study was carried out comparing retroperitoneoscopic and open ureterolithotomy (Table 5) (5). A total of 55 patients with large (mean size 2.1 cm) upper and mid-ureteric calculi with normal renal parameters were subjected to retroperitoneoscopic ureterolithotomy. In 22 patients, earlier attempts with shock wave lithotripsy and ureteroscopy had failed. These cases were compared with 26 cases (mean stone size, 2.4 cm) that underwent open ureterolithotomy during the same period. The two groups were similar to each other regarding patient age, sex, stone size, and stone location. Most stones were calcium based. Mean operating time and mean blood loss in the laparoscopic and open groups were 108.8 minutes versus 98.8 minutes, and 58.5 mL versus 50.5 mL, respectively ($p = \text{NS}$). Mean analgesic (pethidine) requirement and hospital stay were 41.1 mg versus 96.9 mg and 3.3 days versus 4.8 days, respectively ($p < 0.001$). Convalescence was quicker in the laparoscopic group: 1.8 weeks versus 3.1 weeks. The laparoscopic procedure has significant advantages over open surgery as regards analgesia, hospital stay, recuperation, and cosmesis. Retroperitoneal laparoscopy is a viable alternative for large upper and mid-ureteric calculus, and for those which have failed previous attempts at expert endourologic management.

Results of Laparoscopic Pyelolithotomy

We compared retroperitoneoscopic pyelolithotomy ($n = 16$) versus percutaneous nephrolithotripsy ($n = 12$) in the management of a solitary renal pelvic calculus more than 3 cm in size (Table 6). The two groups were similar regarding patient age and sex. Mean stone sizes were 3.6 cm versus 4.2 cm, respectively ($p < 0.006$). There were two conversions in the laparoscopic group for stone migration into the calyx and dense

TABLE 5 ■ Comparison of Retroperitoneoscopic and Open Ureterolithotomy

	RPUL (<i>n</i> = 55)	OUL (<i>n</i> = 26)	<i>p</i> Value
Age in years (mean)	25–65 (43.1)	25–55 (39.8)	NS
Sex (M:F)	39:16	20:6	NS
Stone size in cm (mean)	0.7–3.3 (2.1)	0.7–3.4 (2.4)	NS
Operating time in minutes (mean)	40–275 (108.8) ^a	60–125 (98.8)	NS
Blood loss in mL (mean)	25–160 (58.5) ^a	25–100 (50.5)	NS
Analgesia—mg of pethidine	25–75 (41.1) ^a	50–150 (96.9)	<0.001
Hospital stay in days (mean)	2–14 (3.3) ^a	3–8 (4.8)	<0.001
Return to work in weeks (mean)	1–3 (1.8) ^a	2–4 (3.1)	<0.001

^aData of 45 successful cases.
Abbreviations: RPUL, retroperitoneoscopic ureterolithotomy; OUL, open ureterolithotomy; M:F, male:female.

TABLE 6 ■ Comparison of Retroperitoneoscopic Pyelolithotomy and Percutaneous Nephrolithotripsy

Procedure	RPPL	PCNL	<i>p</i> value
Number of cases	16	12	
Mean age in years (range)	38.9 (21–60)	41.4 (20–62)	NS
Male:female	10:6	8:4	NS
Mean stone size in cm (range)	3.6 (3.2–4.5)	4.1 (3.5–5.2)	<0.006
Conversion	2	0	NS
Mean operating time in minutes (range)	142.2 (45–280)	71.6 (50–100)	<0.000
Mean estimated blood loss in mL (range)	173.1 (60–400)	147.9 (75–200)	NS
Mean hospital stay in days (range)	3.8 (1–10)	3 (2–5)	NS
Mean duration of return to full activity in days (range)	12.7 (7–20) ^a	9.8 (7–12)	NS

^aResults of nine cases only.
Abbreviations: RPPL, retroperitoneoscopic pyelolithotomy; PCNL, percutaneous nephrolithotripsy.

perirenal adhesions, making dissection difficult. Mean operating time was 142 minutes versus 72 minutes for percutaneous nephrolithotripsy ($p < 0.0001$). Blood loss was similar 173 cc versus 141 cc. Mean hospital stay was 3.8 days versus 3 days, although the duration of convalescence was somewhat shorter in the percutaneous nephrolithotripsy group. Laparoscopic pyelolithotomy is associated with longer operating time, longer recuperation, is more invasive, less cosmetic, and requires more skill as compared to percutaneous nephrolithotripsy. Advanced endourological facilities are required for removal of calyceal stones in the event of migration or for localization of stone such as laparoscopic ultrasound. Laparoscopy is not suitable in patients with dense peripelvic adhesions or history of previous retroperitoneal surgery.

Laparoscopic pyelolithotomy may be indicated for ectopically located, congenitally anomalous kidneys or in patients where concomitant laparoscopic procedure is indicated such as pyeloplasty (30–33).

COMPLICATIONS

Acceptance of any surgical procedure depends to a large extent on the demonstration of technical efficacy and an acceptably low complication rate. However, apart from the initial cases where open conversion was required, this has not been a problem in subsequent cases. Among the major intraoperative complications, rare vascular and visceral injuries have occurred, albeit managed successfully. Among 247 cases of retroperitoneoscopic surgery for calculous disease, comprised of ureterolithotomy ($n = 85$), pyelolithotomy ($n = 27$), nephrectomy ($n = 114$), and nephroureterectomy ($n = 31$), we had 10.9% minor complications, 1.6% major complications, and 6.8% conversion to open surgery (Table 7). Unforeseen hemorrhage can occur at any time during the procedure but this does not make it any different from open surgery for calculous disease. Possible problems and tips to manage these are described in Table 8.

Laparoscopic pyelolithotomy may be indicated for ectopically located, congenitally anomalous kidneys or in patients where concomitant laparoscopic procedure is indicated such as pyeloplasty.

TABLE 7 ■ Complications in Retroperitoneoscopic Surgery for Calculous Disease

Complications		Nephrectomy (114) ^a ; nephroureterectomy (21)	Ureterolithotomy (85)	Pyelolithotomy (27)	Total (247)
<i>Minor</i>					
Access and dissection	Peritoneal rent	9	3	0	12 (4.8%)
	Emphysema	3	1	0	4 (1.6%)
	Kidney puncture	2	0	0	2 (0.8%)
	RP collection	0	1	0	1 (0.4%)
	Fever	3	0	0	3 (1.2%)
	Ileus	2	1	0	3 (1.2%)
Postoperative	Port site infection	2	0	0	2 (0.8%)
Total		21	6	0	27 (10.9%)
<i>Major</i>					
	Vascular	0	1	0	1 (0.4%)
	Visceral	1	0	0	1 (0.4%)
	Collections	1	0	0	1 (0.4%)
	Port site hernia	1	0	0	1 (0.4%)
Total		3	1	0	4 (1.6%)
Conversions		7	8	2	17 (6.8%)

^aNumber of cases is given in parentheses.
Abbreviation: RP, retroperitoneal.

TABLE 8 ■ Technical Caveats and Tips

Technical caveats		Tips
Ureterolithotomy	Stone migration	Hold ureter in Babcock forceps above the stone Use of flexible nephroscope to retrieve migrated stones Use of laparoscopic ultrasound or fluoroscopy
	Vascular injury	Careful dissection, and early conversion in cases of extensive adhesions If doubtful, ensure with ultrasound or fluoroscopy
	Inability to localize stone	Use of intraoperative fluoroscopy or ultrasound
	Peritoneal rent in retroperitoneoscopic approach	Place secondary ports under vision or digital guidance
Pyelolithotomy	Stone migration	Retract the peritoneum with fan retractor Veress needle can be used for deflating abdomen Make rent bigger, so as to equalize pressure Avoid excessive palpation of stone especially prior to pyelotomy Keep jaws of forceps open while attempting to grasp Use a flexible nephroscope to retrieve migrated stones Intraoperative fluoroscopy or ultrasound Confirmation of stone and pelvis by USG and gentle dissection
	Excessive perirenal adhesions	
	Adhesions, especially in post ESWL patients	
	Excessive perirenal adhesions and pararenal adhesions	Renal dissection outside the Gerota's fascia
Nephrectomy		Control hilar vessels first as for radical nephrectomy
Nephroureterectomy	Excessive perirenal adhesions	Renal dissection outside the Gerota's fascia Control hilar vessels first
	Inability to dissect the lower ureter due to adhesions	Place the patient in an oblique position rather than dead lateral and use lower port near anterior superior iliac spine

Abbreviations: USG, Ultrasonography, ESWL, extracorporeal shock wave lithotripsy.

SUMMARY

- In our current practice, in the properly selected patient, laparoscopic ureterolithotomy, pyelolithotomy with pyeloplasty, retroperitoneoscopic nephrectomy and nephroureterectomy for nonfunctioning kidneys due to calculous diseases of kidneys are now offered in lieu of open surgery.
- Open conversion may be occasionally necessary.
- Prior open surgery and history of peritonitis are not necessarily regarded as contraindications in expert's hands.
- Laparoscopic pyelolithotomy is performed only in selected cases. However, cases with perinephric adhesions such as xanthogranulomatous pyelonephritis are difficult for the laparoscopic approach.

REFERENCES

1. Micali S, Moore RG, Averch TD, Adams JB, Kavoussi LR. The role of laparoscopy in the treatment of renal and ureteral calculi. *J Urol* 1997; 157:463–466.
2. Kumar R, Hemal AK. Current status of open surgery in the management of the stone diseases. *Prou Science: Timely topics in Medicine*, July, 2004, ttmed.com (epub). www.prou.com
3. Hemal AK, Goel A, Goel R. Minimally invasive retroperitoneoscopic ureterolithotomy. *J Urol* 2003; 169:480–482.
4. Wickham JEA, Miller RA, eds. Percutaneous renal access. In: *Percutaneous Renal Surgery*. New York: Churchill Livingstone, 1983:33–39.
5. Goel A, Hemal AK. Upper and mid ureteric stone: a prospective nonrandomized comparison of retroperitoneoscopic and open ureterolithotomy. *BJU Int* 2002; 89(6):636–637.
6. Clayman RV, Preminger GM, Franklin JF, Curry T, Peters PC. Percutaneous ureterolithotomy. *J Urol* 1985; 133:671–673.
7. Keeley FX, Gialas M, Pillai M, Chrisofos M, Tolley DA. Laparoscopic ureterolithotomy: the Edinburgh experience. *BJU Int* 1999; 84:765–769.
8. Harewood LM, Webb DR, Pope AJ. Laparoscopic ureterolithotomy: the results of an initial series, and an evaluation of its role in the management of ureteric calculi. *Br J Urol* 1994; 74:170–176.
9. Turk I, Deger S, Roigas J, Fahlenkamp D, Schonberger B, Leoning SA. Laparoscopic ureterolithotomy. *Tech Urol* 1998; 4:29–34.
10. Gaur DD, Agarwal DK, Purohit KC, Darshan AS. Retroperitoneal laparoscopic pyelolithotomy. *J Urol* 1994; 151:927–929.
11. Hoenig DM, Shalhav AL, Elbahnasy AM, McDougall EM, Clayman RV. Laparoscopic pyelolithotomy in a pelvic kidney: a case report and review of the literature. *J Soc Laparoendosc Surg* 1997; 1:163–165.
12. Hemal AK, Goel A, Kumar M, Gupta NP. Evaluation of laparoscopic retroperitoneal surgery in urinary stone disease. *J Endourol* 2001; 15:701–705.
13. Ramakumar S, Lancini V, Chan DY, Parsons JK, Kavoussi LR, Jarrett TW. Laparoscopic pyeloplasty with concomitant pyelolithotomy. *J Urol* 2002; 167(3):1378–1380.
14. Goel A, Hemal AK. Evaluation of role of retroperitoneoscopic pyelolithotomy and its comparison with percutaneous nephrolithotripsy. *Int Urol Nephrol* 2003; 35(1):73–76.
15. Hemal AK, Gupta NP, Wadhwa SN, Goel A, Kumar R. Retroperitoneoscopic nephrectomy and nephroureterectomy for benign non-functioning kidneys: a single center experience. *Urology* 2001; 57(4):644–649.
16. Kaouk JH, Gill IS, Desai MM, et al. Laparoscopic anastrophic nephrolithotomy: feasibility study in a chronic porcine model. *J Urol* 2003; 169(2):691–696.
17. Skrepetis K, Doumas K, Siafakas I, Lykourinas M. Laparoscopic versus open ureterolithotomy. A comparative study. *Eur Urol* 2001; 40(1):32–36.
18. Badani KK, Hemal AK, Fumo M, et al. Robotic extended pyelolithotomy for treatment of renal calculi: A feasibility study. *World J Urol* 2006; 24(2):198–202.
19. Hemal AK, Goel R, Goel A. Cost-effective laparoscopic pyeloplasty: single center experience. *Int J Urol* 2003; 10(11):563–568.
20. Ansari MS, Hemal AK. A rare case of urachovesical calculus: a diagnostic dilemma and endo-laparoscopic management. *J Laparoendosc Adv Surg Tech A* 2002; 12(4):281–283.
21. Park H, Park M, Park T. Two year experience with ureteral stones: extracorporeal shockwave lithotripsy vs ureteroscopy manipulation. *J Endourol* 1998; 12:501–504.
22. Segura JW, Preminger GM, Assimos D. Ureteral stones clinical guidelines panel summary report on the management of ureteral calculi. *J Urol* 1997; 158:1915–1921.
23. Koch J, Balk N, Wilbert DM, Strohmaier WL, Bichler KH. Extracorporeal shock wave lithotripsy of upper ureteral stone: in situ versus push and smash treatment. *J Endourol* 1991; 5:195–196.
24. Clayman RV, Surya V, Miller RP. Percutaneous nephrostolithotomy: extraction of renal and ureteral calculi from 100 patients. *J Urol* 1984; 131:868–872.
25. Liong ML, Clayman RV, Gittes RF, Lingeman JE, Huffman JL, Lyon ES. Treatment options for proximal ureteral urolithiasis: review and recommendations. *J Urol* 1989; 141:504–509.
26. Hemal AK, Wadhwa SN, Kumar M, Gupta NP. Transperitoneal and retroperitoneal laparoscopic nephrectomy for giant hydronephrosis. *J Urol* 1999; 162:35–39.
27. Hemal AK. Retroperitoneoscopic nephrectomy for benign diseases of the kidney. *Urol Int* 2001; 67(2):121–129.

28. Casale P, Grady RW, Joyner BD, Zeltser IS, Kuo RL, Mitchell ME. Transperitoneal laparoscopic pyelolithotomy after failed percutaneous access in the pediatric patient. *J Urol* 2004; 172(2):680–683.
29. Hemal AK, Talwar M, Wadhwa SN, Gupta NP. Retroperitoneoscopic nephrectomy for benign disease of the kidney: prospective nonrandomized comparison with open surgical nephrectomy. *J Endourol* 1999; 13(6):425–431.
30. Chang TD, Dretler SP. Laparoscopic pyelolithotomy in an ectopic kidney. *J Urol* 1996; 156:1753–1756.
31. Harmon WJ, Kleer E, Segura JW. Laparoscopic pyelolithotomy for calculus removal in a pelvic kidney. *J Urol* 1996; 155:2019–2020.
32. Turk I, Deger S, Winkelmann B, Schonberger B, Loening SA. Laparoscopic bilateral pyelolithotomy in a horseshoe kidney. *BJU Int* 2001; 88:442–445.
33. Troxel SA, Low RK, Das S. Extraperitoneal laparoscopy-assisted percutaneous nephrolithotomy in a left pelvic kidney. *J Endourol* 2002; 16(9):655–657.

COMMENTARY

D. Assimos

Department of Urology, Wake Forest University School of Medicine, Winston-Salem, North Carolina, U.S.A.

Laparoscopic stone removal currently has a limited role in the management of patients with nephrolithiasis. The indications should be similar to those for the pool of subjects who are candidates for open surgical stone removal. The latter comprises less than 1% of patients undergoing a stone-removing procedure, even at tertiary medical centers (1). Laparoscopic stone removal should not be undertaken in patients in whom shock wave lithotripsy or an endourological approach is anticipated to be successful. Failure of the aforementioned therapies may be a valid reason to consider laparoscopy. However, current endoscopic technology and the skills of contemporary urologists have made this rarely necessary (1).

Laparoscopic nephrectomy is appropriate in subjects with a nonfunctioning renal unit due to a stone-related problem. While some have reported successful laparoscopic removal of xanthogranulomatous pyelonephritic kidneys, I concur with the author that this is not advisable in most cases (2). Laparoscopic partial nephrectomy may be considered for patients with stones in a polar area having no or minimal function. Combined pyeloplasty and pyelolithotomy is indicated for those patients in whom endopyelotomy performed in conjunction with percutaneous nephrolithotomy is not likely to be successful. These include patients with severe hydronephrosis, diminished renal function, and crossing vessels (3,4). Patients with isolated stones in an anterior calyceal diverticulum not accessible or too large for a retrograde ureteroscopic management may benefit from a laparoscopic approach. The same holds true for those having stones located in a type II diverticulum—one that communicates directly with the renal pelvis or an infundibulum. These cavities typically have no overlying renal parenchyma. Laparoscopy can also allow safe percutaneous access for removing stones in pelvic and other types of ectopic kidney (5).

Laparoscopic ureterolithotomy is rarely indicated as retrograde and antegrade ureteroscopic approaches and shock wave lithotripsy are less invasive and highly effective. In most cases, it should only be employed as a salvage procedure. It has been undertaken in some countries where the aforementioned technology is not readily available. Percutaneous nephrolithotomy is the procedure of choice for the majority of patients harboring staghorn calculi (6). Anatomic nephrolithotomy should be reserved for patients with extremely large staghorn calculi in kidneys with complex collecting system anatomy. While this has been done via laparoscopy in a porcine model and select patients with more favorable anatomy, it is not anticipated that this will supplant the open approach in the aforementioned setting.

Laparoscopy will continue to play an extremely small role in the management of patients with nephrolithiasis. In addition, future improvements in endoscopic technology are likely to further narrow its application.

REFERENCES

1. Matlaga BR, Assimos DG. Changing indications of open stone surgery. *Urology* 2002; 59:490–493.
2. Shekarriz B, Meng MV, Lu HF, Yamada H, Duh QY, Stoller ML. Laparoscopic nephrectomy for inflammatory renal conditions. *J Urol* 2001; 166:2091–2094.
3. Van Cangh PJ, Nesa S. Endopyelotomy. Prognostic factors and patient selection. *Urol Clin North Am* 1998; 25:281–288.
4. Gupta M, Tuncay OL, Smith AD. Open surgical exploration after failed endopyelotomy: a 12-year perspective. *J Urol* 1997; 157:1613–1618.
5. Eshghi AM, Roth JS, Smith AD. Percutaneous transperitoneal approach to a pelvic kidney for endourological removal of staghorn calculus. *J Urol* 1985; 134:525–527.
6. American Urological Association 2004 guidelines for management of staghorn calculi. *J Urol*. In press.

LAPAROSCOPIC PYELOPLASTY: TECHNIQUE

George K. Chow

Department of Urology, Mayo Clinic, Rochester, Minnesota, U.S.A.

- INTRODUCTION
- PATIENT SELECTION AND DIAGNOSIS
- PREOPERATIVE PREPARATION
- SURGICAL TECHNIQUE
 - Access
 - Trocar Placement
 - Dissection
 - Pyeloplasty Technique
 - Anderson-Hynes Dismembered Pyeloplasty
- Foley Y-V Plasty
- Fenger Pyeloplasty
- POSTPYELOPLASTY PROCEDURE
- POSTOPERATIVE MANAGEMENT
- POSTOPERATIVE COMPLICATIONS
 - Urinary Leak
 - Stricture
- SUMMARY
- REFERENCES

Laparoscopic pyeloplasty offers a minimally invasive alternative for the management of ureteropelvic junction obstruction that duplicates the surgical principles of open pyeloplasty.

The laparoscopic pyeloplasty can be performed by either retroperitoneal or transperitoneal approach.

INTRODUCTION

Laparoscopic pyeloplasty was first reported by Scheussler et al. in 1993. It offers a minimally invasive alternative for the management of ureteropelvic junction obstruction that duplicates the surgical principles of open pyeloplasty.

Numerous studies attest to the superior long-term efficacy of laparoscopic pyeloplasty over the various methods of antegrade and retrograde endopyelotomy.

Prior to the advent of laparoscopic prostatectomy and the need to perform a vesicourethral anastomosis, the most technically challenging reconstructive laparoscopic procedure was pyeloplasty. As such, the surgeon must be well versed in laparoscopic suturing techniques to perform pyeloplasty.

The laparoscopic pyeloplasty can be performed by either retroperitoneal or transperitoneal approach.

The retroperitoneal approach offers the advantage of less potential postoperative ileus, but has the disadvantage of a limited working space. Conversely, the transperitoneal approach offers familiar anatomic landmarks and more working space, but more bowel manipulation, and therefore higher likelihood of ileus. Choice of anatomic approach is dictated by surgeon experience and training.

Various techniques for pyeloplasty are described. These can be divided into dismembered and nondismembered techniques. The dismembered or Anderson-Hynes technique involves division of the ureteropelvic junction and excision of the narrowed segment, followed by reanastomosis of the ureter to the renal pelvis. The two common nondismembered techniques include Foley Y-V plasty and Fenger pyeloplasty. The Foley Y-V plasty consists of incising through the narrow segment and advancing the apex of the "Y" incision as a flap to bridge the previously narrowed segment. The advantage of this approach is its relative simplicity. The even simpler Fenger pyeloplasty involves horizontal incision through the narrowed segment closed vertically in a Heineke-Mikuluc fashion. Other techniques such as the Culp-DeWeerd pyeloplasty have also been reported, but are not among the commonly used techniques. The nondismembered techniques should not be used when crossing vessels are encountered or reduction of a redundant renal pelvis is anticipated.

The technique chosen depends on the task at hand. In general, when a crossing vessel, redundant renal pelvis, or coexisting renal calculi is present, the dismembered pyeloplasty is preferable.

Due to the inherent complexity of laparoscopic pyeloplasty, new technology has been introduced to facilitate the procedure. Hand-assisted laparoscopy has been described as a means to assist laparoscopic pyeloplasty. In this fashion, one-handed surgical tying can be performed intracorporeally. Furthermore, surgical robots can be employed to assist with suturing. Whether or not you use technological assistance, the technique remains essentially the same.

The indications for laparoscopic pyeloplasty include ureteropelvic junction obstruction associated with the following:

1. Flank pain
2. Deteriorating renal function
3. Renal calculus
4. Urinary tract infections
5. Associated hypertension

Relative contraindications for laparoscopic pyeloplasty include:

1. Previous open renal surgery
2. Bleeding diathesis
3. Untreated active pyelonephritis

Although not technically a preoperative measure, stent placement is an important step prior to laparoscopic pyeloplasty. Prepyeloplasty stent placement is much easier than intraoperative placement.

PATIENT SELECTION AND DIAGNOSIS

The indications for laparoscopic pyeloplasty include ureteropelvic junction obstruction associated with the following:

1. Flank pain
2. Deteriorating renal function
3. Renal calculus
4. Urinary tract infections
5. Associated hypertension

Diagnosis of ureteropelvic junction obstruction is based on radiography. Ultrasound, computed tomography, and intravenous pyelography are capable of identifying suspicious hydronephrotic kidneys. Often additional testing is necessary to confirm ureteropelvic junction obstruction. Retrograde pyelogram is often used to help identify the level of obstruction. A characteristic “jet” of contrast is seen at the area of narrowing during retrograde injection of contrast. Diuretic renography can often differentiate between the nonobstructed and obstructed ureteropelvic junction obstruction. Furthermore, if significant cortical loss is evident on radiography, nuclear renography can quantify renal differential function. If 20% or less of total renal function is present, a simple nephrectomy may be preferable to pyeloplasty.

Diuretic renogram can also document postoperative functional improvement, both with respect to renal function and the presence/absence of obstruction. Be aware that the results of diuretic renogram can be confounded by poor renal function and excessive renal pelvic redundancy.

Relative contraindications for laparoscopic pyeloplasty include:

1. Previous open renal surgery
2. Bleeding diathesis
3. Untreated active pyelonephritis

PREOPERATIVE PREPARATION

Prior to surgery, the patient should refrain from oral intake after midnight the day before surgery, and receive a mechanical bowel preparation. A bottle of magnesium citrate should suffice. An orogastric tube should be placed to deflate the stomach. This precaution should decrease the risk of injury to the stomach during trocar placement. Antibiotic prophylaxis such as a first-generation cephalosporin should be given. Pneumatic compression stockings should be placed to prevent deep venous thrombosis.

Patient positioning is dictated by the anatomic approach chosen. For the retroperitoneal approach, the patient is placed in full flank position, with the surgical table flexed and kidney rest deployed to maximize the space between the costal margin and iliac crest. If the transperitoneal approach is preferred, the patient is placed in a 60° lateral decubitus position. The patient should be carefully strapped to the surgical table. The patient should be sufficiently secured to permit maximal tilt of the table to either side. During the case, the tilt of the table can be adjusted to maximize gravity-assisted retraction of the bowels. Also, the patient should be well padded at all pressure points to avoid neurological injury.

Although not technically a preoperative measure, stent placement is an important step prior to laparoscopic pyeloplasty. Prepyeloplasty stent placement is much easier than intraoperative placement.

Selection of a stent at least 2 cm larger than the estimated required stent length is crucial. With division of the ureteropelvic junction, the natural elastic properties of the tissue result in retraction. If the stent is too short, it may not be easy to replace in the renal pelvis. The added length facilitates positioning of the proximal stent during anastomosis.

After stent placement, a Foley catheter should be placed in the bladder and left to gravity drainage.

SURGICAL TECHNIQUE

Access

Transperitoneal access is obtained by placement of the Veress needle. Aspiration and saline injection should be used to assure proper placement in the peritoneum. The

author's preference is to place the needle via the umbilicus where the abdominal wall is thinnest. Because the patient is in a 60° lateral decubitus position, the table is rotated until the patient is in a relatively supine position to facilitate access. Maintenance of low intra-abdominal pressure while insufflating the abdomen with carbon dioxide at a low flow rate confirms good intraperitoneal position. Once satisfied with the needle placement, the gas can be turned to high flow rate. The gas should be insufflated to a pressure of 10 to 15 mmHg. Initial placement of a 10 mm trocar can be performed under direct vision with an optical trocar such as the Optiview^{TMa} or Visiport^{TMb} devices. The first port can be placed at the umbilicus or in the lateral abdomen.

Retroperitoneal access is achieved by making a 12 mm incision anterior to the tip of the 12th rib. The incision is taken through the intercostal muscles and fasciae using the surgical cautery. The surgical plane between the Psoas fascia and Gerota's fascia is developed bluntly. A retroperitoneal dissecting balloon is placed and inflated to create a retroperitoneal workspace. The balloon is deflated and a balloon-tip trocar placed and secured. Carbon dioxide gas is insufflated to expand the retroperitoneal space.

Trocar Placement

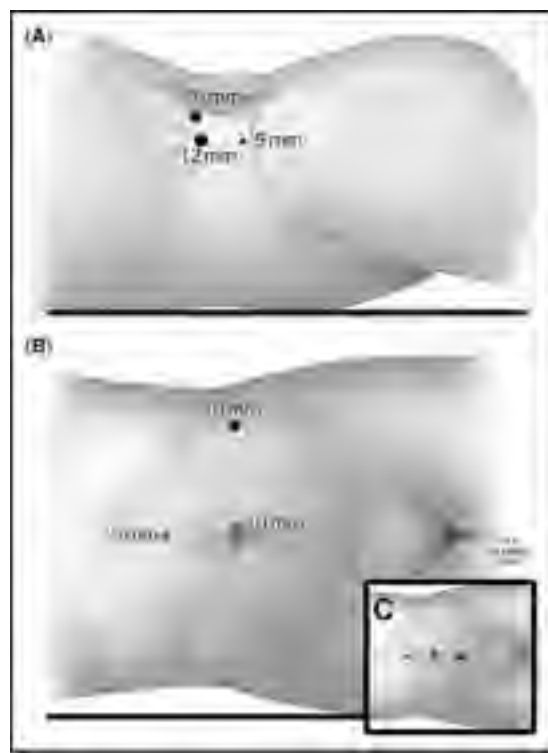
For the transperitoneal approach, a 3-trocar configuration is used (Fig. 1). At least one 10 mm port is necessary to permit intracorporeal suturing. A 5 mm port is placed halfway between the umbilicus and xiphoid process in the midline. A 10 mm port is placed at the umbilicus. An additional lateral 10 mm trocar is placed lateral to the ipsilateral rectus muscle at the level of the umbilicus (Fig. 1B).

Surgical Tip

For right-sided pyeloplasty, liver retraction may be necessary. If so, a 2 mm or 5 mm port can be placed just inferior to the xiphoid process, and a locking grasping forceps used to tent up the liver edge and grasp a segment of the triangular ligament or portion of the peritoneum. This will function as a self-retaining liver retractor. This obviates the need for a surgical assistant to retract the liver. Therefore, your surgical assistant can concentrate on providing a good camera image.

For the retroperitoneal approach, three trocars are used as well. The initial port, a balloon-tip trocar, is placed at the initial incision. An additional 10 mm trocar is placed

FIGURE 1 ■ (A) Trocar placement for retroperitoneal approach; **(B)** trocar placement for transperitoneal approach; **(C)** alternative trocar placement for transperitoneal approach.



^aEthicon, Summerville, NJ.

^bU.S. Surgical Corp., Norwalk, CT.

FIGURE 2 ■ Endostitch™ (Autosuture Co., Norwalk, CT). The toggle from movement transfers the needle from jaw to facilitate suturing.



If a crossing vessel is identified, the ureter needs to be freed up completely from the vessel to facilitate eventual transposition. The renal pelvis needs to be freed up as much as possible to enable possible ureteral transposition and a tension-free anastomosis.

at the junction of the 12th rib and the paraspinal muscles. This can be done under tactile guidance (with a nonbladed trocar) or under direct vision. A 5 mm trocar is placed anteriorly, about two fingerbreadths above the iliac crest.

Dissection

Incision of the line of Toldt and mobilization of the colon is the first step during transperitoneal laparoscopic pyeloplasty. In right-sided cases, the Kocher maneuver may be necessary to mobilize the duodenum and expose the renal hilum. Next, the ureter is identified, and dissected free. Tenting up the ureter, the dissection is cephalad toward the ureteropelvic junction.

If a crossing vessel is identified, the ureter needs to be freed up completely from the vessel to facilitate eventual transposition. The renal pelvis needs to be freed up as much as possible to enable possible ureteral transposition and a tension-free anastomosis.

Retroperitoneal technique is usually facilitated by the fact that no extensive dissection is necessary. When dissecting in the proper anatomic space, the ureter and renal arterial anatomy should be rapidly identified. Dissection of these structures is necessary to ensure a tension-free anastomosis.

Pyeloplasty Technique

Intracorporeal suturing is a necessary part of laparoscopic pyeloplasty. A 4-0 polyglycolic suture is used. Interrupted or running technique can be used. Freehand technique or mechanically assisted suturing can be used. An automatic laparoscopic suturing instrument such as the Endostitch (Fig. 2) can be used.

The author's preference is the interrupted technique for the following reasons:

1. Interrupted suture is potentially less ischemia producing.
2. Correction of unevenness in the anastomosis is easier.
3. A running anastomosis can be compromised by an air knot, and could require redoing the entire anastomosis.

Surgical Tip

Clipping stay sutures to cut edges of the peritoneum can facilitate suturing the anastomosis. This frees up both of the surgeon's hands for suture placement and obviates the need for an assistant to assist with the anastomosis.

Anderson-Hynes dismembered pyeloplasty is preferred when pelvic reduction may be necessary, a renal calculus is present, or a crossing vessel is encountered.

Anderson-Hynes Dismembered Pyeloplasty

Anderson-Hynes dismembered pyeloplasty is preferred when pelvic reduction may be necessary, a renal calculus is present, or a crossing vessel is encountered (Fig. 3).

A dismembered pyeloplasty may have superior efficacy compared with the other nondismembered techniques. In the largest head-to-head comparison of laparoscopic dismembered ($n = 25$) and nondismembered pyeloplasties ($n = 15$), Klingler et al. showed superior efficacy for dismembered (96%) versus nondismembered (73.3%) pyeloplasty.

Once the ureteropelvic junction is dissected free, the narrowed segment is excised (Fig. 3A). If there is excessive redundant pelvis, this can be excised. The defect can be closed. Next, the ureter is spatulated (Fig. 3B). The 6 o'clock and 12 o'clock positions of

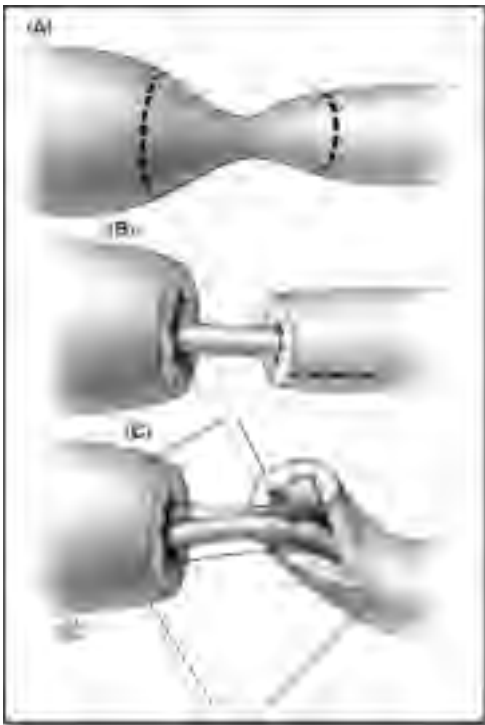


FIGURE 3 ■ Laparoscopic Anderson-Hynes dismembered pyeloplasty.

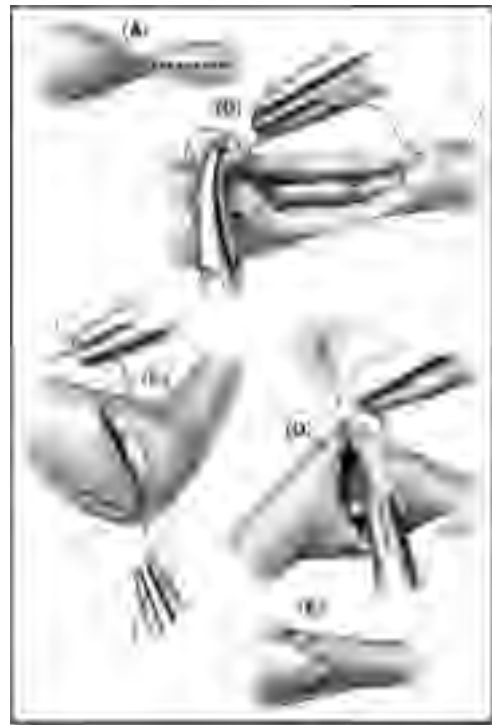


FIGURE 4 ■ Laparoscopic Foley Y-V plasty.

the ureter and pelvis are approximated (Fig. 3C). The intervening gaps on the front and back of the anastomosis can be closed with either running or interrupted suture.

Foley Y-V Plasty

Foley Y-V Plasty can be used with the following:

- Small or modestly enlarged renal pelvis
- Absence of crossing vessel
- High ureteral insertion

A Y-shaped incision is made, which traverses the narrowed segment of the ureteropelvic junction (Fig. 4A). The apex of the Y limb is advanced to the distal end of the incision (Fig. 4B). Stay sutures are placed at each end of the incision (Fig. 4C), and the gaps in the anastomosis are filled in with interrupted sutures (Fig. 4D). The end result of the suturing should be a “V” shaped closure (Fig. 4E).

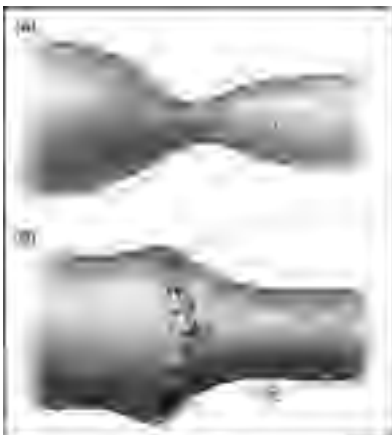


FIGURE 5 ■ Laparoscopic Fenger pyeloplasty.

Fenger Pyeloplasty

The indications for Fenger pyeloplasty are the same as with the Y-V plasty. This relatively simple procedure uses a Heineke-Mikulicz type closure. The ureter is incised horizontally through the narrowed segment (Fig. 5A). The proximal end of the incision (Point 1) is then advanced and secured to the distal end (Point 2). The gaps on either side are then filled in with interrupted sutures (Fig. 5B).

POSTPYELOPLASTY PROCEDURE

After completion of the anastomosis, a Jackson-Pratt drain is left to bulb suction drainage via a lateral trocar site. Careful inspection of the surgical site is performed at low pressure to ensure good hemostasis. Cautery and hemostatic agents can be utilized to deal with nuisance bleeding. More significant bleeds may require suturing or clip application. In transperitoneal cases, some surgeons will reretroperitonealize the kidney by taking the colon back to the line of Toldt at the end of the case.

After the abdomen is desufflated and the gas expelled, the port sites can be closed under direct vision externally with a 2-0 polyglycolic suture if the patient is fairly thin

and the fascia visible. With obese patients, a special port closure device such as the Carter-Thompson needle or CloseSureTM system can be used.

POSTOPERATIVE MANAGEMENT

After surgery, the patient remains in the hospital till a solid diet is tolerated. With retroperitoneal surgery, oral intake can be resumed more rapidly, and hospital stay is usually overnight. With transperitoneal surgery, oral intake can usually be resumed once flatus is passed the next day. Rapid resumption of bowel activity can be facilitated by the use of nonopiate analgesia such as ketorolac.

The drain can be removed if output is less than 100 cc/day. Usually, the drain can be removed the next day. With transperitoneal surgery, the output can be exaggerated by peritoneal fluid. In such cases, checking drain fluid creatinine can be used to biochemically identify if urine leak is the cause of excessive drain output. Management of persistent urinary leakage are addressed below.

The patient returns for stent removal at four to six weeks. One month after stent removal, a diuretic renogram or intravenous pyelogram can be obtained to verify a good surgical result.

POSTOPERATIVE COMPLICATIONS

The potential complications of laparoscopic pyeloplasty run the entire gamut of standard reported surgical complications. Two complications specific to the procedure are urine leak and stricture.

Urinary Leak

Leakage of urine can occur due to poor anastomosis, failure of suture material, distal ureteral obstruction, or unrecognized injury to the ureter distal to the anastomosis. Clinically, this can be identified by excessive and prolonged drain output or abdominal distension from urinary ascites. Confirmation can be achieved biochemically by testing the drain fluid for creatinine and comparing to serum creatinine. A drain fluid creatinine that is greater than the serum creatinine indicates the presence of urine.

Management of urine leak is based on maximizing drainage, and urinary diversion. In the immediate postoperative period, placement or replacement of a Foley catheter can facilitate distal drainage.

Sometimes, leakage can be exacerbated by physical contact of the drain with the anastomosis. The drain can be withdrawn a few centimeters to see if drainage subsides. If the leak is identified after stent removal, intravenous or retrograde pyelography can confirm the location of a leak and evaluate the ureteral anatomy. A stent should be replaced at that point. Prolonged catheter and stent drainage may be necessary to allow for proper healing. If the flank drain has been removed at the time of urine leak, a percutaneous drain or nephrostomy may need to be placed.

Management of urine leak is based on maximizing drainage, and urinary diversion. In the immediate postoperative period, placement or replacement of a Foley catheter can facilitate distal drainage.

Stricture is synonymous with treatment failure.

Endopyelotomy, either antegrade or retrograde, may be used to treat stricture of the ureteropelvic junction. Ultimately, open dismembered pyeloplasty may be necessary to treat recalcitrant secondary ureteropelvic junction obstruction.

MEASURES TO REDUCE THE RISK OF URINE LEAK

1. Make sure that the anastomosis is tension free.
2. Check integrity of the anastomosis: place methylene blue in the bladder via urinary catheter or give intravenous methylene blue. There should be reflux up the stent. Identification of blue dye leakage can identify portions of the anastomosis that may need reinforcement.

Stricture

Stricture is synonymous with treatment failure. Clinical manifestations include flank pain, and/or continued obstruction on radiographic studies. Diuretic renography can confirm functional obstruction. Intravenous pyelogram may show delayed excretion of contrast.

Endopyelotomy, either antegrade or retrograde, may be used to treat stricture of the ureteropelvic junction. Ultimately, open dismembered pyeloplasty may be necessary to treat recalcitrant secondary ureteropelvic junction obstruction.

^cInlet Medical, Eden Prairie, MN.

Risk factors for stricture formation include previous irradiation, previous surgery on the ureteropelvic junction, and devascularization of the ureteral segment. Prevention relies on having a sound tension-free anastomosis at the time of surgery.

SUMMARY

- Laparoscopic pyeloplasty is rapidly becoming the treatment of choice for ureteropelvic junction obstruction.
- It offers success rate comparable to open surgery with all the benefits of minimally invasive surgery.
- Experience with intracorporeal suturing techniques is essential to ensure a good surgical result.

REFERENCES

1. Jarrett TW, Chan DY, Charambura TC, Fugita O, Kavoussi LR. Laparoscopic pyeloplasty: the first 100 cases. *J Urol* 2002; 167:1253–1256.
2. Soulie M, Salomon L, Patard JJ, et al. Extraperitoneal laparoscopic pyeloplasty: a multicenter study of 55 procedures. *J Urol* 2001; 166:48–50.
3. Nakada SY, McDougal EM, Clayman RV. Laparoscopic pyeloplasty for secondary ureteropelvic junction obstruction: preliminary experience. *Urology* 1995; 46:257–260.
4. Frauscher F, Janetschek G, Klauser A, et al. Laparoscopic pyeloplasty for ureteropelvic junction obstruction with crossing vessels: contrast-enhanced doppler findings and long-term results. *Urology* 2002; 59:500–505.
5. Gettman MT, Peschel R, Neururer R, Bartsch G. A comparison of laparoscopic pyeloplasty performed with the da Vinci robot system vs. standard laparoscopic techniques: initial clinical results. *Eur Urol* 2002; 42:453–457.
6. Nadler RB, Thaxton CS, Kim SC. Hand-assisted laparoscopic pyeloplasty and isthmectomy in a patient with a horseshoe kidney. *J Endourol* 2003; 17:909–910.
7. Siqueira TM Jr., Nadu A, Kuo RL, et al. Laparoscopic treatment for ureteropelvic junction obstruction. *Urology* 2002; 60:973–978.
8. Pardalidis NP, Papatsoris AG, Kosmaoglou EV. Endoscopic and laparoscopic treatment of ureteropelvic junction obstruction. *J Urol* 2003; 168:1937–1940.
9. Sundarum CP, Grubb RL III, Rehman J, et al. Laparoscopic pyeloplasty for secondary ureteropelvic junction obstruction. *J Urol* 2003; 169:2037–2040.
10. Turk IA, Davis JW, Winkelmann B, et al. Laparoscopic dismembered pyeloplasty—the method of choice in the presence of an enlarged renal pelvis and crossing vessels. *Eur Urol* 2002; 42:268–275.

ROBOTIC-ASSISTED ADULT AND PEDIATRIC PYELOPLASTY

Joseph J. Del Pizzo,

Department of Urology, James Buchanan Brady Foundation, The New York Presbyterian Hospital–Weill Cornell Medical Center, New York, New York, U.S.A.

Michael A. Palese

Department of Urology, The Mount Sinai Medical Center, New York, New York, U.S.A.

Ravi Munver

Department of Urology, Center for Minimally Invasive Urologic Surgery, Hackensack University Medical Center, Hackensack, New Jersey, U.S.A.

Dix P. Poppas

Institute for Pediatric Urology, New York Presbyterian Hospital–Weill Medical College of Cornell University, New York, New York, U.S.A.

- INTRODUCTION
- PATIENT SELECTION: INDICATIONS AND CONTRAINDICATIONS
- PREOPERATIVE PREPARATION
- ROBOTIC-ASSISTED TECHNIQUE
 - Adult Technique
 - Pediatric Technique
 - Surgical Steps

Various Modifications Published in the Literature

Pros and Cons

- TECHNICAL CAVEATS/TIPS
- SPECIFIC MEASURES TO AVOID COMPLICATIONS
- SUMMARY
- REFERENCES

INTRODUCTION

The etiology of ureteropelvic junction obstruction may result from a number of factors, and can be classified as congenital or acquired in origin. Congenital ureteropelvic junction obstruction is typically characterized by an intrinsic luminal narrowing that is caused by an aperistaltic segment, in which the spiral musculature has been replaced by abnormal longitudinal muscle fibers and fibrous tissue (1–2). A less frequent cause of congenital ureteropelvic junction obstruction is a proximal ureteral stricture caused by abnormal ureteral muscle fiber and collagen deposition in this area (3). Additionally, intrinsic obstruction can be caused by infoldings of ureteral mucosa, a phenomenon that may result from exaggeration of congenital folds that are normally found in the ureter during fetal development (4). In some instances, ureteral adventitia may be present as external bands or adhesions that cause obstruction by producing angulation of the proximal ureter at the lower margin of the renal pelvis. High insertion of the ureter has also been reported as a primary obstructing lesion, and may coincide with other renal anomalies such as ectopia or abnormal fusion (5).

Acquired ureteropelvic junction obstruction may be the result of long-standing vesicoureteral reflux that leads to dilatation of the renal pelvis and upper ureter, with subsequent development of elongation, tortuosity, and kinking. Other causes of obstruction include fibroepithelial polyps, urothelial tumors, urolithiasis, and inflammation or scarring caused by prior surgery or ischemia.

The role of aberrant crossing vessels in the etiology of ureteropelvic junction obstruction remains controversial. Arteries or veins supplying the lower renal pole are noted if as many as 79% of patients with symptomatic ureteropelvic junction obstruction (6), and may arise from the main renal artery or vein, or directly from the great vessels. These vessels usually cross the ureteropelvic junction anteriorly; however in a minority of patients, these vessels cross posteriorly. As crossing vessels have been documented in patients with a normal ureteropelvic junction, it is possible that the associated vessel alone may not be solely responsible as the primary cause of the obstruction.

Open pyeloplasty has been the standard treatment for congenital or acquired ureteropelvic junction in adults and children, with overall success rates of 90% to 100%.

Technologic advances have played a significant role in the therapeutic management of ureteropelvic junction obstruction and have enabled the introduction of laparoscopic- and robotic-assisted laparoscopic pyeloplasty over the last several years.

The robot offers the potential advantages of enhanced three-dimensional visualization, improved dexterity, greater precision, increased range of motion, and reproducibility to even the smallest children. Despite reports of laparoscopic procedures being performed in various pediatric urologic procedures, only a handful of centers have embraced this technology.

The surgical robot is ideally suited for the reconstruction of the ureteropelvic junction and is a good procedure for the novice robotic surgeon to attempt.

Indications for surgical intervention in patients with ureteropelvic junction obstruction include functionally significant obstruction, as defined by the presence of flank pain or other symptoms associated with the obstruction, impairment, or deterioration in renal function.

A combination of an intrinsic lesion at the ureteropelvic junction and subsequent dilatation and draping of the renal pelvis over the polar vessels may be more likely. Nevertheless, the incidence of crossing vessels in the symptomatic population is higher and appears to have functional significance.

Open pyeloplasty has been the standard treatment for congenital or acquired ureteropelvic junction in adults and children, with overall success rates of 90% to 100% (7–9).

The desire to decrease surgical morbidity associated with open surgery has led to the evolution of less invasive procedures over the past two decades, including percutaneous antegrade and ureteroscopic retrograde endopyelotomy. Despite lower success rates of 61% to 89% and an increased risk for perioperative hemorrhage (10–15), the endoscopic approaches have gained favor over open pyeloplasty.

Technologic advances have played a significant role in the therapeutic management of ureteropelvic junction obstruction and have enabled the introduction of laparoscopic- and robotic-assisted laparoscopic pyeloplasty over the last several years.

Laparoscopic pyeloplasty was first described in 1993 by Schuessler et al. (16). This procedure maintained the benefits of endoscopic approaches, short length of hospitalization, and reduced postoperative recovery time, while demonstrating comparable success rates to the conventional open approach (17–20). However, the technical challenge of reconstruction limited this procedure to select medical centers with advanced laparoscopic surgeons.

The introduction of robotic-assisted laparoscopic surgery has widened the surgical dimensions for minimally invasive surgery. Specifically, the availability of the *da Vinci*[®] Robot^a has facilitated complex reconstructive and laparoscopic procedures (21–23). The benefits imparted to the surgeon include enhanced three-dimensional visualization, improved dexterity, greater precision, increased range of motion, and reproducibility. The robot offers these potential advantages to even the smallest children. Despite reports of laparoscopic procedures being performed in various pediatric urologic procedures, only a handful of centers have embraced this technology.

This may be secondary to practice patterns but more likely reflects the inability of most practitioners to successfully implement and exploit laparoscopy for complex reconstructive procedures. With the advent of surgical robotics, the potential for a larger group of surgeons to employ minimal invasive methods for pediatric urologic operations is possible.

Over the last 10 years, laparoscopic pyeloplasties have been performed in adults and children but still remain a challenge for most surgeons. Robotic-assisted surgeries are beginning to find their place in urologic surgery. The surgical robot is ideally suited for the reconstruction of the ureteropelvic junction and is a good procedure for the novice robotic surgeon to attempt.

PATIENT SELECTION: INDICATIONS AND CONTRAINDICATIONS

Indications for surgical intervention in patients with ureteropelvic junction obstruction include functionally significant obstruction, as defined by the presence of flank pain or other symptoms associated with the obstruction, impairment, or deterioration in renal function.

In addition, upper urinary tract infection or renal calculi formation secondary to inadequate urinary drainage can also prompt surgical intervention. Asymptomatic individuals, in whom the physiologic significance of obstruction is indeterminate based on radiologic imaging studies, may reasonably be observed and followed with routine monitoring.

The majority of patients with ureteropelvic junction obstruction will benefit from surgical intervention with the primary goal of relieving symptoms and preserving renal function. The gold standard for achieving unobstructed urinary flow has been open operative repair and reconstruction of the ureteropelvic junction in the form of pyeloplasty. Antegrade and retrograde endoscopic approaches have since become popular as initial procedures of choice due to their minimal invasive nature and patient preference. However, success rates with these alternative techniques have not proved comparable with those of open pyeloplasty, especially in cases of

^aIntuitive Surgical, Sunnyvale, CA.

The principal contraindication to any minimally invasive approach is a long segment of obstruction, precluding the performance of a tension-free anastomosis between normal ureter and the renal pelvis. Age, body mass, prior operations, and/or side of involvement are other possible exclusion criteria.

The presence of a crossing vessel is not a contraindication for laparoscopic- or robotic-assisted repair.

long strictures, crossing vessels, or a large redundant renal pelvis. The indications for open and endoscopic management of ureteropelvic junction obstruction are still evolving, and careful patient selection for each approach may yield improved success rates (24).

The principal contraindication to any minimally invasive approach is a long segment of obstruction, precluding the performance of a tension-free anastomosis between normal ureter and the renal pelvis. Age, body mass, prior operations, and/or side of involvement are other possible exclusion criteria.

The presence of a large struvite stone may present a relative contraindication to robotic-assisted pyeloplasty repair. However, several series of laparoscopic- and robotic-assisted pyeloplasty repairs with concomitant pyelolithotomy have been performed without difficulty. Smaller stones were simply grasped and removed under direct vision or entrapped using a flexible cystoscope. Larger stones were taken out with an EndoCatch[®] bag^b (19,20,25–29). However, in the setting of struvite renal calculi that cannot be easily accessed via a laparoscopic procedure, an alternative approach may be more appropriate.

The presence of a crossing vessel is not a contraindication for laparoscopic- or robotic-assisted repair. In such instance, a dismembered Anderson–Hynes type repair is recommended. Indeed, some authors do not obtain preoperative studies to detect crossing vessels, believing that intraoperative recognition is readily apparent and addressed at the time of surgery (19).

Nephrectomy is often the preferred option for kidneys with no function or poor function and minimal potential for salvage. When repeated attempts at repair have failed and further intervention would be complicated with a low yield for success, nephrectomy may be considered as well. Additionally in patients with significant medical comorbidities, advanced age, or limited life expectancy, nephrectomy may be a suitable option. In any situation warranting surgical removal of the kidney over a reconstructive procedure, it is of extreme importance to verify the presence of an essentially normal contralateral kidney on the basis of radiographic or radionuclide studies.

PREOPERATIVE PREPARATION

Patients undergoing a robotic-assisted pyeloplasty should be subjected to preoperative evaluation and preparation as if they were undergoing an open operative intervention. This includes a search for any comorbidity that may increase the risk of anesthesia. Any urinary infection should be treated, and sterile urine should be ensured at the time of definitive intervention. If upper tract infection cannot be cleared because of obstruction, an internal stent or percutaneous nephrostomy drainage should be placed.

The patient should be counseled as to the risks and benefits of the procedure, including the fact that the success rate of any robotic-assisted approach may be less than that of a standard open operative intervention.

In addition, for any minimally invasive approach, there is always a risk that an open conversion may be possible. Patients should also be apprised of the fact that bleeding requiring transfusion is a risk of the procedure, and a “type and screen” should be part of the protocol.

A bowel preparation is usually recommended especially when robotic surgery is performed by the novice practitioner. Any standard bowel preparation will suffice. In the unlikely event of a bowel injury, this step may ensure a less complicated postoperative course for the patient.

All patients in both the adult and pediatric populations should have radiographic evidence of ureteropelvic junction. This may include ureteropelvic junction on diuresis renography or hydronephrosis with delayed function on excretory urography (IVP). Computed tomography, magnetic resonance imaging, or ultrasound may be helpful for anatomic mapping of the ureteropelvic junction with or without a crossing vessel, but will not always definitively indicate a ureteropelvic junction obstruction.

Finally, a renal split function may be helpful in cases where renal deterioration is suspected. This provides a baseline study to compare with in the future and will also predict the likelihood of a successful repair. The lower the renal function in the obstructed renal unit, the lower the chances of a successful repair.

The patient should be counseled as to the risks and benefits of the procedure, including the fact that the success rate of any robotic-assisted approach may be less than that of a standard open operative intervention.

A bowel preparation is usually recommended especially when robotic surgery is performed by the novice practitioner.

^bU.S. Surgical Corp., Norwalk, CT.

ROBOTIC-ASSISTED TECHNIQUE

Adult Technique

After the induction of general anesthesia, a retrograde pyelogram is often performed to confirm the diagnosis and define the anatomy. If desired, an internal ureteral stent may be placed at that time, and an indwelling Foley catheter is placed to gravity drainage.

Our Anderson–Hynes dismembered pyeloplasty technique is similar to other previously described methods (25–29). The *da Vinci* Surgical System consists of two interactive robotic arms, a camera arm, a three-dimensional imaging system, and a virtual control chamber.

Newer robot surgical systems have incorporated a fourth arm that can be used as either a second right or a left arm. However, the robotic-assisted pyeloplasty does not warrant a fourth robotic arm, and the protocol is described using a three-arm robot with an assistant.

The patient is placed in a lateral or semilateral decubitus position and three laparoscopic ports, including two 8 mm ports and one 12 mm disposable port, are placed in a “c” configuration (Fig. 1). The beginning portion of the operation is performed as a standard transperitoneal laparoscopic approach by gaining access with a Veress needle or Hasson technique. Some institutions have performed this beginning portion entirely with the robot.

For the novice, it is recommended that the first 20 cases be performed with laparoscopic assistance until a comfort level is reached with the *da Vinci* robot.

Noteworthy, there are reports in the adult literature describing a retroperitoneal approach to the laparoscopic pyeloplasty but not as a robotic-assisted pyeloplasty (30–32).

On the left side, the descending colon is displaced medially in order to gain access to the ureteropelvic junction. On the right side, the peritoneum is incised from the liver attachments down to the iliac vessels and parallel to the ascending colon, allowing identification of the ureteropelvic junction between the lower pole of the kidney and the inferior vena cava. The ureter and renal pelvis are also completely mobilized. Extensive dissection of the proximal ureter is avoided to maintain the vascular supply to the ureter and ureteropelvic junction.

Once the diseased ureteropelvic junction and/or crossing vessel are identified, the *da Vinci* robot is docked into place.

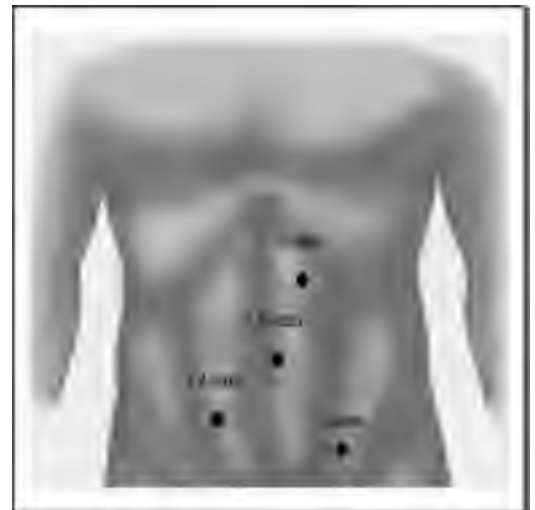Depending on surgeon preference, the camera consisting of a 0° or 30° lens is placed through the disposable 12-mm port at the umbilicus. The robot arms are each placed through the two reusable 8-mm ports. At this time, a fourth port is placed in the lower infraumbilical area in a position contralateral to the operative side. Some surgeons prefer to place this fourth port at the time of the initial port placements. A 12-mm disposable port allows the assisting surgeon to introduce and retrieve sutures, aid in retraction, and perform suctioning. Robotic instruments employed include needle drivers, forceps, and scissors.

Newer robot surgical systems have incorporated a fourth arm that can be used as either a second right or a left arm. However, the robotic-assisted pyeloplasty does not warrant a fourth robotic arm, and the protocol is described using a three-arm robot with an assistant.

For the novice, it is recommended that the first 20 cases be performed with laparoscopic assistance until a comfort level is reached with the *da Vinci* robot.

Once the diseased UPJ and/or crossing vessel are identified, the *da Vinci* robot is docked into place.

FIGURE 1 ■ Trocar positioning for left robotic-assisted laparoscopic Anderson–Hynes-dismembered pyeloplasty in an adult patient. Four laparoscopic ports (two 8 mm ports and two 12 mm disposable ports) are placed in a “c” configuration with one contralateral port. The mirror image is done for a right-sided procedure.



In performing Anderson–Hynes dismembered pyeloplasty, the renal pelvis is circumferentially transected above the ureteropelvic junction (Fig. 2A and B), and the proximal ureter is spatulated laterally. Some earlier cases were performed using laparoscopic endoshears. At this time, the current preference is to spatulate the ureter using potts scissors. In the case of crossing vessels, the ureter and renal pelvis are transposed to the anterior side of the vessel prior to initiation of the anastomosis (Fig. 2C). If the renal pelvis is redundant, excess tissue is excised. An absorbable 4-0 suture is placed through the apex of the spatulated ureter and at the most dependent portion of the renal pelvis. The posterior anastomosis is then performed with an interrupted or running suture. If redundant pelvis tissue was excised, the remaining pyelotomy incision is closed using additional sutures.

If an indwelling stent was not placed at the beginning of the procedure, it is placed into the ureter over a guidewire and under direct vision at this time. The wire can be passed through the abdominal wall using a 14-gauge angiocatheter or the assistant may pass it through the 12-mm accessory port. The distal coil is positioned within the bladder, and the proximal coil is positioned within the renal pelvis. With experience, the distal portion of the stent is easily manipulated into the bladder, but methylene blue dye can be placed in the bladder to confirm positioning of the stent. Alternatively, fluoroscopy may be used to visualize the distal portion of the curled stent in the bladder.

The anterior anastomosis is then completed (Fig. 2D). Following a watertight anastomosis, a drain is placed and then exits the patient via one of the laparoscopic 8-mm ports.

In some of our earlier cases, the indwelling stent was placed prior to surgery but we believe that this made the transection and repair of the ureteropelvic junction more difficult.

Patients are scheduled for follow-up at four to six weeks for stent removal. A diuretic renal scan is performed at three months and annually thereafter. Clinical follow-up is scheduled annually. Success is defined as improvement of symptoms related to the previous renal obstruction and improved function on diuretic renal scan.

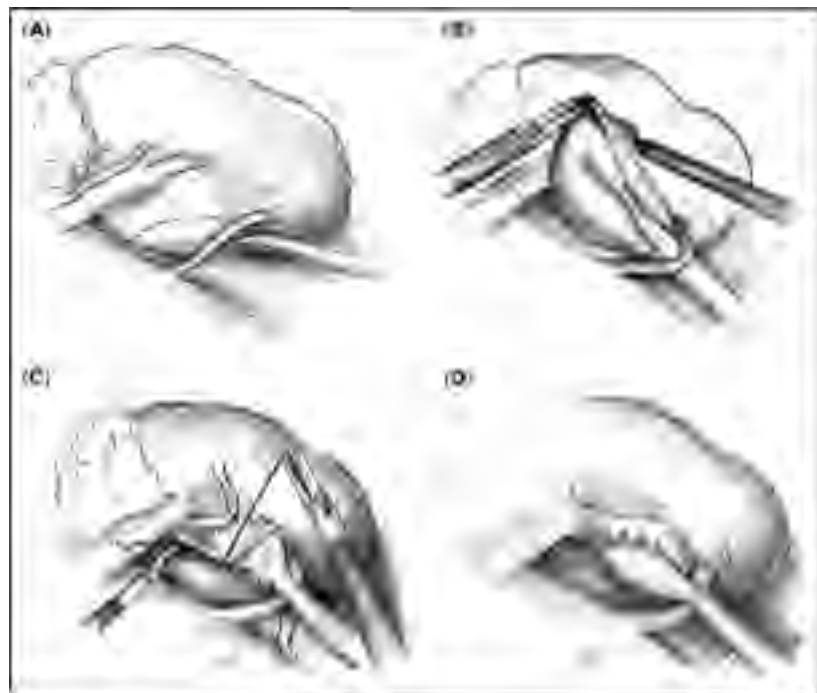
Nondismembered pyeloplasty may be performed for appropriately selected patients using robotic assistance.

Different methods of nondismembered repairs have been described in the laparoscopic pyeloplasty literature such as Culp-DeWeerd spiral flap (33), Fenger plasty (34), Y-V plasty (Fig. 3) (18), Heineke-Mikulicz repair (19), and Davis-intubated ureterotomy (19). The ureteropelvic junction incision and suturing in these repairs are performed in a similar manner as in the open operative intervention.

In some of our earlier cases, the indwelling stent was placed prior to surgery but we believe that this made the transection and repair of the ureteropelvic junction more difficult.

Nondismembered pyeloplasty may be performed for appropriately selected patients using robotic assistance.

FIGURE 2 ■ Anderson–Hynes dismembered pyeloplasty is the procedure of choice for robotic-assisted cases. (A) Dissection of the proximal ureter and ureteropelvic junction reveals a crossing vessel. (B) Incision of the renal pelvis and transposition of the crossing vessel. (C) After spatulation of the ureter laterally, a posterior anastomosis is performed with running or interrupted sutures. (D) A tension-free, water-tight repair is achieved with an internal stent previously placed (not shown).



Pediatric Technique

The transperitoneal Anderson–Hynes dismembered pyeloplasty approach to the pediatric patient is similar to the adult patient (35–38). A retroperitoneal approach to the robotic-assisted pyeloplasty has been described in the pediatric literature, but is less commonly performed (39).

After performing a cystoscopic, retrograde pyelogram to demonstrate the ureteropelvic junction obstruction and placement of a ureteral stent (this may be placed at completion of the repair as an options), the patient is placed in the modified flank position at about 45° to permit transmesenteric access to the pelvis and/or to mobilize the colon medially.

In children with extensive mesenteric fat, mobilization of the colon may be a safer approach. Some authors have suggested performing the initial mobilization of the ureteropelvic junction using the robot, but until a surgeon is completely comfortable with the robot, we suggest starting with a standard laparoscopic approach to mobilize the ureteropelvic junction.

A Hasson approach is used to place a 12-mm supraumbilical trocar for the camera. Two 8-mm robotic trocars are placed in the left anterior axillary line under direct vision (5-mm ports and instruments are likely to be available in the near future). A fourth 5-mm is placed in the left flank just anterior to the colon.

After the renal pelvis is exposed, it is incised leaving a handle of the pelvis and ureteropelvic junction on the ureter for manipulation. Generally a stay suture is also placed at the medial portion of the ureter to aid in retraction. The ureter is spatulated laterally, and any diseased ureteropelvic junction is excised and sent to pathology for evaluation. The previously placed ureteral stent aids in identification of the ureter. The posterior wall anastomosis is started with running or interrupted absorbable suture, usually a 5.0 or 6.0 monocril.

The water-tight anastomosis is finished after the closure of the anterior wall. A JP drain is placed and brought out through the 5-mm port. The transmesenteric incision is closed with a running 4-0 chromic to retroperitonealize the ureter and pelvis. All other ports are closed with fascial stitches that are generally placed at the time of port positioning. A bladder catheter is left in place overnight and then removed in the morning. The JP drain is removed prior to discharge usually the next afternoon.

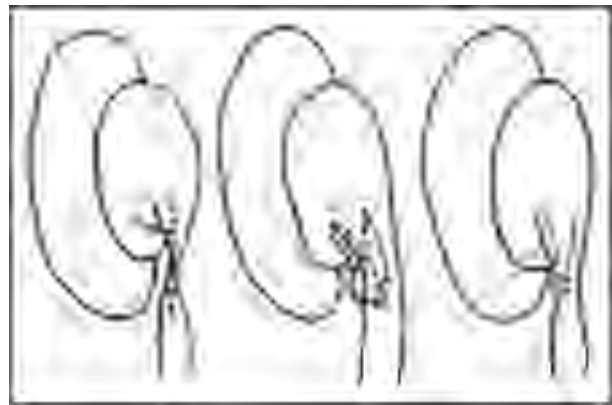
Surgical Steps

The steps involved in a robotic-assisted pyeloplasty can be simplified into a 12-step method.

1. Trocar placement.
2. Transperitoneal exposure of the retroperitoneum using standard laparoscopy.
3. Dissection of the pelvis, ureter, and possible crossing vessel.
4. Docking of the *da Vinci* Surgical System.
5. Transection of the ureteropelvic junction and excision of diseased segment.
6. Spatulation of the ureter laterally.
7. Apical and posterior wall suture placement.
8. Guide wire and stent placement (if not placed at the beginning of operation).

In children with extensive mesenteric fat, mobilization of the colon may be a safer approach. Some authors have suggested performing the initial mobilization of the ureteropelvic junction using the robot, but until a surgeon is completely comfortable with the robot, we suggest starting with a standard laparoscopic approach to mobilize the ureteropelvic junction.

FIGURE 3 ■ Y-V plasty.



9. Anterior wall suture placement.
10. Renal pelvis reconstruction.
11. Reretroperitonealization of the kidney.
12. Placement of JP drain and exiting of the abdomen.

Several experiences with robot-assisted laparoscopic pyeloplasty have demonstrated the feasibility of this technique in providing improved surgical dexterity and decreasing operative times.

We exclusively performed the Anderson–Hynes pyeloplasty repair using the *da Vinci*® robot. This repair is the gold standard for open pyeloplasty repairs and the robot allowed us to duplicate this procedure in the most complicated cases. Intrinsic problems were easily excised and repaired. Exposure and repair of extrinsic problems such as crossing vessels were readily addressed.

During pyeloplasty, the transperitoneal approach offers ease in identifying, dissecting, and mobilizing intra-abdominal structures, whereas the potential disadvantages include prolonged ileus, adhesion formation, and injury to adjacent viscera.

The major advantage of the retroperitoneoscopic approach is that it provides a direct route to the UPJ and allows access without interference from intra-abdominal structures. However, the working space is more restricted and the absence of anatomic landmarks may make dissection more cumbersome for the inexperienced surgeon.

Various Modifications Published in the Literature

Several experiences with robot-assisted laparoscopic pyeloplasty have demonstrated the feasibility of this technique in providing improved surgical dexterity and decreasing operative times (21–23,25–29,35–39).

Gettman et al. compared the *da Vinci* Robotic System to the standard laparoscopic pyeloplasty (23). The investigators noted that the Anderson–Hynes pyeloplasty is feasible with either technique. Procedures performed with the *da Vinci* robot resulted in overall decreased operative times when compared to standard laparoscopy. Gettman et al. also reviewed nine patients who underwent laparoscopic Anderson–Hynes pyeloplasty using the *da Vinci* system (25). The total mean operative time was 138.8 minutes (range 80–215), of which the mean suturing time was 62.4 minutes (range 40–115). Estimated blood loss was less than 50 mL in all cases, and the length of hospitalization averaged 4.7 days (range 4–11). Although there were no intraoperative complications, one patient (11.1%) required postoperative open exploration to repair a persistent renal pelvis defect. At short-term follow-up of 4.1 months (range less than 1–8 months), all procedures were successful on the basis of the subjective and radiographic data. In this series, robot-assisted laparoscopic pyeloplasty resulted in favorable overall operative times, suturing times, and short-term success rates. Peschel et al. presented their clinical experience of 19 patients in whom Anderson–Hynes pyeloplasty and nondismembered pyeloplasty were performed (28). The operative time and hospital stay in both groups were in the range of 90 to 180 and 75 to 130 minutes and 4.7 and 4.5 days, respectively. An overall objective success of 100% was achieved. Another group from France also published an 18 case series of robotic-assisted pyeloplasty with a mean operative time and suturing time of 147 minutes and 42 minutes. The average hospital stay was approximately 6.5 days (29).

In our combined institutional series, all surgeons were able to reduce their operative times (skin to skin) from an average of 283.3 minutes for the first five cases to 192 minutes for the most recent five cases ($p < 0.001$). As even more experience is gained with this procedure, it is likely that this operating time can be reduced even further. In addition, most surgeons preferred to start the case with standard laparoscopic techniques. Reasons for this include that the mobilization of the colon, duodenum, liver, spleen, or pancreas is more easily performed with laparoscopic instruments. Also, during the time of laparoscopy, the surgical staff may set up the *da Vinci* robot. Being performed at a teaching institution, the laparoscopic portion allows all members of the surgical team to be involved with the surgery. Finally, the amount of time required to dock the *da Vinci* system is only 10 to 15 minutes. With more experience, all surgeons will likely start the procedure using only the robot (40).

We exclusively performed the Anderson–Hynes pyeloplasty repair using the *da Vinci* robot. This repair is the gold standard for open pyeloplasty repairs and the robot allowed us to duplicate this procedure in the most complicated cases. Intrinsic problems were easily excised and repaired. Exposure and repair of extrinsic problems such as crossing vessels were readily addressed.

Patients with concomitant stones were successfully addressed at the time of surgery. The larger stones were grasped and extracted under direct vision using a flexible cystoscope. The smaller stones were easily washed out with suction and irrigation. Other authors have similar experiences.

Laparoscopic surgeons continue to show a preference for transperitoneal laparoscopy; however, the feasibility of retroperitoneoscopic pyeloplasty has assisted in elucidating advantages and disadvantages of both approaches.

During pyeloplasty, the transperitoneal approach offers ease in identifying, dissecting, and mobilizing intra-abdominal structures, whereas the potential disadvantages include prolonged ileus, adhesion formation, and injury to adjacent viscera.

The major advantage of the retroperitoneoscopic approach is that it provides a direct route to the ureteropelvic junction and allows access without interference from intra-abdominal structures. However, the working space is more restricted and the absence of anatomic landmarks may make dissection more cumbersome for the inexperienced surgeon.

Olsen et al. describe their experience using the robot surgical system in 13 children to perform robotic-assisted retroperitoneoscopic pyeloplasties (36). They concluded that the technically difficult procedure was easily performed; however, the surgeons without laparoscopic training will encounter problems because the same rules as in laparoscopy apply. These include correct port placement, maintenance of appropriate carbon dioxide pressure, and the basic principle of laparoscopic dissection. In addition, orientation in the retroperitoneal space can be difficult because the surgeon in a remote placement from the patient has no sense of up and down.

Pros and Cons

It is likely that the inexperienced laparoscopic surgeon may gain the most from the *da Vinci* Surgical System.

It is likely the inexperienced laparoscopic surgeon may gain the most from the *da Vinci* Surgical System.

Besides the experience required for performing complex reconstructive procedures, standard laparoscopic surgery is also handicapped by the reduction in the range of motion due to a fixed trocar position determining the angle of the working field. The robotic instruments are designed with seven degrees of motion that mimic the dexterity of the human hand and wrist. Each instrument has a specific surgical mission such as clamping, suturing, and tissue manipulation. In addition, three-dimensional vision is afforded to the surgeon rather than a two-dimensional view in standard laparoscopy. Other advantages include potential loss of tremor, decreased trauma to the patient in comparison to open procedures, and comfort for the surgeon.

Disadvantages include the lack of tactile sensation and thus visualization of anatomic landmarks is the key to successfully completing the operation. The surgeon is away from the operating table and therefore must depend on an experienced assistant. Active communication between the primary surgeon, first assistant, and staff is imperative.

Although the learning curve for the surgeon may be short (in our experience less than 10 cases), there is a substantial learning curve for the ancillary staff. Many hours of in-servicing may be required and consistency in the assignment of staff to *da Vinci* robot cases allows for a smooth transition between cases.

Although the learning curve for the surgeon may be short (in our experience less than 10 cases), there is a substantial learning curve for the ancillary staff. Many hours of in-servicing may be required and consistency in the assignment of staff to *da Vinci* robot cases allows for a smooth transition between cases.

Finally, the cost of the *da Vinci* robot is always a consideration. An initial investment of over \$1,000,000 and subsequent running costs may not make this procedure feasible at many centers. However, as the robotic prostatectomy becomes more popular, the *da Vinci* robot system may become more readily available at many institutions.

TECHNICAL CAVEATS/TIPS

The technical advantages afforded to the surgeon by the robotic surgical system are readily apparent. It is especially intriguing to experience the ease of intracorporeal suturing by the translation of the surgeon's hand movements via a remote console to the robotically manipulated instruments. With any new technology, trial and error pave the way to a successful operation.

It is always important to have performed a cystoscopy and retrograde pyelogram prior to every procedure.

It is always important to have performed a cystoscopy and retrograde pyelogram prior to every procedure. This will help to facilitate your understanding of the ureteropelvic junction anatomy and clearly define the obstruction. In the pediatric population, it may be easier to place the internal stent prior to the docking of the robot system. But in both children and adults, the indwelling stent should never be in the patient for weeks prior to the surgery. The stent leads to ureteral edema, making every anastomotic repair all the more difficult. If a ureteral stent is in place, we recommend removing the stent at least one week prior to pyeloplasty repair.

When placing a ureteral stent prior to completion of the water-tight anastomosis, it is important to make sure that the guide wire is pushed into the bladder.

When placing a ureteral stent prior to completion of the water-tight anastomosis, it is important to make sure that the guide wire is pushed into the bladder.

A "hitch stitch" placed at the medial side of the ureter may aid in retraction.

The addition of methylene blue into a full bladder with a clamped Foley may aid in the successful placement of the ureteral stent. Fluoroscopy or direct vision of the distal end of the stent in the bladder with a flexible cystoscope may also ensure proper placement of the ureteral stent.

The novice robotic surgeon will find the robotic-assisted pyeloplasty to be a wonderful introduction to the robotic surgical system.

A "hitch stitch" placed at the medial side of the ureter may aid in retraction. This stitch can either be held by the operating surgeon or the assistant, or can be tacked up to the peritoneal wall if necessary. Alternatively leaving some diseased ureter and/or periureteral tissue attached will create a handle for retraction.

The novice robotic surgeon will find the robotic-assisted pyeloplasty to be a wonderful introduction to the robotic surgical system.

The first several cases may be time consuming, but for the surgeon, the greatest advantage is the comfortable working position. Also, the three-dimensional view with

easy handling of the instruments will lead to shorter operative times as experience is gained.

SPECIFIC MEASURES TO AVOID COMPLICATIONS

There are several disadvantages to the robotic surgical system that may lead to complications if not taken into account. Firstly, the robot surgical system is expensive and requires a large initial and ongoing investment for the hospital. Surgeons and operating room personnel must both be trained to use the system safely and efficiently. This also includes care and storage of the robot device.

If personnel are not appropriately trained and careful when setting up and taking down the device, complications could theoretically occur secondary to mechanical failures.

There have been no system malfunctions to date that could not be attributed to human error. Most common are instrument malfunction due to incorrect insertion or vision system problems due to incorrect calibration. External collisions of robotic arms are usually due to judgment errors in trocar placement or cart positioning.

The operating surgeon must become accustomed to the absence of haptic feedback. Complications may ensue owing to the lack of tactile sensation. Tissue damage may occur secondarily to excessive pressure or tension.

Until extensive experience is gained with the robotic surgical system, it is recommended that the novice robotic surgeon start the robotic-assisted pyeloplasty with a standard laparoscopic technique.

This will ensure familiarity of the anatomy and help to avoid any complications. Also, preoperative installation of the robot surgical system may require 30 to 60 minutes depending on personnel experience. This must always be taken into consideration when operating room times are assessed. Therefore, beginning the case as a standard laparoscopic procedure may give the operating room staff time to complete the robot surgical system setup.

If personnel are not appropriately trained and careful when setting up and taking down the device, complications could theoretically occur secondary to mechanical failures.

Until extensive experience is gained with the robotic surgical system, it is recommended that the novice robotic surgeon start the robotic-assisted pyeloplasty with a standard laparoscopic technique.

SUMMARY

- Technologic advances have played a significant role in the therapeutic management of ureteropelvic junction obstruction and have enabled the introduction of laparoscopic- and robotic-assisted laparoscopic pyeloplasty over the last several years.
- The surgical robot is well suited for the reconstruction of the ureteropelvic junction and is a good procedure for the novice robotic surgeon to attempt.
- The presence of a crossing vessel is not a contraindication for laparoscopic- or robotic-assisted pyeloplasty.
- Several experiences with robot-assisted laparoscopic pyeloplasty have demonstrated the feasibility of this technique in providing improved surgical dexterity.
- Although the learning curve for the surgeon may be short (in our experience less than 10 cases), there is a substantial learning curve for the ancillary staff. Many hours of in-servicing may be required, and consistency in the assignment of staff to da Vinci robot cases allows for a smooth transition between cases.
- The novice robotic surgeon is likely to find the robotic-assisted pyeloplasty to be a good introduction to the robotic surgical system.

REFERENCES

1. Foote JW, Blennerhassett JB, Wigglesworth FW, Mackinnon KJ. Observations on the ureteropelvic junction. *J Urol* 1970; 104:252.
2. Allen TD. Congenital ureteral strictures. *J Urol* 1970; 104:196.
3. Hanna MK, Jeffs RD, Sturgess JM, Barkin M. Ureteral structure and ultrastructure. Part II. Congenital ureteropelvic junction obstruction and primary obstructive megaureter. *J Urol* 1976; 116:725.
4. Maizels M, Stephens FD. Valves of the ureter as a cause of primary obstruction of the ureter: anatomic, embryologic and clinical aspects. *J Urol* 1980; 123:742.
5. Zincke H, Kelalis PP, Culp OS. Ureteropelvic obstruction in children. *Surg Gynecol Obstet* 1974; 139:873.
6. Janetschek G, Peschel R, Bartsch G. Laparoscopic Fenger plasty. *J Endourol* 2000; 14:889.
7. Notley RG, Beaugie JM. The long-term follow-up of Anderson-Hynes pyeloplasty for hydronephrosis. *Br J Urol* 1973; 45:464.
8. Persky L, Krause JR, Boltuch RL. Initial complications and late results in dismembered pyeloplasty. *J Urol* 1977; 118:162.

9. Brooks JD, Kavoussi LR, Preminger GM, Schuessler WW, Moore RG. Comparison of open and endourologic approaches to the obstructed ureteropelvic junction. *Urology* 1995; 46:791.
10. Cassis AN, Brannen GE, Bush WH, Correa RJ, Chambers M. Endopyelotomy: review of results and complications. *J Urol* 1991; 146:1492.
11. Meretyk I, Meretyk S, Clayman RV. Endopyelotomy: comparison of ureteroscopic retrograde and ante grade percutaneous techniques. *J Urol* 1992; 148:775.
12. Motola JA, Badlani GH, Smith AD. Results of 221 consecutive endopyelotomies: an 8-year follow-up. *J Urol* 1993; 149:453.
13. Nadler RB, Rao GS, Pearle MS, Nakada SY, Clayman RV. Acucise endopyelotomy: assessment of long-term durability. *J Urol* 1996; 156:1094.
14. Faerber GJ, Richardson TD, Farah N, Ohl DA. Retrograde treatment of ureteropelvic junction obstruction using the ureteral cutting balloon catheter. *J Urol* 1996; 157:454.
15. Preminger GM, Clayman RV, Nakada SY, et al. A multicenter clinical trial investigating the use of a fluoroscopically controlled cutting balloon catheter for the management of ureteral and ureteropelvic junction obstruction. *J Urol* 1997; 157:1625.
16. Shuessler WW, Grune MT, Tecuanhuey LV, Preminger GM. Laparoscopic dismembered pyeloplasty. *J Urol* 1993; 150:1795.
17. Bauer JJ, Bishoff JT, Moore RG, Chen RN, Iverson AJ, Kavoussi LR. Laparoscopic versus open pyeloplasty: assessment of objective and subjective outcome. *J Urol* 1999; 162:692.
18. Moore RG, Averch TD, Schulam PG, Adams JB, Chen RN, Kavoussi LR. Laparoscopic pyeloplasty: experience with the initial 30 cases. *J Urol* 1997; 157:459.
19. Jarrett TW, Chan DY, Charambura TC, Fugita O, Kavoussi LR. Laparoscopic pyeloplasty: the first 100 cases. *J Urol* 2002; 167:1253.
20. Chen RN, Moore RG, Kavoussi LR. Laparoscopic pyeloplasty. Indications, technique, and long-term outcome. *Urol Clin North Am* 1998; 25:323.
21. Sung GT, Gill IS, Hsu TH. Robotic-assisted laparoscopic pyeloplasty: a pilot study. *Urology* 1999; 53:1099.
22. Sung GT, Gill IS. Robotic laparoscopic surgery: a comparison of the da Vinci and Zeus systems. *Urology* 2001; 58:893.
23. Gettman MT, Peschel R, Neururer R, Bartsch G. A comparison of laparoscopic pyeloplasty performed with the daVinci robotic system versus standard laparoscopic techniques: initial clinical results. *Eur Urol* 2002; 42:453.
24. Streem SB. Ureteropelvic junction obstruction. Open operative intervention. *Urol Clin North Am* 1998; 25:331.
25. Gettman MT, Neururer R, Bartsch G, Peschel R. Anderson-Hynes dismembered pyeloplasty performed using the da Vinci robotic system. *Urology* 2002; 60:509.
26. Yohannes P, Burjonrappa SC. Laparoscopic Anderson-Hynes dismembered pyeloplasty using the da Vinci Robot: technical Considerations. *J Endourol* 2003; 17:79.
27. Bentas W, Wolfram M, Brautigam R, et al. Da Vinci robot assisted Anderson-Hynes dismembered pyeloplasty: technique and 1 year follow up. *World J Urol* 2003; 21:133.
28. Peschel R, Gettman M, Bartsch G. Robotic-assisted laparoscopic pyeloplasty: initial clinical results. *Eur Urol* 2003; 2:46.
29. Hubert J, Feuillu B, Artis M. Robotic remote laparoscopic treatment of ureteropelvic junction syndrome: 18 cases. *Eur Urol* 2003; 2:101.
30. Puppo P, Perachino M, Ricciotti G, Bozzo W, Pezzica C. Retroperitoneoscopic treatment of ureteropelvic junction obstruction. *Eur Urol* 1997; 31:204.
31. Ben Slama MR, Salomen L, Hoznek A, et al. Extraperitoneal laparoscopic repair of ureteropelvic junction obstruction: initial experience in 15 cases. *Urology* 2000; 56:45.
32. Soulie M, Salomon L, Patard JJ, et al. Extraperitoneal laparoscopic pyeloplasty: a multicenter study of 55 procedures. *J Urol* 2001; 166:48.
33. Nakada SY, McDougall EM, Clayman RV. Laparoscopic pyeloplasty for secondary ureteropelvic junction obstruction: preliminary experience. *Urology* 1995; 46:257.
34. Janetschek G, Peschel R, Altarac S, Bartsch G. Laparoscopic and retroperitoneoscopic repair of ureteropelvic junction obstruction. *Urology* 1996; 47:311.
35. Peters CA. Robotic assisted surgery in pediatric urology. *Ped Endo Inn Tech* 2003; 7:403.
36. Luebbe BN, Woo R, Wolf SA, Irish MS. Robotically assisted minimally invasive surgery in a pediatric population: initial experience, technical considerations, and description of the da Vinci® Surgical System. *Ped Endo Inn Tech* 2003; 7:385.
37. Drasin T, Gracia C, Atkinson J. Pediatric applications of robotic surgery. *Ped Endo Inn Tech* 2003; 7:377.
38. Peters CA. Laparoscopy in pediatric urology. *Curr Opin Urol* 2004; 14:67.
39. Olsen LH, Jorgensen TM. Computer assisted pyeloplasty in children: the retroperitoneal approach. *J Urol* 2004; 171:2629.
40. Palese, MA, Munver R, Phillips CK, et al. The robotic pyeloplasty: a combined New York experience [Abstract-AUA]. *J Urol* 2004; 171:394.
41. Gettman MT, Neururer R, Chow GK, Bartsch G, Peschel R. Robotic-assisted laparoscopic pyeloplasty: Initial clinical results [Abstract-AUA]. *J Urol* 2004; 171:4.
42. Bhalla RS, Hefty TR, Kozloski PM. DaVinci™ assisted laparoscopic pyeloplasty: the use of the daVinci™ system for the entire case [Abstract-AUA]. *J Urol* 2004; 171:395.
43. Schiff JD, Li PS, Nobert C, Poppas DP. Pediatric robotic pyeloplasty [Video-AUA]. *J Urol* 2004; 171:387.

LAPAROSCOPIC PYELOPLASTY: CURRENT STATUS

Ioannis M. Varkarakis and Thomas W. Jarrett

The James Buchanan Brady Urological Institute, Johns Hopkins Medical Institutions, Baltimore, Maryland, U.S.A.

- INTRODUCTION
- CURRENT MANAGEMENT OF URETEROPELVIC JUNCTION OBSTRUCTION AND INDICATIONS FOR LAPAROSCOPIC PYELOPLASTY
- RESULTS: TRANSPERITONEAL LAPAROSCOPIC PYELOPLASTY
- RESULTS: RETROPERITONEAL LAPAROSCOPIC PYELOPLASTY
- LAPAROSCOPIC PYELOPLASTY IN CHILDREN
- ROBOT-ASSISTED LAPAROSCOPIC PYELOPLASTY
- LAPAROSCOPIC PYELOPLASTY FOR SECONDARY URETEROPELVIC JUNCTION OBSTRUCTION
- LAPAROSCOPIC PYELOPLASTY WITH CONCOMITANT PYELOLITHOTOMY
- CAVEATS
- LAPAROSCOPIC PYELOPLASTY IN THE PRESENCE OF UPPER URINARY TRACT ABNORMALITIES
- MANAGEMENT OF FAILED PRIMARY LAPAROSCOPIC PYELOPLASTY
- SUMMARY
- REFERENCES
- COMMENTARY: Michael C. Ost and Arthur Smith

INTRODUCTION

Ureteropelvic junction obstruction leads to progressive dilatation of the renal collecting system and can result in progressive deterioration of renal function. Most cases are congenital; however, symptoms are not clinically apparent until later in life. Most frequent presenting symptoms are flank pain, urinary tract infection, and hematuria after minor trauma. It is the most common site of obstruction in the upper urinary tract, and surgical management is necessary when obstruction is confirmed with functional radiographic studies.

The gold standard therapy for repair of ureteropelvic junction obstruction has been open pyeloplasty with long-term success rates consistently exceeding 90% (1,2).

In an attempt to reduce the morbidity of the flank incision, new minimally invasive procedures, endoscopic or fluoroscopic retrograde, and endoscopic percutaneous antegrade pyelotomy were developed (3–6). All achieved the goals of short hospital stay and rapid recovery, but had lower success rates.

In an effort to achieve both minimal morbidity and results equivalent to or better than those of open surgery, laparoscopic dismembered pyeloplasty was introduced in 1993 (7,8). Initial promising results were confirmed by larger series (9–12). Despite the existing long learning curve, laparoscopic pyeloplasty is now an established procedure at select centers worldwide, applicable to both pediatric (13,14) and adult patient populations.

Dismembered and nondismembered pyeloplasties [Foley Y-V (15), Fenger (16)] may be performed using transperitoneal and retroperitoneal laparoscopic approaches.

CURRENT MANAGEMENT OF URETEROPELVIC JUNCTION OBSTRUCTION AND INDICATIONS FOR LAPAROSCOPIC PYELOPLASTY

The treatment of adult ureteropelvic junction obstruction has undergone significant changes during the past two decades, with the advent of laparoscopic pyeloplasty being one of them. Despite its advantages, this procedure requires both laparoscopic experience and considerable skill with laparoscopic suturing. Laparoscopic approaches are performed in selected centers and only recently have been integrated into almost all residency programs. As a consequence, laparoscopic pyeloplasty is still not widely performed. The familiarity of most urologists with endoscopic techniques makes endopyelotomy feasible without the need for any further training after residency. As a

The gold standard therapy for repair of ureteropelvic junction obstruction has been open pyeloplasty. Long-term success rates consistently exceed 90%.

In an effort to achieve both minimal morbidity and results equivalent to or better than those of open surgery, laparoscopic dismembered pyeloplasty was introduced in 1993.

Dismembered and nondismembered pyeloplasties may be performed using transperitoneal and retroperitoneal laparoscopic approaches.

In the presence of a crossing vessel or a huge pelvis, laparoscopic dismembered pyeloplasty is preferred due to its low morbidity and the capability of transposing the crossing vessel or reducing the renal pelvis similar to open pyeloplasty.

The transperitoneal approach, which provides more anatomic landmarks than the retroperitoneal approach, has been used in most pyeloplasty series and is considered easier for the beginner.

Morbidity of transperitoneal laparoscopic pyeloplasty has been shown to be considerably less than that of open pyeloplasty. Complications have decreased with experience and range between 11% and 20% in latest series.

In all studies comparing laparoscopic versus open pyeloplasty, the laparoscopic approach provides less post-operative pain, shorter hospital stay, and faster recovery. Success rates in most recent series are above 90% and similar to those obtained with the open approach.

consequence, endopyelotomy still continues to be more commonly performed, even in tertiary referral centers (17). However, endopyelotomy frequently fails in the presence of a crossing vessel or a very dilated renal pelvis. Current imaging with three-dimensional helical computing tomography or contrast-enhanced color Doppler can identify accurately abnormal renal vessels. Therefore preoperative knowledge of the existence of a crossing vessel or a huge pelvis allows urologists to avoid endoscopic management.

In the presence of a crossing vessel or a huge pelvis, laparoscopic dismembered pyeloplasty is preferred due to its low morbidity and the capability of transposing the crossing vessel or reducing the renal pelvis similar to open pyeloplasty.

Patients with anatomic variations such as a horseshoe or pelvic kidney are also good candidates for laparoscopic surgery. Failed prior procedures do not preclude laparoscopy (18,19). The presence of ipsilateral renal calculi is not a contraindication for the procedure (20). However, laparoscopic pyeloplasty for small intrarenal pelvis would be technically challenging, similar to open surgery.

RESULTS: TRANSPERITONEAL LAPAROSCOPIC PYELOPLASTY

The transperitoneal approach, which provides more anatomic landmarks than the retroperitoneal approach, has been used in most pyeloplasty series and is considered easier for the beginner.

Although more space for intracorporeal suturing is provided, proficiency in suturing and tying techniques are important in completing a watertight anastomosis. Laparoscopic suturing is tedious and often responsible for the long operating times seen in most laparoscopic pyeloplasty series. Unfortunately, operation time is still the highest among therapeutic modalities for ureteropelvic junction obstruction. Nevertheless with increasing experience and improved instrumentation, operating times have decreased as confirmed in studies with larger number of patients (Table 1) (9,13,21–23). Conversion rates range from 1.4% to 20% (16,22), and are usually dependent on the ability to complete a free tension anastomosis (Table 1).

Morbidity of transperitoneal laparoscopic pyeloplasty has been shown to be considerably less than that of open pyeloplasty (22). Complications have decreased with experience and range between 11% and 20% in latest series (Table 1) (24,25).

A variety of complications general to laparoscopy and specific to the procedure itself have been reported (Table 2). Minor complications predominate with the most common being urine leak and persistent drainage, which are usually treated conservatively. With experience, improving methods of creating the anastomosis and securing drains can minimize complications.

In all studies comparing laparoscopic versus open pyeloplasty, the laparoscopic approach provides less post-operative pain, shorter hospital stay, and faster recovery (27,28). Success rates in most recent series are above 90% and similar to those obtained with the open approach (12,26).

TABLE 1 ■ Transperitoneal Laparoscopic Pyeloplasty Series

Study	Units	Procedure	Mean OR time in minutes (range)	Conversion rate (%)	CV (%)	Mean FU in months (range)	Success rate (%)	Mean HS in days (range)	Complications (%)
Schuessler et al. (7)	5	AH	330 (210–240)	–	–	12 (9–17)	100	3	20
Kavoussi et al. (8)	1	AH	480	–	–	–	100	3	–
Recker et al. (23)	5	AH	305 (190–390)	20	–	9 (6–15)	100	8 (7–10)	–
Janetschek et al. (24)	11	Various	215 (120–360)	9	–	–	100	5.1 (3–11)	18.1
Chen et al. (21)	13	AH	340 (240–360)	–	–	13	100	3.2 (2–4)	15
Moore et al. (15) ^a	30 ^a	AH/Y-V	270 (135–480)	–	60	16.3 (4–73)	96.6	3.4 (2–6)	9.9
Chen et al. (9) ^a	57 ^a	AH/Y-V	258 (138–480)	–	–	–	–	3.3 (2–6)	12.3
Bauer et al. (22) ^a	42 ^a	AH	–	–	38	22 (12–38)	98	–	12
Janetschek et al. (16) ^a	67	Fenger/Y-V	123 (189–210)	1.4	79	25 (4–60)	98	4.1	–
Jarrett et al. (12) ^a	100 ^a	AH/Fenger/Y-V	252 (120–480)	–	57	31 (12–84)	96	3.3 (2–8)	13
Siqueira et al. (25) ^a	19	AH/Fenger	240 (128–470)	–	63	7.8 (6–27)	94	2.9 (2–7)	11.7
Türk et al. (26)	49	AH	165 (90–240)	–	57.1	23.2 (1–53)	97.7	3.7 (3–6)	–

^aExtraperitoneal procedures included.

Abbreviations: OR, operating room; CV, crossing vessel; FU, follow-up; AH, Anderson-Hynes; HS, hospital stay.

TABLE 2 ■ Complications Reported During Transabdominal Laparoscopic Pyeloplasty

Serosal tear	Transient ureteral edema	Myocardial infarction
Abdominal wall hematoma	Stent migration	Congestive heart failure
Clipped colonic diverticulum	Transient ileus	Pneumonia
Urinoma formation	Pyelonephritis	Thrombophlebitis
Postoperative bleeding	Stone recurrence	

When compared to retrograde endopyelotomy, the laparoscopic approach presents with more postoperative pain, longer hospital stay, and slower recovery. On the contrary, when compared to percutaneous endopyelotomy, these differences are not so prominent and all the above parameters are almost similar.

Lack of standardization of pre- and postoperative investigations may confound interpretation of data when evaluating rates of success among various methods of treating ureteropelvic junction obstruction. As such, the definition of final success should comprise subjective improvement of pain analog scores along with objectively improved drainage. Intravenous pyelogram or nuclear renal scan with diuretic is the best way to evaluate for persistent obstruction. Retrograde pyelography is helpful with equivocal cases.

With increasing experience similar operating times to open pyeloplasty have been achieved with retroperitoneal pyeloplasty. Some authors even reported shorter operating times than the transabdominal approach. Open conversion is infrequent and occurs due to problems to create a watertight anastomosis without tension.

This is attributed to the fact that laparoscopy allows direct evaluation of the ureteropelvic junction and therefore appropriate management of crossing vessels and dilated renal pelvis in a similar way to the open procedure. This may be why laparoscopy presents with better overall results than endoscopic management. When the anatomic conditions that predispose to failure of endoscopic management are absent, antegrade endopyelotomy and laparoscopic pyeloplasty present with equally good results (29).

When compared to retrograde endopyelotomy, the laparoscopic approach presents with more postoperative pain, longer hospital stay, and slower recovery. On the contrary, when compared to percutaneous endopyelotomy, these differences are not so prominent and all the above parameters are almost similar (30).

Good pyeloplasty results rely on selecting the appropriate technique. This depends from the anatomy of the obstruction encountered in each patient. For example, Fenger plasty is less extensive repair than dismembered pyeloplasty and should be used for short strictures with a not very dilated renal pelvis. With the laparoscopic approach, the technique chosen, dismembered or nondismembered, can be selected intraoperatively, while taking into consideration the anatomy of the ureteropelvic junction obstruction. This obviates the necessity for detailed preoperative imaging of the ureteropelvic junction anatomy and renal vasculature.

Lack of standardization of pre- and postoperative investigations may confound interpretation of data when evaluating rates of success among various methods of treating ureteropelvic junction obstruction. As such, the definition of final success should comprise subjective improvement of pain analog scores along with objectively improved drainage. Intravenous pyelogram or nuclear renal scan with diuretic is the best way to evaluate for persistent obstruction. Retrograde pyelography is helpful with equivocal cases.

RESULTS: RETROPERITONEAL LAPAROSCOPIC PYELOPLASTY

With the retroperitoneal technique the abdomen is not entered and therefore this approach may be preferable when multiple adhesions from previous intrabdominal operations are expected. Some authors suggest that using the retroperitoneal access, the ureteropelvic junction may be visualized after a relatively limited dissection, and crossing vessels causing the obstruction better appreciated. On the contrary, the transperitoneal access approaches the ureteropelvic junction from the wrong (vessel) side of the renal hilum mandating more dissection with the potential for more distortion before the ureteropelvic junction can be visualized.

Extraperitoneal laparoscopy is difficult for the inexperienced. Orientation is harder because anatomic landmarks are not as evident as in transperitoneal laparoscopy. In addition, less working space is available, making intracorporeal suturing more challenging. Any previous retroperitoneal surgery makes subsequent retroperitoneal laparoscopic pyeloplasty very difficult and therefore unsuitable for secondary ureteropelvic junction.

With increasing experience similar operating times to open pyeloplasty have been achieved with retroperitoneal pyeloplasty (31). Some authors even reported shorter operating times than the transabdominal approach. Open conversion is infrequent and occurs due to problems to create a watertight anastomosis without tension.

Short hospital stay (32), low analgesic requirements, and fast recovery confirm the advantages of laparoscopy also with the retroperitoneal approach. Low morbidity with similar complication rates is seen as well (10).

Success rates of retroperitoneal laparoscopic pyeloplasty are comparable to its transabdominal counterpart (11,33). However long-term outcomes must be assessed for further validation of this approach. In fact, in the only direct comparison of the retroperitoneal approach to the open procedure by Soulie et al. (31) the only advantage reported was a more rapid return to normal activity, particularly in young patients (Table 3).

TABLE 3 ■ Retroperitoneal Laparoscopic Pyeloplasty Series

Authors	Renal units	Procedure	OR time in minutes (range)	Conversion (%)	Crossing vessels (%)	FU in months (range)	Success (%)	HS in days (range)	Complications (%)
Puppo et al. (32)	11	AH	190 (150-240)	45.4			63.4	3.3, (4-7)	
Ben Slama et al. (33)	15	Various	178 (100-250)	6.6	26.6	16.6 (6-32.3)	100	4.8, (1-14)	20
Eden et al. (11)	50	AH	164 (120-240)	4	30	18.8 (3-72)	98	2.6, (2-7)	4
Soulie et al. (10)	55	Various	185 (150-240)	5.4	42.6	14.4 (6-43)	88.9	4.5, (1-14)	12.7

Abbreviations: AH, Anderson-Hynes; FU, follow-up; OR, operating room; HS, hospital stay.

LAPAROSCOPIC PYELOPLASTY IN CHILDREN

The small caliber of a child's ureter makes pyeloplasty a difficult procedure.

The small caliber of a child's ureter makes pyeloplasty a difficult procedure. For this reason, dismembered pyeloplasty is not ideal in children younger than six months and should be avoided. However, this technique remains the preferred method for treating ureteropelvic junction obstruction in older children and the open dismembered pyeloplasty is the gold standard.

Children's body habitus requires smaller instrumentation and fine 6.0 sutures for the ureteropelvic junction reconstruction. The first laparoscopic dismembered pyeloplasty in a pediatric patient was performed by Peters et al. (34) when 3 mm laparoscopic ports and instruments became available.

Available series of laparoscopic dismembered pyeloplasty showed excellent results, thus confirming the feasibility and safety of this procedure in this patient population.

Available series of laparoscopic dismembered pyeloplasty showed excellent results, thus confirming the feasibility and safety of this procedure in this patient population (Table 4) (13,14,35).

Both transperitoneal and retroperitoneal routes, and lower insufflation pressures (12 mmHg) were employed. Recently robot-assisted pyeloplasty was performed using the *da Vinci* Surgical System^a with equally good results in a series of 13 children older than 3.5 years (36). However, longer follow-up and further evaluation of the metabolic effects of CO₂ insufflation in children undergoing laparoscopic surgery are awaited before establishing laparoscopic pyeloplasty the standard of care in this population.

ROBOT-ASSISTED LAPAROSCOPIC PYELOPLASTY

Laparoscopic pyeloplasty requires expertise and ability with intracorporeal suturing. Despite improvements in surgical instrumentation, laparoscopic pyeloplasty remains a demanding procedure that requires a long learning curve.

The recent introduction of robotics in the field of minimally invasive surgery may facilitate this procedure and allow for more widespread implementation by surgeons of varying skill levels. The goal of advance robotic systems is to improve operative technique and simplify suturing during reconstructive procedures.

Initially, two robotic systems were available: the ZeusTM^b and the *da Vinci*TM. Animal studies comparing the two systems demonstrated a shorter learning curve and operative

TABLE 4 ■ Laparoscopic Pyeloplasties in Pediatric Series of Patients

Authors	Units	Age (range)	Access	Procedure	Mean OR time (range)	Conversion (%)	Mean HS (range)	Mean FU (range)	Success (%)
El Ghoneimi et al. (35)	22	8 (1.7-17)	Retroperitoneal	AH dismembered pyeloplasty	228 (170-300)	(18.1)	2.5 (2-4)	12.7 (2-36)	100
Tan (13)	18	1.4 (0.25-10)	Transperitoneal	AH dismembered pyeloplasty	89				87
Yeung et al. (14)	13	2.7 (0.25-10)	Retroperitoneal	AH dismembered pyeloplasty	143 (103-235)	(15.3)			100

Abbreviations: AH, Anderson-Hynes; OR, operating room; HS, hospital stay; FU, follow-up.

^aIntuitive Surgical, Inc., Mountain View, CA.

^bComputer Motion, Santa Barbara, CA.

times with the *da Vinci* system, which is now the only commercially available robotic system (37). These systems may enable the surgeon inexperienced with laparoscopic suturing to perform reconstructive procedures with greater ease. Experimental data showing that intracorporeal suturing and dexterity tasks are learned quicker using robot-assisted than manual laparoscopy indicated the robot as an ideal choice during reconstructive surgery (38).

Gettman et al. (39) confirmed the feasibility and safety of robot-assisted dismembered pyeloplasty in a small number of patients. Mean suturing time was 62.4 minutes and overall operating time 138.8 minutes, shorter than those reported in conventional laparoscopic pyeloplasty series. A comparison of conventional versus robot-assisted laparoscopic pyeloplasty, both dismembered and nondismembered, performed in the same institution confirmed shorter operating times in the robotic group (40). Although the robotic system was favorable for suturing; some aspects of the procedure that require gross rather than precise movements, e.g., the reflection of the bowel or the counter traction during dissection, were more difficult with the robotic arms.

Although suturing for the inexperienced is easier with the robot, laparoscopic knowledge is still required and the use of the robot involves a steep learning curve as well.

Proper trocar placement is necessary to prevent mechanical interference between the robotic arms. Due to the lack of tactile feedback, the surgeon must develop an intuition about suture tension to prevent suture breakage and tissue strangulation during knot-tightening. As a result, laparoscopic surgeons experienced with intracorporeal suturing may not find the robot helpful. Finally investment and running costs are factors that must be considered.

A larger number of patients with longer follow-up must be evaluated to determine whether pyeloplasty performed with robotic assistance have equally good functional results as those obtained with conventional laparoscopic pyeloplasty.

Although suturing for the inexperienced is easier with the robot, laparoscopic knowledge is still required and the use of the robot involves a steep learning curve as well.

LAPAROSCOPIC PYELOPLASTY FOR SECONDARY URETEROPELVIC JUNCTION OBSTRUCTION

Endourological treatment of ureteropelvic junction obstruction has been established as a minimally invasive alternative to open pyeloplasty. It is frequently preferred due to its good results and the familiarity urologists have with endoscopy. Nevertheless, endopyelotomy in the presence of crossing vessels, high-grade hydronephrosis, or poor renal function associates with high failure rates. Although recommended as salvage procedure in such cases, open pyeloplasty associated with incisional morbidity, prolonged recovery, and difficult intraoperative dissection.

Laparoscopic pyeloplasty has been used in the presence of crossing vessels, high-grade hydronephrosis, and poor renal function as another minimally invasive alternative. The laparoscopic ability to directly identify crossing vessels and reduce a large renal pelvis recapitulates the advantages of the open approach.

A transperitoneal access may be preferable. Postoperative fibrosis and adhesions are always present in the region of the previously operated ureteropelvic junction. This makes secondary procedures, both open and laparoscopic more challenging. In the largest series ($N=36$) of secondary laparoscopic pyeloplasties by Sundaram et al. (19), initial long operating time (6.2 hours) decreased with experience and open conversion was necessary only in one instance. Although the advantages of less analgesic requirements, shorter hospital stay, and faster recovery were confirmed, success rates of 83% to 88% are poorer than the results of open pyeloplasty (95%) for secondary ureteropelvic junction obstruction due to failed endopyelotomy (12,18,19,41). However, differences in subjective and objective criteria determining success may be responsible for this difference.

LAPAROSCOPIC PYELOPLASTY WITH CONCOMITANT PYELOLITHOTOMY

Ureteropelvic junction obstruction can be complicated by the presence of renal stones. Correction of the ureteropelvic junction, necessary to prevent stone recurrence, and stone removal consisting of open pyeloplasty and pyelolithotomy or percutaneous pyelolithotomy followed by endopyelotomy performed at the same setting have been the gold standard (42). The open approach has a success rate of 90% but is associated with more postoperative pain and prolonged recovery. On the other hand, the minimally invasive percutaneous approach is associated with lesser morbidity, faster recovery, but also lower success rates (64–85%) (3,43,44).

In an effort to achieve better results and less morbidity, concomitant pyelolithotomy and pyeloplasty were attempted using a laparoscopic approach. Both retroperitoneal and transperitoneal access have been reported (45,46). In the largest series of

Laparoscopic pyeloplasty has been used in the presence of crossing vessels, high-grade hydronephrosis, and poor renal function as another minimally invasive alternative. The laparoscopic ability to directly identify crossing vessels and reduce a large renal pelvis recapitulates the advantages of the open approach.

laparoscopic pyeloplasty and concomitant pyelolithotomy reported by Ramakumar et al., spoon forceps, basket graspers, and holmium laser were used for stone removal or fragmentation (20). A flexible cystoscope was introduced through one of the working ports to detect and remove calculi located in calyces, especially those in the lower pole.

CAVEATS

- Incomplete transection of the ureter before performing a dismembered pyeloplasty prevents retraction of the renal pelvis and the problematic introduction of any further instrument for stone removal.
- Initial pyelotomy through which the stones are removed should be kept as small as possible to prevent avulsion of the ureteropelvic junction during manipulations.

Laparoscopic pyelolithotomy is feasible when combined with pyeloplasty. Although technically demanding, the results obtained are comparable to those of stone removal during open pyeloplasty or percutaneous endopyelotomy. The advantages of open surgery appear to be maintained in this minimally invasive approach.

Both dismembered and nondismembered techniques have been used. Despite long operating times (mean 4.6 hours), no complication occurred and hospital stay was short (3.4 days). Stone free and pyeloplasty success rates were both 90%.

Laparoscopic pyelolithotomy is feasible when combined with pyeloplasty. Although technically demanding, the results obtained are comparable to those of stone removal during open pyeloplasty or percutaneous endopyelotomy. The advantages of open surgery appear to be maintained in this minimally invasive approach.

LAPAROSCOPIC PYELOPLASTY IN THE PRESENCE OF UPPER URINARY TRACT ABNORMALITIES

Ureteropelvic junction obstruction can be associated with renal anomalies and occurs in 25% to 33% of horseshoe kidneys (47), and 22% to 37% of ectopic kidneys (48). Due to the rarity of these renal anomalies, few reports address the treatment of ureteropelvic junction obstruction in adults with congenital urinary tract malformations. Open pyeloplasty is the preferred management and has been reported to be successful in 55% to 80% of patients with a horseshoe kidney (49,50). Despite a success rate of 78% (51), retrograde endopyelotomy in horseshoe or ectopic kidneys is more risky because such kidneys usually have anomalous vascular supply. In addition, the abnormal anatomic site of these kidneys makes percutaneous access quite challenging. In fact, the access to the above mentioned study was obtained with laparoscopic assistance.

Laparoscopic pyeloplasty in the setting of an ectopic or horseshoe kidney has been performed successfully. Trocar positioning can be different for abnormally located kidneys and should be individualized. The overall success rate in the only series presented by Bove et al. is 91% and is higher than those reported for either open repair (55–80%) or endoscopic management (78%) of ureteropelvic junction obstruction in such kidneys (52).

The results compare favorably to the outcome of transperitoneal laparoscopic pyeloplasty in otherwise normal kidneys, which associates with success rates greater than 90%. Risk factors for surgical failure are similar and include a history of multiple prior operations and poor preoperative renal function. The laparoscopic approach provides excellent surgical exposure of these kidneys and operative time similar to laparoscopic pyeloplasty in otherwise normal kidneys. Scant data on extraperitoneal laparoscopic pyeloplasty in a horseshoe kidney are available to date (53).

Laparoscopic pyeloplasty in the setting of an ectopic or horseshoe kidney has been performed successfully. Trocar positioning can be different for abnormally located kidneys and should be individualized. The overall success rate in the only series presented by Bove et al. is 91% and is higher than those reported for either open repair (55–80%) or endoscopic management (78%) of ureteropelvic junction obstruction in such kidneys.

MANAGEMENT OF FAILED PRIMARY LAPAROSCOPIC PYELOPLASTY

All primary ureteropelvic junction repairs can potentially fail, and in such a case a second operation is usually needed. Failure rate after laparoscopic pyeloplasty is approximately 5%. However, little is known about the best management after failure of laparoscopic pyeloplasty for primary ureteropelvic junction obstruction.

Endourologic Management of Failed Primary Laparoscopic Pyeloplasty:

- Comprises balloon dilatation, laser, cold knife, and cutting balloon endopyelotomy.
- Is used in the majority of patients who failed primary laparoscopic repair.
- Has an overall success of 77.7% after a follow-up period of 25.5 months.
- Is performed to treat short (<1 cm) recurrences amenable to incision or dilation performed at the same setting of the retrograde pyelography that confirmed the presence of recurrent obstruction.
- Requires short hospitalization.
- Has a low complication rate (crossing vessels, if existent, were already displaced during the primary laparoscopic procedure and therefore could not account for failures or postoperative bleeding).

SUMMARY

- Laparoscopic dismembered pyeloplasty was introduced in 1993.
- Both dismembered and nondismembered pyeloplasties (Foley Y-V, Fenger) may be performed using transperitoneal and retroperitoneal approaches.
- The transperitoneal approach has been used in most pyeloplasty series.
- Morbidity of transperitoneal laparoscopic pyeloplasty is considerably less than that of open pyeloplasty. Complications occur in approximately 11% to 20% of patients.
- Success rates in most recent series of transperitoneal laparoscopic pyeloplasty are above 90% and similar to those obtained with the open approach.
- Laparoscopic dismembered pyeloplasty is feasible and safe in children.
- The learning curve of robot-assisted laparoscopic pyeloplasty is steep.
- The ability of laparoscopic pyeloplasty to directly identify crossing vessels and reduce a large renal pelvis recapitulates the advantages of the open approach.
- Laparoscopic pyelolithotomy with concomitant pyeloplasty is feasible.
- Laparoscopic pyeloplasty in the setting of an ectopic or horseshoe kidney has been performed successfully.

REFERENCES

1. Notely RG, Beaugie JM. The long term follow-up of Anderson-Hynes pyeloplasty for hydronephrosis. *Br J Urol* 1973; 45:464.
2. Persky L, Krause JR, Boltuch RL. Initial complications and late results in dismembered pyeloplasty. *J Urol* 1977; 118:162.
3. Motola JA, Badlani GH, Smith AD. Results of 212 consecutive endopyelotomies: an eight-year follow up. *J Urol* 1993; 149:453.
4. Nakada SY, Johnson M. Ureteropelvic junction obstruction: retrograde endopyelotomy. *Urol Clin North Am* 2000; 27:677.
5. McClinton S, Steyn JH, Hussey JK. Retrograde balloon dilatation for pelviureteric junction obstruction. *Br J Urol* 1993; 71:152.
6. Lechevallier E, Eghazarian C, Ortega JC, Andre M, Gelsi E, Coulange C. Retrograde acucise endopyelotomy: long term results. *J Endourol* 1999; 13:575.
7. Schuessler WW, Grune MT, Tecuanhuey LV, Preminger GM. Laparoscopic dismembered pyeloplasty. *J Urol* 1993; 150:1795.
8. Kavoussi LR, Peters CA. Laparoscopic pyeloplasty. *J Urol* 1993; 150:1891.
9. Chen RN, Moore RG, Kavoussi LR. Laparoscopic pyeloplasty. Indications, technique, long term outcome. *Urol Clin North Am* 1998; 25:323.
10. Soulie M, Salomon L, Patard JJ, et al. Extraperitoneal laparoscopic pyeloplasty: a multicenter study of 55 procedures. *J Urol* 2001; 166:48.
11. Eden CG, Cahill D, Allen JD. Laparoscopic dismembered pyeloplasty: 50 consecutive cases. *BJU Int* 2001; 88:526.
12. Jarrett TW, Chan DY, Charambura TC, Fugita O, Kavoussi LR. Laparoscopic pyeloplasty. *J Urol* 2002; 167:1253.
13. Tan HL. Laparoscopic Anderson-Hynes dismembered pyeloplasty in children. *J Urol* 1999; 162:1045.
14. Yeung CK, Tam YH, Sihoe JDY, Lee KH, Liu KW. Retroperitoneoscopic dismembered pyeloplasty for pelviureteric junction obstruction in infants and children. *Br J Urol* 2001; 87:509.
15. Moore RG, Averch TD, Schulam PG, Adams JB, Chen RN, Kavoussi LR. Laparoscopic pyeloplasty: experience with the initial 30 cases. *J Urol* 1997; 157:459.
16. Janetschek G, Peschel R, Bartsch G. Laparoscopic Fenger plasty. *J Endourol* 2000; 14:889.
17. Marcovich R, Jacobson AI, Aldana JP, Lee BR, Smith AD. Practice trends in contemporary management of adult ureteropelvic junction obstruction. *Urology* 2003; 62:22.
18. Nakada SY, McDougall EM, Clayman RV. Laparoscopic pyeloplasty for secondary ureteropelvic junction obstruction: preliminary experience. *Urology* 1995; 46:257.
19. Sundaram CP, Grubb RL III, Rehman J, et al. Laparoscopic pyeloplasty for secondary ureteropelvic junction obstruction. *J Urol* 2003; 169:2037.
20. Ramakumar S, Lancini V, Chan DY, Parsons JK, Kavoussi LR, Jarrett TW. Laparoscopic pyeloplasty with concomitant pyelolithotomy. *J Urol* 2002; 167:1378.
21. Chen RN, Moore RG, Kavoussi LR. Laparoscopic pyeloplasty. *J Endourol* 1996; 10:156.
22. Bauer JJ, Bishoff JT, Moore RG, Chen RN, Iverson AJ, Kavoussi LR. Laparoscopic versus open pyeloplasty: assessment of objective and subjective outcome. *J Urol* 1999; 162:692.
23. Recker F, Subotic B, Goepel M, Tscholl R. Laparoscopic dismembered pyeloplasty: preliminary report. *J Urol* 1995; 153:1601.
24. Janetschek G, Peschel R, Altarac S, Bartsch G. Laparoscopic and retroperitoneoscopic repair of ureteropelvic junction obstruction. *Urology* 1996; 47:311.
25. Siqueira TM Jr, Nadu A, Kuo RL, Paterson RF, Lingeman JE, Shalhav AL. Laparoscopic treatment for ureteropelvic junction obstruction. *Urology* 2002; 60:973.
26. Turk IA, Davis JW, Winkelmann B, et al. Laparoscopic dismembered pyeloplasty—the method of choice in the presence of an enlarged renal pelvis and crossing vessels. *Eur Urol* 2002; 42:268.

27. Brooks JD, Kavoussi LR, Preminger GM, et al. Comparison of open and endourological approaches to the obstructed ureteropelvic junction. *Urology* 1995; 46:791.
28. Klingler HC, Remzi M, Janetschek G, Kratzik C, Marberger MJ. Comparison of open versus laparoscopic pyeloplasty techniques in treatment of uretero-pelvic junction obstruction. *Eur Urol* 2003; 44:340.
29. Pardalidis NP, Papatsoris AG, Kosmaoglou EV. Endoscopic and laparoscopic treatment of ureteropelvic junction obstruction. *J Urol* 2002; 168:1937.
30. Brooks JD, Kavoussi LR, Preminger GM, Schuessler WW, Moore RG. Comparison of open and endourologic approaches to the obstructed ureteropelvic junction. *Urology* 1995; 46:791.
31. Soulie M, Thoulouzan M, Seguin P, et al. Retroperitoneal laparoscopic versus open pyeloplasty with a minimal incision: comparison of two surgical approaches. *Urology* 2001; 57:443.
32. Puppo P, Perachino M, Ricciotti G, Bozzo W, Pezzica C. Retroperitoneoscopic treatment of ureteropelvic junction obstruction. *Eur Urol* 1997; 31:204.
33. Ben Slama MR, Salomon L, Hoznek A, et al. Extraperitoneal laparoscopic repair of ureteropelvic junction obstruction: initial experience in 15 cases. *Urology* 2000; 56:45.
34. Peters CA, Schluskel RN, Retik AB. Pediatric laparoscopic dismembered pyeloplasty. *J Urol* 1995; 153:1962.
35. El-Ghoneimi A, Farhat W, Bolduc S, et al. Laparoscopic dismembered pyeloplasty by a retroperitoneal approach in children. *BJU Int* 2003; 92:104.
36. Olsen LH, Jorgensen TM. Computer assisted pyeloplasty in children: the retroperitoneal approach. *J Urol* 2004; 171:2629.
37. Sung GT, Gill IS. Robotic laparoscopic surgery: a comparison of the da Vinci and Zeus systems. *Urology* 2001; 58:893.
38. Yohannes P, Rotariu P, Pinto P, Smith AD, Lee BR. Comparison of robotic versus laparoscopic skills: is there a difference in the learning curve? *Urology* 2002; 60:39.
39. Gettman MT, Neururer R, Bartsch G, Peschel R. Anderson-Hynes dismembered pyeloplasty performed using the da Vinci robotic system. *Urology* 2002; 60:509.
40. Gettman MT, Peschel R, Neururer R, Bartsch G. A comparison of laparoscopic pyeloplasty performed with the da Vinci robotic system versus standard laparoscopic techniques: initial clinical results. *Eur Urol* 2002; 42:453.
41. Gupta M, Tuncay OL, Smith AD. Open surgical exploration after failed endopyelotomy: a 12-year perspective. *J Urol* 1997; 157:1613.
42. Scardino PT, Scardino PL. Obstruction at the ureteropelvic junction. In: Bergman H, ed. *The Ureter*. 2nd ed. New York: Springer-Verlag, 1981:697.
43. Cassis AN, Brannen GE, Bush WH, Correa RJ, Chambers M. Endopyelotomy: review of results and complications. *J Urol* 1991; 146:1492.
44. Meretyk I, Meretyk S, Clayman RV. Endopyelotomy: comparison of ureteroscopic retrograde and antegrade percutaneous techniques. *J Urol* 1992; 148:775.
45. Gaur DD, Agarwal DK, Purohit KC, Darshane AS. Retroperitoneal laparoscopic pyelolithotomy. *J Urol* 1994; 151:927.
46. Micali S, Moore RG, Averch TD, Adams JB, Kavoussi LR. The role of laparoscopy in the treatment of renal and ureteral calculi. *J Urol* 1997; 157:463.
47. Segura JW, Kelalis PP, Burke EC. Horseshoe kidney in children. *J Urol* 1972; 108:333.
48. Gleason PE, Kelalis PP, Husmann DA, Kramer SA. Hydronephrosis in renal ectopia: incidence, etiology and significance. *J Urol* 1994; 151:1660.
49. Pitts WR Jr., Muecke EC. Horseshoe kidneys: a 40-year experience. *J Urol* 1975; 113:743.
50. Das S, Amar AD. Ureteropelvic junction obstruction with associated renal anomalies. *J Urol* 1984; 131:872.
51. Jabbour ME, Goldfischer ER, Stravodimos KG, Klima WJ, Smith AD. Endopyelotomy for horseshoe and ectopic kidneys. *J Urol* 1998; 160:694.
52. Bove P, Ong AM, Rha KH, Pinto P, Jarrett TW, Kavoussi LR. Laparoscopic management of ureteropelvic junction obstruction in patients with upper urinary tract anomalies. *J Urol* 2004; 171:77.
53. Hsu TH, Presti JC Jr. Anterior extraperitoneal approach to laparoscopic pyeloplasty in horseshoe kidney: a novel technique. *Urology* 2003; 62:1114.

COMMENTARY

Michael C. Ost and Arthur Smith

Department of Urology, North Shore-Long Island Jewish Medical Center, New Hyde Park, New York, U.S.A.

Minimally invasive therapies for the management of ureteropelvic junction obstruction currently challenge the standard open surgical approach to this entity with an ever-changing armamentarium of laparoscopic skill and technology. An endopyelotomy, laparoscopic pyeloplasty, or even a combination of the two techniques (1) may be employed with the confidence that outcomes will be highly successful and repairs will be durable. Presently we

most often choose between an endopyelotomy or laparoscopic pyeloplasty for definitive treatment of ureteropelvic junction obstruction rather than even consider an open approach primarily.

Laparoscopy, in particular, is playing an increasing role in ureteropelvic junction management and has proven to be a viable alternative for patients with ureteropelvic junction obstruction. As in the open technique, a tension-free mucosa-to-mucosa watertight anastomosis will dictate operative success. In turn, such success is contingent on proficiency with laparoscopic suturing, a skill that has become easier to acquire with the aid of robotics (2), hand-assisted laparoscopy (3), and newly described laparoscopic instrumentation and techniques (4,5).

In the last decade, approximately 16 series have reported on laparoscopic pyeloplasty for the treatment of primary ureteropelvic junction obstruction. Anderson-Hynes dismembered pyeloplasty, Y-V plasty, and Fengerplasty, which have all been described utilizing either a transperitoneal or retroperitoneal approach. Most impressive are the overwhelming success rates (>95%) in the large majority of these patients with operative times ranging from two to four hours. Few series, however, have compared data on the open versus laparoscopic approach at their respective institutions. Bauer et al. (6), for example, represent the minority to do so demonstrating comparable outcomes between open and laparoscopic groups with regard to relief of obstruction, relief of symptoms, and improved activity. Future efforts in follow-up studies must focus on defining "success rates" prospectively in a stratified and uniform manner. Outcomes, for example, in terms of pre and postoperative renal function (i.e., $T_{1/2}$ emptying time) and objective pain scales will give us the agency to truly compare minimally invasive techniques and determine which method is arguably most successful.

Comparisons between minimally invasive treatments for ureteropelvic junction obstruction have been made. In a multivariate analysis, Gill et al. (7) demonstrated that laparoscopic pyeloplasty was more successful (95.5%) than percutaneous endopyelotomy (86%), ureteroscopic endopyelotomy (85%), or electrocautery balloon endopyelotomy (76.7%). Why was laparoscopy superior? Were the preoperative parameters capable of foretelling such success? Massive hydronephrosis, poor renal function, stenotic segments greater than 1 cm, and a large renal pelvis draped over a renal vessel, for example, may be predictors of such success if a laparoscopic approach is used. It is important to note that it is still debatable as to whether or not "crossing vessel(s)" are truly significant in the etiology of ureteropelvic junction obstruction (8). Until the significance of this anatomic entity is better elucidated, treatment should not necessarily be dictated based on its presence.

Conversely, absence of the aforementioned anatomical variants suggests that there is more of an indication to utilize an endopyelotomy as the primary treatment modality. To this end, Pardalidis et al. (9) reported a success rate of 95% when patients were well selected for either endopyelotomy or laparoscopy based on such anatomical differences. Currently, this appears to be the general practice trend among academic endourologists in North America (10). It is evident that success in approaching a ureteropelvic junction obstruction may not necessarily rely on which minimally invasive technique is used but rather which procedure is utilized on an individual basis.

The pediatric population may be the most important group to focus on when analyzing the benefits of new technology for the treatment of ureteropelvic junction obstruction. Similar to adult cohorts, laparoscopic pyeloplasties in three pediatric series have demonstrated success rates from 87% to 100%. The dismembered pyeloplasty has been deemed the ultimate challenge in pediatric urological laparoscopy, as fine suturing with small instrumentation is required (11). Robotics may aid the pediatric urologist in this demanding operation, serving as a model for the adult urologist wishing to acquire better laparoscopic suturing skills. Future prospective and well-stratified studies in the pediatric population will especially give us a clearer view of the effect of laparoscopy on renal development and functionality over time. Results with pediatric endopyelotomy have yielded poor results that have been attributed to

the difficulties encountered with ureteral stenting. Further development in pediatric endopyelotomy is needed. There is no doubt, however, that laparoscopic approaches to ureteropelvic junction obstruction in the pediatric population will soon challenge the open technique as the standard of care.

A secondary ureteropelvic junction repair poses a challenge for the laparoscopist. Adhesions and fibrosis may limit exposure and prolong operative times. Despite this, minimally invasive salvage procedures yield a greater than 80% success rate. Salvage procedures for failed primary laparoscopic pyeloplasties are best served with an endopyelotomy. Conversely, failed primary endopyelotomies are best served with a laparoscopic pyeloplasty.

Laparoscopic pyeloplasty with concomitant pyelolithotomy has also emerged as a primary mode of treatment for instances of nephrolithiasis with a ureteropelvic junction obstruction. Although series reporting on this approach are few and demonstrate prolonged operative times, the feasibility of this technique has been demonstrated. It is our practice to evaluate the extent of edema at the ureteropelvic junction if repair is anticipated at the time of percutaneous nephrolithotomy. If there is no edema, endopyelotomy is performed. Conversely, the presence of edema calls for re-evaluation of the ureteropelvic junction with a functional study once all stones have been cleared and the edema has subsided. A ureteropelvic junction "obstruction" in the presence of nephrolithiasis may be a function of inflammation, precluding repair. Immediate laparoscopic pyeloplasty with concomitant pyelolithotomy may run the risk of unnecessary ureteropelvic junction "repair." Perhaps better technology fusing endoscopic technique during laparoscopy will further facilitate the employment of this procedure. Along the same line, laparoscopic pyeloplasties performed for ureteropelvic junction obstructions in the presence of upper tract anomalies in horseshoe kidneys or ectopic kidneys have yielded equivalent results to the open approach. Although comparable success rates have been reported, such anomalies may present technical challenges (i.e., anomalous blood supply) requiring cases to be individualized only in highly skilled hands.

A minimally invasive approach for the treatment of primary ureteropelvic junction obstruction has certainly emerged as perhaps a "new gold standard." Laparoscopic pyeloplasty, in particular, is more widely utilized and has proven to be efficacious. It is specifically geared toward cases in which known anatomical variables preclude the likelihood of endoscopic success. In the very near future, it will be exciting to see how accelerations in endoscopic and laparoscopic refinements, "raise the bar" even higher for what we will consider or demand as standard of care in both the adult and pediatric populations with ureteropelvic junction obstructions. Operator experience coupled with ultimate advancements in laparoscopic suturing techniques and instrumentation will certainly decrease operative times, further minimize morbidity, and assure that patients undergoing laparoscopic pyeloplasties will be in near perfect stead. On the horizon, urinary markers such as tumor growth factor (12) and nuclear factor-kappa B (13) hold great promise as predictive markers for what might translate into a ureteropelvic junction obstruction repair success or failure, further aiding in our minimally invasive treatment decisions.

REFERENCES

1. Gill IS, Desai MM, Kaouk JH, et al. Percutaneous endopyeloplasty: description of a new technique. *J Urol* 2002; 168:2097–2102.
2. Gettman MT, Ncururer R, Bartsch G, et al. Anderson-Hynes dismembered pyeloplasty performed using the da Vinci robotic system. *Urology* 2002; 60:509.
3. Hsech K, et al. Hand-assisted laparoscopic suturing: reconstruction. *J Endourol* 2004; 18(4):374.
4. Eichel L, Khonsari S, Lee DI, et al. One-knot pyeloplasty. *J Endourol* 2004; 18(3):201–204.
5. Chen RN, Moore RG, Kavoussi LR. Laparoscopic pyeloplasty—indications, technique, and long-term outcome. *Urol Clin North Am* 1998; 25(2):323–330.
6. Bauer JJ, Bishoff JT, Moore R, et al. Laparoscopic versus open pyeloplasty: assessment of objective and subjective outcomes. *J Urol* 1999; 162:692.
7. Gill IS, Kaouk J. Laparoscopic reconstructive urology. *J Urol* 2003; 170:1071.

8. Gupta M, Smith AD. Crossing vessels at the ureteropelvic junction: do they influence endopyelotomy outcome? *J Endourol* 1996; 10(2):183–187.
9. Pardalidis NP, Papatsoris AG, Kosmaoglou EV. Endoscopic and laparoscopic treatment of ureteropelvic junction obstruction. *J Urol* 2003; 168:1937–1940.
10. Marcovich R, Jacobson AL, Aldana JPA, et al. Practice trends in contemporary management of adult ureteropelvic junction obstruction. *Urology* 2003; 62:22–26.
11. Peters CA. Laparoscopy in pediatric urology. *Curr Opin Urol* 2004; 14(2):69.
12. Liatsikos EN, Dinlteno CZ, Bernardo NO, et al. Endopyelotomy failure is associated with reduced urinary transforming growth factor-beta 1 levels in patients with upper urinary tract obstruction. *J Endourol* 2001; 15(6):567–570.
13. Ruiz-Deya G, Sikka SC, Thomas R, et al. Potential role for the nuclear transcription factor NF-kappa B in the pathogenesis of ureteropelvic junction obstruction. *J Endourol* 2002; 16(8):61–65.

LAPAROSCOPY FOR THE CALYCEAL DIVERTICULUM: TECHNIQUE AND RESULTS

Christopher S. Ng

*Minimally Invasive Urology Institute, Cedars-Sinai Medical Center,
Los Angeles, California, U.S.A.*

- BACKGROUND
- INDICATIONS FOR UROLOGIC INTERVENTION
- IMAGING
- UROLOGIC TREATMENT MODALITIES
- PATIENT AND TREATMENT SELECTION
 - Transperitoneal vs. Retroperitoneal
 - Laparoscopic Access
- PREOPERATIVE PREPARATION
- TECHNIQUE: LAPAROSCOPIC CALYCEAL DIVERTICULECTOMY
 - Step 1: Cystoscopic Placement of Ureteral Catheter
 - CAVEAT
 - Step 2: Laparoscopic Access
 - CAVEAT
 - Step 3: Operative Exposure
 - CAVEATS
 - Step 4: Identification of Calyceal Diverticulum
 - CAVEAT
 - Step 5: Excision of Overlying Renal Parenchyma
 - CAVEAT
 - Step 6: Nephrolithotomy
 - CAVEAT
 - Step 7: Identification and Management of Calyceal Diverticular Infundibulum
 - CAVEAT
 - Step 8: Management of Calyceal Diverticular Epithelium
 - CAVEAT
 - Step 9: Obliteration of Diverticular Cavity
 - CAVEAT
 - Step 10: Drain Placement and Exit
 - Step 11: Ureteral Stent Placement
 - CAVEAT
 - POSTOPERATIVE MANAGEMENT
 - RESULTS
 - SUMMARY
 - REFERENCES

BACKGROUND

A calyceal diverticulum is an anomalous intrarenal cavity lined by nonsecretory transitional cell epithelium that communicates with the normal collecting system via a narrow diverticular neck.

A calyceal diverticulum is an anomalous intrarenal cavity lined by nonsecretory transitional cell epithelium that communicates with the normal collecting system via a narrow diverticular neck.

Although not directly associated with a draining renal papilla, calyceal diverticula fill passively with urine from the adjacent collecting system. Calyceal diverticula are usually less than 10 mm in size, and found incidentally during evaluation for other conditions. Incidence, from 2.1 to 4.5 per 1000 intravenous pyelograms, is similar in adults and children, which suggests an embryologic origin (1). It has been proposed that failure of degeneration of third- and fourth-order divisions of the developing ureteral bud results in a blind-ending outpouching of the collecting system. Others have implicated childhood vesicoureteral reflux, intrarenal rupture of a cyst or abscess, and fibrosing infundibular stenosis (2,3).

Types of Calyceal Diverticula Based on Their Location:

- Type I: diverticula communicate with minor calyces in the upper and lower polar regions
- Type II: diverticula communicate with the renal pelvis or major calyces and are located in the interpolar region.

It is important to differentiate a calyceal diverticulum from a hydro calyx, which is a true calyx with its own renal papilla that has become severely dilated due to congenital or acquired infundibular obstruction.

Currently, this classification remains purely descriptive and bears no implication regarding patient selection for urologic intervention. It is important to differentiate a calyceal diverticulum from a hydrocalyx, which is a true calyx with its own renal papilla that has become severely dilated due to congenital or acquired infundibular obstruction (4). The appearance of the calyceal distribution and configuration on intravenous pyelograms may be helpful in this regard.

The diagnosis of a calyceal diverticulum in itself is not an indication for surgery, because most lesions are found incidentally. However, urologic intervention is warranted if a patient becomes symptomatic as a result of the calyceal diverticulum.

Because it is lined with urothelium, a calyceal diverticulum may potentially harbor urothelial carcinoma, although this is exceedingly rare.

Computed tomography scan enables precise localization of the lesion as well as demonstrates its relation to surrounding structures. Most importantly, it allows for characterization of the renal parenchyma overlying the calyceal diverticulum, which is paramount in selecting patients for a laparoscopic approach.

Each minimally invasive modality has its own inherent technical limitations, such that “definitive management” of the congenital anomaly itself in the traditional sense, namely complete obliteration of the lesion, may not be possible for certain approaches. Therefore, it is apparent from the reported literature that proper patient selection is paramount to successful outcomes.

INDICATIONS FOR UROLOGIC INTERVENTION

The diagnosis of a calyceal diverticulum in itself is not an indication for surgery, because most lesions are found incidentally. However, urologic intervention is warranted if a patient becomes symptomatic as a result of the calyceal diverticulum.

Passive filling and poor drainage of urine from the diverticulum lead to focal urinary stasis, which may result in urinary tract infection and calculus formation, and therefore intermittent or persistent flank pain and gross hematuria. Recurrent infections or hematuria should be localized to the side of the lesion, prior to definitive intervention. Rarely, large calyceal diverticula may cause ischemic or obstructive renal damage, and nephrectomy may be required (2).

Because it is lined with urothelium, a calyceal diverticulum may potentially harbor urothelial carcinoma, although this is exceedingly rare (5,6).

IMAGING

Most calyceal diverticula are found by the intravenous pyelograms. With the aid of tomograms and oblique films, intravenous pyelograms can demonstrate the anterior–posterior orientation of the diverticulum; however, it may not clearly demonstrate the communicating neck or the renal parenchyma. Cystoscopy with ureteral catheterization and retrograde pyelography may be necessary not only to localize symptoms but also to better identify the width, length, and location of the diverticular neck. This is particularly useful when an endourologic approach is considered.

Computed tomography scan enables precise localization of the lesion as well as demonstrates its relation to surrounding structures. Most importantly, it allows for characterization of the renal parenchyma overlying the calyceal diverticulum, which is paramount in selecting patients for a laparoscopic approach.

Recently, a novel computed tomography protocol has been described in which noncontrast computed tomography is performed prone during inspiratory and expiratory phases (7). Three-dimensionally rendered images clearly demonstrate the anatomic relationship between the diverticulum, the parietal pleura, and retroperitoneal organs, and may identify patients in whom a percutaneous approach may not be safe or feasible, warranting a laparoscopic approach.

UROLOGIC TREATMENT MODALITIES

Prior to the advent of endourologic and laparoscopic techniques, the mainstays of surgical management for symptomatic calyceal diverticula with or without stones included open calyceal diverticulectomy or open partial nephrectomy. Calyceal diverticulectomy involved unroofing the thinned area of overlying renal parenchyma, removal of stones, figure-of-eight suture closure of the communicating neck when possible, fulguration of the diverticular surface, marsupialization of the cut diverticular edge, and obliteration of the cavity with perinephric fat. Partial nephrectomy was reserved for deeper lesions that were not amenable to diverticulectomy.

Over the last two decades, increasing experience with minimally invasive techniques has significantly changed the management of symptomatic stone-bearing calyceal diverticula. Nearly all contemporary, minimally invasive approaches have been applied to calyceal diverticula, including extracorporeal shock-wave lithotripsy, retrograde intrarenal surgery, percutaneous endoscopy, and laparoscopy.

Each minimally invasive modality has its own inherent technical limitations, such that “definitive management” of the congenital anomaly itself in the traditional sense, namely complete obliteration of the lesion, may not be possible for certain approaches. Therefore, it is apparent from the reported literature that proper patient selection is paramount to successful outcomes.

Shock-wave lithotripsy has been applied to stone-bearing calyceal diverticula with the primary goal of symptomatic relief of pain, with the understanding that the underlying anomaly remains unchanged. It has been shown that patients with a stone burden of less than 15 mm and a patent diverticular neck on X-ray can achieve symptomatic relief (86%) and stone-free status (58%) with shock-wave lithotripsy alone (8). However, recurrent symptoms and stone formation requiring secondary interventions may be more the rule (9).

The retrograde intrarenal approach allows for balloon dilation or laser incision of the narrow diverticular neck with intracorporeal lithotripsy and stone extraction in the same setting. Generally, no attempt is made to fulgurate the diverticular epithelium. This approach is technically feasible in 70% to 95% of cases, with the majority of failures due to a

Percutaneous management of calyceal diverticula is the most widely used endourologic modality, providing definitive obliteration of the congenital anomaly.

Successful diverticular eradication via the percutaneous approach appears to be related to the ability to obtain direct diverticular access, performing incision of the infundibular neck, fulguration of the epithelial lining, and placement of a nephrostomy tube. With this in mind, performing a “neoinfundibulotomy” when the true diverticular neck cannot be identified may provide improved outcomes.

lower pole location. When complete stone fragmentation is achieved, with or without the aid of concurrent shock-wave lithotripsy, symptom-free and stone-free rates are more than 90% (10,11). This technique may provide improved drainage of the diverticulum; however, the adynamic cavity remains in situ as a potential source for recurrent symptoms and stones.

Percutaneous management of calyceal diverticula is the most widely used endourologic modality, providing definitive obliteration of the congenital anomaly. This technique involves accessing the diverticulum via a percutaneous tract, which can be dilated up to 30 French. Percutaneous nephrolithotomy is performed in standard fashion. The draining infundibulum, if identified, can be fulgurated, incised, or dilated with a balloon and traversed by a nephrostomy tube. Symptom-free, stone-free, and “diverticular-free” success rates of 75% to 100% have been reported (9,12–14).

Successful diverticular eradication via the percutaneous approach appears to be related to the ability to obtain direct diverticular access, performing incision of the infundibular neck, fulguration of the epithelial lining, and placement of a nephrostomy tube (12,15). With this in mind, performing a “neoinfundibulotomy” when the true diverticular neck cannot be identified may provide improved outcomes (16,17).

This technique involves creating a new direct tract from the diverticulum into the renal pelvis, which can then be dilated for placement of a nephrostomy tube. The angle of approach for the percutaneous access still remains critically important to successful outcomes. As such, a percutaneous approach may not be ideally suited for some anterior or medial diverticula.

Laparoscopic Management of Calyceal Diverticula

- It is the most invasive of the closed surgical approaches.
- Nevertheless, like the percutaneous approach, it definitively removes the underlying congenital anomaly.
- Unlike the other minimally invasive modalities, it most closely recapitulates the standard open surgical principles, therefore providing the best chance of long-term success.
- It includes laparoscopic calyceal diverticulectomy and laparoscopic partial nephrectomy, both of which duplicate all open surgical steps.
- It allows for complete renal exploration and subsequent simple nephrectomy, in cases where the diverticulum causes irreversible renal functional loss.

PATIENT AND TREATMENT SELECTION

Due to inherent limitations of various minimally invasive modalities of treatment for symptomatic calyceal diverticula, proper patient and treatment selection are crucial to successful outcomes. Miller et al. proposed a detailed patient-selection algorithm for retrograde intrarenal, percutaneous, and laparoscopic approaches derived from a purely technical standpoint (Fig. 1) (18). Several key factors determine the ultimate urologic intervention, including degree of overlying renal parenchyma, diverticular size and location, and presence of retrograde access.

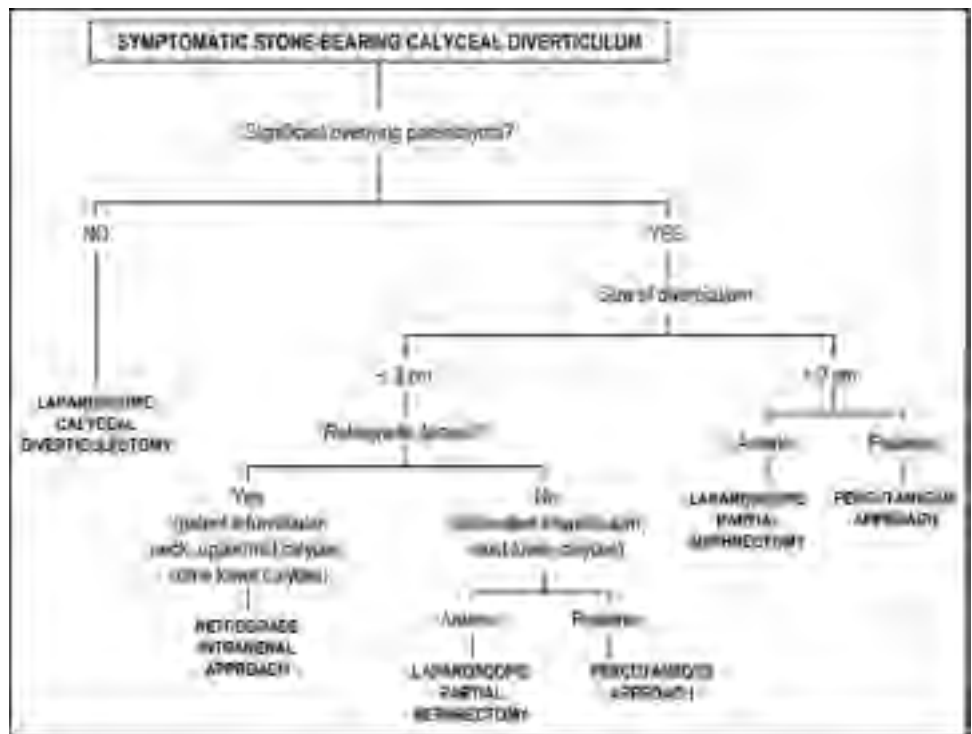
- Any lesion with thinned overlying renal parenchyma is amenable to laparoscopic calyceal diverticulectomy.
- Conversely, those lesions with thicker overlying parenchyma that are not endoscopically accessible may require formal laparoscopic partial nephrectomy.
- Lastly, repeated endoscopic treatment failures may be best managed with a definitive laparoscopic approach.

In the era of minimally invasive surgery, one must emphasize the role of well-informed patient preference in selecting treatment modalities—patients often opt for the least invasive or least morbid procedure, while accepting the fact that a secondary procedure may be necessary. For example, when the indication for intervention is recurrent infections, hematuria, or pain without stones, definitive management of the congenital anomaly is desired, and therefore a percutaneous or laparoscopic approach is preferable. However, if technically feasible, an initial attempt with an outpatient retrograde intrarenal balloon dilation or laser incision of the diverticular neck may provide temporary or even long-standing symptomatic relief, and may be preferred in the setting of a functionally solitary kidney.

Transperitoneal vs. Retroperitoneal Laparoscopic Access

When considering laparoscopic calyceal diverticulectomy, the selection of the method of laparoscopic renal access, whether transperitoneal or retroperitoneal, depends on

FIGURE 1 ■ Patient-selection algorithm for symptomatic stone-bearing calyceal diverticula.



several factors including size and location of the diverticulum, likelihood of requiring a partial nephrectomy, and patient-related factors (prior surgery and body habitus).

- Most lesions with thin overlying parenchyma are amenable to laparoscopic calyceal diverticulectomy.
- Larger lesions (greater than 2 cm) can be adequately accessed from either the transperitoneal or retroperitoneal approaches. In these cases, the risk of bleeding is low because there is minimal renal tissue excised.

When there is significant renal parenchyma overlying the diverticulum, a formal laparoscopic partial nephrectomy offers the best chance for definitive management of the calyceal diverticulum, as well as for a watertight and hemostatic end result.

Furthermore, with complete renal mobilization, adequate suturing angles to the diverticular infundibulum can be created from either approach. However, for smaller lesions, the angle toward the diverticular infundibulum becomes more restricted, and therefore anterior lesions should be approached transperitoneally, whereas posterior lesions should be approached retroperitoneoscopically.

When there is significant renal parenchyma overlying the diverticulum, a formal laparoscopic partial nephrectomy offers the best chance for definitive management of the calyceal diverticulum, as well as for a watertight and hemostatic end result.

The technique of laparoscopic partial nephrectomy in this setting is identical to that for renal masses. Several caveats regarding selection of method of laparoscopic access have arisen from a large comparative study between transperitoneal and retroperitoneal laparoscopic partial nephrectomy at the Cleveland Clinic (19). A transperitoneal approach to laparoscopic partial nephrectomy provides increased working space and improved suturing angles for renal reconstruction, and should be the approach of choice for substantive or deep resections, and for all anterior, lateral, or apical lesions. The retroperitoneal approach to laparoscopic partial nephrectomy should be reserved for smaller, more superficial lesions that are directly posterior or posteromedial. This is a rare situation in the setting of calyceal diverticula, because the majority of such lesions can be managed successfully with a percutaneous approach.

Patients undergoing laparoscopic management of symptomatic calyceal diverticulum should receive the same preoperative regimen as any laparoscopic renal surgery patient.

PREOPERATIVE PREPARATION

Patients undergoing laparoscopic management of symptomatic calyceal diverticulum should receive the same preoperative regimen as any laparoscopic renal surgery patient. Bowel preparation consists of a clear liquid diet and one to two bottles of magnesium citrate the day before surgery. In addition, culture-specific antibiotics should be started

at least 48 hours prior to surgery. This may require outpatient intravenous dosing or admission to the hospital. In the absence of documented urinary tract infection, a prophylactic intravenous dose of cefazolin is given one hour prior to surgery. All candidates for laparoscopic management of symptomatic calyceal diverticulum should have undergone computed tomography scan to delineate the three-dimensional location and the overlying renal parenchyma of the lesion.

TECHNIQUE: LAPAROSCOPIC CALYCEAL DIVERTICULECTOMY

Step 1: Cystoscopic Placement of Ureteral Catheter

An open-ended ureteral catheter is advanced into the ipsilateral renal pelvis so that diluted methylene blue can be later administered to assist in the identification of the calyceal diverticulum itself (Step 4) and identification of the infundibular connection to the normal collecting system (Step 7).

The patient is placed in the dorsal lithotomy position. Under cystoscopic guidance, a 0.035-inch. or 0.038-inch. guidewire is passed into the ipsilateral renal pelvis, followed coaxially by a 6 French open-ended ureteral catheter. The wire is removed, and the ureteral catheter is secured with 2–0 silk ties to a Foley urethral catheter. A luer-lock adapter is used to connect the ureteral catheter to extension tubing (such as intravenous catheter line tubing), whose end is capped. The cystoscopy table and wires are maintained for placement of a double-pigtail ureteral stent at the end of the procedure (Step 11).

CAVEAT

- The utility of the setup for retrograde injection of methylene blue is enhanced if the surgical team has access to the syringe rather than having the circulating staff inject from “under the drapes.”

Therefore, on the sterile field, one ampule of methylene blue is diluted in 300 to 400 cc of sterile water or glycine—saline is avoided if one anticipates the use of monopolar electrocautery for fulguration of the diverticular epithelium (Step 8). A 60-cc syringe with the prepared methylene blue is filled and connected to additional sterile extension tubing to be kept on the field. Once the patient has been repositioned, prepped, and draped for laparoscopy, the two free ends of tubing off the field are connected by the circulating staff.

Step 2: Laparoscopic Access

For the “transperitoneal approach,” the patient is repositioned into 60-degree flank, with the iliac crest just below the break of the operating table. The patient is supported with a back roll and axillary rolls, and all pressure points are adequately padded. The table is slightly flexed to expand the working space. The patient is secured on to the table with a 3-inch. cloth tape across the greater trochanter of the ipsilateral femur and across the upper chest at the nipple line. Veress needle access is obtained along the parasagittal plane at the midpoint between the umbilicus and the anterior superior iliac spine, at or just above the level of the umbilicus. A 12-mm trocar is placed at this location. Under laparoscopic visualization, a 5-mm trocar is placed along the same parasagittal line, just under the costal margin. Lastly, a second 12-mm trocar is placed between the working ports in the midline or along the ipsilateral pararectal line. On the right side, an additional 5-mm trocar may be necessary to retract the liver.

CAVEAT

- In select cases with thin overlying parenchyma and known milk of calcium or small stone burden, only 5-mm trocars may be utilized if a 5-mm laparoscope is available.

For the “retroperitoneal approach,” the patient is placed in the 90° flank position, with the iliac crest just below the break of the operating table. The patient is supported with

an axillary roll, and all pressure points adequately padded. The table is maximally flexed to expand the retroperitoneal working space. The patient is secured to the table with a 3-inch. cloth tape across the greater trochanter of the ipsilateral femur and across the upper chest at the nipple line. Landmarks include the tips of the 11th and 12th ribs, iliac crest, and the angle between the body of the 12th rib and the paraspinal musculature. A 15-mm incision is made along the mid-axillary line between the tips of the 11th and 12th ribs and carried through the lumbodorsal fascia. The plane between Gerota's fascia and the psoas fascia is created bluntly with index finger dissection. The retroperitoneal space is created with balloon dilation of 800 cc. A cuffed balloon port is placed at this entry site. Under laparoscopic visualization, a 12-mm trocar is placed anteriorly. Additional blunt mobilization of the peritoneum medially using the tip of the laparoscope may be necessary in order for this trocar to be placed extraperitoneally. Lastly, a 5-mm trocar is placed at the posterior angle.

Step 3: Operative Exposure

For the transperitoneal approach, the ipsilateral colon is reflected medially to expose Gerota's fascia. The remainder of the procedure is identical for the transperitoneal and retroperitoneal approaches. Gerota's fascia is entered to expose the cortical surface of the kidney in the suspected area of the diverticulum. Limited exposure over the diverticulum is sufficient if there is a direct angle of approach. However, when suboptimal angles exist, completely mobilize and rotate the kidney.

CAVEATS

- Whenever possible, an adequate vascularized flap of perinephric fat for subsequent obliteration of the diverticular cavity should be maintained (Step 9).
- If a more substantial excision of renal parenchyma is needed or partial nephrectomy anticipated, vascular clamping of the renal hilum may be necessary.

When utilizing a laparoscopic Satinsky-type instrument, en bloc hilar clamping may be performed. This requires mobilization of the periureteral package off the psoas fascia, continuing the dissection up to the caudal border of the hilum. On the left side, care must be taken to identify and preserve lower pole renal vessels and lumbar veins. The anterior and posterior aspects of the renal hilum must be freed completely. Lastly, a window above the hilum between the adrenal gland and upper medial aspect of the kidney is created. An additional trocar is placed in the ipsilateral lower quadrant for entry of the vascular clamp. Alternatively, selective arterial clamping using either Bulldog-type or Satinsky-type clamps requires complete exposure of the main artery and all accessory arteries.

Step 4: Identification of Calyceal Diverticulum

Large diverticula are readily identifiable as a cystic mass. However, smaller diverticula may only appear as a dimpled scar along an otherwise normal-appearing cortical surface.

CAVEAT

- Retrograde injection of methylene blue via the ureteral catheter may demonstrate bluish discoloration of the diverticulum.

The laparoscopic cyst-aspiration needle can be useful to probe the suspected area of the diverticulum. Intraoperative laparoscopic ultrasound allows for precise three-dimensional localization of the diverticulum (Fig. 2). If this is not available, fluoroscopy via C-arm device may be necessary, albeit cumbersome, because the kidney is positioned at the break or post of the operating table. Cross-table lateral and oblique views will be necessary. In the absence of a radiopaque calculus, retrograde injection of diluted contrast material may be necessary as well.

Step 5: Excision of Overlying Renal Parenchyma

With the location of the diverticulum precisely demarcated, the nephrotomy incision is begun at the thinnest portion of the diverticulum, typically at the tip of the exophytic

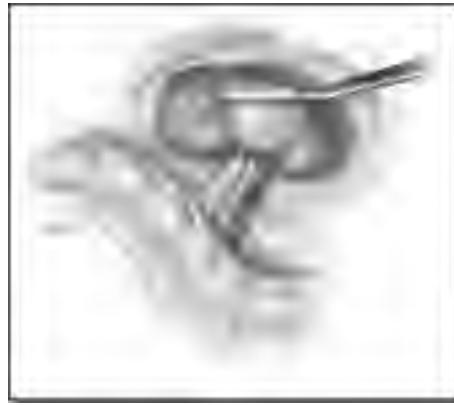

FIGURE 2 ■ Transperitoneal laparoscopic view of the left kidney with large anteromedial calyceal diverticulum. Intraoperative laparoscopic ultrasound is useful in localizing the diverticulum.



FIGURE 3 ■ Wide excision of the thinned parenchyma overlying the large stone-bearing calyceal diverticulum.

dome. The overlying renal parenchymal tissue is circumferentially excised to expose the base of the diverticulum using monopolar electrocautery hook electrode or scissors, or harmonic/ultrasonic scalpel or shears (Fig. 3).

CAVEAT

- Hemostatic adjuncts should always be readily available, because more substantive renal parenchymal excision may be required.

Applying pressure with oxidized cellulose (Surgicel^{TMa}), or collagen–thrombin matrix products (FloSeal^{TMb}), provides excellent hemostasis for mild parenchymal bleeding. Argon beam coagulation may also be sufficient for mild oozing (the intra-abdominal argon gas rapidly generated when activating the argon beam has to be simultaneously released). For brisk bleeding, simple parenchymal figure-of-eight or horizontal mattress sutures of 2–0 or No.0 polyglactin on a computed tomography-2 or computed tomography-1 needle may be necessary. Lastly, if a wedge-type excision of the lesion is necessary, formal parenchymal sutures of No.0 polyglactin on a computed tomography-1 needle over Surgicel bolsters may be required for hemostasis. Hilar clamping may be required to control major bleeding, in preparation for formal laparoscopic partial nephrectomy.

Step 6: Nephrolithotomy

Once the diverticulum is unroofed and hemostasis is obtained, the stone burden can be readily removed. Milk of calcium can simply be aspirated using the suction irrigator. Multiple small stones may be individually removed through the trocar or initially placed in a specimen retrieval bag (Fig. 4).

CAVEAT

- For stones larger than the port site, mechanical lithotripsy with a heavy grasper can be performed intracorporeally inside the specimen retrieval bag. Alternatively, the stone can be removed in toto at the end of the procedure by extending one port site.

Step 7: Identification and Management of Calyceal Diverticular Infundibulum

With the stone burden removed, the base of the diverticulum has to be examined for the communicating infundibulum, and methylene blue injected through the retrograde

^aEthicon, Inc., Somerville, NJ.

^bBaxter Healthcare Corp., Fremont, CA.



FIGURE 4 ■ Removal of the diverticular stone burden with grasping forceps. The diverticular infundibulum may be readily identifiable.

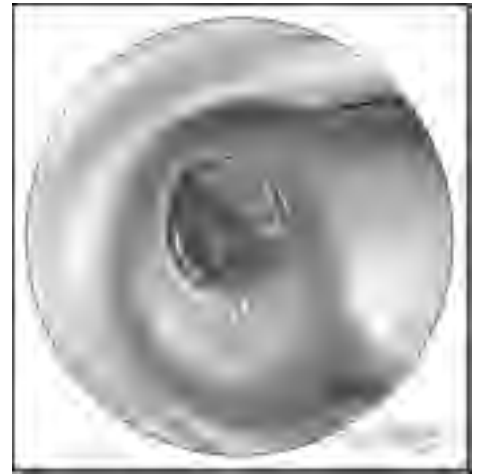


FIGURE 5 ■ Retrograde injection of diluted methylene blue solution through the ureteral catheter can assist in identifying the infundibular connection to the normal collecting system.

ureteral catheter (Fig. 5). One or two figure-of-eight sutures are placed across the infundibulum using 2-0 or 3-0 polyglactin on an RB-1 or computed tomography-2 needle (Fig. 6). Repeat retrograde injections of methylene blue are performed to recheck the integrity of the closure. Additional sutures may be added as needed.

If the connection to the main collecting system is not identified, or if suture placement is not feasible, the base can be carefully fulgurated with monopolar electrocautery or argon beam coagulation.

CAVEAT

- Tiny persistent communications with the collecting system may be effectively closed by using commercially available tissue sealant products (Step 9).

Discussion: Is Suture Repair Necessary?

Of 14 reported cases, only two utilized suture ligation of the infundibular neck, albeit successful in both (18). Of the other 12 cases in which the communication was fulgurated, only one had a prolonged self-limited fluid leak from the primary retroperitoneal port site (20).

Is suture repair necessary? Perhaps the question should be “why not?”. Intracorporeal suturing is becoming part of the basic laparoscopic skill set. In the interest of adhering to open surgical principles, suture closure of the infundibular connection should be performed whenever possible.

Step 8: Management of Calyceal Diverticular Epithelium

The remainder of the calyceal diverticular epithelium should be carefully fulgurated with monopolar electrocautery or argon beam. If sutures were placed, fulguration near or on the sutured area should be avoided (Fig. 7).

Is suture repair necessary? Perhaps the question should be “why not?”. Intracorporeal suturing is becoming part of the basic laparoscopic skill set. In the interest of adhering to open surgical principles, suture closure of the infundibular connection should be performed whenever possible.

CAVEAT

- Beware of thin areas of the diverticular wall adjacent to the normal collecting system. This may appear as a cystic bulge or translucent membrane. Aggressive fulguration in this area may lead to urine leak and urinoma formation. Argon beam coagulation may be superior to monopolar electrocautery in this regard. Repeat retrograde instillation of methylene blue to identify any leak that may need suture closure.

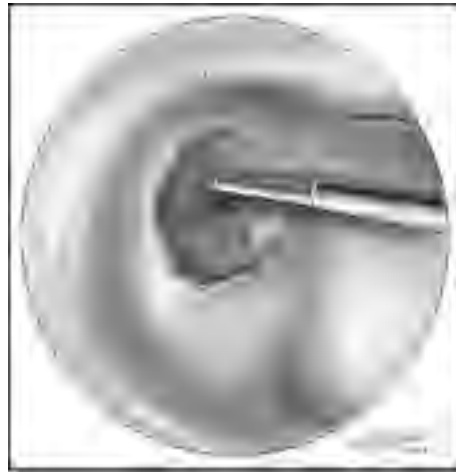

FIGURE 6 ■ Suture repair of the diverticular infundibulum with a figure-of-eight stitch using 2-0 or 3-0 polyglactin on a computed tomography or 2 RB-1 needle. Repeat retrograde injection of methylene blue may check the integrity of the closure.

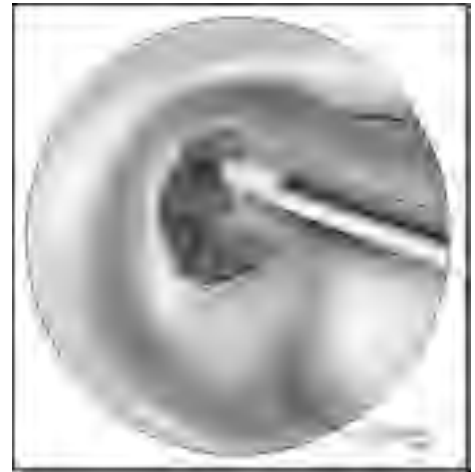

FIGURE 7 ■ Fulguration of the diverticular epithelium with argon beam coagulation. Avoid fulguration in the area of the suture line.

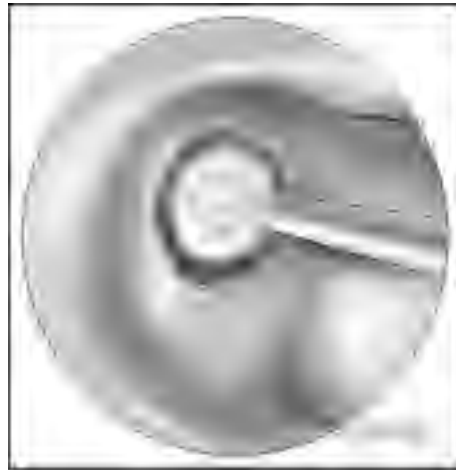

FIGURE 8 ■ Commercially available tissue sealant products or fibrin glue may be used to reinforce the suture repair and is particularly useful when sutures cannot be placed.

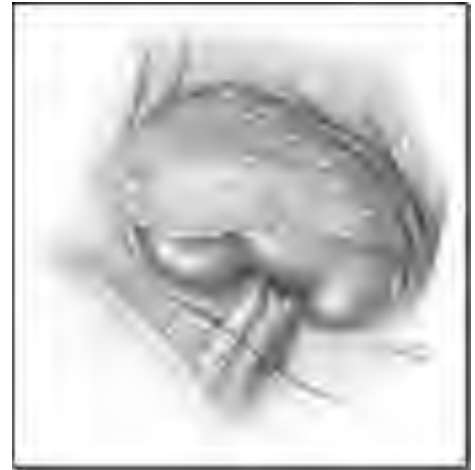

FIGURE 9 ■ The remainder of the diverticular cavity should be completely obliterated with a surrounding pedicle of fat from the perinephric tissue or omentum.

TABLE 1 ■ Operative Steps for Laparoscopic Calyceal Diverticulectomy for Symptomatic Calyceal Diverticula With or Without Stones

Step 1	Cystoscopic placement of ureteral catheter
Step 2	Laparoscopic access
Step 3	Operative exposure
Step 4	Identification of calyceal diverticulum
Step 5	Excision of overlying renal parenchyma
Step 6	Nephrolithotomy
Step 7	Identification and management of calyceal diverticular infundibulum
Step 8	Management of calyceal diverticular epithelium
Step 9	Obliteration of diverticular cavity
Step 10	Drain placement and exit
Step 11	Ureteral stent placement

Step 9: Obliteration of Diverticular Cavity

Cover the base of the diverticular cavity with any commercially available tissue sealant products such as TisseelTM or CoSealTM or other form of fibrin glue (Fig. 8). Hoznek et al. utilized gelatin resorcinol formaldehyde glue on a piece of surgical mesh to provide adjunctive hemostasis and sealing as well as obliteration of the cavity (21).

The remainder of the cavity should be filled with a fat pedicle (Fig. 9), such as perinephric fat or omentum (if transperitoneal), to eliminate any “dead space.” This may be pexed to the renal capsule with 3-0 polyglactin as needed.

CAVEAT

- Formal marsupialization of the cut cortical edge is generally not necessary to preclude recurrent diverticular formation as long as the cavity is adequately filled and obliterated.

^cBaxter Healthcare Corp., Fremont, CA.

TABLE 2 ■ List of Instruments, Materials, and Devices Utilized for Laparoscopic Calyceal Diverticulectomy

Operative Equipment Checklist	
Instrument	Standard laparoscopic renal instrument tray Laparoscopic cyst aspiration needle Laparoscopic needle drivers Laparoscopic vascular clamps Cystoscopy table, ureteral catheter, guidewire
Materials	Methylene blue ampule in 200 cc sterile water Radiopaque contrast material, diluted 50% Tissue sealants (fibrin glue, Tisseel™ ^a) Hemostatic agents (Surgicel™ ^a , Floseal™ ^b) 3-0 or 2-0 polyglactin, RB-1 or CT-2 needle #0 polyglactin, CT-1 needle
Devices	Intraoperative ultrasound probe C-arm fluoroscopy Argon beam coagulator

^aEthicon, Inc., Somerville, NJ.
^bBaxter Healthcare Corp., Fremont, CA.

Nevertheless, for the purpose of hemostasis, several interrupted figure-of-eight or horizontal mattress sutures of 3-0 or 2-0 polyglactin on a computed tomography-2 or computed tomography-1 needle may be placed. Alternatively, a running circumferential stitch may be placed.

Step 10: Drain Placement and Exit

Through the lateral most port site, a 19-French closed suction drain is placed and secured to the skin with 3-0 nylon suture. The working space is completely desufflated for several minutes and the operative field is reinspected under an intra-abdominal pressure of less than 10 mmHg. Hemostasis is obtained as needed. For the transperitoneal approach, any port sites of more than 8 mm is closed with No. 0 or No. 1 polyglactin ties using a fascial closure device, such as a Carter-Thomason system, under direct laparoscopic visualization.

If the specimen retrieval bag has not yet been extracted, the string of the cinch knot is brought through the anticipated exit site. All remaining trocars are removed under direct laparoscopic visualization. The extraction site is extended as needed for specimen removal, and closed with No. 0 polyglactin suture.

Step 11: Ureteral Stent Placement

The patient is repositioned in the dorsal lithotomy position, the guidewire placed into the renal pelvis through the ureteral catheter, and the ureteral catheter removed with the Foley urethral catheter. Under cystoscopic guidance, a double-pigtail indwelling ureteral stent is placed. Alternatively, the stent is placed using fluoroscopic guidance. The Foley catheter is replaced (Tables 1 and 2).

Discussion

Descriptions of the open operative technique do not routinely include ureteral stenting. In six of 14 reported cases, neither a ureteral stent nor a ureteral catheter was left in place—only one patient had prolonged but self-limited fluid leak; however, this was not specified as urine. Therefore, with the meticulous surgical technique described herein, including infundibular suturing, tissue sealant application, and obliteration of the cavity, it seems reasonable to omit routine postoperative ureteral J-stenting (Table 3).

CAVEAT

- Alternatively, the ureteral catheter and Foley catheter are left to gravity until the day of discharge. This provides an extended period of drainage without the need for a double-pigtail indwelling stent.

TABLE 3 ■ Specific Technical Alternatives Described in the Literature, Including Type of Laparoscopic Approach, Use of Ureteral Stenting, and Method of Management of the Diverticular Epithelium, Infundibular Neck, and Cavity

Series (patients)	Laparoscopic approach	Diverticular size (mm)	Epithelial fulguration	Infundibular management	Cavity filled?	Indwelling stent?
Gluckman et al. (21) (N = 1)	Transperitoneal	N/A	Argon beam	Argon beam	Omentum	No
Ruckle et al. (22) (N = 1)	Transperitoneal	30	Monopolar electrocautery	Monopolar electrocautery	No	No
Harewood et al. (19) (N = 3)	Retroperitoneal	12-31	Monopolar electrocautery	Not seen	No (N = 1) Fat tissue (N = 2)	No
Hoznek et al. (20) (N = 3)	Retroperitoneal	10-12	Monopolar electrocautery	Monopolar electrocautery	Tissue sealant on mesh ^a	Ureteral catheter ^b
Curran et al. (23) (N = 1)	Retroperitoneal	50	Monopolar electrocautery	Not seen	No	No
Miller et al. (18) (N = 5)	Retroperitoneal	20-45	Argon beam	Argon beam (N = 3) Suture repair (N = 2)	Perinephric fat	4-6 weeks

^aGelatin resorcinol formaldehyde glue on surgical mesh.
^bUreteral catheter for five to eight days with retrograde pyelogram confirming no leak prior to removal.
Abbreviation: N/A, not available.

POSTOPERATIVE MANAGEMENT

Follow-up intravenous pyelograms or computed tomography urogram is obtained at six weeks after stent removal, then at six months, 12 months, and as needed for symptoms. Subsequent yearly follow-up with ultrasound is sufficient.

Laparoscopic calyceal diverticulectomy replicates the techniques and principles of the open surgical approach. As such, symptom-free, stone-free, and “diverticulum-free” rates in reported series are 100%, 100%, and 93%, respectively, albeit with very short follow-up.

Standard postoperative care of the laparoscopic renal surgery patient should ensue. The Foley catheter should be kept in place until the day of discharge to maximize drainage. The closed-suction drain may be removed when output remains less than 60 cc per day. The ureteral stent, if placed, may be removed two weeks after drain removal.

Follow-up intravenous pyelograms or computed tomography urogram is obtained at six weeks after stent removal, then at six months, 12 months, and as needed for symptoms. Subsequent yearly follow-up with ultrasound is sufficient.

RESULTS

For open calyceal diverticulectomy, success is the rule (2). Laparoscopic calyceal diverticulectomy replicates the techniques and principles of the open surgical approach. As such, symptom-free, stone-free, and “diverticulum-free” rates in reported series are 100%, 100%, and 93%, respectively, albeit with very short follow-up (Table 4) (18–24).

In one patient, a residual diverticulum was noted on follow-up intravenous pyelograms, measuring only 10% of the original lesion (20). The authors noted that the diverticular cavity was fulgurated but not filled with fat tissue in this case; all subsequent cases involved obliterating the diverticulum with fat tissue, and no recurrences were noted.

Overall morbidity is low with laparoscopic calyceal diverticulectomy. Operative time is about three hours, and hospital stay is generally two to three days. Complications were minor, including subcutaneous emphysema, self-limited fluid leak, and a three-unit blood transfusion, occurring in one patient each (Table 4).

TABLE 4 ■ Reported Results After Laparoscopic Management of Symptomatic Calyceal Diverticuli, Including Complications, Stone-Free and Symptom-Free Rates, and the Rate of Persistence of the Diverticulum

Series (patients)	Operative time (min)	Hospital stay (days)	Follow-up exam (months)	Stone-free (%)	Symptom-free (%)	Persistent diverticulum (%)	Complications
Gluckman et al. (21) (N = 1)	<180	3	IVP (N/A)	100	100	0	Subcutaneous emphysema
Ruckle et al. (22) (N = 1)	N/A	3	IVP (2 mo)	100	100	0	None
Harewood et al. (19) (N = 3)	80–180	3–5	IVP (3–5 mo)	100	100	33 ^a	Blood transfusion (N = 1) Port site fluid leak (N = 1)
Hoznek et al. (20) (N = 3)	60–90	5–9	CT scan (6 mo)	100	100	0	None
Curran et al. (23) (N = 1)	215	2	CT scan (4 mo)	100	100	0	None
Miller et al. (18) (N = 5)	90–200	0–5	IVP (1.5 mo)	100	100	0	None

^aResidual diverticulum measuring 10% of original size, cavity not filled.
Abbreviations: N/A, not available; IVP, intravenous pyelogram; CT, computed tomography.

SUMMARY

- Laparoscopic calyceal diverticulectomy presented herein strictly adheres to open surgical principles.
- The procedure includes:
 - clear identification of the diverticular cavity,
 - wide unroofing of the diverticular dome,
 - suture closure of the infundibular neck,
 - fulguration of the diverticular epithelium, and
 - obliteration of the diverticular cavity.
- Patients with large diverticula with thin overlying renal parenchyma are ideal candidates for laparoscopic calyceal diverticulectomy.
- High success rates and low morbidity can be achieved with laparoscopic calyceal diverticulectomy.

REFERENCES

1. Timmons JW Jr., Malek RS, Hattery RR, Deweerd JH. Caliceal diverticulum. *J Urol* 1975; 114:6.
2. Wulfsohn MA. Pyelocaliceal diverticula. *J Urol* 1980; 123:1.
3. Amar AD. The clinical significance of renal caliceal diverticulum in children: relation to vesicoureteral reflux. *J Urol* 1975; 113:255.
4. Wolf JS Jr. Caliceal diverticulum and hydrocalyx. Laparoscopic management. *Urol Clin North Am* 2000; 27:655.
5. Roberts CC, Collins JM, Lidner TK, Larson TR. Transitional cell carcinoma obstructing a calyceal diverticulum: unusual presentation as a peripheral cystic mass. *J Ultrasound Med* 1999; 18:19.
6. Conrad M, Newton J, Harkins J. Growing caliceal diverticular defect. *Urol Radiol* 1987; 9:194.
7. Ng CS, Herts BR, Strem SB. Percutaneous access to upper pole renal stones: role of prone 3-dimensional computed tomography in inspiratory and expiratory phases. *J Urol* 2005; 173:124.
8. Strem SB, Yost A. Treatment of caliceal diverticular calculi with extracorporeal shock wave lithotripsy: patient selection and extended followup. *J Urol* 1992; 148:1043.
9. Jones JA, Lingeman JE, Steidle CP. The roles of extracorporeal shock wave lithotripsy and percutaneous nephrostolithotomy in the management of pyelocaliceal diverticula. *J Urol* 1991; 146:724.
10. Chong TW, Bui MH, Fuchs GJ. Calyceal diverticula. Ureteroscopic management. *Urol Clin North Am* 2000; 27:647.
11. Batter SJ, Dretler SP. Ureterorenoscopic approach to the symptomatic caliceal diverticulum. *J Urol* 1997; 158:709.
12. Shalhav AL, Soble JJ, Nakada SY, Wolf JS Jr., McClennan BL, Clayman RV. Long-term outcome of caliceal diverticula following percutaneous endosurgical management. *J Urol* 1998; 160:1635.
13. Bellman GC, Silverstein JL, Blickensderfer S, Smith AD. Technique and follow-up of percutaneous management of caliceal diverticula. *Urology* 1993; 42:21.
14. Ellis JH, Patterson SK, Sonda LP, Platt JF, Sheffner SE, Woolsey EJ. Stones and infection in renal caliceal diverticula: treatment with percutaneous procedures. *Am J Roentgenol* 1991; 156:995.
15. Schwartz BF, Stoller ML. Percutaneous management of caliceal diverticula. *Urol Clin North Am* 2000; 27:635.
16. Al-Basam S, Bennett JD, Layton ZA, Denstedt JD, Razvi H. Treatment of caliceal diverticular stones: transdiverticular percutaneous nephrolithotomy with creation of a neoinfundibulum. *J Vasc Interv Radiol* 2000; 11:885.
17. Auge BK, Munver R, Kourambas J, Newman GE, Wu NZ, Preminger GM. Neoinfundibulotomy for the management of symptomatic caliceal diverticula. *J Urol* 2002; 167:1616.
18. Miller SD, Ng CS, Strem SB, Gill IS. Laparoscopic management of caliceal diverticular calculi. *J Urol* 2002; 167:1248.
19. Ng CS, Gill IS, Ramani AP, Steinberg AP, Spaliviero M, Abreu SC, Kaouk JH, Desai MM. Transperitoneal versus retroperitoneal laparoscopic partial nephrectomy: patient selection and perioperative outcomes. *J Urol* 2005; 174:846.
20. Harewood LM, Agarwal D, Lindsay S, Vaughan MG, Cleeve LK, Webb DR. Extraperitoneal laparoscopic caliceal diverticulectomy. *J Endourol* 1996; 10:425.
21. Hoznek A, Herard A, Ogier N, Amsellem D, Chopin DK, Abbou CC. Symptomatic caliceal diverticula treated with extraperitoneal laparoscopic marsupialization fulguration and gelatin resorcinol formaldehyde glue obliteration. *J Urol* 1998; 160:352.
22. Gluckman GR, Stoller M, Irby P. Laparoscopic pyelocaliceal diverticula ablation. *J Endourol* 1993; 7:315.
23. Ruckle HC, Segura JW. Laparoscopic treatment of a stone-filled, caliceal diverticulum: a definitive, minimally invasive therapeutic option. *J Urol* 1994; 151:122.
24. Curran MJ, Little AF, Bouyounes B, Nieh PT, Bihle W III. Retroperitoneoscopic technique for treating symptomatic caliceal diverticula. *J Endourol* 1999; 13:723.

LAPAROSCOPIC LIVE DONOR NEPHRECTOMY: TECHNIQUE

Joseph J. Del Pizzo

Department of Urology, James Buchanan Brady Foundation, The New York Presbyterian Hospital–Weill Cornell Medical Center, New York, New York, U.S.A.

■ INTRODUCTION	Step 3: Dissection of the Ureter
■ PATIENT SELECTION	Step 4: Dissection of the Upper Pole of the Kidney
Initial Screening	Step 5: Release of Lateral and Posterior Attachments
Radiographic Evaluation	Step 6: Preparing the Allograft Extraction Site
■ PREOPERATIVE PREPARATION	Step 7: Transection of the Ureter
■ RIGHT-SIDED DONOR NEPHRECTOMY	Step 8: Placement of the Allograft in the Entrapment Sac
■ OPERATIVE PREPARATION	Step 9: Transection of the Renal Vessels
Patient Preparation	Step 10: Delivery of the Allograft
Patient Positioning	Step 11: Inspection of the Renal Bed/Closure
Operating Room Setup	Laparoscopic Right-Sided Live Donor Nephrectomy
Instrumentation and Medication	Hand-Assisted Laparoscopic Live Donor Nephrectomy
■ LAPAROSCOPIC DONOR NEPHRECTOMY:	Retroperitoneoscopic Live Donor Nephrectomy
BASIC INSTRUMENTATION	■ REFERENCES
■ OPERATIVE TECHNIQUE	■ SUMMARY
Laparoscopic Left-Sided Live Donor Nephrectomy	
Step 1: Reflecting the Descending Colon/Splenic Mobilization	
Step 2: Identification of the Renal Hilum	

INTRODUCTION

Renal transplantation is the ideal solution to end-stage renal disease. It has had a major impact on the survival and quality of life of those suffering from kidney failure, affording these patients an independent lifestyle free from dialysis and its significant morbidity. Unfortunately, the annual supply of renal allografts has continued to fall short of the increasing number of patients seeking renal transplantation.

Live donor nephrectomy has long been viewed as an underused alternative in renal replacement therapy. Live donor kidney transplantation offers substantially superior graft function and survival compared to cadaveric renal transplantation (1,2). Other advantages over cadaveric renal allografts include shorter time waiting for transplantation, the ability to schedule it as an elective procedure and therefore optimize the medical status of the recipient, and overall reduced immunosuppression requirements (3). The large discrepancy between the supply and demand for renal allografts, coupled with the advantages of live versus cadaveric renal transplantation, has prompted efforts to increase the pool of live renal donors.

Prior to 1995, the standard method of kidney procurement was open donor nephrectomy performed through a flank or subcostal incision. Although this procedure can be performed safely and produces an allograft of excellent quality with minimal warm ischemia, it is associated with considerable perioperative morbidity for the renal donor. Postoperative pain, prolonged hospitalization and convalescence, lost wages, and poor cosmesis have been identified as significant disincentives for organ donation (4). As a result, the number of live renal transplants that were performed accounted for only a small fraction of the total number of transplants performed.

The first series of laparoscopic live donor nephrectomies were performed in 1995, specifically intended to decrease the morbidity of renal donation for the healthy donor and thus reduce disincentives and expand the pool of live donor candidates (3,4). Since its inception, technical modifications that have come with surgeon experience have led to a substantial reduction in total donor complications, as well as a progressive decline in the rate of recipient complications including delayed graft function or loss, ureteral stricture and necrosis, and vascular thrombotic events (5–9).

Laparoscopic live donor nephrectomy is now the standard technique at many transplant centers, resulting in less postoperative pain and convalescence for the living donor while maintaining equivalent allograft function and recipient outcomes as compared with results from traditional open donor nephrectomy. Despite technical modifications, improved instrumentation, and increased surgeon experience, laparoscopic live donor nephrectomy remains a technically challenging operation with a steep learning curve.

Psychologic evaluation includes a complete evaluation of the donor's emotional stability and determination if an altruistic motivation for donation exists.

Radiologic imaging is a crucial component of the preoperative assessment of potential live renal donors. Precise preoperative mapping of the number and location of the main renal vessels, and the presence of accessory vessels is crucial for obtaining safe hilar dissection and minimizing vascular complications.

Computed tomography angiography is highly accurate and specific for the delineation of renal vascular anatomy in these patients, including detection of multiple renal vessels.

Laparoscopic live donor nephrectomy is now the standard technique at many transplant centers, resulting in less postoperative pain and convalescence for the living donor while maintaining equivalent allograft function and recipient outcomes as compared with results from traditional open donor nephrectomy (5,10–13). Despite technical modifications, improved instrumentation, and increased surgeon experience, laparoscopic live donor nephrectomy remains a technically challenging operation with a steep learning curve.

With no margin for error, it requires an advanced level of laparoscopic skill and meticulous technique, as well as a detailed knowledge of renal vascular anatomy. It must replicate the standards set by traditional open donor nephrectomy—optimize the safety of the donor and procure a healthy functioning allograft for transplantation.

PATIENT SELECTION

Initial Screening

All potential donor candidates must undergo an extensive medical and psychological evaluation in accordance with guidelines published by the American Society of Transplant Physicians (14–16).

Psychological evaluation includes a complete evaluation of the donor's emotional stability and determination if an altruistic motivation for donation exists.

A thorough laboratory evaluation is performed for histocompatibility testing and to ensure that the healthy donor will be left with normal renal function after nephrectomy. Standard blood testing includes ABO histocompatibility, HLA crossmatching, complete blood count, serum chemistries including liver function tests, and a coagulation profile.

The potential donor is also screened for viral exposure, including hepatitis profile and exposure to human immunodeficiency virus, cytomegalovirus, varicella, and Epstein–Barr virus. Urine testing includes urinalysis, urine culture, and a 24-hour urine collection analysis to evaluate urine protein levels and creatinine clearance. Female patients over age 40 must have a recent negative Papanicolaou cervical smear and negative screening mammogram.

Radiographic Evaluation

Radiologic imaging is a crucial component of the preoperative assessment of potential live renal donors. Precise preoperative mapping of the number and location of the main renal vessels, and the presence of accessory vessels is crucial for obtaining safe hilar dissection and minimizing vascular complications.

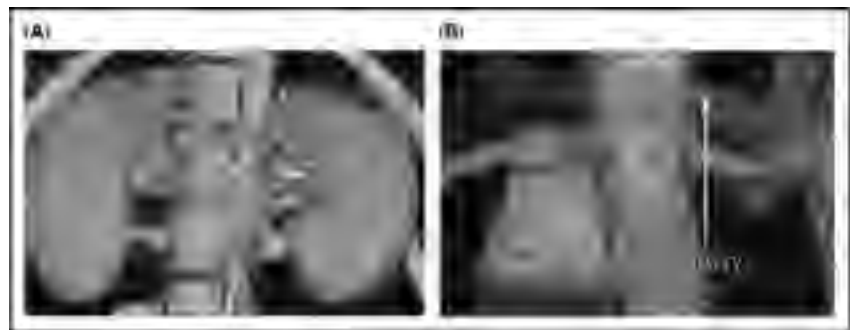
Assessment of the kidneys and renal vasculature will identify some unsuitable donors and dictate which renal unit should be chosen for transplantation in others.

The traditional role of excretory urography, intravenous pyelography, and renal arteriography in the evaluation of potential kidney donors has been challenged by helical computed tomography with three-dimensional arteriography. Helical computed tomography arteriography can be employed as a single imaging modality to evaluate the entire region of the kidney and obtain relatively noninvasive arteriogram-like images of the renal vasculature. In addition, these images can be reformatted to provide the surgeon with a three-dimensional display of the data and allow improved vascular imaging.

Computed tomography angiography is highly accurate and specific for the delineation of renal vascular anatomy in these patients, including detection of multiple renal vessels (Fig. 1) (17).

The presence of multiple vessels is not a contraindication to laparoscopic live donor nephrectomies, but preoperative identification will optimize patient safety and

FIGURE 1 ■ Helical computed tomography with three-dimensional arteriographic images demonstrating (A) left renal artery outlined cephalad to the left renal vein and (B) accessory renal artery (*arrow*) off the aorta and supplying the left upper renal pole.



possibly recipient outcome. The entire surgical transplant team should review the films together, because a clear picture of renal vascular anatomy is mandatory in helping to plan both the donor and recipient procedures.

PREOPERATIVE PREPARATION

The donor and recipient surgeon(s) decide which renal unit will be used for transplantation.

- When the kidneys are equal in size and function and have favorable vascular anatomies, the left kidney is selected to take surgical advantage of the longer left renal vein for recipient surgical implantation (4).
- Selection of the right kidney is based on traditional criteria independent of the laparoscopic approach.
- When deemed a good candidate for donation, the patient is left with the “better” kidney if a discrepancy exists.

RIGHT-SIDED DONOR NEPHRECTOMY

Absolute Indications

- Larger left kidney with presumed greater glomerular filtration rate
- The presence of cysts in the right kidney
- Mild fibromuscular dysplasia of only the right renal artery

Relative Indications

- Complex or aberrant left renal vasculature
- Duplicated left collecting system
- Ptosis of the right kidney

Additional considerations include the donor’s body mass index and prior abdominal surgical procedures. Laparoscopic donor nephrectomy has been performed safely in obese patients. Donor and recipient outcomes have been similar to those seen in nonobese donors (18). Therefore, obesity is not a contraindication for laparoscopic donor nephrectomy. Patients who have undergone extensive prior intra-abdominal surgery, especially in close proximity to the proposed operative field, are still considered candidates for renal donation but may benefit more from a retroperitoneal approach, either laparoscopic or open.

Informed consent should be obtained from the donor surgeon. All potential complications are discussed, with ample opportunity for the donor patient to ask and receive answers to questions. The potential for open conversion is discussed. It is made clear to the patient that the primary responsibility of the surgical team is to ensure patient safety and procure a healthy allograft suitable for transplantation. If either of these objectives is compromised during the laparoscopic approach, conversion to traditional open surgery may be necessary. The donor patient is also educated about living with a solitary kidney. Although there is no need for major dietary or other lifestyle modifications, these patients should avoid contact sports and have serum creatinine and blood pressure monitoring in the perioperative period and then yearly.

Patients are advised to maintain a clear liquid diet the day prior to surgery. No preoperative bowel preparation is necessary.

OPERATIVE PREPARATION

Patient Preparation

Surgery is performed with the donor under general endotracheal anesthesia. Sequential compression stockings are placed on the lower extremities. After induction of anesthesia, an oral gastric tube is placed to decompress the stomach, and a Foley catheter is placed to decompress the bladder. One dose of intravenous antibiotics is administered. The urine collection bag is placed near the anesthesiologist to closely monitor intraoperative urine output.

Pneumoperitoneum decreases renal blood flow; so vigorous intravenous hydration is necessary to maintain urine output (19). Patients should receive 1 to 2 L of intravenous fluid prior to insufflation of the abdomen, and typically receive 5 to 6 L of

Pneumoperitoneum decreases renal blood flow; so vigorous intravenous hydration is necessary to maintain urine output.

The anesthesiologist should be instructed to maintain a urine output of 100 cc/hr. This will keep the potential allograft well hydrated and keep the renal vein appearing full and make it easier to identify during the dissection.

The extraction incision site should be marked prior to positioning and rotating the patient to ensure symmetry and a good cosmetic result.

crystalloid during a routine procedure. The first dose of intravenous mannitol (12.5 g) is given after the second liter of fluid is infused.

The anesthesiologist should be instructed to maintain a urine output of 100 cc/hr. This will keep the potential allograft well hydrated and will keep the renal vein appearing full and make it easier to identify during the dissection.

Patient Positioning

Prior to patient positioning, a 5 to 6 cm Pfannenstiel incision is drawn with a marking pen two fingerbreadths above the symphysis pubis. This will serve as the extraction site. The extraction incision site should be marked prior to positioning and rotating the patient to ensure symmetry and a good cosmetic result.

The patient is placed in a modified flank position at a 45° angle with the operating table, with the ipsilateral flank facing upwards. Two 10 lbl. sandbags are placed behind the patient to maintain the modified flank position. The downside leg is flexed at the knee and separated from the extended upside leg with a pillow. All pressure points on the downside ankle, hip, and knee are well padded. The downside arm is padded and an axillary roll is carefully positioned. The upside arm is placed on a well-padded arm-board, or, alternatively, pillows may be used (Fig. 2). The upper extremities must be positioned such that there is no tension on the brachial plexus. Once the patient is adequately positioned, the table is gently flexed to extend the flank. The patient is secured to the operating table at the level of the shoulders and thighs with 3-inch cloth tape. A surgical blue towel or additional foam pads are placed over these areas to prevent skin irritation or compression injuries from the secured tape. Once the patient is secured to the operating table, the table can be rotated to facilitate exposure during the procedure.

Operating Room Setup

When performing either left or right transperitoneal laparoscopic live donor nephrectomies, both the operating surgeon and assistant stand on the abdominal side of the patient. The equipment table is positioned at the foot of the operating table, and the scrub nurse stands opposite the surgeon. This allows the scrub nurse to hand instruments directly to the operating surgeon. The main video monitor should be placed at eye level, near the head of the table, opposite the surgeon. The secondary monitor is placed in a similar position on the other side of the table, allowing the scrub nurse to also monitor the surgical procedure. A standard monopolar electrocautery unit and/or a harmonic scalpel generator are placed either in front of or behind the operating surgeon. A typical operating room configuration for a left laparoscopic donor nephrectomy is shown in Figure 3.


Some surgeons use the AESOP™^a robotic arm to control the laparoscope during laparoscopic live donor nephrectomies. In these cases, the robotic arm should be attached to the operating table on the surgeon side at the level of the patient's shoulders. Its position must be monitored throughout the procedure to ensure that no pressure is being placed on the patient's hands, arms, or shoulder as the robotic arm is maneuvered.

FIGURE 2 ■ Patient positioning for left-sided laparoscopic live donor nephrectomy. Patient is secured to the operating table and all pressure points are well padded. Extraction site is marked prior to positioning.



^aComputer Motion, Inc., Goleta, CA.

FIGURE 3 ■ Operating-room configuration for left-sided laparoscopic live donor nephrectomy.



Instrumentation and Medication

Instrumentation for performing laparoscopic live donor nephrectomies varies according to surgeon comfort and experience.

LAPAROSCOPIC DONOR NEPHRECTOMY: BASIC INSTRUMENTATION

- Standard laparoscopic tower, complete with a carbon dioxide insufflator, light source, camera, monitor, and suction-irrigation device
- A laparoscope with a 30° lens, because the angled lens facilitates direct videoscopic visualization during challenging portions of the procedure, such as splenic mobilization and hilar dissection.
- A 5-mm curved tip Harmonic® scalpel^b for the majority of the blunt and coarse pararenal dissection, including periarterial dissection. It allows for expeditious, safe dissection with excellent hemostasis.
- Suction-irrigation device. Its tip can also be used as a blunt tip dissector for nonvascular tissue.

Control of the major branches of the renal vein is achieved with titanium clips. The renal artery, renal vein and ureter are controlled with the Endo-GIA® linear stapler with a vascular load. Occasionally, the Endo-TA^c linear stapler is used to achieve extra length on the renal hilar vessels. A 15-mm Endocatch^c bag is used to entrap and deliver the renal allograft through the Pfannenstiel extraction incision.

In addition to standard preoperative antibiotics, several medications are necessary to perform laparoscopic live donor nephrectomies and optimize immediate graft function. Each application will be discussed in detail during the comprehensive description of the operative technique. Mannitol is given on two occasions to help optimize renal perfusion. Anticoagulation is achieved with intravenous heparin prior to dividing the renal artery and then reversed with intravenous protamine prior to division of the renal vein. Topical papaverine is used to reduce arterial vasospasm during hilar dissection and allograft manipulation.

Table 1 lists necessary and optional laparoscopic equipment for performing laparoscopic live donor nephrectomies. A list of intraoperative medications is also supplied.

OPERATIVE TECHNIQUE

Laparoscopic Left-Sided Live Donor Nephrectomy

Insufflation and Trocar Placement

The peritoneal cavity is insufflated through a Veress needle to establish a pneumoperitoneum of 15 mmHg. A 5-mm incision is made just lateral to the umbilicus to accommodate the Veress needle. The needle is inserted directly perpendicular to the skin surface, with the distal tip stabilized by the surgeon's hand to prevent past-pointing during placement. The position of the needle tip is confirmed by the saline drop test. If the saline passes through the needle without resistance, the insufflation

^bEthicon Endo-Surgery, Cincinnati, OH.

^cU.S. Surgical Corp., Norwalk, CT.

TABLE 1 ■ Laparoscopic Instrumentation and Intraoperative Medications

Instruments	
■ Veress needle	■ Endoscopic shears
■ Two 5-mm laparoscopic trocars	■ 10-mm right-angled dissector
■ One 12-mm laparoscopic trocar	■ 10-mm Titanium clip applier
■ One 15-mm laparoscopic trocar	■ 15-mm Endocatch device ^b
■ 30° laparoscope (5 or 10 mm)	■ Endo-GIA ^b vascular stapler with two reload cartridges
■ Harmonic scalpel ^a	■ Carter-Thomason ^c fascial closure device
■ Antifog lens solution	■ Sterile ice slush
■ Debakey forceps/Maryland dissector	■ Standard open nephrectomy tray, retractors, and instrumentation
■ Suction-irrigation device	
Optional equipment	
■ 12-mm Endo Paddle Retract ^b	■ Hemo-lok clips ^d
■ Electrocautery hook	■ Hand-access device
■ Bipolar electrocautery forceps	
Medications	
■ Mannitol (12.5 g intravenous × 2 doses)	
■ Papaverine (30 mg/mL solution, 20 mL total)	
■ Heparin (5000 U intravenous)	
■ Protamine (30 mg intravenous)	
■ Cephazolin (1 g intravenous)	
^a Ethicon Endo-Surgery, Cincinnati, OH.	
^b U.S. Surgical Corp., Norwalk, CT.	
^c Inlet Medical, Eden Prairie, MN.	
^d Weck, Research Triangle Park, NC.	

In patients who have had extensive intra-abdominal surgery, a direct cut down to the peritoneal space (Hasson technique) is recommended.

Alternative to a 30° laparoscope, an optical trocar may be used, which allows the surgeon to visualize the layers of the abdominal wall and confirm safe placement of the initial trocar.

tubing is connected and the flow of carbon dioxide is initiated. An initial intra-abdominal pressure of less than 10 mmHg confirms achieved access to the peritoneal cavity.

In patients who have had extensive intra-abdominal surgery, a direct cut down to the peritoneal space (Hasson technique) is recommended.

Three transperitoneal trocars are used to perform left laparoscopic live donor nephrectomies (Fig. 4). The initial 5-mm trocar is placed at the site of the Veress needle. The abdominal contents are inspected using a 30° laparoscope to ensure that no injury occurred during placement of the Veress needle or the first trocar.

Alternative to a 30° laparoscope, an optical trocar may be used, which allows the surgeon to visualize the layers of the abdominal wall and confirm safe placement of the initial trocar.

Next, another 5-mm trocar is placed under direct vision, approximately three fingerbreadths below the xiphoid process just lateral to the abdominal midline. This will be used for operating the laparoscope during the procedure. The surgeon may choose a 10-mm trocar if he/she wishes to use a 10 mm, 30° laparoscope to perform the operation. A 12-mm trocar is placed on the mid-clavicular line, halfway between the umbilicus and the anterior superior iliac spine. The position of this trocar is important to avoid injury to the epigastric vessels. A 12-mm trocar must be used here to accommodate a standard endovascular stapling device, which is used to control the renal hilum. Some surgeons describe making the Pfannenstiel extraction incision, at the beginning of the procedure, and inserting a 12-mm trocar, through which an instrument can be placed to assist with retraction of the colon, pancreas, or mesentery (12,14). This trocar site is then extended during extraction of the renal allograft at the conclusion of the procurement. In most cases, if these intra-abdominal structures are fully mobilized during the initial steps of the procedure, further retraction is not necessary.

Step 1: Reflecting the Descending Colon/Splenic Mobilization

The white line of Toldt is incised at the pelvic inlet using either laparoscopic electrocautery endoshears or the active blade of the harmonic scalpel. The colon must be protected from electrocautery to prevent burn injury. Dissection is made in a cephalad




FIGURE 4 ■ Trocar placement for left-sided laparoscopic live donor nephrectomy. A 6-cm Pfannenstiel incision is used for allograft extraction.

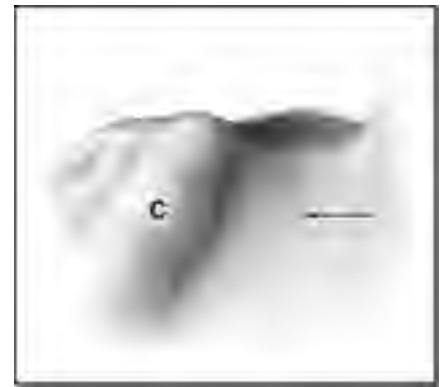


FIGURE 5 ■ The line of Toldt (arrow) is incised to begin mobilization of the descending colon (C).

It is crucial to release only the peritoneal attachments between the colon and the lateral sidewall; deeper dissection can result in the kidney dropping medially and obscuring the renal hilum, precluding safe hilar dissection. This also prevents inadvertent torsion of the kidney on its vascular pedicle during manipulation.

Dissection too close to the mesentery may result in injury to mesenteric vessels and bleeding, which may obscure the plane of dissection or cause a mesenteric defect. In addition, premature violation of Gerota's fascia may also cause excessive bleeding and limit identification of the renal hilum.

The tip of the dissection instruments should be maintained in direct view because past-pointing may lead to diaphragmatic injury and pneumothorax.

Visualization of the fundus of the stomach is the landmark used to signal that complete mobilization has been achieved.

direction over the anterior surface of the kidney toward the spleen (Fig. 5). There are often adhesions from the descending colon at the level of the splenic flexure to the anterior abdominal wall; these attachments need to be divided to carry the incision of the line of Toldt along the spleen toward the diaphragm. This includes releasing any splenophrenic attachment, thereby mobilizing the spleen from the abdominal sidewall.

It is crucial to release only the peritoneal attachments between the colon and the lateral sidewall; deeper dissection can result in the kidney dropping medially and obscuring the renal hilum, precluding safe hilar dissection. This also prevents inadvertent torsion of the kidney on its vascular pedicle during manipulation.

Once the peritoneal attachments have been divided, the avascular plane between Gerota's fascia and the mesentery of the colon is identified and developed. The bright yellow fat of the colonic mesentery is separated from the glistening white fibers of Gerota's fascia. The mesentery is bluntly dissected and mobilized medially. Tethering attachments are divided with the harmonic scalpel. Identification of this plane is critical.

Dissection too close to the mesentery may result in injury to mesenteric vessels and bleeding, which may obscure the plane of dissection or cause a mesenteric defect. In addition, premature violation of Gerota's fascia may also cause excessive bleeding and limit identification of the renal hilum.

Dissection is taken in a cephalad direction and continued by dividing the splenocolic ligament, which allows further medial mobilization of the descending colon. The surgeon's left-handed instrument (Maryland dissector) gently retracts the spleen medially, allowing incision of the splenorenal ligament, which further releases the spleen and precludes inadvertent tearing of the splenic capsule. Bleeding from the splenic capsule should be managed with gentle pressure and application of a hemostatic agent, such as Surgicel®. In addition, the argon beam coagulation device is often successful in achieving hemostasis in minor splenic tears. Major splenic injuries often require open conversion for splenorrhaphy. The dissection then follows the plane between the spleen and pancreas, and the upper border of Gerota's fascia. Attachments are divided using the harmonic scalpel, and the surgeon will feel the spleen releasing medially (Fig. 6).

The tip of the dissection instruments should be maintained in direct view because past-pointing may lead to diaphragmatic injury and pneumothorax (20).

The operating table can be rotated medially to facilitate the dissection. The goal is to release all the lateral attachments of the spleen so that it does not have to be retracted during the procedure, thereby minimizing the chance of injury. In addition, this will allow safe dissection of the upper pole of the kidney with minimal risk of splenic injury.

Visualization of the fundus of the stomach is the landmark used to signal that complete mobilization has been achieved.

Additional attachments between the pancreas and Gerota's fascia will also be seen and can be bluntly dissected. Minimal traction should be placed on the pancreas during its mobilization.

Step 2: Identification of the Renal Hilum

Once the descending colon, pancreas, and spleen have been mobilized and reflected medially en bloc, the surgeon should not have the need for retraction and should be able to identify the renal hilum with both instruments.

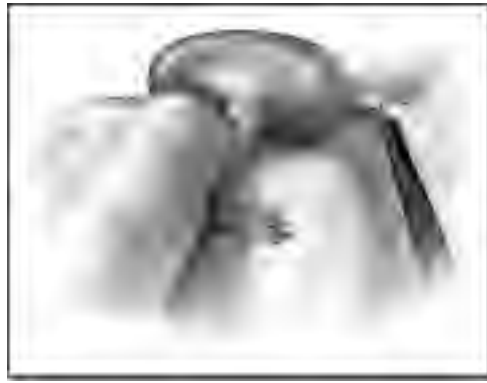

FIGURE 6 ■ The colonic mesentery is mobilized off of the anterior surface of Gerota's fascia en bloc with the pancreas and spleen. The splenophrenic ligament is divided to allow complete mobilization of the spleen away from the upper pole of the left kidney.

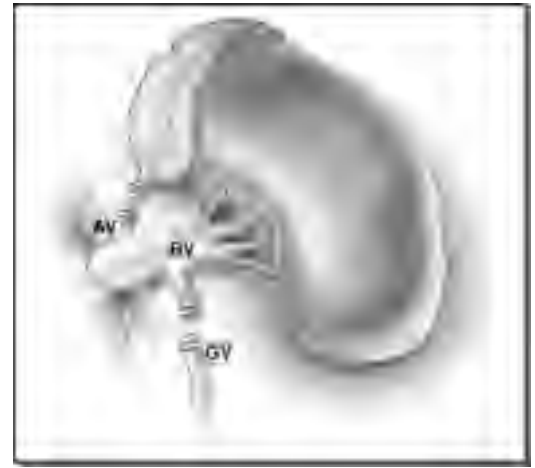

FIGURE 7 ■ The adrenal (AV) and gonadal veins (GV) are divided to attain maximum length on the renal vein (RV).

Once the descending colon, pancreas, and spleen have been mobilized and reflected medially en bloc, the surgeon should not have the need for retraction and should be able to identify the renal hilum with both instruments.

Clips on the specimen side should not be placed too close to the renal vein in anticipation of using the vascular stapling device later in the procedure. Retained clips may become entrapped within the Endo-GIA® stapler and cause misfiring of the device at the time of transection of the renal vessels.

If the renal vein is not easily identified, the left gonadal vein is an important structure because it reliably leads the surgeon to the renal vein.

Great care must be taken not to past-point the clips on the lumbar vein, because they may inadvertently catch the renal artery, which classically is located behind the lumbar branch of the renal vein.

Excessive traction on the renal hilum must be avoided to prevent arterial vasospasm.

Bleeding occurring during laparoscopic donor nephrectomy is most commonly encountered during hilar dissection.

The renal vein can often be visualized through Gerota's fascia, especially if adequate intravenous hydration has been maintained. The investing tissues overlying the renal vein are grasped and divided. The anterior surface of the renal vein is meticulously skeletonized, primarily by blunt dissection with the suction-irrigation device. Sharp dissection should be used sparingly around the renal hilum to minimize the chance of iatrogenic injury to the main renal vessels. Dissection is taken medially to ensure adequate length of the vein for transplantation. The take-off of the adrenal and gonadal veins is identified, and each vessel is isolated using blunt dissection. The harmonic scalpel is an excellent device to control several small branches that are often seen coming off the gonadal vein. Both the adrenal vein and gonadal vein are divided between hemoclips (Fig. 7).

Clips on the specimen side should not be placed too close to the renal vein in anticipation of using the vascular stapling device later in the procedure. Retained clips may become entrapped within the Endo-GIA stapler and cause misfiring of the device at the time of transection of the renal vessels (21).

The second dose of intravenous mannitol (12.5 g) is given at this point of the operation.

If the renal vein is not easily identified, the left gonadal vein is an important structure because it reliably leads the surgeon to the renal vein.

The gonadal vein is most easily identified inferiorly; it can then be traced in a cephalad direction to the level of the renal hilum. Once the gonadal vein has been safely transected, the surgeon gently grasps the proximal cut end of the gonadal vein and rotates it medially, exposing the lumbar vein. Hemostatic clips are applied to the lumbar vein prior to transection.

Great care must be taken not to past-point the clips on the lumbar vein, because they may inadvertently catch the renal artery, which classically is located behind the lumbar branch of the renal vein.

The renal artery is usually easily identified once the lumbar vein is transected. The renal artery should be dissected down to its origin from the aorta to achieve maximum renal vascular length.

Excessive traction on the renal hilum must be avoided to prevent arterial vasospasm. To minimize vasospasm, topical papaverine (30mg/mL) may be applied to the renal artery periodically. The renal artery should be skeletonized toward the origin of its surrounding perivascular and lymphatic tissues. Further skeletonization of the artery toward the renal sinus is not necessary. Aggressive dissection may cause vasospasm and will risk injury to branches of the artery if it bifurcates proximally.

Bleeding occurring during laparoscopic donor nephrectomy is most commonly encountered during hilar dissection. Bleeding emanating from small venous branches can often be controlled with direct pressure, placement of Surgicel or Gelfoam, or by temporarily elevating the insufflation pressure. Minor arterial sources of bleeding usually require hemoclips.

Large venous or arterial injuries, including damage to the main renal artery or vein often require open conversion to obtain hemostasis and ensure the safety of the living donor and the health of the allograft.

Large venous or arterial injuries, including damage to the main renal artery or vein often require open conversion to obtain hemostasis and ensure the safety of the living donor and the health of the allograft.

Surgeons with advanced laparoscopic skills may attempt to manage certain vascular injuries laparoscopically or with conversion to a hand-assisted approach. However, the importance of maintaining a low threshold for open conversion with this procedure cannot be overstated.

When the decision for open conversion is made, the surgeon should hold pressure with a laparoscopic instrument until the necessary equipment for open conversion is available. The surgeon quickly decides which incision (flank, subcostal, or midline) will give the best exposure to the renal hilum.

Successful dissection of the ureter during laparoscopic donor nephrectomy centers upon performing a wide dissection to ensure preservation of the periureteral tissue and blood supply, as well as obtaining satisfactory ureteral length for transplantation.

Step 3: Dissection of the Ureter

Successful dissection of the ureter during laparoscopic donor nephrectomy centers upon performing a wide dissection to ensure preservation of the periureteral tissue and blood supply, as well as obtaining satisfactory ureteral length for transplantation.

Early published series of laparoscopic live donor nephrectomies cited aggressive dissection of periureteral tissues to expose and identify the ureter as the main factor in a high incidence of ureteral complications, including ureteral stricture and necrosis (6,9). To avoid this, dissection is carried out medial to the distal gonadal vein stump, bluntly sweeping this structure and the periureteral tissues in a lateral direction. The medial attachments of the gonadal vein can be controlled with the harmonic scalpel, because small tributaries may cause minor bleeding. However, thermal energy should be used carefully to prevent thermal injury to the ureter or its blood supply.

In our current technique, one instrument is placed under the ureteral packet (including the gonadal vein) and elevated anteriorly (Fig. 8). The other instrument bluntly dissects the posterior attachments back to the fascia overlying the psoas muscle. Dissection is carried to the lateral abdominal sidewall and continued inferiorly to the iliac vessels.

There is no need to identify the ureter along its course; this minimizes the likelihood of compromising its blood supply during dissection.

Limited dissection is performed between the renal artery and the proximal ureter, thereby maintaining the ureteral blood supply arising from the renal artery. At this point in the procedure, the ureter is left intact. It will not be divided until the kidney is ready for extraction.

There is no need to identify the ureter along its course; this minimizes the likelihood of compromising its blood supply during dissection.

Step 4: Dissection of the Upper Pole of the Kidney

An area of Gerota's fascia cephalad to the renal hilum is incised sharply along the anterior aspect of the upper pole, exposing the renal capsule. The surgeon then places his/her left-handed instrument (suction irrigator or DeBakey forceps) next to the capsule and retracts medially. This will develop the plane to dissect the adrenal gland from the upper pole of the kidney. The harmonic scalpel is used here, because it easily coagulates small, friable perforating vessels that may be traveling to the adrenal gland.

During dissection of the upper pole of the kidney, upper pole renal vessels may be encountered and potentially injured. Despite potential identification of these vessels on preoperative computed tomography arteriography, meticulous dissection is necessary to prevent injury.

Next, the upper pole is elevated with the surgeon's left hand, allowing the harmonic scalpel to divide the posterior upper pole attachments.

During dissection of the upper pole of the kidney, upper pole renal vessels may be encountered and potentially injured. Despite potential identification of these vessels on preoperative computed tomography arteriography, meticulous dissection is necessary to prevent injury.

Step 5: Release of Lateral and Posterior Attachments

The lateral and posterior attachments are released while the surgeon gently retracts the kidney anteriorly. Because the posterior dissection progresses medially, the surgeon must be aware of the exact location of the renal hilum, to minimize the chance of iatrogenic injury to the renal vessels and their branches. In addition, as the allograft becomes more mobile, great care must be taken to avoid torsion of the kidney about its vascular pedicle. Now, the renal artery, renal vein, and ureter are the only attachments to the kidney.

Step 6: Preparing the Allograft Extraction Site

The extraction site is prepared by making a 5 to 6 cm Pfannenstiel incision, which was outlined at the beginning of the procedure. The anterior rectus fascia is skeletonized, making sure to mobilize overlying subcutaneous tissue. The fascia is incised longitudinally in the midline, ensuring sufficient room for extraction of the kidney. The rectus muscle is separated in the midline, and the underlying peritoneum is left intact in order

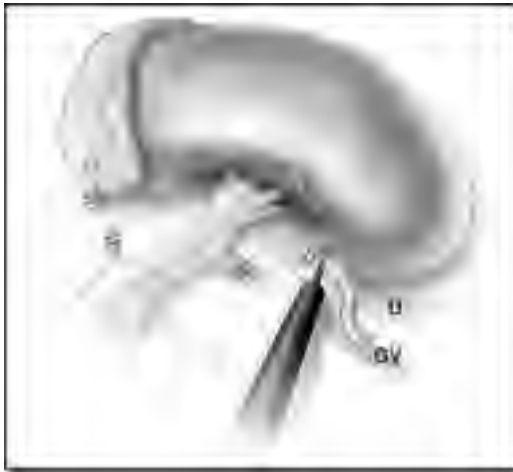


FIGURE 8 ■ Dissection of the ureter. An instrument is placed under the ureteral packet, including the clipped gonadal vein (GV), elevating it anteriorly because posterior attachments are dissected. The ureter (U) need not be visualized, because attempts to do so may compromise its delicate blood supply.

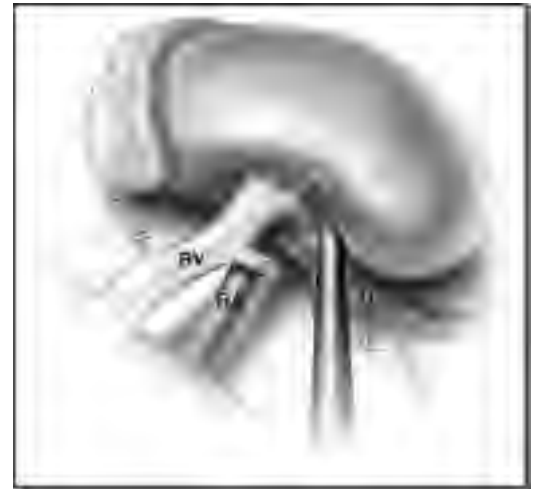

FIGURE 9 ■ The kidney is elevated with a blunt instrument, assisting in skeletonizing the renal vessels. Abbreviations: RA, renal artery; RV, renal vein.

to preserve the pneumoperitoneum. A 15-mm trocar is placed under direct vision in the middle of the extraction incision.

Step 7: Transection of the Ureter

Before initiating final delivery of the kidney, the surgical team must be alerted that the transplantation team is prepared to receive the allograft.

The back table must be equipped with ice slush and an intracellular electrolyte preservation solution. When the recipient surgical team is ready, the ureter and its well-preserved periureteral tissue packet is transected distally at the level of the iliac vessels using an endoscopic vascular stapling device. Alternatively, hemoclips can be placed distally and the ureter divided with endoscopic shears.

Step 8: Placement of the Allograft in the Entrapment Sac

The 15-mm Endocatch bag is deployed over the kidney toward the splenic fossa. The surgeon gently places the allograft onto its anterior surface and moves the bag behind the graft. The kidney is then gently placed into the bag, making sure that the ureteral stump is entrapped as well (Fig. 9). The bag must be kept in view during this maneuver, taking great care not to injure the bowel or other intraperitoneal structures.

- The advantages of “prebagging” the kidney prior to hilar vessel transection include rapid delivery with minimal warm ischemia time and providing traction to help obtain maximum vessel length.
- The main potential disadvantage of this technique is the possibility of arterial vasospasm. This should not occur if minimal traction is placed on the renal hilum during the extraction process.

Step 9: Transection of the Renal Vessels

Prior to securing the renal hilum, the patient is given 5000 U of intravenous heparin sulfate.

- With the renal vessels on gentle traction, the renal artery is transected flush with the aorta with a linear endovascular stapler or Hem-O-Lok clips (Fig. 10).
- The endovascular TA stapler or Hem-O-Lok clips will secure the patient side of the renal artery while leaving the graft side of the vessel open. This will maximize arterial length, because graft-side staples that are placed with the Endo-GIA stapler have to be excised by the recipient surgical team (22).

In addition, some transplant surgeons are concerned that these graft-side staples may cause intimal injury that may lead to more technical problems with the recipient

Before initiating final delivery of the kidney, the surgical team must be alerted that the transplantation team is prepared to receive the allograft.

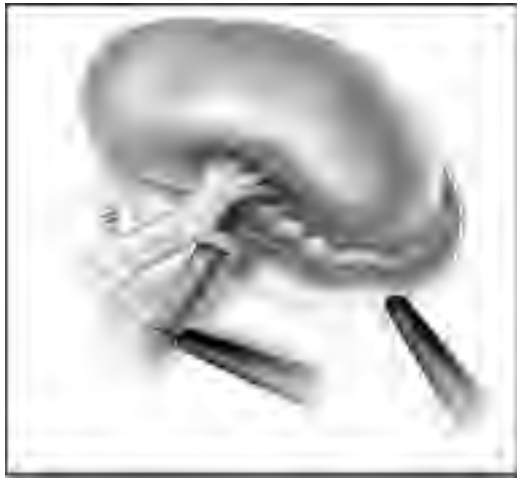

FIGURE 10 ■ The kidney with the divided ureter is gently placed into a 15-mm Endocatch® bag. The skeletonized renal vessels are placed on gentle traction for division. Transection of the renal artery (RA) using an Endo-GIA® stapling device. The renal vein (RV) will then be divided medial to the adrenal vein stump.

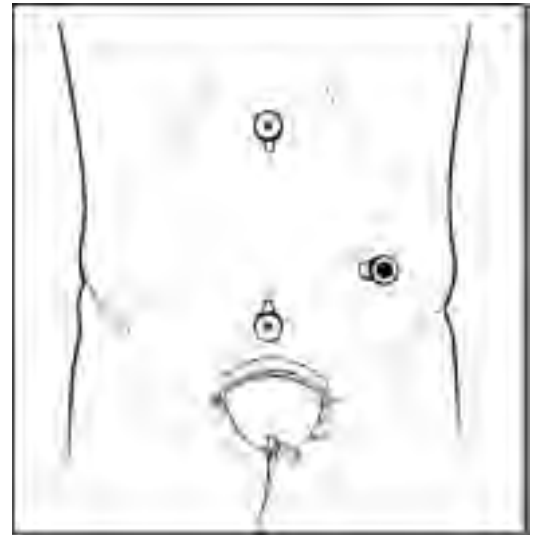


FIGURE 11 ■ Delivery of the kidney within the Endocatch® bag via the Pfannenstiel incision.

It is critical to avoid previously placed clips on the adrenal and lumbar veins when placing a stapling device on the renal vein. A misfire on the renal vein will result in almost certain open conversion, because the renal vein stump will retract anterior to the aorta and be difficult to control laparoscopically.

If multiple renal arteries are present, each should be transected prior to transection of the renal vein(s).

The allograft should not be forced through an incision too small to accommodate it.

The allograft is immediately immersed in ice slush and delivered to the recipient surgical team for immediate perfusion with iced preservation solution.

arterial anastomosis. Also, avoiding the Endo-GIA stapling device creates a safety net to avoid possible stapler misfire (21). With the Endo-TA or Hem-O-Lok clips, the security of the patient-side staples or clips can be observed prior to vessel transection.

After transection of the renal artery, anticoagulation is reversed with 50 mg protamine intravenously. This is followed by immediate transection of the renal vein as far medial from the adrenal vein stump as possible, affording maximal vessel length.

It is critical to avoid previously placed clips on the adrenal and lumbar veins when placing a stapling device on the renal vein. A misfire on the renal vein will result in almost certain open conversion, because the renal vein stump will retract anterior to the aorta and be difficult to control laparoscopically. If this happens, pressure should be applied in the area of the vein stump and the allograft delivered through the extraction site. Once the kidney is safely extracted, an appropriate incision is made to obtain hemostasis.

If multiple renal arteries are present, each should be transected prior to transection of the renal vein(s) (23).

Small accessory renal vessels (less than 2 mm) may be sacrificed after consultation with the recipient surgical team.

Step 10: Delivery of the Allograft

Once the renal vein is safely divided, the kidney drops into the Endocatch bag. After ensuring that the entire kidney and ureter are in the bag, the ring cord on the device is pulled, closing the sac and entrapping the allograft. The handle of the bag and trocar are removed, and the surgeon's hand opens the peritoneal cavity, creating a defect large enough for atraumatic delivery of the kidney (Fig. 11).

The allograft should not be forced through an incision too small to accommodate it. If necessary, then skin and/or fascial incisions are extended, taking great care to protect intraperitoneal contents that may herniate into the wound.

The allograft is immediately immersed in ice slush and delivered to the recipient surgical team for immediate perfusion with iced preservation solution.

Step 11: Inspection of the Renal Bed/Closure

The anterior rectus fascia is immediately closed with a running 0-polyglactin suture. Pneumoperitoneum is reestablished, and the renal bed is inspected at a low insufflation pressure. The renal artery and vein stumps are closely inspected. In addition, the splenic capsule, colon, and its associated mesentery, pancreas, and adrenal gland are examined for injury and to ensure meticulous hemostasis. Small sites of bleeding can be controlled

with electrocautery of hemoclips. A hemostatic agent, such as Surgicel, can be placed in the renal bed, if necessary.

The fascial defect from the 12-mm trocar site is closed under direct laparoscopic visualization with 2-0 polyglactin suture using the Carter-Thomason^d fascial closure device. All 5-mm trocars are removed without the need for fascial closure. The remaining pneumoperitoneum is released before the last trocar is removed. The fascial defect created from bladed trocars 10 mm in size or greater must be closed to minimize the risk of port-site herniation. Some surgeons believe that conical blunt trocar insertion may eliminate the need for fascial closure in transperitoneal laparoscopic renal surgery (24). This concept applies to blunt trocar placement through muscular parts of the abdominal wall, relying on muscle splitting and eventual muscle retraction when the trocar is removed. Fascial nonclosure after transperitoneal 12-mm blunt trocar insertion may be safe and efficacious and eliminate the last step in transperitoneal laparoscopic renal surgery. However, port-site hernia at the site of insertion of 10-mm nonbladed trocars has been described (25). It is generally recommended that all trocar sites larger than 5 mm, whether bladed or nonbladed, be closed in patients undergoing transperitoneal laparoscopic live donor nephrectomies.

Laparoscopic Right-Sided Live Donor Nephrectomy

Indications for laparoscopic procurement of the right kidney have been outlined earlier in this chapter. Patient positioning and trocar placement mirror those used for a left-sided dissection (Fig. 12).

An extra 5-mm trocar is placed laterally in the mid-axillary line to accommodate an instrument for retraction of the right lobe of the liver. Alternatively, this fourth trocar may be placed along the costal margin.

The operative steps for a right-sided dissection are similar to that on the left, with modification of the technique used for hilar dissection due to the presence of the inferior vena cava and the anatomically short right renal vein (26–28).

The dissection of the white line of Toldt is carried upward to the lower pole of the kidney at which point it is continued medially, staying several centimeters away from the ascending colon. This allows complete colon mobilization while keeping the lateral attachments of the kidney intact, thereby facilitating the hilar dissection later in the procedure. Continuing in a cephalad direction toward the diaphragm, the triangular and coronary ligaments of the liver are divided up to the diaphragm, allowing mobilization of the lateral aspect of the right lobe of the liver off of the upper pole of the right kidney. The liver may be retracted using a variety of instruments, including the PEER Jarit retractor^e or the diamond flex triangle retractor.^f

Kocherization of the duodenum is performed to mobilize it medially and skeletonize the anterior and lateral surfaces of the inferior vena cava. Minimal electrocautery is used to avoid thermal injury.

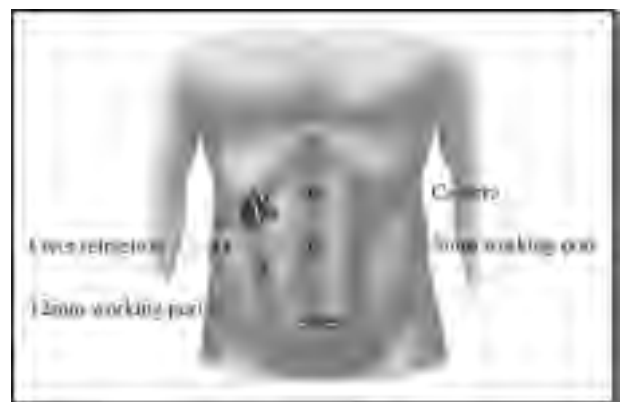
The duodenum must always be identified before dissection of the vena cava is initiated.

Adequate renal vein length and vascular control are primary concerns when performing right laparoscopic live donor nephrectomies. Gently retracting the renal vein and skeletonizing the anterior and lateral borders of the vessel initially identify the renal artery (29).

An extra 5-mm trocar is placed laterally in the mid-axillary line to accommodate an instrument for retraction of the right lobe of the liver. Alternatively, this fourth trocar may be placed along the costal margin.

The duodenum must always be identified before dissection of the vena cava is initiated.

FIGURE 12 ■ Trocar placement for right-sided laparoscopic live donor nephrectomy. An extra port is needed for liver retraction.



^dInlet Medical, Eden Prairie, MN.

^eJ. Jamner Surgical Instruments, Hawthorne, NY.

^fGenzyme Surgical Products, Tucker, GA.

Once the posterior and lateral attachments are released, the kidney is gently placed on its anterior surface and the renal artery dissection is completed posteriorly.

The use of an articulating stapler positioned parallel to, and flush with, the inferior vena cava allows procurement of the entire length of the right renal vein.

Once the posterior and lateral attachments are released, the kidney is gently placed on its anterior surface and the renal artery dissection is completed posteriorly. This allows the retrocaval dissection of the renal artery that is necessary to obtain adequate vessel length. The renal vein is dissected down to the level of the vena cava. Once the allograft is placed in the Endocatch bag, the artery is ligated at a level medial to the vena cava, and the renal vein is transected flush with the vena cava. Although the length of the right renal vein harvested laparoscopically is slightly shorter than that procured via the open technique, meticulous hilar dissection of the vessel on the bench table combined with extensive mobilization of the recipient external iliac vein typically provides sufficient length for a tension-free allograft venous anastomosis.

Technical modifications have been designed to optimize renal vein length and maximize safety during hilar dissection. The use of an articulating stapler positioned parallel to, and flush with, the inferior vena cava allows procurement of the entire length of the right renal vein.

Hand-assisted laparoscopy has been used as a method to improve retrocaval dissection of the renal artery, achieve maximal renal vein length, and simplify kidney extraction (30–34). The hand port incision that is required is usually made in the right lower quadrant. The hand-assisted approach does not add morbidity to the procedure for the donor patient and is an acceptable alternative to the pure laparoscopic transperitoneal approach.

Groups at several institutions have addressed concerns regarding harvesting a shorter renal vein by placing a clamp on the inferior vena cava and including a vessel cuff, mimicking the open approach. Turk et al. describe placing a modified laparoscopic Satinsky clamp[§] across the vena cava after the kidney has been placed inside the Endocatch bag and the artery transected (35). The allograft is then safely delivered, the extraction site closed, and the cavotomy closed with a laparoscopic running suture. Another modification described involves making a transverse subcostal incision over the renal hilum at the end of the procedure as an alternative to a Pfannenstiel extraction site (10). The hilar vessels are transected using the standard open technique, including a cuff of vena cava. Although this incision is not optimal with respect to postoperative pain and cosmesis, it ensures excellent control of the renal hilum with minimal warm ischemia time.

The cumulative experience with laparoscopic live donor right-sided nephrectomy is significantly less compared to the left-sided procedure. However, many studies have specifically examined right laparoscopic live donor nephrectomies and suggest that in experienced hands, it is safe for the donor patient and produces excellent immediate graft function. Boorjian et al. described a series of 40 right-sided laparoscopic live donor nephrectomies where donor morbidity and recipient allograft function did not differ from those seen with left kidneys procured laparoscopically (33). Similarly, Abrahams et al. reported on a similar series of patients where donor and recipient outcomes were equivalent between left-sided and right-sided procedures, without technical graft loss in either group (26,27). Although technically challenging because of the potential problems with dissection of the renal hilum, the right kidney can be procured laparoscopically when indicated and when an experienced surgeon is present.

Hand-Assisted Laparoscopic Live Donor Nephrectomy

Hand-assisted laparoscopy combines the principles of open and laparoscopic surgery to create a hybrid technique that was initially developed to shorten the learning curve for surgeons not trained in conventional laparoscopy. In addition, more complex laparoscopic procedures that failed to progress with standard laparoscopy could be completed with a hand-assisted approach instead of being converted to an open operation. The surgeon's nondominant hand is placed in the abdomen through a small incision to work in concert with the instrument-bearing dominant hand. A hand-access device is used to prevent the loss of pneumoperitoneum during the procedure.

The hand-assisted technique confers certain advantages to the surgeon, especially the novice laparoscopist. It provides the surgeon with tactile sensation and spatial orientation and allows palpation of vessels and adjacent organs. The surgeon's hand is a versatile instrument for exposing, dissecting, and retracting tissue. In addition, as in open surgery, hemostasis, and intracorporeal suturing and knot tying are facilitated by the surgeon's nondominant hand.

In performing hand-assisted laparoscopic live donor nephrectomies, the operative steps are identical to those already outlined for the standard laparoscopic approach. Unlike the standard technique, the extraction incision is made at the beginning of the procedure for placement of the hand-assist device.

[§]Aesculap Inc., Tuttlingen, Germany.

Selection of the proper incision site for placement of the device is critically important. The surgeon must be able to easily reach the superior aspect of the kidney to ensure complete mobilization and gentle handling of the allograft. For a left-sided donor nephrectomy, a periumbilical midline incision is used. For a right-sided donor nephrectomy, a modified muscle-splitting Gibson incision is made in the right lower quadrant.

Direct comparison of the hand-assisted technique to the standard laparoscopic technique reveals similar donor and recipient outcomes. Generally, operative times are slightly less with the hand-assisted technique, whereas postoperative pain and cosmesis favor the standard laparoscopic technique.

An important technical consideration with the retroperitoneal approach is maintaining the attachments of the anterior kidney to the parietal peritoneum during most of the procedure.

Selection of the proper incision site for placement of the device is critically important. The surgeon must be able to easily reach the superior aspect of the kidney to ensure complete mobilization and gentle handling of the allograft. For a left-sided donor nephrectomy, a periumbilical midline incision is used. For a right-sided donor nephrectomy, a modified muscle-splitting Gibson incision is made in the right lower quadrant.

After insertion of a hand-assist device and establishment of pneumoperitoneum, the camera and working trocars are placed in the same positions as in the standard laparoscopic technique. During the procedure, the intraperitoneal hand is used to present tissues for dissection, and is especially useful in elevating the kidney during transection of the renal hilum. After division of the renal vessels, the kidney is delivered directly through the hand-assist device incision and does not require placement within an entrapment sac. This minimizes warm ischemia time to the allograft.

There are numerous series in the literature describing the hand-assisted technique for live donor nephrectomy and reporting on outcomes for both donor and recipient allograft function (35–41). These series have shown hand-assisted laparoscopic live donor nephrectomies to be a safe, efficacious, and reproducible minimally invasive technique for renal donation. When compared with the open technique, hand-assisted laparoscopic live donor nephrectomies parallels the standard laparoscopic approach in terms of reduced donor morbidity while producing a healthy renal allograft for transplantation.

Direct comparison of the hand-assisted technique to the standard laparoscopic technique reveals similar donor and recipient outcomes. Generally, operative times are slightly less with the hand-assisted technique, whereas postoperative pain and cosmesis favor the standard laparoscopic technique (36,37).

With these results, hand-assisted laparoscopic live donor nephrectomies has emerged as a viable option to the laparoscopic surgeon for performing this technically challenging minimally invasive procedure.

Retroperitoneoscopic Live Donor Nephrectomy

The retroperitoneal approach to laparoscopic live donor nephrectomies initially evolved as an alternative technique to address concern with the low rates of right-sided laparoscopic donor nephrectomy in most series, an apparent reflection of the increased degree of technical difficulty harvesting the right kidney by the transperitoneal approach. As such, most reported series of retroperitoneoscopic donor nephrectomy involve the right kidney (42–45), although a small series of successful left-sided retroperitoneoscopic donor nephrectomy has recently been reported (46).

In performing retroperitoneal laparoscopic live donor nephrectomies, the patient is placed in the flank position, and the operating table is flexed to maximize the space between the iliac crest and the 12th rib. The retroperitoneal space is created by making a 15-mm incision inferior to the tip of the 12th rib through the lumbo-dorsal fascia. The space is expanded with blunt finger dissection and then a balloon dilator. Balloon dilation is performed anterior to the psoas muscle and outside of and posterior to Gerota's fascia. A three-port technique is used, with the primary 12-mm port placed at the site of entry. Another 12-mm port is placed anteriorly near the anterior axillary line approximately 3 cm cephalad to the iliac crest. A posterior 5-mm port is placed at the junction of the lateral border of the paraspinal muscles and the 12th rib (42).

The renal hilum is identified posteriorly, and the renal artery is isolated and mobilized from the renal hilum to its retrocaval location. The renal vein, along with a segment of inferior vena cava, is skeletonized. The ureter within the periureteral sheath is dissected distally into the pelvis.

An important technical consideration with the retroperitoneal approach is maintaining the attachments of the anterior kidney to the parietal peritoneum during most of the procedure.

Similar to the intact posterolateral attachments during the transperitoneal approach, this prevents the kidney from flopping posteriorly and obscuring the surgeon's view of the renal hilum.

During preparation for extraction, a muscle-splitting Gibson incision is made and developed to the transversalis fascia, avoiding disruption of the pneumoretroperitoneum (47). The renal artery and renal vein are divided in standard fashion. An articulating vascular stapler is positioned parallel to and flush with the vena cava as in the transperitoneal operation, ensuring procurement of the entire length of the right renal vein. Once the renal hilum is secured, the anterior attachments are rapidly divided to free the allograft completely. The intact fascial layer at the Gibson incision is divided, and the retroperitoneum is entered to quickly extract the kidney manually (47). The ureter is then transected using the incision for distal exposure.

The pure retroperitoneoscopic approach does have certain advantages over transperitoneal laparoscopic live donor nephrectomies. It allows rapid and direct access to the renal hilum, obviating the need to mobilize the liver, ascending colon, and duodenum. The right renal artery is effectively skeletonized in a retrocaval location, ensuring optimal arterial length for transplantation.

The pure retroperitoneoscopic approach does have certain advantages over transperitoneal laparoscopic live donor nephrectomies (48–50). It allows rapid and direct access to the renal hilum, obviating the need to mobilize the liver, ascending colon, and duodenum. The right renal artery is effectively skeletonized in a retrocaval location, ensuring optimal arterial length for transplantation.

The right renal vein and adjacent vena cava can be dissected under direct vision. Intra-abdominal adhesions in patients with prior abdominal surgery are avoided. Because the peritoneal cavity is not violated, iatrogenic injury to intraperitoneal organs and the likelihood of postoperative paralytic ileus are reduced.

Disadvantages of the pure retroperitoneoscopic approach to live donor nephrectomy include a longer warm ischemia time of the allograft, because antero-medial kidney attachments are not divided until after the renal vessels have been transected. Identification of landmarks is limited, and dissection in obese patients with large amounts of retroperitoneal fat can be quite difficult. Although hand-assisted retroperitoneoscopic live donor nephrectomy has been reported, the smaller working space limits the surgeon's ability to effectively use his/her hand to optimize dissection (48).

The largest experience with retroperitoneal laparoscopic live donor nephrectomies is reported by Ng et al. (45). In this series, right retroperitoneal laparoscopic live donor nephrectomies is compared with left transperitoneal laparoscopic live donor nephrectomies in a consecutive single-institutional experience. Operative times were significantly less with the retroperitoneal approach, whereas hospital stay, analgesic use, and donor–recipient creatinine were similar in both groups. Despite a statistically significant longer warm ischemia time with the retroperitoneal technique, recipient functional outcomes at one week and one month were similar in both groups (45).

SUMMARY

- Laparoscopic live donor nephrectomies is a remarkable technical achievement. It has had a substantial impact on the donor operation by providing a less-invasive approach to kidney procurement.
- Since its inception, it has emerged as the preferred technique for live kidney donation at many institutions.
- Despite technical modifications and development of refined instrumentation, this procedure still remains challenging.
- The donor surgeon must have a thorough knowledge of renal and pararenal anatomical structures, and be aware of specific steps in the operation susceptible to complications in order to proactively optimize complication management strategies.
- The surgeon's individual technique may evolve over time, but the basic steps in laparoscopic live donor nephrectomies have been firmly established.

REFERENCES

1. Wolfe RA, Ashby VB, Milford EL, et al. Comparison of mortality in all patients on dialysis, patients on dialysis awaiting transplantation, and recipients of a first cadaveric transplant. *N Engl J Med*, 1999; 341:1725–1730.
2. Cecka JM. Living donor transplants. In: Cecka MJ, Terasaki PI, eds. *Clinical Transplants 1995*. Los Angeles: UCLA Tissue Typing Laboratory, 1996:363–377.
3. Ratner LE, Cisceck LJ, Moore RG, et al. Laparoscopic live donor nephrectomy. *Transplantation* 1995; 60(9):1047–1049.
4. Jacobs SC, Cho E, Dunkin BJ, et al. Laparoscopic live donor nephrectomy: The University of Maryland 3-year experience. *J Urol* 2000; 164:1494–1499.
5. Jacobs SC, Cho E, Foster C, et al. Laparoscopic donor nephrectomy: The University of Maryland 6-year experience. *J Urol* 2004; 171:47–51.
6. Dunkin BJ, Johnson LB, Kuo PC. A technical modification eliminates early ureteral complications after laparoscopic donor nephrectomy. *J Am Coll Surg* 2000; 190:96–97.
7. Meng MV, Freise CE, Kang SM, et al. Techniques to optimize vascular control during laparoscopic donor nephrectomy. *Urology* 2003; 61(1):93–97.
8. Kuo PC, Cho E, Flowers JL, et al. Laparoscopic living donor nephrectomy and multiple renal arteries. *Am J Surg* 1998; 176:559–563.
9. Philosophe B, Kuo PC, Schweitzer EJ, et al. Laparoscopic versus open donor nephrectomy: comparing ureteral complications in the recipients and improving the laparoscopic technique. *Transplantation* 1999; 68:497–502.
10. Ratner LE, Fabrizio M, Chavin K, et al. Technical considerations in the delivery of the kidney during laparoscopic live donor nephrectomy. *J Am Coll Surg* 1999; 189:427–430.
11. Flowers JL, Jacobs SC, Cho E, et al. Comparison of open and laparoscopic live donor nephrectomy. *Ann Surg* 1997; 226:483–490.
12. Fabrizio MD, Ratner LE, Montgomery RA, et al. Laparoscopic live donor nephrectomy. *Urol Clin North Am* 1999; 26:247–256.

13. Su LM, Ratner LE, Montgomery RA, et al. Laparoscopic live donor nephrectomy: trends in donor and recipient morbidity following 381 consecutive cases. *Ann Surg* 2004; 240:358–363.
14. London E, Rudich S, McVicar J, et al. Equivalent renal allograft function with laparoscopic versus open live donor nephrectomies. *Transplant Proc* 1999; 31:258–260.
15. Bishoff JT, Kavoussi LR. Laparoscopic surgery of the kidneys. In: Walsh PC, Retik AB, Vaughan ED, Wein AP, eds. *Campbell's Urology*. 8th ed. Philadelphia: WB Saunders, 2002:3655–3661.
16. Dunn JF, Nylander WA, Richie RE, et al. Living related kidney donors: a 14-year experience. *Ann Surg* 1986; 203:637–643.
17. D'Alessandro AM, Sollinger HW, Knechtle SJ, et al. Living related and unrelated donors for kidney transplantation: a 28-year experience. *Ann Surg* 1995; 222:353–364.
18. Del Pizzo JJ, Sklar GN, You-Cheong JW, et al. Helical computerized tomography arteriography for evaluation of live renal donors undergoing laparoscopic nephrectomy. *J Urol* 1999; 162:31–34.
19. Kuo PC, Plotkin JS, Stevens S, et al. Outcomes of laparoscopic donor nephrectomy in obese patients. *Transplantation* 2000; 69:180–182.
20. London ET, Hung SH, Nehaus AM, et al. Effects of intravascular volume expansion on renal function during prolonged CO₂ pneumoperitoneum. *Ann Surg* 2000; 231:195–201.
21. Del Pizzo JJ, Jacobs SC, Bishoff JT, et al. Pleural injury during laparoscopic renal surgery: early recognition and management. *J Urol* 2003; 169:41–45.
22. Chan DY, Bishoff JT, Ratner LE, et al. Endovascular gastrointestinal stapler device malfunction during laparoscopic nephrectomy: early recognition and management. *J Urol* 2000; 164(2):319–321.
23. Bishoff JT, Allaf ME, Kirkels W, et al. Laparoscopic bowel injury: incidence and clinical presentation. *J Urol* 1999; 161(3):887–891.
24. Gurkan A, Kacar S, Basak K, et al. Do multiple renal arteries restrict laparoscopic donor nephrectomy? *Trans Proc* 2004; 36:105–107.
25. Shalhav AL, Barret A, Lifshitz DA, et al. Transperitoneal laparoscopic renal surgery using blunt 12-mm trocar without fascial closure. *J Endo* 2002; 16(1):43–46.
26. Lowry PS, Moon TD, D'Alessandro A, Nakada SY. Symptomatic port site hernia associated with a non-bladed trocar after laparoscopic live donor nephrectomy. *J Endourol* 2003; 17(7):93–94.
27. Abrahams HM, Freise CE, Kang SM, et al. Technique, indications and outcomes of pure laparoscopic right donor nephrectomy. *J Urol* 2004; 171:1793–1796.
28. Abrahams HM, Meng MV, Freise CE, et al. Pure laparoscopic right donor nephrectomy: step-by-step approach. *J Endourol* 2004; 18(3):221–224.
29. Lind MY, Hazebroek EJ, Hop WC, et al. Right-sided laparoscopic live donor nephrectomy: is reluctance still justified? *Transplantation* 2002; 74:1045–1048.
30. Chow GK, Chan DY, Ratner LE, Kavoussi LR. Interaortocaval renal artery dissection for right laparoscopic donor nephrectomy. *Transplantation* 2001; 72:1458–1460.
31. Wang DS, Bird VG, Winfield HN, Rayhill S. Hand-assisted laparoscopic right donor nephrectomy: surgical technique. *J Endourol* 2004; 18(3):205–210.
32. Buell JF, Hanaway MJ, Potter SR, et al. Surgical techniques in right laparoscopic donor nephrectomy. *J Am Coll Surg* 2002; 195:131–134.
33. Boorjian S, Munver R, Sosa RE, Del Pizzo JJ. Right laparoscopic live donor nephrectomy: a single institution experience. *Transplantation* 2004; 77(2):32–36.
34. Buell JF, Hanaway MJ, Woodle ES. Maximizing renal artery length in right laparoscopic donor nephrectomy by retrocaval exposure of the aortorenal junction. *Transplantation* 2003; 75:83–85.
35. Turk IA, Giessing M, Deger S, et al. Laparoscopic live right donor nephrectomy: a new technique with preservation of vascular length. *Trans Proc* 2003; 35:838–840.
36. Mendez-Torres FR, Urena R, Slakey D, Thomas R. Donor nephrectomy in the era of hand-assisted laparoscopic urologic surgery. *J Endourol* 2004; 18(4):359–363.
37. Validedeoglu E, Williams N, Brayman KL, et al. Comparison of open, laparoscopic and hand-assisted approaches in live donor nephrectomy. *Transplantation* 2002; 74:169–173.
38. Lindstrom P, Haggman M, Wadstrom J. Hand assisted laparoscopic surgery for live donor nephrectomy is more time and cost effective than standard laparoscopic nephrectomy. *Surg Endosc* 2002; 16:422–425.
39. Stifelman MD, Hull D, Sosa RE, et al. Hand assisted donor nephrectomy: a comparison with the open approach. *J Urol* 2001; 166:444–448.
40. Gershbein AB, Fuchs GJ. Hand-assisted and conventional laparoscopic live donor nephrectomy: a comparison of two contemporary techniques. *J Endourol* 2002; 16(7):509–513.
41. Ruiz-Deya G, Cheng S, Palmer E, et al. Open donor, laparoscopic donor and hand-assisted laparoscopic donor nephrectomy: a comparison of outcomes. *J Urol* 2001; 166:1270–1274.
42. Wolf JS, Marcovich R, Merion RM, Konnak JW. Prospective, case matched comparison of hand assisted laparoscopic and open surgical live donor nephrectomy. *J Urol* 2000; 163:1650–1655.
43. Gill IS, Uzzo RG, Hobart MG, et al. Laparoscopic retroperitoneal live donor right nephrectomy for purposes of allotransplantation and autotransplantation. *J Urol* 2000; 164:1500–1504.
44. Hernal AK, Iqbal MS. Minimally invasive retroperitoneoscopic live donor nephrectomy: point of technique. *Surg Laparo Endo* 2001; 11(5):341–343.
45. Buell JF, Abreu SC, Hanaway MJ, et al. Right donor nephrectomy: a comparison of hand-assisted transperitoneal and retroperitoneal laparoscopic approaches. *Transplantation* 2004; 77:521–525.
46. Ng CS, Abreu SC, Abou El-Fettouh HI, et al. Right retroperitoneal versus left transperitoneal laparoscopic live donor nephrectomy. *Urology* 2004; 63(5):857–861.
47. Hoznek A, Olsson LE, Salomon L, et al. Retroperitoneal laparoscopic living donor nephrectomy: preliminary results. *Eur Urol* 2001; 40:614–618.
48. Matin SF, Gill IS. Modified pfannenstiel incision for intact specimen extraction after retroperitoneoscopic renal surgery. *Urology* 2003; 61:830–832.
49. Sundqvist P, Feuk U, Haggman M, et al. Hand-assisted retroperitoneoscopic live donor nephrectomy in comparison to open and laparoscopic procedures: a prospective study on donor morbidity and kidney function. *Transplantation* 2004; 78(1):147–153.
50. Abreu SC, Goldfarb AD, Derweesh I, et al. Factors related to delayed graft function after laparoscopic live donor nephrectomy. *J Urol* 2004; 171:51–54.

LAPAROSCOPIC DONOR NEPHRECTOMY: CURRENT STATUS

Michael W. Phelan and Stephen C. Jacobs

Division University of Maryland School of Medicine, Baltimore, Maryland, U.S.A.

- INITIAL EXPERIENCE AND MOTIVATION
- EARLY CONTROVERSIES
 - Pneumoperitoneum
 - Warm Ischemia Time
 - Ureteral Complications
 - Laterality of Nephrectomy
 - Extraction Sites
- UNSOLVED CONTROVERSIES
 - Vascular Control
 - Skill Levels Required for Teaching
- SURGICAL TECHNICAL ISSUES
 - Approach
 - Robotics
- DONOR EVALUATION
- EXPANSION OF LIVE RENAL DONATION
 - Age
 - Obesity
 - Renal Stones
 - Renal Cysts
 - Malignancies
 - Other Measures
- CURRENT STATUS OF LAPAROSCOPIC APPROACH
 - Expansion of Laparoscopic Approach
 - International Experience
- SUMMARY
- REFERENCES
- COMMENTARY: John M. Barry

INITIAL EXPERIENCE AND MOTIVATION

Clayman et al. first introduced laparoscopic nephrectomy in 1990 (1). Patients who underwent such a “noninvasive” nephrectomy demonstrated less postoperative pain, shorter hospitalization, and faster recovery. With the benefits of laparoscopic nephrectomy becoming more apparent, laparoscopic donor nephrectomy was perceived as a technique that might encourage more individuals to undergo renal donation. Laparoscopic donor nephrectomy was first performed in an animal model in 1994 (2). Soon thereafter, the first laparoscopic donor nephrectomy in a human was performed in 1995 (3).

Initially, laparoscopic donor nephrectomy was treated with healthy skepticism, and the procedure was considered controversial. Complications seen in the early laparoscopic donors were worrisome, especially in the setting of open donor nephrectomy, which had been performed successfully for nearly five decades.

In many open donor series, the complication rates were as low as 1% to 8%, and early graft loss was extremely rare (4–9). To gain wide acceptance, laparoscopic donor nephrectomy appropriately had to meet the standards set by open donor nephrectomy.

The initial concerns revolved around graft function following laparoscopic surgery. Many feared that the pneumoperitoneum with increased abdominal pressure might lead to acute tubular necrosis and delayed graft function. Extraction of the kidney through a small incision might also injure the kidney. Other concerns included adequacy of vessel length and ureteral viability. Lastly, it was believed that the increased warm ischemia time associated with laparoscopic donor surgery would have long-term detrimental effects on graft function. In the rush to embrace new technology and the perceived requirement to compete for patients, many believed that the popularity of the technique would lead transplant programs to compromise the central ethos of leaving the best kidney with the donor in favor of performing the laparoscopic technique.

Table 1 shows that, in current series, the total operating time required to perform laparoscopic donor nephrectomy is comparable to that required for open surgery. In our review of 59 series, comprising 3330 donors, operative time for laparoscopic donor nephrectomy averaged 3 hours 45 minutes.

Overall reported complication rates averaged 5.6% in 2834 donors, although this number is difficult to use for comparison because of the disparate definitions of complications and because any comparison group of open donor nephrectomy is fraught with similar problems.

In many open donor series, the complication rates were as low as 1% to 8%, and early graft loss was extremely rare. To gain wide acceptance, laparoscopic donor nephrectomy appropriately had to meet the standards set by open donor nephrectomy.

Table 1 shows that, in current series, the total operating time required to perform laparoscopic donor nephrectomy is comparable to that required for open surgery. In our review of 59 series, comprising 3330 donors, operative time for laparoscopic donor nephrectomy averaged 3 hours 45 minutes.

TABLE 1 ■ Laparoscopic Donor Nephrectomy Series: Donor Characteristics

Technique	Total N	Left N	Right N	WIT (sec)	OR time (min)	Complications (%)	Conversion (%)	LOS (days)
<i>Standard transperitoneal</i>								
Maryland (10)	738	708	30	169	202	6.8	1.6	2.7
UCSF (11–13)	387	333	54	240	208	5.0	0.3	3.2
Johns Hopkins (14)	381	362	19	294	253	7.6	2.1	3.3
33 series; $n < 125$ (15–52) ^a	1631	947	138	249	247	4.2	3.2	2.8
Subtotal average	3137	2350	241	229	229	5.6	2.2	2.9
<i>Hand-assisted</i>								
18 series; 125 (24,45–63) ^a	744	180	120	118	150	8.0	2.4	3.6
<i>Retroperitoneal</i>								
Five series; 135 (64–68) ^a	211	159	52	286	265	2.5	1.2	5.6
Total average	4092	2689	413	219	215	5.6	2.1	3.2

^aNot all series reported all data points.
Abbreviations: N, nephrectomy; UCSF, University of California San Francisco; OR, operating time; WIT, warm ischemia time; LOS, length of stay.

EARLY CONTROVERSIES

Pneumoperitoneum

With good intraoperative hydration of the donor (5–6 L), initial concerns for renal dysfunction due to increased pressure from pneumoperitoneum have not been realized (69–71). In addition to aggressive hydration, the donors are given 25 g of intravenous mannitol, which provides an osmotic diuresis and has antioxidant properties. Clinically, all renal transplant centers attempt aggressive hydration of the donor prior to and during the nephrectomy, with some services even aiming for 4000 to 6000 mL of intravenous fluids prior to and during the procedure (25).

Warm Ischemia Time

Laparoscopic donor nephrectomy is associated with longer warm ischemia time when compared to open surgery (39). The warm ischemia time for a typical open surgery should be less than a minute, but this has never been precisely measured in a large series. The University of Maryland six-year experience (10) reported a slow but steady decline in the warm ischemia time for the first 400 cases, showing that the early experience in laparoscopic donor nephrectomy did require a learning curve for the development of the procedure. At the time of this writing, we reviewed 36 published series comprising 3137 standard transperitoneal laparoscopic donor nephrectomies (Table 1). The average warm ischemia time reported was four minutes for the 2256 cases in which it was measured. The hand-assisted laparoscopic donor nephrectomy technique allows an even quicker extraction after clamping of the renal vessels, as shown in 18 published series reporting a sum total of 744 hand-assisted donor nephrectomies with an average warm ischemia time of only two minutes in the 354 cases in which this parameter was measured.

Despite an average warm ischemia time of only 21/2 minutes for their entire series of 722 donors, the University of Maryland group could not detect a correlation between the length of warm ischemia time and recipient creatinine levels or delayed graft function (10,72).

The impact of small increments in warm ischemia time is largely unknown. In fact, Opelz et al. (73) have shown that there was no strong correlation between warm ischemia time and long-term graft function even in cadaver kidney grafts. In their large series, warm ischemia times even as long as 30 to 40 minutes resulted in no appreciable difference in graft survival (15). At the current time, it is reasonable to assume that any small increase in warm ischemia time results in a small, but probably immeasurable, renal injury.

The etiology of delayed graft function is multifactorial. Table 2 shows that delayed graft function occurred in 3.2% of the 2888 donors reported. Overall, the recipient's serum creatinine at one week following the transplantation was 1.8 mg% ($N = 2610$), which is comparable to that of open nephrectomy series.

Laparoscopic donor nephrectomy is associated with longer warm ischemia time when compared to open surgery.

Despite an average warm ischemia time of only 21/2 minutes for their entire series of 722 donors, the University of Maryland group could not detect a correlation between the length of warm ischemia time and recipient creatinine levels or delayed graft function.

TABLE 2 ■ Laparoscopic Donor Nephrectomy: Recipient Results

Technique	DGF	Creatinine (at 1 wk in mg%)	Ureteral complications
<i>Standard transperitoneal</i>			
Maryland (10)	2.6%	2.0	4.5%
UCSF (11–13)	5.0%	1.4	6.0%
Johns Hopkins (14)	2.0%	2.3	6.0%
33 series; n < 125 (15–52) ^a	3.8%	1.6	2.0%
Subtotal average	3.4%	1.8	4.1%
<i>Hand-assisted</i>			
18 series; n < 125 (24,45–63) ^a	2.8%	1.8	1.1%
<i>Retroperitoneal</i>			
Five series; n < 135 (64–68) ^a	0.6%	1.3	1.5%
Total average	3.2%	1.8	3.7%

^aNot all series reported all data points.

Abbreviations: DGF, delayed graft function; UCSF, University of California San Francisco.

Technical modifications included (i) en-bloc wide removal of the peri-ureteral tissue along with the ureter; (ii) preservation of the triangle between the junction of the gonadal vein–renal vein and the lower pole of the kidney; and (iii) en-bloc removal of the entire gonadal vein along with the ureter and all periureteric tissue and resulted in lower ureteral complications.

Although the majority of ureteral complications are due to technical errors in harvesting or reimplantation, some distal ureteral strictures can be the result of allograft rejection ischemia.

Since the inception of living, related kidney donation, the better kidney has always remained with the donor.

Ureteral Complications

Early in the laparoscopic donor experience, rates of ureteral complications were high. The ureteral complication rate was 10.5% and 10% in the University of Maryland and the Johns Hopkins series, respectively (74,75). These ureteral complication rates were alarmingly higher when compared to that in the contemporary open donor cohorts (9,75) and led to changes in the technique aimed at preservation of ureteral vascularity (74).

Technical modifications included (i) en-bloc wide removal of the periureteral tissue along with the ureter; (ii) preservation of the triangle between the junction of the gonadal vein–renal vein and the lower pole of the kidney; and (iii) en-bloc removal of the entire gonadal vein along with the ureter and all periureteric tissue and resulted in lower ureteral complications.

At Johns Hopkins, the ureteral complication rate for the first 100 laparoscopic donor nephrectomies was 10%, whereas the complication rate for the next 100 cases dropped to 3% (75). At the University of Maryland, the ureteral complication rate of 14.5% (74) in the initial (76) cases subsequently dropped to less than 3% (10). Overall, the published collective experience of 36 large series reporting on 2206 standard transperitoneal laparoscopic donors shows a ureteral complication rate of 4.5%. These series are now mature enough that one would not expect this number to grow due to late complications. Hand-assisted laparoscopic donor nephrectomy has a low incidence of ureteral complications. In 18 published series of 188 hand-assisted laparoscopic donors, the recipient ureteral complication rate was only 1.1%. However, hand-assisted laparoscopic series are less mature, and late complications might increase the number slightly. Nevertheless, this is still a very low rate that competes favorably with any open nephrectomy series.

Usual presentation of ureteral complications in the recipient includes ureteral leak, necrosis, or stricture. Although the majority of ureteral complications are due to technical errors in harvesting or reimplantation, some distal ureteral strictures can be the result of allograft rejection ischemia.

Most ureteral complications (88%) occur within the first six postoperative months (10). The decrease in ureteral complications seen in the laparoscopic donor nephrectomy series has been attributed to improved technique and preservation of ureteral blood supply in the triangle between the proximal ureter and the lower pole of the kidney. Although definitely not desirable, ureteral injuries are usually reparable and do not have the potential of immediate graft loss.

Laterality of Nephrectomy

Since the inception of living, related kidney donation, the better kidney has always remained with the donor (77).

Historically, the percentage of right kidney donors in the open experience ranges from 26% to 37% (78). Common indications for right-sided donor nephrectomy include multiple left renal arteries or veins, right renal cysts, smaller right kidney, or possibly solitary right-sided nephrolithiasis (79–81).

Right renal vein length is significantly shorter than left donor vein length. Laparoscopic use of the endovascular stapler or multiple clips also contributes to loss of vessel length of approximately 1 to 1.5 cm. The shorter length of the right renal vein may precipitate higher rates of graft thrombosis, because the technical issues of sewing a short renal vein into the recipient can be considerable.

The early laparoscopic donor nephrectomy experience concentrated heavily on the left kidney. The reason for this preference included both the known longer left renal vein and the less complex operative exposure of the left renal artery compared to the right one. Also, the short right renal vein presented technical challenges for the recipient surgeon, and a high rate of recipient vein thrombosis following right-sided laparoscopic nephrectomy was concerning. A multicenter review of right-sided laparoscopic donor nephrectomy revealed a higher rate of graft thrombosis (79). As a result, in the initial experience of Johns Hopkins, the University of Maryland, the Washington Hospital Center, and the Seattle group, the left side was preferred in more than 95% of patients (16,18,75,82).

Right renal vein length is significantly shorter than left donor vein length (75). Laparoscopic use of the endovascular stapler or multiple clips also contributes to loss of vessel length of approximately 1 to 1.5 cm (83). The shorter length of the right renal vein may precipitate higher rates of graft thrombosis, because the technical issues of sewing a short renal vein into the recipient can be considerable.

Recipient surgeons have become more comfortable with implanting multiple vessel kidneys (10,21,28,80), and, given the choice, many prefer two arteries with a long left renal vein compared to a single artery and a short right renal vein.

The confidence developed with increased laparoscopic experience and the ability to concentrate on obtaining greater vein length has allowed some programs to start using more right kidneys. The published results of 36 centers on 2691 standard laparoscopic donor nephrectomies show only an 8.6% predilection for the right side, which is higher than the early reports of less than 5% (16,18,75,82).

Technical modifications to maximize renal vein length and thus allow more standard right laparoscopic donations have been made. Mandal et al. at Johns Hopkins report three technical modifications that aid in successful right-sided laparoscopic donor nephrectomies (80). First, ports are placed in a configuration that allows the endovascular stapler to be fired parallel to the vena cava. Second, a small subcostal incision is made at the conclusion of laparoscopic dissection of the right kidney to allow use of a standard Satinsky clamp. This hybrid laparoscopic/open technique allows a cuff of vena cava to be harvested with the right renal vein. Third, the recipient's saphenous vein can be used as a panel graft to lengthen the right renal vein. Buell et al. reported a multi-institutional review of right laparoscopic donors (79). After two early graft losses, Buell et al. modified their technique, including extensive vein mobilization, division of the vein parallel to the vena cava, and incorporation of a portion of the cava into the staple line by stretching the vein with the use of either a hand-assisted device or standard laparoscopic instruments. With these modifications, outcomes of right-sided laparoscopic donor nephrectomy became comparable to that of left donations.

However, the major increase in right-sided donor nephrectomy performance has been due to hand-assisted laparoscopic technique, which affords not only an atraumatic lateral stretch on the kidney to maximize the vein length prior to firing an endovascular stapler, but also superior control of the vena cava in the event of bleeding. Published results from 18 centers on 610 hand-assisted laparoscopic donor nephrectomies show a 40% preference for the right side. Despite the higher and slightly larger extraction site, the hand-assisted laparoscopic technique still offers a similar reduction in convalescence (84,85). The use of the retroperitoneal laparoscopic approach is somewhat more preferentially employed for right donations. Fewer centers use this approach due to lack of anatomic familiarity, but those centers that do report an 11.2% right-sided nephrectomy preference (Table 1).

Turk et al. reported the use of a laparoscopic Satinsky clamp to maximize the length of the right renal vein (86). The clamp was applied to the vena cava at the ostium of the right renal vein, and the entire renal vein with a small cuff of vena cava was harvested. After kidney removal and pneumoperitoneum reestablishment, the cavotomy was closed with a running suture. This maneuver requires a reliable assistant to hold and stabilize the Satinsky clamp during removal of the kidney and closure of cavotomy with delicate laparoscopic suturing technique. Application of this technique is challenging and, therefore, not widely used.

Extraction Sites

Suprapubic, umbilical, lower quadrant, and dorsal lumbotomy extractions all have been performed, and there are only minor differences in discomfort and recovery between these sites. At the time of this writing, transvaginal extraction has not yet been performed. It is hard to imagine any further improvements in outcome with alternative extraction sites because of the size requirement to remove the kidney.

The best site to extract the graft is through an infraumbilical midline or Pfannenstiel incision. Port site hernias may occur and are more common for the larger ports with cutting blades.

Extraction site hernias are fortunately uncommon. They are more likely to occur if an umbilical site or lateral abdominal wall sites are used.

The best site to extract the graft is through an infraumbilical midline or Pfannenstiel incision. Port site hernias may occur and are more common for the larger ports with cutting blades.

UNSOLVED CONTROVERSIES

Vascular Control

Live donor nephrectomy can be a dangerous operation. Five donor deaths have been reported in the United States. Of these, two occurred due to hemorrhage. One of these donors suffered anoxic brain damage and lived in a vegetative state for four years before dying recently (87).

Conversion of a laparoscopic nephrectomy to open nephrectomy is most commonly performed for vascular control. The overall rate of conversion reported is 2.1% in 3478 donors (Table 3).

Vascular injuries are the most feared complication in laparoscopic surgery (88–90). Vascular injuries may occur at the time of peritoneal entry, during placement of the Veress needle or the trocars. Injuries may also occur at any step of the surgical dissection or vascular stapling. Vascular injuries occurring during laparoscopic donor nephrectomy may be classified as minor or major injuries. Minor injuries are defined as those that can be handled laparoscopically without jeopardizing the outcome of the surgery for either the donor or the recipient. Minor bleeding from injury to gonadal, lumbar, or adrenal veins falls into this category. However, if these injuries are not controlled rapidly, they can quickly become major problems. Major vascular injuries are defined as those that result in conversion to open surgery or graft loss. Major vascular injury is the most common cause for conversion to open surgery.

Sixty percent of the vascular injuries requiring open conversion occur during the use of the endovascular stapler (10). Therefore, complete dissection prior to use and great care in avoiding other clips and staples when applying the endovascular staplers are essential. With major vascular injuries, quick conversion will minimize blood loss and maximize the chances for a successful outcome for both the donor and the recipient.

The optimal technique for vessel control is another point of debate in laparoscopic donor surgery. The current methods of control of renal vessels are laparoscopic clips, endovascular staples, or Hem-O-Lok clips. These methods fail infrequently, but when they do fail, major complications and even donor death may occur. Most centers, including ours, use some form of endovascular staples. Although not perfect, the endovascular staples provide reliable division and simultaneous hemostasis of the renal vessels. As per our experience, staple failure may occur, and one must always be prepared for staple failure (91). Prior to firing any vascular staples, we always double check to ensure that we have vascular clamps and an open tray immediately available for rapid conversion to control bleeding if needed. In the event of a staple misfire and a major vascular injury, a delay in conversion could result in a surgical catastrophe. Another method followed by some centers for achieving vascular control is the use of Hem-O-Lok clips. Proponents of this technique argue that the vascular length is better preserved with this device. However, a single Hem-O-Lok slipping off the renal artery within 24 hours did lead to exsanguination

Sixty percent of the vascular injuries requiring open conversion occur during the use of the endovascular stapler. Therefore, complete dissection prior to use and great care in avoiding other clips and staples when applying the endovascular staplers are essential. With major vascular injuries, quick conversion will minimize blood loss and maximize the chances for a successful outcome for both the donor and the recipient.

TABLE 3 ■ Relative Advantages of Different Laparoscopic Approaches

	Standard transperitoneal	Hand-assisted	Retroperitoneal
Incisional stability	****	**	***
Incisional pain	****	***	**
Vascular control (emergency)	*	****	*
Warm ischemia time	*	***	*
Operative time	***	*	***
Disposables cost	**	*	**
Surgical experience required	*	***	*
Risk of intraperitoneal organ injury	***	***	*

* Lowest; **** highest.

Currently, the biggest risk to the donor is potential vascular catastrophe. There is room for device reliability improvement even for the available excellent products.

Laparoscopic donor nephrectomy requires much more skill and finesse than laparoscopic radical nephrectomy. There is no margin of error. Superb technique is absolutely essential to obtaining good donor outcome and recipient graft function.

The real challenge with laparoscopic donor nephrectomy is achieving and maintaining the skill levels required for the entire laparoscopic team. The team participating in the surgery includes surgeons, anesthesiologist, circulating nurses, and surgical technicians. Each one of these team members plays a vital role. Team cohesion, consistency, and skill are all vital to successful outcomes—especially in the event of an emergency.

The authors prefer a standard transperitoneal approach. The main advantages of the transperitoneal approach are twofold. First, the transperitoneal approach allows for a large working space and good visualization of the entire operative field. Second, in cases of surgical emergency and conversion to an open technique, rapid visualization and access to the great vessels is optimal with the transperitoneal approach. The disadvantage of the transperitoneal approach is the dissection of the intraperitoneal organs in accessing the retroperitoneum. Mobilization of the intra-abdominal organs exposes these organs to potential injury.

and a donor death. Therefore, multiple clips should be used for safety. The ultimate goal is to provide the maximum vessel length with the safest method; the renal vein length is especially important. However, this should not in any way compromise donor safety.

Currently, the biggest risk to the donor is potential vascular catastrophe. There is room for device reliability improvement even for the available excellent products.

Skill Levels Required for Teaching

The common obstacle to overcoming high rates of complications in laparoscopic donor nephrectomy has been the steep learning curve. Laparoscopic donor nephrectomy requires much more skill and finesse than laparoscopic radical nephrectomy. There is no margin of error. Superb technique is absolutely essential to obtaining good donor outcome and recipient graft function.

Training laparoscopic donor surgeons is particularly difficult. It is certainly helpful if the donor surgeon trainees already know how to perform an open nephrectomy and have laparoscopic skills. The surgeon needs to be fully trained in open surgery first. In a donor, if conversion to open surgery is required, this will need to be done very quickly and with no warning. The surgeon must pay attention to many little details constantly. The best approach is to have a team of surgeons, and constant interplay between the surgeons is valuable to constantly reaffirm safety. The stress level of these cases is an order of magnitude higher than that with ordinary laparoscopic surgery. In general, an individual surgeon does not really feel comfortable until he has performed more than 100 cases. However, mastering the technical skills is only one part of the equation to a successful donor program.

The real challenge with laparoscopic donor nephrectomy is achieving and maintaining the skill levels required for the entire laparoscopic team. The team participating in the surgery includes surgeons, anesthesiologist, circulating nurses, and surgical technicians. Each one of these team members plays a vital role. Team cohesion, consistency, and skill are all vital to successful outcomes—especially in the event of an emergency.

In these situations, the surgical team's immediate action is paramount. The anesthesia team must try to optimize the renal function and be prepared for potential problems such as bleeding, pneumothorax, and position-induced injuries. Skilled operating room personnel need to know where each piece of equipment is and how to retrieve elements quickly. A kidney donor is ostensibly a *healthy* adult and the requirement for safety is absolutely paramount. Assembling a correct and committed team is the first step to assuring donor safety.

SURGICAL TECHNICAL ISSUES

Approach

There are several laparoscopic techniques in clinical practice that provide good results. Standard transperitoneal, hand-assisted, or retroperitoneal laparoscopy are all techniques that are commonly used. Each technique is associated with advantages and disadvantages, which are shown in Table 3.

The authors prefer a standard transperitoneal approach. The main advantages of the transperitoneal approach are twofold. First, the transperitoneal approach allows for a large working space and good visualization of the entire operative field. Second, in cases of surgical emergency and conversion to an open technique, rapid visualization and access to the great vessels is optimal with the transperitoneal approach. The disadvantage of the transperitoneal approach is the dissection of the intraperitoneal organs in accessing the retroperitoneum. Mobilization of the intra-abdominal organs exposes these organs to potential injury.

Some centers use the retroperitoneal laparoscopic approach for donors (68,92,93). The main advantage of this approach is rapid access to the kidney with minimal dissection. The main disadvantages of this approach are twofold. First, the small working space afforded in this approach allows more limited visualization. Second, in cases of surgical emergency, rapid access and visualization of the great vessels may be cumbersome. A group in Tokyo recently performed retroperitoneal laparoscopic donor nephrectomy and removed the kidney at an extraperitoneal suprapubic extraction site (93). This combination may well prove the least morbid for the doors. Most surgeons, however, are more familiar with the transperitoneal approach and, therefore, it is likely to remain the most popular approach.

Rudich et al. reported good results with the hand-assisted laparoscopic approach (94). The main advantage of hand-assisted laparoscopic surgery is the ability to maintain tactile sensation. Because of the tactile feedback and the ability to use effective compression, the actual conversion rate for hand-assisted laparoscopic donor nephrectomy is lower compared to that for standard laparoscopy. The 1.2% conversion rate for hand-assisted laparoscopic donor nephrectomy is half of the rate for the other approaches (Table 1). Many argue this advantage of hand assistance may lower the steep learning curve associated with pure laparoscopic techniques. The main disadvantages of hand-assisted surgery are forearm fatigue that the surgeon experiences at the site of the hand port and cost of the device. Hand-assist devices add considerable cost to the procedure, which Wolf et al. estimated as high as 11% of the total operating room cost (95).

Robotics

Robotic laparoscopic donor nephrectomy has been documented. The use of robotics is not accepted as advantageous for this procedure. In the donor nephrectomy procedure, the camera movements require wide swings, which are too frequent and complex for the robot to react as quickly as a human assistant. It seems unlikely that robotic technology will provide any improvements in technique in the immediate future.

DONOR EVALUATION

A multidisciplinary team of transplant coordinators, social workers, psychiatrists, nephrologists, transplant surgeons, and donor surgeons provides protection for the donor. The evaluation process includes questionnaire screening of medical and psychosocial status, diagnostic studies, and, finally, informed consent. Contraindications to donation are shown in Table 3. Total creatinine clearance over 80 mL/min is required to qualify as a donor. Obese individuals and those who have a diabetic first-degree relative should undergo glucose tolerance testing. All donors undergo screening chest X-ray and electrocardiogram. Patients over 50 years of age should undergo additional cardiac stress testing. Female candidates should undergo PAP Anicolav smear and mammography (over 40 years of age). Prostate specific antigen and digital rectal exam screening is performed in men over 40 years. Repeated routine blood pressure measurements recording a systolic pressure below 140mmHg and a diastolic blood pressure below 80 mmHg are required. Borderline readings are evaluated with 24-hour blood pressure monitoring. After all the tests are done, a helical computed tomography (CT) arteriogram of the abdomen and pelvis is performed. This study is accurate in determining vascular anatomy (96–98), renal volume, renal masses, and stones. The excretory phase provides anatomic detail of the collecting system and ureters. The donor surgeon is responsible for obtaining informed consent. Just prior to the surgery, a final repeat crossmatch is performed.

EXPANSION OF LIVE RENAL DONATION

The frontier of laparoscopic donor nephrectomy is now focused on safely broadening the donor pool (99). Acceptable candidates may now include older donors, unrelated donors, on call emergency donors for recipients needing concomitant pancreas transplantation (100), obese donors (101), voluntary prisoners, paired-exchange donors, and Good Samaritan donors. Table 4 shows the remaining contraindications for live renal donation, although some of these contraindications may be overcome.

Patients who may ultimately be significantly harmed by the donor surgery or suffer long-term consequences from having a solitary kidney must be protected. There have been five known donor deaths (87) (personal communication), due to embolism, hemorrhage, respiratory failure, or undetermined cause. Reporting to United Network for Organ Sharing is voluntary and, therefore, it is possible that underreporting exists.

In expanding the spectrum of donors, there are controversial areas. Clearly, the demand for kidneys is growing at a far greater rate than the supply. While the cadaver pool has remained stable, living donor nephrectomy has grown steadily. Since 2001, live donor renal transplants have exceeded cadaveric transplants according to United Network for Organ Sharing reports.

Age

Aging of the general population and the attendant increase in End stage renal disease has widened the gap between available cadaver kidneys and demand. It appears that there is the development of an organ “social security” system in which younger donors

In expanding the spectrum of donors, there are controversial areas. Clearly, the demand for kidneys is growing at a far greater rate than the supply. While the cadaver pool has remained stable, living donor nephrectomy has grown steadily. Since 2001, live donor renal transplants have exceeded cadaveric transplants according to United Network for Organ Sharing reports.

TABLE 4 ■ Contraindications for Live Kidney Donation

Absolute	Comments	Relative	Comments
Positive crossmatch	Desensitization protocol	Blood type incompatibility	Desensitization protocol
Monetary incentive		Positive flow cytometric crossmatch	Desensitization protocol
Chronic kidney disease		Heart disease	Age above 50 yrs; require stress test
Anatomic kidney abnormalities		Hypertension	Blood pressure above 140/85 mmHg; may require 24 hr home monitoring
Diabetes	Donate after delivery		
Pregnancy		Abnormal glucose tolerance	
Active infection		Obesity	Above 35 kg/m ² (body mass index); may require weight loss
		Malignancy	No evidence of disease
		Hepatitis	
		Tuberculosis	
		Psychiatric disease	
		Chronic nephrotoxic drugs	
		Kidney stone history	Metabolic workup, 24 hr urine studies, and CT scan

Abbreviation: CT, computed tomography.

supply kidneys for older end-stage renal failure patients. Laparoscopic renal donation by elderly donors has been shown to be safe and efficacious (102), and an elderly source may alleviate some of the pressure on the younger generation.

Obesity

Obese donors present technical challenges. Jacobs et al. reported that markedly obese patients required longer operative times (approximately 40 minutes) when compared to nonobese donors (101). Obese donors are also more likely to require conversion to open surgical nephrectomy. Chow et al. (56) have recommended using the hand-assisted technique with a paramedian hand port as an alternative to standard laparoscopic donor nephrectomy in the obese donor.

There is no difference in recipient graft function when received from obese donors. However, the future health and well-being of obese donors is a real concern due to the significant risk factor for future diabetes and hypertension. The long-term health and renal function of obese donors with a solitary kidney is unknown.

However, because obesity becomes pandemic in some donor subgroups (e.g., African-American females), the inclusion of obese donors will be required to keep transplant programs functioning.

Renal Stones

Donors with stones or a history of stones require additional workup and considerations. First, the age of the donor must be considered. Young adults with stones or a history of stones are probably not good candidates for donation. In older adults, a history of stones may not necessarily disqualify them as donors.

Many remote stones were never well documented, and often, muscle skeletal pain is assigned the diagnosis of "kidney stone." Metabolic workup including serum studies and two random 24-hour urine studies are recommended. When metabolic studies are normal and imaging shows no evidence of stones, the donor evaluation should be continued. In older adults with a small, unilateral stone, the affected kidney may be taken in donation because the future risk of stones is very low.

Renal Cysts

Simple renal cysts are common in the older adult population and should not disqualify a donor. Complex cysts should be approached with caution, because some of these may, in fact, harbor a malignancy.

There is no difference in recipient graft function when received from obese donors. However, the future health and well-being of obese donors is a real concern due to the significant risk factor for future diabetes and hypertension. The long-term health and renal function of obese donors with a solitary kidney is unknown.

Young adults with stones or a history of stones are probably not good candidates for donation. In older adults, a history of stones may not necessarily disqualify them as donors.

Simple renal cysts are common in the older adult population and should not disqualify a donor. Complex cysts should be approached with caution, because some of these may, in fact, harbor a malignancy.

Potential donors with previous malignancy can still be donors. However, donor age, the type of malignancy, and the potential need for chemotherapy affect their candidacy.

With the fine-cut computed tomography scans currently in use, many patients are now being diagnosed with “too small to characterize” lesions. These are likely to represent simple cysts and should not disqualify the donor. In general, we advocate removing the kidney with the renal cyst. However, we tend to remove the left kidney if the cyst is a “too small to characterize” lesion on the right kidney. Patients with simple small bilateral cysts are not disqualified and the kidney with the largest cyst is chosen.

Malignancies

Potential donors with previous malignancy can still be donors. However, donor age, the type of malignancy, and the potential need for chemotherapy affect their candidacy.

Further, the malignancy must not adversely affect the recipient by transmission to the recipient (103). The risk of transferring malignancy from a donor with a history of common malignancies, such as localized prostate, skin, or colon cancer, is low. In general, the donor must be without any evidence of disease for at least 18 months prior to their donating.

Kidneys with small renal tumors (less than 3 cm) have been successfully transplanted into marginal recipients following excision of the renal tumor (104). No recipients have developed malignancy with a mean follow-up of 33 months.

Other Measures

A number of research developments or social changes may open up a larger number of potential living donors. These include bridging the problem of ABO-incompatible transplants (105,106) and evading the positive recipient–donor crossmatch by either recipient treatment (107–109) or paired exchanges (110,111). Paid renal donation (112–114), as is done in parts of the world, might profoundly alter the application of laparoscopic nephrectomy.

CURRENT STATUS OF LAPAROSCOPIC APPROACH

It has long been documented that grafts from living kidney donors show superior function and survival when compared to those from cadaver donors. Open donor nephrectomy has been performed successfully for nearly five decades with low rates of complications and graft loss. Donor nephrectomy is a unique surgery because the outcomes and complications affect both the donor and the recipient. Mis-steps that occur during the harvest may ultimately affect the donor and graft function. The initial laparoscopic experience did not meet the standards of the traditional open surgery technique. The University of Maryland and Johns Hopkins demonstrated an overall complication rate of 14.3% and 17%, respectively (9,75). The most common areas of initial concern, such as ureteral injury, vascular injury, and warm ischemia time, have diminished but not completely disappeared, with increased surgical experience.

Laparoscopic donor grafts have been shown over the short term to function as well as open donor grafts (10,115). Many centers have demonstrated good short-term follow-up of graft survival in kidneys procured with the laparoscopic techniques. Montgomery and coworkers report 94% graft function at five years (115). The jury is still out as regards how long these grafts will function. Living donation is a personal sacrifice for the donor. Therefore, every effort should be made to maximize long-term graft survival. In a large series of living donors from the University of Minnesota, risk factors for worse long-term recipient graft survival included pretransplant smoking, pretransplant peripheral vascular disease, pretransplant dialysis for more than one year, acute rejection episodes, and donor age over than 50 (116). Out of respect to the donor, detrimental factors in the recipient should be modified as much as possible.

Expansion of Laparoscopic Approach

Pain, extended hospitalization, time away from work, and long-term disability are barriers to potential donors. The laparoscopic approach provides potential donors with a minimally invasive alternative to open donor nephrectomy. Laparoscopic donor nephrectomy has definitely decreased hospitalization. The average hospital stay for 2339 standard transperitoneal donors reported has been 2.9 days. There is a clear difference between the United States and the rest of the world, where pressure for decreasing length of stay is not as strong. In the United States, transplant programs are even moving to 24-hour stays for donors (27).

In addition to decreasing convalescence, laparoscopic donor nephrectomy is associated with less blood loss when compared to open surgical techniques, though transfusion rates are probably indistinguishable from open surgery.

The introduction of laparoscopic donation has increased the number of donors at many transplant centers. By the year 2001, nearly two-thirds of the living donor nephrectomies in the United States were performed using a laparoscopic technique.

It is evident that the laparoscopic approach, while not perfect, has done well enough to be considered the first-choice approach for a majority of donors. However, laparoscopic donor nephrectomy is more expensive than open donor nephrectomy, as shown by Mullins et al. in a study evaluating the actual Medicare expenditures, which found that all transplantations were less expensive than dialysis in the long term.

Because laparoscopic nephrectomy is currently more commonly performed than the open technique, a potential problem for donor surgery in the future is the lack of open nephrectomy experience. Open surgical techniques and skills are essential for emergency conversions, and their lack thereof is a big concern.

The introduction of laparoscopic donation has increased the number of donors at many transplant centers (40,117). By the year 2001, nearly two-thirds of the living donor nephrectomies in the United States were performed using a laparoscopic technique (118).

At the University of Maryland, 925 laparoscopic donor nephrectomies have been performed from 1996 to 2004; over the same time frame, only 37 open donor nephrectomies have been performed (3.8%).

It is evident that the laparoscopic approach, while not perfect, has done well enough to be considered the first-choice approach for a majority of donors. However, laparoscopic donor nephrectomy is more expensive than open donor nephrectomy, as shown by Mullins et al. (119) in a study evaluating the actual Medicare expenditures, which found that all transplantations were less expensive than dialysis in the long term.

Cadaveric transplantation reaches a break-even point in costs over dialysis at 18 months posttransplant. Laparoscopic living donation reaches the break-even point at 14 months posttransplant. Open donor nephrectomy was most efficient costwise, reaching a break-even point at only 10 months posttransplant compared to dialysis. So, there is a dollar cost to the benefits of laparoscopy for the donors.

However, living donors are not always the best transplant option for all recipients. There are situations when a cadaver kidney may be better than one from a living donor. Mandal et al. suggest that a young cadaver kidney with fewer human leukocyte antigen mismatches may be better than an older living donor kidney (80).

International Experience

Laparoscopic donor nephrectomy has rapidly spread from its origins, largely in Maryland, throughout the United States. Moreover, it has grown rapidly on the international scene as well. Laparoscopic donor nephrectomy is being performed successfully in Europe, Asia, the Middle East, Australia, Africa, and South America. Laparoscopic donor nephrectomy is performed by urologists, transplant surgeons, or general surgeons.

Because laparoscopic nephrectomy is currently more commonly performed than the open technique, a potential problem for donor surgery in the future is the lack of open nephrectomy experience. Open surgical techniques and skills are essential for emergency conversions, and their lack thereof is a big concern.

SUMMARY

- The introduction of laparoscopic donation has increased the number of donors at many transplant centers. By the year 2001, nearly two-thirds of the living donor nephrectomies in the United States were performed using a laparoscopic technique.
- Laparoscopic donor nephrectomy requires much more skill and finesse than laparoscopic radical nephrectomy. There is no margin of error. Superb technique is absolutely essential for good donor outcome and recipient graft function.
- The laparoscopic approach, while not perfect, is considered the first-choice approach for the majority of donors.
- Good short-term follow-up of graft survival after laparoscopic donor nephrectomy has been demonstrated at many centers.
- During laparoscopic donor nephrectomy, the biggest risk to the donor is potential vascular catastrophe.
- Laparoscopic donor nephrectomy is associated with longer warm ischemia time when compared to open surgery. However, the duration of warm ischemia does not correlate with recipient creatinine levels or delayed graft function.
- Total operating time of laparoscopic donor nephrectomy is comparable to that of open surgery, whereas blood loss and hospitalization are decreased.
- The laparoscopic approach is more expensive than open donor nephrectomy.

REFERENCES

1. Clayman RV, Kavoussi LR, Soper NJ, et al. Laparoscopic nephrectomy: initial case report. *J Urol* 1991; 146:278–282.
2. Gill IS, Carbone JM, Clayman RV, et al. Laparoscopic live donor nephrectomy. *J Endourol* 1994; 8:143–148.
3. Ratner LE, Ciseck LJ, Moore RG, Cigarroa FG, Kaufman HS, Kavoussi LR. Laparoscopic live donor nephrectomy. *Transplantation* 1995; 60:1047–1049.

4. Stroom SB, Novick AC, Steinmuller DR, et al. Flank donor nephrectomy: efficacy in the donor and recipient. *J Urol* 1989; 141:1099–1101.
5. Bay WH, Herbert LA. The living kidney donor in kidney transplantation. *Ann Intern Med* 1987; 106:719–723.
6. Demarco T, Amin M, Harty JL. Living donor nephrectomy: factors influencing morbidity. *J Urol* 1982; 127:1082–1083.
7. Weinstein SH, Navarre RJ, Loening SA, et al. Experience with live donor nephrectomy. *J Urol* 1980; 124:321–323.
8. Shaffer D, Sahyoun AI, Madras PN, et al. Two hundred one consecutive living donor nephrectomies. *Arch Surg* 1998; 133:426–431.
9. Flowers JL, Jacobs SC, Cho E, et al. Comparison of open and laparoscopic live donor nephrectomy. *Ann Surg* 1997; 226:483–489.
10. Jacobs SC, Cho E, Foster C, et al. Laparoscopic donor nephrectomy: The University of Maryland 6-year experience. *J Urol* 2004; 171:47–51.
11. Abrahams HM, Freise CE, Kang S-M, Stoller ML, Meng MV. Technique, indications and outcomes of pure laparoscopic right donor nephrectomy. *J Urol* 2004; 171:1793–1796.
12. Posselt AM, Mahanty H, Kang S-M, et al. Pure laparoscopic right donor nephrectomy: a large single center experience. *Transplantation* 2004; 78(11):1665–1669.
13. Abrahams HM, Meng MV, Freise CE, Stoller ML. Pure laparoscopic right donor nephrectomy: step-by-step approach. *J Endourol* 2004; 18:221–225.
14. Su LM, Ratner LE, Montgomery RA, et al. Laparoscopic live donor nephrectomy: trends in donor and recipient morbidity following 381 consecutive cases. *Ann Surg* 2004; 240:358–363.
15. Hazebroek EJ, Gommers D, Schreve MA, et al. Impact of intraoperative donor management on short-term renal function after laparoscopic donor nephrectomy. *Ann Surg* 2002; 236:127–132.
16. Sasaki T, Finelli F, Barhyte D, Trollinger J, Light J. Is laparoscopic donor nephrectomy here to stay? *Am J Surg* 1999; 177:368–370.
17. Sasaki TM, Finelli F, Bugarin E, et al. Is laparoscopic donor nephrectomy the new criterion standard? *Arch Surg* 2000; 135(8):943–947.
18. Rawlins MC, Hefty TL, Brown SL, Biehl TR. Learning laparoscopic donor nephrectomy safely: a report on 100 cases. *Arch Surg* 2002; 137:531–535.
19. Siqueira RM Jr, Kuo RL, Gardner TA, et al. Major complications in 213 laparoscopic nephrectomy cases: the Indianapolis experience. *J Urol* 2002; 168:1361–1365.
20. Lventhal JR, Decik BK, Joehl RJ, et al. Laparoscopic live donor nephrectomy—is it safe? *Transplantation* 2000; 70:602–606.
21. Troppmann C, Wiesmann K, McVicar JP, Wolfe BM, Perez RV. Increased transplantation of kidneys with multiple renal arteries in the laparoscopic live donor nephrectomy era: surgical technique and surgical and nonsurgical donor and recipient outcomes. *Arch Surg* 2001; 136:897–907.
22. Troppmann C, Pierce JL, Wiesmann KM, et al. Early and late recipient graft function and donor outcome after laparoscopic vs open adult live donor nephrectomy for pediatric renal transplantation. *Arch Surg* 2002; 137:908–916.
23. London E, Rudich S, McVicar J, Wolfe B, Perez R. Equivalent renal allograft function with laparoscopic versus open live donor nephrectomies. *Transplant Proc* 1999; 31:258–260.
24. Kumar A, Chaudhary H, Srivastava A, Raghavendran M. Laparoscopic live-donor nephrectomy: modifications for developing nations. *BJU Int* 2004; 93:1291–1295.
25. Ramani AP, Gill IS, Steinberg AP, et al. Impact of intraoperative heparin on laparoscopic donor nephrectomy. *J Urol*. In 2005; 174(1):226–228.
26. Reddy KS, Mastrangelo M, Johnston T, et al. Recipient outcome following living donor kidney transplantation using kidneys procured laparoscopically. *Clin Transplant* 2003; 17(suppl 9):44–47.
27. Kuo PC, Johnson LB, Sitzmann JV. Laparoscopic donor nephrectomy with a 23-hour stay: a new standard for transplantation surgery. *Ann Surg* 2000; 231:772–779.
28. Giessing M, Deger S, Ebeling V, et al. Laparoscopic living donor nephrectomy of kidneys with multiple renal vessels. *Urologe* 2003; 42:225–232.
29. Giessing M, Slowinski T, Deger S, et al. Living donor nephrectomy—no impact of genetic relationship. *Transplant Proc* 2003; 35:2860–2862.
30. Giessing M, Deger S, Schonberger B, Turk I, Loening SA. Laparoscopic living donor nephrectomy: from alternative to standard procedure. *Transplant Proc* 2003; 35:2093–2095.
31. Berends FJ, den Hoed PT, Bonjer HJ, et al. Technical considerations and pitfalls in laparoscopic live donor nephrectomy. *Surg Endosc* 2002; 16:893–898.
32. Khauli RB, Hussein M, Shaar A, et al. A prospective evaluation of laparoscopic donor nephrectomy versus open donor nephrectomy. *Transplant Proc* 2003; 35:2552.
33. Simforoosh N, Bassiri A, Ziaee SA, et al. Laparoscopic versus open live donor nephrectomy: the first randomized clinical trial. *Transplant Proc* 2003; 35:2553–2554.
34. Biancospino G, Amoroso G, Lugli D, et al. Perioperative management for laparoscopic kidney donation. *Minerva Anestesiol* 2003; 69:681–689.
35. Muthu C, McCall J, Windsor J, et al. The Auckland experience with laparoscopic donor nephrectomy. *NZ Med J* 2003; 116:1178.
36. Hawasli A, Boutt A, Cousins G, Schervish E, Oh H. Laparoscopic versus conventional live donor nephrectomy: experience in a community transplant program. *Am Surg* 2001; 67:342–345.
37. Perry KT, Freedland SJ, Hu JC, et al. Quality of life, pain and return to normal activities following laparoscopic donor nephrectomy versus open mini-incision donor nephrectomy. *J Urol* 2003; 169:2018–2021.
38. Hood N, Young CJ, Deierhoi M, Urban DA. Donor nephrectomy: a comparison of techniques and results of open, hand assisted and full laparoscopic nephrectomy. *J Urol* 2004; 171:40–43.
39. Odland MD, Ney AL, Jacobs DM, et al. Initial experience with laparoscopic live donor nephrectomy. *Surgery* 1999; 126:603–606.

40. Shafizadeh S, McEvoy JR, Murray C, et al. Laparoscopic donor nephrectomy: impact on an established renal transplant program. *Am Surg* 2000; 66:1132–1135.
41. Ostraat O, Lonnroth H, Olausson M, Blohme I. Experience with laparoscopic donor nephrectomy at a European transplant centre. *Transpl Int* 2000; 13(suppl 1):S253–S254.
42. Duchene DA, Johnson DB, Li S, Roden JS, Sagalowsky AI, Cadeddu JA. Laparoscopic donor nephrectomy at a low volume living donor transplant center: successful outcomes can be expected. *J Urol* 2003; 170:731–733.
43. Bettschart V, Boubaker A, Martinet O, Golshayan D, Wauters JP, Mosimann F. Laparoscopic right nephrectomy for live kidney donation: functional results. *Transplant Int* 2003; 16:419–424.
44. Hensman C, Lionel G, Hewett P, Rao M. Laparoscopic live donor nephrectomy: the preliminary experience. *ANZ J Surg* 1999; 69:365–368.
45. Kercher KW, Joels CS, Matthews BD, Lincourt AE, Smith TI, Heniford BT. Hand-assisted surgery improves outcomes for laparoscopic nephrectomy. *Am Surg* 2003; 69:1061–1066.
46. Kercher K, Dahl D, Harland R, Blute R, Gallaher K, Litwin D. Hand-assisted laparoscopic donor nephrectomy using the handport device minimizes warm ischemia. *Urology* 2000; 58:152–156.
47. Velidedeoglu E, Williams N, Brayman KL, et al. Comparison of open, laparoscopic, and hand-assisted approaches to live-donor nephrectomy. *Transplantation* 2002; 74(2):169–172.
48. Gershbein AB, Fuchs GJ. Hand-assisted and conventional laparoscopic live donor nephrectomy: a comparison of two contemporary techniques. *J Endourol* 2002; 16:509–513.
49. Ruiz-Deya G, Cheng S, Palmer E, Thomas R, Slakey D. Open donor, laparoscopic donor and hand assisted laparoscopic donor nephrectomy: a comparison of outcomes. *J Urol* 2001; 166:1270–1274.
50. Mateo RB, Sher L, Jabbour N, et al. Comparison of outcomes in noncomplicated and in higher-risk donors after standard versus hand-assisted laparoscopic nephrectomy. *Am Surg* 2003; 69:771–778.
51. El-Galley R, Hood N, Young CJ, Deierhoi M, Urban DA. Donor nephrectomy: a comparison of techniques and results of open, hand assisted and full laparoscopic nephrectomy. *J Urol* 2004; 171:40–43.
52. Sundqvist P, Feuk U, Haggman M, Persson AE, Stridsberg M, Wadstrom J. Hand-assisted retroperitoneoscopic live donor nephrectomy in comparison to open and laparoscopic procedures: a prospective study on donor morbidity and kidney function. *Transplantation* 2004; 78:147–153.
53. Hollenbeck BK, Seifman BD, Wolf JS Jr. Clinical skills acquisition for hand-assisted laparoscopic donor nephrectomy. *J Urol* 2004; 171:35–39.
54. Wolf JS Jr, Merion RM, Leichtman AB, et al. Randomized controlled trial of hand-assisted laparoscopic versus open surgical live donor nephrectomy. *Transplantation* 2001; 72:284–290.
55. Simon SD, Castle EP, Ferrigni RG, et al. Complications of laparoscopic nephrectomy: the Mayo Clinic experience. *J Urol* 2004; 171:1447–1450.
56. Chow GK, Prieto M, Bohorquez HE, Stegall D. Hand-assisted laparoscopic donor nephrectomy for morbidly obese patients. *Transplant Proc* 2002; 34:728.
57. Oh HK, Hawasli A, Cousins G. Management of renal allografts with multiple renal arteries resulting from laparoscopic living donor nephrectomy. *Clin Transplant* 2003; 17:353–357.
58. Balm R, Surachno S, Bemelman WA. Hand-assisted laparoscopic live donor nephrectomy. *Br J Surg* 2004; 91:344–348.
59. Boorjian S, Munver R, Sosa RE, Del Pizzo JJ. Right laparoscopic live donor nephrectomy: a single institution experience. *Transplantation* 2004; 77:437–440.
60. Stifelman MD, Hull D, Sosa RE, et al. Hand assisted laparoscopic donor nephrectomy: a comparison with the open approach. *J Urol* 2001; 166:444–448.
61. Salazar A, Yilmaz S, Monroy M, Sepandj F, Tibbles L, McLaughlin K. Title laparoscopic hand-assisted living donor nephrectomy: the Calgary experience. *Transplant Proc* 2003; 35:2403–2404.
62. Deorah S, Rayhill SC, Nguyen TT, Katz DA, Winfield HN. Laparoscopic vs. open right living donor nephrectomy: a comparative study. *J Urol*. In press.
63. Johnson MW, Andreoni K, McCoy L, et al. Technique of right laparoscopic donor nephrectomy: a single center experience. *Am J Transplant* 2001; 1:293–295.
64. Bachmann A, Dickenmann M, Gurke L, et al. Retroperitoneoscopic living donor nephrectomy: a retrospective comparison to the open approach. *Transplantation* 2004; 78:168–171.
65. Sulser T, Gurke L, Langer I, et al. Retroperitoneoscopic living-donor nephrectomy: first clinical experiences in 19 operations. *J Endourol* 2004; 18:257–262.
66. Tanabe K, Miyamoto N, Ishida H, et al. Retroperitoneoscopic live donor nephrectomy (RPLDN): establishment and initial experience of RPLDN at a single center. *Am J Transplant*. 2005; 5(4 Pt1): 739–45.
67. Rassweiler JJ, Wiesel M, Carl S, Drehmer I, Jurgowski W, Staehler G. Laparoscopic liver donor nephrectomy. Personal experiences and review of the literature. *Urologe* 2001; 40:485–492.
68. Gill IS, Uzzo RG, Hobart MG, Stroom SB, Goldfarb DA, Noble MJ. Laparoscopic retroperitoneal live donor right nephrectomy for purposes of allotransplantation and autotransplantation. *J Urol* 2000; 164:1500–1504.
69. Harman PK, Kron IL, McLachlan HD, et al. Elevated intra-abdominal pressure and renal function. *Ann Surg* 1982; 196:594.
70. London E, Neuhaus A, Ho H, et al. Beneficial effect of volume expansion on the altered renal hemodynamics of prolonged pneumoperitoneum. Presented at the 24th Annual Scientific Meeting of the American Society of Transplant Surgeons, Chicago, IL, May 1998.
71. Kirsch AJ, Kayton ML, Henske TW, et al. Renal effects of CO₂ insufflation: oliguria and acute renal dysfunction in a rat pneumoperitoneum model. *Urology* 1994; 43:453.
72. Buzdon MM, Cho E, Jacobs SC, Jarrell B, Flowers JL. Warm ischemia time does not correlate with recipient graft function in laparoscopic donor nephrectomy. *Surg Endosc* 2003; 17:746–749.
73. Opelz G. Cadaver kidney graft outcome in relation to ischemic time and HLA match. *Transplant Proc* 1998; 30:4294–4296.
74. Philosophie B, Kuo PC, Schweitzer EJ, et al. Laparoscopic versus open donor nephrectomy: comparing ureteral complications. *Transplantation* 1999; 68:497–502.

75. Montgomery RA, Kavoussi LR, Su LM, et al. Improved recipient results after 5 years of performing laparoscopic donor nephrectomy. *Transplant Proc* 2001; 33:1108–1110.
76. Dunkin BJ, Johnson LB, Kuo PC. A technical modification eliminates early ureteral complications after laparoscopic donor nephrectomy. *J Am Coll Surg* 2000; 190:96–97.
77. Murray JE, Harrison JH. Surgical management of fifty patients with kidney transplants including eighteen pairs of twins. *Am J Surg* 1963; 105:205.
78. Barry JM. Editorial: Living donor nephrectomy. *J Urol* 2004; 171:61–62.
79. Buell JF, Edye M, Johnson, et al. Are concerns over right laparoscopic donor nephrectomy unwarranted? *Ann Surg* 2001; 233:645–651.
80. Mandal AK, Cohen C, Montgomery RA, et al. Should the indication for laparoscopic live donor nephrectomy of the right be the same as for the open procedure? Anomalous left renal vasculature is not a contraindication to laparoscopic left donor nephrectomy. *Transplantation* 2001; 71:660–664.
81. Arenas J, Gupta M, et al. Initial program experience with right laparoscopic donor nephrectomy. *Transplantation* 2000; 69:S335.
82. Jacobs SC, Cho E, Dunkin BJ, et al. Laparoscopic live donor nephrectomy: the University of Maryland 3 year experience. *J Urol* 2000; 164:1494–1499.
83. Lind MY, Ijzermans JNM, Bonjer HJ. Open vs laparoscopic donor nephrectomy in renal transplantation. *BJU Int* 2002; 89:162–168.
84. Buell JF, Abreu SC, Hanaway MJ, et al. Right donor nephrectomy: a comparison of hand-assisted transperitoneal and retroperitoneal approaches. *Transplantation* 2004; 77:521–525.
85. Slakey DP, Wood JC, Hender D, et al. Laparoscopic living donor nephrectomy. Advantages of the hand-assisted method. *Transplantation* 1999; 68:581–583.
86. Turk IA, Deger S, Davies JW, et al. Laparoscopic live donor right nephrectomy: a new technique with preservation of vascular length. *J Urol* 2002; 167:630–633.
87. Vastag B. Living-donor transplants reexamined. *JAMA* 2003; 290:181–182.
88. Fruhwirth J, Koch G, Mischinger H, et al. Vascular complication in minimally invasive surgery. *Surg Laparosc Endosc* 1997; 7:251.
89. Roviato GC, Varoli F, Vergani C, et al. Major vascular injuries in laparoscopic surgery. *Surg Endosc* 2002; 16:1192–1196.
90. Gill I, Kavoussi LR, Clayman, et al. Complications of laparoscopic nephrectomy in 185 patients: a multi-institutional review. *J Urol* 1995; 154:479.
91. Chan D, Bischoff JT, Ratner LR, Kavoussi LR, Jarrett T. Endovascular gastrointestinal stapler device malfunction during laparoscopic nephrectomy: early recognition and management. *J Urol* 2000; 164:319–321.
92. Gill IS, Rassweiler JJ. Retroperitoneoscopic renal surgery: our approach. *Urology* 1999; 54:734–738.
93. Tanabe K, Miyamoto N, Ishida H, et al. Excellent renal function obtained by retroperitoneoscopic live donor nephrectomy under low CO₂ gas pressure. *Am J Transplant*. In press.
94. Rudich SM, Marcovich R, Magee JD, et al. Hand-assisted laparoscopic donor nephrectomy: comparable donor/recipient outcomes, costs and decreased convalescence as compared to open donor nephrectomy. *Transplant Proc* 2001; 33:1106–1107.
95. Wolf JS, Moon TD, Nakada SY, et al. Hand assisted laparoscopic nephrectomy. *J Urol* 1998; 160:22–27.
96. Janoff DM, Davol P, Hazzard J, et al. Computerized tomography with 3-dimensional reconstruction for the evaluation of renal size and arterial anatomy in the living kidney donor. *J Urol* 2004; 171:27–30.
97. Del Pizzo T, Sklar G, You-Cheong, et al. Helical computerized tomography arteriography for evaluation of live donors undergoing laparoscopic nephrectomy. *J Urol* 1999; 162:31.
98. Cochran T, Krasny RM, Danovitch GM, et al. Helical computerized tomography angiography for examination of living renal donors. *Am J Roentgenol* 1997; 168:1569.
99. Gridelli B, Remuzzi G. Current concepts: strategies for making more organs available for transplantation. *New Engl J Med* 2000; 343:404–410.
100. Farney AC, Cho E, Schweitzer EJ, et al. Simultaneous cadaver pancreas-living donor kidney transplantation (SPLK): a new approach for the type 1 diabetic uremic patient. *Ann Surg* 2000; 232:696–703.
101. Jacobs SC, Cho E, Dunkin BJ, Jarrell B, Bartlett T, Jacobs SC. Laparoscopic nephrectomy in the markedly obese renal donor. *Urology* 2000; 56:926–929.
102. Jacobs SC, Ramey JR, Sklar GN, Bartlett ST. Laparoscopic kidney donation from patients older than 60 years. *J Am Coll Surg* 2004; 198:892–897.
103. Kaufman HM, McBride MA, Cherikh WS, Spain PC, Marks WH, Roza AM. Transplant tumor registry: donor related malignancies. *Transplantation* 2002; 74:358–362.
104. Nicol D, Preston JM, Griffin AG, et al. Kidneys from patients with small renal tumors- a novel donor source. Presented at American Urology Association Meeting, San Francisco, 2004.
105. Sorensen JB, Grant WJ, Blenap LP, et al. Transplantation of ABO group A2 kidneys from living donors into group O and B recipients. *Am J Transplant* 2001; 1:296–299.
106. Gloor JM, Lager DJ, Moore LS, et al. ABO-incompatible kidney transplantation using both A and non-A donors. *Transplantation* 2003; 75:971–977.
107. Schweitzer EJ, Wilson J, Fernandez-Vina M, et al. A high panel reactive antibody rescue protocol for cross-match positive live donor kidney transplants. *Transplantation* 2003; 70:1531–1537.
108. Zachary AA, Montgomery RA, Ratner LE, et al. Specific and durable elimination of the antibody to donor HLA antigens in renal transplant patients. *Transplantation* 2003; 76:1519–1525.
109. Sonnenday CJ, Ratner LE, Zachary. Preemptive therapy with plasmapheresis/intravenous immunoglobulin allows successful live donor renal transplantation in patients with a positive cross-match. *Transplant Proc* 2002; 34:1614–1616.
110. Park K, Moon JI, Kim YS. Exchange donor program in kidney transplantation. *Transplantation* 1999; 67:336–338.

111. Zenios SA, Woodle ES, Ross LF. Primum non nocere: avoiding harm to vulnerable wait list candidates in an indirect kidney exchange. *Transplantation* 2001; 72:648–654.
112. Zargooshi J. Iranian kidney donors: motivations and relations with recipients. *J Urol* 2001;386–392.
113. Living Non Related Renal Transplant study group. Commercially motivated renal transplantation: results in 540 patients transplanted in India. *Clin Transplant* 1997; 11:536–544.
114. Thiagarajan CM, Reddy KC, Shunmugasundaram, et al. The practice of unconventional renal transplantation (VCRT) at a single center in India. *Transplant Proc* 1990; 22:912.
115. Ratner R, Montgomery R, Maley W, et al. Laparoscopic live donor nephrectomy: the recipient. *Transplantation* 2000; 69:2319–2323.
116. Mates AJ, Payne WD, Sutherland DE, et al. 2500 living donor kidney transplants: a single-center experience. *Ann Surg* 2001; 234:149–164.
117. Schweitzer EJ, Wilson J, Jacobs SC, et al. Increased rates of donation with laparoscopic donor nephrectomy. *Ann Surg* 2000; 232:392–400.
118. Cecka JM. The United Network for Organ Sharing renal transplant registry. In: Cecka JM, Terasaki PI, eds. *Clinical Transplants* 2002. Los Angeles: UCLA Immunogenetics Center, 2003:14.
119. Mullins CD, Thomas SK, Pradel FG, Bartlett ST. The economic impact of laparoscopic living-donor nephrectomy on kidney transplantation. *Transplantation* 2003; 75:1505–1512.

COMMENTARY

John M. Barry

Division of Urology and Renal Transplantation, The Oregon Health & Science University, Portland, Oregon, U.S.A.

Laparoscopic donor nephrectomy is a remarkable technical achievement. This chapter traces the evolution of the technique in the center with the world's largest experience. As the authors correctly state, in order for laparoscopic donor nephrectomy to gain wide acceptance, it had to meet the standards set by open nephrectomy. It has come close.

Warm ischemia time continues to be a bit longer than that reported for open donor nephrectomy, simply because of the extraction procedure, which includes, in some cases, resection of staple lines on the renal artery and renal vein so that the kidney graft can be flushed with ice-cold preservation solution. The citation that reportedly showed that there was not a strong correlation between warm ischemia time and long-term graft function for first cadaver kidney transplants is a bit misleading because the warm ischemia times greater than 20 minutes seem to have been confused with reanastomosis or rewarm times (1). In that reference, five-year first cadaver kidney graft survival rates were appropriately decreased in a step-wise fashion from 66% to 59% when warm ischemia times increased from 0 to 20 minutes; however, five-year corresponding kidney graft survival rates when warm ischemia times increased from 21 to 40 minutes were 66% and 61%, respectively.

Although many single-center studies that compared laparoscopic donor nephrectomy with open donor nephrectomy reported similar short- and intermediate-term results for both techniques, the United Network for Organ Sharing (United Network for Organ Sharing) registry reported poorer graft survivals by 3% at three years and reduced kidney transplant half-life projections by 2.1 years for laparoscopically retrieved kidney transplants when compared with kidney grafts removed by an open flank approach (2).

The preponderance of laparoscopic left donor nephrectomies suggests that the principle of leaving the better kidney with the donor (3) has been compromised because of the more favorable anatomy of the left kidney. The more normal kidney should be left with the donor and, in the case of women who may become pregnant and who otherwise have two equivalent kidneys, we think the right kidney should be used because pyelonephritis and hydronephrosis of pregnancy are more common in that kidney (4).

As the authors state, laparoscopic donor nephrectomy has become routine for kidneys with multiple renal arteries, and it has been reported that heparinization of the laparoscopic kidney donor is unnecessary (5).

The problem of short donor renal vessels in the laparoscopically retrieved organs has been lessened by the complete mobilization of the pelvic vessels in the recipient to allow anterior displacement of the vascular targets.

Although laparoscopic donor nephrectomy teams have apparently solved the technical problems associated with donor obesity, this donor source should be used with caution because obesity has been shown to put these uninephrectomized patients at risk for subsequent proteinuria and chronic renal failure (6).

The more rapid recovery of the patient from laparoscopic donor nephrectomy has made living donor nephrectomy more acceptable to donors and recipients, the latter because there is less guilt associated with what is perceived by the recipient to be a lesser procedure for a donor who undergoes the laparoscopic procedure.

To the authors I say, "Well done, but please leave the better kidney with the donor, and do not take kidneys from donors who are at risk for developing proteinuria and/or renal failure in the years following donation."

REFERENCES

1. Opelz G. Cadaver kidney graft outcome in relation to ischemia time and HLA match. *Transplant Proc* 1998; 30:4294.
2. Cecka JM. The United Network for Organ Sharing Renal Transplant Registry. In: Cecka JM, Terasaki PI, eds. *Clinical Transplants 2002*. Los Angeles: UCLA Immunogenetics Center, 2003:16.
3. Murray JE, Harrison JH. Surgical management of fifty patients with kidney transplants including eighteen pairs of twins. *Am J Surg* 1963; 105:205.
4. Monga M. Maternal cardiovascular and renal adaptation to pregnancy. In: Creasy RK, Resnik R, eds. *Maternal Fetal Medicine*. 4th ed. Philadelphia: W.B. Saunders, 1998:787-788.
5. Steinberg A, Ramani AP, Abren SC, et al. Is intraoperative heparin necessary during laparoscopic donor nephrectomy? *J Urol* 2004; 171(4 suppl):515.
6. Praga M, Hernandez E, Herrero JC, et al. Influence of obesity on the appearance of proteinuria and renal insufficiency after unilateral nephrectomy. *Kidney Int* 2000; 58:2111.

LAPAROSCOPIC URETERAL SURGERY: NONCALCULOUS APPLICATIONS

Thomas H. S. Hsu and Keith L. Lee

Department of Urology, Stanford University Medical Center, Stanford University School of Medicine, Stanford, California, U.S.A.

- | | |
|---------------------------------------|--------------------------|
| ■ INTRODUCTION | ■ CUTANEOUS URETEROSTOMY |
| ■ RETROCAVAL URETER | ■ URETERONEOCYSTOSTOMY |
| ■ IDIOPATHIC RETROPERITONEAL FIBROSIS | ■ SUMMARY |
| ■ TRANSURETEROURETEROSTOMY | ■ REFERENCES |

INTRODUCTION

With most published data based on case reports and small case series, utilization of laparoscopy for noncalculous ureteral surgery remains in its infancy. However, as the urologic community's experience with laparoscopy grows, a dramatic increase in laparoscopic applications to the ureter is likely to be seen in the next decade. The principles of surgical approaches to the retrocaval ureter, idiopathic retroperitoneal fibrosis, transuretero-ureterostomy, cutaneous ureterostomy, and ureteroneocystostomy in adults are discussed in this chapter.

Persistence of the lumbar segment of the subcardinal vein beyond early development results in the formation of the retrocaval ureter (also known as the circumcaval ureter or preureteral vena cava).

RETROCAVAL URETER

Persistence of the lumbar segment of the subcardinal vein beyond early development results in the formation of the retrocaval ureter (also known as the circumcaval ureter or preureteral vena cava).

Anatomically, the right ureter is affected, and the retrocaval segment is located dorsal to the vena cava as it travels down from the kidney to the bladder. The retrocaval ureter can either encircle the cava by crossing it ventrally from medial to lateral before reaching the bladder or simply lie dorsal to the cava for a segment without wrapping around the cava completely and end in the bladder distally. In both anatomic forms, the retrocaval ureteral segment is susceptible to proximal urinary obstruction as the ureter takes this tortuous "reverse-J" or "S-shaped" course down to the bladder. When obstructive symptoms of flank pain or renal parenchymal loss develop, surgical repair is indicated.

The principles of repair with the laparoscopic approach are similar to those of open surgery. The retrocaval ureteral segment has to be mobilized to a location anterior and lateral to the cava. When the ureter encircles the cava, dismemberment with reanastomosis is needed. When the ureter does not encircle the cava, a simple ureterolysis may be sufficient.

Baba et al. first reported the transperitoneal laparoscopic management of the retrocaval ureter in 1994 (1). Their success was subsequently confirmed by several other investigators (2,3). In the typical transperitoneal approach, cystoscopy is first performed with placement of a double J-stent in the ureter (1-3). The patient is then placed in a right lateral position with 45 to 70 degree of table-tilt to allow the ascending colon to fall away from the operative field. The camera port is usually placed at the umbilicus, and three working ports are placed at the ipsilateral mid-clavicular line subcostally, at the iliac fossa, and in the ipsilateral flank. The last port at the flank may be optional depending on the patient's anatomy (4). Following successful trocar placement and establishment of pneumoperitoneum, the white line of Toldt is incised, and the ascending colon is mobilized and reflected medially. Upon entering the retroperitoneum, the ureter is mobilized with sharp and blunt dissection. Once mobilized, the ureter is transected just distal to the obstructive, circumcaval segment, and the ureteral catheter is withdrawn distally. If stenotic, the retrocaval segment is then

The principles of repair with the laparoscopic approach are similar to those of open surgery. The retrocaval ureteral segment has to be mobilized to a location anterior and lateral to the cava. When the ureter encircles the cava, dismemberment with reanastomosis is needed. When the ureter does not encircle the cava, a simple ureterolysis may be sufficient.

excised, and the distal ureteral stump may be spatulated prior to reanastomosis to the proximal ureteral segment. In cases where the retrocaval ureteral segment cannot be freed easily from the cava, it can be left in situ after dividing the ureter both proximally and distally to this segment. The proximal and distal ureteral ends are then brought anterior and lateral to the cava for reanastomosis with interrupted absorbable sutures over the ureteral stent. In the end, a closed suction drain is placed in the retroperitoneal space, and a Foley catheter is left in the bladder for one to two days after surgery.

The retroperitoneoscopic approach has also been used by several investigators with success (5–8). The patient is similarly placed in a modified flank position with a more exaggerated table-tilt. The surgical approach to ureterolysis, ureteral transection and reanastomosis to create a more anterolateral position for the ureter is similar to that for the transabdominal approach.

The advantage of retroperitoneoscopic approach compared to the transperitoneal method is that bowel mobilization is minimized. In addition, the retroperitoneal approach avoids urinary spillage into the peritoneum, which may reduce the risk of subsequent intraperitoneal adhesion formation. The main disadvantages include limited working space (9).

The first reported cases on laparoscopic surgical management of retrocaval ureter took 9.3 hours with the end-to-end ureteral anastomosis requiring almost 2.5 hours. The authors found that laparoscopic suturing of the anastomosis was the most difficult part of the operation (1). Despite the long operative duration, the patient's recovery was uneventful, and he did not require any analgesics postoperatively. Although not commented on specifically, the patient remained in the hospital until postoperative day 9 and subsequent convalescence was "brief."

With refinement in laparoscopic techniques, experience, and perioperative management, operative times have decreased in contemporary cases to 3.5 to 4.1 hours with the transperitoneal approach (2,4,9), and to 3.5 to 4.5 hours with the retroperitoneal approach (5,6). In either approach, patients do remarkably well after surgery with minimal postoperative pain and short convalescence. Ramalingam and Selvarajan and Gupta et al. reported the use of only nonopiate analgesics after surgery (2,5); while Polascik and Chen found that analgesics were not required beyond postoperative day one (4). Operative blood loss is insignificant in these cases, and patients now stay two to five days after surgery. The ureteral stent may be removed at four to eight weeks depending on the surgeon's preference, and follow-up nuclear drainage studies may be obtained afterwards to evaluate drainage.

Given the small number of cases reported in the literature and bias from case selection and the surgeon's experience, it is difficult to compare the transperitoneal approach to the retroperitoneal approach critically.

In the hands of experienced surgeons, operative time today is approximately four hours. Both approaches are well tolerated by patients with minimal blood loss and little need for postoperative analgesic beyond several days. Most investigators report a short convalescence, and patients are back to work in one to two weeks.

IDIOPATHIC RETROPERITONEAL FIBROSIS

Idiopathic retroperitoneal fibrosis is a chronic inflammatory process that comes to urologic attention when extrinsic compression and encasement of the ureter by surrounding retroperitoneal tissues cause ureteral obstruction. The progressive nature of the inflammatory process can lead to flank pain and renal deterioration. Radiographic findings on intravenous pyelogram or retrograde pyelogram may include medial deviation of the involved ureter and the absence of intraluminal obstruction. Whitaker test as well as nuclear functional studies often demonstrates delayed drainage as a result of extrinsic ureteral compression. Causes of retroperitoneal fibrosis are myriad and include inflammatory bowel disease, vascular aneurysms, radiation, malignancies, retroperitoneal bleeding, and idiopathic, which accounts for the majority of cases.

The laparoscopic approach to the idiopathic retroperitoneal fibrosis ureter remains challenging with only a few cases described in the literature (10–14).

The principles of the laparoscopic approach include biopsy of the retroperitoneal tissues for histologic diagnosis and complete ureterolysis.

First reported by Kavoussi et al. in 1992, laparoscopic dissection and mobilization of the entrapped ureter are feasible but can be technically challenging (10). The extent of retroperitoneal fibrosis often determines the level of technical difficulty, as

The advantage of retroperitoneoscopic approach compared to the transperitoneal method is that bowel mobilization is minimized. In addition, the retroperitoneal approach avoids urinary spillage into the peritoneum, which may reduce the risk of subsequent intraperitoneal adhesion formation. The main disadvantages include limited working space.

Given the small number of cases reported in the literature and bias from case selection and the surgeon's experience, it is difficult to compare the transperitoneal approach to the retroperitoneal approach critically.

The principles of the laparoscopic approach include biopsy of the retroperitoneal tissues for histologic diagnosis and complete ureterolysis.

longer affected ureteral segments (≥ 5 cm) require longer operative time than shorter ones (≤ 2 cm) (11).

The laparoscopic surgical approach to idiopathic retroperitoneal fibrosis is similar to that used for the retrocaval ureter (1–4,10,11). After the placement of a ureteral stent, the patient is typically placed in a modified flank position (10,11). The laparoscopic camera port can be placed along the anterior axillary line 2 cm above the umbilicus. Typically three other working ports are needed on the ipsilateral side: one port along the mid-clavicular line at 2 to 3 cm below the costal margin, one at the level of the umbilicus, and one at 2 to 3 cm above the anterior superior iliac spine. In cases where both ureters are affected and require surgical mobilization, additional ports are placed in the corresponding locations on the contralateral abdomen. In more difficult cases, surgical management of the second ureter can be performed in a staged manner (12).

Following mobilization of the colon, a biopsy of the retroperitoneal fibrotic tissue is first taken for diagnostic purposes. Then ureterolysis can be initiated either near the renal hilum or below the iliac vessels, the two locations where the ureter is typically not involved with the fibrotic process. Using blunt and sharp dissection techniques, the ureter is mobilized circumferentially. Use of a vessel loop or Penrose drain around the freed portion of the ureter can provide needed traction and facilitate dissection. Once ureteral mobilization is complete, the ureter is retracted anteriolaterally into the peritoneal cavity. The parietal peritoneum is reapproximated with sutures or clips to close the retroperitoneal defect, and normal intraperitoneal fatty tissue or the greater omentum can be interposed between the ureter and the retroperitoneal defect. It is important not to kink the ureter excessively in its lateral intraperitoneal placement. The ureteral stent is left in place for two to three weeks, and follow-up nuclear functional studies are recommended at three to six months postoperatively to evaluate urinary drainage.

The laparoscopic approach remains technically challenging with operative times for unilateral ureterolysis that range from 195 to 330 minutes (10,12,14). In certain cases, bilateral ureterolysis at the same setting maybe successful; however, it is not unreasonable to approach each side at a different setting should dissection become too difficult (12). Postoperative hospitalization ranged from 3 to 10 days, and blood loss was negligible in these cases (10,12,14). In the casecontrol report by Elashry et al., laparoscopic unilateral ureterolysis for idiopathic retroperitoneal fibrosis was compared to open surgery (14). In the two laparoscopic cases, mean estimated blood loss was 100 cc compared to 400 cc in the five open cases for idiopathic retroperitoneal fibrosis. Blood transfusions were required in two of the five open cases and not in either of the laparoscopic cases. Parenteral analgesic (morphine) requirement after surgery was dramatically different in the two groups with the laparoscopic group requiring only 2 and 3 mg compared to an average of 143 mg (range, 50–267 mg) in the five open cases. Convalescence was two to three weeks from the laparoscopic group and six to eight weeks for the open group. However, given the small number of cases in this report and possible bias in case selection, the data must be interpreted with caution.

When considering the body of literature on laparoscopic ureterolysis in idiopathic retroperitoneal fibrosis, the advantages include lower operative morbidity, blood loss, postoperative analgesic requirements, and shorter convalescence compared to traditional open approaches. Given the rarity of idiopathic retroperitoneal fibrosis, its uncertain natural history, and the lack of long-term outcome data, close patient follow-up is crucial in the postoperative setting.

TRANSURETEROURETEROSTOMY

The laparoscopic approach to transureteroarterostomy remains in its infancy with no documented clinical case in the literature. This may be due to the fact that there are few indications for a transureteroarterostomy and that there are more attractive alternatives such as bladder flaps or ileal ureteral replacements that would not affect the “contralateral” renal unit. Similarly, in cases of palliative surgery to relieve urinary obstruction, simple percutaneous drainage or a laparoscopic cutaneous diversion is much easier. Nevertheless, Dechet et al. demonstrated that laparoscopic transureteroarterostomy is technically feasible in a porcine model (15). Operative times ranged from 2.5 to 6 hours and eight out of nine procedures were successful. Whether this technique will be applied clinically remains to be seen.

Laparoscopic cutaneous ureterostomy is a valuable palliative procedure in the management of distal ureteral obstruction from advanced pelvic cancers such as prostate, bladder, and uterine cancer.

CUTANEOUS URETEROSTOMY

Laparoscopic cutaneous ureterostomy is a valuable palliative procedure in the management of distal ureteral obstruction from advanced pelvic cancers such as prostate, bladder, and uterine cancer.

It is a more permanent form of urinary diversion than percutaneous nephrostomy and may be more advantageous in patients who require repetitive nephrostomy tube exchanges (16). Puppo et al. reported their initial experience in four cases with excellent results. Operative times ranged from 1.2 to 2.2 hours, and estimated blood loss was negligible in one, less than 50 cc in two, and less than 150 cc in the fourth case. All patients tolerated the procedure well and were discharged home between postoperative day 5 to day 11 (17). These same investigators then reported six more laparoscopic cutaneous ureterostomies via both the transperitoneal and retroperitoneal approach with similar success (18). Operative times were similar between 35 minutes to 2.2 hours minutes, and postoperative patient analgesic requirements were minimal. The technical approach to the ureter is similar to that already described in the above sections. The cutaneous stoma can be matured at any convenient site on the abdominal wall as performed in open surgery.

In a slight variation of simple diversion, cutaneous ureterostomy can also be used for urinary bladder diversion in the form of a catheterizable stoma for selected patients with a neurogenic bladder. Strand et al. reported an interesting case where the ipsilateral ureter from the nonfunctioning renal unit was brought out to the skin and used as a cutaneous catheterizable ureterovesicostomy (19). The laparoscopic portion of the case was 250 minutes, and postoperative recovery was uneventful.

URETERONEOCYSTOSTOMY

Distal ureteral reimplantation or ureteroneocystostomy in adults is indicated in the setting of distal ureteral stricture disease or ureteral injury sustained during gynecologic or pelvic laparoscopic surgery. While both refluxing and nonrefluxing reimplantations have been performed laparoscopically in adults, the former is much more common. The first laparoscopic ureteroneocystostomy was reported by Reddy and Evans for the treatment of a 1-cm distal obliterate ureteral stricture that developed in a 74-year-old man as a delayed complication of transurethral resection of the prostate (20). Operative time in this transperitoneal refluxing reimplant was 4.5 hours, and estimated blood loss was less than 50 cc. The patient required only four tablets of acetaminophen/codeine for pain control during the first 36 hours after surgery and was discharged home on postoperative day 2. His recovery was unremarkable and at one-year follow-up, he had excellent urinary drainage documented by excretory urogram.

Attesting to the feasibility of laparoscopic ureteroneocystostomy, other investigators have reported excellent results in the treatment of secondary ureteral stricture due to perforations from ureteroscopy as well as in gynecologic cases where infiltrative ureteral endometriosis or inadvertent ureteral injuries necessitate distal ureteral resection and reimplantation (21–25).

In performing laparoscopic ureteroneocystostomy, placing the patient in a low dorsal-lithotomy position is ideal, and the table is tilted at 15 to 45 degree of Trendelenburg to allow overlying bowel fall out of the pelvis (20–25). A transperitoneal approach provides excellent exposure and is important in longer strictures where a bladder psoas hitch may be needed for a tension free repair. Typically, four ports are needed. After creation of pneumoperitoneum and medial mobilization of the colon, the ureter is identified and circumferentially mobilized where it crosses the iliac vessels. An umbilical tape or vessel loop can be placed around the ureter and used for traction during dissection distally toward the bladder. Care is taken to preserve periureteral blood supply and avoid thermal injury from overly aggressive use of coagulation. The ureter is transected, and the pathologic ureteral segment is resected or ligated and left in situ. The proximal end of the ureter is inspected and then spatulated in preparation of reimplantation. The bladder is filled with saline, and under both cystoscopic and laparoscopic visualization, a location closest to the spatulated ureter is selected for the cystostomy. A 1–2 cm full-thickness cystostomy is made.

The typical refluxing anastomosis is created with four to five interrupted fine absorbable sutures that traverse all layers of the bladder and the ureter.

Intracorporeal and extracorporeal knot-tying as well as the Endostitch device can be used to bring the ureter and bladder together. Nonrefluxing anastomosis has also

Attesting to the feasibility of laparoscopic ureteroneocystostomy, other investigators have reported excellent results in the treatment of secondary ureteral stricture due to perforations from ureteroscopy as well as in gynecologic cases where infiltrative ureteral endometriosis or inadvertent ureteral injuries necessitate distal ureteral resection and reimplantation.

The typical refluxing anastomosis is created with four to five interrupted fine absorbable sutures that traverse all layers of the bladder and the ureter.

been reported in the clinical setting with success (25–27). In either nonrefluxing or refluxing reimplants, it is also important to avoid tension, ureteral torsion and angulation. When additional length is needed, the ureter can be mobilized further proximally or a vesicopsoas hitch can be used (22,23). At the end, the repair is then tested by bladder filling and direct laparoscopic visualization. At the conclusion of the repair, a pelvic drain is left for one to two days, and the ureteral stent is left for four to six weeks. Follow-up intravenous pyelograms or retrograde pyelograms should be obtained to ensure continuity and patency. Given the fact that indications for ureteral reimplant vary and that reimplantations are sometimes performed at the same setting of other gynecologic procedures such as hysterectomies, data on operative times, blood loss, and postoperative hospitalization are difficult to compare. In general, laparoscopic ureteroneocystostomy takes three to four hours (3.5–4.5 hours) with estimated blood loss of less than 50 cc (20,21,25). Patients can expect minimal postoperative pain, a short convalescence and excellent urologic outcomes.

SUMMARY

- The laparoscopic approach to the ureter is not only feasible but has been shown to provide significant advantages over traditional open surgery in terms of lower postoperative analgesic requirements, shorter convalescence and improved cosmesis.
- Although the acceptance of laparoscopic ureteral surgery trails that of ablative surgeries such as radical nephrectomy and nephroureterectomy, the minimally invasive approach to the ureter will likely become a powerful tool in the urologist's surgical armamentarium.
- Different laparoscopic approaches to the retrocaval ureter, idiopathic retroperitoneal fibrosis, transureteroureterostomy, cutaneous ureterostomy, and ureteroneocystostomy have been used successfully.
- Greater clinical experience is expected to be available with increasingly wider acceptance and application of laparoscopy in urology.

REFERENCES

1. Baba S, Oya M, Miyahara M, et al. Laparoscopic surgical correction of circumcaval ureter. *Urology* 1994; 44:122.
2. Ramalingam M, Selvarajan K. Laparoscopic transperitoneal repair of retrocaval ureter: report of two cases. *J Endourol* 2003; 17:85.
3. Matsuda T, Yasumoto R, Tsujino T. Laparoscopic treatment of a retrocaval ureter. *Eur Urol* 1996; 29:115.
4. Polascik TJ, Chen RN. Laparoscopic ureteroureterostomy for retrocaval ureter. *J Urol* 1998; 160:121.
5. Gupta NP, Hemal AK, Singh I, et al. Retroperitoneoscopic ureterolysis and reconstruction of retrocaval ureter. *J Endourol* 2001; 15:291.
6. Salomon L, Hoznek A, Cicco A, et al. Retroperitoneoscopic nephroureterectomy for renal pelvic tumors with a single iliac incision. *J Urol* 1999; 161:541.
7. Ameda K, Kakizaki H, Harabayashi T, et al. Laparoscopic ureteroureterostomy for retrocaval ureter. *Int J Urol* 2001; 8:71.
8. Mugiya S, Suzuki K, Ohhira T, et al. Retroperitoneoscopic treatment of a retrocaval ureter. *Int J Urol* 1999; 6:419.
9. Bhandarkar DS, Lalimalani JG, Shivde S. Laparoscopic ureterolysis and reconstruction of a retrocaval ureter. *Surg Endosc* 2003; 17.
10. Kavoussi LR, Clayman RV, Brunt LM, et al. Laparoscopic ureterolysis. *J Urol* 1992; 147:426.
11. Matsuda T, Arai Y, Muguruma K, et al. Laparoscopic ureterolysis for idiopathic retroperitoneal fibrosis. *Eur Urol* 1994; 26:286.
12. Castilho LN, Mitre AI, Iizuka FH, et al. Laparoscopic treatment of retroperitoneal fibrosis: report of two cases and review of the literature. *Rev Hosp Clin Fac Med (Sao Paulo)* 2000; 55:69.
13. Kawabata G, Shimogaki H, Yamanaka N. Laparoscopic approach to idiopathic retroperitoneal fibrosis. *Nippon Hinyokika Gakkai Zasshi* 1995; 86:1060.
14. Elashry OM, Nakada SY, Wolf JSJ, et al. Ureterolysis for extrinsic ureteral obstruction: a comparison of laparoscopic and open surgical techniques. *J Urol* 1996; 156:1403.
15. Dechet CB, Young MM, Segura JW. Laparoscopic transureteroureterostomy: demonstration of its feasibility in swine. *J Endourol* 1999; 13:487.
16. Loisesides P, Grasso M, Lui P. Laparoscopic cutaneous ureterostomy: technique for palliative upper urinary tract drainage. *J Endourol* 1995; 9:315.
17. Puppo P, Perachino M, Ricciotti G, et al. Laparoscopic bilateral cutaneous ureterostomy for palliation of ureteral obstruction caused by advanced pelvic cancer. *J Endourol* 1994; 8:425.
18. Puppo P, Ricciotti G, Bozzo W, et al. Videoendoscopic cutaneous ureterostomy for palliative urinary diversion in advanced pelvic cancer. *Eur Urol* 1995; 28:328.
19. Strand WR, McDougall EM, Leach FS, et al. Laparoscopic creation of a catheterizable cutaneous ureterovesicostomy. *Urology* 1997; 49:272.

20. Reddy PK, Evans RM. Laparoscopic ureteroneocystostomy. *J Urol* 1994; 152:2057.
21. Yohannes P, Gershbaum D, Rotariu PE, et al. Management of ureteral stricture disease during laparoscopic ureteroneocystostomy. *J Endourol* 2001; 15:839.
22. Nezhat CH, Malik S, Nezhat F, et al. Laparoscopic ureteroneocystostomy and vesicopsoas hitch for infiltrative endometriosis. *JSL* 2004; 8:3.
23. Nezhat CH, Nezhat FR, Freiha F, et al. Laparoscopic vesicopsoas hitch for infiltrative ureteral endometriosis. *Fertil Steril* 1999; 71:376.
24. Nezhat CH, Nezhat F, Seidman D, et al. Laparoscopic ureteroureterostomy: a prospective follow-up of 9 patients. *Prim Care Update Ob Gyns* 1998; 5:200.
25. Andou M, Yoshioka T, Ikuma K. Laparoscopic ureteroneocystostomy. *Obstet Gynecol* 2003; 102:1183.
26. McDougall EM, Urban DA, Kerbl K, et al. Laparoscopic repair of vesicoureteral reflux utilizing the Lich-Gregoir technique in the pig model. *J Urol* 1995; 153:497.
27. Lakshmanan Y, Fung LC. Laparoscopic extravesicular ureteral reimplantation for vesicoureteral reflux: recent technical advances. *J Endourol* 2000; 14:589.

LAPAROSCOPIC MARSUPIALIZATION OF LYMPHOCELE

W. Patrick Springhart, Charles D. Scales, Jr., and David M. Albala

Division of Urology, Duke University Medical Center, Durham, North Carolina, U.S.A.

- INTRODUCTION
- PATIENT SELECTION: INDICATIONS AND CONTRAINDICATIONS
- PREOPERATIVE PREPARATION
- LAPAROSCOPIC TECHNIQUE
- TECHNICAL CAVEATS AND TIPS
- AVOIDING COMPLICATIONS
- SUMMARY
- REFERENCES

INTRODUCTION

Lymphocele has been reported after a variety of different procedures. Typically, it occurs after pelvic lymphadenectomy or renal transplantation but has also been observed after retroperitoneal lymphadenectomy or aortic graft placement. Etiologic factors associated with lymphocele development include transected lymphatics, increased lymphatic flow, delayed healing, or deficiencies with the intrinsic clotting mechanism. Specifically, these include prior radiotherapy, extensive dissection, lack of peritoneal communication, reoperations, and the administration of perioperative mini-dose heparin, diuretics, high-dose steroid medication, or immunosuppressants. The surgical approach, the number of transected lymphatics around renal grafts, and transplant rejection episodes are also factors associated with the development of lymphocele (1–4). Whatever the causative agent(s), the result is accumulation of lymphatic fluid in an epithelialized, confined space, which may or may not result in symptoms.

Studies have shown that both open and laparoscopic pelvic lymphadenectomies result in similar amounts of lymph node extirpation (5). However, open pelvic lymph node dissection for prostate cancer has been reported with a lymphocele formation rate of 3.2% to 14.8% (3,6,7). Additional studies have focused on the occurrence of lymphocele formation after laparoscopic transperitoneal lymphadenectomy for prostate cancer. Earlier observations by Fried et al. reported on symptomatic lymphoceles after laparoscopic transperitoneal lymphadenectomy and noted a 3.5% incidence in a group of 57 patients when compared with 6.5% incidence of lymphoceles after extraperitoneal laparoscopic transperitoneal lymphadenectomy (8). More recently, additional authors have reported rates of 1.1% in a large series of 177 laparoscopic transperitoneal lymphadenectomies in comparison to 1.54% to 2.4% after laparoscopic extraperitoneal approach (9,10).

The exposure to the peritoneal surface results in the absorption of lymphatic fluid and forms the basis of surgical therapy for lymphocele treatment through either an open or laparoscopic approach.

Traditionally, treatment of a lymphocele required open surgical fenestration to allow the lymphatic drainage to be reabsorbed by the peritoneal cavity. However, since the initial description by McCullough et al. in 1991, along with technologic advances and increased surgical experience, laparoscopic marsupialization of lymphoceles is now the proposed first-line approach (11,12).

PATIENT SELECTION: INDICATIONS AND CONTRAINDICATIONS

The indications for lymphocele treatment are based on the development of clinical symptoms as the majority of lymphoceles remain asymptomatic (13,14). Most lymphoceles tend to be small in size and remain clinically insignificant. In a longitudinal study by Spring et al. spontaneous resolution of the majority of lymphoceles after open pelvic lymph node dissection was observed. However, larger lymphoceles or those that persisted became clinically significant and required some form of intervention (3,9,15).

The exposure to the peritoneal surface results in the absorption of lymphatic fluid and forms the basis of surgical therapy for lymphocele treatment through either an open or laparoscopic approach.

Since the initial description by McCullough et al. in 1991, along with technologic advances and increased surgical experience, laparoscopic marsupialization of lymphoceles is now the proposed first-line approach.

Albeit rare, clinically significant lymphoceles develop in approximately 1.1% to 10% following pelvic lymph node dissection and 0.5% to 12% following renal transplantation and are one of the most important predisposing factors for incisional hernia in the transplant population (13,16,17).

Clinically significant lymphoceles present in several different manners depending on their precipitating cause. The most common occurrence is after a pelvic lymph node dissection. In these cases, patients will present with lower abdominal discomfort or swelling, fever, ipsilateral lower extremity swelling, deep venous thrombosis, scrotal swelling, lymphocutaneous fistula, or incidentally on computed tomography for adjuvant radiotherapy to treat prostate cancer. Presentation following pelvic renal transplantation is similar, with the addition of perinephric fluid collections, renal failure, or suspected graft rejection.

In the largest series to date, Hsu et al. performed a multicenter study evaluating current treatment strategies used for the treatment of lymphoceles. In the cohort evaluated, 96% of lymphoceles developed after renal transplantation and 4% after pelvic lymphadenectomy (13). Hence the majority of lymphoceles encountered will be in those patients who have undergone renal transplantation.

Percutaneous needle aspiration has been described as an initial attempt to manage symptomatic lymphoceles. However, high recurrence rates are reported ranging from 42% to 100% (17–19).

Moreover, attempts at percutaneous aspiration with concomitant instillation of sclerosing agents such as minocycline, tetracycline, ampicillin, alcohol, povidine-iodine, and fibrin sealants may cause an inflammatory reaction such that ureteral obstruction may occur, increasing the difficulty of dissection by either laparoscopic or open technique (13,20,21). Furthermore, the potential for contaminating a potentially sterile space exists as well.

Like most procedures, experience of the surgeon is inversely proportional to complication rates. The clinically significant lymphoceles that follow pelvic lymphadenectomy will share a common wall with the parietal peritoneum. Access to those that are in close juxtaposition to the peritoneal cavity are relatively straightforward and require an opening and wide marsupialization of the overlying peritoneum for durable success.

The most frequent location of posttransplantation lymphoceles was superomedial or inferomedial to the renal graft (19). Small lymphoceles (<100 mL) lying near the renal hilum, or lateroposterior, lateroinferior, or inferomedial lymphoceles are the most difficult to drain laparoscopically. If laparoscopic experience is limited, other modalities for drainage should be employed (13,14,19).

Intervention is indicated for symptomatic lymphoceles or those causing graft dysfunction. Conservative management, including percutaneous drainage or sclerotherapy, may be considered for small lymphoceles or those causing minor symptoms. However, for larger lymphoceles, or those causing serious complications such as renal insufficiency, surgical therapy is required. Laparoscopic techniques may be used in these patients or in patients with recurrent lymphoceles after conservative therapy had failed.

Laparoscopic drainage is contraindicated if the lymphocele is infected. These patients should undergo open surgical drainage with concomitant administration of intravenous antibiotics.

Percutaneous needle aspiration has been described as an initial attempt to manage symptomatic lymphoceles. However, high recurrence rates are reported ranging from 42% to 100% (17–19).

Small lymphoceles (<100 mL) lying near the renal hilum, or lateroposterior, lateroinferior, or inferomedial lymphoceles are the most difficult to drain laparoscopically. If laparoscopic experience is limited, other modalities for drainage should be employed.

Laparoscopic drainage is contraindicated if the lymphocele is infected. These patients should undergo open surgical drainage with concomitant administration of intravenous antibiotics.

PREOPERATIVE PREPARATION

The patient should be explained the procedure in detail along with risks, benefits, and potential complications. Furthermore, the patient should be informed that conversion to an open approach occurs in 5% to 9% of laparoscopic cases (13,19).

Prior to intervention, basic laboratory evaluation, including blood counts, serum chemistries, and blood typing and screening should be obtained. A preoperative computed tomography scan with and without contrast should be performed to delineate the lymphocele size and relationship to other anatomical structures. Aspirin, nonsteroidal anti-inflammatory drugs, and anticoagulant medications should be stopped at least one week prior to surgery. As with any surgical procedure, the patient should be instructed not to eat after midnight prior to the surgery.

LAPAROSCOPIC TECHNIQUE

The patient is placed in the supine position on the operative table, prepped and draped in a standard sterile fashion. A Foley catheter is placed along with a nasogastric tube to

decompress the bladder and stomach, respectively. In the absence of a previous midline scar, access and insufflation are accomplished with a Veress needle using conventional laparoscopic techniques. Once pneumoperitoneum has been achieved, a 3-trocar transperitoneal approach is used. The placement of trocars is similar to a laparoscopic pelvic lymph node dissection (Fig. 1). A 12-mm trocar is placed for use by the camera along with an additional 12-mm trocar for potential use of a clip applier. A 5-mm trocar is placed for laparoscopic instruments. The peritoneal cavity is inspected for adhesions. Careful attention should be paid to check whether the adhesions will complicate marsupialization of the lymphocele and potential mobilization of the omentum. Identification and extent of the lesion may be facilitated by a percutaneous needle or catheter placed into the lymphocele either by preoperative or intraoperative ultrasound guidance. Often the lymphocele appears as a blue-tinged dome protruding into the peritoneal cavity. In patients who have undergone renal transplantation care should be taken to identify the ureter as well as the renal vessels.

After complete visualization, the wall of the lymphocele is grasped and the cavity is opened using electrocautery scissors (Fig. 2). Lymphoceles typically contain straw-colored fluid, which may exude upon opening. The interior of the lymphocele should be aspirated with the irrigator-aspirator after opening. A large window from the peritoneal cavity into the interior of the lymphocele should be created by incision. Inspection of the lymphocele cavity is followed by gentle irrigation with an antibiotic solution. Pathologic analysis should be performed on the excised portion of the lymphocele.

Significant bleeding is a rare complication of the laparoscopic marsupialization of lymphocele.

If needed, hemostasis can be achieved through the use of electrocautery or the application of titanium clips. The patency of the peritoneal window can be maintained by the placement of a pedicle flap of omentum into the cavity. The pedicle flap should be secured with titanium clips to prevent closure of the window and also bowel herniation through the peritoneal opening. A permanent peritoneal dialysis catheter can be placed in lieu of omentum in recurrent lymphoceles, those with limited peritoneal openings or those that are anatomically difficult to access. Similar to omentoplasty, peritoneal dialysis catheters must be fixed to the lymphocele wall to prevent migration. They are, however, contraindicated in those lymphoceles that are infected (20). As with any laparoscopic procedure, careful inspection for hemostasis is critical.

If dissection occurs near the transplanted ureter, indigo carmine can be given intravenously to confirm the integrity of the ureter.

Following hemostasis, the pneumoperitoneum is released. The larger trocar sites (>5 mm) are closed with a fascial suture and steri-strips are applied over the incisions.

Postoperatively, patients typically require only oral analgesics. Shoulder pain, although uncommon, may result from diaphragmatic irritation caused by the carbon

Significant bleeding is a rare complication of the laparoscopic marsupialization of lymphocele.

If dissection occurs near the transplanted ureter, indigo carmine can be given intravenously to confirm the integrity of the ureter.

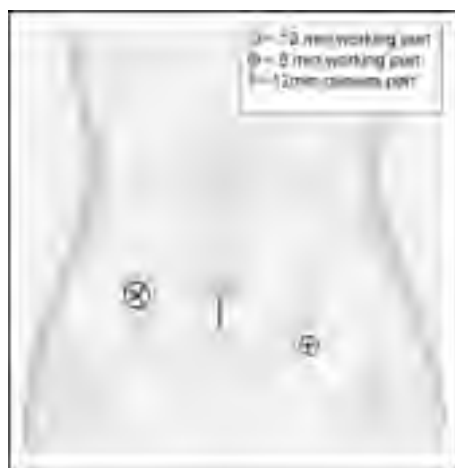

FIGURE 1 ■ Trocar placement for right pelvic lymphocele marsupialization. To perform left sided marsupialization, use mirror image of this trocar configuration.

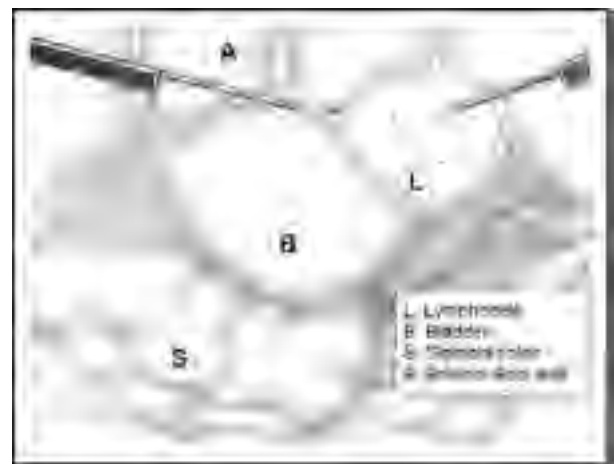


FIGURE 2 ■ Laparoscopic marsupialization of a right-sided lymphocele. Scissors are depicted in surgeon's right hand, grasper in the left hand. Dotted line depicts peritoneal window.

dioxide insufflation. Diaphragmatic irritation will resolve as the carbon dioxide is reabsorbed by the peritoneum. Patients are given a liquid diet immediately. Hospital discharge typically occurs on the first or second postoperative day. Lymphocele resolution is confirmed with a postoperative computed tomography scan.

TECHNICAL CAVEATS AND TIPS

- A preoperative computed tomography scan gives the best definition of size and location of the lymphocele cavity. This study can determine the relationship of the lymphocele cavity to the bladder and the renal allograft.
- Aspirated fluid creatinine and blood urea nitrogen are helpful to distinguish between a lymphocele and an urinoma. A gram stain and culture help to determine if the lymphocele is infected.
- Careful laparoscopic dissection will prevent injury to the transplanted ureter or renal vessels.
- In selected cases, a portion of the omentum can be placed in the lymphocele cavity to keep the cavity open for drainage.

The most common complication (7% of cases) of laparoscopic marsupialization of lymphocele is injury to adjacent structures, especially transection of the transplanted ureter.

If intraoperatively the lymphocele is found to be infected, conversion to an open procedure is required.

AVOIDING COMPLICATIONS

The most common complication (7% of cases) of laparoscopic marsupialization of lymphocele is injury to adjacent structures, especially transection of the transplanted ureter (22).

Bowel is less commonly injured, but both complications may be avoided by careful and complete visualization of the lymphocele. As noted earlier, a needle or catheter placed into the lymphocele may assist in localizing the cavity. Meticulous dissection with identification of the transplanted ureter helps to avoid injury. Stent placement into the transplanted ureter is technically demanding and is not routinely performed. If intraoperatively the lymphocele is found to be infected, conversion to an open procedure is required.

Peritonitis may result from opening an infected lymphocele with subsequent seeding of the peritoneal cavity. Careful patient selection will prevent attempting to open an infected lymphocele laparoscopically.

Peritonitis may also occur secondary to an undetected bowel injury. Careful inspection of the peritoneal cavity prior to removing the trocars is required to detect and repair any injured bowel.

Finally, a rare complication of laparoscopic lymphocele fenestration is herniation of bowel through the peritoneal window with entrapment in the lymphocele cavity. This can cause a recurrent lymphocele or bowel injury. Attachment of a pedicle flap of omentum to the lymphocele cavity helps maintain the patency of the peritoneal window, as well as preventing migration of bowel into the lymphocele cavity.

SUMMARY

- Lymphoceles most commonly occur after renal transplantation and pelvic lymphadenectomy.
- The use of laparoscopy for drainage of a lymphocele cavity is safe and effective. This procedure has lowered the morbidity as well as the hospitalization rate when compared with its open counterpart and is associated with a low recurrence rate.
- Laparoscopic marsupialization is now the proposed first-line approach to lymphoceles.

ACKNOWLEDGMENT

The authors gratefully acknowledge the work of Audrey L'Esperance, medical illustrator.

REFERENCES

1. Khauli RB, Stoff JS, Lovewell T, Ghavamian R, Baker S. Post transplant lymphoceles: a critical look into the risk factors, pathophysiology and management. *J Urol* 1993; 150:22–26.
2. Oyen O, Siwach V, Line PD, et al. Improvement of posttransplant lymphocele treatment in the laparoscopic era. *Transplant Int* 2002; 15:406–410.

3. Solberg A, Angelsen A, Bergan U, Haugen OA, Vise T, Klepp O. Frequency of lymphoceles after open and laparoscopic pelvic lymph node dissection in patients with prostate cancer. *Scand J Urol Nephrol* 2003; 37:218–221.
4. Catalona WJ, Kadmon D, Crane DB. Effects of mini-dose heparin injection on lymphocele formation following extraperitoneal pelvic lymphadenectomy. *J Urol* 1980; 123:890.
5. Winfield HN, Donovan JF, See WA, Loening SA, Williams RD. Urological laparoscopic surgery. *J Urol* 1991; 146:941–948.
6. Sogani PC, Watson RC, Whitmore WF Jr. Lymphocele after pelvic lymphadenectomy for urologic cancer. *Urology* 1981; 17:39–43.
7. Ojeda L, Sharifi R, Lee M, Mouli K, Guinan P. Lymphocele formation after extraperitoneal pelvic lymphadenectomy: possible predisposing factors. *J Urol* 1986; 136:616–618.
8. Freid RM, Siegel D, Smith AD, Weiss GH. Lymphoceles after laparoscopic pelvic node dissection. *Urology* 1998; 51(suppl. 5A): 131–134.
9. Stolzenburg JU, Minh D, Rabenalt R, et al. Endoscopic extraperitoneal radical prostatectomy: initial experience after 70 procedures. *J Urol* 2003; 169:2066–2071.
10. Vallancien G, Cathelineau X, Baumert H, Doublet JD, Guillonnet B. Complications of transperitoneal laparoscopic surgery in urology: review of 1,311 procedures at a single center. *J Urol* 2002; 168:23–26.
11. McCullough CS, Soper NJ, Clayman RV, et al. Laparoscopic drainage of a posttransplant lymphocele. *Transplantation* 1991; 51:725.
12. Hsu THS, Gill IS, Gurne MT, et al. Laparoscopic lymphocelelectomy: a multi-institutional analysis. *J Urol* 2000; 163:1096–1099.
13. Gruessner RW, Fasola C, Benedetti E, et al. Laparoscopic drainage of lymphoceles after kidney transplantation: indications and limitations. *Surgery* 1995; 117:288.
14. Braun WE, Banowsky LH, Straffon RA, et al. Lymphocytes associated with renal transplantation. Report of 15 cases and review of the literature. *Am J Med* 1974; 57:714.
15. Spring DB, Schroeder D, Babu S, Agee R, Gooding GAW. Ultrasonic evaluation of lymphocele formation after staging lymphadenectomy for prostate carcinoma. *Radiology* 1981; 141:479–483.
16. Teruel JL, Escobar ME, Quereda C, et al. A simple and safe method for management of lymphoceles after renal transplantation. *J Urol* 1983; 130:1058.
17. Kay R, Fuchs E, Barry JM. Management of post operative pelvic lymphoceles. *Urology* 1980; 15:345.
18. Gill IS, Hodge EE, Munch LC, et al. Transperitoneal marsupialization of lymphoceles: a comparison of laparoscopic and open techniques. *J Urol* 1995; 153:706.
19. Fuller TF, Kang S, Hirose R, et al. Management of lymphoceles after renal transplantation: laparoscopic versus open drainage. *J Urol* 2003; 169:2022–2025.
20. Melvin WS, Bumgardner GL, Davies EA, et al. The laparoscopic management of posttransplant lymphocele: a critical review. *Surg Endosc* 1997; 11:245.
21. Schilling M, Abendroth D, Kunz, R. Treatment of lymphocele in renal transplant recipients by laparoscopic fenestration after transcutaneous staining. *Brit J Surgery* 1995; 82(2):246–248.
22. Matin SR, Gill IS. Laparoscopic marsupialization of the difficult lymphocele using internalized peritoneal dialysis catheter. *J Urol* 2000; 163:1498–1500.

LAPAROSCOPIC BLADDER AUGMENTATION: WITH AND WITHOUT URINARY DIVERSION

Raymond R. Rackley and Joseph B. Abdelmalak

Section of Voiding Dysfunction and Female Urology, Glickman Urological Institute, Cleveland Clinic Foundation, Cleveland, Ohio, U.S.A.

- INTRODUCTION
- PATIENT SELECTION: INDICATIONS AND CONTRAINDICATIONS
- PREOPERATIVE PREPARATION
- SURGICAL TECHNICAL STEPS
 - Port Placement
 - Selection and Mobilization of the Bowel Segment
 - Exclusion and Re-Anastomosis of the Bowel
 - Refashioning of the Isolated Bowel Segment
 - Bladder Mobilization and Cystotomy
- Enterovesical Anastomosis
- Postoperative Management
- Results
- Comparative Analysis of Open and Laparoscopic Approaches
- Laparoscopic Ileovesicostomy and Augmentation
- Surgical Technique
- RESULTS
- SUMMARY
- REFERENCES

INTRODUCTION

Augmentation cystoplasty remains the most widely accepted reconstructive technique for creating a compliant, large capacity bladder that protects the upper urinary tract and provides urinary continence in people with bladder dysfunction secondary to noncompliance or reduced functional capacity.

Augmentation cystoplasty remains the most widely accepted reconstructive technique for creating a compliant, large capacity bladder that protects the upper urinary tract and provides urinary continence in people with bladder dysfunction secondary to noncompliance or reduced functional capacity (1–4).

Augmentation cystoplasty may be combined with continent catheterizable stoma formation for use as an accessible port for bladder emptying. In 1888, Tizzoni and Foggi demonstrated the feasibility of performing ileocystoplasty in a canine model. Ten years later, Mikulicz performed the first clinical ileocystoplasty (5). Since that time, the standard enterocystoplasty has classically evolved as a procedure performed through an open laparotomy incision utilizing various segments of well-vascularized segments of the gastrointestinal system that are reconfigured before anastomosis with the urinary bladder (6). One hundred years have passed since the original open approach for this procedure has become an established reconstructive technique performed laparoscopically.

No matter what surgical approach is chosen, the use of any bowel segment for augmentation is associated with advantages and disadvantages. However, the versatility of choosing a particular bowel segment, for both open and laparoscopic approaches, provides a variety of clinical options based on an individualized set of objectives for the person requiring this form of bladder reconstruction.

Enterocystoplasty effectively provides a durable increase in bladder capacity and compliance; however, the morbidity and postoperative discomfort associated with the open laparotomy incision are major deterrents.

For patients with pre-existing debilitating neurologic and other comorbid conditions, the open surgical approach may significantly prolong the hospital stay, increase the metabolic needs for wound healing, and delay postoperative recovery. Laparoscopy has distinct advantages when compared with open surgical procedures with regard to postoperative pain and morbidity, a shorter hospital stay, decreased convalescence period, and improved cosmesis. Furthermore, postoperative intra-abdominal adhesions are significantly reduced after laparoscopic surgery when compared with open surgery (7).

Laparoscopy has an established role in diagnostic and ablative urologic surgery. The use of laparoscopic techniques in reconstruction has been limited because of the technical complexity of the procedures involved. The technical steps in performing a laparoscopic bladder augmentation are designed to emulate the open surgical counterpart in every aspect, thereby producing similar functional results with improved recovery.

PATIENT SELECTION: INDICATIONS AND CONTRAINDICATIONS

The goal of augmentation cystoplasty is to restore the compliant storage properties of the urinary bladder. Noncompliant, small capacity bladders that typically do not respond to

Enterocystoplasty effectively provides a durable increase in bladder capacity and compliance; however, the morbidity and postoperative discomfort associated with the open laparotomy incision are major deterrents.

The use of laparoscopic techniques in reconstruction has been limited because of the technical complexity of the procedures involved. The technical steps in performing a laparoscopic bladder augmentation are designed to emulate the open surgical counterpart in every aspect, thereby producing similar functional results with improved recovery.

more conservative forms of treatment can be surgically augmented. Interruption of the bladder innervation and musculature with the use of detubularized bowel to augment the resultant defect may decrease efficiency of the spontaneous voiding mechanism. People with neurogenic bladder dysfunction will generally require clean intermittent catheterization for prolonged or indefinite periods postoperatively to empty the bladder effectively. In addition, the physical disabilities or limitations due to neurologic conditions may prevent one's ability to catheterize via the urethra; thus, a continent catheterizable abdominal stoma should be considered in addition to bladder augmentation.

A relative contraindication specific to laparoscopic bladder augmentation is the presence of extensive intra-abdominal and pelvic adhesions that would preclude a laparoscopic bowel dissection.

A relative contraindication specific to laparoscopic bladder augmentation is the presence of extensive intra-abdominal and pelvic adhesions that would preclude a laparoscopic bowel dissection.

Our experience in open and laparoscopic approaches for this procedure suggests that people with ventriculoperitoneal shunts typically have increased abdominal adhesions that may preclude a successful laparoscopic approach. Routine laboratory studies include renal function and serum electrolytes, whole blood cell count, urinalysis, and when appropriate, a urine culture. Upper and lower urinary tract studies are important baseline evaluations. A urodynamic study and cystoscopy will provide additional useful information about the competence of the urinary sphincter and pre-existing bladder pathologies.

PREOPERATIVE PREPARATION

Mechanical and antibiotic bowel preparation includes a low residue, clear liquid diet for two days before the operation, a bowel preparation the day before the operation, preoperative antibiotics for bowel and urinary tract surgical prophylaxis, and antifungal medication when indicated.

Patients with neurologic diseases have chronic constipation and may need more time for an adequate bowel preparation.

Patients with neurologic diseases have chronic constipation and may need more time for an adequate bowel preparation.

The patient is placed in the supine position and pneumatic compression stockings are applied to both legs. After induction with general anesthesia and endotracheal intubation, an oral gastric tube is inserted, and the patient is placed in the low-lithotomy position for the remainder of the operation. Both arms are tucked in and protected along the sides so that the surgical team may direct their operative movements deep into the pelvis. Effective intraoperative urine and pelvic fluid drainage by intermittently opening the urethral catheter to preserve the pneumoperitoneum augments the suction removal of any excessive fluid collections.

SURGICAL TECHNICAL STEPS

For laparoscopic or open approaches the surgical technique of enterocystoplasty is based on the following fundamentals: (i) selection of an optimal segment of bowel based on a broad, well-vascularized mesenteric pedicle, (ii) isolation of the bowel segment, (iii) re-establishment of bowel continuity and closure of the mesenteric defect, (iv) detubularization and reconfiguration of the bowel segment without peritoneal soiling of bowel contents, (v) bladder mobilization with formation of an adequate sized cystotomy, (vi) creation of a tension-free, watertight, full-thickness, circumferential anastomosis of the bowel to the bladder, and (vii) confirmation of adequate postoperative urinary drainage.

Port Placement

An incision is made at the infraumbilical crease, and a disposable 10-mm port with occluding balloon and cuff is introduced under direct vision into the peritoneal cavity. A 10-mm, 0° laparoscope is introduced and the subsequent ports are introduced under visual guidance. For the right-handed surgeon, the right-sided 10 mm and left-sided 5 mm ports are inserted bilaterally at the lateral borders of the rectus muscle at the level of the umbilicus (Fig. 1). Most of the operative suturing takes place via the two paraumbilical ports. The 10-mm port not only facilitates the introduction of sutures on large needles but also is useful for extracorporeal knot tying. Additional 5-mm ports are inserted bilaterally at the level of the anterior superior iliac spines. Other ports may be placed depending on the bowel mobilization required and surgeon's preference.

In laparoscopic ileocystoplasty, the initial step is identification of the ileocecal junction.

In laparoscopic sigmoidocystoplasty, a loop of sigmoid colon is selected using similar techniques.

Selection and Mobilization of the Bowel Segment

Various segments of the gastrointestinal system may be used for the procedure depending on the clinical requirements of the patient. A length of 20 cm of bowel is usually desirable to attain an adequate augmented bladder capacity. An appropriate segment of bowel is identified based on the following criteria: (i) the bowel segment will reach the area of the bladder neck without tension and (ii) a well-defined arterial arcade should be present in the isolated bowel mesentery.

In laparoscopic ileocystoplasty, the initial step is identification of the ileocecal junction. With the use of laparoscopic small bowel clamps, a 20-cm segment of ileum at least 15 cm proximal to the ileocecal junction is identified (Fig. 2). The mesentery adjacent to the proximal and distal ends of the selected bowel loop is scored with laparoscopic electrosurgical scissors for subsequent extracorporeal identification.

In laparoscopic sigmoidocystoplasty, a loop of sigmoid colon is selected using similar techniques. Many patients with neurogenic bladder dysfunction also have defecating dysfunction resulting in a redundant sigmoid colon. In patients planning to perform intermittent catheterization via the urethra, the sigmoid colon may be the preferred segment of bowel for harvesting if continent stoma formation is not required. Extracorporeal manipulation of the sigmoid is best achieved via extension of the left lower abdominal port defect (Fig. 3).

The right colon and terminal ileum are selected in patients who require continent abdominal stoma formation in addition to bladder augmentation. The cecum and ascending colon are used for the bladder augmentation, and 10 cm of terminal ileum is used to create the catheterizable conduit and stoma at the umbilicus. The peritoneum lateral to the cecum and ascending colon and the peritoneum of the terminal aspect of the Z line are incised. The entire right colon and terminal ileum are mobilized for extracorporeal manipulation via the extended incision of the umbilical port. Ensuring a low position of the patient's thighs via low-lithotomy enables proper manipulation of the laparoscopic instruments through the lower abdominal ports for mobilization of the right colonic flexure.

Exclusion and Re-Anastomosis of the Bowel

Following mobilization of the bowel for extracorporeal manipulation, the pneumoperitoneum is desufflated and the umbilical port removed. Except for the sigmoidocystoplasty procedure as described earlier, the umbilical incision is enlarged

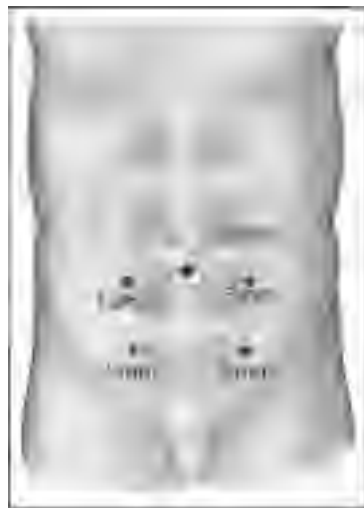

FIGURE 1 ■ Options for selection of port sizes and location in laparoscopic enterocystoplasty procedures. Source: Courtesy of the Cleveland Clinic Foundation.

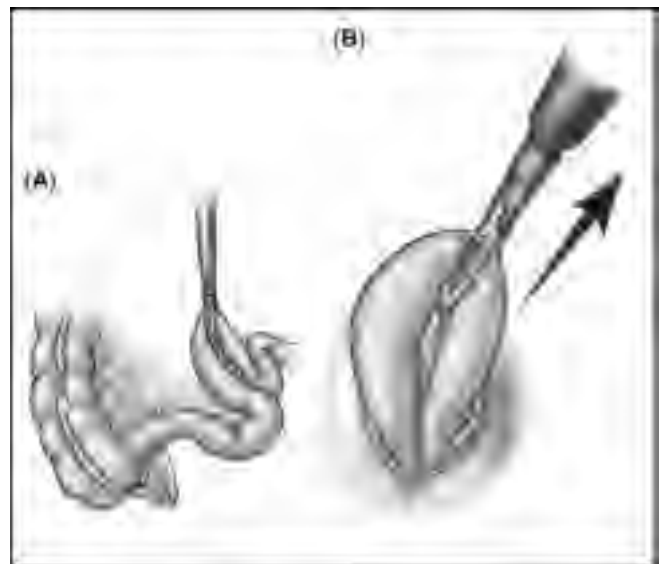


FIGURE 2 ■ Extracorporeal isolation (A) and manipulation of the small bowel (B) via the umbilical port site. Source: Courtesy of the Cleveland Clinic Foundation.

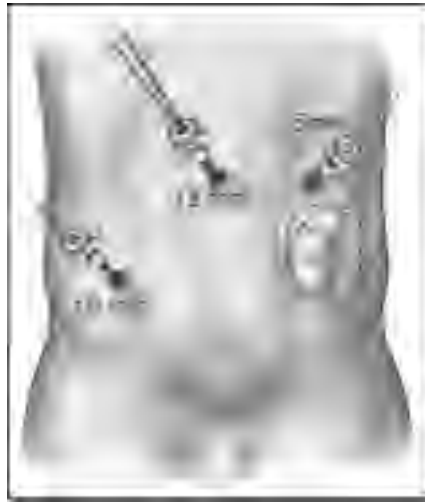


FIGURE 3 ■ Selection of port sizes and location for laparoscopic sigmoidocystoplasty. Source: Courtesy of the Cleveland Clinic Foundation.

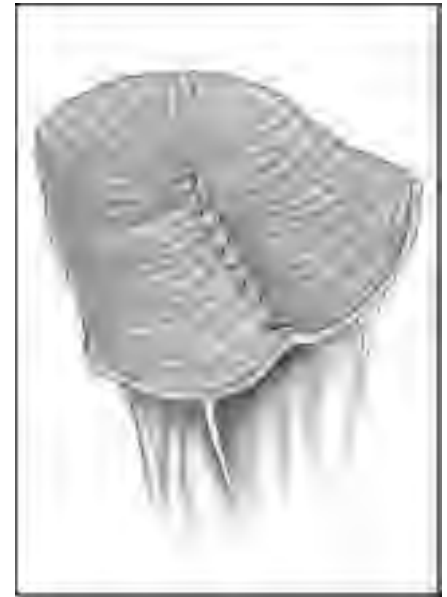


FIGURE 4 ■ Detubularization and reconfiguration of the isolated bowel segment. Source: Courtesy of the Cleveland Clinic Foundation.

Bowel continuity is re-established using traditional open techniques and the mesenteric window is closed. The bowel anastomosis is performed cephalad to the excluded segment of bowel, and the reanastomosed bowel is returned to the abdominal cavity before any further manipulations are performed. This step reduces the potential need to enlarge the circumumbilical incision for re-introduction of an edematous combination of both the bowel reanastomosis and the reconfigured bowel segment for augmentation.

circumumbilically and extended inferiorly in obese patients for an additional 2 cm. The preselected loop of bowel is delivered extracorporeal through this incision. Care is taken to prevent any twisting of the mesenteric pedicle and to ensure proper proximal–distal orientation of the loop. Using traditional open surgical techniques, the 20-cm bowel segment with its vascular pedicle is divided between bowel clamps and isolated as in ileocystoplasty.

Bowel continuity is re-established using traditional open techniques and the mesenteric window is closed. The bowel anastomosis is performed cephalad to the excluded segment of bowel, and the reanastomosed bowel is returned to the abdominal cavity before any further manipulations are performed. This step reduces the potential need to enlarge the circumumbilical incision for re-introduction of an edematous combination of both the bowel reanastomosis and the reconfigured bowel segment for augmentation.

Refashioning of the Isolated Bowel Segment

The excluded bowel segment is draped in moist, warm sponges and then irrigated thoroughly with normal saline until the returning irrigation is clear. The antimesenteric border of the bowel is incised using electrocautery. For the small bowel or sigmoid, a U-shaped plate is created by a side-to-side anastomosis with a 2-0 absorbable suture (Fig. 4). After the isolated bowel segment for augmentation is reintroduced into the peritoneal cavity, the ports are replaced to re-establish the pneumoperitoneum.

In ileocystoplasty, reintroducing a disposable 10-mm blunt-tip port with a fascial retention balloon and foam cuff to minimize gas leakage is warranted. In sigmoidocystoplasty, the extended left lower abdominal port incision is reduced to accommodate a 5-mm port. The pneumoperitoneum is then re-established and the laparoscope inserted. The isolated bowel segment is oriented appropriately and inspected to exclude torsion of the pedicle.

For patients requiring a continent catheterizable stoma, the right colon and terminal ileum are utilized. Following detubularization of the cecum and proximal colon, an appendectomy is performed. The terminal ileum is narrowed over a 16-French red rubber catheter using a gastrointestinal anastomosis stapling device, and the ileocecal junction is imbricated and intussuscepted to augment the continence mechanism of the ileocecal valve using 2-0 permanent sutures (Fig. 5). Orientation sutures are placed at the cephalic ends of the bowel patch to facilitate intracorporeal laparoscopic identification and manipulation. The 16 French red rubber catheter is



FIGURE 5 ■ Detubularization and reconfiguration of the right colon and ileum for cecocolocystoplasty in preparation for formation of a catheterizable stoma. *Source:* Courtesy of the Cleveland Clinic Foundation.

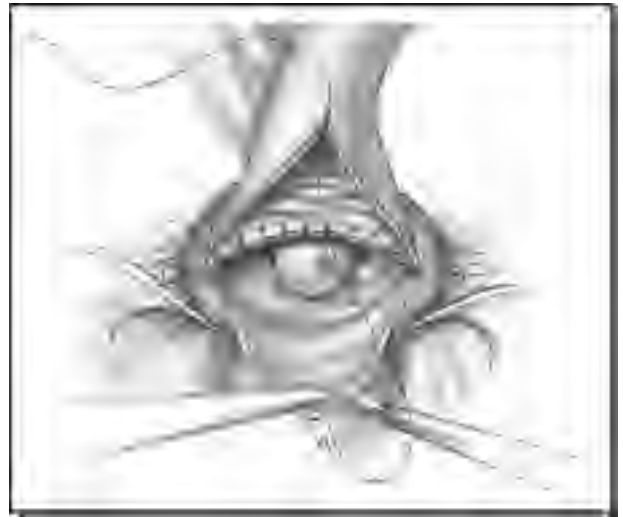

FIGURE 6 ■ Intracorporeal suturing of the isolated bowel segment to the bladder. Point A is at the apical aspect of the newly formed bladder flap that was derived from the anterior aspect of the bladder wall near the bladder neck. *Source:* Courtesy of the Cleveland Clinic Foundation.

secured to the terminal end of the catheterizable segment of ileum with a suture for atraumatic intracorporeal manipulation and for delivering this terminal segment to the umbilicus for stoma maturation at the end of the procedure. The isolated bowel patch is then returned to the abdominal cavity and the pneumoperitoneum is re-created as described earlier.

Exclusion of the bowel segment and subsequent restoration of bowel continuity can be performed intracorporeally using stapling devices and is thought to reduce any theoretical complications from undue tension placed on the bowel mesentery during the extracorporeal manipulation of the bowel in obese patients. We have not experienced any complications related to this proposed concern using this extracorporeal maneuver in obese patients. We prefer to routinely perform these manipulations extracorporeally by delivering the bowel outside the abdomen through the umbilical or lower abdominal port site, respectively, for the following several reasons: (i) the bowel segment can be measured precisely and the mesentery incised after ensuring good vascularity; (ii) the bowel may be reanastomosed meticulously using open surgical techniques with increased confidence; (iii) the excluded loop may be irrigated without any peritoneal spillage, thereby eliminating the potential for subsequent pelvic abscess formation; (iv) the detubularization and desired modification of the isolated loop can be performed expeditiously by traditional open suturing; (v) if the mesenteric length allows the segment to be delivered outside the anterior abdominal wall comfortably without evidence of bowel ischemia, it is also likely to reach the bladder without tension; and (vi) the extracorporeal approach allows considerable savings in overall operative time and cost.

Bladder Mobilization and Cystotomy

Placing the patient in extreme Trendelenburg position aids in displacement of the bowel loops from the pelvic cavity and facilitates the subsequent steps of the procedure. The bladder is distended with saline through the urethral catheter. The peritoneum overlying the bladder is incised at the medial border of the left medial umbilical ligament and extended to the right in a linear fashion to the right medial umbilical ligament. The median umbilical ligament is taken down during the procedure using electro-surgical scissors. If needed, the lateral peritoneum incisions are extended down along the medial umbilical ligaments to increase exposure. The loose areolar tissue surrounding the bladder is bluntly dissected to expose the anterior bladder neck and perivesical spaces. A large cystostomy is created by making an anterior bladder wall flap through a curvilinear incision that positions the apex at the dome of the bladder and the base extending to the level approaching the trigone (Fig. 6). This type of cystostomy ensures a large dysfunctional disruption of the bladder musculature for increasing the linear length of bladder wall for bowel anastomosis. It is most useful in cases where the uterus

Placing the patient in extreme Trendelenburg position aids in displacement of the bowel loops from the pelvic cavity and facilitates the subsequent steps of the procedure.

is present and potentially prevents an adequate cystostomy incision. Furthermore, adequate exposure for enterovesical anastomosis in all of the procedures described previously is preserved by avoiding a closure of the deep posterior bladder wall incision in the pelvis that will be obscured by bowel and the isolated bowel segment to be used for the augmentation.

Enterovesical Anastomosis

Although different approaches can be used for intracorporeal suturing of the bowel segment to the bladder as shown in Figure 6, we prefer to begin by running the preplaced suture on the “posterior” wall of the reconfigured bowel patch to the apical aspect of the bladder flap in a medial to lateral direction on each side.

Completion of the posterior wall of the reconfigured bowel segment from an intravesical approach beginning medially and finishing laterally facilitates the best exposure to ensure a watertight anastomosis.

Completion of the posterior wall of the reconfigured bowel segment from an intravesical approach beginning medially (point A) and finishing laterally (points B and C, respectively) facilitates the best exposure to ensure a watertight anastomosis.

If one attempts to complete the anterior wall of the reconfigured bowel patch to the bladder first as shown in Figure 6, it may be difficult to visualize the suturing of the posterior wall anastomosis to the bladder owing to the constraints of pelvic anatomy. To complete a circumferential, continuous, full-thickness, single-layer anastomosis of the bowel to the bladder, we finish by running the preplaced sutures of the anterior wall of the reconfigured bowel patch and additional sutures as required. Free hand laparoscopic suturing and intracorporeal knot tying techniques are used exclusively for the entire procedure. Exposure of the operative field for intracorporeal suturing can be improved by temporarily fixing the anterior bladder flap to the abdominal wall. This not only opens the operative suturing field for easier identification of the bladder and bowel mucosal edges, but also stabilizes the tissues for rapid suture placement. At the completion of the anastomosis, the bladder is distended to confirm a watertight anastomosis.

A suction drain is inserted into the pelvic cavity through one of the lower lateral 5-mm port sites. Postoperative bladder drainage is maintained with a 22 French urethral catheter. Because a smaller urethral catheter may be preferred for postoperative drainage in males, a suprapubic tube may be placed through the bladder wall and externalized via the remaining lower port site.

The umbilical and remaining 10-mm ports are closed in layers. In patients who require a catheterizable stoma, the previously refashioned ileal segment is located and the attached red rubber catheter is grasped with an endoscopic clamp via the umbilical port site. After the pneumoperitoneum is decompressed, the terminal end of the ileal segment is delivered to the umbilicus and secured to the anterior rectus fascia and skin at the level of the umbilicus (Fig. 7). A Y-V flap maturation of the stoma to the skin of the umbilicus is performed using 4-0 chromic sutures. In obese patients, use of the umbilicus at the site of stoma formation decreases the amount of ileum needed to mature the stoma to the skin. A 16-Fr catheter is placed through the stoma and into the bladder to optimize bladder drainage and healing of the newly created catheterizable segment in the early postoperative period.

Postoperative Management

The oral-gastric decompression tube is removed before extubation. The suction drain is removed when the drainage is less than 25 mL or fluid chemistries suggest peritoneal fluid. The patient can be discharged when they are afebrile and able to complete three consecutive meals without abdominal distension, the first meal is usually started on the first postoperative day. Patients are discharged with the indwelling urethral catheter used for bladder drainage and three times daily bladder irrigation with 100 mL of sterile saline. Low-dose prophylactic antibiotics are continued during the first three postoperative weeks. At that time, the urinary catheter is removed and intermittent catheterization is initiated. For patients who have an indwelling catheter via the umbilical stoma, the catheter is usually capped at the time of hospital discharge, but may be used to flush the augmented bladder at the time of bladder irrigations.

Results

From 1999 to 2001, we performed laparoscopic enterocystoplasty in 18 patients with functionally reduced bladder capacities owing to neurogenic causes (Table 1). The procedures included ileocystoplasty (5), sigmoidocystoplasty (3), colcystoplasty (1),

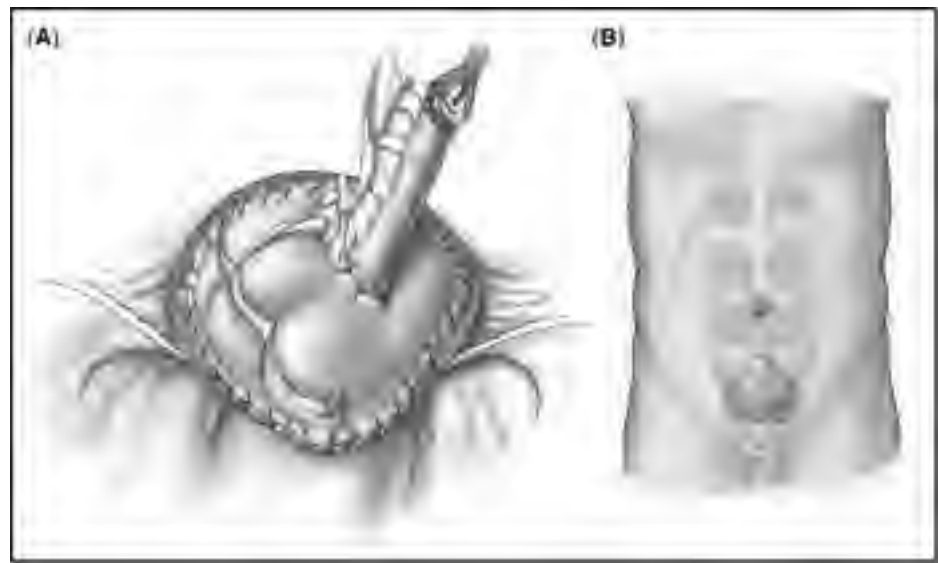


FIGURE 7 ■ Augmentation cecocystoplasty with formation of a continent catheterizable stoma. Complete view of the bowel to bladder anastomosis (A) in preparation for maturation of the catheterizable stoma to the umbilicus (B). *Source:* Courtesy of the Cleveland Clinic Foundation.

and cecocolocystoplasty with a continent catheterizable ileal stoma (9). Total surgical time from patient arrival to the OR until transportation to the recovery room ranged from 5.3 to 8 hours (average 7.0 hours). The time for laparoscopic suturing ranged from 1.7 to 3.1 hours (average 2.4 hours). Blood loss was minimal and did not exceed 250 mL in any of the cases (average 175 mL). The only intraoperative complication was a trocar-induced rectus sheath hematoma during the course of the sigmoidocystoplasty that was controlled laparoscopically. Oral feeding was resumed by 24 hours in 17 of 18 patients. Our first patient had a self-limited paralytic ileus that responded to conservative treatment. Despite the fact that most of the patients in this initial experience had moderate to severe forms of neurological dysfunction owing to multiple sclerosis, the average hospital stay until the patient was discharged home was only 5.7 days (range 3–7). Most

TABLE 1 ■ Laparoscopic Enterocystoplasty Experience

ID	Age (yrs)	Gender	Primary disease	OR time (hrs)	Blood loss	Hospital	Bowel segment Isolated
1	27	M	SUS	6	300	10	Ileum
2	49	F	MS	7	350	9	Sigmoid colon
3	30	F	SCI	7	200	5	Cecum and right colon and ileum
4	48	F	TM	3	60	6	Ileum
5	36	F	MS	8	150	6	Cecum and right colon and ileum
6	62	M	MS	5	300	4	Ileum
7	18	F	SCI	8	110	6	Cecum and right colon and ileum
8	46	F	MS	8	125	6	Cecum and right colon and ileum
9	52	F	MS	5	200	5	Sigmoid colon
10	23	F	SB	8	200	6	Rectal colon
11	38	F	MS	7	350	7	Cecum and right colon and ileum
12	45	F	SCI	9	550 l	5	Cecum and right colon and ileum
13	31	F	SCI	9	300	4	Cecum and right colon and ileum
14	58	F	MS	4	150	4	Ileum
15	27	F	SCI	7	200	3	Sigmoid colon
16	39	M	MS	8	200	4	Cecum and right colon and ileum
17	49	F	DI	8	200	3	Ileum
18	42	F	MS	6	100	5	Cecum and right colon and ileum

Abbreviations: OR, Operating room; SUS, sensory urgency syndrome; MS, multiple sclerosis; SCI, spinal cord injury; SB, spina bifida; D, detrusor overactivity.

notable was the absence of long-term or extended care needs for the patients with multiple sclerosis because of demands of wound healing or functional neurological loss that typically occur with an open procedure in this subset of patients.

All patients have been evaluated with preoperative and postoperative questionnaires concerning bladder (bladder control scale; BLCS) and bowel control (bowel control scale; BWCS). Fourteen patients [2 (14.4%) male and 12 (85.6%) female; mean age, 40 years (range 18–62)] have completed at least the sixth month postoperative questionnaires based on a mean follow-up of 17 months (range, 7–27). With regard to the quality of life measure using the BLCS, there was significant clinical improvement. The average improvement revealed a significant reduction from the baseline score of 14.9 ± 5.0 to 1.6 ± 1.8 , $P = 0.0002$. In regards to the potential risk of causing bowel dysfunction by harvesting various bowel segments for augmentation cystoplasty, there was no clinically significant difference in the bowel control score before or after the procedure when comparing the average change from 6.4 ± 6.5 to 5.3 ± 6.0 , $P = 0.30$.

Comparative Analysis of Open and Laparoscopic Approaches


In order to define the clinical outcomes of a laparoscopic approach to bladder reconstruction, we compared prospectively, our initial experience in laparoscopic augmentation cystoplasty with continent catheterizable ileal stoma to a similar cohort of patients who underwent an open approach. Eighteen consecutive cases of augmentation colocolocystoplasty with continent catheterizable ileal stoma were performed at our Institute; nine patients underwent the open approach (eight women and one man; mean age, 45 years, range 21–56), and nine cases underwent the laparoscopic approach (eight women and one man; mean age, 36 years; range, 18–46). All cases were performed by the same surgical team. Indications for the operation were reduced bladder capacity and/or compliance either due to a neurologic condition (mostly multiple sclerosis), or idiopathic refractory detrusor overactivity. Before the operation, all patients had urodynamically proven detrusor overactivity with incontinence that had failed conservative therapy. The right colon and terminal ileum were used in the operation with the cecum and ascending colon being used to augment the bladder, while 10 cm of terminal ileum with a reinforced ileocecal valve was used to create the catheterizable conduit and stoma at the umbilicus. Demographic data and baseline characteristics were recorded for patients in both groups. Bladder and bowel function and the patient's perception of their symptoms and quality of life were assessed by asking the patient to complete the two questionnaires mentioned earlier. One year after the operation, changes in the patients' symptoms, their quality of life and their perception of treatment outcome were reassessed. Perioperative and convalescence parameters for each patient in both groups were recorded including operative time (defined as the time from skin incision to final dressing as recorded by the anesthesia team), estimated intraoperative blood loss, hospital stay, postoperative oral intake time, and the time to meet the discharge criteria (three consecutive meals without developing nausea or vomiting) (Table 2).

The mean operative time for the open augmentation enterocystoplasty with catheterizable stoma formation was 278 minutes compared to 468 minutes for the laparoscopic series ($P < 0.001$). There was no significant difference between the two groups with regard to intraoperative blood loss. The mean estimated intraoperative blood loss in the laparoscopic series was 178 cc (range, 100–350) versus 248 cc for the open group (range, 100–500 cc) ($P = 0.4$). Both groups were significantly different in regard to the mean time to begin oral intake after the operation. Mean time to oral intake was significantly shorter after the laparoscopic approach (1.7 days) when compared with the open approach (5.2 days, $P < 0.0001$). The mean time necessary to meet the

TABLE 2 ■ Comparison Between Open and Laparoscopic Cecocolocystoplasty with Continent Catheterizable Ileal Stoma

	Open cases	Laprosopic cases	P value
Number of patients	9	9	
Gender (male/ female)	1/8	1/8	
Mean age	45	36	<0.09
Mean operative time (min)	278	468	<0.001
Mean blood loss (mL)	248	178	<0.15
Mean time to oral intake (days)	5.2	1.7	<0.001
Mean hospital stay (days)	8.2	4.4	<0.001
Mean bladder scale	2.2	3.8	<0.07
Mean bowel scale	0.15	0.2	<0.63

FIGURE 8 ■ Comparison between the bladder and bowel scale after open and laparoscopic approaches.



discharge criteria (three consecutive meals without developing nausea, vomiting, or abdominal distension) was significantly shorter with laparoscopic approach (mean, 2.8 days) than with open approach (mean, 7.1 days, $P < 0.0001$). The mean hospital stay until the patient was discharged home was significantly shorter with laparoscopic cases (mean, 4.4 days; range, 3–6) than with open cases (average 8.2 days, range 5–11) ($P < 0.001$). There was significant improvement in the bladder function as demonstrated by the BLCS after both open and laparoscopic approaches. The mean improvement in bladder function after the laparoscopic approach and after the open approach was 3.8 and 2.2, respectively. Improvement in bladder function was better after the laparoscopic approach ($P = 0.07$); there was no adverse effect on the bowel function after both procedures (Fig. 8).

Laparoscopic Ileovesicostomy and Augmentation

In the past three decades, clean intermittent catheterization proposed by Lapides has been accepted by the urologic community as an excellent method of management of the neurogenic bladder that fails to empty (8). However, this option may not be applicable for some patients such as those without manual dexterity and without assistance from care givers. In these cases, options may include the use of chronic indwelling urethral or suprapubic catheter or urinary diversion. Chronic catheter placement is frequently associated with complications including stone formation, tissue erosion, frequent infection and malignancy; therefore, it is uncommonly used as first-line definitive management (9). Urinary diversion, which traditionally takes the form of an ileal conduit involving ureteral reimplantation, may lessen the risk for catheter-associated problems. However, a different set of problems such as urinary reflux and ureteral obstruction may arise (10).

Incontinent ileovesicostomy providing low-pressure urinary storage and drainage was first introduced in 1994 to address the problems associated with conventional incontinent urinary diversions (11). Without ureteral mobilization or reimplantation, it decreases the operative time and avoids the risk for ureteral complications. Preserving the ureterovesical junction, it maintains the antireflux mechanism and prevents pyocystitis formation. Furthermore, it does not require the use of any catheter or foreign material, either intermittently or chronically. These advantages, together with excellent renal function preservation and the low rate of complications, have been confirmed by several recent reports with long-term follow-up. In fact, ileovesicostomy has been recommended as a better alternative to all other types of incontinent urinary diversion (12–14).

Prior to our publication in 2002, all ileovesicostomy procedures described were performed in the conventional, open manner. Similar to augmentation, the major surgical components of ileovesicostomy included the following: (i) bladder mobilization with cystotomy creation, (ii) harvesting of a well-vascularized bowel segment, (iii) establishment of bowel-to-bowel anastomosis with closure of the mesenteric window, and (iv) performance of full-thickness, mucosa-to-mucosa ileovesical anastomosis in a tension-free, watertight manner. Using the laparoscopic approach described below, we have been able to accomplish all these steps in four patients to date and use this technique as a primary approach to ileovesicostomy formation.

Surgical Technique

The patient is positioned in the dorsal lithotomy position and catheterized with a urethral catheter. After creation of a pneumoperitoneum, a five-port transperitoneal

laparoscopic approach is used. The bladder is distended with sterile saline solution and then mobilized anteriorly and laterally with standard laparoscopic techniques. An inverted U cystotomy is then made antero-superiorly with laparoscopic technique. The ileocecal junction and the distal 15 cm of ileum are laparoscopically identified. The distal margin of the ileal segment to be harvested is marked with a superficial electrocautery burn and then exteriorized through a 2-cm extension of the infraumbilical laparoscope port site. The pneumoperitoneum is then evacuated.

A 17-cm ileal segment proximal to the superficial electrocautery marking is harvested with conventional open techniques through the infraumbilical post site, with careful preservation of its vascular supply. Bowel-to-bowel continuity is restored in the side-to-side manner. The proximal end of the harvested ileal segment is opened with complete removal of the surgical staples. The segment is thoroughly irrigated with saline solution, and the proximal end of the bowel segment is spatulated for a distance of 3–4 cm along its antimesenteric surface. The bowel is then reintroduced into the abdominal cavity with the conduit caudal to the bowel anastomosis. The 2-cm extended infraumbilical incision is then closed and the pneumoperitoneum is re-established.

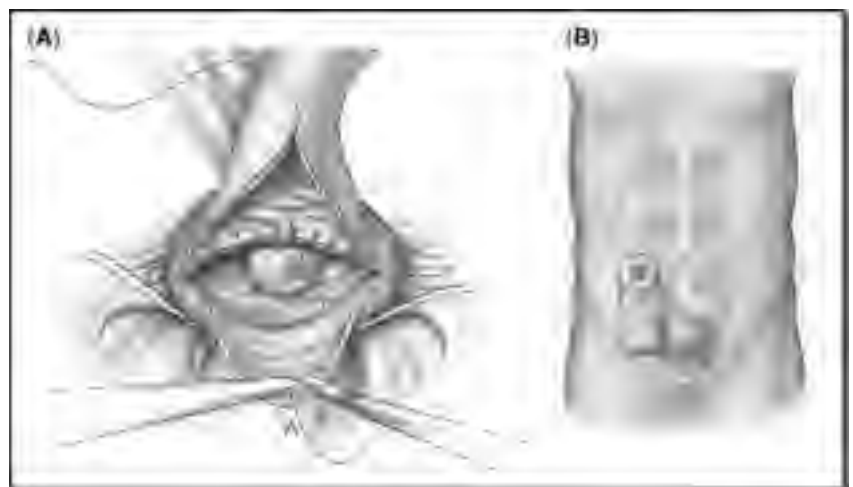
The mesenteric pedicle is first inspected carefully to prevent torsion. The spatulated proximal ileal end is oriented in relation to the cystotomy site. Single-layer ileovesical anastomosis with 2-0 absorbable sutures is then performed by laparoscopic free hand suturing and intracorporeal knot-tying techniques in a circumferential manner (Fig. 9). At the completion of the ileovesical anastomosis, the bladder is distended with saline solution via the urethral catheter to rule out leakage. The distal end of the ileal segment is brought to the skin level at the planned stoma site of the right 10-mm port site and a loop stoma or end stoma is created with open techniques. One suction drain is placed through the left 5 mm port site, with the rest of the port sites closed following evacuation of the pneumoperitoneum.

Isolation and reanastomosis of the exteriorized bowel through a 2-cm extension of an existing port site has been considered as an acceptable component of laparoscopic intestinal surgery (15). This approach provides several advantages including the ability to effectively evacuate residual fecal materials in the isolated bowel segment without significant intraperitoneal contamination, thereby minimizing abdomino-pelvic abscess formation.

RESULTS

Our results are comparable with the published surgical techniques utilizing an open approach. In the most recent report of traditional ileovesicostomy formation, the mean operative time was 4 hours (range, 2.8–6.6 hours), and the mean estimated blood loss was 403.8 cc (range, 50–2000 cc) (14). The laparoscopic operative time and blood loss presented here are well within the ranges of those in open surgery. Postoperatively, our patient resumed oral intake and physical activity quickly, had minimal narcotic requirements, and a short hospital stay. There are no detailed data on postoperative morbidity and convalescence in the recent literature for comparison. Our preliminary experience

FIGURE 9 ■ Laparoscopic ileovesicostomy formation: Anastomosis of the spatulated end of the proximal ileal loop end to the cystotomy site with intracorporeal suturing (A); maturation of the stoma to the laparoscopic port site (B). *Source:* Courtesy of the Cleveland Clinic Foundation.



appears to be promising. Further clinical experience and long-term follow-up will be necessary to confirm our findings and define the role of the laparoscopic approach for this technique of bladder augmentation and urinary diversion.

SUMMARY

- Laparoscopic augmentation enterocystoplasty with or without urinary diversion is technically feasible and successfully emulates the established principles of using an open approach while minimizing operative morbidity and maximizing clinical effectiveness.
- Various bowel segments can be fashioned and anastomosed to the bladder laparoscopically.
- The increased costs associated with laparoscopy and with minimally invasive surgery in general have been a significant disadvantage; however, a previous report on the costs of laparoscopic procedures concluded that increased surgical experience reduces the surgical time and length of the hospital stay, thereby decreasing the overall costs.
- The increased use of reusable instruments results in considerable economic benefits. Implementation of appropriate time and cost saving strategies will ultimately result in decreased expenses associated with laparoscopy (16).
- Although laparoscopic enterocystoplasty is currently a lengthy procedure lasting twice as long as open surgery, further technical modifications and increasing experience will continue to reduce the surgical time involved.
- Laparoscopic augmentation cystoplasty is an attractive option for patients with complex comorbid illnesses who desire an improved quality of life similar to that associated the traditional open procedure.
- A clinically significant positive impact on patient postoperative QOL related to bladder control compared with the preoperative status can be achieved using a laparoscopic approach, which does not negatively impact the patient's bowel control.
- Our experience suggests that laparoscopic enterocystoplasty with or without urinary diversion is a viable alternative to open enterocystoplasty.

REFERENCES

1. Hasan ST, Marshall C, Robson WA, Neal DE. Clinical outcome and quality of life following enterocystoplasty for idiopathic detrusor instability and neurogenic bladder dysfunction. *Br J Urol* 1995; 76:551–557.
2. Mundy AR, Stephenson TP. Clam: ileocystoplasty for the treatment of refractory urge incontinence. *Br J Urol* 1985; 57:641–664.
3. Rink RC, Adams MC. Augmentation Cystoplasty. In: *Operative Urology*. Edit. Bruce H. Stewart. Williams and Wilkins and Wilkins, Baltimore/London. 1982: 98–106.
4. Smith JJ, Swierzewewski SJ. Augmentation cystoplasty. *Urol Clin North Am* 1997; 24:745–754.
5. Mikulicz J. Zur Operation der angeborenen Blasenspalte. *Zentralbl Chir* 1899; 26:641.
6. Novick AC. Augmentation cystoplasty. In: *Burce H. Stewart, ed. Operative Urology*. Williams and Wilkins, Baltimore/London. 1982: 98–106.
7. Garrard CL, Clements RH, Nanney L, Davidson JM, Richards WO. Adhesion formation after laparoscopic surgery. *Surg Endosc* 1999; 13:10–13.
8. Lapides J, Diokno AC, Silber SJ, Lowe BS. Clean, intermittent self-catheterization in the treatment of urinary tract disease. *Trans Am Assoc Genitourin Surg* 1971; 63:92–96.
9. Perikash I. Long-term urologic management of the patient with spinal cord injury. *Urol Clin North Am* 1993; 20:423–434.
10. Pitts WR, Muecke EC. A 20-year experience with ileal conduits: the fate of the kidneys. *J Urol* 1979; 122:154–157.
11. Schwartz SL, Kennely MJ, McGuire EJ. Incontinent ileovesicostomy urinary diversion in the treatment of lower urinary tract dysfunction. *J Urol* 1994; 152:99–102.
12. Mutchnik SE, Hinson JL, Nickell KG, Boone TB. Ileovesicostomy as an alternative form of bladder management in tetraplegic patients. *Urology* 1997; 49:353–357.
13. Leng WW, Faerber G, Del Terzo M, McGuire EJ. Long-term outcome of incontinent ileovesicostomy management of severe lower urinary tract dysfunction. *J Urol* 1999; 161:1803–1806.
14. Gudziak MR, Tiguert R, Puri K, Gheiler EL, Triest JA. Management of neurogenic bladder dysfunction with incontinent ileovesicostomy. *Urology* 1999; 54:1008–1011.
15. Milsom JW, Bohm B. Major operative procedures in laparoscopic colorectal surgery. In: *Milsom JW, Bohm B, eds. Laparoscopic Colorectal Surgery*. New York: Springer-Verlag, 1996: 122–123.
16. Hobart MG, Gill IS, Schweizer D, Bravo EL. Financial analysis of needlescopic versus open adrenalectomy. *J Urol* 1999; 162:1264–1267.

LAPAROSCOPIC BLADDER NECK SUSPENSION: TECHNIQUE AND RESULTS

Jim Ross

Center for Female Continence, Department of Obstetrics and Gynecology, University of California Los Angeles School of Medicine, Salinas, California, U.S.A.

Mark Preston

Gynecologic Center for Women's Health, Waterbury, Connecticut, U.S.A.

<ul style="list-style-type: none"> ■ INTRODUCTION <ul style="list-style-type: none"> Burch Colposuspension: The Evolution of a Procedure Laparoscopic Colposuspensions ■ SELECTION, EVALUATION, AND ANATOMY <ul style="list-style-type: none"> Patient Selection Evaluation Surgical Anatomy ■ SET-UP, INSTRUMENTATION, AND SURGICAL PROCEDURE <ul style="list-style-type: none"> Set-Up Instrumentation 	<ul style="list-style-type: none"> Surgical Procedure ■ ENTRY INTO THE SPACE OF RETZIUS ■ OUTCOMES, COMPARATIVE STUDIES, COMPLICATIONS, AND COSTS <ul style="list-style-type: none"> Outcomes Comparative Studies Complications Costs ■ PARAVAGINAL REPAIR ■ SUMMARY ■ REFERENCES
---	--

INTRODUCTION

Burch Colposuspension: The Evolution of a Procedure

In 1961, Burch (1) published the development of a new technique for colposuspension, based on a technique started in 1958. A paramedian incision was used to enter the abdomen and space of Retzius. He instilled 50 cc of milk in the bladder to identify possible perforations. The periurethral tissue was cleaned off and then three 2.0 chromic sutures were placed at the midurethra and the bladder neck. These sutures were fixed to Cooper's ligament. In 1968, Burch (2) reported a subjective cure rate of 92% in 143 patients with 10 to 60 months of follow-up.

Tanagho (3) suggested several refinements to increase the cure rate for Burch colposuspension (Table 1). Tanagho stressed that the importance of the surgical repair "is to preserve the initially intact sphincteric mechanism, to restore its proper position, and to provide it with adequate support." This was achieved by clearing off the overlying fat, while staying at least 2 cm lateral to the urethra and urethrovesical junction. Elevation of the anterior vaginal wall by the surgeon's hand enabled the dissection and correct placement of absorbable sutures at the midurethra and lateral to the urethrovesical junction. He stressed the formation of a "hammock" of support without compressing the urethra against the pubic bone, while elevating the vaginal wall to approximately 2 cm below Cooper's ligament. Many physicians consider the Burch-Tanagho colposuspension the "gold standard" for the treatment of primary genuine stress incontinence. We feel the laparoscopic colposuspension must include the Burch-Tanagho technique in order to be called a laparoscopic Burch colposuspension, and any variation on this technique in this chapter will be simply called a laparoscopic colposuspension.

Laparoscopic Colposuspensions

In 1991, Vancaillie and Schuessler (4) attempted the first laparoscopic retropubic repair, a Marshall-Marchetti-Krantz, and in 1992 (5) reported a series of laparoscopic Marshall-Marchetti-Krantz and Burch colposuspensions. Over the next few years, several others (6-8) reported larger series. Before widely recommending the laparoscopic procedure, cure rates better or comparable to open surgery need to be demonstrated.

SELECTION, EVALUATION, AND ANATOMY

Patient Selection

After the diagnosis of genuine stress incontinence is made, the physician and the patient determine the necessity of surgery, usually after a trial of more conservative treatment.

TABLE 1 ■ The Tanagho Principles for Burch Colposuspension

1. Remove paraurethral fat out to lateral sidewalls.
2. Keep dissection 2 cm from urethra and bladder neck.
3. Elevate paraurethral tissue with vaginal hand during dissection and suture placement.
4. Clean off Cooper's ligament.
5. Place a right and left suture through the paraurethral tissue 2 cm lateral to the midurethra and up through Cooper's ligament.
6. Keep paraurethral tissue elevated with vaginal hand while tying.
7. Repeat bilateral suture placement 2 cm lateral to the bladder neck and through Cooper's ligament.
8. Do not over-correct when tying the sutures, leaving 2 cm between pubic ramus and the urethra.

Relative contraindications for laparoscopy include history of severe abdominal or pelvic adhesions, prior incontinence procedures, intrinsic sphincter deficiency, or the necessity of other abdominal procedures requiring laparotomy.

The decision to perform the Burch procedure through an open or laparoscopic technique depends on the patient's history and the skill of the surgeon.

Relative contraindications for laparoscopy include history of severe abdominal or pelvic adhesions, prior incontinence procedures, intrinsic sphincter deficiency, or the necessity of other abdominal procedures requiring laparotomy.

Many physicians will only treat primary genuine stress incontinence, but the author (9,10) and others (11) have successfully treated recurrent genuine stress incontinence laparoscopically. Prior procedures such as anterior vaginal repair, needle suspensions, Marshall–Marchetti–Krantz, Burch, and bone anchor procedures are not absolute contraindications.

Laparoscopic Burch has been used to successfully to treat patients with low urethral closure pressure, low Valsalva leak point pressure, and urethral hypermobility. Laparoscopic Burch is not the surgery of choice with a frozen urethra.

Evaluation

In many clinics, a basic evaluation consists of history, physical exam, urine culture and sensitivity, 24-hour urolog, quality-of-life questionnaires, cystoscopy, bladder neck ultrasound, cough stress test, postvoid residual, and multichannel urodynamics.

When obtaining history, besides in-depth questions about urinary complaints and pelvic support problems, patients are questioned in detail about obstructive defecation and fecal incontinence. In our clinic, 23% of patients with severe genuine stress incontinence or pelvic organ prolapse have fecal incontinence, which is in agreement with others (12–15). Many have obstructive defecation associated with rectal prolapse, rectocele, and intussusception (16,17). When there is a history of fecal incontinence or obstructive defecation, we include anal manometry, anal ultrasound, and pudendal nerve terminal motor latency studies to aid in the treatment plan. A basic filling cystometrogram with Valsalva leak point pressure is essential if multichannel urodynamic testing is not available.

Surgical Anatomy

It is essential to understand the anatomy of the anterior wall and the pelvis to safely perform laparoscopy. There are several vessels and nerves that come into play with laparoscopic pelvic procedures. The first vessels at risk from trocar placement are the great vessels (aorta/vena cava) at the infraumbilical site. The umbilicus is at the L3–L4 level and, in women with thin to normal body habitus, the aortic bifurcation is at L4–L5. In obese women, the umbilicus is lower. In thin to normal-sized women, the infraumbilical trocar is placed at a 45 degree angle inclined toward the pelvis, while in an obese female, the trocar can be placed closer to a 90 degree angle. The left common iliac vein crosses over the lateral half of the lower lumbar vertebrae and can be inferior to the umbilicus, making it susceptible to injury at trocar insertion or when exposing the sacral promontory. The common iliac vessels course 5 to 6 cm lateral from the midline before bifurcating into the internal and external common iliac vessels.

The inferior epigastric artery, arising from the distal portion of the external iliac artery, crosses the medial border of the inguinal ligament and runs along the inferior lateral edge of the rectus muscle to anastomose with the superior epigastric artery, a branch of the internal mammary artery (Fig. 1). Two inferior epigastric veins accompany the artery. The superficial epigastric artery arises from the femoral artery 1 cm below the inguinal ligament and passes through the femoral sheath to supply the superficial area of the abdominal wall, up to the umbilicus. If the patient is thin, this vessel can be transilluminated.

The obturator artery is one of the terminal branches of the internal iliac artery and is found on the lateral pelvic sidewall, leaving the pelvis via the obturator canal along with the obturator nerve (Fig. 2). It gives off a pubic branch, which anastomoses with

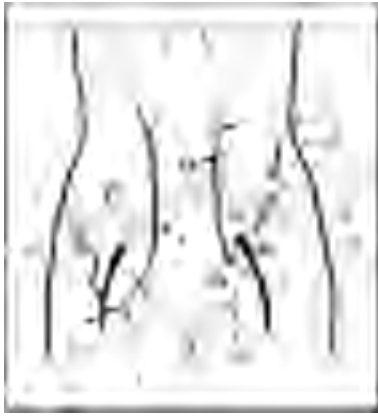

FIGURE 1 ■ Abdominal wall vascular and neural structures at risk during laparoscopy and normal trocar sites. (A) Superficial circumflex artery, (B) femoral artery, (C) superficial inferior epigastric artery, (D) external iliac artery, (E) inferior epigastric artery, (F) iliohypogastric nerve, (G) ilioinguinal nerve, (H) 10-mm trocar sites, (I) 5-mm trocar sites.

the pubic branch of the inferior epigastric artery to supply the posterior surface of the symphysis. In 25% of patients, an accessory obturator artery arises from the inferior epigastric artery. In approximately 4% of patients, both an obturator and an accessory obturator branch are present. Care must be taken with these vessels, because they complete an anastomotic circle of vessels between the internal and external iliac arteries, referred to as the circle of death in many surgical texts. Damage to any vessel in this circle can result in significant hemorrhage.

Neuropathies can occur from nerve damage or entrapment during laparoscopic surgery. Lateral trocar placement can damage the iliohypogastric and ilioinguinal nerve, leading to sharp pain in the suprapubic or groin area (18) (Fig. 1). Obturator nerve damage can occur during dissection of the space of Retzius or with paravaginal repairs, causing sensory loss to the medial thigh and difficulty in ambulating (19).

SET-UP, INSTRUMENTATION, AND SURGICAL PROCEDURE

Set-Up

It is helpful to place a video monitor lateral to each thigh of the patient, if two monitors are available. If only one monitor is available, we find it helpful to position it between the patient's legs so we are turned toward the patient's pelvis as we operate. This helps in judging spatial relationships. The surgeon stands on the left and the assistant on the right, with the scrub nurse next to the surgeon beside the patient's left thigh. The patient is in a supine position and her legs are placed in low AllenTM stirrups for easy maneuverability. A three-way 20-French Foley is placed in the bladder. Methylene blue is added to the saline and attached to the Foley.

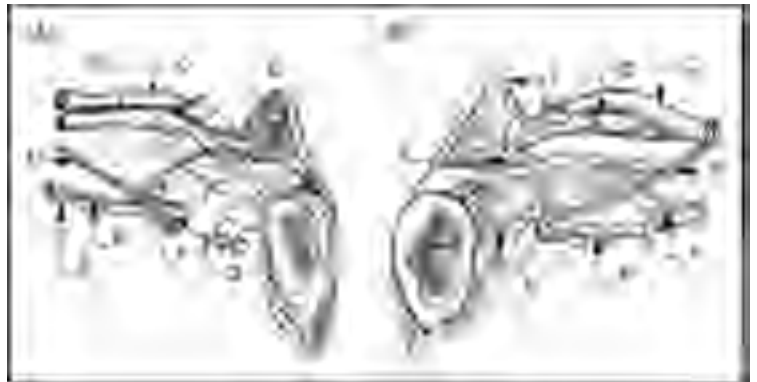Instrumentation

A "saddle bag pouch" is draped over the patient's right thigh to conveniently place frequently used instruments such as monopolar spatula, scissors, bipolar forceps, graspers, blunt-tipped dissectors, needle holders, and suction-irrigation device. We find the monopolar spatula, set at 50 to 90 W pure cut, to be a very useful tool to enter the space of Retzius. It is used for dissection on its thin side and as small vessels come into the operating field, it is turned to the broad side for coagulation. We use Talon 90-degree self-righting needle holders with spring handles^b. A 0 polydioxone on a C-1 needle^c is used for the four Burch sutures and the closure of the space of Retzius. If paravaginal sutures are needed, interrupted figure-of-eight 2.0 Prolene sutures are used. Four disposable trocars^d are used: 10-mm infraumbilical, 10-mm left lateral, 5-mm right lateral, and 5-mm suprapubic. The Inlet Closure Device^e is used to close all 10-mm or greater trocar sites and any 5 mm site used for back loading needles. An open-ended knot pusher is used for extracorporeal knots.

Surgical Procedure

The patient's legs are placed in low Allen stirrups and a three-way Foley is put in the bladder.

FIGURE 2 ■ Obturator and Accessory Obturator Artery. (A) Normal Obturator artery, present 70 percent. A Obturator a.; B Obturator v.; C External Iliac a.; D External Iliac v.; E Inferior Epigastric a.; F Obturator branch anastomosing with pubic branch of the Inferior Epigastric a.; G Pubic a. branch, H Obturator nerve. (B) Accessory Obturator, present 25%. Five percent of patient have a combination of A and B. A, Obturator a., B, Obturator v.; C, External Iliac a.; D, External Iliac v.; E, Inferior Epigastric a.; F, Pubic branch of the Inferior Epigastric a.; G, Pubic a. branch supplying pubic ramus; H, Obturator nerve.



^aAllen Medical, Garfield, OH.

^bCook OB/GYN, Spencer, IN.

^cEthicon, Inc., Somerville, NJ.

^dEthicon EndoSurgery, Cincinnati, OH.

^eInlet Medical, Inc., Eden Prairie, MN.

The patient should be flat and not in Trendelenburg, which can bring the pelvic vessels closer to the abdominal wall.

The patient should be flat and not in Trendelenburg, which can bring the pelvic vessels closer to the abdominal wall.

The infraumbilical area is infiltrated with marcaine 25% (as are all of the trocar sites) and a stab incision is made. Preemptive anesthesia significantly decreases postoperative pain.

Veress needle or open Hasson technique is employed to achieve pneumoperitoneum (20). Once the abdominal pressure reaches 15 mmHg, the infraumbilical trocar is passed into the abdomen through the umbilical aponeurosis. The laparoscope, with video camera, is inserted. The left lateral port area is transilluminated to identify the superficial inferior epigastric vessels. A skin incision is made, and the 10-mm trocar, with a 5-mm reducer, is passed through the abdominal wall under direct vision. The same technique is used to place the right lateral and suprapubic 5-mm trocar. At this point, the patient can be placed in Trendelenburg in order to visualize the pelvis. After the initial abdominopelvic inspection is done, approximately 150 cc of methylene blue saline are instilled through the Foley catheter to delineate the borders of the bladder. The surgical landmarks for the initial peritoneal incision into the space of Retzius are the right and left obliterated umbilical arteries, slightly lateral and superior to the pubic tubercles. A transverse incision is made approximately 3 cm above the inferior aspect of the pubic bone from one obliterated vessel to the other. In the midline, care should be taken as the obliterated urachus, which can be vascular, is incised. It is important to remember that the patient is in Trendelenburg position and to not direct the dissection perpendicular to the pubic bone, but rather to dissect in an upward fashion. This will prevent inadvertent cystotomy. The pubic bone is identified under the retroperitoneal fat layer and can be followed into the space of Retzius. The correct plane is composed of fine areolar tissue and fat, which can be easily swept away with the spatula.

The Foley bulb is identified and care is taken to stay at least 2 cm lateral to the urethra. Adipose tissue is not removed from the anterior surface of the urethra. The surgeon's left hand is placed in the vagina to elevate the lateral paraurethral tissue, which greatly aids dissection. The rich venous plexus adherent to pubocervical fascia can be coagulated as necessary. On the sidewall, the arcus tendineus of fascia pelvis (arcus white line), along with the branching of the arcus tendineus of the levator ani, is identified. The obturator vessels and nerve are identified entering the obturator canal. The ischial spine is directly below the obturator canal. The Cooper's ligament is identified along the superior surface of the pelvic bone and cleaned off. The first absorbable 0 PDS suture^f is placed 2 cm lateral to the midurethra as this tissue is elevated with the vaginal hand. A large purchase of tissue is taken. A figure-of-eight suture is not necessary, as demonstrated by Burch and Tanagho (1,3). The needle is passed up through the Cooper's ligament, and while the vaginal tissue is elevated, the suture is tied with an extracorporeal knot utilizing an open-ended knot pusher (Table 2).

The vaginal tissue should not be pulled all the way up to Cooper's ligament because this may result in overcorrection of the urethrovesical angle and possibly kink the ureter.

The vaginal tissue should not be pulled all the way up to Cooper's ligament because this may result in overcorrection of the urethrovesical angle and possibly kink the ureter.

We leave approximately 2 cm of space between the suture and Cooper's ligament and a similar space between the urethra and pubic arch. The second suture is placed 2 cm lateral to the bladder neck and tied. Sutures are placed on the opposite side in similar fashion. At completion, the four sutures elevate the pubocervical fascia to form "dog ears," creating a hammock under the midurethra and bladder neck (Fig. 3). As the last two sutures are being placed, indigo carmine is given intravenously.

The final step is cystoscopy. It is essential that dye is seen coming from both ureteral orifices and that no sutures have penetrated the bladder wall. If the dye is not seen, the sutures must be removed from that side and replaced. We know of no reports of the ureter actually being caught in a Burch suture. The cause of ureteral obstruction is due to overelevation of the trigone, which crimps the ureter, preventing flow (21). After cystoscopy, the space of Retzius is closed with a continuous 0 PDS suture.

The Burch is always done last if there are concomitant procedures. The urethrovesical angle can be affected by other repairs done after the Burch, secondary to changes in the pelvic axis. We usually do uterosacral vaginal colpopexies prior to the Burch to prevent prolapse in the posterior pelvic compartment in any patient demonstrating vaginal support weakness. The Burch has been combined with anterior and posterior support procedures, sacrocolpopexy (9), laparoscopic hysterectomy, external anal sphincteroplasty (12), and rectopexy.

^fEthicon, Inc., Somerville, NJ.

TABLE 2 ■ Laparoscopic Burch Colposuspensions with Sutures

Name (Ref.)	Study type	N	Follow-up (mo)	Suture		Cure type of follow-up	%	Major complications (%)
				Type	No.			
Albala (5)	R	10	7	P	2	S	100	0
Liu (6)	R	107	3-27	P	4	O	97	7.4
Nezhat (7)	R	62	8-30	P	4	O	100	10
Radomski (36)	P	34	17	P	4	S	85	11.8
Papasakelariou (32)	P	32	24	P	4	S	91	6.3
Saidi (22)	R	70	12.9	P	4	S	91	NR
Ross (8)	P	32	12	DA	4	O	94	6.3
Ross (39)	P	35	12	DA	4	O	91	
Ross (9)	P	19	12	DA	4	O	93	
Ross (10)	P	48	24	DA	4	O	89	
Ross (12)	P	40	12	DA	4	O	89	
Ross (41)	P	87	>60	DA	4	O	84	

Abbreviations: Study type: R, retrospective; P, prospective; N, number of patients, suture type; P, permanent; DA, delayed absorbable; Cure: S, subjective; O, objective.

ENTRY INTO THE SPACE OF RETZIUS

The space of Retzius can be reached by an intraperitoneal or an extraperitoneal approach. The suggested advantages of the extraperitoneal approach include not entering the intraperitoneal cavity, decreased risk of vascular and bowel injury, and bypassing intra-abdominal adhesions (23–24). Decreased blood loss reportedly is due to instillation of CO₂ gas at 20 mmHg into the extraperitoneal space, causing compression of capillaries (23). Some authors suggest the extraperitoneal dissection allows better vision and gives the added advantage of using regional anesthesia (22,23). It also allows lower placement of trocars, making it easier to reach the operative field. At one center (24), extraperitoneal laparoscopic Burch was cheaper than open Burch (\$3100 vs. \$6000).

In several experiences, this extraperitoneal dissection is reported as faster and cheaper than open or laparoscopic transperitoneal Burch, with comparable cure rates and high patient satisfaction (22,25–27).

Possible complications include higher rates of cystotomy, subcutaneous emphysema, inadvertent entry into the peritoneal cavity, conversion to open or intraperitoneal Burch, and exclusion of patients with prior abdominal surgery (22,24,26). Prior surgery is not a contraindication in some centers (27,28).

Extraperitoneal laparoscopy can result in greater degrees of carbon dioxide absorption than transperitoneal surgery, increasing the chance of pneumomediastinum and pneumothorax (26,29).

Extraperitoneal access can be achieved via balloon dissector, operating laparoscope, direct vision trocar, or regular trocar, or by the surgeon's finger. The technique is started by making a small incision in the abdominal midline that is opened down to the preperitoneal space. Then, either a balloon or a trocar is placed in this potential space and carbon dioxide is instilled, opening the space of Retzius. Two 5-mm ports are placed

In several experiences, this extraperitoneal dissection is reported as faster and cheaper than open or laparoscopic transperitoneal Burch, with comparable cure rates and high patient satisfaction.

Extraperitoneal laparoscopy can result in greater degrees of carbon dioxide absorption than transperitoneal surgery, increasing the chance of pneumomediastinum and pneumothorax.

FIGURE 3 ■ (A) Superior (laparoscopic) view of space of Retzius with four Burch sutures in place. (B) Parasagittal view of Burch sutures attached to Cooper's ligament.



It is uncommon to see a patient who requires only a Burch colposuspension; therefore, the intraperitoneal technique is the more common approach in many centers.

When examining outcomes of Burch colposuspension procedures, a differentiation between procedures done with the true Burch-Tanagho technique and those utilizing multiple modifications in surgical techniques is important. The confusingly varied outcomes reported for the laparoscopic "Burch" result, in part, from a failure to make this differentiation between techniques.

3 cm above the suprapubic bone and 2 cm lateral to midline, avoiding the inferior epigastric vessels. The remainder of the procedure is carried out similar to the transperitoneal Burch. Mesh and tacks are utilized more often than sutures in the extraperitoneal Burch literature. Cure rates reported for both techniques are comparable to that for open Burch.

It is uncommon to see a patient who requires only a Burch colposuspension; therefore, the intraperitoneal technique is the more common approach in many centers (10,30–32).

Most patients requiring pelvic reconstructive surgery need additional procedures including apical vault support, paravaginal repair, anterior and/or posterior vaginal repair, or other intra-abdominal procedures (33).

OUTCOMES, COMPARATIVE STUDIES, COMPLICATIONS, AND COSTS

Outcomes

When examining outcomes of Burch colposuspension procedures, a differentiation between procedures done with the true Burch-Tanagho technique and those utilizing multiple modifications in surgical techniques is important. The confusingly varied outcomes reported for the laparoscopic "Burch" result, in part, from a failure to make this differentiation between techniques.

We will delineate the outcomes from laparoscopic classical Burch technique verses "modified Burch" procedures. As stated earlier, the laparoscopic Burch will refer only to procedures utilizing the Burch-Tanagho technique and all other procedures will be called laparoscopic colposuspensions.

In their initial report, Vancaillie and Schuessler (4) duplicated the Marshall-Marchetti-Krantz laparoscopically. Subsequently, the same group (5) reported 10 laparoscopic Burch colposuspensions, utilizing one suture per side. Several series reported laparoscopic Burch success rates of 89% to 100% with one to two-year follow-up (Table 3) (6,7,8,32,34–38). Liu (6) reported on 107 cases with 97% subjective cure rate over a follow-up of 3 to 27 months. He had a 10% complication rate including four cystotomies and one kinked ureter. He reported high patient satisfaction.

Extracting data from six different studies (8,10,12,33,39,41), we demonstrated an objective cure rate of 91% at one year in 178 patients. The majority of these patients showed objective cure by multichannel urodynamic testing. In most of these studies, patients with detrusor instability and intrinsic sphincter deficiency were excluded. The de novo detrusor instability rate was less than 9% with one to two years of follow-up, which is lower than that reported in most open Burch colposuspension studies (42–45). On urodynamic testing, there was a significant increase in pressure transmission ratio, functional urethral length, and maximum bladder capacity. There was no significant change in maximal flow rate. Multiple laparoscopic procedures for total vaginal vault prolapse and genuine stress incontinence were performed (33), including the first reported laparoscopic paravaginal repair. With the laparoscopic Burch alone, 97% of the patients were discharged in less than 24 hours and 93% voided spontaneously prior to

TABLE 3 ■ Comparison of Laparoscopic versus Open Burch Colposuspension

Author (yr)	Study type	N		Months follow-up:		Objective cure (%)			Subjective cure (%)		
				LSC	Open	LSC	Open	p value	LSC	Open	p value
Burton (66, 67)	P	30	30	12/36	12/36	73/60	97/93	<0.05/<0.05	NR	NR	
Ross (8)	R	32	30	12	12	94	93	NS	NR	NR	
Polascik (73)	R	12	10	20.8 (8-29)	35.6 (11-50)	83	70	NS	NR	NR	
Su (71)	P	46	46	>12	>12	80 ^a	96	0.04	NR	NR	
Lavin (70)	R	116	52	6	6	73	77		81	73	
Miannay (69)	R	36	36	12/24	12/24	NR	NR		79/68 ^a	69/64	NS/NS
Saidi (22)	R	70	87	12.9 (2-24)	16.3 (6-30)	NR	NR		91.4	91.9	NS
Summitt (69)	P	28	34	12	12	93	88	NS	NR	NR	
Carey (68)	P	96	104	6	6	69	80	0.1	100	95	0.12
Fatthy (72)	P	34	40	18	18	88 ^a	85 ^a	NS	NR	NR	
Huang (74)	R	82	75	12	12	NR	NR		84	89	0.49

^aModified Burch with one suture per side.

Abbreviations: Study type: P, prospective; R, retrospective; NR, not reported; NS, not significant.

discharge. When combined with multiple repairs including laparoscopic hysterectomy, posterior vaginal repair, apical vault repair, and sacrocolpopexy, 91% of the patients were discharged in less than 48 hours. The few patients who experienced delayed voiding had substantial posterior repairs or preoperative maximum flow rates of ≤ 15 cc per second. In the absence of these two factors, it was uncommon for a patient to not be able to void on the first postoperative day.

Cooper et al. (38) reported on 113 women in a retrospective study, with a mean follow-up of eight months. A combination of transperitoneal (94) and extraperitoneal (21) approaches were used. There was an 87% subjective cure rate. Fourteen percent of these patients had mixed incontinence. There were 10 cystotomies, one inferior epigastric vessel injury, one vaginal tear, one suture in the bladder, and one possible enterotomy. Papasakelariou and Papasakelariou (32) reported a subjective cure of 91% at two years. Flax (46) used gasless laparoscopy to perform Burch colposuspensions in 47 patients. A balloon was used to open the retropubic space and then a laparolift system was used for exposure in placing four Burch sutures. Forty-four of 47 patients—a 90% cure rate—needed no pads with a mean follow-up of 8.2 months. Persson and Wolner-Hanssen (47), in a randomized controlled study of 161 patients, demonstrated the importance of two sutures per side in the laparoscopic Burch colposuspension. One group of 78 had one double-bite and the other group of 83 had two single-bite sutures on each side. At one year, the objective cure rate was 58% and 83%, respectively ($p = 0.001$). These findings support the necessity of two sutures per side for optimum results and give a possible explanation for the high failure rate reported by many with a single suture per side. Persson stopped this study before he reached adequate numbers of patients required to power the study, because of poor outcomes in patients with one suture per side.

There are numerous reports of modified laparoscopic colposuspensions with varying results. The majority of these modifications are attempts to minimize intracorporeal laparoscopic suturing in order to simplify the procedure.

The staple-mesh technique was first reported in 1993 (48). After opening the space of Retzius and removing the fat from the paraurethral area, the vaginal hand elevates the tissue 2 cm lateral to the bladder neck and a one by three centimeter strip of Prolene hernia mesh is attached with two to three staples. With the tissue still elevated, the other end of the mesh is stapled to Cooper's ligament. All 40 patients, with a mean follow-up of six months, reported improved voiding and resolution or improvement of symptoms. At five years (49), 27 patients were seen in the office and seven returned questionnaires. The five-year success rate, defined as no recurrent leaking by history, was 88% (30 of 34 confirmed outcomes). These authors recommend this procedure for the advantages of a shorter learning curve and good outcome, as reported by others (50,51).

We performed a randomized controlled study comparing laparoscopic suture Burch (35 patients) and laparoscopic staple-mesh colposuspensions (34 patients). At one year, the objective cure rates were 91% and 94%, respectively.

In a work in progress, the five-year follow-up showed a significant difference, with an 84% cure for the suture group and 57% cure for the staple mesh ($p < 0.003$) (Ross, unpublished data). Reentry into the space of Retzius was extremely difficult in the staple-mesh group, secondary to extreme scarification. The mesh had pulled away from the pubocervical fascia in the several patients who had repeat surgery. We no longer use this technique due to our high long-term failure rate and the difficulty in additional surgery. Others (52,53) have reported similarly poor long-term outcomes.

McDougall (54) compared modified laparoscopic colposuspension to a Raz procedure, reporting similar one-year outcomes. In the laparoscopic colposuspension, two braided sutures were placed in the endopelvic fascia on each side and tied intracorporeally. The sutures were then passed through Cooper's ligament and secured with a polydioxanone clip. In a retrospective long-term review (54) (mean 45 months, range 17–71 months), only 15 of 50 patients with laparoscopic colposuspension and 10 of 29 patients who underwent Raz procedures were continent. In addition, there was a 28% rate of urge incontinence. The failure of delayed absorbable clips could possibly play a role in the early poor outcomes reported. Two more studies reporting poor long-term outcomes used different ways of suturing. At 36 months, laparoscopic colposuspensions done with bone screws had a 40% cure rate by patient questionnaires. Das, Lobel and Davis (57) used a variety of suturing techniques utilizing curved needles, straight needles, and Stamey needles. Many of these patients had one suture per side and at 36 months, the cure rate was 69% and improved 11%. There are several reports utilizing different types of needle to incorporate transvaginal tissue, transfix Cooper's ligament, or to fix sutures to the abdominal wall with buttons to complete a laparoscopic

There are numerous reports of modified laparoscopic colposuspensions with varying results. The majority of these modifications are attempts to minimize intracorporeal laparoscopic suturing in order to simplify the procedure.

We performed a randomized controlled study comparing laparoscopic suture Burch (35 patients) and laparoscopic staple-mesh colposuspensions (34 patients). At one year, the objective cure rates were 91% and 94%, respectively.

colposuspension (58–61) Harewood, (62). It is difficult to compare these studies to studies utilizing the traditional Burch–Tanagho procedure.

Other variations in sutures include a staple-suture procedure (63), in which a hernia stapler is used to staple a Gore-Tex suture to the pubocervical fascia and then to Cooper's ligament. The free ends of the suture are then tied with an extracorporeal knot to help set the height of elevation. No outcome data for the 60 patients treated with this technique have been published. In the Nolan–Lyons procedure (64), the pubocervical tissue is pulled up through an endoloop, which is tightened down to hold the tissue. The endoloop is used to pull the tissue to the desired elevation and then stapled to Cooper's ligament. Lyons reported a 92% subjective cure rate at 12 months. No long-term data have been reported. Kiilholma et al. (65) performed a modified colposuspension on 17 patients by applying fibrin sealant glue to the urethrovesical junction on each side of the bladder neck. Then, placing the first and middle finger in the vagina, the urethrovesical junction was pressed to the retropubic periosteum and held there for five minutes. Twelve patients were followed for 12 months; 10 reported being completely dry and two were improved.

In 1999, we reported an 85% objective cure rate at five years in a prospective longitudinal study of 87 women who had undergone laparoscopic Burch (41). Objective cure was defined as no evidence of genuine stress incontinence, detrusor instability, or intrinsic sphincter deficiency on urodynamic testing or CST. In addition, bladder neck ultrasound at maximum cystometric capacity was used on many patients. The laparoscopic technique duplicated the open Burch–Tanagho except for the mode of entry into the space of Retzius. All patients voided spontaneously before discharge at 24 hours, or 48 hours if they had a concomitant laparoscopic hysterectomy. All patients were on oral pain medication in less than 12 hours. Treatment failures were greatest in the first year after surgery. There were no additional failures in the fourth year and only one in the fifth year. There was a positive correlation between failure and severity of pelvic organ prolapse at the time of repair.

Comparative Studies

Ideally, comparisons between surgical procedures should be based on the long-term results of direct, head-to-head studies in which cohorts of similar patients are prospectively randomized to undergo one of the different procedures to be studied, and follow-up evaluation is conducted by practitioners blinded as to which procedure the patients have undergone. Unfortunately, it is often difficult to get patients to agree to randomization after two different procedures have been described as successful, making randomized controlled studies rare. The following studies compare the clinical outcomes of laparoscopic Burch colposuspension with those of the open Burch colposuspension, laparoscopic colposuspension with mesh and staples, tension-free vaginal tape suburethral sling, and bone anchor suburethral slings. For comparison purposes, the laparoscopic Burch colposuspension is defined as the Burch–Tanagho colposuspension performed via laparoscopic access.

Laparoscopic vs. Open Burch Colposuspension

There are five prospective, randomized controlled studies comparing open and laparoscopic colposuspension in the literature. Three of these studies utilized the classic Burch–Tanagho technique, and two modified the technique by using one suture per side in most cases. All three studies utilizing the Burch–Tanagho technique have been reported in abstracts. Burton (66,67) reported a randomized controlled trial comparing open and laparoscopic Burch, utilizing absorbable suture. His study included 30 patients with moderate to severe genuine stress incontinence in each arm followed for three years postoperatively. Superior results, in terms of both subjective and objective cure, were noted in the open arm, both at one- and three-year follow-up. Objective cure, defined as no genuine stress incontinence on video cystourethrography at one year, was noted in 97% of the open cases and 73% of the laparoscopic cases. At three years, the open procedure maintained a 93% objective cure rate, while the laparoscopic cure rate had dropped to 60%. Burton has been criticized for having done only 10 laparoscopic procedures prior to the onset of the study. Subsequently, two multicenter studies demonstrated no significant differences in outcomes between the two procedures. Carey et al. (68), in a multicenter study involving 200 patients with proven genuine stress incontinence randomized to open or laparoscopic Burch colposuspension, showed six-month objective urodynamic cure rates of 80% and 69% for the two procedures, respectively, and subjective success of 95% and 100% between the two procedures, respectively. Neither difference was statistically significant. Summitt et al. (69), in a multicenter trial involving 28 laparoscopic procedures and 34 open procedures, demonstrated objective one-year success rates of 92.9% for the laparoscopic Burch and 88.2% for the open Burch.

Lavin et al. (70) had cure or improvement of 71% and 91% in a laparoscopic Burch group and 67% and 89% in an open Burch group at six months. At two years, cure and improvement had fallen to 58% and 77% in the laparoscopic group and 50% and 59% in the open group. Saidi et al. (22), in a retrospective study, compared 70 patients with laparoscopic Burch to 87 patients with open Burch and reported 91% and 92% objective cure at 12 months, respectively.

Prospective randomized studies in which one stitch per side was utilized have shown mixed results. Su et al. (71), utilizing two to three stitches per side for open colposuspensions but only one stitch per side on most of their laparoscopic colposuspensions, showed objective cure rates of 80.4% and 95.6% for laparoscopic and open colposuspensions, respectively. These patients had a minimum one-year follow-up and objective cure was defined as dry on urodynamic testing. Interestingly, on a one-hour extended pad test, the laparoscopic group showed a slightly greater improvement than the open group, although there was no statistically significant difference between the groups pre- or postoperatively with respect to this measure. As previously discussed, the difference between one stitch and two per side likely accounts for the difference in outcomes. In 2001, Fatthy et al. (72) published a study in which one suture per side was utilized for both the open and laparoscopic colposuspensions.

Prospective randomized studies have shown no statistically significant difference in objective cure (by urodynamic testing), with cure reported in 87.9% of the laparoscopic cases and 85% of open cases after a follow-up of 18 months.

There are three published retrospective cohort studies comparing open with laparoscopic Burch, utilizing the classic Burch-Tanagho technique. Ross (8) reported one-year objective cure rates of 94% and 93%, respectively, for the laparoscopic and open approaches in a cohort study involving 30 patients followed prospectively in the laparoscopic arm compared to a retrospective evaluation of 32 in the open arm. That same year, Polascik et al. (73) reported on a retrospective cohort study, showing a subjective cure rate of 83% using the laparoscopic approach with a mean follow-up of 20.8 months versus 70% via the abdominal route with a mean follow-up of 35.6 months. More recently, Huang and Yang (74), in a retrospective cohort study, reported one-year subjective cure rates of 84% and 89% for laparoscopic and open Burch colposuspensions, respectively. There were no statistically significant differences in cure rates between the two approaches in any of these three studies. Miannay et al. (75) also demonstrated no difference in subjective cure rates at one and two-year follow-up between open and laparoscopic colposuspension, even though only one suture per side was utilized in the laparoscopic cases.

Laparoscopic Burch studies report the following advantages: a shorter length of stay with the laparoscopic approach was noted in all but one study in which this parameter was studied (3,5–7,9,11,12,74). Likewise, significantly less postoperative pain (5–7,12) and a quicker return to normal activity were noted in the laparoscopic group (5,7,11,12). When reported, complications did not differ statistically. The data from these studies are, for the most part, consistent with prior noncomparative studies of laparoscopic Burch colposuspension.

Overall, laparoscopic Burch colposuspension, when performed in an identical fashion to the open Burch, yields one-year results comparable with those of the open Burch and results in less post-operative pain, a shorter hospital stay, and a quicker return to normal activity. Long-term comparative data are still lacking.

Laparoscopic Burch vs. Tension-Free Vaginal Tape Suburethral Sling

It has been almost a decade since Ulmsten et al. (76) described the tension-free vaginal tape suburethral sling procedure and reported on his early successes. The rapid rise in popularity of the tension-free vaginal tape procedure has coincided with the rise in popularity of the laparoscopic Burch colposuspension as minimally invasive procedures for the cure of genuine stress urinary incontinence. Both procedures have their cadre of proponents, with laparoscopic Burch colposuspension advocates noting the longer track record of the Burch procedure, the ability to visualize the surgical field, and the lack of concern over erosion, while tension-free vaginal tape advocates point to shorter duration of surgery, slightly shorter recovery, relative ease of the procedure, and perceived lower cost. To date, there have been two prospective, randomized controlled trials published comparing the two procedures and one large prospective randomized controlled trial comparing tension-free vaginal tape with the open Burch procedure.

Persson et al. (77) reported one-year follow-up data on their prospective randomized trial comparing tension-free vaginal tape with laparoscopic Burch colposuspension. Their study, assessing 31 patients in the laparoscopic arm and 37 patients in the

Prospective randomized studies have shown no statistically significant difference in objective cure (by urodynamic testing), with cure reported in 87.9% of the laparoscopic cases and 85% of open cases after a follow-up of 18 months.

Overall, laparoscopic Burch colposuspension, when performed in an identical fashion to the open Burch, yields one-year results comparable with those of the open Burch and results in less post-operative pain, a shorter hospital stay, and a quicker return to normal activity. Long-term comparative data are still lacking.

tension-free vaginal tape arm, demonstrated no significant difference in efficacy between the two procedures, with objective cure rates (defined as a negative short pad test) of 87% and 89%, respectively, for the laparoscopic Burch and tension-free vaginal tape. Interestingly, subjective cure rates were markedly lower in both groups, 52% and 57%, respectively. These findings were based on a strict questionnaire and there was no significant difference between the two. Ustun et al. (78) reported a study of 46 patients with genuine stress incontinence randomized to undergo laparoscopic Burch ($n = 23$) or tension-free vaginal tape ($n = 23$) who were followed for up to 24 months postoperatively. They showed an objective cure rate of 82.6% in both groups. The laparoscopic Burch group had a mean follow-up of 13.5 months, and the tension-free vaginal tape group with 11.3 months. Cure was defined as subjectively dry, negative stress test, and no leakage on urodynamic testing performed at three months.

Ward and Hilton (79) recently published two-year data on their ongoing prospective randomized controlled trial comparing tension-free vaginal tape with open Burch colposuspension. The two-year follow-up data for objective cure by negative pad test was not statistically different between the two procedures, with 81% of tension-free vaginal tape patients and 80% of open Burch patients cured. Sixty-two percent of the patients with the open Burch procedure and 60% of tension-free vaginal tape patients reported being dry in this study. These findings are in agreement with other studies comparing these procedures.

There are few studies with direct comparisons of complication rates, costs, length of stay, and perioperative convalescence between laparoscopic colposuspension and tension-free vaginal tape. In Persson and Wolner-Hanssen's study (47), the authors noted a statistically shorter operating time and fewer postoperative visits in the tension-free vaginal tape group. There was also a trend toward earlier discharge in the tension-free vaginal tape group. Ustun et al. (78) reported shorter operating room time and length of stay in the tension-free vaginal tape group. These data are, for the most part, consistent with noncomparative data on tension-free vaginal tape, which generally show operating time shorter than that reported in most studies for laparoscopic Burch. In general, the more experienced the laparoscopist, the smaller the difference in time between the two procedures. Despite the shorter operating room time, Persson and Wolner-Hanssen (47) found the total cost of tension-free vaginal tape to be higher than that of the laparoscopic Burch, because of the high cost of the tension-free vaginal tape set. Cost comparisons are notoriously difficult not only because of differences in surgery times among different surgeons but also because operating roomtime costs per minute differ among different locations. There are no studies with direct comparisons of intraoperative and postoperative complications.

In a prospective randomized study comparing immediate outcomes of tension-free vaginal tape and laparoscopic mesh colposuspension, Valpas et al. noted no major differences in intraoperative or postoperative complications. Likewise, Debodinance et al. (81), in a retrospective review of all 800 female anti-incontinence procedures performed at their hospital over 13 years, showed no major differences in intraoperative or immediate postoperative complications between tension-free vaginal tape and laparoscopic Burch colposuspension. He did note higher de novo voiding difficulties (18.5% vs. 0%) and de novo urgency (11% vs. 4.8%) in tension-free vaginal tape when compared to laparoscopic Burch colposuspension. Valpas et al. (80) demonstrated a shorter duration to complete bladder emptying and reduced pain medication consumption in the tension-free vaginal tape group.

Laparoscopic Burch vs. Bone-Anchored Sling

In addition to tension-free vaginal tape, transvaginal bone-anchored sling procedures have been introduced in an attempt to provide a minimally invasive sling for the treatment of female genuine stress incontinence. There are no long-term follow-up studies beyond 36 months for bone-anchored slings and no comparative studies. There is no prospective data or objective outcomes analysis.

Studies reporting on bone-anchored slings utilizing cadaveric fascia for the sling component demonstrate cure rates ranging from 37% to 78%, with mean follow-ups of 10.6 and 30 months (82–84). Suspected failure of the cadaveric material is the given for the poor results. The best results are a 78% subjective cure rate with a mean follow-up of 12.4 months, obtained utilizing Tutoplast cadaveric fascia lata. Complication rates were low, though de novo urge incontinence was noted in 58% of patients in one study (83).

Three studies utilized coated polyester for the sling component. Cure rates were 61.5% at a mean follow-up of 11.4 months (85) to 90% with a minimum follow-up of 24 months (86). The latter study excluded patients with ISD. Giberti and Rovida (87) reported

a 100% failure rate with four patients with intrinsic sphincteric deficiency. Erosion and impaired wound healing were a significant problem in two of these studies, affecting 16% (87) and 53.8% of patients (85). Rates of de novo urgency and/or voiding dysfunction ranged from 8.6% (85,86).

With the lack of comparative trials, evidence from the current literature on transvaginal bone-anchored sling would indicate that it offers no advantage over laparoscopic Burch, in terms of efficacy, and may produce inferior results. Additionally, the studies suggest a higher complication rate. Comparative studies are necessary to make any further clinical assessment of transvaginal bone-anchored sling procedures.

Complications

Few studies differentiate between major and minor complications. The complication rates range from 0% to greater than 20% (Table 4) (5,33,38,57). Major complications seen with laparoscopic Burch include bladder injury, ureteral damage or kinking, abscess or seroma formation in the space of Retzius, failed procedure requiring additional surgery, de novo detrusor instability, new onset intrinsic sphincter deficiency, urinary retention, voiding dysfunction, and a possible increase in posterior compartment prolapse (87).

Speights et al. (89) reported a 2.3% lower urinary tract injury rate in 171 patients. The four injuries were inadvertent cystotomies, two following prior Marshall–Marchetti–Krantz and staple-mesh procedures. All occurred in the dome of the bladder and were repaired laparoscopically intraoperatively. There were no ureteral injuries. The authors pointed out that this injury rate was lower than the 10% injury rate observed in an open Burch colposuspension series (90). A French center (91) reported a 3% injury rate in 104 laparoscopic Burch procedures, two cystotomies and one partial ureteral transection. Ferland and Rosenblatt (21) reported ureteral obstruction in two postoperative patients. Cystoscopy revealed a transmural passage of suture anterior and lateral to the urethral orifice in one patient and puckering and lateral displacement of the right trigone, causing ureteral obstruction in the second patient. Both these injuries were on the patient's right side, similar to other reports (92,93). Ferland suggested that when the surgeon stands on the patient's left side, suture placement tends to be lateral-to-medial with the right-sided sutures, increasing the risk of entrapment of the right bladder wall and intramural ureter (Fig. 4). To prevent this complication which is not seen on the left side because the natural suture placement is medial-to-lateral away from the bladder for a right handed surgeon, he recommended passing the right sutures medial-to-lateral (Fig. 5).

Dwyer et al. (93) reported three cases of bladder sutures and three cases of ureteral obstructions by suture in 178 patients, with an overall lower urinary tract injury rate of 3.4%. Cooper et al. (38) reported on 10 cystotomies and 1 bladder suture in 113 patients, resulting in a 9.7% lower urinary tract injury rate. The overall laparoscopic injury rate for the lower urinary tract in all gynecologic cases ranges from 0.02% to 1.7%, which is not different from that seen with open gynecologic cases. The higher incidence of inadvertent cystotomies reported in some series were usually in patients with prior surgery in the space of Retzius and were bladder dome injuries easily recognized and repaired at the time of surgery. It is essential that intraoperative cystoscopy be performed to identify occult bladder and ureteral injuries in all major urogynecologic procedures.

Data on de novo detrusor instability are scant and not well reported in most studies. The range appears to be approximately 3% to 13% (31,38,72,95). Cardozo et al. (45) reported a rate of 18.5% de novo detrusor instability in open Burch, supported by others (43,96,97). Jarvis reported a 9.6% mean incidence of laparoscopic de novo detrusor instability in a meta-analysis, with a range of 4% to 18% (98). These reports suggest a slightly higher rate of de novo detrusor instability with the open procedure. It has been suggested that the less scarring in the laparoscopic procedure could minimize occurrence of

TABLE 4 ■ Comparison of Laparoscopic Burch versus Transvaginal Tape

Author (yr)	No. of patients		Type	Months follow-up mean (range)		Objective cure (%)			Subjective cure (%)		
	LSC	TVT		LSC	TVT	LSC	TVT	p value	LSC	TVT	p value
Persson (77)	31	37	P	12	12	87	89	NS	52	57	NS
Usten (78)	23	23	P	13.5	11.3	82.6	82.6	NS	NR	NR	
Ward (79)	108*	137	P	24*	24	80*	81	NS	62*	60	NS

Abbreviations: LSC, laparoscopic Burch; TVT, transvaginal tape; NS, not significant; P, prospective.

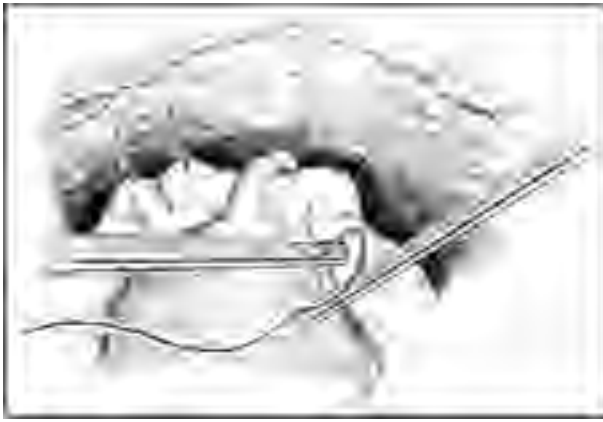


FIGURE 4 ■ Lateral to medial placement of the bladder neck suture increases the chance of catching the bladder wall and kinking the ureter. Source: From Ref. 21.



FIGURE 5 ■ A safer suture technique goes medial to lateral avoiding the bladder. Source: From Ref. 21.

detrusor instability. This has not been clearly demonstrated. In over 300 cases, our de novo detrusor instability rate following laparoscopic Burch has been 8% (Ross, unpublished data, 2004).

Several published series report no significant voiding dysfunction with laparoscopic Burch (6,10,37,40). Lavin et al. (70) found significantly less subjective voiding dysfunction after two years in laparoscopic versus open Burch, 16% and 52%, respectively. Su et al. (71) reported 4.3% voiding dysfunction in both laparoscopic and open Burch. No long-term follow-up studies are available. We have as many as 20% of our patients report positional changes in order to empty their bladders in the first six months following laparoscopic Burch, usually with resolution by the end of the first year. Routine bladder ultrasounds in our clinic have not demonstrated significant problems with increased postvoid residue.

The majority of studies have found less blood loss with laparoscopic Burch (22,70,71,73). Earlier, spontaneous voiding compared to other procedures has been reported in several studies (22,71,99). Decreased length of stay in the hospital has been reported in almost all of the laparoscopic studies (73).

Abdominal wall vascular injury is usually secondary to lateral trocar placement, resulting in inferior epigastric vessel damage (8). The reported incidence is 0.5% and it is reported to be less frequent with cone-shaped or blunt trocars (0%) as compared to sharp-cutting ones (0.83%) (100). Major bleeding, requiring transfusion, has been reported after injury to abdominal wall vessels (101).

A major advantage of laparoscopic surgery is the significantly lower ventral hernia formation (100). Most hernias that develop at trocar sites are due to lack of closure and are entirely preventable. The majority of these hernias are extraumbilical and the contents are usually small bowel (Richter hernia) (84.2%) and, less often, colon and omentum (102). Margossian et al. (103) reported a preperitoneal herniation of the terminal ileum through the right lateral 10-mm port in which the fascia had been closed, but not the muscle and peritoneum (Fig. 6). We had a similar experience with a left 10-mm trocar site. To prevent this complication, it is necessary to close the peritoneum, muscle, and fascia at large trocar sites. Several companies have simple devices to use for this purpose[§] and it adds very little time to the operative procedure (Fig. 7).

A rare complication reported during laparoscopy is postoperative acute ischemic necrosis of the small bowel. Hasson et al. (104) reported a case of a 34-year-old woman who underwent extensive adhesiolysis and myolysis and was readmitted with an acute abdomen 48 hours after discharge. At laparotomy, the patient had acute peritonitis, extensive adhesions, and a 3-cm perforation in the small bowel. Tissue examination of the resected bowel showed ischemic necrosis. Seven of eight patients with this diagnosis died. None of these patient's surgeries took longer than 1.4 hours. These cases reported in this series were described as elective, routine, uneventful, or without apparent complications at the time of surgery. The possible pathophysiology could stem from

[§]Inlet Closure, Inlet Medical, Inc., Eden Prairie, MN; Endoclose, U.S. Surgical Corp., Norwalk, CT; Storz Reuseable Fascial Closure, Karl Storz, Culver City, CA.



FIGURE 6 ■ Small bowel herniated through an unclosed peritoneal defect. Source: From Ref. 102.



FIGURE 7 ■ It is important to close fascia, muscle, and peritoneum; especially at large trocar sites. Source: From Ref. 102.

CO₂ pneumoperitoneum, which can cause decreased cardiac output due to increased systemic resistance, decreased venous return, and elevated intrathoracic pressure. It can potentially cause reduction in splanchnic blood flow, resulting from mechanical compression of mesenteric veins, humoral vasoconstriction of mesenteric vessels, and increased portal venous pressure caused by absorption of CO₂ and increased release of vasopressin. These effects can lead to mesenteric thrombosis, resulting in infarction of small bowel. Atherosclerosis, dense adhesions, or congenital stenosis can trigger these mechanisms. Hasson et al. suggest prevention is better than treatment in handling this catastrophic complication and recommend not letting the intra-abdominal pressure exceed 15 mmHg and periodically decompressing the pneumoperitoneum. This reinforces the adage that a patient should typically get better each day following laparoscopic surgery, and even small setbacks require immediate action.

Walter et al. report minimal differences in complications, blood loss, operative time, hemoglobin change, hospitalization, or hospital charges between open and laparoscopic Burch.

Costs

Walter et al. (105) report minimal differences in complications, blood loss, operative time, hemoglobin change, hospitalization, or hospital charges between open and laparoscopic Burch.

At Walter et al.'s (104) facility, charges were \$9900 and \$9400, respectively, for the laparoscopic and open procedure. The authors concluded that there were no benefits with laparoscopy when vaginal prolapse repairs were performed. Kohli et al. (99) found laparoscopic operative times to be significantly longer and laparoscopy was higher than laparotomy (\$4960 vs. \$4079). Mean length of stay was 1.3 days and 2.1 days with laparoscopy and open colposuspensions, respectively, with laparoscopic equipment usage and cost being greater. Kung et al. (106) extracted cost data from hospital charts and office records. Professional fees, investigations, drugs, capital equipment, disposable equipment, and length of stay were used to calculate costs. There was a significant difference between laparoscopy and open procedures (\$2938 vs. \$5692). The cost-effective ratios (cost/cure) were \$3029 and \$6324 for laparoscopy and open procedures, respectively.

PARAVAGINAL REPAIR

Paravaginal herniation is commonly associated with urinary incontinence. The defect is suspected on pelvic exam when, on the Valsalva maneuver, the lateral sulcus bulges out, causing a cystocele with prominent vaginal rugae. The diagnosis is confirmed if both lateral sulci are supported and, on maximal Valsalva, the cystocele is no longer present. The defect can be unilateral or bilateral (33,107). It is caused by the tearing away of the pubocervical fascia from the arcus white line. The defect can be complete from the ischial spine to the pubic bone or partial, usually starting in the proximal portion. To start the repair, the pelvic floor is elevated with the vaginal hand and the bladder is mobilized medially. Interrupted permanent sutures are placed through the torn edge of the pubocervical fascia and then through the arcus white line. The first suture is placed proximally just above the ischial spine with the obturator canal directly above. Interrupted sutures are continued distally until the defect is closed, usually requiring four to six sutures. The paravaginal repair is done before performing the Burch procedure.

SUMMARY

- Laparoscopy has become an extremely useful tool in the surgical armamentarium of pelvic floor reconstruction over the past decade.
- Centers utilizing the laparoscopic Burch–Tanagho technique have reported comparable results to the open technique. Long-term follow-up studies are awaited.
- There is no reason to anticipate different outcomes between open and laparoscopic procedures because the only technical variation is mode of entry.
- Proper laparoscopic suture technique is just as efficient as open knot tying. Many initial reports of poor outcomes may be secondary to the steep learning curve and the difficulty in becoming proficient in suturing with laparoscopy.
- Due to increased experience, more exposure to advanced procedures, better instrumentation, and better criteria for patient selection, reported complication rates after laparoscopic procedures are decreasing.
- The incidence of urinary incontinence in women is increasing, and because there is better dissemination of information, younger women are seeking minimally invasive treatment for urinary incontinence. Laparoscopic Burch, transvaginal tape, and now transobturator procedures are appealing options.

REFERENCES

1. Burch JC. Urethrovaginal fixation to Cooper's ligament for correction of stress incontinence, cystocele, and prolapse. *Am J Obstet Gynecol* 1961; 81:281–290.
2. Burch J. Cooper's ligament urethrovesical suspension for stress incontinence. *Am J Obstet Gynecol* 1968; 100:764–774.
3. Tanagho E. Colpocystourethropey: the way we do it. *J Urol* 1976; 116:751–753.
4. Vancaillie T, Schuessler W. Laparoscopic bladder neck suspension. *J Laparoendosc Surg* 1991; 13:169–173.
5. Albala D, Schuessler WE, Vancaillie TG. Laparoscopic bladder suspension for the treatment of stress incontinence. *Semin Urol* 1992; 10:222.
6. Liu C. Laparoscopic retropubic colposuspension (Burch procedure). A review of 58 cases. *J Reprod Med* 1993; 38:526–530.
7. Nezhat CH, Nezhat F, Nezhat CR, Rottenberg H. Laparoscopic retropubic cystourethropey. *J Am Assoc Gynecol Laparosc* 1994; 1(4):339–349.
8. Ross JW. Laparoscopic Burch repair compared to laparotomy Burch for cure of urinary stress incontinence. *Int Urogynecol J* 1995; 6:323–328.
9. Ross JW. Techniques of laparoscopic repair of total vault eversion after hysterectomy. *J Am Assoc Gynecol Laparosc* 1997; 4:173–183.
10. Ross JW. Multichannel urodynamic evaluation of laparoscopic Burch colposuspension for genuine stress incontinence. *Obstet Gynecol* 1998; 91:55–59.
11. Moore RD, Speights SE, Miklos JR. Laparoscopic Burch colposuspension for recurrent stress urinary incontinence. *J Am Assoc Gynecol Laparosc* 2001; 8(3):389–392.
12. Ross JW. Laparoscopic Burch colposuspension and overlapping sphincteroplasty for double incontinence. *JSL* 2001; 5(3):203–209.
13. Sultan AH, Kamm MA, Hudson CN, Thomas JM, Bartram CI. Anal-Sphincter disruption during vaginal delivery. *N Engl J Med* 1993; 329:1905–1911.
14. Sultan AH, Loder PB, Bartram CI, Kamm MA, Hudson CN. Vaginal endosonography. New approach to image the undisturbed anal sphincter. *Dis Colon Rectum* 1994; 37:1296–1299.
15. Jackson SL, Weber AM, Hull TL, et al. Fecal incontinence in women with urinary incontinence and pelvic organ prolapse. *Obstet Gynecol* 1997; 89(3):423–427.
16. Goei R, Baeten C. Rectal intussusception and rectal prolapse: detection and postoperative evaluation with defecography. *Radiol* 1990; 174:124–126.
17. Healy JC, Halligan S, Reznick RH, et al. Patterns of prolapse in women with symptoms of pelvic floor weakness: assessment with MR imaging. *Radiology* 1997; 203(1):77–81.
18. El-Minawi AM, Howard FM. Iliohypogastric nerve entrapment following gynecologic operative laparoscopy. *Obstet Gynecol* 1998; 91(5):871.
19. Kumar H, Cauchi J, Mackinnon AE. Periurethral gortex sling in lower urinary reconstruction. *Eur J Pediatr Surg* 1999; 9:33–34.
20. Magrina JF. Complications of laparoscopic surgery. *Clin Obstet Gynecol* 2002; 45(2):469–480.
21. Ferland RD, Rosenblatt P. Ureteral compromise after laparoscopic Burch colpopexy. *J Am Assoc Gynecol Laparosc* 1999; 6(2):217–219.
22. Saidi MH, Gallagher MS, Skop IP, et al. Extraperitoneal laparoscopic colposuspension: short-term cure rate, complications, and duration of hospital stay in comparison with Burch colposuspension. *Obstet Gynecol* 1998; 92(4 Pt 1):619–621.
23. Lee CL, Yen CF, Wang CJ, et al. Extraperitoneal approach to laparoscopic Burch colposuspension. *J Am Assoc Gynecol Laparosc* 2001; 8(3):374–377.
24. Hannah SL, Roland B, Gengenbacher PM. Extraperitoneal retropubic laparoscopic urethropey. *J Am Assoc Gynecol Laparosc* 2001; 8(1):107–110.
25. Batislam E, Germiyanoglu C, Erol D. Simplification of laparoscopic extraperitoneal colposuspension: results of two-port technique. *Int Urol Nephrol* 2000; 32(1):47–51.

26. Meltomaa S, Haarala M, Makinen J, Kiilholma P. Endoscopic colposuspension with simplified extraperitoneal approach. *Tech Urol* 1997; 3(4):216–221.
27. Froeling FM, Deprest JA, Ankum WM, et al. Controlled balloon dilatation for laparoscopic extraperitoneal bladder neck suspension in patients with previous abdominal surgery. *J Laparoendosc Adv Surg Tech A* 2000; 10(1):27–30.
28. Smith ML, Perry C. Simplified visual preperitoneal access to the space of Retzius for laparoscopic urethrocolpopexy. *J Am Assoc Gynecol Laparosc* 1996; 3(2):295–298.
29. Wolf J, Monk TG, McDougall EM, McClennan BL, Clayman RV. The extraperitoneal approach and subcutaneous emphysema are associated with greater absorption of carbon dioxide during laparoscopic renal surgery. *J Urol* 1995; 154:959–963.
30. Liu CY, Paek W. Laparoscopic retropubic colposuspension (Burch procedure). *J Am Assoc Gynecol Laparosc* 1993; 1(1):31–35.
31. Liu CY. Laparoscopic treatment for genuine urinary stress incontinence. *Baillieres Clin Obstet Gynaecol* 1994; 8(4):789–798.
32. Papasakelariou C, Papasakelariou B. Laparoscopic bladder neck suspension. *J Am Assoc Gynecol Laparosc* 1997; 4(2):185–189.
33. Ross JW. Apical vault repair, the cornerstone of pelvic vault reconstruction. *Int Urogynecol J* 1997; 8:146–152.
34. Langebrenne A, Dahlstrom B, Eraker R, Urnes A. The laparoscopic Burch procedure. A preliminary report. *Acta Obstet Gynecol Scand* 1995; 74(2):153–155.
35. Carter JE. Laparoscopic bladder neck suspension. *Endosc Surg Allied Technol* 1995; 3(2):81–87.
36. Radomski SB, Herschorn S. Laparoscopic Burch bladder neck suspension: early results. *J Urol* 1996; 155(2):515–518.
37. Lam AM, Jenkins GJ, Hyslop RS. Laparoscopic Burch colposuspension for stress incontinence: preliminary results. *Med J Aust* 1995; 162(1):18–21.
38. Cooper MJ, Cario G, Lam A, Carlton M. A review of results in a series of 113 laparoscopic colposuspensions. *Aust N Z J Obstet Gynaecol* 1996; 36(1):44–48.
39. Ross JW. Two techniques of laparoscopic Burch repair for stress incontinence: a prospective, randomized study. *J Am Assoc Gynecol Laparosc* 1996; 3:351–357.
40. Belair G, Tessier J, Bertrand PE, Schick E. Retropubic cystourethropepy: is it an obstructive procedure? *J Urol* 1997; 158(2):533–538.
41. Ross JW. 5-Year outcome of laparoscopic Burch for stress incontinence. *J Am Assoc Gynecol Laparosc* 1999; 6(3):S48.
42. Eriksen B, Hagen B, Eik-Nes SH, Molne K, Mjølnerod OK, Romslo I. Long-term effectiveness of the Burch colposuspension in female urinary stress incontinence. *Acta Obstet Gynecol Scand* 1990; 69:45–50.
43. Feyereisl J, Dreher E. Long-term results after Burch colposuspension. *Am J Obstet Gynecol* 1994; 171:647–652.
44. Alcalay M, Monga A, Stanton SL. Burch colposuspension: a 10-20 year follow up. *Br J Obstet Gynaecol* 1995; 102(9):740–745.
45. Cardozo LD, Stanton SL, Williams JE. Detrusor instability following surgery for genuine stress incontinence. *Br J Urol* 1979; 51(3):204–207.
46. Flax S. The gasless laparoscopic Burch bladder neck suspension: early experience. *J Urol* 1996; 156(3):1105–1107.
47. Persson J, Wolner-Hanssen P. Laparoscopic Burch colposuspension for stress urinary incontinence: a randomized comparison of one or two sutures on each side of the urethra. *Obstet Gynecol* 2000; 95:151–155.
48. Ou CS, Presthus J, Beadle E. Laparoscopic bladder neck suspension using hernia mesh and surgical staples. *J Laparoendosc Surg* 1993; 3(6):563–566.
49. Ou CS, Rowbotham R. Five-year follow-up of laparoscopic bladder neck suspension using synthetic mesh and surgical staples. *J Laparoendosc Adv Surg Tech A* 1999; 9(3):249–252.
50. Birken RA, Leggett PL. Laparoscopic colposuspension using mesh reinforcement. *Surg Endosc* 1997; 11(11):1111–1114.
51. Washington JL, Somers K. Laparoscopic mesh and staple Burch colposuspension. *Int Urogynecol J Pelvic Floor Dysfunct* 2002; 13(4):253–255.
52. Zullo F, Palomba S, Piccione F, et al. Laparoscopic Burch colposuspension: a randomized controlled trial comparing two transperitoneal surgical techniques. *Obstet Gynecol* 2001; 98(5):783–788.
53. Zullo F, Morelli M, Russo T, et al. Two techniques of laparoscopic retropubic urethropepy. *J Am Assoc Gynecol Laparosc* 2002; 9(2):178–181.
54. McDougall E, Klute CG, Cornett T. Comparison of transvaginal versus laparoscopic bladder neck suspension for stress urinary incontinence. *Urol* 1995; 45:641–646.
55. McDougall EM, Heidorn CA, Portis AJ, Klutke CG. Laparoscopic bladder neck suspension fails the test of time. *J Urol* 1999; 162(6):2078–2081.
56. Das S. Comparative outcome analysis of laparoscopic colposuspension, abdominal colposuspension and vaginal needle suspension for female urinary incontinence. *J Urol* 1998; 160:368–371.
57. Lobel R, Davis G. Long-term results of laparoscopic Burch urethropepy. *J Am Assoc Gynecol Laparosc* 1997; 4:341–345.
58. Breda G, Silvestre P, Gherardi L, et al. Correction of stress urinary incontinence: laparoscopy combined with vaginal suturing. *J Endourol* 1996; 10(3):251–253.
59. Carter JE. Laparoscopic Burch procedure for stress urinary incontinence: the Carter modification. *Keio J Med* 1996; 45(3):168–171.
60. Pelosi MA III, Pelosi MA. Laparoscopic-assisted transpectineal needle suspension of the bladder neck. *J Am Assoc Gynecol Laparosc* 1998; 5(1):39–46.
61. Takeda M, Hatano A, Kurumada S, et al. Bladder neck suspension using percutaneous bladder neck stabilization to the pubic bone with a bone-anchor suture fixation system: a new extraperitoneal laparoscopic approach. *Urol Int* 1999; 62(1):57–60.
62. Harewood LM. Laparoscopic needle colposuspension for genuine stress incontinence. *J Endourol* 1993; 7: 319–322.

63. Henley C. The Henley staple-suture technique for laparoscopic Burch colposuspension. *J Am Assoc Gynecol Laparosc* 1995; 2:441–444.
64. Lyons T. Minimally invasive retropubic urethropexy: the Nolan-Lyons modification to the Burch procedure. *Gynecol Endocrinol* 1994; 3:40–43.
65. Kiilholma P, Haarala M, Polvi H, et al. Sutureless endoscopic colposuspension with fibrin sealant. *Tech Urol* 1995; 1(2):81–83.
66. Burton G. A randomized comparison of laparoscopic and open colposuspension. *Neurourol Urodyn* 1993; 13:497–498.
67. Burton G. A three year prospective randomized urodynamic study comparing open and laparoscopic colposuspension. *Neurourol Urodyn* 1997; 16:353–354.
68. Carey MR, Maher C, Cronish A, et al. Laparoscopic versus open colposuspension: a prospective multicentre randomised single-blind comparison. *Neurourol Urodyn* 2000; 19:389–390.
69. Summitt RL, Lucente V, Karram MM, et al. Randomized comparison of laparoscopic and transabdominal Burch urethropexy for the treatment of genuine stress incontinence. *Obstet Gynecol* 2000; 95(4):S2.
70. Lavin JM, Lewis CJ, Foote AJ, Hosker GL, Smith AR. Laparoscopic Burch colposuspension: a minimum of 2 year's follow up and comparison with open colposuspension. *Gynaecological Endoscopy* 1998; 7:251–258.
71. Su T, Wang KG, Hsu Cy, Wei HJ, Hong BK. Prospective comparison of laparoscopic and traditional colposuspensions in the treatment of genuine stress incontinence. *Acta Obstet Gynecol Scand* 1997; 76:576–582.
72. Fatthy H, El Hao M, Samaha I, Abdallah K. Modified Burch colposuspension: laparoscopy versus laparotomy. *J Am Assoc Gynecol Laparosc* 2001; 8(1):99–106.
73. Polascik TJ, Moore RG, Rosenberg MT, Kavoussi LR. Comparison of laparoscopic and open retropubic urethropexy for treatment of stress urinary incontinence. *Urology* 1995; 45(4):647–652.
74. Huang WC, Yang JM. Anatomic comparison between laparoscopic and open Burch colposuspension for primary stress urinary incontinence. *Urology* 2004; 63(4):676–681.
75. Miannay E, Cosson M, Lanvin D, Querleu D, Crepin G. Comparison of open retropubic and laparoscopic colposuspension for treatment of stress urinary incontinence. *Eur J Obstet Gynecol Reprod Biol* 1998; 79:159–166.
76. Ulmsten U, Henriksson L, Johnson P, Varhos G. An ambulatory surgical procedure under local anesthesia for treatment of female urinary incontinence. *Int Urogynecol J* 1996; 7:81–86.
77. Persson J, Wolner-Hanssen P. Laparoscopic Burch colposuspension for stress urinary incontinence: Arandonized comparison of one or two sutures on each side of the urethra. *Obstet Gynecol* 2000; 95: 151–155.
78. Ustun Y, Engin-Ustun Y, Gungor M, Tezcan S. Tension-free vaginal tape compared with laparoscopic Burch urethropexy. *J Am Assoc Gynecol Laparosc* 2003; 10(3):386–389.
79. Ward KL, Hilton P. A prospective multicenter randomized trial of tension-free vaginal tape and colposuspension for primary urodynamic stress incontinence: two-year follow-up. *Am J Obstet Gynecol* 2004; 190(2):324–231.
80. Valpas A, Kivela A, Penttinen J, et al. Tension-free vaginal tape and laparoscopic mesh colposuspension in the treatment of stress urinary incontinence: immediate outcome and complications—a randomized clinical trial. *Acta Obstet Gynecol Scand* 2003; 82(7):665–671.
81. Debodinance P, Cosson M, Burlet G. Tolerance of synthetic tissues in touch with vaginal scars: review to the point of 287 cases. *Eur J Obstet Gynecol Reprod Biol* 1999; 87(1):23–30.
82. Carbone JM, Kavalier E, Hu JC, Raz S. Pubovaginal sling using cadaveric fascia and bone anchors: disappointing early results. *J Urol* 2001; 165(5):1605–1611.
83. Franco N, Shobeiri SA, Echols KT. Medium-term follow-up of transvaginal suburethral slings: variance in outcome success using two different evaluation methods. *Urology* 2002; 60(4):607–610.
84. Kobashi KC, Leach GE, Chon J, Govier FE. Continued multicenter followup of cadaveric prolapse repair with sling. *J Urol* 2002; 168(5):2063–2068.
85. Schostak M, Miller K, Muller M, et al. Transvaginal bone anchors in female stress urinary incontinence: poor results. *Gynecol Obstet Invest* 2002; 54(3):154–158.
86. Carbone A, Palleschi G, Ciavarella S, et al. Experience with a bone anchor sling for treating female stress urinary incontinence: outcome at 30 months. *BJU Int* 2004; 93(6):780–788.
87. Giberti C, Rovida S. Transvaginal bone-anchored synthetic sling for the treatment of stress urinary incontinence: an outcomes analysis. *Urology* 2000; 56(6):956–961.
88. Balaloski SP, Richards SR, Singh E. Conservative management of delayed suprapubic abscess after laparoscopic Burch colposuspension using nonabsorbable polypropylene mesh. *J Am Assoc Gynecol Laparosc* 1999; 6(2):225–228.
89. Speights SE, Moore RD, Miklos JR. Frequency of lower urinary tract injury at laparoscopic Burch and paravaginal repair. *J Am Assoc Gynecol Laparosc* 2000; 7(4):515–518.
90. Harris R, Cundiff GW, Theofrastous JP, Yoon H, Bump RC, Addison WA. The value of intraoperative cystoscopy in urogynecologic and reconstructive pelvic surgery. *Am J Obstet Gynecol* 1997; 177:1367–1371.
91. Soulie M, Salomon L, Seguin P, et al. Multi-institutional study of complications in 1085 laparoscopic urologic procedures. *Urology* 2001; 58(6):899–903.
92. Aslan P, Woo HH. Ureteric injury following laparoscopic colposuspension. *Br J Obstet Gynaecol* 1997; 104(2):266–268.
93. Dietz HP, Wilson PD, Samalia KP, et al. Ureteric injury following laparoscopic colposuspension. *Br J Obstet Gynaecol* 1997; 104(10):1217.
94. Dwyer PL, Carey MP, Rosamilia A. Suture injury to the urinary tract in urethral suspension procedures for stress incontinence. *Int Urogynecol J Pelvic Floor Dysfunct* 1999; 10(1):15–21.
95. Lawton V, Smith AR. Laparoscopic colposuspension. *Semin Laparosc Surg* 1999; 6(2):90–99.
96. Bergman A, Ballard CA, Koonings PP. Comparison of three different surgical procedures for genuine stress incontinence: prospective randomized study. *Obstet Gynecol* 1989; 160:1102–1106.

97. Wang AC. Burch colposuspension versus Stamey bladder neck suspension. A comparison of complications with special emphasis on detrusor instability and voiding dysfunction. *J Reprod Med* 1996; 41(7):529–533.
98. Jarvis GJ. Surgery for genuine stress incontinence. *Br J Obstet Gynaecol* 1994; 101(5):371–374.
99. Kohli N, Jacobs PA, Sze EH, et al. Open compared with laparoscopic approach to Burch colposuspension: a cost analysis. *Obstet Gynecol* 1997; 90(3):411–415.
100. Hashizume M, Sugimachi K. Needle and trocar injury during laparoscopic surgery in Japan. *Japan Surg Endosc* 1997; 11:1198–1201.
101. Hurd W, Pearl ML, DeLancey JO, Quint EH, Garnett B, Bude RO. Laparoscopic injury of abdominal wall blood vessels: a report of three cases. *Obstet Gynecol* 1993; 82:673–676.
102. Boike G, Miller CF, Spirtos NM. Incisional bowel herniations after operative laparoscopy: a series of nineteen cases and review of the literature. *Am J Obstet Gynecol* 1995; 172:1726.
103. Margossian H, Pollard RR, Walters MD. Small bowel obstruction in a peritoneal defect after laparoscopic Burch procedure. *J Am Assoc Gynecol Laparosc* 1999; 6(3):343–345.
104. Hasson H, Galanopoulos C, Langerman A. Ischemic necrosis of small bowel following laparoscopic surgery. *J Soc Laparoendosc Surg* 2004; 8:159–163.
104. Walter AJ, Morse AN, Hammer RA, et al. Laparoscopic versus open Burch retropubic urethropexy: comparison of morbidity and costs when performed with concurrent vaginal prolapse repairs. *Am J Obstet Gynecol* 2002; 186(4):723–728.
106. Kung RC, Lie K, Lee P, Drutz HP. The cost-effectiveness of laparoscopic versus abdominal Burch procedures in women with urinary stress incontinence. *J Am Assoc Gynecol Laparosc* 1996; 3(4):537–544.
107. Miklos JR, Kohli N. Laparoscopic paravaginal repair plus Burch colposuspension: review and descriptive technique. *Urology* 2000; 56(6):64–69

LAPAROSCOPIC MANAGEMENT OF VESICOVAGINAL FISTULA

Ali Mahdavi

Department of Obstetrics and Gynecology, Division of Gynecologic Oncology, Mount Sinai School of Medicine, New York, New York, U.S.A.

Farr Nezhat

Mount Sinai School of Medicine, New York, New York, U.S.A.

Bulent Berker

Center for Special Minimally Invasive Surgery, Palo Alto, California, U.S.A.

Ceana Nezhat

Nezhat Medical Center, Endometriosis Clinic, Atlanta, Georgia, U.S.A.

Camran Nezhat

Stanford University Medical School, Palo Alto, California, U.S.A.

- INTRODUCTION
- ETIOLOGY
- DIAGNOSIS
- SURGICAL TECHNIQUE

- PREVENTION
- RESULTS
- SUMMARY
- REFERENCES

INTRODUCTION

Vesicovaginal fistula remains a challenge to surgeons and a nuisance to patients, more so if it is recurrent. Controversy still exists over the ideal approach and time to repair. Introduction and promulgation of videolaparoscopy by Nezhat (1) has revolutionized modern day surgery and has become the predominant means of performing many common surgical procedures (2–4). With recent advances in minimally invasive urogynecologic techniques, it is possible to repair some of these fistulas laparoscopically. Operative laparoscopy for segmental bladder resection, vesicovaginal fistula repair, ureteroureterostomy and ureteroneocystostomy with or without psoas hitch had been reported by Nezhat et al. in 1990s (5,6). The laparoscopic approach significantly reduces the access trauma of traditional laparotomy with additional advantages of magnified vision of pelvic organs and less traumatic tissue handling and enables the surgeon to treat concomitant intraperitoneal pathology at the same time. Shorter hospital stay and accelerated postoperative recovery are other benefits of laparoscopic approach.

The primary etiology of vesicovaginal fistula in developed countries is surgical trauma associated with gynecologic procedures. Abdominal hysterectomy has been shown to be the most common cause, with vesicovaginal fistula occurring in approximately one of every 1800 hysterectomies.

ETIOLOGY

The primary etiology of vesicovaginal fistula in developed countries is surgical trauma associated with gynecologic procedures. Abdominal hysterectomy has been shown to be the most common cause, with vesicovaginal fistula occurring in approximately one of every 1800 hysterectomies (7). Secondary causes include complications of obstructed labor, and radiation therapy of urogynecologic cancers.

There is a paucity of data regarding the pathogenesis of posthysterectomy vesicovaginal fistula. It is generally believed that vesicovaginal fistula are caused by suture ligation or crush injuries to the bladder at the time of hysterectomy. However, Meeks et al. (8) studied the outcome of 2/0 polyglactin suture placed through the bladder and vaginal cuff at the time of hysterectomy in 21 rabbits. Despite the placement of a hemostatic stitch through the bladder and vaginal cuff, no vesicovaginal fistula was seen in any of the animals. They concluded that if bladder injury were the sole cause of vesicovaginal fistula, a much higher rate of vesicovaginal fistula would be expected. Recently, Cogan et al. (9) investigated the relationship between various types of laparoscopic

bladder injuries (bipolar injury without perforation vs. 2-0 polyglactin suture through the bladder wall vs. bladder laceration with monopolar cautery that was repaired with 2-0 polyglactin suture) and vesicovaginal fistula formation in an animal model. Vesicovaginal fistulas were detected only in the groups with monopolar cautery bladder injuries. It was concluded that an electrosurgically induced cystotomy and repair of the bladder during the performance of a laparoscopic hysterectomy was associated with the formation of postoperative vesicovaginal fistulas. Flynn and Amundsen (10) noted multiple cavities in the vaginal epithelium and pathologic evidence of chronic inflammation in an acute setting in a patient with recurrent vesicovaginal fistula. They suggest that vesicovaginal fistula formation is multifactorial and that additional factors besides bladder injury such as chronic infection and formation of small abscesses may also play a role in the formation of postoperative fistula. In addition abscess rupture may be a mechanism for fistula tract formation.

DIAGNOSIS

Postsurgical vesicovaginal fistulas usually present 7 to 21 days after surgery.

Postsurgical vesicovaginal fistulas usually present 7 to 21 days after surgery. Most patients have urinary incontinence or persistent vaginal discharge. If the fistula is very small, leakage may be intermittent, occurring only at maximum bladder capacity or with particular body position. Other signs and symptoms include unexplained fever; hematuria; recurrent cystitis or pyelonephritis; vaginal, suprapubic, or flank pain; and abnormal urinary stream (11).

Office testing is often able to distinguish between fistulas involving the bladder or ureters. Instillation of methylene blue into the bladder stains vaginal swabs or tampons in the presence of vesicovaginal fistula. If this test is not diagnostic, a transurethral Foley catheter should be placed to prevent any staining of the distal tampon from the urethral meatus. Unstained but wet swabs may indicate a ureterovaginal fistula. If leakage is not demonstrated, the bladder is filled to maximum capacity and provocative maneuvers such as valsalva or manual pressure over the bladder used to reproduce and confirm patient's symptoms. Intravenous indigo carmine can be given to rule out ureterovaginal fistula. Further evaluations, such as cystoureteroscopy and intravenous urogram permit the physician to localize the fistula, determine adequacy of renal function, and exclude or identify other types of urinary tract injury.

SURGICAL TECHNIQUE

Vesicovaginal fistulas are treated with different surgical techniques, depending on their cause and location. Small vesicovaginal fistulas that are not responsive to nonsurgical management, are usually repaired easily (12). The edges of the fistula are removed, and the defect is closed. Latzko's technique is used commonly for fistulas that are surrounded by severe fibrosis and close to the bladder neck or urethral meatus. Lee et al. (13) recommend an abdominal approach for fistulas in the upper part of a narrow vagina, multiple fistulas, those associated with other pelvic abnormalities, and fistulas close to the ureter. A combined abdominal and vaginal approach is used in some instances (14). Laparoscopy can be an alternative to laparotomy for managing vesicovaginal fistulas (15). Proposed advantages include magnification during the procedure, hemostasis, and shorter hospital stay and postoperative recovery.

The basic principles for laparoscopic repair of vesicovaginal fistula include adequate exposure, excision of fibrous tissue from the edges of the fistula, approximation of the edges without tension, the use of suitable suture material, and efficient postoperative bladder drainage.

After induction of general anesthesia and placement of patient in dorsal lithotomy position, a 10-mm intraumbilical incision is made for insertion of the operative laparoscope coupled with the CO₂ laser. Any other cutting modality such as scissors, or ultrasonic or radio frequency energy can be used. Three 5-mm trocars are inserted in the lower abdomen for the suction-irrigator probe, grasping forceps, and bipolar forceps (16). The abdominal and pelvic cavities are inspected for any coexisting pathology. A simultaneous cystoscopy is done, and both ureters are catheterized to aid in their identification and protection during excision and closure of the fistula. A urethral catheter is pulled through the fistula into the vagina to facilitate identification during excision.

A digital rectovaginal examination is carried out to exclude rectal involvement. The bladder is carefully dissected away from the vagina using laparoscopic scissors

The basic principles for laparoscopic repair of vesicovaginal fistula include adequate exposure, excision of fibrous tissue from the edges of the fistula, approximation of the edges without tension, the use of suitable suture material, and efficient postoperative bladder drainage.

and gentle countertraction. An opening is made into the vagina, avoiding the bladder and rectum, and an inflated glove in the vagina helps maintain pneumoperitoneum. The anterior vaginal wall is elevated with a grasping forceps, and the fistula is identified with the previously inserted catheter, which also delineates the posterior bladder wall. The bladder is filled with water, and a cystotomy is made above the fistula. The water is evacuated as the bladder is distended by pneumoperitoneum from the cystotomy. The fistula tract, vesicovaginal space, and ureters are observed laparoscopically (Fig. 1). The vesicovaginal space is further developed laparoscopically using sharp dissection. The bladder is freed posteriorly from the vaginal wall. The fistula is identified, held with a grasping forceps, and excised (Fig. 2). Adequate bladder dissection and mobilization are essential to eliminate tension upon suturing.

Initially, the vaginal wall opening of approximately 1.5 cm is closed with one layer of interrupted polyglactin (Vicryl) suture (Fig. 3). Then the vesical defect is repaired in one or two layers with interrupted 2-0 or 3-0 polyglactin sutures, using intra- or extracorporeal knotting. Defects in the vagina and bladder are closed separately. Hemostasis in the vesicovaginal space and fistula area is essential. A peritoneal flap is obtained superior and lateral to the bladder dome, close to the round ligament and diverted toward the bladder base. The flap is used to separate the vesicovaginal space. The omentum can also be mobilized and introduced between the bladder and vaginal wall. Using two interrupted sutures of 3-0 polyglactin, the peritoneal or omental flap is anchored to the anterior vaginal wall. The bladder is filled in a retrograde fashion with 300 mL of diluted indigo carmine to confirm the integrity of the vesical wall. No intraperitoneal drainage is used. A suprapubic or transurethral catheter is inserted and ureteral catheters are removed. Prophylactic antibiotic can be administered postoperatively. The bladder catheter is left in place for 10 to 20 days and then a cystogram is performed to verify the bladder integrity.



FIGURE 1 ■ The fistula tract, vesicovaginal space and ureters are observed laparoscopically.



FIGURE 2 ■ Vesicovaginal space is further developed laparoscopically.



FIGURE 3 ■ The fistula tract is excised using CO₂ laser.

In operative laparoscopy, meticulous dissection of vesicovaginal space and good hemostasis are essential for prevention of vesicovaginal fistula.

PREVENTION

In operative laparoscopy, meticulous dissection of vesicovaginal space and good hemostasis are essential for prevention of vesicovaginal fistula.

Based on a study on mongrel dogs by Cogan et al. (9), cystotomy induced by electrosurgery during laparoscopic hysterectomy, can be a risk factor for formation of vesicovaginal fistula. Caution should be exercised when using electrosurgery in the vicinity of the bladder. The benefit of electrosurgical burn margin excision or omental flap interposition remains unclear, but both are accomplished easily with little risk and may play a role in fistula prevention. In another study on mongrel dogs, Sokol et al. (17) concluded that double-layer bladder closure appeared to be superior to single-layer repair for prevention of vesicovaginal fistula after monopolar cystotomy. Meticulous suture placement and avoidance of tissue strangulation are also essential for prevention of vesicovaginal fistula. During operative laparoscopy performed to treat extensive endometriosis, intentional or unintentional bladder lacerations, or ureteral injury are recognized complications. Repair of a resected ureter or closure of the bladder can be effectively accomplished endoscopically by experienced laparoscopic surgeons. This will prevent the complication of vesicovaginal fistula that requires reoperation (18–20).

RESULTS

Laparoscopic vesicovaginal fistula repair was first reported by Nezhat in 1994 (15). A total of seven patients with laparoscopic vesicovaginal fistula repair have been reported in the literature (15,21–24). Despite minor differences in surgical techniques, fistula repair was successful in all seven cases three to six months postoperatively. All cases were treated by surgeons with extensive experience and interest in advanced operative laparoscopy.

SUMMARY

- Laparoscopy is a viable alternative to open surgical repair of vesicovaginal fistulas.
- Advantages of the laparoscopic approach include magnification during the procedure, and shorter hospital stay and postoperative recovery.
- The fistula is resected under direct visualization and a tension-free reconstruction is performed.
- Based on limited number of case reports on laparoscopic vesicovaginal fistulas repair, it appears to be a safe and effective approach for fistulas that cannot be repaired vaginally.
- Undoubtedly, operative laparoscopy will replace most laparotomies in gynecologic surgery, it is only a matter of time.

REFERENCES

1. Nezhat C. Videolaparoscopy and videolaseroscopy: a new modality for the treatment of endometriosis and other diseases of reproductive organs. *Colposc Gynecol Laser Surg* 1986; 2:221–224.
2. Nezhat C, Crowgey SR, Garrison CP. Surgical treatment of endometriosis via laser laparoscopy. *Fertil Steril* 1986; 45:778–783.
3. Nezhat C, Nezhat F, Nezhat CH, Admon D. Videolaseroscopy and videolaparoscopy. *Baillieres Clin Obstet Gynaecol* 1994; 8:851–864.
4. Nezhat C. Operative laparoscopy will replace almost all open procedures. *JLS* 2004; 8:101–102.
5. Nezhat C, Nezhat F, Green B. Laparoscopic treatment for obstructed ureter due to endometriosis by resection and ureteroureterostomy: a case report. *J Urol* 1992; 148:865–868.
6. Nezhat CH, Nezhat FR, Freiha F, Nezhat CR. Laparoscopic vesicopsoas hitch for infiltrative ureteral endometriosis. *Fertil Steril* 1999; 71:376–379.
7. Miller EA, Webster GD. Current management of vesicovaginal fistulae. *Curr Opin Urol* 2001; 11:417–421.
8. Meeks GR, Sams JO, Field KW, Fulp KS, Margolis MT. Formation of vesicovaginal fistula: the role of suture placement into the bladder during closure of the vaginal cuff after transabdominal hysterectomy. *Am J Obstet Gynecol* 1997; 177:1298–1304.
9. Cogan SL, Paraiso MF, Bedaiwy MA. Formation of vesicovaginal fistulas in laparoscopic hysterectomy with electrosurgically induced cystotomy in female mongrel dogs. *Am J Obstet Gynecol* 2002; 187:1510–1513.
10. Flynn MK, Amundsen CL. Delayed presentation and successful repair of a recurrent vesicovaginal fistula after hysterectomy and primary abdominal repair. *Int Urogynecol J Pelvic Floor Dysfunct* 2004; 15:53–55.

11. Walters MD, Karram MM. Lower urinary tract fistulas. In: *Urogynecology and Reconstructive Pelvic Surgery*. 2nd ed. St. Louis: Mosby, 1999:355–366.
12. Shull BL. Urologic surgical techniques. *Curr Opin Obstet Gynecol* 1991; 3:534–540.
13. Lee RA, Symmonds RE, William TJ. Current status of genitourinary fistula. *Obstet Gynecol* 1988; 72:313–319.
14. Taylor JS, Hewson AD, Rachow P. Synchronous combined transvaginal repair of vesicovaginal fistulas. *Aust N Z Surg* 1980; 50:23–25.
15. Nezhat CH, Nezhat F, Nezhat C, Rottenberg H. Laparoscopic repair of a vesicovaginal fistula: a case report. *Obstet Gynecol* 1994; 83:899–901.
16. Nezhat C, Nezhat F, Nezhat C. Operative laparoscopy (minimal invasive surgery): state of the art. *J Gynecol Surg* 1992; 8:111–141.
17. Sokol AI, Paraiso MF, Cogan SL, Bedaiwy MA, Escobar PF, Barber MD. Prevention of vesicovaginal fistulas after laparoscopic hysterectomy with electrosurgical cystotomy in female mongrel dogs. *Am J Obstet Gynecol* 2004; 190:628–633.
18. Nezhat C, Nezhat F. Laparoscopic repair of ureter resected during operative laparoscopy. *Obstet Gynecol* 1992; 80:543–544.
19. Nezhat CH, Seidman DS, Nezhat F, Rottenberg H, Nezhat C. Laparoscopic management of intentional and unintentional cystotomy. *J Urol* 1996; 156:1400–1402.
20. Nezhat CR, Nezhat FR. Laparoscopic segmental bladder resection for endometriosis: a report of two cases. *Obstet Gynecol* 1993; 81:882–884.
21. Nezhat C, Siegler A, Nezhat F, Nezhat C, Seidman D, Luciano A. Vesico-vaginal fistula repair. In: *Operative Gynecologic Laparoscopy: Principles and Techniques*. 2nd ed. New York: McGraw-Hill, 2000:349–351.
22. Ou CS, Huang UC, Tsuang M, Rowbotham R. Laparoscopic repair of vesicovaginal fistula. *J Laparoendosc Adv Surg Tech* 2004; 14:17–21.
23. Nabi G, Hemal AK. Laparoscopic repair of vesicovaginal fistula and right nephrectomy for non-functioning kidney in a single session. *J Endourol* 2001; 15:801–803.
24. Miklos JR, Sobolewski C, Lucente V. Laparoscopic management of recurrent vesicovaginal fistula. *Int Urogynecol J Pelvic Floor Dysfunct* 1999; 10:116–117.

LAPAROSCOPIC SURGERY OF THE SEMINAL VESICLES

Robert B. Nadler and Scott E. Eggener

Department of Urology, Northwestern University Feinberg School of Medicine, Chicago, Illinois, U.S.A.

- INTRODUCTION
- ANATOMY, EMBRYOLOGY, AND FUNCTION
- INDICATIONS
 - Cysts
 - Stones
 - Masses
- IMAGING
- SURGICAL TECHNIQUE
 - Preoperative Considerations
 - Patient Positioning
 - Operative Technique
- SUMMARY
- REFERENCES

Primary pathology of the seminal vesicle is quite rare. With current imaging modalities such as computed tomography and magnetic resonance imaging, the seminal vesicles are being visualized more frequently and with better precision. As a result, more men are being diagnosed with abnormalities of the seminal vesicle, such as cysts or stones. Even when recognized, most are incidental findings not requiring treatment.

The blood supply enters at the tip of the seminal vesicle and is usually from the vesiculodeferential artery, a branch of the superior vesical artery. Occasionally, there may also be branches from the inferior vesical artery.

INTRODUCTION

Primary pathology of the seminal vesicle is quite rare. With current imaging modalities such as computed tomography and magnetic resonance imaging, the seminal vesicles are being visualized more frequently and with better precision. As a result, more men are being diagnosed with abnormalities of the seminal vesicle, such as cysts or stones. Even when recognized, most are incidental findings not requiring treatment.

When confronted with the infrequent man requiring a therapeutic excision of the seminal vesicle(s), the surgical approach can be abdominal (1), perineal (2), retrovesical (3), transvesical (4), transcoccygeal (5), or transurethral (6). However, with the increasing laparoscopic experience and expertise of many urologists, the seminal vesicles can safely and suitably be removed laparoscopically.

ANATOMY, EMBRYOLOGY, AND FUNCTION

The seminal vesicles are paired structures lying obliquely from inferomedial to superolateral at the posterior junction of the prostate and bladder. They contribute approximately 70% of the seminal fluid to the ejaculate (7). The right seminal vesicle is larger than the left in approximately one-third of men (8).

The blood supply enters at the tip of the seminal vesicle and is usually from the vesiculodeferential artery, a branch of the superior vesical artery (9). Occasionally, there may also be branches from the inferior vesical artery (1).

Among fertile men without urologic disease or symptoms, the seminal vesicles range in size from 1.9 to 4.1 cm in length and 0.4 to 1.4 cm in width (10). Owing to their common embryologic origin, abnormalities of the seminal vesicle are often associated with congenital anomalies of the kidney and ureter. Since the seminal vesicle develops from the distal mesonephric duct along with the kidney and ureter (11), it is common to have ipsilateral seminal vesicle, renal, and ureteral anomalies. The most common association is a congenital seminal vesicle cyst along with renal agenesis. Furthermore, ectopic ureters may enter directly into the seminal vesicle (11).

INDICATIONS

Most patients requiring laparoscopic excision of the seminal vesicle have cysts, obstructing stones, or an ectopic ureter draining into the seminal vesicle. Rarely, a seminal vesicle abscess or recalcitrant seminal vesiculitis may warrant surgery. The majority of men with seminal vesicle pathology present with pain, infections, hematuria, or hematospermia.

Cysts

Cystic disease of the seminal vesicles is recognized more frequently in the era of cross-sectional imaging and transrectal ultrasonography. Seminal vesicle cysts are composed of a cuboidal or flattened epithelium, fibrous wall, and contain whitish, thick fluid (12). When congenital, most men also have concomitant renal dysgenesis and ureteral ectopia (13). Acquired

Seminal vesicle cysts should be distinguished from mullerian duct cysts, which are found in the midline flanked on each side by a normal seminal vesicle. Since most seminal vesicle cysts are asymptomatic, no treatment is required.

seminal vesicle cysts usually follow urinary tract infections or ejaculatory duct lithiasis and only rarely occur bilaterally (14,15). Seminal vesicle cysts can grow quite large (up to 15 cm) and have been reported to cause rectal obstruction (16). While prenatal ultrasonographic identification of a seminal vesicle cyst has been reported (17), most are diagnosed postpuberty following an evaluation for pain, hematospermia, or infections (18,19).

Seminal vesicle cysts should be distinguished from mullerian duct cysts, which are found in the midline flanked on each side by a normal seminal vesicle. Since most seminal vesicle cysts are asymptomatic, no treatment is required.

When treatment is deemed necessary, cyst aspiration and transurethral resection of the ejaculatory duct are options but usually not effective (20,21). Surgical excision remains the definitive treatment.

Stones

Seminal vesicle calculi are typically brown in color and may comprise inspissated protein or contain a mucoepithelial core covered with stone forming components such as calcium carbonate, urates, and phosphate (Fig. 1) (22). Men typically present with hematospermia, hematuria, painful ejaculation (23), pain, or as an incidental finding (22). Reflux of urine into the seminal vesicle, obstruction, infection, or congenital anomalies have all been described as predisposing factors. Intervention is only necessary if symptoms warrant it, the pain is lateralizing, and imaging with computed tomography or magnetic resonance imaging indicates a stone. If composed only of inspissated protein seminal vesicle stones will not be visible on a computed tomography scan, and a T2-weighted magnetic resonance imaging with coronal imaging is recommended (Fig. 2) (22).

Masses

Rarely, men are diagnosed with masses of the seminal vesicle. Pain, obstruction of adjacent organs, dysuria, hematuria, or hematospermia can occur (24). Since the masses are often indistinguishable from adjacent organs, serum prostate-specific antigen and carcinoembryonic antigen can be helpful in determining if there is a prostatic or colorectal origin (24). Alternatively, an elevated serum CA125 is strongly suggestive of a primary seminal vesicle carcinoma (25). Most masses of the seminal vesicle are benign, such as papillary adenomas, cystadenoma, fibromas, and leiomyomas. Seminal vesicle tumors with malignant potential are exceedingly rare. Primary malignancies of the seminal vesicle such as adenocarcinoma (24), sarcoma (26), schwannoma (27), and squamous cell carcinoma (28) can occur and are probably best managed by aggressive extirpative surgery via either radical prostatectomy or cystoprostatectomy. While surgical excision is the primary form of therapy, radiotherapy and hormones have been used as adjuvant treatment (29–32). Regardless of treatment, the prognosis is poor (24).

To date there have been no reports of laparoscopic excision of the seminal vesicle for a primary malignancy.

To date there have been no reports of laparoscopic excision of the seminal vesicle for a primary malignancy.

IMAGING

Antegrade vasography and seminal vesiculography were first described in 1913 (33). When used for the evaluation of the infertile man, seminal vesicle abnormalities may

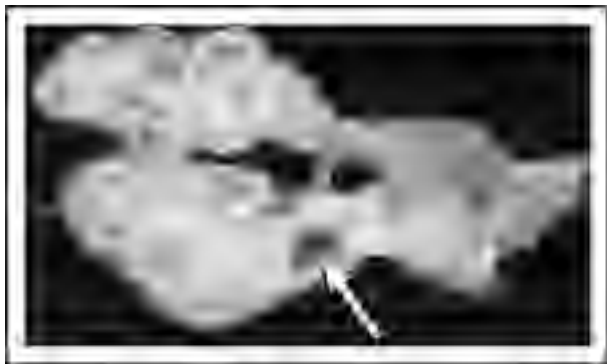

FIGURE 1 ■ Pathological specimen shows seminal vesicle with calculus (arrow). Source: From Ref. 22.



FIGURE 2 ■ T2-weighted magnetic resonance imaging reveals seminal vesicle stone (arrow) as discrete, signal void, nodular structures. Source: From Ref. 22.

be identified. Owing to its invasive nature and risk of vasa fibrosis or scarring, its use for seminal vesicle surgery has largely been supplanted by ultrasound, computed tomography, and magnetic resonance imaging.

Imaging of the seminal vesicles with intravenous urography has been replaced by other modalities. Rarely, intravenous urography diagnoses a radio-opaque stone, an ectopic ureter draining directly into the seminal vesicle, or a mass effect from a cyst or neoplasm.

As prostate cancer screening has become more routine, the number of transrectal ultrasound procedures has increased. Along with obtaining prostate biopsies, the urologist is afforded a view of the seminal vesicles. In addition to quantifying seminal vesicle size, stones appear as highly echogenic structures and cysts as hypoechoic fluid-filled cavities. Solid masses can be appreciated disfiguring the normal contour of the seminal vesicle and are typically hyperechoic.

Computed tomography can often provide useful information regarding the seminal vesicle and any associated renal or ureteral abnormalities. Since the seminal vesicle enhances following contrast administration, inflammatory lesions, cysts, and masses can be identified and distinguished from the surrounding structures. Simple cystic lesions display Hounsfield units of 0–10. When filled with stones, debris, blood, or pus the Hounsfield units are higher. Even with modern computed tomography capabilities, masses of the seminal vesicle can sometimes be difficult to differentiate from the adjacent bladder, prostate, or rectum. Furthermore seminal vesicle stones may be composed of protein without any calcification making visualization on noncontrast computed tomography very difficult or impossible (22).

Magnetic resonance imaging has proven to be an accurate and useful imaging tool for the seminal vesicles. Since the seminal vesicles are of intermediate signal intensity on T1-weighted images they can reliably be distinguished from the adjacent fat, bladder, and rectum. On T2-weighted images, the seminal vesicles are of varying intensity, depending on the age and androgen status of the man (34). As the levels of circulating androgens increase, the intensity of the seminal vesicles does also. Therefore, the seminal vesicles of postpubertal men with normal androgen levels have high signal intensity whereas those of prepubertal boys, many elderly men, and men undergoing androgen ablation have low signal intensity. The use of endorectal coils, the advent of higher Tesla magnets, and fast spin-echo techniques have all enhanced, and will continue to improve MR imaging of the seminal vesicles. Seminal vesicle cysts typically show high T2 and low T1 signal intensity but can vary based on composition (proteinaceous, hemorrhagic, etc.) and concentration of the fluid. The signal intensity of an inflammatory lesion of the seminal vesicle depends on the chronicity of the disease and whether bleeding is present. Chronic seminal vesiculitis typically appears as low intensity signals on both T1 and T2-weighted images (35).

Proteinaceous seminal vesicle stones are seen as discrete, signal void structures on T2-weighted images making magnetic resonance imaging superior to computed tomography for imaging the seminal vesicles (Fig. 2) (22).

Proteinaceous seminal vesicle stones are seen as discrete, signal void structures on T2-weighted images making magnetic resonance imaging superior to computed tomography for imaging the seminal vesicles (Fig. 2).

SURGICAL TECHNIQUE

Preoperative Considerations

Owing to their embryologic similarities, congenital seminal vesicle abnormalities often coexist with ureteral or renal anomalies (21,36). Because of this association, all patients with a congenital seminal vesicle cyst should be considered for imaging of their kidneys and ureter with a computed tomography scan or magnetic resonance imaging as well as cystoscopy to evaluate for ureteral ectopy or duplication.

The surgeon performing excision of a congenital seminal vesicle cyst should also be prepared to remove ureteral and renal remnants when necessary.

Prior to laparoscopic seminal vesicle surgery, the patient undergoes a mechanical bowel preparation with either magnesium citrate or Fleet's phosphosoda. Debulking the gastrointestinal tract affords the surgeon more working space in the abdominal cavity and also allows for a primary closure of bowel should an injury to the intestine occur. In men with a sterile urine culture, an intravenous first-generation cephalosporin is given one hour prior to surgery.

Patient Positioning

Following general anesthesia and gastric decompression, an 18 French urethral catheter is placed in the bladder. We prefer to use a catheter with a 30 cc balloon to aid in intraoperative identification of the trigone and bladder neck. The patient is positioned supine on spreader bars with both arms tucked alongside the body. Spreader bars allow

The surgeon performing excision of a congenital seminal vesicle cyst should also be prepared to remove ureteral and renal remnants when necessary.

An exaggerated Trendelenburg position may lead to excessive facial edema and paresthesias.

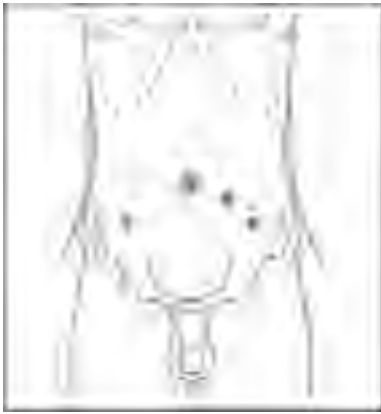

FIGURE 3 ■ Depicted here are 10 mm (X) and 5 mm (x) port size locations for laparoscopic seminal vesicle excision.

The surgeon must carefully identify and stay away from the ureters. If there is any question as to their location or proximity to the seminal vesicles, an externalized ureteral stent can be placed via flexible cystoscopy to identify the ipsilateral ureter.

easy access to the rectum where an O'Connor drape is placed to allow digital prostatic manipulation during the procedure. The table is gently flexed to open up the pelvis and a moderate Trendelenburg position is used to allow gravity retraction of the bowels.

An exaggerated Trendelenburg position may lead to excessive facial edema and paresthesias.

Operative Technique

The laparoscopic surgical approach to the seminal vesicles was first described by Kavoussi and Clayman in 1993 as a method for freeing up the seminal vesicles at the time of laparoscopic pelvic lymph node dissection immediately prior to a perineal prostatectomy (37). This transabdominal laparoscopic approach has subsequently become one of the initial steps of laparoscopic radical prostatectomy (38).

Pneumoperitoneum is obtained with a Veress needle or via an open technique. Either a 10–12 mm umbilical port is placed. Kavoussi originally described a five-port fan configuration for trocar placement with a 12 mm trocar just below the umbilicus, two 10 mm trocars lateral to the rectus muscle just caudal to the umbilicus and two 10 mm trocars just lateral to the rectus muscle approximately 2 cm above the superior iliac crest (36). We have found four ports to be adequate for laparoscopic seminal vesicle surgery with a 10–12 mm port just below the umbilicus, two 5 mm ports just lateral to the rectus sheath 2–3 cm below the umbilicus and a 5 mm port in the left lower quadrant just above the level of the anterior superior iliac crest (Fig. 3) (22). Larger 10–12 mm ports always can be substituted for 5 mm ports should instrumentation such as stapling devices, clip applicators, ultrasound probes, hernia staplers, or large fan retractors be necessary. If necessary, an additional fifth port can be placed in the right lower quadrant just above the anterior superior iliac crest or in the midline midway between the umbilicus and symphysis pubis as the surgeon sees fit.

The surgeon typically stands on the patient's left side while the assistant guides the camera and provides retraction or suctioning from the patient's right side. An AESOP robot or a fixed camera holder can also be used, which typically is placed through the umbilical port.

A full visual inspection of the abdomen is performed prior to addressing the seminal vesicles. Often, the colon overlies the area of the seminal vesicles and may need to be mobilized and retracted with either a fan or Jarit retractor. Upon reflecting the bladder anteriorly, the ureters can be visualized alongside the posterior surface of the bladder. Immediately inferior to the ureters the vas deferens enters into the prostate (Fig. 4).

The surgeon must carefully identify and stay away from the ureters. If there is any question as to their location or proximity to the seminal vesicles, an externalized ureteral stent can be placed via flexible cystoscopy to identify the ipsilateral ureter.

The size of the seminal vesicles can vary widely. A large congenital cyst may completely fill the pelvis whereas a seminal vesicle with a stone may be difficult to identify.

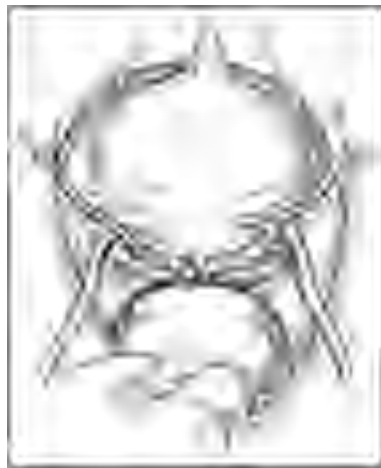

FIGURE 4 ■ The seminal vesicles seen there through the peritoneal reflection are the lowest ridge of tissue below the ureter and vas deferens.

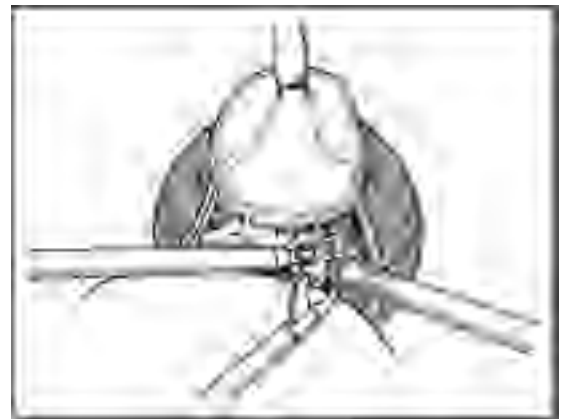


FIGURE 5 ■ The surgeon typically stands on the patient's left side to dissect out the seminal vesicle, while the assistant who is on the right directs the suction device.

The neurovascular bundles responsible for erectile function travel lateral to the seminal vesicles. Sharp dissection rather than coagulation should be used in that area.

Following anterior retraction of the bladder, the peritoneum is incised transversely 2–3 cm above the rectovesical junction until the lateral border of the seminal vesicle is fully visualized. A longitudinal incision over the course of the seminal vesicle of interest is then made perpendicular to and crossing the previously made transverse incision. A combination of sharp and blunt dissection, clips, and cautious electrocautery is utilized to dissect the seminal vesicle caudally to its ampulla at the junction of the prostate (Fig. 5).

The neurovascular bundles responsible for erectile function travel lateral to the seminal vesicles (39). Sharp dissection rather than coagulation should be used in that area.

When identification of the seminal vesicle and its adjacent structures is challenging, injection of methylene blue or indigo carmine transperineally (13), transurethrally (19), or transvasal (13) helps to identify the seminal vesicle. To assist in identification of complex or large congenital seminal vesicle cysts Basillote advocates cannulating the ipsilateral ejaculatory duct with a 75cm three French ureteral catheter and injecting a mixture of contrast and indigo carmine so that additional fluoroscopic and laparoscopic guidance is available (19). We have additionally found intraoperative laparoscopic ultrasonography of the seminal vesicle to be helpful. It may be necessary to open Denonvillier's fascia in some cases to get as close to the prostate as possible when clipping and transecting the seminal vesicle. Depending on the extent of dilation, the seminal vesicle can be taken at its junction with the prostate using a Weck clip, titanium clip, or endo-GIA stapler. For patients with large congenital seminal vesicle cysts desiring to bear children the vas deferens needs to be carefully identified and dissected free from the cyst. The vas deferens can occasionally be difficult to separate from the cyst wall. Leaving a narrow strip of the cyst wall on each side along the vas deferens helps minimize the chances of vasal injury (17). Other groups advocate clipping and transecting the vas deferens to facilitate complete resection of the cyst (13,15,18).

After the seminal vesicle has been resected, it can be removed using an endo-catch bag. For large symptomatic congenital cysts, intracorporeal drainage with a needle can facilitate its safe removal. If the surgeon chooses to reapproximate the peritoneum a hernia or universal stapler can be employed. Oral nutrition is resumed the night of surgery and the urethral catheter is removed once the patient is ambulatory. Discharge from the hospital typically occurs the day following surgery.

SUMMARY

- Primary pathology of the seminal vesicle is quite rare.
- Owing to their embryologic similarities, congenital seminal vesicle abnormalities often coexist with ureteral or renal anomalies. The surgeon performing excision of a congenital seminal vesicle cyst should also be prepared to remove ureteral and renal remnants when necessary.
- The neurovascular bundles responsible for erectile function travel lateral to the seminal vesicles (39). Sharp dissection rather than coagulation should be used in that area.
- To date there have been no reports of laparoscopic excision of the seminal vesicle for a primary malignancy.

REFERENCES

1. Sandlow J, Williams R. Surgery of the seminal vesicles. In: Walsh P, ed. Campbell's Urology. 8th ed. Philadelphia: WB Saunders, 2002: 3869–3883.
2. Weldon VE, Tavel FR. Potency-sparing radical perineal prostatectomy: anatomy, surgical technique and initial results. *J Urol* 1988; 140:559.
3. deAssis J. Seminal vesiculectomy. *J Urol* 1952; 68:747.
4. Politano VA, Lankford RW, Susaeta R. A transvesical approach to total seminal vesiculectomy: a case report. *J Urol* 1975; 113:385.
5. Kreager J, Jordan W. Transcocygeal approach to seminal vesicles. *Am Surg* 1965; 31:126.
6. Gonzalez CM, Dalton DP. Endoscopic incision of a seminal vesicle cyst. *Urology* 1998; 51:831.
7. Aumuller G, Riva A. Morphology and functions of the human seminal vesicle. *Andrologia* 1992; 24:183.
8. Redman J. Anatomy of the genitourinary system. In: Gillenwater J, Grayhack J, eds. *Adult and Pediatric Urology*. Chicago: Year Book Medical Publishers 1987:45.
9. Braithwaite JL. The arterial supply of the male urinary bladder. *Br J Urol* 1952; 24:64.
10. Jarow JP. Transrectal ultrasonography of infertile men. *Fertil Steril* 1993; 60:1035.
11. Arey L. The urinary system. In: *Developmental Anatomy*. Philadelphia: WB Saunders 1965:313.
12. Bostwick D. *Urological Surgical Pathology*. St Louis: Mosby 1997:425–426.

13. Carmignani G, Gallucci M, Puppo P, De Stefani S, Simonato A, Maffezzini M. Video laparoscopic excision of a seminal vesicle cyst associated with ipsilateral renal agenesis. *J Urol* 1995; 153:437.
14. Linhares Furtado AJ. Three cases of cystic seminal vesicle associated with unilateral renal agenesis. *Br J Urol* 1973; 45:536.
15. McDougall EM, Afane JS, Dunn MD, Shalhav AL, Clayman RV. Laparoscopic management of retro-vesical cystic disease: Washington University experience and review of the literature. *J Endourol* 2001; 15:815.
16. Altunrende F, Kim ED, Klein FA, Waters WB. Seminal vesicle cyst presenting as rectal obstruction. *Urology* 2004; 63:584.
17. Valla JS, Carfagna L, Tursini S, Mohaidi MA, Bosson N, Steyaert H. Congenital seminal vesicle cyst: prenatal diagnosis and postnatal laparoscopic excision with an attempt to preserve fertility. *BJU Int* 2003; 91:891.
18. Ikari O, Castilho LN, Lucena R, D'Ancona CA, Netto NR Jr. Laparoscopic excision of seminal vesicle cysts. *J Urol* 1999; 162:498.
19. Basillote JB, Shanberg AM, Woo D, Perer E, Rajpoot D, Clayman RV. Laparoscopic excision of a seminal vesicle cyst in a child. *J Urol* 2004; 171:369.
20. van den Ouden D, Blom JH, Bangma C, de Spiegeleer AH. Diagnosis and management of seminal vesicle cysts associated with ipsilateral renal agenesis: a pooled analysis of 52 cases. *Eur Urol* 1998; 33:433.
21. Cherullo E, Meraney A, Bernstein L, Einstein D, Thomas A, Gill I. Laparoscopic management of congenital seminal vesicle cysts associated with ipsilateral renal agenesis. *J Urol* 2002; 167:1263.
22. Nadler RB, Rubenstein JN. Laparoscopic excision of seminal vesicle for chronic pelvic pain syndrome. *J Urol* 2001; 166:2293–2294.
23. Corriere JN Jr. Painful ejaculation due to seminal vesicle calculi. *J Urol* 1997; 157:626.
24. Thiel R, Effert P. Primary adenocarcinoma of the seminal vesicles. *J Urol* 2002; 168:1891.
25. Ohmori T, Okada K, Tabei R, et al. CA125-producing adenocarcinoma of the seminal vesicle. *Pathol Int* 1994; 44:333.
26. Berger AP, Bartsch G, Horninger W. Primary rhabdomyosarcoma of the seminal vesicle. *J Urol* 2002; 168:643.
27. Latchamsetty KC, Elterman L, Coogan CL. Schwannoma of a seminal vesicle. *Urology* 2002; 60:515.
28. Tabata K, Irie A, Ishii D, Yanagisawa N, Iwamura M, Baba S. Primary squamous cell carcinoma of the seminal vesicle. *Urology* 2002; 59:445.
29. Oxley JD, Brett MT, Gillatt DA, Burton P. Seminal vesicle carcinoma. *Histopathology* 1999; 34:562.
30. Davis NS, Merguerian PA, DiMarco PL, Dvoretzky PM, Rashid H. Primary adenocarcinoma of seminal vesicle presenting as bladder tumor. *Urology* 1988; 32:466.
31. Scheinar J, Hruska F, Dusek J. Carcinoma of the seminal vesicles. *Z Urol Nephrol* 1980; 73:415.
32. Rodriguezkees OS. Clinical improvement following estrogenic therapy in a case of primary adenocarcinoma of the seminal vesicle. *J Urol* 1964; 91:665.
33. Marmar J, Siegelman E. Seminal vesiculography and vasography. In: Pollack H., ed. *Clinical Urography*. Philadelphia: WB Saunders 2000:378–387.
34. Secaf E, Nuruddin RN, Hricak H, McClure RD, Demas B. MR imaging of the seminal vesicles. *Am J Roentgenol* 1991; 156:989.
35. David V. MR imaging of the prostate and seminal vesicles. *Magn Reson Imaging Clin N Am* 1996; 4:497.
36. Zinner A. Ein fall von intravesikaler samenblasenzyste. *Wein Med Wochenschr* 1914; 64:605.
37. Kavoussi LR, Schuessler WW, Vancaillie TG, Clayman RV. Laparoscopic approach to the seminal vesicles. *J Urol* 1993; 150:417.
38. Guillonneau B, Vallancien G. Laparoscopic radical prostatectomy: the Montsouris technique. *J Urol* 2000; 163:1643.
39. Tewari A, Peabody J, Fischer M, et al. An operative and anatomic study to help in nerve sparing during laparoscopic and robotic radical prostatectomy. *Eur Urol* 2003; 43:444.

James F. Donovan

Division of Urology, Department of Surgery, University of Cincinnati, Cincinnati, Ohio, U.S.A.

Marlou B. Heiland

University of Cincinnati, Cincinnati, Ohio, U.S.A.

- | | |
|--|-----------------|
| ■ INTRODUCTION | Instrumentation |
| ■ DIAGNOSIS | Operation |
| ■ INDICATIONS FOR TREATMENT | ■ RESULTS |
| ■ TREATMENT OPTIONS | Fertility |
| Nonoperative Therapy | Pain |
| Operative Therapy | Complications |
| ■ CONTRAINDICATIONS TO LAPAROSCOPIC VARIX LIGATION | ■ REFERENCES |
| ■ SURGICAL TECHNIQUE | |
| Patient Preparation | |

INTRODUCTION

A varicocele is an abnormally dilated and tortuous pampiniform plexus, the venous complex that flows into the spermatic veins. Varicocele is present in 15% of the male population and not present prior to puberty (1–3). The majority of cases are thought to be due to absent or incompetent valves in the proximal internal spermatic vein with left-sided predominance linked to the higher venous pressures in the left internal spermatic venous system. The right spermatic vein enters the vena cava at an oblique angle, while the left spermatic vein enters the left renal vein at a right angle. The left venous insertion is also 8 to 10 cm more cephalad than the insertion on the right. Both factors presumably increase the hydrostatic pressure within the left spermatic vein when compared with the right (1). Approximately 90% of unilateral varicoceles are left-sided, although bilateral varices may be found in 50% of patients (4, 25).

Varicocele is usually asymptomatic, but occasionally causes orchalgia. When symptomatic, varicocele causes a dull ache or heavy sensation in the testes that is typically worse at the end of the day or after prolonged standing or heavy exertion. Recumbency usually offers relief. Varicoceles are associated with impaired spermatogenesis and steroidogenesis (5–7). In a study conducted by the World Health Organization on 9043 men, the incidence was 25.4% in men with abnormal semen and 11.7% in men with normal semen (8). The majority of varicoceles are not associated with infertility. However, the prevalence of varicocele is increased in men presenting with male-factor subfertility—40% in men presenting with primary infertility and 80% in men presenting with secondary infertility suggesting a progressive decline in spermatogenesis and steroidogenesis over time if left untreated (9). Deleterious effects on the contralateral testis have also been noted (6, 10). The exact mechanism of impaired fertility is unknown and probably multifactorial (11). Reversed venous blood flow in the spermatic veins disrupts the counter-current testicular temperature modulation. Zorgniotti and Macleod demonstrated increased testicular temperature associated with varices (12) and Wright et al. reported a decrease in testis temperature following varicocelectomy (13).

DIAGNOSIS

Varicocele presents due to male-factor subfertility, orchalgia, or as an incidental finding on routine physical examination. Varicocele is diagnosed primarily by physical

examination of the cooperative, relaxed, and warm patient in the upright position. To limit the effect of cremasteric retraction the testes are gently supported. Inspection and palpation of the scrotal contents is directed to a point just superior to the testes. Grade III (large) varicoceles are visibly thickened veins above the testis. Grade II (medium) varicoceles are palpable in the standing patient without a Valsalva's maneuver. Grade I (small) are palpable only with a Valsalva's maneuver. Ipsilateral testicular atrophy may also be present based on measurement or comparison to the contralateral testes. Isolated varicocele on the right may be associated with renal tumors, retroperitoneal masses, or lymph-adenopathy and should be further evaluated for causes of proximal venous compression. Dilated veins can be distinguished from a cord lipoma because the lipoma will tend to slip from grasp when gently pinched (14).

Additional diagnostic studies include ultrasound, thermography, venography, scintigraphy, and MRI but are not recommended in the routine evaluation of the infertile male unless the physical examination is equivocal. When faced with an inconclusive physical examination and a high index of suspicion, scrotal ultrasonography may provide evidence of subclinical varicocele based upon venous caliber and demonstration of reversed venous flow during Valsalva's maneuver. Furthermore, ultrasonography is noninvasive and can identify other pathologic processes in the testes, epididymis, and spermatic cord including objective measurement of testicular dimensions with greater accuracy than physical examination or orchidometer (15). A subclinical varicocele is found only on scrotal sonography and not on physical examination. According to Jarroo et al., only palpable varicoceles are clearly linked to male subfertility (16).

INDICATIONS FOR TREATMENT

Varix ligation is indicated in patients with a palpable varix and at least one of the following: (i) pain that is not attributable to other intrascrotal pathology (17); (ii) adolescent ipsilateral testis volume loss of 2 ml or greater than 20% of volume (18–21); or (iii) infertility attributable to the male partner based upon abnormal semen analysis or abnormal results of sperm function tests associated with a female partner who is fertile or suffers a treatable cause of subfertility (16). Treatment of varicocele is not indicated for infertility if the male partner has normal semen quality or a subclinical varicocele (16). Men with palpable varicoceles and abnormal semen quality who are not currently attempting conception but are interested in preservation of fertility may wish to undergo varix ligation when informed of the progressive deterioration of semen quality associated with varicocele (5,7,9). Varix ligation is cost-effective in comparison to alternate treatments, which might include assisted reproductive techniques such as in vitro fertilization with or without intracytoplasmic sperm injection (22,23). Young men with asymptomatic varicoceles and normal semen parameters should be followed with semen analyses and physical examination every one to two years. Adolescents with an asymptomatic varicocele and normal ipsilateral testicular size should be offered annual examination and measurement of testicular size. Repair should be offered at the first sign of testicular or semen abnormality (16). Varix ligation is not recommended for a subclinical varicocele or for prophylaxis in the asymptomatic adolescent (2,24).

TREATMENT OPTIONS

Nonoperative Therapy

Varicoceles can currently be treated by both operative and nonoperative techniques. Nonoperative treatment is typically performed by interventional radiology and includes transvenous embolization with coils or balloons or injection of sclerosing agents (boiling-hot contrast or absolute ethanol) to induce varix thrombosis. Both embolization and sclerosis are performed under local anesthesia with supplementary intravenous sedation at a cost of one-fourth to one-fifth that of surgery (25). Rates of success vary but generally do not approach those reported for operative varix ligation especially with right-sided varicoceles (24,25).

Other nonoperative treatments have not gained acceptance due to equivocal outcomes. Attempts to decrease testicular temperature by means of a scrotal cooling were cumbersome and lacking in durable improvements in semen analysis (12). Empiric medical therapy (clomiphen citrate, tamoxifen) showed no benefit (26).

Operative Therapy

Surgical treatment options are derivatives of either the inguinal approach of Ivanissevich (27) or the retroperitoneal approach of Palomo (28). Microsurgical techniques in the inguinal and subinguinal exposures require careful dissection in order to protect the spermatic artery and preserve lymphatic channels; magnification (e.g., loupes in the inguinal approach and microscope in the subinguinal approach) is mandatory (16,29). The inguinal approach identifies the spermatic vessels as they course through the inguinal canal where spermatic cord structures incorporate the cremasteric vein that may contribute to the varix pathophysiology. The spermatic and cremasteric veins are isolated and ligated while protecting the vas and spermatic artery. The inguinal approach is associated with increased postoperative pain and delay in return to full activity when compared with the subinguinal or laparoscopic techniques (30,31).

The subinguinal approach requires magnification and ligation of a greater number of venous tributaries that are intimately associated with the testicular artery (32). Furthermore, multiple spermatic arteries may course through the spermatic cord at the subinguinal level making dissection more demanding (33). Doppler ultrasound can facilitate detection of number and location of spermatic arteries.

The Palomo approach, e.g., ligation of the spermatic veins above the internal ring, can be performed by open or laparoscopic technique. The retroperitoneal approach permits ligation of spermatic veins without the attendant risk of injuring arterial collaterals, specifically the cremasteric and deferential arteries, which join the spermatic cord at or below the internal ring. One disadvantage of this approach is the lack of access to the cremasteric vein, which, according to Enquist and Stein, will contribute to a higher recurrence rate when compared with the subinguinal approach (32,34).

Advantages of laparoscopic varix ligation

- Access to right and left varices with the same number of access ports (25, 35);
- Improved visualization of the vessels via a transperitoneal approach especially in the obese patient;
- Decreased number of veins to ligate (and fewer arteries to spare in the cephalad spermatic vascular bundle if one so chooses);
- Magnification of vascular structures and a panoramic view of the retroperitoneal structures, which permits identification and ablation of aberrant collateral veins arising from the kidney, iliac vein, or sigmoid colon;
- Minimal postoperative pain and a very short convalescence with reduction in lost productivity and early return to work;
- Avoidance of injury to the vas and collateral arterial flow as may occur with the inguinal or subinguinal approaches;
- An option in the presence of a failed inguinal/subinguinal or percutaneous embolization approach or in patients who have had previous inguinal hernia repair (36).

Laparoscopic varicocelelectomy is contraindicated in patients with recurrent or persistent with recurrent or persistent varix following a retroperitoneal varix ligation.

CONTRAINDICATIONS TO LAPAROSCOPIC VARIX LIGATION

Laparoscopic varicocelelectomy is contraindicated in patients with recurrent or persistent varix following a retroperitoneal varix ligation.

The site of laparoscopic transperitoneal and open retroperitoneal varix ligation is the same. Patients with persistent varix following retroperitoneal ligation should be treated by alternate methods: either transvenous spermatic vein sclerosis or spermatic vein ligation via the inguinal or subinguinal approach (36,37). We have, however, successfully performed salvage laparoscopic varicocelelectomy in patients who have undergone failed transvenous or inguinal varix ligation. Previous abdominal surgery is a relative contraindication and risk to intraperitoneal structures but can be minimized with use of the Hasson cannula or the Endopath Optiview^{®a}. Successful laparoscopic varix ligation utilizing the Hasson cannula has been performed in patients who previously have undergone appendectomy, hernia repair, omphalocele, and pyloromyotomy without complication (38,39).

SURGICAL TECHNIQUE

Patient Preparation

The patient should be advised of the risks and benefits to varix ligation and of the available approaches with discussion of the advantages and disadvantages to each (40). Special emphasis is paid to the risks peculiar to laparoscopy and to the possibility need to convert to open technique and possible laparotomy to repair injury to intestine or blood

^aEthicon, Cincinnati, OH.

vessel. In our series to date, all varix ligations have been completed laparoscopically. Each patient should be aware that successful varix ligation results in improvement in semen parameters and/or reduction in pain in most but not all patients. In fact, there is a nominal risk of testicular atrophy due to compromise of testicular arterial blood flow. In a recent study laparoscopic varix ligation for painful varicocele resulted in complete resolution of pain in 84.5% at a median follow-up of six months (41).

Laparoscopy is typically performed under general anesthesia. Although this procedure has been done under both epidural and local anesthesia, we feel that laparoscopy with pneumoperitoneum is best tolerated under general anesthesia. There is a report of laparoscopic varix ligation using local anesthesia but no attempt to preserve the testicular artery was made (42). Preservation of the spermatic artery is delicate and time-consuming and hampered by patient movement. Proponents of the retroperitoneal approach to varix ligation debate the utility of sparing the spermatic artery. Several reports have found no difference in testis volume after laparoscopic clipping of the entire retroperitoneal spermatic vascular bundles without arterial sparing (43–45). Several authors report increased rates of varix recurrence and hydrocele formation when the spermatic artery is spared (43,46,47). Conversely, many surgeons have excellent success with arterial sparing techniques (29,48).

We do not currently require a bowel preparation prior to laparoscopic varix ligation. Routine antibiotic prophylaxis consists of a cephalosporin one hour before surgery. After induction of anesthesia, an oral gastric tube is placed and the stomach evacuated. The surgical field includes the external genitalia and the entire abdomen. Gentle retraction of the testes and spermatic cord can aid in identifying the spermatic vessels and collateral veins traversing the internal ring. We typically pass a straight catheter to drain the bladder before proceeding with insertion of the Veress needle.

Instrumentation

We have used both the Veress needle and the open Hasson technique to gain initial pneumoperitoneum. Currently, we use the Veress needle and feel this is safe when appropriate precautions are taken. The principle instruments we use are curved scissors, a curved dissector, and a right-angle dissector. For intracorporeal ties we add two laparoscopic needle drivers. Five millimeter clip applicators can be used to clip-ligate smaller vessels. A 5-mm 45° laparoscopic lens is used. We no longer routinely use a 5 mm laparoscopic Doppler probe to assist in the identification of the spermatic artery or arteries because several investigators have shown no benefit from sparing the internal spermatic artery (43–45). We use 5-mm ports, which decrease morbidity when compared with 10mm ports. Small veins can be ligated with use of the 5-mm clip applicator. Larger veins or bundles of veins that exceed the capacity of the 5-mm clip can be ligated with 2-0 silk ligature using intracorporeal tying techniques thus avoiding the need to separate the venous branches into several small bundles. An instrument tie can be accomplished using two needle drivers or two curved dissectors. Alternatively, one may ligate by performing extracorporeal ties using a 5-mm knot pusher. If choosing not to preserve the testicular artery, mass ligation of the entire vascular bundle can be accomplished with extracorporeal ligation or a two-port technique using the harmonic scalpel.

Operation

Patient Position and Port Placement

We place the patient in supine position with arms adducted. Skin preparation includes the abdomen and genitalia. After infiltrating with 0.25% marcaine, a 5 mm skin incision is made just above the umbilicus. The Veress needle is passed through this incision and into the peritoneal cavity. Proper positioning of the Veress needle is confirmed using appropriate tests and insufflation proceeds to reach intraperitoneal pressure of 20 mmHg. Once proper pneumoperitoneum is achieved, a 5 mm trocar is advanced into the peritoneal cavity and a 45° camera is inserted. We inspect the peritoneal contents, giving special attention to viscera deep to the site of the Veress needle and first trocar insertion. Next, we place two 5 mm ports. In the case of a left varicocele, one port is placed lateral to the rectus muscle just below the umbilicus and the other is placed in the midline midway between the umbilicus and pubis. For bilateral varicoceles, both ports are placed lateral to the left and right rectus muscle just below the level of the umbilicus. Once the ports are in place the patient is placed in the Trendelenburg position.

Dissection and Ligation

If the sigmoid colon is fixed over the spermatic veins cephalad to the left internal ring (the proposed site of surgery), the colon is mobilized to expose the spermatic vascular bundle incising along the lateral peritoneal reflection. Once the internal ring is exposed, the spermatic vessels are identified deep to the peritoneal membrane passing cephalad over the psoas muscle. The vas is seen curving medially over the external iliac vein and artery.

Using curved scissors, a 3- to 5-cm incision through the peritoneum is made parallel and lateral to the spermatic vessels with the caudal limit 3 cm above the internal ring. This minimizes injury to the vas deferens and scrotal insufflation. The medial flap of the peritoneum is grasped and the underlying spermatic vessels are gently and bluntly swept from the underside of this flap. From the midpoint of the first incision a perpendicular incision is made through the medial peritoneal flap to the lateral aspect of the iliac artery. This resulting T incision provides ample exposure. External traction on the testis/spermatic cord helps to identify all veins that may contribute to the varicocele.

The entire spermatic vascular bundle is mobilized from the underlying psoas muscle using both blunt and sharp dissection. Deep dissection is avoided to spare the underlying genitofemoral nerve crossing anterior to the psoas muscle. Loose adventitial tissue is stripped from the spermatic vessels. The vascular bundle is separated into medial and lateral bundles. Typically there are three to eight spermatic veins and a single spermatic artery located posterior and medial to the veins. The spermatic artery is not specifically identified and intracorporeal knotting techniques are used to ligate and divide each vascular bundle, which are then divided between ligatures. The procedure may be performed on the contralateral side as needed.

Completion of the Operation

An orderly and systematic departure from the abdomen is recommended to ensure hemostasis and rule out inadvertent injury. The operative site(s) is inspected with intraperitoneal pressure reduced to <8 mmHg and active bleeding sites are identified and cauterized. Each trocar site is inspected at the time of removal to ensure no active bleeding from the anterior abdominal wall. Scrotal emphysema from extravasation of CO₂ through the internal ring can be massive and this can be expressed back into the peritoneal cavity and vented through an open trocar site. The patient is returned to the horizontal position; we aspirate any blood or irrigant that may have collected in the pelvis. The subcutaneous tissues are reapproximated and the skin is closed with a subcuticular 3-0 Vicryl Rapide^{®b} or Dermabond^{®c}. Virtually all procedures are performed in the outpatient setting. The patient is advised to return to full activity as tolerated. Semen analyses are performed every three months for one year or until pregnancy is achieved (16).

RESULTS

Fertility

Varicocele repair has been proven to improve semen parameters in 50% to 80% of men and surgical methods successfully eliminate >90% of the varicoceles (16,34,35,43). Pregnancy rates following laparoscopic varix ligation (26–46%) are similar to those reported following open repair (49,50). The American urological association's Best Practice Guidelines identified only two well-designed, randomized, prospective controlled studies of men with palpable varicoceles, abnormal semen quality, and normal spouses (16). In one study there was a significant increase in testicular volume and semen quality but no increase in pregnancy rates after repair was demonstrated (51). The other study showed a 60% conception rate following varicocele repair compared to a 10% conception rate in the untreated group (52). American urological association's Best Practice Guidelines considers varicocele repair for infertile men with palpable varicoceles an appropriate option because of the proven improvement in semen parameters, low operative risks, and the possibility of increased fertility (16).

^bEthicon, Cincinnati, OH.

^cJohnson & Johnson, Somerville, NJ.

Pain

Pain attributable to varicocele resolves in 50% to 86% of patients presenting with orchalgia (41,53). Cadeddu et al. report significant pain reduction following laparoscopic testicular denervation (gonadal vessels divided cephalad to the vas deferens) in men with chronic orchalgia refractory to medical management and not attributable to varicocele (54).

Complications

Complications include hydrocele and recurrent varicocele. Incidence of either is reportedly less when the internal spermatic artery is not preserved (29,43,46–48). Other complications are rare and include the following: (i) bleeding either from inferior epigastric vessel secondary to trocar placement or delayed bleeding from the spermatic vessel due to incomplete ligation or thermal injury and (ii) visceral injury due to trocar or instrument mishap. Very few surgeons report conversion to open approach. Conversion is usually due to bowel adhesions. The operating microscope is not readily available to many urologists and for surgeons skilled at laparoscopy, the effectiveness and low complication rate of laparoscopic varicocelectomy supports its use in urologic practice.

REFERENCES

1. Fretz PC, Sandlow JI. Varicocele: current concepts in Pathophysiology, diagnosis, and treatment. *Urol Clin North Am* 2002; 29:921–937.
2. Belman AB. The dilemma of the adolescent varicocele. *Contemp Urol* 1991; 3:21–27.
3. Sigman M, Howards SS. Male infertility. In: Walsh PC, et al., ed. *Campbell's Urology*. Philadelphia: WB Saunders Company, 1992:661–705.
4. Bigot JM, Barret F, Helenon C. Phlebography of the right spermatic vein in varicoceles. In: Jecht EW, Zeitler EP, eds. *Varicocele and Male Infertility*. Berlin, Springer-Verlag 1982:59–70.
5. Gorelick JI, Goldstein M. Loss of fertility in men with varicocele. *Fertil Steril* 1993; 59:613–661.
6. Saypol DC, Howard SS, Turner TT, et al. Influence of surgically induced varicocele on testicular blood flow, temperature, and histology in adult rats and dogs. *J Clin Invest* 1981; 68:39–45.
7. Witt MA, Lipshultz LI. Varicocele: a progressive or static lesion? *Urology* 1993; 42:541–543.
8. World Health Organization. The influence of varicocele on parameters of fertility in a large group of men presenting to infertility clinics. *Fertil Steril* 1992; 57:1289–1293.
9. Chehval MJ, Purcell MH. Deterioration of semen parameters over time in men with untreated varicoceles: evidence of progressive testicular damage. *Fertil Steril* 1992; 57:174–177.
10. Green KF, Turner TT, Howards SS. Varicocele: reversal of the testicular blood flow and temperature effects by varicocele repair. *J Urol* 1984; 131:1208–1211.
11. Howards SS. Treatment of male infertility. *N Engl J Med* 1995; 332:312–317.
12. Zorngiotti AW, Macleod J. Studies in temperature, human semen quality, and varicocele. *Fertil Steril* 1973; 24:854–863.
13. Wright EJ, Young GP, Goldstein M. Reduction in testicular temperature after varicocelectomy in infertile men. *Urology* 1997; 50:257–259.
14. Kwon ED, Sandlow JI, Donovan JF. Varix Ligation. In: *Basic and Procedural Laparoscopy***** (from one of your book chapters)*
15. Rivkees SA, Hall DA, Boepple PA, et al. Accuracy and reproducibility of clinical measures of testicular volume. *J Pediatr* 1987; 110(6):914–917.
16. Jarow JP, Sharlip ID, Belker AM, et al. Best practice policies for male infertility. *J Urol* 2002; 167:2138–2144.
17. Goldstein M. Surgical management of male infertility and other scrotal disorders. In: Walsh PC, et al., ed. *Campbell's Urology*. Philadelphia: WB Saunders Co, 2002:1582.
18. Okuyama A, Nakamura M, Namikim, et al. Surgical repair of varicocele at puberty: preventative treatment for fertility improvement. *J Urol* 1988; 139:562–564.
19. Paduch DA, Niedzielski J. Repair versus observation in adolescent varicocele: a prospective study. *J Urol* 1997; 158(3 Pt 2):1128–1132.
20. Yamamoto M, Hibih, Miyake k, et al. Effects of varicocelectomy on testis volume and semen parameters in adolescents: a randomized prospective study. *Nagoya J Med Sci* 1995; 58:127–132.
21. Sigman M and Jarow JP. Ipsilateral testicular hypotrophy is associated with decreased sperm counts in infertile men with varicoceles. *J Urol* 1997; 158:605–607.
22. Schlegel PN. Is assisted reproduction the optimal treatment for varicocele-associated infertility? A cost-effective analysis. *Urology* 1997; 49:83–90.
23. Marmar J and Benoff S. Editorial: New scientific information related to varicoceles. *J Urol* 2003; 170:2371–2373.
24. McClure RD, Khoo D, Jawvi K, et al. Subclinical varicocele: the effectiveness of varicocelectomy. *J Urol* 1991; 145:789–791.
25. Fisch H. The surety of surgical repair of varicoceles. *Contemp Urol* 1991; 68–74.
26. Unai D, Yeni E, Verif A, et al. Clomiphene citrate versus varicocelectomy in treatment of subclinical varicocele: a prospective randomized study. *Int J Urol* 2001; 8(5):227–230.

27. Ivanissevich O. Left varicocele due to reflux: experience with 4,470 operative cases in forty-two years. *J Int Coll Surgeons* 1960;34:742–755.
28. Palomo A. Radical cure of varicocele by a new technique: preliminary report. *J Urol* 1949; 61:604.
29. Goldstein M, Gilbert BR, Dicken AP, et al. Microsurgical inguinal varicocelectomy with delivery of the testis: an artery and lymphatic sparing technique. *J Urol* 1992;148:1808–1811.
30. Kramolowsky EV, et al. Randomized comparison of open versus laparoscopic varix ligation for the treatment of infertility. *J Urol* 1997;157:143.
31. Hopps CV, Lemer ML, Schlegel PN, et al. Intraoperative varicocele anatomy: a microscopic study of the inguinal versus subinguinal approach. *J Urol* 2003;170:2366–2370.
32. Marmar JL, DeBenedictis TJ, Prais D. The management of varicoceles by microdissection of the spermatic cord at the external inguinal ring. *Fertil Steril* 1985; 43:583.
33. Ogle A, et al. Analysis of testicular artery arborization within the spermatic cord. *J Urol* 1991;145(Suppl.):283A.
34. Enquist E, Stein BS, Sigman M. Laparoscopic versus subinguinal varicocelectomy: a comparative study. *Fertil Steril* 1994;61:1092–1096.
35. Donovan JF, Winfield HN. Laparoscopic varix ligation. In Gomella LG, Kozminski M, and Winfield HN eds: *Laparoscopic Urologic Surgery*. New York, Raven Press, 1994: 99137–99149.
36. Murray RR Jr, Mitchell SE, Kachir S, et al. Comparison of recurrent varicocele anatomy following surgery and percutaneous balloon occlusion. *J Urol* 1986;135:286–289.
37. Gill B, et al. Significance of intraoperative venographic patterns on the postoperative recurrence and surgical incision placement of pediatric varicoceles. *J Urol* 1990;144(Pt 2):502–505.
38. Donovan JF, Winfield HN. Laparoscopic varix ligation. *J Urol* 1992;147:77–81.
39. Donovan JF. Laparoscopic varix ligation with the Nd:YAG laser. *J Endourol* 1992;6:165–171.
40. Donovan JF. Legal issues in laparoscopy. *Contemp Urol* 1992;4:74–81.
41. Maghraby HA. Laparoscopic varicocelectomy for painful varicoceles: merits and outcomes. *J Endourol* 2002;16:107–110.
42. Matsuda T, et al. Laparoscopic varicocelectomy. *J Urol* 1991;145:325A.
43. Kattan S. The impact of internal spermatic artery ligation during laparoscopic varicocelectomy on recurrence rate and short post operative outcome. *Scand J Urol Neph* 2001;35:218–221.
44. Matsuda T, Horni Y, Yoshida O. Should the testicular artery be preserved at varicocelectomy? *J Urol* 1993;149:1357–1360.
45. Atassi O, Kass EJ, Steinert BW. Testicular growth after successful varicocele correction in adolescents: comparison of artery sparing techniques with the Palomo procedure. *J Urol* 1995; 153:482–483.
46. Kass EJ, Marcol B. Results of varicocele surgery in adolescents: a comparison of techniques. *J Urol* 1992;148: 694–696.
47. Lenk S, Fahlenkamp D, Glied V, et al. Comparison of different methods of treating varicoceles. *J Androl* 1994; 15 suppl 34S–37S.
48. Minevich E, Wacksman J, Lewis AG, et al. Inguinal microsurgical varicocelectomy in the adolescent; technique and preliminary results. *J Urol* 1998;159:1022–1024.
49. Jarow JP, Assimos DG, Pittaway DE. Effectiveness of laparoscopic varicocelectomy. *Urology* 1992; 42:544–547.
50. Lund GO, Donovan JF, Winfield HN. Laparoscopic varicocele ligation. In: Arregui ME, et al. eds. *Principles of Laparoscopic Surgery; Basic and Advanced Techniques*. New York, Springer-Verlag, 1996.
51. Nieschlag E, Hertle L, Fischedick A, et al. Update on treatment of varicocele: counseling as effective as occlusion of the vena spermatica. *Hum Reprod* 1998;13:2147.
52. Madgar I, Lunenfeld B, Maskiach S, et al. Controlled trial of high spermatic vein ligation for varicocele in infertile men. *Fertil Steril* 1995;63:120.
53. Peterson AC, Lance RS, Ruiz HE. Outcomes of varicocele ligation done for pain. *J Urol* 1998; 159:1565–1567.
54. Cadeddu JA, Bishoff JT, Chan Dr, et al. Laparoscopic testicular denervation for chronic orchalgia. *J Urol* 1999;162:1708.

LAPAROSCOPIC PLACEMENT OF PERITONEAL DIALYSIS CATHETER

Wisoot Konchareonsombat

Division of Endourology, Laparoscopy and Minimally Invasive Surgery, Department of Urology, University of Miami Miller School of Medicine, Miami, Florida, U.S.A

Arif Asif

University of Miami Miller School of Medicine, Miami, Florida, U.S.A.

Raymond J. Leveillee

Division of Endourology, Laparoscopy and Minimally Invasive Surgery, Department of Urology, University of Miami Miller School of Medicine, Miami, Florida, U.S.A.

- | | |
|---|--|
| <ul style="list-style-type: none"> ■ INTRODUCTION ■ ANATOMY OF THE ABDOMINAL WALL AND PERITONEUM <ul style="list-style-type: none"> Innervation and Lymphatic Drainage The Peritoneum Physiology of the Peritoneum ■ FACTORS AFFECTING PERITONEAL DIALYSIS EFFICIENCY <ul style="list-style-type: none"> Surface Area ■ THE INDICATION FOR DIALYSIS ■ PERITONEAL ACCESS DEVICES <ul style="list-style-type: none"> Acute Peritoneal Dialysis Catheter Chronic Peritoneal Dialysis Catheter ■ CONTRAINDICATIONS TO PERITONEAL DIALYSIS CATHETER PLACEMENT ■ SURGICAL TECHNIQUES <ul style="list-style-type: none"> Dissecting Technique (Open Surgery) Blind or "Seldinger" Technique Peritoneoscopic Technique ■ LAPAROSCOPIC IMPLANTATION OF CONTINUOUS AMBULATORY PERITONEAL DIALYSIS CATHETER | <ul style="list-style-type: none"> Patient Preparation Instrumentation Technique ■ VIDEOLAPAROSCOPY-ASSISTED IMPLANTATION OF CONTINUOUS AMBULATORY PERITONEAL DIALYSIS CATHETER <ul style="list-style-type: none"> Technique ■ MINILAPAROSCOPIC PLACEMENT OF PERITONEAL DIALYSIS CATHETER <ul style="list-style-type: none"> Technique ■ BURYING THE PERITONEAL DIALYSIS CATHETER ■ POSTOPERATIVE CARE ■ COMPLICATIONS OF LAPAROSCOPIC PLACEMENT OF CHRONIC PERITONEAL DIALYSIS CATHETER <ul style="list-style-type: none"> Acute Complications Late Complications ■ PERITONEAL DIALYSIS CATHETER REMOVAL ■ SUMMARY ■ REFERENCES |
|---|--|

INTRODUCTION

Chronic renal failure and end-stage renal disease are increasingly significant public health problems both medically and economically. Approximately 3 million persons in the United States have chronic renal failure, as defined by a glomerular filtration rate of less than 60 mL/min/1.73 m. Many of these patients progress to end-stage renal disease, the prevalence of which in the United States was almost 1400 per million, or a total of 406,081 patients in 2001, with an average age of 57.8 years. The prevalence of end-stage renal disease has increased every year since 1980, although the rate of increase has slowed to 2.4% per year (1).

The etiology of this persistent increase in end-stage renal disease is multifactorial. The four most common causes of end-stage renal disease in the United States are diabetes mellitus (138,483 total cases and 41,312 new cases in 2001), hypertension (91,636 total cases and 24,942 new cases in 2001), glomerulonephritis (60,888 total cases and 7687 new cases in 2001), and cystic kidney diseases (17,112 total cases and 2143 new cases in 2001) (1). The incidence of diabetic nephropathy, which is the leading cause of end-stage renal disease in adults, continues to increase. Another factor is the improved survival of patients with severe cardiovascular disease and diabetes, who are at high risk for end-stage renal disease, and our increasing acceptance of the placement of persons with severe comorbid illnesses on treatment for end-stage renal disease. Also, end-stage renal disease has increased dramatically in the elderly population and this has coincided with the increasing age of the U.S. population.

The annual cost of the end-stage renal disease treatment program consumes an ever-increasing portion of the Medicare budget—22.8 billion dollars in 2001, amounting to 6.4% of the annual Medicare budget (1). Treatment options for end-stage renal disease include hemodialysis, peritoneal dialysis, which may be continuous ambulatory peritoneal dialysis or continuous cycling peritoneal dialysis, cadaveric renal transplantation, or living donated renal transplantation.

The 2003 annual data report from the U.S. Renal Data System listed 86,289 patients initiated on hemodialysis and 6991 initiated on peritoneal dialysis for the preceding calendar year. From 1997 to 2001, the incident rates for initiation of peritoneal dialysis dropped by 4%, whereas the incident rates for hemodialysis increased 3.3% and the incident rate for renal transplant as the initial end-stage renal disease treatment modality increased 8.9%. The prevalent end-stage renal disease population currently includes 264,710 patients treated with hemodialysis and 24,268 treated with peritoneal dialysis; 113,866 patients have a functioning renal transplant. Thus 65% of prevalent end-stage renal disease patients are treated with hemodialysis, 28% are treated with a functioning renal transplant, and 7% are treated with peritoneal dialysis (1).

The incidence of peritoneal dialysis indicates that approximately 7000 new peritoneal dialysis catheters are placed each year in the United States and that approximately 24,000 must be properly maintained. Many different renal replacement therapies are available for the treatment of end-stage renal disease patients. The most commonly utilized renal replacement therapies are hemodialysis, peritoneal dialysis, and renal transplantation. Outcome comparisons suggest that renal transplantation is the best overall treatment for end-stage renal disease patients. Specific patient characteristics supporting the use of one modality over another have previously been described. Renal replacement therapy is preserved longer on peritoneal dialysis than on hemodialysis (2).

Continuous ambulatory peritoneal dialysis is an established and effective method for end-stage renal failure patients. Open surgical insertion is often associated with significant morbidity. Percutaneous and laparoscopic catheter placement has been used increasingly in recent years (3).

ANATOMY OF THE ABDOMINAL WALL AND PERITONEUM

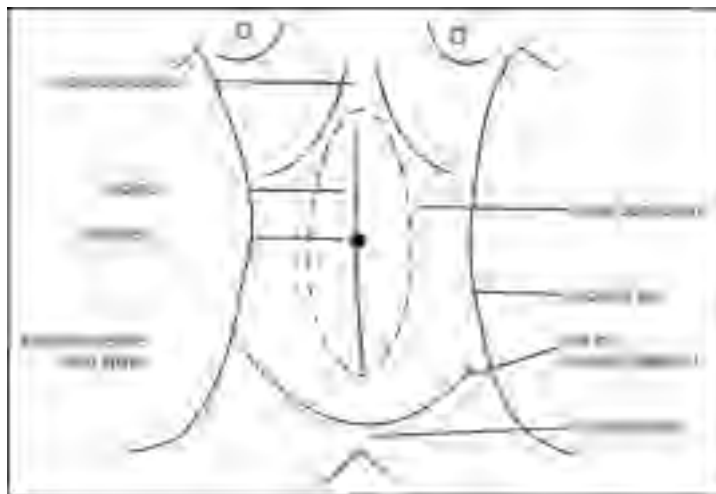
The abdominal wall (Fig. 1) extends from the osteocartilaginous thoracic cage to the pelvis. It is helpful for descriptive purposes to subdivide it into anterior abdominal wall, right and left abdominal walls (loin and flanks), and posterior abdominal wall. The combined term “anterolateral wall” is used because some structures (the external oblique muscle and cutaneous nerves) are located in the anterior and lateral walls (4–6).

Innervation and Lymphatic Drainage

The abdominal wall is composed of nine layers. From outward in they are: (i) skin, (ii) subcutaneous tissue, (iii) superficial fascia (Scarpa’s fascia), (iv) external abdominal oblique muscle, (v) internal abdominal oblique muscle, (vi) transversus abdominis muscle, (vii) transversalis fascia, (viii) extraperitoneal adipose tissue, and (ix) peritoneum.

The muscular abdominal wall is composed of three flat muscles (external oblique muscle, internal oblique, and transversus abdominis) and one strap-like muscle (rectus

FIGURE 1 ■ The anterior abdominal wall.



abdominis muscle). The parietal peritoneum is the innermost layer of the abdominal wall. It is a thin layer of dense, irregular connective tissue and is covered on the inside by a layer of simple squamous mesothelium. The peritoneum provides little strength in wound closure, but it affords remarkable protection from infection if it remains uninvolved.

The rectus muscles are each contained within a facial sheath, which is derived from the aponeurosis of the three flat abdominal muscles. Below the semicircular line, which is the point at which the inferior epigastric artery enters the rectus sheath, the posterior rectus sheath is lacking because the fascia of flat muscles pass anterior to the rectus muscle. A thin layer of the transversalis fascia covers the muscle, below the semicircular line, posteriorly, which is usually transparent when viewed from the inside at operation (3–5).

The Peritoneum

The peritoneum is composed of two portions (4,6,7). The parietal peritoneum lines the inner abdominal wall and is supplied by somatic nerves. The visceral peritoneum lines the visceral organs and is supplied by the visceral nerves. The epithelial lining of the peritoneum is mesoepithelium and produces a small volume of peritoneal fluid for lubrication of the visceral organs. The peritoneal space between the parietal and visceral peritoneum is the peritoneal cavity. The peritoneal membrane covers the inner surface of the abdominal wall and passes along the mesenteric vessels to form the mesentery.

Physiology of the Peritoneum

The peritoneal membrane lined by mesoepithelium provides a frictionless environment for visceral organs and produces visceral fluid of about 100 cc daily. Its characteristic is clear straw colored (6,7). The peritoneal membrane can absorb fluid and solute, which is controlled by the concentration of fluid and solutes. The peritoneum can absorb normal saline solution approximately 35 mL/hr after initial equilibrium 300 to 500 mL/hr in hypertonic normal saline.

The peritoneal circulation plays a major role in the exchange of fluid and solutes draining peritoneal dialysis. The parietal peritoneum is supplied by the vessels from the abdominal wall and the visceral peritoneum. The splanchnic vasculature contains about one-third of total blood volume and a blood flow rate that exceeds 1200 mL/min, with mesenteric blood flow representing about 10% of cardiac output. There are many factors that influence the peritoneal circulation, such as age, cardiac output, exercise, and hormonal substances (such as angiotensin and epinephrine) (6,7).

The peritoneal circulation plays a major role in the exchange of fluid and solutes draining peritoneal dialysis.

FACTORS AFFECTING PERITONEAL DIALYSIS EFFICIENCY

Surface Area

The estimated surface area of the peritoneal cavity is about 1 to 2 m². Factors that may limit surface area include previous abdominal surgery, episodes of peritonitis, chronic inflammation, cellular metabolic alterations, condition of hydration of the mesothelium—all of which can affect the efficiency of the peritoneal membrane (8–11).

THE INDICATION FOR DIALYSIS

There are two modalities of dialysis: hemodialysis and peritoneal dialysis. The indication for dialysis includes end-stage renal disease, acute renal failure, drug and chemical poisoning, acute hyperkalemia, metabolic disorder, and volume overload from congestive heart failure or lung diseases. In the case of renal failure, dialysis therapy is initiated when approximately 90% of normal renal function has been lost.

The absolute contraindications for all forms of dialysis are irreversible dementia or coma, hepatorenal syndrome, and advance malignancy. Both forms of dialysis are effective with proper patient selection. hemodialysis has the advantage of rapid clearance. It is useful in hyperkalemia, volume overload, and drug overdose. Continuous ambulatory peritoneal dialysis has been utilized during the last five years with increasing frequency in the treatment of patients with chronic renal failure. Peritoneal dialysis is preferred in patients who cannot tolerate the hypotensive state or the heparinization required for hemodialysis. Other advantages include portability, safety, fewer medications, no routine anticoagulation, and little change in hematocrit. Severe peritoneal fibrosis or pleuroperitoneal fistula are the absolute contraindications in peritoneal dialysis.

PERITONEAL ACCESS DEVICES

The optimal access device must transfer large volumes of dialysate into and out of the peritoneal cavity in a minimal amount of time, as well as maintain normal anatomy, bacteriology, and physiology of the surrounding tissues. There are two types of peritoneal catheters (8,9,11).

Acute Peritoneal Dialysis Catheter

These catheters are designed to be used for up to three days. Acute peritoneal dialysis catheters are made of polyurethane or nylon, appear like a straight tube, are relatively rigid, and have numerous 1-mm diameter side holes for drainage. *There is no cuff.* If it is necessary to perform dialysis for more than three days, the placement of a chronic catheter at the start of dialysis therapy should be considered.

Chronic Peritoneal Dialysis Catheter

Chronic peritoneal dialysis catheter are designed to be used on a long-term basis, are made from biocompatible material such as silicone or polyurethane, and usually contain numerous 1-mm diameter side holes; however, at least one type of chronic peritoneal catheter that has linear grooves or slots rather than side holes is available on the market. All of the chronic peritoneal dialysis catheters have one or two extraperitoneal Dacron® cuffs that promote local inflammatory response and cause a fibrous plug to fix the catheter in position, which prevents fluid leakage and inhibits organism migration from outside the peritoneal cavity.

There are four common types of peritoneal dialysis catheters:

1. Straight Tenckhoff, with 8 cm portion containing 1 mm diameter side holes
2. Straight Tenckhoff, with perpendicular disc
3. Curled Tenckhoff, with 16 cm portion containing 1-mm diameter side holes
4. T-fluted catheter, with grooved limbs positioned against the parietal peritoneum

The various intraperitoneal designs are created to diminish outflow obstruction. Besides intraperitoneal geometry, there are many designs of chronic peritoneal catheter, which alter the shapes of the subcutaneous portion between the muscle wall and the skin opening. The shapes all provide a lateral or downward direction to decrease the risk of the infection.

The cuff of continuous ambulatory peritoneal dialysis catheters also has many designs: single cuff, double cuffs, and disc-bell deep cuffs. The material used to manufacture chronic peritoneal catheters are soft, such as silicone rubber or polyurethane. The polyurethane catheters form a weak bond with the Dacron cuff and loosening of this bond can create pericatheter leakage. The diameter of the catheters can vary but the outer diameter is approximately 5 mm, with the internal diameter ranging from 2.6 to 3.5 mm.

CONTRAINDICATIONS TO PERITONEAL DIALYSIS CATHETER PLACEMENT

There are relatively few contraindications to the placement of peritoneal dialysis catheters. The most important consideration is whether or not the abdominal cavity has previously been violated. Previous pelvic surgery that may lead to adhesions, colostomy, ileostomy, or urinary diversion would be a relative contraindication. Absolute contraindications include aortic vascular graft within three months, presence of ventriculoperitoneal shunt, ascites, and peritonitis. Previous retroperitoneal/extraperitoneal surgical procedures such as hysterectomy, caesarean section, and nephrectomy (retroperitoneally) are not considered contraindications.

SURGICAL TECHNIQUES

In the case of chronic renal failure, a soft catheter providing a lower risk of erosion to visceral organs is preferred. Besides the type of the catheter, the placement technique influences the longevity of the catheter, hospital stay, and infection rates. These “complications” will be discussed later in this chapter. There are four common methods of implantation:

1. Dissecting technique (open surgery)
2. Blind puncture

3. Peritoneoscopy-assisted percutaneous method
4. Laparoscopy-assisted techniques

Dissecting Technique (Open Surgery)

The dissecting technique is commonly utilized by general surgeons and involves placing the catheter by minilaparotomy under general anesthesia (11). The layers of the abdominal wall are dissected under direct vision. The parietal peritoneum is identified and incised. The catheter is advanced into the peritoneal cavity by feel until the deep cuff is within the rectus muscle. The cuff is then secured in the rectus muscle by sutures placed at the peritoneal entry site and at the outer rectus sheath.

Blind or “Seldinger” Technique

In the blind or modified Seldinger technique, a needle is inserted into the abdomen, a guidewire placed, a tract dilated, and the catheter inserted through a split-sheath; all maneuvers are performed without visualization of the peritoneal cavity (11). The deep cuff usually remains outside the outer rectus sheath after implantation. The blind technique is not widely used in the United States. The bedside blind insertion technique is associated with a significant risk of visceral damage and high rate (31%) of subsequent migration leading to failed dialysis (12). The other disadvantage is that final catheter placement cannot be controlled, and it is not suitable for the placement of “complex” catheters.

Peritoneoscopic Technique

Peritoneoscopic insertion, which is now, most often, performed by nonsurgeons, employs a small (2.2 mm diameter) optical peritoneoscope (Y-Tec[®] Scope^a) for direct inspection of the peritoneal cavity and identification of a suitable site for the intraperitoneal portion of the catheter (11,13–21). Hence, of the three techniques described so far, only the latter allows for the direct visualization of the intraperitoneal structures. This technique is most commonly used by nephrologists and its use is rapidly expanding.

Peritoneoscopic placement varies from laparoscopic techniques, which will be elaborated on below (22,23), because it employs a much smaller scope and puncture size, only one peritoneal puncture site, a device to advance the cuff into the musculature, air in the peritoneum rather than CO₂, and local anesthesia rather than general anesthesia.

For peritoneoscopic insertion, the entire abdomen is prepped and draped in sterile fashion. A small skin incision (2–3 cm) is made over the desired location under local anesthesia (11). Dissection is carried down only to the subcutaneous tissue. The anterior rectus sheath is identified but not incised. A preassembled cannula with trocar and a spiral sheath is then inserted into the abdominal cavity through the rectus muscle (Fig. 2). Either medial or lateral border of the rectus could be used to gain access to the peritoneal cavity. The trocar is then removed and replaced by the peritoneoscope to confirm the intra-abdominal position of the cannula. Approximately 600 to 1000 cc of air is then infused to create a pneumoperitoneum and separate visceral and parietal peritoneal surfaces. At this point, peritoneoscopy is performed (Fig. 3). Bowel loops, the dome of the bladder, and the presence or absence of intra-abdominal adhesions are identified. The cannula with the spiral sheath wrapped around it is then advanced to an identified location (usually in the pelvis). The cannula and the peritoneoscope are then removed, leaving the spiral sheath in place. The spiral sheath is dilated to 6 mm diameter and the catheter is advanced into the desired location through the spiral sheath using an internal stylette. The deep cuff is implanted into the rectus muscle using an implanter tool without dissection of the anterior rectus sheath or the muscle. Some secure the deep cuff into the rectus muscle by using a purse-string suture at the anterior rectus sheath. The superficial cuff is implanted into the subcutaneous tissue and a tunnel and an exit site are created (Fig. 4). The tunnel and exit site are routinely directed inferiorly. The subcutaneous tissue is sutured using absorbable material while the skin is closed with nylon. No sutures are placed on the external rectus sheath or at the skin exit site.

The ability to directly visualize intraperitoneal structures is advantageous to the catheter placement (15,16,18). With this approach, the surgeon can avoid bowel loops, adhesions, and the omentum and determine the most suitable site for catheter placement. In this technique, neither the rectus sheath/muscle nor the parietal peritoneum

Peritoneoscopic placement varies from laparoscopic techniques, which will be elaborated on below because it employs a much smaller scope and puncture size, only one peritoneal puncture site, a device to advance the cuff into the musculature, air in the peritoneum rather than CO₂, and local anesthesia rather than general anesthesia.

^aMedigroup, Naperville, IL.



FIGURE 2 ■ During peritoneoscopic insertion of a peritoneal dialysis catheter, a trocar and cannula, with its wrapped spiral sheath, is being inserted through the rectus muscle under local anesthesia.

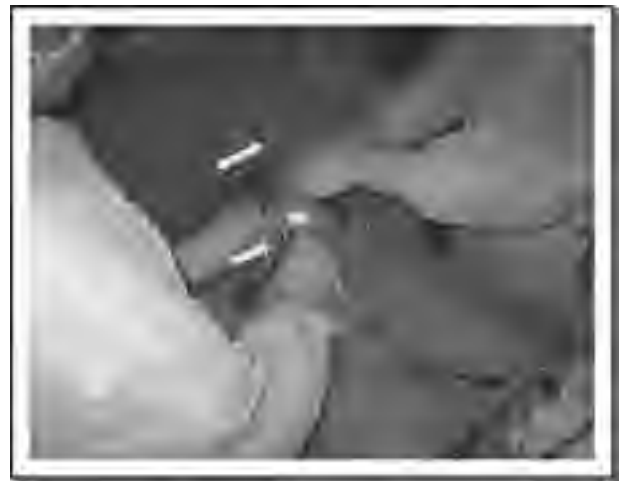

FIGURE 3 ■ A peritoneoscope (single arrow) has been introduced into the abdominal cavity through the cannula and the fibro-optic light (double arrow) source is being connected to the scope.

The preference of one technique over another must take into account the incidence of complications (pericatheter leakage, exit site and tunnel infection), long-term catheter survival associated with each technique, costs, ease and timely insertion of the catheter, and factors contributing to mortality risk (general anesthesia).

is incised, and the initial puncture is only about 3 mm in diameter. Thus, the layers of the anterior abdominal wall remain intact and tightly opposed to the catheter and cuff after placement.

The preference of one technique over another must take into account the incidence of complications (pericatheter leakage, exit site and tunnel infection), long-term catheter survival associated with each technique, costs, ease and timely insertion of the catheter, and factors contributing to mortality risk (general anesthesia).

Peritoneoscopic placement of peritoneal dialysis catheters by nephrologists has been rigorously compared with the surgical and the blind technique (Table 1). Both randomized and nonrandomized studies have documented the superiority of the peritoneoscopic technique in terms of incidence of catheter complications (infection, outflow failure, and pericatheter leak) and catheter survival (13,15,21–40). Recently, Gadallah et al. (15) reported the results of a randomized trial comparing the peritoneoscopic and the surgical technique. Early peritonitis episodes (occurring within two weeks of the catheter placement) occurred in 9 of 72 patients (12.5%) in the surgical group as compared to 2 of 76 patients (2.6%) in the peritoneoscopic group ($p = 0.02$). A higher incidence of exit site leaks was also found in the surgical group (11.1%) than in the peritoneoscopic cohort (1.3%) ($p = 0.002$). Finally, the study clearly demonstrated prolonged catheter survival with peritoneoscopic placement at 12, 24, and 36 months [77.5% vs. 62.5% ($p = 0.02$); 63% vs. 41.5% ($p = 0.01$); 51.3% vs. 36% ($p = 0.04$), respectively]. In addition, the overall catheter failure rate was higher in the surgical group than in the peritoneoscopic group (55.2% vs. 32.8%; $p = 0.003$). Pastan et al. (21) found similar results in a separate randomized study. The avoidance

FIGURE 4 ■ Using a disposable tunneler tool (straight arrow), a subcutaneous tunnel is created for the catheter. The superficial cuff shown (curved arrow) will be implanted in the subcutaneous tissue.

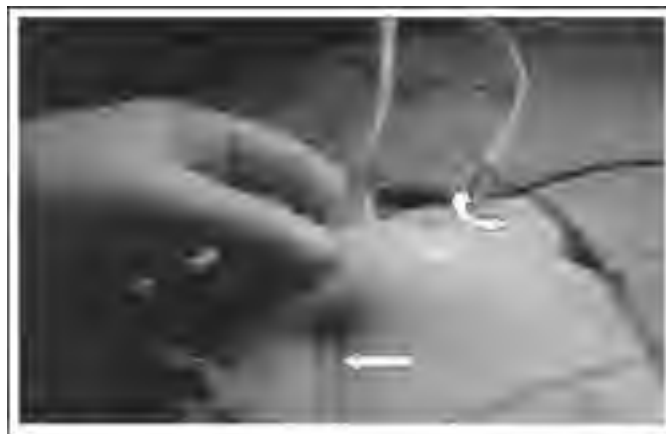

TABLE 1 ■ Comparison of the Blind, Dissective, and Peritoneoscopic Techniques Utilizing the Double-Cuff Tenckhoff Catheter

Investigator (year) (Ref.)	No. of patients	Mean follow-up (mo)	Infectious complications	Outflow failure	Subcutaneous leaks
<i>Blind or Seldinger technique</i>					
Bierman (1985) (24)	222	24.0	0.12	0.36	0.03
Valenti (1985) (25)	30	13.7	N/A	N/A	0.26
Zappacosta (1991) (26)	101	36.0	0.15	0.07	0.03
Nebel (1991) (27)	49	9.6	0.05	0.30	0.02
Swartz (1990) (28)	134	12.3	0.75	0.11	0.22
Scalamonga (1994) (29)	110	20.0	0.10	0.02	N/A
Ozener (2001) (30)	133	17	0.20	0.09	0.07
Average		18.9	0.23	0.16	0.11
<i>Dissective or surgical technique</i>					
Khanna (1981) (31)	132	13.3	0.19	0.07	0.07
Rottenbour (1981) (32)	48	12.0	N/A	N/A	0.30
Odor (1985) (33)	150	6.1	0.10	0.33	0.00
Twardowski (1985) (34)	83	18.0	0.50	0.11	N/A
Swartz (1990) (28)	79	12.1	0.88	0.14	0.10
Piraino (1991) (35)	228	36.0	1.00	0.04	0.06
Shyr (1994)	43	18	0.46	0.07	0.00
Rugiu (1996) (36)	134	27.0	0.50	0.20	0.08
Gadallah (1999) (15)	72	24	0.13	0.08	0.11
Ozener (2001) (30)	82	21.2	0.27	0.16	0.05
Average		17.6	0.45	0.13	0.09
<i>Peritoneoscopic/laparoscopic technique</i>					
Ash (1983) (13)	61	10.0	0.02	0.04	0.05
Handt (1984) (37)	98	27.0	0.15	0.00	0.00
Cruz (1989)	150	12.0	0.01	0.01	0.01
Adamson (1992) (38)	100	10.0	0.01	0.04	0.09
Swartz (1993) (22)		38.0	0.07	0.00	0.03
Chadha (1994) (23)	70	24	0.04	0.07	N/A
Scott (1994) (39)	30	12.0	0.10	0.1	0.00
Copley (1996) (40)	135	8.7	0.21	0.07	0.04
Gadallah (1999) (15)	76	24	0.02	0.07	0.01
Average		18.4	0.07	0.04	0.02

of various complications by peritoneoscopic placement may relate to the decreased tissue dissection required with this technique. Extensive dissection (incising/splitting the rectus sheath/muscle as well as incising the parietal peritoneum) in the surgical technique may lead to loose attachment of the catheter to the abdominal wall increasing, thereby, the incidence of pericatheter leaks, subsequent tunnel infection and peritonitis, and catheter loss.

Laparoscopic management for obstructed catheter was first described in 1985 (41). Since then, a number of authors have reported their success in using laparoscopy to assist the placement or the salvage of obstructed catheters (42–46).

Peritoneal dialysis catheters have been successfully placed via the open surgical technique, the percutaneous (blind puncture) method, and the peritoneoscopy-assisted percutaneous methods. The latter two techniques were associated with lower complication rates, quicker use of the catheter, and longer functional survival, but also carried the risk of vascular and visceral injury during blind entry with a Veress needle or other penetrating instrumentation. Newer techniques that reduce the incidence of iatrogenic complications and provide greater visualization of the peritoneal cavity have been described. Laparoscopy-assisted placement allows for the visualization and positioning of the catheter under adequate pneumoperitoneum status with the ability to manipulate and not just visualize intra-abdominal structures. On comparing to other techniques, many reported series have shown better outcomes of laparoscopy-assisted technique as regards reduced risk of visceral organ injury or vascular injury, incidence of catheter flow dysfunction, peritoneal leakage, abdominal wall hernia, pain, hospital stay, and early start of peritoneal dialysis (45,47–57). Laparoscopic implantation procedures are also a cost-effective means

Laparoscopic management for obstructed catheter was first described in 1985. Since then, a number of authors have reported their success in using laparoscopy to assist the placement or the salvage of obstructed catheters.

of establishing peritoneal dialysis access as compared with the open dissection technique (22,58).

LAPAROSCOPIC IMPLANTATION OF CONTINUOUS AMBULATORY PERITONEAL DIALYSIS CATHETER

There are several laparoscopic variations in the placement of continuous ambulatory peritoneal dialysis catheters (3,59). The “different techniques” are similar but one may offer slight advantages over the other; thus they are described in some detail below.

Patient Preparation

Before the patients undergo placement of continuous ambulatory peritoneal dialysis catheter, the position of the exit catheter should be chosen due to the characteristic of abdominal wall, and the exit hole should be created at least 2 cm above or below the belt line. With this caveat, the position of the patient’s body and manipulation will not put pressure on the tunnel catheter

Instrumentation

- High-flow carbon dioxide insufflator
- CCD camera and at least one monitor
- 30° laparoscope
- One 5- to 10-mm port (trocars/cannulas) and two 3- to 5-mm ports (trocars/cannulas)
- Laparoscopic tissue forceps
- Laparoscopic grasping forceps

Technique

Under general anesthetic with muscle paralysis and assisted ventilation, the patient is put in a supine position with the head tilted downward at a 30° angle. The urinary bladder is emptied and a nasogastric tube is inserted. Pneumoperitoneum is performed by inserting a needle (Veress needle) into the abdomen. The position of the needle should be checked by aspirating and infusing 5 mL of saline (i.e., the “water drop test”). Intra-abdominal pressure must be carefully observed to ensure that it is below 12 mmHg during insufflation.

Previous abdominal surgery is a relative contraindication to blind needle insertion and consequently a Hasson cut-down technique can be used instead for the first port, especially, if there has been extensive previous abdominal surgery of peritonitis. A Tenckhoff catheter is placed in the peritoneal cavity, and an adequate pneumoperitoneum is created. A subumbilical transverse incision, 0.5- to 1.0-cm long, is made dissecting through to the subcutaneous layer. After opening the anterior rectus sheath, a blunt dissection is made of the rectus muscle to posterior sheath and peritoneum. A 5- or 10-mm trocar is inserted and fixed. The formation of the pneumoperitoneum is made via this trocar. An operative laparoscope facilitates ideal visualization and distal catheter placement. A small separate incision is created for catheter exit (Figs. 5 and 6) (47).

The initial exploratory laparoscopy is conducted with a 30° videolaparoscope. Two 3- to 5-mm trocar ports are inserted lateral to the rectus sheath under direct vision and one 3- to 5-mm port is used as the exit site of the catheter. Fixing the omentum to the parietal peritoneum at two points on the lateral abdominal wall level with the umbilicus, using 3-0 prolene, can be done and creates an omental wrapping that is effective in averting mechanical problems. The continuous ambulatory peritoneal dialysis catheter is then inserted through the umbilical trocar deep into the true pelvis by stiffening the stylet. This method allows for adjustment of the position of the catheter in the true pelvis by grasping the forceps under vision and fixing the catheter tip to the posterior wall of the urinary bladder in males and uterus in females. Implementing this method lowers the risk of migration of the catheter and prevents subsequent catheter migration, leading to failed dialysis of the kidney. The sutures encircle the catheter rather than pass through it, so that the catheter can be easily removed later if necessary (60). The cuff is then placed between the posterior rectus sheath and the rectus muscle fiber and the fascia is sewn tightly. The portion of the peritoneal catheter at the subcutaneous layer is grasped by a hemostat clamp, creating a subcutaneous tunnel from the exit port (5-mm port wound). It is necessary to check the distal catheter to make certain it is in the right position, as well as treat any bleeding at the closure of the incisional wound. The subcutaneous tunnel path and catheter exit are best evaluated with the abdomen in a



FIGURE 5 ■ Laparoscopy-assisted implantation of continuous ambulatory peritoneal dialysis catheter.

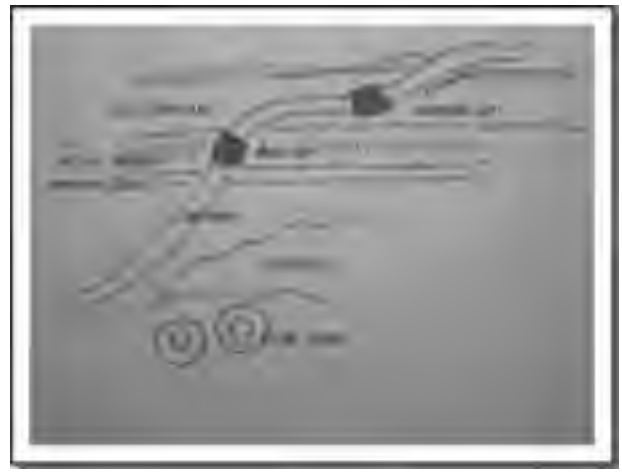

FIGURE 6 ■ Diagram shows cross section of continuous ambulatory peritoneal dialysis catheter in the abdominal wall.

normal position, without the bulging of pneumoperitoneum. A catheter without a preformed bend is laid out over the skin to assist in marking the exit site. The tunnel is shaped in an arched fashion so that the catheter makes a gentle bend in the subcutaneous tract and exits the skin in a downward direction with the superficial cuff no closer than 2 cm from the skin exit site. Proper alignment of the catheter is maintained with the assistance of the radio-opaque stripe as the catheter is passed through the subcutaneous tunnel. Care is taken not to alter the catheter position in the transabdominal wall tract during the subcutaneous tunneling process (61).

VIDEOLAPAROSCOPY-ASSISTED IMPLANTATION OF CONTINUOUS AMBULATORY PERITONEAL DIALYSIS CATHETER (51,62)

Historically, this procedure has been performed under general anesthetic because a pneumoperitoneum with CO₂ gas is not well tolerated by patients. Subsequently, this procedure has been modified by Giannattasio et al. and Crabtree and Fishman and can now be performed under local anesthesia with nitrous oxide gas and intravenous sedation. Currently videolaparoscopy is used more due to many benefits such as lower risk of trauma, short recovery time, short hospital stay, and small surgical scar (51).

Technique

Under a general anesthesia with muscle paralysis and assisted ventilation, the patient is put in a supine position with the head tilted downward. Pneumoperitoneum is performed by inserting the pneumoperitoneum needle (Veress needle) off the midline lateral to the rectus sheath at the umbilical level. The pneumoperitoneum needle is then replaced by the port sleeve of the scope and the gas insufflation tubing is transferred to this port. A 5-mm laparoscope is recommended. A small vertical incision is made on the opposite side of the abdominal wall at the umbilical level. An additional port (surgeon preference) is inserted through the rectus muscle along the incision with the patient in a Trendelenburg position and at an angle of 45° in the caudal direction, making the peritoneum entry 2 to 3 cm below the umbilical level. The point of penetration through the anterior rectus sheath is more cranial than the penetration point of the posterior rectus sheath. The caudally angulated passage through the abdominal wall encourages the peritoneal dialysis catheter to remain oriented in a pelvic direction. Insertion of the continuous ambulatory peritoneal dialysis catheter into this port allows adjustments to the distal cuff above the peritoneal layer under laparoscopic control.

MINILAPAROSCOPIC PLACEMENT OF PERITONEAL DIALYSIS CATHETER

Some surgeons have evaluated a new technique for continuous ambulatory peritoneal dialysis catheter placement, which requires only a single 2-mm port (49,56).

Minilaparoscopic placement of peritoneal dialysis catheter has been described by Varela et al. and Al-Dohayan et al. This procedure uses a single 2-mm port under direct visualization with a 2-mm scope and a modified Seldinger technique.

Technique

Under a general anesthesia with muscle paralysis and assisted ventilation, the patient is put on the supine position with the head tilted down. A 2-mm supraumbilical incision is made and the pneumoperitoneum is performed by inserting a Veress needle, creating a 2-mm portal. After establishing pneumoperitoneum (CO₂) with Trendelenburg positioning, an 18-gauge needle is introduced into the right and left lower quadrants. A guidewire is inserted through the 18-gauge needle and advanced to the true pelvic cavity. The dilator and sheath are advanced over the guidewire. Then, a continuous ambulatory peritoneal dialysis catheter is advanced through the sheath, over the right lower quadrant toward the pelvis. The sheath and guidewire are removed. A 5 cm subcutaneous tunnel is made by blunt dissection through the exit wound above the belt line. The catheter position is verified by direct visualization. A second 2-mm trocar may be placed to guide the catheter toward the pelvis. The catheter is flushed with heparinized saline. Local anesthesia is administered and the skin incisions are closed. Placement of the catheter can be performed under local anesthesia. This method has been described utilizing helium or nitrous gas, which is less irritating to the peritoneum than carbon dioxide.

BURYING THE PERITONEAL DIALYSIS CATHETER

Traditional surgical implantation of Tenckhoff catheters involves immediate exteriorization of the external segment through the skin, so that the catheter can be used for supportive peritoneal dialysis or for intermittent infusions during the “break-in” period. To prevent blockage and to confirm function, the catheter is flushed weekly with saline or dialysate; each exchange carries the same risk of peritonitis as in continuous ambulatory peritoneal dialysis therapy to avoid bacterial contamination of the exit site. The catheter must also be bandaged and the skin exit site must be kept clean in the weeks after placement. The patient must, therefore, be trained in some techniques of catheter care. It has always been difficult to decide when to place a peritoneal dialysis catheter in a patient with chronic renal insufficiency. If the catheter is placed too early, the patient may spend weeks to months caring for a catheter that is not used for dialysis. If the catheter is placed after the patient becomes uremic, it is often used for peritoneal dialysis therapy without a “break-in” period.

Moncrief et al. devised a placement technique in which the entire peritoneal catheter can be buried under the skin some weeks to months before it is used (63). The catheter-burying technique was first described for the placement of a modified Tenckhoff catheter with a 2.5 cm-long superficial cuff, but the technique has been adopted for standard dual-cuff Tenckhoff catheters (64–66). In the original technique, the external portion of the catheter was brought through a 2 to 3 cm skin exit site (much larger than the usual 0.5 cm incision). The catheter was then tied off with silk suture then coiled and placed into a “pouch” created under the skin. The skin exit site was then closed. Weeks to months later, the original skin exit site was opened, and the free end of the catheter was brought through the original skin large exit site (63,64).

The goal of burying the peritoneal dialysis catheter was to allow ingrowth of tissue into the cuffs of the catheter to prevent bacterial colonization and to allow ingrowth and anchoring of the deep and subcutaneous cuffs. Burying the catheter effectively eliminated early peri-catheter leaks and decreased the incidence of peritonitis rate. In 66 months of follow-up, patients with the buried Tenckhoff catheter had peritonitis infection rates of 0.017 to 0.37 infections per year, versus 1.3 to 1.9 infections per year in control patients (63). In a study of 26 buried Tenckhoff catheters, incidence of infectious complications during peritoneal dialysis was 0.8 infections per year and catheter-related peritonitis was only 0.036 per patient-year (64). A retrospective study confirmed a significantly lower catheter infection and peritonitis rate in patients having had buried catheters and a significantly longer catheter life (67,68), although the procedure was not effective when used for single-cuff catheters.

Exit site infections were not decreased in catheters that were buried, but this is understandable, because a large exit site was created when the catheter was buried, and a similarly large site was recreated when the catheter was exteriorized. Creating the “pouch” under the skin requires a considerable amount of dissection and trauma near the exit site. The size of the pocket limits the length of catheter that can be coiled and

buried under the skin, limiting the external length of the catheter after exteriorization. The exit site must be opened widely to remove the catheter, because the coil rests in a position distant from the skin exit site. Subcutaneous adhesions to the silk suture around the catheter further restrict removal. Increased trauma near the exit site during placement and exteriorization of the catheter may have caused an increased incidence of early exit infection with this technique. In one study of “embedded” catheters in 26 adult patients (with mean subcutaneous residence of 79.5 days), 2 patients developed local seromas and 12 developed subcutaneous hematomas (5 of which were revised surgically) (69). At catheter “activation,” there were a number of flow problems: nine patients developed fibrin thrombi (two requiring operative clearance) and four patients had omental catheter obstruction (four requiring omentectomy). When burying the Tenckhoff catheter by standard techniques, there were a total of 27 complications in 26 catheter placements, with 13 of these complications requiring corrective surgery.

When catheters are placed by the Y-Tec procedure, the quill and cannula of the system can be reassembled and used to bury the external portions of dual-cuff Tenckhoff and Advantage catheters (12). The catheter exit site is made slightly larger than the standard exit site. The quill and cannula are inserted through this exit site to create a long, straight tunnel for the external end of the catheter. The catheter is blocked with an internal plug, rather than an external silk suture. This technique has been used to bury and then remove over 40 Tenckhoff and Advantage catheters. There have been few early complications of insignificant hematoma (3%), seroma (0%), exit infection (3%), or outflow failure (0%) and all catheters have functioned after exteriorization (12). Nephrologists can bury and exteriorize peritoneal dialysis catheters with greater ease and lesser trauma than surgical procedures and obtain results and benefits that are at least as positive.

POSTOPERATIVE CARE

Postoperative care after minimally invasive placement is very convenient because of shortened recuperation time and rapid wound healing. If there is an urgent indication to perform dialysis, minimally invasive placement of catheters allows rapid initiation of dialysis without leakage (54).

COMPLICATIONS OF LAPAROSCOPIC PLACEMENT OF CHRONIC PERITONEAL DIALYSIS CATHETER

Continuous ambulatory peritoneal dialysis is now an established technique for renal dialysis. In chronic peritoneal dialysis, operative laparoscopy is minimally invasive and is associated with the low morbidity and rapid return to normal activity. Reported series have shown feasibility and safety of the laparoscopic technique, which is also more effective than the open procedure or blind technique (61,70–72); however, the laparoscopic placement of the chronic peritoneal dialysis catheter can still have complications, both acute and chronic.

Acute Complications

Peritoneal Access

Complication from Veress needle or trocar placement can occur as with any laparoscopic procedure. Injuries to the abdominal wall vasculature or visceral organ injury can occur. If perforation occurs, the needle should be immediately removed and discarded. Because of the small size of Veress needle, the majority of the injuries do not require operative intervention (70). The Veress needle may injure the omental or mesenteric blood vessels or may cause major abdominal or pelvic vessel vascular injury. Their management depends on the amount of bleeding.

The incidence of serious hemorrhage from trocar injury requiring transfusion is approximately 0.4% (71). The introduction of a trocar into the abdominal cavity is likely responsible for bowel injury when a peritoneal dialysis catheter is inserted using the peritoneoscopic technique (16) or laparoscopic techniques. Bowel injuries due to the introduction of insufflation needles, trocars, and rigid catheters and colonoscopic examinations have been reported (73–76). A majority of these perforations are usually small and seal spontaneously (77,78). These “miniperforations” close spontaneously within 24 to 48 hours, most likely secondary to omental adherence (77,78). Simkin and Wright (79) provided direct evidence of the self-sealing nature of bowel perforations sustained during peritoneal dialysis catheter insertion.

During surgical exploration, they observed sealed bowel perforations that were sustained during peritoneal dialysis catheter insertion 12 to 16 hours earlier. A majority of small perforations are self-sealing and do not require surgical intervention (76–78,80–82).

Pneumoperitoneum

Pneumoperitoneal pressure greater than 10 to 15 mmHg, especially in children, for prolonged time can result in barotrauma. High gas pressure can cause decreased venous return due to caval compression and can result in decreased cardiac output, leading to hypotension (70). Hydrothorax occurs in less than 1% of patients and is manifested by very poor drainage of dialysate, dyspnea, and abnormal chest radiographic findings (pleural effusion) (72).

Late Complications

Exit Wound and Tunnel Infection

Erythema around the skin exit site may be part of the normal wound-healing process. Evidence of pain or extrusion of pus should elicit concern about catheter infection. Empiric treatment with antibiotics is advised to try to salvage the catheter and is appropriate as long as there are no sign of peritonitis, fasciitis, or sepsis. *Staphylococcus aureus* is the prominent organism for both exit site and tunnel infection and peritonitis. The incidence of *S. aureus* is greatest in the first year and decreases over time on dialysis (61). The cuff of the catheter is a strong barrier against penetration of infection into the abdominal cavity via subcutaneous tunnel (83).

Catheter Obstruction

In the late phase, the causes of catheter obstruction are the translocation of the catheter and bowel or fibrin clot formation and are resolved by laxatives and/or addition of heparin 500 U/L to dialysis solution.

Pericatheter Leak

Pericatheter leaks are more likely with midline catheter incision than with rectus muscle insertion. The late leakage and acute leakage are not managed differently but the late leakage usually requires surgical correction.

Peritonitis

The peritoneal segment of the catheter is a foreign body in the abdominal cavity and may be a source of colonization by bacteria that have migrated around the catheter. The deep cuff may cause recurrent peritonitis because bacteria can form microabscess around the deep cuff. Exit site and tunnel infection by *S. aureus* and related peritonitis led to catheter loss in 85% of cases in a recent series (61).

Peritoneal Dialysis Catheter Migration

This complication occurs more frequently in open rather than minimally invasive techniques. The proper placement of the catheter in the deep pelvis and fixation of the catheter tip to the posterior wall of the urinary bladder in males and uterus in females has been suggested to lower the risk of catheter migration (21,60). peritoneal dialysis catheter migration to the upper abdomen is not an uncommon problem (15–35%) and usually leads to outflow problems and catheter failure. The condition is suspected by encountering flow problems and is confirmed by plain abdominal X-ray. A variety of techniques have been used to combat migration with long-term success rates of 27% to 48%. Recently, the success of Fogarty catheter manipulation for the migrated peritoneal dialysis catheter was evaluated prospectively in 232 patients by nephrologists. In this study, a Fogarty catheter was advanced into the peritoneal dialysis catheter to a pre-marked point at which the end of the Fogarty catheter was near the end of the intraperitoneal portion of the peritoneal dialysis catheter. The Fogarty catheter was then inflated with 0.5 cc of sterile saline and manipulation was performed by tugging movement until the proper positioning of the catheter into the pelvis was suspected. Four to five attempts were made. Catheter patency was evaluated by checking dialysis inflow and outflow and the position of the catheter was confirmed by abdominal X-ray. In this study, the incidence of migration was found to be 15%. The results indicated a long-term (>90 days) success rate of 71% without any procedure-related complications. In contrast, at our center, Fogarty catheter manipulation corrected only 1/10 (10%) migrated catheters. Despite our inability to reposition these catheters, we were able to reinsert a new catheter during the same procedure, avoiding transfer to hemodialysis, placement of a tunneled hemodialysis catheter, and interruption of peritoneal dialysis.

FIGURE 7 ■ Peritoneal dialysis catheter removal. The catheter (straight arrow) has been exposed by dissection of the subcutaneous tunnel (double arrow). Note the catheter emerging at the exit site (arrow head).



PERITONEAL DIALYSIS CATHETER REMOVAL

Peritoneal dialysis catheter removal can also be safely performed without significant discomfort under local anesthesia. Here too, an operating room is not needed because the procedure can be performed in a procedure room using standard precautions for infection control. Briefly, the local anesthetic is infiltrated at the site of the primary incision and the subcutaneous tissue. Dissection is then carried down to the subcutaneous tissue and the subcutaneous tunnel harboring the catheter is identified. Using blunt dissection, a portion of the tunnel is separated from the surrounding tissue. The tunnel is then lifted by applying a hemostat under it. Using toothed forceps and Metzenbaum scissors, the tunnel layers are cut in a longitudinal direction and the catheter is exposed (Fig. 7). The catheter is clamped with hemostats and a nylon suture is applied through the catheter just outside the hemostats as a tag. At this point, the catheter is cut just outside the hemostat (remaining inside the nylon tag suture). Using Metzenbaum scissors, dissection is performed exposing tissue in the direction of the deep cuff. At this point, local anesthetic is infiltrated around the deep cuff. For catheters that have been in place for less than a month, blunt dissection using hemostats is all that is required to free the superficial and the deep cuff. For catheters in place for more than a month, sharp dissection using Metzenbaum scissors and a scalpel is needed. Exposure of the deep cuff and the anterior rectus sheath is required. Once the deep cuff is separated from the surrounding tissue, the intraperitoneal portion of the catheter is gently withdrawn from the peritoneal cavity. The defect created at the entry point (anterior rectus sheath) of the catheter is then closed with a purse-string suture using an absorbable material. The nylon tag is then pulled to expose the cut surface of the outer catheter segment and dissection is performed in the direction of the superficial cuff. Once the superficial cuff is free, this portion of the catheter can be easily removed through the primary incision site or the exit site. Absorbable suture material such as Vicryl is used to close the subcutaneous tissue while nylon is used to close the skin. The exit site is not sutured. The procedure should be performed only with sterile technique, good lighting, and antiseptic skin preparation.

SUMMARY

- Continuous peritoneal dialysis is an effective treatment for patients with renal failure.
- The open technique placement of continuous ambulatory peritoneal dialysis catheter is still the standard procedure.
- Current results of continuous ambulatory peritoneal dialysis catheter placement under direct peritoneoscopic or laparoscopic vision are encouraging
- The peritoneoscopy-assisted technique is very similar to laparoscopy-assisted technique and can be performed by nonsurgeon physicians (nephrologists).
- Laparoscopy-assisted technique allows the surgeon to fix the catheter to the abdominal wall to prevent catheter migration.
- Laparoscopy is also increasingly used as a technique for salvage of the malpositioned or blocked catheter. It is also associated with decreased infection, more rapid onset of use, decreased complication, and improved patient comfort.

REFERENCES

1. www.usrds.org/2003. U.S.R.D.S., 2003 Annual Data Report. Chapters 1–4. 2003:1–82.
2. Goldfarb DA, Nally JV, Schreiber MJ. Etiology, pathogenesis and management of renal failure. In: Walsh PC, ed. *Campbell's Urology*. Saunders, 2002.
3. Poole GH, Tervit P. Laparoscopic Tenckhoff catheter insertion: a prospective study of a new technique. *Aust N Z J Surg* 2000; 70(5):371–373.
4. Gray H. The Peritoneum. *Anatomy of the Human Body*. Philadelphia: Lea & Deibiger, 1985:1450–1463.
5. Agur MRA, L.J. Abdominal Region. *Grant's Atlas of Anatomy*. Williams & Wilkins, 1991.
6. Kevin M, S.M., Jhon C. Abdominal wall, umbilicus, peritoneum and retroperitoneum. *The Biological Basis of Modern Surgical Practice*. 1997:809–825.
7. AC G. Formation of urine by kidneys. *Human Physiology and Mechanisms of Disease*, 1992:204–220.
8. Karl D, N.M. Peritoneal Dialysis: Limitations and Continuous Ambulatory Peritoneal Dialysis. Update. Masson Publishing, 1981:67–73.
9. Ash SR. Peritoneal Access Devices Hydraulic Function and Biocompatibility. *Clinical Dialysis*. Appleton & Lange, 1995:295–321.
10. Ronco C, C.R., Aquilla A, et al. Factors affecting peritoneal dialysis efficiency. *Peritoneal Dialysis*. Milano: Wichtig Editore, 2000:59–70.
11. Ash SR. Chronic peritoneal dialysis catheters: procedures for placement, maintenance, and removal. *Semin Nephrol* 2002; 22(3):221–236.
12. Ash SR. Chronic peritoneal dialysis catheters: overview of design, placement, and removal procedures. *Semin Dial* 2003; 16(4):323–334.
13. Ash SR. Peritoneoscopic placement of the Tenckhoff catheter: further clinical experience. *Perit Dial Bull* 1983; 3:8–12.
14. Ash SR. Bedside peritoneoscopic peritoneal catheter placement of Tenckhoff and newer peritoneal catheters. *Adv Perit Dial* 1998; 14:75–79.
15. Gadallah MF, Pervez A, el-shahauri MA, et al. Peritoneoscopic versus surgical placement of peritoneal dialysis catheters: a prospective randomized study on outcome. *Am J Kidney Dis* 1999; 33(1):118–122.
16. Asif A, Byers P, Gadalean F, et al. Peritoneal dialysis underutilization: the impact of an interventional nephrology peritoneal dialysis access program. *Semin Dial* 2003; 16(3):266–271.
17. Ash SR. Is a break-in period necessary following peritoneal catheter insertion? A break-in period is unnecessary. *Semin Dial* 1992; 5:199–201.
18. Ash SR. Who should place peritoneal catheters? A nephrologist's view. *Nephrol News Issues* 1993; 7(5):33–34, 40.
19. Gadallah MF, Ramdeen G, Torres-Rivera C, et al. Changing the trend: a prospective study on factors contributing to the growth rate of peritoneal dialysis programs. *Adv Perit Dial* 2001; 17:122–126.
20. American Society of Diagnostic and Interventional, www.asdin.org, 2001.
21. Pastan S, Gasseusmith C, Manatunga AK, et al. Prospective comparison of peritoneoscopic and surgical implantation of continuous ambulatory peritoneal dialysis catheters. *ASAIO Transpl* 1991; 37(3):M154–M156.
22. Swartz DA, Moles KA. Laparoscopic Tenckhoff catheter placement: a single center's experience. *Perit Dial Int* 1993; S31.
23. Chadha I, J.M., Viscuso R, Friedman G. Outcome of laparoscopic Tenckhoff catheter insertion (LTCI) versus surgical Tenckhoff catheter insertion (STCI): a prospective randomized comparison. *Perit Dial Int* 1994; 14:S89.
24. Bierman M, K.A. Peritoneal catheter survival and complications in end stage renal disease. *Perit Dial Bull* 1985; 5:229.
25. Valenti G, B.M., Corghi E, Lorenz M, Bucciatti G. Surgical complications during continuous ambulatory peritoneal dialysis. *Perit Dial Bull* 1985; 5:39–45.
26. Zappacosta AR, Perras ST, Closkey GM. Seldinger technique for Tenckhoff catheter placement. *ASAIO Transpl* 1991; 37(1):13–15.
27. Nebel M, Marczewski K, Finke K. Three years of experience with the swan-neck Tenckhoff catheter. *Adv Perit Dial* 1991; 7:208–213.
28. Swartz R, Messama J, Rocher L, et al. The curled catheter: dependable device for percutaneous peritoneal access. *Perit Dial Int* 1990; 10(3):231–235.
29. Scalapogna A, C.C.P.C. Peritoneal catheter outcome effect of mode of placement. *Perit Dial Int* 1994; 14:881.
30. Ozener C, Bihorac A, Akoglu E. Technical survival of continuous ambulatory peritoneal dialysis catheters: comparison between percutaneous and conventional surgical placement techniques. *Nephrol Dial Transpl* 2001; 16(9):1893–1899.
31. Khanna R, D.N. continuous ambulatory peritoneal dialysis after three years: still promising treatment. *Perit Dial Bull* 1981; 1:23–24.
32. Rottembourg J, V.L.M., Issad B, Shahat YE. Straight or curled Tenckhoff peritoneal catheter for continuous ambulatory peritoneal dialysis. *Perit Dial Bull* 1981; 1:123–124.
33. Odor A, L.J. Experience with 150 consecutive peritoneal catheters in patients on continuous ambulatory peritoneal dialysis. *Perit Dial Bull* 1985; 5:226–229.
34. Twardowski ZJ, Khamma RN, Prowent BF, Ryan LP, Nichols WK. The need for “swan neck” permanently bent, accurate peritoneal dialysis catheter. *Perit Dial Bull* 1985; 5:219–223.
35. Piraino B, Beruasdini J, Centra PK, et al. The effect of body weight on continuous ambulatory peritoneal dialysis related infections and catheter loss. *Perit Dial Int* 1991; 11(1):64–68.
36. Rugiu C, Lupo A, Bernich P, et al. 14-year experience with the double-cuff straight Tenckhoff catheter. *Perit Dial Int* 1997; 17(3):301–303.
37. Handt AD, A.S. Longevity of Tenckhoff catheters placed by the y-tec peritoneoscopic technique. *Perspect Perit Dial* 1984; 2:30–33.

38. Adamson AS, Kelleher JP, Snell ME, et al. Endoscopic placement of continuous ambulatory peritoneal dialysis catheters: a review of one hundred procedures. *Nephrol Dial Transpl* 1992; 7(8):855–857.
39. Scott PD, Bakran A, Pearson R, et al. Peritoneal dialysis access. Prospective randomized trial of 3 different peritoneal catheters—preliminary report. *Perit Dial Int* 1994; 14(3):289–290.
40. Copley JB, Lindberg JS, Back SN, et al. Peritoneoscopic placement of swan neck peritoneal dialysis catheters. *Perit Dial Int* 1996; 16(suppl 1):S330–S332.
41. Wilson JA, Swartz RD. Peritoneoscopy in the management of catheter malfunction during continuous ambulatory peritoneal dialysis. *Dig Dis Sci* 1985; 30(5):465–467.
42. Davis R, Young J, Diamond D, et al. Management of chronic peritoneal catheter malfunction. *Am J Nephrol* 1982; 2(2):85–90.
43. Smith DW, Rankin RA. Value of peritoneoscopy for nonfunctioning continuous ambulatory peritoneal dialysis catheters. *Gastrointest Endosc* 1989; 35(2):90–92.
44. Kimmelstiel FM, Miller RE, Mdinelli BM, et al. Laparoscopic management of peritoneal dialysis catheters. *Surg Gynecol Obstet* 1993; 176(6):565–570.
45. Mutter D, Maridhal JF, Heibel F, et al. Laparoscopy: An alternative to surgery in patients treated with continuous ambulatory peritoneal dialysis. *Nephron* 1994; 68(3):334–337.
46. Owens LV, Brader AH. Laparoscopic salvage of Tenckhoff catheters. *Surg Endosc* 1995; 9(5):517–518.
47. Brownlee J, Elkhairi S. Laparoscopic assisted placement of peritoneal dialysis catheter: a preliminary experience. *Clin Nephrol* 1997; 47(2):122–124.
48. Draganic B, James A, Booth M, et al. Comparative experience of a simple technique for laparoscopic chronic ambulatory peritoneal dialysis catheter placement. *Aust N Z J Surg* 1998; 68(10):735–739.
49. Leung LC, Yiu MK, Man CW, et al. Laparoscopic management of Tenckhoff catheters in continuous ambulatory peritoneal dialysis. A one-port technique. *Surg Endosc* 1998; 12(6):891–893.
50. Al-Dohayan A. Laparoscopic placement of peritoneal dialysis catheter (same day dialysis). *JSLs* 1999; 3(4):327–329.
51. Giannattasio M, La Rosa R, Balestrazzi A. How can videolaparoscopy be used in a peritoneal dialysis programme? *Nephrol Dial Transpl* 1999; 14(2):409–411.
52. Wang JY, Hsieh JS, Chen FM, et al. Secure placement of continuous ambulatory peritoneal dialysis catheters under laparoscopic assistance. *Am Surg* 1999; 65(3):247–249.
53. Crabtree JH, Fishman A. A laparoscopic approach under local anesthesia for peritoneal dialysis access. *Perit Dial Int* 2000; 20(6):757–765.
54. Tsimoyiannis EC, Siakis P, Glantzounis G, et al. Laparoscopic placement of the Tenckhoff catheter for peritoneal dialysis. *Surg Laparosc Endosc Percutan Tech* 2000; 10(4):218–221.
55. Batey CA, Crane JJ, Jenkins MA, et al. Mini-laparoscopy-assisted placement of Tenckhoff catheters: an improved technique to facilitate peritoneal dialysis. *J Endourol* 2002; 16(9):681–684.
56. Varela JE, Elli EF, Vamino D, et al. Mini-laparoscopic placement of a peritoneal dialysis catheter. *Surg Endosc* 2003; 17(12):2025–2027.
57. Crabtree JH, Fishman A. Laparoscopic omentectomy for peritoneal dialysis catheter flow obstruction: a case report and review of the literature. *Surg Laparosc Endosc Percut Tech* 1999; 9(3):228–233.
58. Crabtree JH, Kaiser Ke, Huen IT, et al. Cost-effectiveness of peritoneal dialysis catheter implantation by laparoscopy versus by open dissection. *Adv Perit Dial* 2001; 17:88–92.
59. Ogunc G, Tuncer M, Ogunc D, et al. Laparoscopic omental fixation technique versus open surgical placement of peritoneal dialysis. *Surg Endosc* 2003; 10:1007.
60. Lu CT, Watson DI, Elias TJ, et al. Laparoscopic placement of peritoneal dialysis catheters: 7 years experience. *ANZ J Surg* 2003; 73(3):109–111.
61. Crabtree JH, Siddiqi RA. Dialysis catheter infection related peritonitis: incidence and time dependent risk. *ASAIO J* 1999; 45(6):574–580.
62. Crabtree JH, Fishman A. Videolaparoscopic implantation of long-term peritoneal dialysis catheters. *Surg Endosc* 1999; 13(2):186–190.
63. Moncrief JW, Popovich RP, Broadrick LJ, et al. The Moncrief-Popovich catheter. A new peritoneal access technique for patients on peritoneal dialysis. *ASAIO J* 1993; 39(1):62–65.
64. Moncrief JW, Popovich RP, Simmons E, et al. Peritoneal access technology. *Perit Dial Int* 1993; 13(suppl 2):S121–S123.
65. Moncrief JW, Popovich RP, Seare W, et al. Peritoneal dialysis access technology: the Austin Diagnostic Clinic experience. *Perit Dial Int* 1996; 16(suppl 1):S327–S329.
66. Moncrief JW, O.D. Continuous Ambulatory Peritoneal Dialysis. N.K., Gokal R, eds. Dordrech: Kluwer Academic Publishers, 1994:357–398.
67. Prischl FC, Wallner M, Kalchmair H, et al. Initial subcutaneous embedding of the peritoneal dialysis catheter—a critical appraisal of this new implantation technique. *Nephrol Dial Transpl* 1997; 12(8):1661–1667.
68. Caruso DM, Gary DL, Kohr JM, et al. Reduction of infectious complications and costs using temporary subcutaneous implantation of peritoneal dialysis catheters. *Adv Perit Dial* 1997; 13:183–189.
69. Esson ML, Quinn MJ, Hudson EL, et al. Subcutaneously tunnelled peritoneal dialysis catheters with delayed externalization: long-term follow-up. *Adv Perit Dial* 2000; 16:123–128.
70. Taha A. Prevention and Management of Complications of Laparoscopic Procedure. Smith's Textbook of Endourology. Quality Medical Publishing, Inc., 1996:851–869.
71. Madhukar KR. Complications of Peritoneal Access In Acute and Chronic Peritoneal Dialysis. Complications of Dialysis. Marcel Dekker, Inc., 2000:133–149.
72. Zappacosta AR. Complications of Acute Peritoneal Catheter Insertion. Dialysis Therapy. Philadelphia: Hanley & Belfus, Inc., 2002:51–53.
73. Birns MT. Inadvertent instrumental perforation of the colon during laparoscopy: nonsurgical repair. *Gastrointest Endosc* 1989; 35(1):54–56.
74. Reich H. Laparoscopic bowel injury. *Surg Laparosc Endosc* 1992; 2(1):74–78.

75. Berry MA, Rangraj M. Conservative treatment of recognized laparoscopic colonic injury. *JSL* 1998; 2(2):195–196.
76. Nomura T, Shirai Y, Okamoto H, et al. Bowel perforation caused by silicone drains: a report of two cases. *Surg Today* 1998; 28(9):940–942.
77. Christie JP, Marrazzo J 3rd. “Mini-perforation” of the colon — not all postpolypectomy perforations require laparotomy. *Dis Colon Rectum* 1991; 34(2):132–135.
78. Damore LJ, Rantis PC, Vernava AM, et al. Colonoscopic perforations: etiology, diagnosis, and management. *Dis Colon Rectum* 1996; 39(11):1308–1314.
79. Simkin EP, Wright FK. Perforating injuries of the bowel complicating peritoneal catheter insertion. *Lancet* 1968; 1(7533):64–66.
80. Kahn SI, Garella S, Chazan JA. Nonsurgical treatment of intestinal perforation due to peritoneal dialysis. *Surg Gynecol Obstet* 1973; 136(1):40–42.
81. Rubin J, Oreopoulos DG, Lio TT, et al. Management of peritonitis and bowel perforation during chronic peritoneal dialysis. *Nephron* 1976; 16(3):220–225.
82. Chao TH, Wang Hm, Lion TY et al. Clinical treatment in colonoscopic perforation: a comparison of surgical and conservative management. *Zhonghua Yi Xue Za Zhi (Taipei)* 1997; 60(1):36–39.
83. Makovnik P, Kozova B. Peritoneal catheters in the treatment of continuous peritoneal dialysis continuous ambulatory peritoneal dialysis. *Vnitr Lek* 1997; 43(1):51–54.

N. P. Gupta

Department of Urology, All India Institute of Medical Sciences, New Delhi, India

M. S. Ansari

Department of Urology and Renal Transplantation, Sanjay Gandhi Postgraduate Institute of Medical Sciences, Lucknow, India

- INTRODUCTION
- ETIOPATHOGENESIS
- CLINICAL PRESENTATION AND EVALUATION
- CONSERVATIVE TREATMENT
- PATIENT SELECTION FOR LAPAROSCOPIC LYMPHATIC DISCONNECTION
- TECHNIQUE OF RETROPERITONEOSCOPIC LAPAROSCOPIC LYMPHATIC DISCONNECTION
 - Nephrolympholysis
 - Stripping of Hilar Vessels
 - Ureterolympholysis
- Fasciectomy (Excision of Perinephric Fat and Fascia Gerota)
- Nephropexy
- TECHNICAL TIPS TO AID LAPAROSCOPIC LYMPHATIC DISCONNECTION
- POSTOPERATIVE CARE AND FOLLOW-UP
- ADVANTAGES OF LAPAROSCOPY
- RETROPERITONEAL VS. TRANSPERITONEAL LYMPHOLYSIS
- SUMMARY
- REFERENCES

INTRODUCTION

The most common cause of chyluria is parasitic infection secondary to filariasis caused by *Wuchereria bancrofti*.

Chyluria, the passage of chyle into the urine giving it a typical milky appearance, is due to a communication between lymphatic and urinary system. Chyluria is rare except in the areas of the world where filariasis is endemic specially India, Japan, Southeast Asia, and parts of Africa, Australia, and South America (1). The most common cause of chyluria is parasitic infection secondary to filariasis caused by *Wuchereria bancrofti*.

In 1878, Bancroft discovered adult worm in an abscess cavity; in 1929 it was named as *Wuchereria bancrofti* (2–4). Wood demonstrated pyelolymphatic reflux during retrograde pyelography in 1929 (5). In 1968, Wucherer described microfilaria in the urine of a patient with hematochyluria. Kinmoth (1955) introduced the technique of lymphangiography, and Kittredge described the lymphaticourinary communication (6).

Chyluria can occur anywhere in urinary tract, but the chyluria of renal origin is the most common and usually represents the chronic stage of the filarial disease. Chyle consists of lymphatic elements: albumin, fat (triglycerides), and fibrin due to a formation of coagulum if a urine is left standing for a long time.

Chyluria can occur anywhere in urinary tract, but the chyluria of renal origin is the most common and usually represents the chronic stage of the filarial disease. Chyle consists of lymphatic elements: albumin, fat (triglycerides), and fibrin due to formation of a coagulum if a urine sample is left standing for a long time.

The quantity of lipids depends on the size of the fistula and the amount and composition of dietary fat. There are other pathologic conditions, which may clinically mimic chyluria and need differentiation (Table 1).

ETIOPATHOGENESIS

The theory of lymphatic obstruction appears to be most convincing and is well supported by the existing literature.

Chyluria may be classified as parasitic or nonparasitic (Table 2). Various theories have been suggested to explain the cause of chyluria. Prout postulated the theory of secretion of fat from blood through the kidney (9). Mollenbroch (1670) suggested abnormal connection between lymphatic and urinary system (10). Ackerman (1863) gave the “obstructive theory” and suggested that the obstruction of lymphatics anywhere between intestinal lacteals and the thoracic duct may give rise to chyluria (3). The theory of lymphatic obstruction appears to be most convincing and is well supported by the existing literature (11–13).

The lymph vessels of the kidneys form three plexi, one of them lies within the renal parenchyma, second beneath the capsule, and the third in the perinephric fat (Fig. 1). The second and third groups communicate freely with each other. The vessels emerging from the renal substance converge to form four to seven trunks. At the

TABLE 1 ■ Conditions Mimicking Chyluria

Gross pyuria
Phosphaturia
Amorphous urate material in the urine
Fungiuria
Heavy proteinuria (nephrotic range)

TABLE 2 ■ Classification of Chyluria

Parasitic	Nonparasitic
Filariasis (<i>Wuchereria bancrofti</i>)	Trauma
Echinococcosis (<i>Cysticercus cellulose</i>)	Tuberculosis
Ascariasis (<i>Ascaris lumbricoides</i>)	Diabetes
Ancylostomiasis	Retroperitoneal neoplasm
Trichiniasis	Retroperitoneal abscess
Malaria	Lymphatic aneurysm
	Congenital disorders of lymphatic system
	Congenital stenosis of thoracic duct
	Pernicious anemia
	Pregnancy

Source: From Refs. 7 and 8.

Chyluria occurs after the lymphatic vessel ruptures into the renal tubules. This is secondary to the obstruction in the draining lymphatic, which is usually due to an acquired cause. The obstruction in tropical countries is most commonly caused by filariasis, i.e., *W. bancrofti* infection. The dying worm provokes lymphangiolar dilatation and finally obstruction. The obstruction leads to high intralymphatic pressure and rupture of lymphatic in to urinary system.

hilum, these lymphatics join capsular and perinephric groups and traverse along the renal vessels to lateral aortic nodes. The perinephric group also drains in to the lateral aortic nodes. The renal pelvis and upper ureter lymphatics are connected to lymphatics around the renal vessels or lateral aortic nodes. Lymphatics from lower ureter pass to common iliac nodes. Lymphatics from the bladder originate in three sets: vessels from trigone, superior surface, and inferolateral surface all drain in to external iliac group (14).

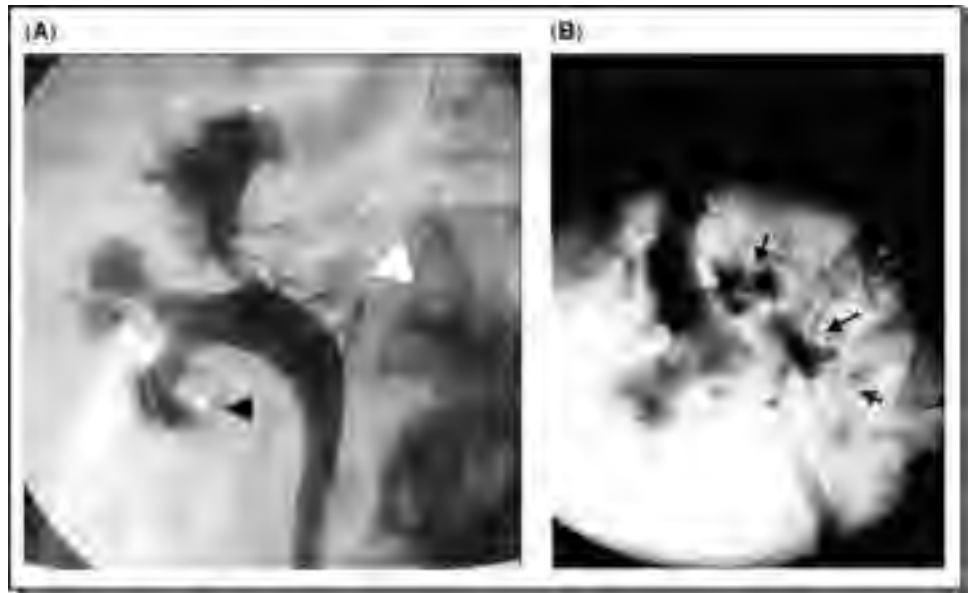
Chyluria occurs after the lymphatic vessel ruptures into the renal tubules. This is secondary to the obstruction in the draining lymphatic, which is usually due to an acquired cause. The obstruction in tropical countries is most commonly caused by filariasis, i.e., *W. bancrofti* infection. The dying worm provokes lymphangiolar dilatation and finally obstruction. The obstruction leads to high intralymphatic pressure and rupture of lymphatic in to urinary system (3).

The reported incidence of chyluria is up to 2% in cases of filariasis, and in endemic areas about 10% of the population may be infected (15).

FIGURE 1 ■ Diagrammatic display of lymphatic system of kidney, ureter, and bladder.

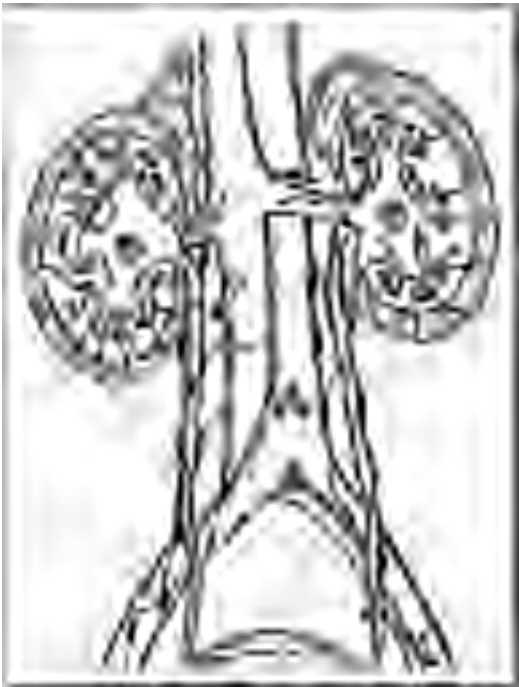

FIGURE 2 ■ Retrograde ureteropyelograms (two different patients) showing dilated lymphatic channels (arrow heads) of right kidney (A) and upper ureter and fistulous communication with retroperitoneal lymphatics (B).



Chyluria can lead to considerable weakness and weight loss secondary to loss of proteins, cholesterol, and triglycerides.

Retrograde ureteropyelogram helps in establishing the connection between the lymphatics and urinary system.

Ultrasonography or computed tomography of the abdomen may be required in cases of nonfilarial etiology, e.g., malignant tumors.

Retrograde pyelography and sclerotherapy have been used with a success rate varying from 55% to 68% with a recurrence rate above 50% on a long-term basis.

CLINICAL PRESENTATION AND EVALUATION

Chyluria has an unpredictable course associated with remission and exacerbation. The disease usually affects young adults presenting with complaints of passage of whitish urine, white clots, or hematuria (hematochyluria). Sometimes chylous clots can lead to obstruction in the urinary tract, leading to clot colic (flank pain), retention of urine, or even anuria. Although not life threatening, the disease can be debilitating.

Chyluria can lead to considerable weakness and weight loss secondary to loss of proteins, cholesterol, and triglycerides (11,12,16).

Patient, usually come from an endemic area and give a long history of the disease. Urinary chemistry reveals proteinuria and lipiduria with high triglycerides along with a layer of chylomicrons. Serum proteins may be low in cases of intractable chyluria. Renal functions are usually normal. Intravenous urography is usually not helpful in delineating the pyelolymphatic leak but is required to know the function and anatomy of upper tracts. Cystoscopy may show the chylous efflux from the ureteral orifice from one or both the sides. In cases of clear efflux, ureters should be catheterized, and selective sampling should be tested for the chyle to know the exact side of the involved renoureteral unit.

Retrograde ureteropyelogram helps in establishing the connection between the lymphatics and urinary system. It is useful not only to identify the affected side but also to assess the severity of the pyelolymphatic communications (Fig. 2).

Ultrasonography or computed tomography of the abdomen may be required in cases of nonfilarial etiology, e.g., malignant tumors (7).

CONSERVATIVE TREATMENT

Conservative treatment of chyluria includes bed rest, low-fat diet (omission of long-chain triglycerides), and encouraging the use of medium-chain triglycerides (coconut oil) and high-protein diet (8). Medium-chain triglycerides (less than 12 C atoms) are transported directly from the gut to the liver via the portal system and not through the lymphatic channels, as are long-chain fatty acids. Multiple courses of antifilarial drugs are required. Other modalities of treatment include retrograde pyelography and instillation of sclerosing agents such as 10% to 25% bromide, normal saline, 0.2% povidone iodine, 50% glucose saline, or 1% to 2% silver nitrate in to the renal pelvis (12,17–19). Silver nitrate induces an inflammatory reaction in the lymphatics, resulting in chemical lymphangitis and edema of the lymph channels. Finally, fibrosis ensues causing blockage leading to immediate relief.

Retrograde pyelography and sclerotherapy have been used with a success rate varying from 55% to 68% with a recurrence rate above 50% on long-term basis (12,16,19).

A simple algorithm to treat chyluria is given in Figure 3.



FIGURE 4 ■ Schematic diagram for the port placement for right-side lymphatic disconnection.



FIGURE 5 ■ Opening of Gerota's fascia posteriorly to dissect out the kidney.

a second port (10 mm) is inserted in the same line 2 cm above the iliac crest. A third (10/5 mm) canula is inserted in midaxillary line, 2 cm below the costal margin (Fig. 4). The procedure of laparoscopic lymphatic disconnection includes five important steps (2,7,11–13):

1. Nephrolympholysis
2. Stripping of hilar vessels
3. Ureterolympholysis
4. Fasciectomy
5. Nephropexy

Nephrolympholysis

The kidney and adrenal gland are surrounded by perinephric or perirenal fat these together are enclosed by perirenal fascia or Gerota's fascia. Nephrolympholysis is the dissection of kidney from its surrounding perirenal fascia. Gerota's fascia is opened, and the kidney is dissected gradually out of the perirenal fascia (Fig. 5). The dissection is started posteriorly followed by dissection of the upper pole, lower pole, and finally the anterior surface. Once the kidney is mobilized all around, the dissection of the renal vessels is started posteriorly.

Stripping of Hilar Vessels

The vascular dissection is to be done with utmost care. The dilated perirenal and perihilar lymphatics are individually clipped and divided (Fig. 6).

The renal vessels are laid bare of perivascular tissue. The dilated lymphatics are diligently searched for and taken care under laparoscopic magnification. Once the posterior dissection is completed, the anterior surface of the vessels is cleared of loose areolar tissue and lymphatics.

Ureterolympholysis

Ureterolympholysis includes circumferential mobilization of ureter down to common iliac vessels (Fig. 7). All lymphatics are individually ligated/clipped and divided. Transverse sweeping movements downwards help in clearing ureter out of the loose fatty tissue.

Fasciectomy (Excision of Perinephric Fat and Fascia Gerota)

The kidney is bared of its coverings. As much of perirenal fat as possible is removed. This maneuver removes the perinephric group of lymphatics, which freely communicate with subcapsular group of lymphatics and drain in to the lateral aortic nodes.

The vascular dissection is to be done with utmost care. The dilated perirenal and perihilar lymphatics are individually clipped and divided.

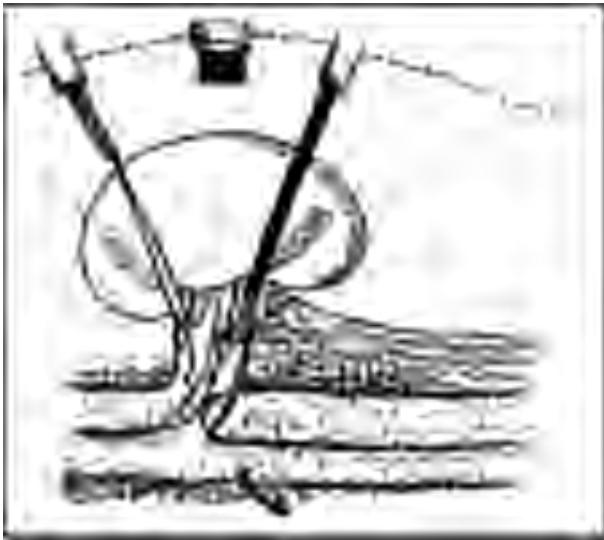

FIGURE 6 ■ Stripping of hilar vessels.



FIGURE 7 ■ Dissection of ureter all around with transverse sweeping movements.

Nephropexy

If the kidney thus freed is hypermobile in the retroperitoneal space, the renal capsule is fixed to the posterior abdominal wall using three sutures at upper, middle, and lower poles of the kidney. This is done to avoid tension on renal vessels. Finally, the retroperitoneal space is irrigated with saline, inspected for hemostasis, and a drain is placed. After desufflation, the port sites are closed with muscles and skin sutures.

TECHNICAL TIPS TO AID LAPAROSCOPIC LYMPHATIC DISCONNECTION

- Acquaintance to the variations in number and course of renal vessels helps in avoiding vascular catastrophe. During hilar stripping, one should carefully look for the posterior segmental branch of renal artery, which is the most constant division and makes its way out of the renal artery before it enters the renal hilum and proceeds posterior to the renal pelvis to supply a large posterior segment of the kidney. It may be mistaken for a dilated lymphatic vessel and get inadvertently clipped (12).
- Occasionally, the right renal artery may arch anterior to the inferior vena cava. In that way it will be located more anteriorly to the right renal vein. In retroperitoneoscopic approach, such anteriorly located right renal artery may be best approached through the plane created between the anterior surface of the kidney and peritoneal reflection medially. In such a situation, conversion of retroperitoneal to transperitoneal approach may be a more judicious step.
- During ureterolympholysis, staying in proper dissection plane, i.e., outside the ureteral adventitia that contains the plexus of ureteral blood supply that courses longitudinally along the ureter, helps in preserving the ureteral blood supply.
- To ensure complete lymphatic dissection, a few drops of methylene blue can be applied to the renal hilum via a specially designed laparoscopic syringe to aid in the visualization of the remaining lymphatic vessels (Fig. 8) (11).

FIGURE 8 ■ Diagrammatic representation after completion of nephrolympholysis, stripping of hilar vessels, and ureterolympholysis.

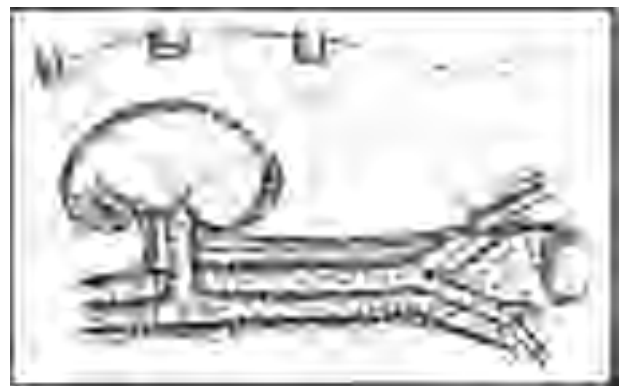


TABLE 3 ■ Causes of Failure after Laparoscopic Lymphatic Disconnection

Early failure	Late failure
Incomplete stripping	Recanalization of lymphatic
Release of chyle from contralateral unit	fistulae to the operated kidney
Fistula in the lower part of the ureter and bladder	
Collateral release of chyle due to increased lymphatic pressure	
Source: From Refs. 19 and 22.	

POSTOPERATIVE CARE AND FOLLOW-UP

Usually the patient is allowed oral food by evening on the day of surgery itself. The Foley catheter is removed next morning. Follow-up includes subjective and objective evaluation of the patient. Urine examination for chyle, lipids (triglycerides and cholesterol), and proteins should be checked in the postoperative period and then every six months. In spite of surgical intervention, chyluria may persist, which needs reevaluation, and some of the causes are discussed below (Table 3).

ADVANTAGES OF LAPAROSCOPY

Laparoscopy provides optical magnification that facilitates the identification of small lymphatics easily, thus increasing the chances of success with lesser blood loss and operative time.

As the open surgical procedure requires extensive mobilization within the retroperitoneum over a large area, it necessitates a large flank or midline incision. The objectives of open surgery can be easily met with minimally invasive technique of laparoscopy (Table 4) (11–13).

Laparoscopy provides optical magnification that facilitates the identification of small lymphatics easily, thus increasing the chances of success with lesser blood loss and operative time.

Postoperative recovery is rapid and hospital stay is short (11–13).

TABLE 4 ■ Laparoscopic Lymphatic Disconnection Reported by Various Authors

Study (Ref.)	No. of renoureteral units	Approach	Technique	Results	Follow-up	Comments
Zhang et al. (11)	7	RP	Nephrolympholysis Hilar stripping	100%	2–12 mo (mean 6.7 ± 4)	Used 3 ports
Jiang et al. (20)	6	RP	Ureterolympolysis Nephrolympholysis Hilar stripping	100%	1–1.6 yr	
Hemal and Gupta (12)	11	RP	Ureterolympolysis Nephrolympholysis Hilar stripping	Initially chyluria subsided in	6 mo–4.5 yr (mean, 31 mo)	1prolonged drainage (>5 days) 1inadvertent clipping of a branch of posterior segmental artery
			Ureterolympolysis Fasciectomy ^a Nephropexy ^a	all cases Recurred in two cases because of contralateral side at 1 and 9 mo, respectively which was treated successfully		
Gomella et al.(3)	1	RP	Removal of fascia Gerota Stripping of renal hilum	Chyluria subsided	2 yr	Used 4 ports
Chui et al. (2)	1	TP	Ligation and division of lymphatics of hilum and ureter (hilar stripping and ureterolympolysis)	Chyluria subsided	2 yr	Used 5 ports

^aOptional.

Abbreviations: RP, retroperitoneal; TP, transperitoneal.

Retroperitoneal laparoscopic lympholysis has an obvious advantage, because the peritoneum is not transgressed at any level thus avoiding the potential complications such as bowel injury and prolonged ileus.

RETROPERITONEAL VS. TRANSPERITONEAL LYMPHOLYSIS

Leaving the initial report of transperitoneal approach (2), mostly the procedure of lympholysis has been performed retroperitoneally (11–13). Retroperitoneal laparoscopic lympholysis has the obvious advantage, because the peritoneum is not transgressed at any level, thus avoiding the potential complications such as bowel injury and prolonged ileus (4). It offers minimal invasion with lesser postoperative pain, lower morbidity, short hospital stay, and rapid recovery (4,8,11,12). Table 4 summarizes the various reported series on laparoscopic management of chyluria.

SUMMARY

- The severe or intractable chyluria does not respond to conservative measures such as dietary modifications or sclerotherapy and usually requires surgical intervention.
- The results of laparoscopic lymphatic disconnection are excellent, and the objectives of open surgery are effectively achieved by this minimally invasive approach.
- Laparoscopic lymphatic disconnection is safe, effective, and gives durable results in patients with intractable filarial chyluria; hence, it should be the procedure of choice.
- Laparoscopic lymphatic disconnection not only considerably reduces the incision-related morbidity without compromising the principles of open surgery, but also offers a quick recovery with a shorter hospital stay.

REFERENCES

1. Hampton HH. Case of nonparasitic haematochyluria. *John Hopkins Hosp Bull* 1920; 31:20.
2. Chui AW, Chen MT, Cahng LS. Laparoscopic nephrolysis for chyluria: case report of long-term success. *J Endourol* 1995; 9(4):319–322.
3. Gomella LG, Shenot P, Abdul-Meguid TA. Extra peritoneal laparoscopic nephrolysis for the treatment of chyluria. *Br J Urol* 1998; 81:320–321.
4. Hemal AK, Kumar M, Pawar RS, Gupta NP. The laparoscopic management of chyluria by retroperitoneal access. *BJU Int* 2000; 86(3):402.
5. Wood AH. Unilateral chyluria. *J Urol* 1929; 21:109.
6. Kittredge RD. Demonstration of lymphatic abnormalities in patient of chyluria. *AJR* 1963; 90:159.
7. Ansari MS, Kumar P. Laparoscopic Management of Chyluria: Contemporary Trends in Laparoscopic Urologic Surgery. New Delhi: B I Churchill Livingstone, 2002:197–202.
8. Hashim SA, Roholt HB, Babayan VK, et al. Treatment of chyluria and chylothorax with medium chain triglycerides. *N Eng J Med* 1964; 270:756.
9. Prout. *On the Nature and Treatment of Stomach and Urinary Diseases*. 3rd ed. London: B I Churchill Livingstone, 1841:120.
10. Xu YM, Ji RJ, Chen ZQ, et al. Microsurgical treatment of chyluria: a preliminary report. *J Urol* 1991; 145:1184.
11. Zhang X, Ye ZQ, Chen Z, et al. Comparison of open surgery versus retroperitoneoscopic approach to chyluria. *J Urol* 2003; 169:991–993.
12. Hemal AK, Gupta NP. Retroperitoneoscopic lymphatic disconnection in the management of intractable chyluria. *J Urol* 2002; 167:2473–2474.
13. *Lymphatic drainage of abdomen and pelvis*. *Grays Anatomy*. 38th ed. London: ELBS with Churchill Livingstone, 1995:1623.
14. Yamuchi S. Chyluria: clinical laboratory and statistical study of 45 personal cases observed in Hawaii. *IBID* 1955; 54:318.
15. Kano K, Arisaka O. Chyluria due to retroperitoneal lymphangioma producing nephrotic syndrome. *J Pediatr* 2003; 143(5):685.
16. Okamoto K, Ohi Y. Causes and treatment of chyluria. *Jpn Med J* 1971; 24562:23.
17. Shanmugam TV, Prakash JV, Shivshanker G. Povidone iodine used as a sclerosing agent in the treatment of chyluria. *Br J Urol* 1998; 82:587.
18. Sabnis RB, Puneekar SV, Desai MR, et al. Instillation of silver nitrate in the treatment of chyluria. *Br J Urol* 1992; 70:660.
19. Okamoto K, Ohi Y. Recent distribution and treatment of filarial chyluria in Japan. *J Urol* 1983; 129:64.
20. Jiang J, Zhu F, Jin F, Jiang Q, Wang L. Retroperitoneoscopic renal pedicle lymphatic disconnection for chyluria. *Chin Med J (Engl)* 2003; 116(11):1746–1748.
21. Torres LF, Estrada J. Experience in the treatment of chyluria. *J Urol* 1962; 73:566.
22. Brunkwall J, Simson O, Berquist D, et al. Chyluria treated with renal transplantation: a case report. *J Urol* 1946; 56:246.
23. Yamuchi S. Chyluria: clinical laboratory and statistical study of 45 cases observed in Hawaii. *J Urol* 1945; 54:318.
24. Puneekar SV, Kelkar AR, Prem AR, et al. Surgical dissection of lymphorenal communication for chyluria: a 15 years experience. *Br J Urol* 1997; 80(6):858–863.
25. Prasad PB, Chaudhary DK, Barnwall SN, et al. Periureteric lymphovenous stripping in cases of chylohaematuria-report of 15 cases. *IJS* 1977; 39(11):607–612.

LAPAROSCOPIC INGUINAL HERNIA SURGERY

Bipan Chand and Jeffrey Ponsky

Department of Minimally Invasive Surgery, Cleveland Clinic Foundation, Cleveland, Ohio, U.S.A.

- | | |
|--|---|
| <ul style="list-style-type: none"> ■ INTRODUCTION ■ INDICATIONS AND CONTRAINDICATIONS ■ ANATOMY ■ SURGICAL TECHNIQUES <ul style="list-style-type: none"> Transabdominal Preperitoneal Hernia Repair Totally Extraperitoneal Hernia Repair ■ POSTOPERATIVE CARE | <ul style="list-style-type: none"> ■ TECHNICAL PEARLS <ul style="list-style-type: none"> Bleeding Nerve Injury Visceral Injury Recurrences ■ SUMMARY ■ REFERENCES |
|--|---|

INTRODUCTION

The first laparoscopic hernia repair was performed prior to laparoscopic cholecystectomy, yet has not supplanted open hernia repair, as has laparoscopic cholecystectomy for gallbladder disease. Reasons may include a steeper learning curve, an assumed increased operative cost, and the excellent alternative in open hernia repair. Ger in 1982 reported on 13 patients undergoing hernia repair, using a stapling device; the 13th patient underwent a laparoscopic repair (1). This early technique used a stapling device to close the neck of the hernia as the sole repair. Since then various techniques have been devised for laparoscopic herniorrhaphy. The initial approach consisting of simple ring closure had a high failure, because the deeper tissues were not approximated. This evolved to the necessity of a prosthetic biomaterial to reinforce the defect. Bogojavalensky first introduced hernia repair using a biomaterial in 1989 (2). At that time, a rolled piece of polypropylene mesh was placed into the indirect space of the hernia. Preliminary reports of this technique were promising, but long-term follow-up revealed a recurrence rate of 15% to 20%, leading to abandonment of such technique. Subsequently, the plug-and-patch and then the development of the intraperitoneal onlay mesh followed.

The intraperitoneal onlay mesh technique consisted of a large piece of biomaterial placed intra-abdominally to cover the peritoneum with a fixation device (3,4). This technique involved no dissection and was simple to perform, but led to a high failure rate for a number of reasons. The mesh would slip into the hernia defect, leading to adhesions with the bowel and also potential erosion into the bowel. Therefore, proper fixation of the mesh to the fascia of the transversalis muscle was deemed necessary to prevent this high failure rate and led to the development of the current transabdominal preperitoneal repair. Schultz et al. were the first to report on this technique, which involves dissection of the preperitoneal space and then fixation of a mesh to reinforce the defect (5). A later modification of this technique consisted of totally extraperitoneal approach, which involves balloon dissection into the preperitoneal space and avoids entering the abdomen (6). The totally extraperitoneal repair also incorporates a biomaterial mesh to repair the hernia with and sometimes without a fixation device.

Transabdominal preperitoneal and totally extraperitoneal approaches are the current modalities used in laparoscopic herniorrhaphy.

INDICATIONS AND CONTRAINDICATIONS

Contraindications to the laparoscopic approach are similar to those to open hernia repair (Table 1). The most important consideration is the surgeon's experience in performing a laparoscopic repair.

The learning curve for a transabdominal preperitoneal or totally extraperitoneal repair has been documented to be around 50 cases (7).

The laparoscopic transabdominal preperitoneal approach requires general anesthesia for adequate abdominal relaxation and insufflation. Although there have

Transabdominal preperitoneal and totally extraperitoneal approaches are the current modalities used in laparoscopic herniorrhaphy.

The learning curve for a transabdominal preperitoneal or totally extraperitoneal repair has been documented to be around 50 cases.

TABLE 1 ■ Contraindications to Laparoscopic Hernia Repairs

Inexperience
 Contraindication of general anesthesia
 Previous preperitoneal surgery
 Pelvic irradiation
 Extensive intraperitoneal adhesions (transabdominal preperitoneal repair)
 Gigantic scrotal hernia

Patients with chronic incarceration without mechanical bowel obstruction may be more amenable to the laparoscopic approach, given that less bowel dilation is encountered.

Gigantic scrotal hernias are difficult to approach laparoscopically.

The initial landmarks for the transabdominal preperitoneal repair include (i) the medial umbilical ligament, which contains the obliterated umbilical arteries and (ii) the lateral umbilical ligament, which contains the inferior epigastric arteries.

Once the peritoneum is opened, key anatomical structures for the transabdominal preperitoneal repair and, initially, in the totally extraperitoneal repair include:

- Pubic tubercle
- Cooper's ligament
- Direct and indirect space
- Iliopubic tract

been reports of patients undergoing a laparoscopic operation (mostly totally extraperitoneal approach) using a spinal and even at times a local anesthetic, these types of regional anesthesia may not give adequate abdominal relaxation or afford good pain control. Other contraindications are related to abdominal insufflation and subsequent cardiopulmonary compromise. Patients with significant pulmonary obstructive disease or significant cardiac dysfunction may not tolerate the increased abdominal pressure or deep sedation of general anesthetic. These patients would benefit from open herniorrhaphy using a regional or local anesthetic. Laparoscopic hernia repair may be contraindicated in male patients with elevated prostate specific antigen, and indication for prostatectomy as dissection in the preperitoneal space after laparoscopic hernia repair is difficult.

Incarcerated hernias can be approached through a laparoscopic approach, but can be a challenge for the inexperienced laparoscopic surgeon. The manipulation of contents within the hernia sac and acute nature of incarceration (with possible bowel obstruction) may be difficult to reduce. In selected cases, general anesthetic and pneumoperitoneum will allow for adequate abdominal wall relaxation with subsequent spontaneous reduction of the hernia. If spontaneous reduction does not occur, then the surgeon must be meticulous in reducing the bowel from within the hernia sac. Occasionally, opening the hernia sac and widening the neck of the defect will allow the surgeon to safely reduce its contents.

Patients with chronic incarceration without mechanical bowel obstruction may be more amenable to the laparoscopic approach, given that less bowel dilation is encountered.

Other factors that may make operating on an acute obstruction unsafe include difficult abdominal entry, inadequate space for pneumoperitoneum, and difficult handling of dilated bowel. Signs and symptoms of peritonitis may alert the surgeon of possible strangulation and bowel ischemia requiring bowel resection, which may be approached laparoscopically. Again, the difficulty is obtaining a safe pneumoperitoneum and handling dilated and possibly ischemic bowel. Newer instruments and stapling devices have allowed for complete intracorporeal bowel anastomosis. Mesh infection is the primary concern in these contaminated fields, and appropriate biomaterial choice is important.

Gigantic scrotal hernias are difficult to approach laparoscopically. The difficulty is reducing the contents into the abdominal cavity while maintaining pneumoperitoneum. Repairing the large floor defect of the inguinal canal may also pose a problem. These hernias may require a laparotomy as well as an inguinal incision for reduction of the contents and then adequate floor repair.

ANATOMY

Laparoscopic herniorrhaphy requires detailed knowledge of pelvic anatomy. In fact the operation requires the surgeon to start from the deeper structures and work toward the more superficial layers. This unfamiliarity with internal inguinal anatomy may be one of the reasons that surgeons are uncomfortable with learning laparoscopic herniorrhaphy.

The initial landmarks for the transabdominal preperitoneal repair include (i) the medial umbilical ligament, which contains the obliterated umbilical arteries and (ii) the lateral umbilical ligament, which contains the inferior epigastric arteries. The direct space is seen medial to the epigastric vessels and the indirect space lateral to the vessels and adjacent to the cord structures within the internal inguinal ring.

Once the peritoneum is opened, key anatomical structures for the transabdominal preperitoneal repair and, initially, in the totally extraperitoneal repair include:

- Pubic tubercle
- Cooper's ligament
- Direct and indirect space
- Iliopubic tract

Once these key structures are identified, the hernia sac can be reduced, and mesh repair undertaken. Knowledge of the regional nerves is critical to avoid the neuralgias that had complicated the early laparoscopic repairs.

Important anatomic triangles have also been identified in laparoscopic hernia repairs. The "triangle of doom" is bounded by the medial aspect of the ductus deferens and laterally by the spermatic vessels and houses the iliac vessels and femoral nerve. The "triangle of pain" is made up of the iliopubic tract and the spermatic vessels and contains the lateral femoral cutaneous nerve and the genitofemoral nerve. These two regions should be avoided during fixation of the mesh to the transversalis fascia.

SURGICAL TECHNIQUES

The current two most common laparoscopic approaches to inguinal hernia repair include the transabdominal preperitoneal and the totally extraperitoneal repair.

The current two most common laparoscopic approaches to inguinal hernia repair include the transabdominal preperitoneal and the totally extraperitoneal repair.

Both the totally extraperitoneal and the transabdominal preperitoneal approach rely on the same concept introduced by Stoppa in the late 1980s (8). A prosthetic mesh is placed in the preperitoneal space covering and reinforcing the direct and indirect space of the inguinal floor. The only difference in these approaches involves the access into the preperitoneal space. The transabdominal preperitoneal approach requires entry into the abdominal cavity and incision of the peritoneum with creation of a flap, allowing access to the preperitoneal space. The totally extraperitoneal repair does not enter the abdominal cavity and allows for dissection only in the preperitoneal space.

Transabdominal Preperitoneal Hernia Repair

Transabdominal preperitoneal approach requires entry into the abdominal cavity. The patient is asked to empty the bladder prior to operation, and general anesthesia is administered. A Foley catheter is not routinely used in either laparoscopic approach. The patient is placed supine, and the monitors placed at the foot of the table. The surgeon stands on the opposite side of the inguinal hernia, and the abdomen is prepped from xiphoid to inguinal region, including the hernia. The initial trocar is placed using an open technique at the level of the umbilicus. We prefer to use a 10-mm trocar at this site allowing for a 10 mm 30° laparoscope.

Angled scopes are mandatory when performing laparoscopic transabdominal preperitoneal.

Angled scopes are mandatory when performing laparoscopic transabdominal preperitoneal.

The 10-mm port allows for easy introduction of prosthetic mesh into the abdominal cavity. The patient is placed in Trendelenburg position, and diagnostic laparoscopy performed. The defect is identified and characterized as to either a direct or indirect hernia. The opposite side is also evaluated to rule out a double hernia. Two additional 5-mm trocars are then placed below the level of the camera and lateral to the rectus muscle. The use of a 20-gauge needle attached to a 10-cc syringe with local anesthetic allows for excellent visualization of each trocar site and for instillation of anesthetic into the peritoneum for postoperative pain control. Trocar placement lateral to the rectus muscle prevents injury to the epigastric vessels.

The medial umbilical ligament contains the obliterated umbilical arteries and the lateral umbilical ligament contains the inferior epigastric vessels. A direct hernia defect is identified medial to the epigastric vessels and an indirect defect is lateral to the vessels and follows the cord structures through the internal ring.

Familiarity with pelvic anatomy is crucial to performing a successful operation. The medial umbilical ligament contains the obliterated umbilical arteries and the lateral umbilical ligament contains the inferior epigastric vessels. A direct hernia defect is identified medial to the epigastric vessels and an indirect defect is lateral to the vessels and follows the cord structures through the internal ring.

Incising the peritoneum medially from the medial umbilical ligament to the anterior iliac spine laterally begins the operation. This peritoneal flap is further developed by bluntly pushing the fat and epigastric vessels toward the "ceiling." A wide pocket is required for adequate mesh placement. A large piece of mesh is required to provide adequate defect coverage and reduce the chance of recurrence. Dissection is then continued medially toward the pubic tubercle and Cooper's ligament. These structures are exposed using careful blunt dissection because numerous small crossing veins may be encountered and easily injured. The tubercle lies in the midline and can be felt with the instruments. Dissection is then continued laterally to expose the iliopubic tract and internal ring. Direct defects do not require manipulation of cord structures because the defect is only of the inguinal floor. When exposing this defect, the surgeon must reduce the hernia sac into the abdominal cavity. This is accomplished by retracting inferiorly on the peritoneal flap until the pseudosac of the floor, a white line that runs parallel to the inguinal floor, can be identified. The principle is to completely reduce the inverted peritoneum into the abdominal cavity and allows for complete coverage of the defect by prosthetic mesh. The indirect hernia courses along the cord structures through the internal ring. The reduction of an indirect hernia requires careful identification of the ductus deferens, which runs over Cooper's ligament from medial to lateral, and other cord structures. Exposure of the direct space is also achieved when repairing indirect hernias. Blunt atraumatic graspers are used to carefully separate and reduce the indirect hernia away from the cord structures.

The fat surrounding the cord structures, known as cord lipomas, should be identified and removed. If this is not accomplished, patients may feel a recurrence has occurred.

The fat surrounding the cord structures, known as cord lipomas, should be identified and removed. If this is not accomplished, patients may feel a recurrence has occurred.

Once the hernia has been reduced, a prosthetic mesh is placed into the abdominal cavity through the umbilical trocar. A large piece of polypropylene mesh that measures 10 × 15 cm is preferred. The mesh is orientated so there is complete coverage of

the direct and indirect space, and, most importantly, to cover the pubic tubercle where most recurrences occur. There have been no studies showing a benefit to creating a “slit” in the mesh to encircle the cord structures, and some authors feel that this may lead to cord ischemia. The mesh is then in place using a spiral tacker. The first tack is medially placed on the pubic tubercle and then along Cooper’s ligament laterally. Next, the mesh is fixed to the “ceiling” of the inguinal floor along the posterior aspect of the transversalis fascia and then laterally above the iliopectic tract. The peritoneal flap is then reapproximated and tacked in place. The trocars are removed and fascia closed at the umbilical site.

Totally Extraperitoneal Hernia Repair

Patient and operating room are prepared in a similar fashion to the transabdominal preperitoneal repair. After an infraumbilical vertical incision is made, the anterior rectus fascia is incised, and the rectus muscle lifted upward and laterally, exposing the posterior sheath. The surgeon’s finger is then used to gently separate the rectus muscle from the posterior sheath. The dissecting balloon is placed into this plane and directed toward the pubic tubercle. A 10-mm laparoscope is then placed into the balloon and the balloon slowly inflated under direct visualization. The balloon is then left inflated for a short time to tamponade any small vessels. The inferior epigastric vessels should be directed anteriorly during this step. The balloon is then removed, and a Hasson type trocar placed and the cavity insufflated to 12 mmHg. Two 5-mm trocars are then placed in the midline between the pubic tubercle and the umbilical trocar under direct visualization.

The pelvic anatomy is then delineated with identification of the pubic tubercle, Cooper’s ligament, and the epigastric vessels. The lateral space is then bluntly developed toward the anterior iliac spine. For an indirect hernia, the sac is dissected perpendicular to the cord structures. The sac is then completely invaginated if at all possible to allow for placement of the mesh. A 10 × 15 cm mesh is placed into this space and tacked in a similar fashion as described in the transabdominal preperitoneal repair. Insufflation and trocars are removed and the skin closed. No fascial defect needs to be closed in the totally extraperitoneal repair.

Recent studies have shown the decreased necessity of fixation of the mesh in the totally extraperitoneal repair. This may lead to decreased postoperative neuralgia and decreased cost of surgery while not incur any an increase incidence of hernia recurrence (9).

Recent studies have shown the decreased necessity of fixation of the mesh in the totally extraperitoneal repair. This may lead to decreased postoperative neuralgia and decreased cost of surgery while not incur any an increase incidence of hernia recurrence.

POSTOPERATIVE CARE

Patients are observed for a short time in the outpatient area and routinely discharged the same day of surgery. An intravenous nonsteroid, such as ketorolac, is given to patients at the time of emergence from anesthesia for pain control. Patients are ambulated in the recovery area, asked to void prior to release, and given a mild narcotic for postoperative pain control for the next several days. Routine activities, including showering, can be initiated the day after surgery. Patients are to refrain from driving while on narcotics and whether substantial pain still exists. Table 2 lists the most common postoperative complications.

TECHNICAL PEARLS

Bleeding

Significant bleeding may occur from various sources, including the epigastric vessels, the crossing veins over Cooper’s ligament, and the iliac vessels. Proper trocar placement and dissection in the correct plane prevents injury to such vessels.

The use of a small gauge needle and syringe filled with anesthetic at the time of initial trocar placement during the transabdominal preperitoneal repair will allow for direct placement of trocars lateral to the epigastric vessels. During initial dissecting balloon placement in the totally extraperitoneal repair, it is important to visualize balloon expansion of the cavity and the correct anterior displacement of the epigastric vessels. If it becomes apparent that the epigastric vessels are being displaced incorrectly, insufflation should be stopped and the remainder of the dissection done under direct visualization. If the vessels become torn in either operation, they can be directly ligated using a suture passer and absorbable suture or clipped. Confidence with anatomy and location of the external iliac vessels and the constant

Significant bleeding may occur from various sources, including the epigastric vessels, the crossing veins over Cooper’s ligament, and the iliac vessels. Proper trocar placement and dissection in the correct plane prevents injury to such vessels.

crossing vein over Cooper's ligament will help the surgeon in avoiding these structures during the dissection.

Nerve Injury

Pain and paresthesias in the inguinal region were not uncommon after the early reports of laparoscopic hernia repair because of the initial unfamiliarity of the course of these nerves and the greater number of tacks to fixate the mesh (10). Careful attention to the anatomy of these nerves and reduction in the number of tacks used to fix the mesh to the transversalis fascia have decreased the incidence of these nerve injuries.

Avoidance of tack placement below the iliopubic tract and constant palpation of the tacker against the abdominal wall will ensure correct placement of tacks. However, if nerve entrapment occurs in the immediate postoperative period, the patient should be brought back to the operating room for tack removal.

Table 3 shows the nerves involved in hernia repair and the potential postoperative symptoms of nerve injury.

Visceral Injury

The transabdominal preperitoneal repair has the potential of injuring bowel and vascular structures during initial trocar placement as well as during hernia repair. It is imperative that appropriate patient selection be used when choosing a laparoscopic repair. Patients with multiple prior laparotomies or previous pelvic surgery may be better served through open repair. During totally extraperitoneal repair, there is also the potential for bladder injury with initial balloon dissection. A bowel obstruction can occur if the peritoneum is opened during a totally extraperitoneal repair and not recognized, and the bowel herniates into the preperitoneal space during desufflation.

Avoidance of tack placement below the iliopubic tract and constant palpation of the tacker against the abdominal wall will ensure correct placement of tacks. However, if nerve entrapment occurs in the immediate postoperative period, the patient should be brought back to the operating room for tack removal.

TABLE 2 ■ Postoperative Complications

Nonrepair related:	Urinary retention MI, UTI, DVT, etc.
Repairs related:	Seroma Hematoma
Neuralgias:	Nerve entrapment Nerve injury
Groin pain:	Early (transient) Late (chronic)
Testicular symptoms:	Pain Ischemia
Trocar site problems:	Bleeding, Hernia, Infection Wound infection
Mesh complications:	Infection Late rejection

Abbreviations: MI, myocardial infarction; UTI, urinary tract infection; DVT, deep venous thrombosis.

- If the bowel is injured during laparoscopic hernia repair, the bowel should be repaired and mesh placed using an open approach to prevent mesh infection.
- Bladder injury may be avoided carefully directing the balloon above the pubic tubercle with an empty bladder.
- Patients with previous retropubic surgery should not be offered a totally extraperitoneal repair.
- Bowel herniates into the preperitoneal space during desufflation is prevented by closing all peritoneal openings with an endoloop and desufflating under careful visualization.

During transabdominal preperitoneal repair, it is also important to completely close the peritoneum to prevent exposure of the mesh to bowel. Polypropylene mesh exposed to bowel can lead to erosion of the biomaterial into bowel. If the peritoneum does not cover the mesh in its entirety, then an alternative biomaterial must be used to decrease the risk of adhesion and fistula formation.

Although both transabdominal preperitoneal and totally extraperitoneal repairs offer excellent results in regard to hernia repairs, there appears to be a trend toward more surgeons performing the totally extraperitoneal repair. This may be related to the decreased risk of bowel and vascular injury seen during totally extraperitoneal surgery (11). However, the incidence of complications is directly related to the surgeon's experience with the type of laparoscopic repair and therefore should the surgery.

TABLE 3 ■ Inguinal Nerves

Nerve	Function	Preventing injury
Ileohypogastric	Sensation along inguinal crease	Avoid deep tack placement, important to provide bimanual palpation
Ileoinguinal	Sensation over the base of the penis	As for ileohypogastric
Lateral femoral cutaneous	Sensation for entire lateral thigh	Avoid tacks below the iliopubic tract lateral to iliac vessels (triangle of "pain")
Genitofemoral	Genital branch is sensation of scrotum and adjacent thigh; Femoral branch innervates proximal anterior thigh	As for lateral femoral cutaneous
Femoral	Muscular innervation of leg	Avoid dissecting deep to the femoral vessels (triangle of "doom")

The most common causes of hernia recurrence are incomplete dissection and inadequate size of the mesh coverage.

Numerous studies have demonstrated that at least 2 to 3 cm of defect overlap is required, as well as the size of prosthesis being greater than 10 × 14 cm to prevent this type of failure.

Recurrences

Hernia recurrence remains the most reported and widely scrutinized aspect of herniorrhaphy. There are numerous causes of recurrences during laparoscopic hernia repair, with the majority being technical failures (Table 4).

The most common causes of hernia recurrence are incomplete dissection and inadequate size of the mesh coverage (12,13).

When performing a laparoscopic hernia repairs, it is imperative that all potential defect sites as well as cord lipomas be investigated. Failure to identify and remove a cord lipoma may let the patient believe a hernia still exists (14). A large piece of mesh is required to cover all potential sites including the direct, indirect, and femoral space.

Numerous studies have demonstrated that at least 2 to 3 cm of defect overlap is required, as well as the size of prosthesis being greater than 10 × 14 cm to prevent this type of failure (9,11,15).

Other causes of recurrences include mesh migration, shrinkage, and poor fixation (10). Fixation of the mesh is currently debatable. Two studies have shown no difference in recurrence rates when a large piece of mesh is used to cover the defect without fixation tacks (9,16). The most important finding in both studies is that a large piece of mesh was required for the repair.

TABLE 4 ■ Causes of Recurrences

Learning curve	
Incomplete dissection:	Missed hernia
	Missed lipoma
Mesh:	Inadequate reduction of sac
	Inadequate size of mesh
	Inadequate overlap of defect
	Poor fixation
	Mesh displacement:
	Hematoma
	Seroma
	Migration
	Rolling of mesh
	Shrinkage

TABLE 5 ■ Recurrence Rates of Laparoscopic Herniorrhaphy

Study	Technique	No. of repairs	Follow-up (mo)	Recurrence rates (%)
Aeberhard et al. (Surg Endosc)	TEP	1605	12	1.3
Felix et al. (Surg Endosc)	TAPP/TEP	1423	42	0.4
Frankum et al. (Am Surg)	TEP	779	30	0.2
Knook et al. (Surg End)	TEP	256	40	5
O'Dwyer et al. (Lancet)	TEP/TAPP	468	12	1.9
Sayed et al. (Surg Endosc)	TAPP	536	17	0.6

Abbreviations: TAPP, transabdominal preperitoneal repair; TEP, totally extraperitoneal.

SUMMARY

- The last decade has witnessed multiple studies comparing the laparoscopic hernia repair to the open approach.
- Over 70-randomized controlled trials, four meta-analyses, and two systematic reviews looking at inguinal hernia repairs have been published. These studies have demonstrated the safety and comparable recurrence rates of laparoscopic herniorrhaphy to the open technique (Table 5).
- The majority of studies show decreased postoperative pain and a faster return to preoperative activity with the laparoscopic repair (17-19).
- The operative time and overall cost has been shown to be higher in the laparoscopic repair. However, the majority of studies look at direct costs, such as operative equipment and operative time and not overall costs, such as time lost from work and increased pain medication requirements.
- Choosing reusable equipment, less fixation devices, and simple biomaterial meshes may decrease overall costs and allow for an increase in laparoscopic herniorrhaphy.

REFERENCES

1. Ger R. The management of certain abdominal herniae by intra-abdominal closure of the neck of the sac. *Ann R Coll Surg Engl* 1982; 64:342-344.

2. Bogojavalensky S. Laparoscopic treatment of inguinal and femoral hernia (video presentation). 18th Annual Meeting of the American Association of Gynecological Laparoscopists, Washington, D.C., 1989.

3. Salerno GM, Fitzgibbons RJ, Filipi C. Laparoscopic inguinal hernia repair. In: Zucker KA, ed. *Surgical Laparoscopy*. St. Louis: Quality Medical Publishing, 1991:281-293.

4. Toy FK, Smoot RT. Toy-Smoot laparoscopic hernioplasty. *Surg Laparosc Endosc* 1991; 1:151-155.

5. Schultz L, Graber J, Pietrafitta J, et al. Laser laparoscopic herniorrhaphy: a clinical trial, preliminary results. *J Laparoendosc Surg* 1990; 1:41–45.
6. Arregui ME. Preperitoneal repair of direct inguinal hernia with mesh. Presented At Advanced Laparoscopic Surgery: The International Experience, Indianapolis, May 20–22, 1991.
7. Neumayer L, Giobbie-Hurder A, Jonasson D, et al. Open mesh versus laparoscopic mesh repair of inguinal hernia. *N England J Med* 2004; 350(18):1819–1827.
8. Stoppa RE. The treatment of complicated groin and incisional hernias. *World J Surg* 1989; 13(5):545–554.
9. Ferzli GS, Frezza EE, Pecoraro AM Jr., et al. Prospective randomized study of stapled versus mesh in laparoscopic preperitoneal inguinal hernia repair. *J Am Coll Surg* 1999; 188(5):461–465.
10. Phillips EH, Arregui M, Carroll BJ, et al. Incidence of complications following laparoscopic hernioplasty. *Surg Endosc* 1995; 9:16–21.
11. Felix EL, Michas CA, Gonzalez MH Jr. Laparoscopic hernioplasty transabdominal preperitoneal vs. totally extraperitoneal. *Surg Endosc* 1995; 9(9):984–989.
12. Felix EL, Harbertson N, Vartanian S. Laparoscopic hernioplasty: significant complications. *Surg Endosc* 1999; 13(4):328–331.
13. Fitzgibbons RJ, et al. Laparoscopic inguinal herniorrhaphy: results of a multicenter trial. *Ann Surg* 1995; 212:3.
14. Gersin KS, et al. Missed lipoma of the spermatic cord. A pitfall of transabdominal preperitoneal laparoscopic hernia repair. *Surg Endosc* 1999; 13:6.
15. Felix EL, Michas CA, Gonzalez MH. Laparoscopic hernioplasty: why does it work? *Surg Endosc* 1997; 11:36.
16. Smith AI, et al. Stapled and nonstapled laparoscopic transabdominal preperitoneal (transabdominal preperitoneal) inguinal hernia repair: a prospective randomized trial. *Surg Endosc* 1999; 13:8.
17. Farinas LP, Griffen FD. Cost containment and totally extraperitoneal laparoscopic herniorrhaphy. *Surg Endosc* 2000; 14:37.
18. Kozol R, et al. A prospective, randomized study of open vs. laparoscopic inguinal hernia repair: an assessment of postoperative pain. *Arch Surg* 1997; 132:292.
19. Payne JH, et al. Laparoscopic or open inguinal herniorrhaphy: randomized prospective trial. *Arch Surg* 1994; 129:973.

SECTION

V

LAPAROSCOPIC UROLOGIC ONCOLOGY

LAPAROSCOPIC ADRENALECTOMY FOR MALIGNANCY

Alireza Moinzadeh

Section of Laparoscopic and Robotic Surgery, Glickman Urological Institute, Cleveland Clinic Foundation, Cleveland, Ohio, U.S.A.

- INTRODUCTION
- ADRENALECTOMY FOR SOLITARY METASTASIS
- ADRENALECTOMY FOR ADRENOCORTICAL CARCINOMA
- CONTROVERSY ABOUT THE ROLE OF LAPAROSCOPY FOR MALIGNANCY
- LAPAROSCOPY FOR MALIGNANT ADRENAL LESIONS
- GENERAL GUIDELINES FOR SURGERY
- LAPAROSCOPIC ADRENALECTOMY FOR MALIGNANCY: CAVEATS
- SUMMARY
- REFERENCES

Currently, laparoscopic adrenalectomy is the gold standard for benign medical adrenal masses. However, the role of laparoscopy for malignant adrenal disease including primary adrenocortical carcinoma (adrenocortical carcinoma) and metastatic lesions is more controversial.

INTRODUCTION

With improved radiographic imaging, adrenal masses are more frequently detected following a treated primary malignancy or noted incidentally as part of an unrelated work-up. Along with improvements in diagnostic techniques, laparoscopy has emerged as a formidable option for various urologic malignancies.

Currently, laparoscopic adrenalectomy is the gold standard for benign medical adrenal masses (1,2). However, the role of laparoscopy for malignant adrenal disease including primary adrenocortical carcinoma and metastatic lesions is more controversial.

ADRENALECTOMY FOR SOLITARY METASTASIS

Metastases to the adrenal gland are more common than primary adrenocortical carcinoma. Such metastases tend to originate from pulmonary, renal, mammary, and gastrointestinal carcinomas (3). Adrenal metastasis has been noted in 10% to 27% of autopsies of patients with known malignancy (4,5). Patients with metastasis to the adrenal gland commonly have disseminated cancer. Rarely does the clinician diagnose a patient suspected of harboring an isolated adrenal metastasis. The management of such a patient presents a challenging dilemma. Having already undergone definitive treatment for the primary malignancy, the physician is faced with counseling the patient on the best treatment strategy for the presumed metastasis. Unfortunately, the treatment of such lesions is controversial. Although some reports support the surgical treatment of isolated adrenal metastases with long-term survivors, identifying the most suitable surgical candidate is less clear. The ideal study would involve a prospective comparison of patients with adrenal metastasis randomized to receive surgical treatment or observation or another form of treatment (chemotherapy/radiation). However, the accrual period of such a study would be extraordinarily long given the rare subset of patients in question. As such, clinical decisions must rely on larger retrospective studies, addressing a heterogeneous group of patients with a wide array of primary malignancies that have metastasized to the adrenal gland.

Several studies supporting the role of adrenalectomy for isolated adrenal metastasis have been reported. Several case reports have highlighted survival for solitary adrenal metastasis from colorectal cancers in carefully selected patients (6–8). These case reports consist of patients with solitary adrenal metastasis noted after primary colorectal resection. With intermediate follow-up, a survival advantage has been noted in patients with solitary adrenal metastasis of primary colorectal surgery undergoing adrenalectomy. Interestingly, the serum carcinoembryonic antigen was found to be elevated in patients with colorectal recurrence in the adrenal gland, although this elevation has not been noted in all reports (9).

Patients with metastatic lung cancer typically have a poor prognosis. Only 7% of patients present with solitary metastasis (10). Although still controversial, a survival advantage has been noted in patients with solitary adrenal metastasis from a non-small cell lung malignancy, whether synchronous or metachronous (11–15). These published series, with relatively small numbers and intermediate follow-up, have reported survival in this very select subset of patients. Luketich and Burt (11) compared the median survival of eight patients with isolated adrenal metastases from lung cancer who underwent adrenalectomy and chemotherapy with six patients who underwent chemotherapy alone. The median survival in the surgical group was found to be significantly increased (31 months) versus the chemotherapy alone group (8.5 months, $p = 0.03$). In another study, survival was noted in a multicenter trial of 43 patients with isolated adrenal metastases (32 synchronous, 11 metachronous) for patients with primary non-small cell lung cancer who underwent adrenalectomy (12). Median overall survival was 11 months, with three patients surviving over five years.

The survival of patients with metastatic renal cell carcinoma and multiple metastatic sites is poor. Although the overall number of patients is limited, those with solitary metastatic sites have been shown to possibly benefit from resection of the metastatic site, in particular, solitary metastasis to the lung (16–20). Lau et al. reported the largest series of 11 patients at Mayo Clinic with contralateral adrenal metastasis from renal cell carcinoma who underwent adrenalectomy. In this series, 2 of 11 patients (18%) were alive at last follow-up. Seven patients died at a mean of 3.9 years after adrenalectomy. Their review of the literature reveals that of 56 patients treated surgically for adrenal metastasis from RCC, 27 (48%) patients showed no evidence of disease on last follow-up. The median follow-up time is unfortunately not provided.

ADRENALECTOMY FOR ADRENOCORTICAL CARCINOMA

Adrenocortical carcinoma is a rare disease with estimated 75 to 115 new cases a year in the United States (21). The staging system commonly used for adrenocortical carcinoma is shown in Table 1 (22). In this staging system, stages I and II include tumors localized to the adrenal gland, while stages, III and IV include tumors with local or distant spread, respectively. In a review of 602 patients from seven institutions, Ng and Libertino (23) found five-year survival based on stage as: stage I, 30% to 45%; stage II, 12.5% to 57%; stage III, 5% to 18%; and stage IV, 0%. Median survival was shorter in patients with unresectable tumors (3–9 months) as compared to those with complete surgical resection (13–28 months).

Stage appears to be one of the best prognostic indicators of survival. Specifically, those with localized disease (stage I or II) tend to have the best outcome after surgical resection (24,25).

The primary therapy for adrenocortical carcinoma is surgical en bloc removal of the tumor. However, even with complete resection, local recurrence is seen in 35% to 85% of reported cases (23).

The primary therapy for adrenocortical carcinoma is surgical en bloc removal of the tumor. However, even with complete resection, local recurrence is seen in 35% to 85% of reported cases.

TABLE 1 ■ Staging System for Adrenocortical Carcinoma

<i>Tumor characteristics, disease extent:</i>	
T1	Tumor ≤5 cm, no capsule invasion
T2	Tumor >5 cm, no capsule invasion
T3	Tumor with invasion into periadrenal fat
T4	Tumor invading adjacent organs
N0	Negative lymph nodes
N1	Positive regional lymph nodes
M0	No metastases
M1	Distant metastases
<i>Staging categories:</i>	
I	T1, N0, M0
II	T2, N0, M0
III	T1–2, N1, M0; T3, N0, M0
IV	Any T, any N, M1; T3–4, N1, M0
Source: From Ref. 22.	

CONTROVERSY ABOUT THE ROLE OF LAPAROSCOPY FOR MALIGNANCY

Although the role of laparoscopy for benign adrenal disease is currently defined, laparoscopic excision of malignant renal tumors of the adrenal gland remains controversial.

It is believed that laparoscopy may have been responsible for intraperitoneal tumor spread or local recurrence. However, definitive proof for this concern is not provided. More importantly, the innate aggressive nature of these cancers and the techniques involved in their removal are not addressed.

Although the role of laparoscopy for benign adrenal disease is currently defined, laparoscopic excision of malignant renal tumors of the adrenal gland remains controversial.

The concern about laparoscopy for adrenal malignancy stems from seven individual case reports published in the last several years (Table 2) (26–32). These single case reports challenge the adequacy of adrenal resection for adrenal glands with a primary adrenal malignancy or solitary metastatic site. In each case report, the authors describe local recurrence or peritoneal carcinomatosis shortly after (4–14 months) routine laparoscopic adrenalectomy. Two of the case reports consist of metastatic lung cancer to the adrenal gland. The other five case reports describe an initial adrenal mass thought to be benign after initial histopathologic analysis and only later diagnosed as malignancy when clinical recurrence was noted.

It is believed that laparoscopy may have been responsible for intraperitoneal tumor spread or local recurrence. However, definitive proof for this concern is not provided. More importantly, the innate aggressive nature of these cancers and the techniques involved in their removal are not addressed.

These case reports raise two broad concerns about laparoscopic excision of malignant organs, namely, (i) port-site metastasis, and (ii) local recurrence/carcinomatosis. As regards port-site metastasis, Tsivian and Sidi reported the relatively rare occurrence in 11 cases (0.6%) in over 2000 urologic laparoscopic cases reviewed (34).

TABLE 2 ■ Literature Review: Single Case Reports Questioning the Safety of Laparoscopic Adrenalectomy in the Setting of Malignancy

Author and year (Ref.)	Age/sex	Side	Tumor size (cm)	History	Laparoscopic approach	Comment about surgery	Time to recurrence (mo)	Location of recurrence	Initial specimen pathology	Final reoperation pathology
Ushiyama et al., 1997 (26)	50/F	L	5	Cushing's syndrome	N/A	Uncomplicated case	14	Local recurrence, carcinomatosis	Benign adenoma	ACC
Suzuki et al., 1997 (27)	62/M	L	5.5	Lung cancer (adenocarcinoma)	N/A	Conversion to open surgery with en-block removal of part of kidney	8	"Multiple metastasis"	Poorly differentiated lung cancer	Poorly differentiated lung cancer
Hofle et al., 1998 (28)	43/F	L	3	Cushing's syndrome	N/A	Uncomplicated case	4	Local recurrence, carcinomatosis	"Undetermined" malignant potential	Could not confirm ACC as tumor was fragmented
Hamoir et al., 1998 (29)	25/F	R	12	Secondary amenorrhea and virilization	N/A	"Difficult and bloody" converted to open procedure	6	Carcinomatosis	Benign	ACC
Deckers et al., 1999 (30)	74/M	R	2.7	Conn's syndrome	Trans	Partial adrenalectomy performed	10	Carcinomatosis	Benign	Same features as initial tumor, with increased cellularity and necrosis consistent with ACC
Foxius et al., 1999 (31)	74/M	R	2.7	Conn's syndrome	Trans	Uncomplicated case	6	Local recurrence, carcinomatosis	Benign	Identical to initial tumor, deemed ACC based on clinical metastasis
Chen et al., 2002 (32)	55/F	L	2.5	Lung cancer (non small cell)	Trans	Intraoperatively, mass was noted to have increased to 8 × 6 cm. Specimen was removed intact in entrapment sack	5	Carcinomatosis including port-site recurrence	Non small cell lung cancer	Non small cell lung cancer

Abbreviations: R, right; L, left; Trans, transperitoneal; ACC, adrenal cell carcinoma; N/A, not available.

Source: From Ref. 33.

The most significant risk factors in terms of port-site metastasis included the biological aggressive nature of the tumor, non-placement of the tumor in a specimen bag, violation of the tumor boundary, and ascites.

A carcinomatosis, two hypothetical concerns specific to the laparoscopic approach have been expressed including the dispersion of the malignant cells by the peritoneal CO₂ gas and the possibility of the immunosuppressive effects of pneumoperitoneum.

The most significant risk factors in terms of port-site metastasis included the biological aggressive nature of the tumor, non-placement of the tumor in a specimen bag, violation of the tumor boundary, and ascites.

Port-site metastatic potential has been addressed in animal models as well. It is hypothesized that the escape of potential tumor filled pneumoperitoneum gas around loose fitted trocars may produce a “chimney effect” leading ultimately to port-site metastasis. Tseng et al. demonstrated the increased tumor growth rate in the rat model at port sites where there was a leak of pneumoperitoneum (478 mg of tumor) versus a control group (153 mg, $p = 0.01$) (35). However, such occurrence has not been clinically validated. Ikramuddin et al. used a saline trap to capture the effluent gas of 35 patients who underwent elective laparoscopic procedures (36). Although 15 patients had malignancies, only two were found to have malignant cells in the effluent. Both of these patients had carcinomatosis detected at the beginning of the case. As such, the authors concluded the unlikely nature of cell aerosolization as a significant contributor to port-site metastasis. The various animal models used thus far must be called into question (37). It may not be valid to extrapolate from such studies founded on the use of foreign malignancies remote from the usual primary site, which are introduced into the abdominal cavity.

With regard to carcinomatosis, two hypothetical concerns specific to the laparoscopic approach have been expressed including the dispersion of the malignant cells by the peritoneal CO₂ gas and the possibility of the immunosuppressive effects of pneumoperitoneum (38).

There are a limited number of basic science manuscripts using animal models that specifically attempt to address these concerns. In one such study using a rat model, a suspension of adenocarcinoma cells was placed in the abdomen with or without insufflation and compared to a third group with laparotomy (39). The animals were sacrificed six days post-tumor implantation. The abdomen was divided in six quadrants and gross examination was performed to score tumor density in each quadrant. The group with CO₂ insufflation had more disseminated cancer spread when compared to the gasless group or the laparotomy group. However, validation of these results has been mixed. Using a murine model, Allendorf et al. demonstrated an increased number ($p = 0.04$) and two times larger sized ($p < 0.01$) tumor carcinomatosis at peritoneal sites in the laparotomy group when compared to the insufflation group. The same authors have further defined the seeming protective effects of pneumoperitoneum in preventing carcinomatosis. They propose that a relative increased T-cell function associated with insufflation may lead to protection against cancer spread. This advantage may be lost with conventional laparotomy (40).

LAParoscopy FOR MALIGNANT ADRENAL LESIONS

To date, there have only been a limited number of series dealing with adrenalectomy for malignancy (Table 3) (33,41–47). These series, from experienced laparoscopic surgeons from around the world, present small numbers of patients with relatively short follow-up. Nonetheless, certain inferences regarding the safety of laparoscopy for malignant lesions may be drawn. As stated previously, carcinomatosis and port-site metastasis are major concerns leading to reservations about laparoscopy for adrenal malignancies. In this group of 98 patients, only one case of carcinomatosis (one case in the authors' series) was documented. In addition, no cases of port-site metastases were noted in any of the series.

Our review of 31 patients (33 procedures) with malignant adrenal lesions is the largest published experience to date (33). The cohort comprised metastatic cancer ($n = 26$) and primary adrenal malignancy ($n = 7$). Mean adrenal tumor size was 5 cm (range, 1–10 cm). Mean operative time was three hours with estimated blood loss 258 cc and a mean hospital stay of 2.1 days. Of the 33 procedures, one was electively converted to open surgery. There was no operative mortality. The metastatic group consisted most commonly of RCC ($n = 13$), colonic malignancy ($n = 6$), and lung cancer ($n = 5$). With a median follow-up of 26 months, 17 (55%) were alive, of whom 15 (48%) had no evidence of disease. Five-year actuarial survival was 40%. Seven (23%) patients had local recurrence with no cases of port-site metastasis. Local recurrence was associated with an inferior survival when compared to no local recurrence ($p = 0.016$). Survival did not correlate to a patient's age, gender, tumor size, tumor side, or surgical approach. Unlike prior reports where a disease-free interval of more than six months was associated with overall improved survival (46,48), similar analysis of data in our series did not reveal a survival benefit.

The reader may note the variance in outcome when comparing Table 2 (case reports) to Table 3 (contemporary series supporting laparoscopy for adrenal malignancy). This

TABLE 3 ■ Literature Review: Series of Laparoscopic Adrenalectomy for Cancer^a

Study (Ref.)	No. of patients	Follow-up (mo)	Comments
Heniford et al., 1999 (41)	11	8.3 (mean)	10 of 11 patients (91%) disease free
Valeri et al., 2001 (42)	6	8.6 (mean)	3 of 6 patients (50%) disease free
Henry et al., 2002 (43)	6	27.5 median	All patients with ACC, 5 of 6 patients (93%) disease free
Kebebew et al., 2002 (44)	18	39.6 (mean)	9/13 (69%) patients with metastatic disease to the adrenal gland disease free; 2/5 patients with primary ACC (40%) disease free
Lombardi et al., 2003 (45)	9	17 (mean)	9 of 11 patients (82%) disease free; 1 died of unrelated cause
Sarela et al., 2003 (46)	11	21 (median)	~60% survival. Comparison of 11 laparoscopic adrenalectomy with 20 open radical adrenalectomies. No difference noted in terms of overall survival
Feliciotti et al., 2003 (47)	6	19.5 (mean) for 2 patients died; 7 (mean) for 4 patients alive	4 of 6 patients (67%) disease free
Moinzadeh and Gill	31	26 (median)	13 of 31 patients (42%) disease free

^aOnly series with 5 or more cases are included.
Abbreviation: ACC, adrenal cell carcinoma.
Source: From Ref. 33.

discrepancy may be attributed to several factors. Solitary metastases of the adrenal gland cover a broad range of primary malignancies. Each specified cancer may have its own unique natural history and innate aggressiveness. With an adrenal metastasis, all the cancers in question have demonstrated the ability to metastasize; therefore, placing them in a more aggressive category. An overall limited survival with loco-regional recurrence should, therefore, not be surprising. The overall survival outcomes in Table 3 appear to compare favorably to the open series of adrenalectomy for malignancy presented earlier in this chapter.

With regard to adrenocortical carcinoma, the overall five-year survival after open surgery has been reported to be 25% (49). Furthermore, in a series of 179 patients having undergone open adrenalectomies, Bellantone et al. documented 52 patients (37%) with local recurrence (50). These data appear to compare favorably to available laparoscopic series, albeit small numbers of cases with the latter. Henry et al. (43) presented five of six patients with ACC having undergone laparoscopic excision with no evidence of disease at a median follow-up of 27.5 months. In our series, of the six patients with adrenocortical carcinoma, three (50%) were alive at a median follow-up of 21 months. Two patients had no evidence of disease, and one was undergoing chemotherapy.

GENERAL GUIDELINES FOR SURGERY

The technique of laparoscopic adrenalectomy has previously been outlined. Additional technical caveats are worth highlighting.

LAPAROSCOPIC ADRENALECTOMY FOR MALIGNANCY: CAVEATS

- All patients should have preoperative workup to rule out the possibility of multiple metastatic sites.
- Currently, the most important preoperative decision for successful postoperative outcome is patient selection.
- Our current contraindications for a laparoscopic approach include peri-adrenal tumor infiltration seen on preoperative computed tomography scan or a known renal vein/inferior vena cava tumor thrombus.
- Although size per se is not an absolute contraindication, tumor size >10 cm leading to a decreased working space, is probably best handled with an open approach.
- As en bloc radical excision should be the standard for potential surgical cure, the threshold for open conversion should be low. This philosophy ensures that basic principles of oncologic surgery are not compromised for the sake of performing the procedure laparoscopically.
- Technical expertise for multiple laparoscopic approaches (transperitoneal, retroperitoneal, and transthoracic) affords the surgeon additional options of access in patients with prior abdominal or retroperitoneal surgery (51).

SUMMARY

- With the increasing publications in support of laparoscopic adrenalectomy for malignancy, the controversy may ultimately end.
- Initial laparoscopic results indicate equivalent survival data with open surgical series.
- Patient selection, sound surgical judgment and technique are paramount for acceptable oncologic results.
- Concerns about laparoscopic excision of malignant organs, e.g., laparoscopic adrenalectomy includes (i) port-site metastasis and (ii) local recurrence/carcinomatosis.
- Further follow-up and additional experience is required prior to definitive conclusions regarding this topic.

REFERENCES

1. Smith CD, Weber CJ, Amerson JR. Laparoscopic adrenalectomy: new gold standard. *World J Surg* 1999; 23:389.
2. Sung GT, Gill IS. Laparoscopic adrenalectomy. *Semin Laparosc Surg* 2000; 7:211.
3. Bullock WK, Hirst AE Jr. Metastatic carcinoma of the adrenal. *Am J Med Sci* 1953; 226:521.
4. Abrams H, Spiro R, Goldstein N. Metastasis in carcinoma: analysis of 1000 autopsied cases. *Cancer* 1950; 3:74.
5. Willis R. *Pathology of Tumors*. St. Louis: Mosby, 1948:178–184.
6. Katayama A, Mafune K, Makuuchi M. Adrenalectomy for solitary adrenal metastasis from colorectal carcinoma. *Jpn J Clin Oncol* 2000; 30:414.
7. Fujita K, Kameyama S, Kawamura M. Surgically removed adrenal metastasis from cancer of the rectum. Report of a case. *Dis Colon Rectum* 1988; 31:141.
8. Watatani M, Ooshima M, Wada T, et al. Adrenal metastasis from carcinoma of the colon and rectum: a report of three cases. *Surg Today* 1993; 23:444.
9. Murakami S, Terakado M, Hashimoto T, Tsuji Y, Okubo K, Hirayama R. Adrenal metastasis from rectal cancer: report of a case. *Surg Today* 2003; 33:126.
10. Albain KS, Crowley JJ, LeBlanc M, Livingston RB. Survival determinants in extensive-stage non-small-cell lung cancer: the Southwest Oncology Group experience. *J Clin Oncol* 1991; 9:1618.
11. Luketich JD, Burt ME. Does resection of adrenal metastases from non-small cell lung cancer improve survival? *Ann Thorac Surg* 1996; 62:1614.
12. Porte H, Siat J, Guibert B, et al. Resection of adrenal metastases from non-small cell lung cancer: a multicenter study. *Ann Thorac Surg* 2001; 71:981.
13. Ambroggi V, Tonini G, Mineo TC. Prolonged survival after extracranial metastasectomy from synchronous resectable lung cancer. *Ann Surg Oncol* 2001; 8:663.
14. Abdel-Raheem MM, Potti A, Becker WK, Saberi A, Scilley BS, Mehdi SA. Late adrenal metastasis in operable non-small-cell lung carcinoma. *Am J Clin Oncol* 2002; 25:81.
15. Schuchert MJ, Luketich JD. Solitary sites of metastatic disease in non-small cell lung cancer. *Curr Treat Options Oncol* 2003; 4:65.
16. Kierney PC, van Heerden JA, Segura JW, Weaver AL. Surgeon's role in the management of solitary renal cell carcinoma metastases occurring subsequent to initial curative nephrectomy: an institutional review. *Ann Surg Oncol* 1994; 1:345.
17. O'Dea MJ, Zincke H, Utz DC, Bernatz PE. The treatment of renal cell carcinoma with solitary metastasis. *J Urol* 1978; 120:540.
18. Lau WK, Zincke H, Lohse CM, Cheville JC, Weaver AL, Blute ML. Contralateral adrenal metastasis of renal cell carcinoma: treatment, outcome and a review. *BJU Int* 2003; 91:775.
19. Barnes RD, Abratt RP, Cant PJ, Dent DM. Synchronous contralateral adrenal metastasis from renal cell carcinoma: a 7 year survival following resection. *Aust N Z J Surg* 1995; 65:540.
20. Stein A, Mecz Y, Sova Y, Lurie M, Lurie A. Synchronous and metachronous contralateral adrenal metastases from primary renal cell carcinoma. *Urol Int* 1997; 58:58.
21. Third National Cancer Survey. National Cancer Institute Monogram, 1975; 41:1.
22. Norton J. *Cancer Principles & Practice of Oncology*. Philadelphia: JB Lippincott Co., 1997:1659.
23. Ng L, Libertino JA. Adrenocortical carcinoma: diagnosis, evaluation and treatment. *J Urol* 2003; 169:5.
24. Wajchenberg BL, Albergaria Pereira MA, Medonca BB, et al. Adrenocortical carcinoma: clinical and laboratory observations. *Cancer* 2000; 88:711.
25. Luton JP, Cerdas S, Billaud L, et al. Clinical features of adrenocortical carcinoma, prognostic factors, and the effect of mitotane therapy. *N Engl J Med* 1990; 322:1195.
26. Ushiyama T, Suzuki K, Kageyama S, Fujita K, Oki Y, Yoshimi T. A case of Cushing's syndrome due to adrenocortical carcinoma with recurrence 19 months after laparoscopic adrenalectomy. *J Urol* 1997; 157:2239.
27. Suzuki K, Ushiyama T, Mugiya S, Kageyama S, Saisu K, Fujita K. Hazards of laparoscopic adrenalectomy in patients with adrenal malignancy. *J Urol* 1997; 158:2227.
28. Hofle G, Gasser RW, Lhotka K, Janetschek G, Kreczy A, Finkenstedt G. Adrenocortical carcinoma evolving after diagnosis of preclinical Cushing's syndrome in an adrenal incidentaloma. A case report. *Hormone Res* 1998; 50:237.
29. Hamoir E, Meurisse M, Defechereux T. Is laparoscopic resection of a malignant corticoadrenaloma feasible? Case report of early, diffuse and massive peritoneal recurrence after attempted laparoscopic resection. *Annales de Chirurgie* 1998; 52:364.
30. Deckers S, Derdelinckx L, Col V, Hamels J, Maiter D. Peritoneal carcinomatosis following laparoscopic resection of an adrenocortical tumor causing primary hyperaldosteronism. *Hormone Res* 1999; 52:97.

31. Foxius A, Ramboux A, Lefebvre Y, Broze B, Hamels J, Squifflet J. Hazards of laparoscopic adrenalectomy for Conn's adenoma. When enthusiasm turns to tragedy [comment]. *Surg Endosc* 1999; 13:715.
32. Chen B, Zhou M, Cappelli MC, Wolf JS Jr. Port site, retroperitoneal and intra-abdominal recurrence after laparoscopic adrenalectomy for apparently isolated metastasis. *J Urol* 2002; 168:2528.
33. Moinzadeh A, Gill IS. Laparoscopic radical adrenalectomy for malignancy in 31 patients. *J Urol* 2005; 173:519–525.
34. Tsivian A, Sidi AA. Port site metastases in urological laparoscopic surgery. *J Urol* 2003; 169:1213.
35. Tseng LN, Berends FJ, Wittich P, et al. Port-site metastases. Impact of local tissue trauma and gas leakage. *Surg Endosc* 1998; 12:1377.
36. Ikramuddin S, Lucas J, Ellison EC, Schirmer WJ, Melvin WS. Detection of aerosolized cells during carbon dioxide laparoscopy. *J Gastrointest Surg* 1998; 2:580.
37. Basu A, Wexner SD, Bergamaschi R. Validity of current experimental evidence on laparoscopic surgery for colorectal cancer. *Surg Endosc* 2003; 17:179.
38. Lefor AT. The role of laparoscopy in the treatment of intra-abdominal malignancies. *Cancer J* 2000; 6(suppl 2):S159.
39. Mathew G, Watson DI, Rofo AM, Ellis T, Jamieson GG. Adverse impact of pneumoperitoneum on intraperitoneal implantation and growth of tumour cell suspension in an experimental model. *Aust N Z J Surg* 1997; 67:289.
40. Allendorf JD, Bessler M, Horvath KD, Marvin MR, Laird DA, Whelan RL. Increased tumor establishment and growth after open vs laparoscopic surgery in mice may be related to differences in postoperative T-cell function. *Surg Endosc* 1999; 13:233.
41. Heniford BT, Arca MJ, Walsh RM, Gill IS. Laparoscopic adrenalectomy for cancer. *Semin Surg Oncol* 1999; 16:293.
42. Valeri A, Borrelli A, Presenti L, et al. Adrenal masses in neoplastic patients: the role of laparoscopic procedure. *Surg Endosc* 2001; 15:90.
43. Henry JF, Sebag F, Iacobone M, Mirallie E. Results of laparoscopic adrenalectomy for large and potentially malignant tumors. *World J Surg* 2002; 26:1043.
44. Kebebew E, Siperstein AE, Clark OH, Duh QY. Results of laparoscopic adrenalectomy for suspected and unsuspected malignant adrenal neoplasms. *Arch Surg* 2002; 137:948.
45. Lombardi CP, Raffaelli M, Boscherini M, et al. Laparoscopic adrenalectomy in the treatment of malignant adrenal lesions. *Tumori* 2003; 89:255.
46. Sarella AI, Murphy I, Coit DG, Conlon KC. Metastasis to the adrenal gland: the emerging role of laparoscopic surgery. *Ann Surg Oncol* 2003; 10:1191.
47. Feliciotti F, Paganini AM, Guerrieri M, et al. Laparoscopic anterior adrenalectomy for the treatment of adrenal metastases. *Surg Laparosc Endosc Percutan Tech* 2003; 13:328.
48. Kim SH, Brennan MF, Russo P, Burt ME, Coit DG. The role of surgery in the treatment of clinically isolated adrenal metastasis. *Cancer* 1998; 82:389.
49. Bodie B, Novick AC, Pontes JE, et al. The Cleveland Clinic experience with adrenal cortical carcinoma. *J Urol* 1989; 141:257.
50. Bellantone R, Ferrante A, Boscherini M, et al. Role of reoperation in recurrence of adrenal cortical carcinoma: results from 188 cases collected in the Italian National Registry for Adrenal Cortical Carcinoma. *Surgery* 1997; 122:1212.
51. Gill IS, Meraney AM, Thomas JC, Sung GT, Novick AC, Lieberman I. Thoracoscopic transdiaphragmatic adrenalectomy: the initial experience [comment]. *J Urol* 2001; 165:1875.

LAPAROSCOPIC RADICAL NEPHRECTOMY: TRANSPERITONEAL APPROACH

Michael Grasso III

*Department of Urology, St. Vincent's Catholic Medical Center,
New York, New York, U.S.A.*

- | | |
|---|---|
| <ul style="list-style-type: none"> ■ INTRODUCTION ■ INDICATIONS FOR SURGICAL INTERVENTION USING A TRANSPERITONEAL LAPAROSCOPIC APPROACH ■ CONTRAINDICATIONS TO LAPAROSCOPIC RADICAL NEPHRECTOMY ■ PREOPERATIVE EVALUATION ■ SURGICAL TECHNIQUE | <ul style="list-style-type: none"> Initial Intraoperative Steps and Patient Positioning Port Placement Schemes ■ CAVEATS Technical Surgical Steps ■ RESULTS ■ SUMMARY ■ REFERENCES |
|---|---|

INTRODUCTION

Since the first description of laparoscopic nephrectomy performed by Clayman et al. in 1990, there has been great enthusiasm for employing endoscopic techniques to treat renal disease processes (1). The natural progression from treating benign disease states to more complex malignancies has followed. In fact, in 2004, the majority of renal tumors are treated laparoscopically. The transperitoneal approach was the first and, by many accounts, the traditional approach in addressing renal tumors. Where there was debate in the past on whether an adequate cancer result could be obtained with laparoscopic technique, long-term follow-up has shown that laparoscopic intervention produces reproducible and acceptable results with regard to cancer control (2–7). Laparoscopic nephrectomy also results in decreased postoperative pain, a reduction in analgesic requirement, a decline in hospital stay, and a quicker overall recovery (2,6,8–10). The indications for performing a radical nephrectomy have also been refined. Many smaller lesions today are treated with laparoscopic partial nephrectomy with excellent long-term disease-free survival rather than proceeding with complete organ removal (11–14).

The indications for performing a laparoscopic radical nephrectomy include solid and complex cystic renal tumors that are not amenable to partial nephrectomy by size criteria, location, or multifocality. Larger lesions and those involving the main renal vessels represent technical challenges with a higher conversion rate to open surgery.

In the early published series of laparoscopic radical nephrectomy, a tumor size of 8 cm was a relative cutoff. In reality, larger lesions and, in fact, many complex and bulky lesions can be addressed laparoscopically (15).

There are many attractive aspects of laparoscopic nephrectomy in the setting of renal cell carcinoma. The majority of patients who present with this disease state are elderly with comorbidities including pulmonary and cardiovascular disease. With the absence of a large flank or abdominal incision, patients tend to recuperate faster and frequently there is less postoperative exacerbation of underlying diseases such as chronic obstructive pulmonary disease due to decreased postoperative requirement of narcotics.

In adults, there is no age limit for laparoscopic radical nephrectomy. It has become a standard therapy for the elderly and even the oldest patients presenting with an indication for surgical intervention being treated in this fashion.

INDICATIONS FOR SURGICAL INTERVENTION USING A TRANSPERITONEAL LAPAROSCOPIC APPROACH

There are two major techniques that are employed to remove a cancerous kidney laparoscopically. Firstly, the more traditional transperitoneal approach, where the retroperitoneum is exposed and opened, and the kidney and the contents of Gerota's

In the early published series of laparoscopic radical nephrectomy, a tumor size of 8 cm was a relative cutoff. In reality, larger lesions and, in fact, many complex and bulky lesions can be addressed laparoscopically.

In adults, there is no age limit for laparoscopic radical nephrectomy. It has become a standard therapy for the elderly and even the oldest patients presenting with an indication for surgical intervention being treated in this fashion.

fascia are brought into the peritoneal cavity during the surgical intervention. The other technique, which has gained increasing popularity, is a purely retroperitoneal dissection. There are certain relative contraindications and clinical presentations that lend themselves more to a retroperitoneal approach versus a transperitoneal approach.

In patients requiring prompt addressing of the renal hilum during dissection and in those patients with large anterior tumors where the transperitoneal dissection may be complicated by a tumor mass blocking the renal hilum, the retroperitoneal approach is superior. In addition, the retroperitoneal approach may be preferred in patients who have undergone prior intra-abdominal surgery, abdominal radiation therapy, or suffered from an intraperitoneal inflammatory state such as peritonitis.

The transperitoneal approach is preferential in patients with large renal tumors or renal lesions in an ectopic or horseshoe kidney.

Renal tumors, like other malignancies, can involve adjacent organs. Although a relatively uncommon occurrence, the surgeon must be aware of such a possibility and employ preoperative imaging to direct surgical intervention. If adjacent organs are involved, and specifically if the tumor appears to invade into the bowel or adjacent solid organs, and the surgeon feels that to obtain an adequate surgical margin adjacent organs may require resection, then a transperitoneal laparoscopic approach rather than a retroperitoneal endoscopic dissection is preferred. On the right side, the right colon and/or liver may be involved. On the left side, the spleen, the left colon, and the tail of the pancreas can also be involved. In all these settings, laparoscopic dissection via a transperitoneal approach is preferential.

The transperitoneal approach is preferential in patients with large renal tumors or renal lesions in an ectopic or horseshoe kidney.

CONTRAINDICATIONS TO LAPAROSCOPIC RADICAL NEPHRECTOMY

There are general contraindications for performing surgical intervention, and specific clinical states which would prohibit a transperitoneal laparoscopic radical nephrectomy. General contraindications include those patients who cannot tolerate a general anesthetic, those who present with an uncorrectable bleeding diathesis, or patients with underlying severe cardiovascular or pulmonary disease, who are thus not ideal surgical candidates. Relative contraindications to transperitoneal laparoscopic surgery include abdominal wall infection or suspected carcinomatosis and malignant ascites. Other specific and relative contraindications to a transperitoneal laparoscopic nephrectomy include multiple prior intra-abdominal procedures with severe adhesions, a history of severe peritonitis, or a diaphragmatic hernia. Patients with a history of cirrhosis with portal hypertension reflect another relative contraindication to transperitoneal laparoscopic radical nephrectomy. A retroperitoneal approach can be safely performed and is preferred in many of such patients.

In patients whose preoperative imaging suggests severe hilar adenopathy or encasement of the renal vasculature with tumor, there is a relative contraindication to laparoscopic nephrectomy. Finally, the presence of a renal vein or vena cava thrombus is a relative contraindication to laparoscopic surgical intervention. Although resection of a renal tumor with laparoscopic control of the renal vein distal to a tumor thrombus has been reported with a successful outcome, extensive vein thrombosis or extension into the vena cava should generally lead to open intervention, often with the assistance of vascular or cardiothoracic colleagues (16).

Severe hepato- or splenomegaly is a relative contraindication to transperitoneal laparoscopic nephrectomy. An enlarged or fatty liver, which must be retracted to allow access to the kidney, adds to the complexity of the overall procedure. In these patients, a retroperitoneal approach is preferred.

Obesity, however, is not a contraindication to laparoscopic nephrectomy. In fact, in obese patients whose renal pathology fits the criteria for laparoscopic nephrectomy, this endoscopic approach is the preferred treatment, although a modification of the standard port placement scheme may be required and excess adipose tissue can make dissection and landmark identification challenging (17).

Severe hepato- or splenomegaly is a relative contraindication to transperitoneal laparoscopic nephrectomy. An enlarged or fatty liver, which must be retracted to allow access to the kidney, adds to the complexity of the overall procedure. In these patients, a retroperitoneal approach is preferred.

PREOPERATIVE EVALUATION

As with any major open surgery, a complete history and physical exam, basic laboratory studies, electrocardiogram, and chest radiograph should be completed to identify any possible relative or absolute contraindications to laparoscopy. Additional studies may be necessary in patients with pulmonary or cardiac disease. In fact, such diseases

may be exacerbated secondary to the hypercarbia and acidosis noted with pneumoperitoneum, which may result from prolonged exposure to CO₂.

Prior to removal of the diseased kidney, the function of the contralateral kidney should be assessed. A serum creatinine level and visualization of normal contrast uptake and excretion on an imaging study are usually adequate. If renal insufficiency is present or the function of the kidney is in question, a nuclear medicine renal scan and creatinine clearance level may be helpful. Partial nephrectomy should be considered in patients with marginal renal function if technically feasible.

A metastatic evaluation is employed in all patients who present with renal tumors prior to radical nephrectomy. In patients undergoing transperitoneal laparoscopic radical nephrectomy, there is particular emphasis on the intra-abdominal organs, specifically to rule out concurrent processes or direct tumor extension to adjacent organs. Three-dimensional computed tomography or magnetic resonance imaging is often useful in directing surgical intervention. Attention to the renal hilum, in particular the size, location, and number of renal vessels is always helpful. Imaging may also define and quantify the extent of a renal vein thrombus. Three-dimensional computed tomography reconstruction produces clear images that can direct surgical technique. Magnetic resonance imaging with three-dimensional reconstruction and magnetic resonance angiography is often particularly useful in patients with iodine-based intravenous contrast intolerance or with renal functional insufficiency contraindicating iodine-based contrast load. If clinically indicated, a bone scan or imaging of the central nervous system can define widespread disease preoperatively and may direct the surgeon to observation or potential palliative intervention.

In preparation for surgery, patients are instructed to refrain from nonsteroidal anti-inflammatory drug and multivitamins including vitamin E due to increased risk of perioperative bleeding. Patients with large lesions and those with a heightened risk of bleeding based on a clinical presentation are offered the opportunity to bank their own blood or have donor-directed blood prepared. Mechanical bowel preparation is essential when performing a transperitoneal laparoscopic nephrectomy, because colon cleansing increases the ease of bowel retraction and mobilization. In patients where direct tumor extension into the bowel is suspected, an oral antibiotic and mechanical bowel preparation is implemented, so that an en bloc resection of adjacent organs can be performed with primary bowel repair if necessary.

SURGICAL TECHNIQUE

Initial Intraoperative Steps and Patient Positioning

The patient is brought into the operating theater and a general endotracheal anesthesia is administered.


Combined team efforts of the operating surgeon and the attending anesthesiology staff lead to the best outcomes. Complete muscle relaxation is essential. In addition, the anesthesiologist should be experienced with the management of anesthetic agents and the monitoring of the patient during complex laparoscopic procedures, which may take several hours to complete. CO₂ monitoring and relaying the extent of the hypercarbic state during the procedure to the surgeon are particularly important.

After induction of a general anesthetic, the bladder is drained with a standard indwelling Foley catheter. The stomach is decompressed with either an oral or nasogastric tube, and large-bore intravenous access should be obtained. Central venous access or arterial access is useful in complex patients or in those patients with comorbidities requiring special monitoring.

The patient is positioned in a standard complete flank position or at 45° to the operating table with the surgical side being elevated (Fig. 1). The majority of surgeons perform transperitoneal laparoscopic surgery in a full flank position. When the patient is placed in the full flank position, an axillary roll is employed. A pillow and padding are placed to protect the lower extremities and all bony prominences. Compression boots are applied to help preventing deep venous thrombosis of the lower extremities. The upper extremities, head, and neck are carefully padded and protected. The kidney rest elevator can be employed based on the surgeon's preference, most frequently, for smaller lesions and in small-size kidneys. In addition, in particularly large or obese patients, the kidney rest is useful in defining the organ. The abdomen and flank are prepared and draped in standard fashion.

Combined team efforts of the operating surgeon and the attending anesthesiology staff lead to the best outcomes. Complete muscle relaxation is essential. The anesthesiologist should be experienced in complex laparoscopic procedures, which may take several hours to complete. CO₂ monitoring and relaying the extent of the hypercarbic state during the procedure to the surgeon are particularly important.

FIGURE 1 ■ Patient positioning for a transperitoneal laparoscopic nephrectomy. (A) Patient in the complete lateral position for a left transperitoneal laparoscopic nephrectomy. (B) The 45°-midline lateral position is employed for large renal lesions and/or large kidneys (e.g., adult polycystic kidney disease).



The minimal number of ports that are required is three, with additional ports placed when specific retraction is required, e.g., patients with a relatively large liver require the placement of a fourth port to retract the liver during dissection of the right upper renal pole.

Port Placement Schemes

Figure 2 shows three and four port placement schemes for transperitoneal laparoscopic radical nephrectomy. Port placement varies according to center and surgeon preference. Depending on the complexity of the procedure, the number of ports can vary from three to six.

The minimal number of ports that are required is three, with additional ports placed when specific retraction is required, e.g., patients with a relatively large liver require the placement of a fourth port to retract the liver during dissection of the right upper renal pole.

The location of the ports follows a variety of schemes. Traditionally, either a periumbilical or supraumbilical port was placed for the endoscope, with additional ports placed subcostally. In many centers, this has evolved to a scheme where a port is placed at the mid-clavicular line lateral to the kidney. This port is employed for visualization, and two additional ports are placed, one on either side, for working instruments.

CAVEATS

- Inadvertent puncture or laceration of the epigastric vessels can be prevented with port placement lateral or medial to the body of the rectus muscle.
- Ports that are placed too close to the rib cartilage, e.g., less than 1 cm from the costochondral margin, will be difficult to pivot during laparoscopic dissection.

Technical Surgical Steps

Once the three initial operating ports are placed, the surgeon can employ either a 1 cm or 5 mm laparoscopic lens to illuminate the intraperitoneal contents to rule out the pres-

FIGURE 2 ■ Various port placement schemes for transperitoneal laparoscopic nephrectomy. A 10/12-mm port is utilized for the camera; working ports are 5- or 10-mm; and a 5-mm port is usually sufficient for the additional retraction port.



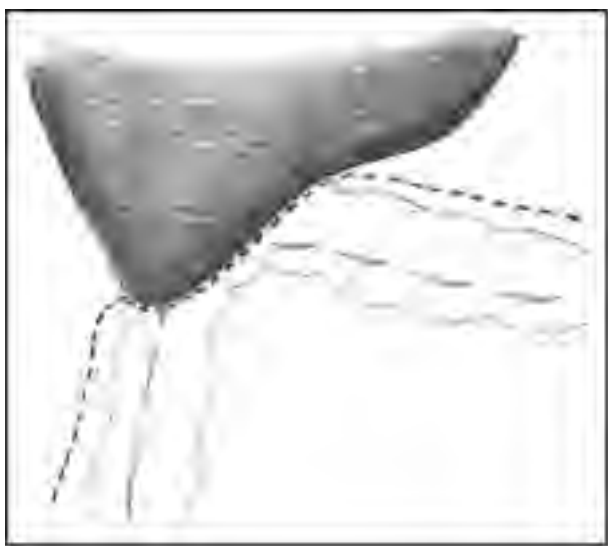

FIGURE 3 ■ Laparoscopic right radical nephrectomy. Resection begins with incision of the white line of Toldt and peritoneal attachments between the liver and right colon. Mobilization of the first portion of the transverse colon improves access to the right renal hilum.

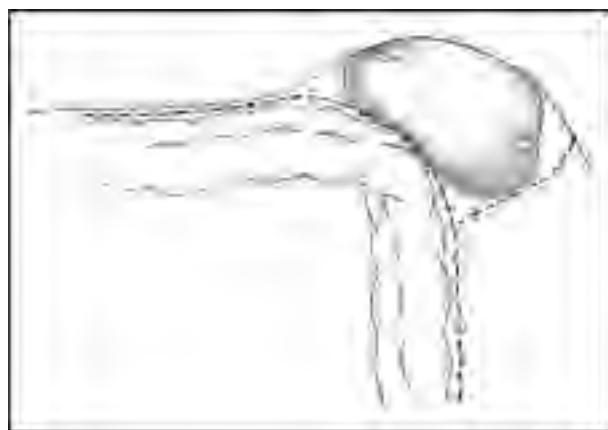


FIGURE 4 ■ Laparoscopic left radical nephrectomy. The white line of Toldt is incised along the left colon, and the peritoneal attachments between the colon and spleen are divided. The distal end of the transverse colon is mobilized, as is the spleen laterally.

ence of distant metastases. On either side of the abdomen, the dissection begins with the mobilization of the colon medially and the entry into the retroperitoneum. On the right side, the colon is mobilized by incising the white line of Toldt and dividing the attachments between the liver and first portion of the transverse colon (Fig. 3).

- During right nephrectomy, the mobilization of the colon is continued along the first portion of the transverse colon to allow complete retraction of the right colon, which exposes the right retroperitoneum.
- On the left side, the same incision along the white line of Toldt is continued up along the distal end of the transverse colon with division of the attachments between the colon and the spleen for the same reason stated above (Fig. 4).

When performing a transperitoneal right laparoscopic radical nephrectomy, entry into the retroperitoneum should direct the surgeon to specific landmarks (Fig. 5). The vena cava should be defined and traced to the renal vein. Other landmarks including the gonadal vein are commonly noted during the dissection. The most common location of the renal artery is posterior to the main renal vein. Multiple renal veins like multiple renal arteries may be present. Variations in renal vascular anatomy are common, and the surgeon should take great care in defining the vessels and carefully dissecting them free from adjacent structures.

On the left side, after entering the retroperitoneum, the surgeon should seek to define the common anatomic constellation that includes the main renal vein crossing the aorta and the adrenal and gonadal veins entering this vessel (Fig. 6).

During transperitoneal radical nephrectomy, hilar vessels should be divided in a stepwise fashion. The arteries should be dissected free from the renal veins and carefully clipped and divided prior to addressing the main renal vein. Most surgeons place multiple clips on the arteries and divide these vessels with endoscopic shears between the clips.

When all the arteries have been clipped, the renal vein will flatten. A still engorged renal vein after arterial control commonly indicates the presence of an accessory renal artery that needs to be addressed.

The renal vein is addressed with an EndoGIA stapling device (Fig. 7). There are two techniques that may be employed: (i) the stapling device fires six rows of titanium staples and divides the vessel between row three and four and (ii) the stapling device fires six rows of staples with no blade. The unbladed device is particularly useful in the case of a short renal vein or in complex presentations where the surgeon would prefer to inspect the staple lines and then divide the vessel using endoscopic shears either between staple lines or between two fires of this device.

During transperitoneal radical nephrectomy, hilar vessels should be divided in a stepwise fashion. The arteries should be dissected free from the renal veins and carefully clipped and divided prior to addressing the main renal vein.

When all the arteries have been clipped, the renal vein will flatten. A still engorged renal vein after arterial control commonly indicates the presence of an accessory renal artery that needs to be addressed.

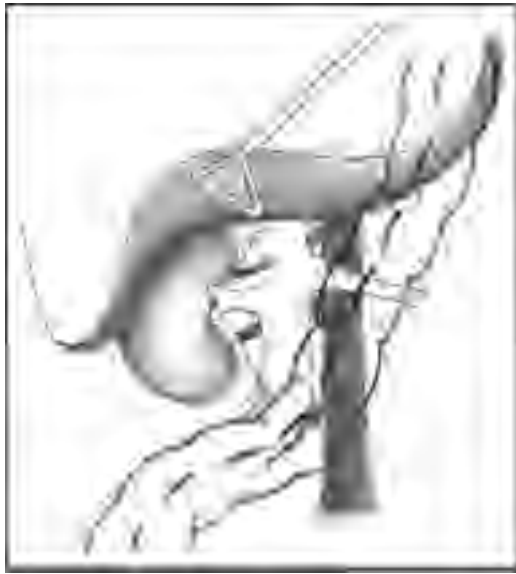

FIGURE 5 ■ Laparoscopic right radical nephrectomy. After entering the retroperitoneum, the colon is mobilized medially as needed to expose the right renal hilum. Cephalad retraction of the liver is essential. In this case, note the accessory upper-pole renal artery, which is a common variant.

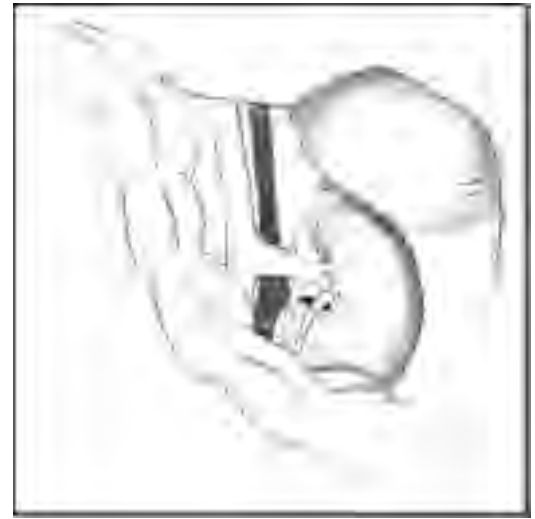

FIGURE 6 ■ Laparoscopic left radical nephrectomy. Medial mobilization of the colon exposes the renal hilum. Landmarks include the branching left renal vein commonly overlying the renal artery.

EndoGIA staplers may misfire if a surgical clip is inadvertently caught between the jaws. Also, when separating the vessels, the surgeon should be well aware of the location of the clips on the renal artery or other vessels before employing the EndoGIA stapler.

Division of the gonadal vein is particularly useful for inferior tumors with local adhesion or involvement by the tumor mass.

EndoGIA staplers may misfire if a surgical clip is inadvertently caught between the jaws. Also, when separating the vessels, the surgeon should be well aware of the location of the clips on the renal artery or other vessels before employing the EndoGIA stapler.

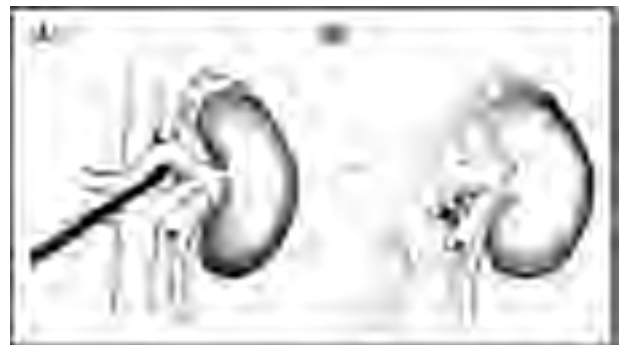When resection of the adrenal gland is planned as part of the radical nephrectomy procedure, then the hilar dissection should be extended cephalad, defining the adrenal vein and dividing it between clips. Multiple adrenal arteries may be present and need to be either clipped or sealed as the adrenal is mobilized during dissection. Left adrenal vein can be divided between clips as it enters the renal vein. Right adrenal vein usually enters directly into the inferior vena cava. Adrenal venous drainage is commonly based on multiple vessels, where a large cephalad phrenic vein may be encountered. Such vessels should be addressed in a similar fashion to the main adrenal vein, which is often inferior.

After control of the renal hilum is completed, mobilization of the kidney is continued cephalad under the diaphragm, often including the adrenal. The dissection is then continued laterally and posteriorly. The ureter is identified and divided between clips. If warranted, division of the gonadal vein as it courses through the retroperitoneum can be performed between clips at various locations.

Division of the gonadal vein is particularly useful for inferior tumors with local adhesion or involvement by the tumor mass.

Division of renal tumor friable neovascularity encountered in the retroperitoneum is performed by clipping or sealing, e.g., using the Ligasure device.

FIGURE 7 ■ Dissection of the left renal hilum. (A) The left gonadal vein is clipped and divided to allow mobility and retraction of the renal vein, providing exposure to the renal artery. (B) The renal artery is first clipped and then the renal vein is addressed with an EndoGIA stapler. Care must be taken to avoid catching a staple from the renal artery or gonadal vein when employing the EndoGIA stapler for it will misfire if a metallic foreign body is caught in its jaws.



The contents of Gerota's space, including all the adipose tissue surrounding the kidney, should be developed and removed en bloc.

Specimens can be extracted either by extending the umbilical trocar site incision or with a small suprapubic incision. Transvaginal extraction has also been reported.

Results of laparoscopic radical nephrectomy are similar if not better than traditional open radical nephrectomy.

Complications with laparoscopic radical nephrectomy are similar to those associated with open surgery, including injury to adjacent organs, bleeding, infection, port site or wound herniation, peritonitis, and postoperative ileus.

The contents of Gerota's space, including all the adipose tissue surrounding the kidney, should be developed and removed en bloc.

Once the specimen has been mobilized completely, it is brought centrally into the peritoneum and entrapped into an endocatch bag. Commonly the specimen is large and so the largest available laparoscopic sac is employed. There are various methods and locations utilized to remove the specimen. There is a general debate amongst surgeons on whether the specimen should be morcellated or removed intact. However, intact specimen removal rather than morcellation allows preservation of the histologic landmarks necessary to achieve adequate tumor staging.

Specimens can be extracted either by extending the umbilical trocar site incision or with a small suprapubic incision. Transvaginal extraction has also been reported (18).

After performing transperitoneal laparoscopic radical nephrectomy, the larger port sites, e.g., 10 mm or larger ports, are closed at the fascial level. A variety of fascial closure devices that place sutures through the fascia on either side of the defect may be employed to prevent herniation. Extraction incision is closed using standard surgical technique employing absorbable suture.

In the majority of patients, the gastric tube is removed at the end of the procedure. Diet is advanced when clinically indicated based on the general course of the patient post-procedurally. The Foley catheter is usually removed the morning after the procedure.

RESULTS

Table 1 presents outcomes of six series of transperitoneal laparoscopic radical nephrectomy. Tumor size and stage and perioperative parameters including blood loss and length of stay are presented.

Results of laparoscopic radical nephrectomy are similar if not better than traditional open radical nephrectomy.

As with any relatively new procedure, most authors describe a learning curve, with results improving over time. Comparative series show a trend with experience to shorter operative times and less blood loss. In addition, the indications for this procedure continue to grow as surgeons treat more complex presentations including larger tumors. Nevertheless, there is a growing enthusiasm for laparoscopic nephron-sparing surgery to treat smaller lesions.

Complications associated with laparoscopic radical nephrectomy are similar to those associated with open surgery (Table 2), including injury to adjacent organs, bleeding, infection, port site or wound herniation, peritonitis, and postoperative ileus (9,22–27).

The incidence and severity of intraperitoneal adhesions associated with transperitoneal laparoscopic surgery have been shown to be significantly less than noted after open abdominal surgery (28). However, specific vascular complications associated with the dissection and ligation of the renal vessels may occur, e.g., clip misfire during renal artery ligation due to significant atherosclerosis may lead to vessel

TABLE 1 ■ Laparoscopic Radical Nephrectomy Series

Author	No. of pts	Trans-peritoneal	Retro-peritoneal	Conversion to open (%)	Blood loss (mL)	Tumor size (cm)	Comp major	Comp minor	Specimen extraction	Postop. stay (day)	OR time (min)	Stage			
												T1	T2	T3	T4
Wille et al. (19)	125	125	None	2 (1.6)	210	5.1	6	NA	I	6	200	78	12	28	0
Ono et al. (5)	103	85	18	4	254	3.1	10	3	M	NA	282	102	0	1	0
Gill et al. (4)	100	27	73	2	212	5.1	14	3	I	1.6	179	63	11	4	1
Dunn et al. (3)	61	58 ^a	3	NA	172	5.3	2	21	M	3.4	330	9	32	1	0
Janetschek et al. (20)	73	73	None	0	170	3.8	5	3	I	7.2	142	59	0	9	0
Barrett et al. (21)	72	72	None	6	NA	4.5	6	2	M	4.4	175	8	61	3	0

^aThree cases were intentionally combined retroperitoneal and transperitoneal.

Abbreviations: OR, operating room; I, intact; M, morcellated.

TABLE 2 ■ Complications Associated with Laparoscopic Radical Nephrectomy

Intraoperative bowel injury
Small bowel
Duodenum
Colon
Splenic injury
Liver injury
Vascular injury
Bleeding
Clip misfire and/or slippage
EndoGIA misfire
Abdominal wall hematoma
Intraperitoneal abscess
Peritonitis

Complications occurring during transperitoneal laparoscopic nephrectomy are slightly different compared to retroperitoneal laparoscopic nephrectomy. During dissection of the renal hilum, the renal vein, may require retraction to allow adequate visualization of the renal artery. Aggressive retraction, particularly on the left side, may lead to bleeding from venous tributaries. This is usually not an issue when employing a retroperitoneal approach.

crush injury proximal to the clips and hemorrhage. In addition, EndoGIA misfire can occur if a dense structure (i.e., fibrotic or calcified vessel, adjacent metal clip, etc.) is inadvertently caught within the jaws during engagement. Precise dissection of accessory vessels minimizes intraoperative blood loss.

The complications occurring during transperitoneal laparoscopic nephrectomy are slightly different compared to retroperitoneal laparoscopic nephrectomy. In fact, during dissection of the renal hilum, the renal vein, which is commonly anterior to the renal artery, may require retraction to allow adequate visualization of the renal artery. Aggressive retraction, particularly on the left side, may lead to bleeding from venous tributaries (including the adrenal vein). This is usually not an issue when employing a retroperitoneal approach. There is also a decreased risk of trauma to intra-abdominal organs when using the retroperitoneal approach.

SUMMARY

- Laparoscopic radical nephrectomy is standard treatment for renal cell carcinoma. The indications continue to broaden.
- The intraperitoneal approach is particularly useful for large lesions or in patients with a tumor in an ectopic or horseshoe kidney.
- Transperitoneal laparoscopic nephrectomy has a complimentary role with retroperitoneal laparoscopic nephrectomy.
- The retroperitoneal approach is preferred in patients with significant intra-abdominal scarring.

REFERENCES

1. Clayman RV, Kavoussi LR, Soper NJ. Laparoscopic nephrectomy: initial case report. *J Urol* 1991; 146:278.
2. Cadeddu JA, Ono Y, Clayman RV, et al. Laparoscopic nephrectomy for renal cell cancer: evaluation of efficacy and safety: a multicenter experience. *Urology* 1998; 52:773.
3. Dunn MD, Portis AJ, Shalhav AL, et al. Laparoscopic versus open radical nephrectomy: a 9-year experience. *J Urol* 2000; 164:1153.
4. Gill IS, Meraney AM, Schweizer DK, et al. Laparoscopic radical nephrectomy in 100 patients. *Cancer* 2001; 92:1843.
5. Ono Y, Kinukawa T, Hattori R, et al. The long-term outcome of laparoscopic radical nephrectomy for small renal cell carcinoma. *J Urol* 2001; 165:1867.
6. Portis AJ, Yan Y, Landman J, et al. Long-term followup after laparoscopic radical nephrectomy. *J Urol* 2002; 167:1257.
7. Rassweiler J, Tsivian A, Kumar AV, et al. Oncological safety of laparoscopic surgery for urological malignancy: experience with more than 1,000 operations. *J Urol* 2003; 169:2072.
8. Keeley FX, Tolley DA. A review of our first 100 cases of laparoscopic nephrectomy: defining risk factors for complications. *Br J Urol* 1998; 82:615.
9. Rassweiler J, Fornara P, Weber M, et al. Laparoscopic nephrectomy: the experience of the laparoscopy working group of the German Urologic Association. *J Urol* 1998; 160:18.
10. Rassweiler J, Frede T, Henkel TO, et al. Nephrectomy: a comparative study between the transperitoneal and retroperitoneal laparoscopic versus the open approach. *Eur Urol* 1998; 33:489.
11. Finelli A, Gill IS. Laparoscopic partial nephrectomy: contemporary technique and results. *Urol Oncol* 2004; 22:139.
12. Gill IS, Matin SF, Desai MM, et al. Comparative analysis of laparoscopic versus open partial nephrectomy for renal tumors in 200 patients. *J Urol* 2003; 170:64.
13. Patard JJ, Shvarts O, Lam JS, et al. Safety and efficacy of partial nephrectomy for all T1 tumors based on an international multicenter experience. *J Urol* 2004; 171:2181.
14. Matin SF, Gill IS, Worley S, et al. Outcome of laparoscopic radical and open partial nephrectomy for the sporadic 4 cm or less renal tumor with a normal contralateral kidney. *J Urol* 2002; 168:1356.
15. Pautler SE, Walther MM. Transperitoneal laparoscopic radical nephrectomy for bulky renal tumors. *Can J Urol* 2002; 9:1653.
16. Desai MM, Gill IS, Ramani AP, et al. Laparoscopic radical nephrectomy for cancer with level I renal vein involvement. *J Urol* 2003; 169:487.
17. Fugita OE, Chan DY, Roberts WW, et al. Laparoscopic radical nephrectomy in obese patients: outcomes and technical considerations. *Urology* 2003; 63:247.
18. Gill IS, Cherullo EE, Meraney AM, et al. Vaginal extraction of the intact specimen following laparoscopic radical nephrectomy. *J Urol* 2002; 167:238.
19. Wille AH, Roigas J, Deger S, et al. Laparoscopic radical nephrectomy: techniques, results and oncological outcome in 125 consecutive cases. *Eur Urol* 2004; 45:483.
20. Janetschek G, Jeschke K, Peschel C. Laparoscopic surgery for stage T1 renal cell carcinoma: radical nephrectomy and wedge resection. *Eur Urol* 2000; 38:131.
21. Barrett PH, Fentie DD, Taranger LA. Laparoscopic radical nephrectomy with morcellation for renal cell carcinoma: the Saskatoon experience. *Urology* 1998; 52(1):23.
22. Simon SD, Castle EP, Ferrigni RG, et al. Complications of laparoscopic nephrectomy: the Mayo clinic experience. *J Urol* 2004; 171:1447.

23. Soulie M, Salomon L, Seguin P, et al. Multi-institutional study of complications in 1085 laproscopic urologic procedures. *Urology* 2001; 58:899.
24. Vallancien G, Cathelineau X, Baumert H, et al. Complications of transperitoneal laparoscopic surgery in urology: review of 1,311 procedures at a single center. *J Urol* 2002; 168:23.
25. Siqueira TM, Kuo RL, Gardner TA, et al. Major complications in 213 laparoscopic nephrectomy cases: The Indianapolis Experience. *J Urol* 2002; 168:1361.
26. Stephenson AJ, Hakimi AA, Snyder ME, et al. Complications of radical and partial nephrectomy in a large contemporary cohort. *J Urol* 2004; 171:130.
27. Gill IS, Kavoussi LR, Clayman RV, et al. Complications of laparoscopic nephrectomy in 185 patients: a multi-institutional review. *J Urol* 1995; 154:479.
28. Pattaras JG, Moore RG, Landman J, et al. Incidence of postoperative adhesion formation after transperitoneal genitourinary laparoscopic surgery. *Urology* 2002; 59:37.

LAPAROSCOPIC RADICAL NEPHRECTOMY: RETROPERITONEAL TECHNIQUE

Howard Evans and Michael G. Hobart

Division of Urology, Department of Surgery, University of Alberta, Alberta, Canada

- INTRODUCTION
- INDICATIONS AND CONTRAINDICATIONS
 - Contraindication of Laparoscopic Retroperitoneal Radical Nephrectomy
- PREOPERATIVE PREPARATION
- PROCEDURE
 - Step 1: Patient Positioning
 - Step 2: Retroperitoneal Access
 - Step 3: Balloon Dilation of the Retroperitoneal Space
 - Step 4: Port Placement
 - Step 5: Dissection and Ligation of the Renal Hilum
 - Step 6: Mobilization of the Kidney

- Step 7: Entrapment and Removal of Specimen
- Step 8: Hemostasis and Closure
- TECHNICAL CAVEATS AND TIPS
- SPECIFIC MEASURES TAKEN TO AVOID COMPLICATIONS
 - Complications Related to Retroperitoneal Access and Insufflation
 - Complications Related to the Renal Hilum Dissection
 - Complications Related to Renal Mobilization
- SUMMARY
- REFERENCES

Despite skepticism, the technique of retroperitoneal laparoscopic radical nephrectomy evolved into a standardized approach, which resolved problems related to retroperitoneal landmark recognition.

INTRODUCTION

During the early 1990s, pioneering work by Clayman and Gaur established the early technique and equipment that allowed retroperitoneal laparoscopy or retroperitoneoscopy to expand into extirpative surgery (Table 1). Initial problems with inadequate insufflation and dissection of the retroperitoneum were elegantly overcome by Gaur et al. with their description of atraumatic balloon dissection of the retroperitoneal space (1,11,12,14). Historically, these early reports and, similarly, the important early transperitoneal laparoscopy technical reports were all too often met with skepticism by the general urologic community.

Despite skepticism, the technique of retroperitoneal laparoscopic radical nephrectomy evolved into a standardized approach, which in turn resolved problems related to retroperitoneal landmark recognition (16).

During the intervening years, the laparoscopic radical nephrectomy has been firmly established as standard of care for renal masses not amenable to partial nephrectomy. Outcome analysis of surgical series from transperitoneal and retroperitoneal approaches has demonstrated similar intraoperative and postoperative results. Early reports of less postoperative ileus allowing earlier postoperative discharge with the retroperitoneal approach have not been consistently demonstrated in comparative analysis (2,3). Thus distinct advantages between these approaches appear indiscernible (24); however, both approaches are clearly superior to traditional open surgery (9,10).

Selection of a surgical approach should, therefore, be based on the following factors:

- Patient size
- Mass size
- Prior ipsilateral surgery
- Peritoneal dialysis
- Surgeon preference and experience

Regardless of individual surgeon preference, the retroperitoneal laparoscopic radical nephrectomy remains an important tool in the urologic armamentarium for minimally invasive surgical treatment (13,19). Ideally, it is advantageous for a laparoscopic urologic surgeon to have familiarity with both approaches.

TABLE 1 ■ Equipment List for Retroperitoneal Laparoscopic Radical Nephrectomy

Scalpel blade—No. 15
S Retractors (2)
Retroperitoneal balloon dilator
Laparoscopic trocars
Blunt-tip (10 or 12 mm) with fascial balloon (1)
12-mm trocar (1)
5-mm trocar (1)
Laparoscope—10 mm with 30° lens
Electrosurgical scissors—5 mm
Electrosurgical J or L hook—5 mm
Suction/irrigation device—5 mm
Laparoscopic right angle forceps—small (5 mm) and large (10 mm)
Laparoscopic forceps and small bowel forceps (2)
Laparoscopic 10-mm metal fan retractor (1)
Laparoscopic clip applicator (1) (single fire, multifire, or locking clips)
Laparoscopic Endo-GIA vascular stapler
Laparoscopic specimen bag

The indications for laparoscopic retroperitoneal radical nephrectomy are similar to the indications for open radical nephrectomy, namely the presence of a renal mass not amenable to a partial nephrectomy.

INDICATIONS AND CONTRAINDICATIONS

The indications for laparoscopic retroperitoneal radical nephrectomy are similar to the indications for open radical nephrectomy, namely the presence of a renal mass not amenable to a partial nephrectomy.

In comparison to the transperitoneal approach, the retroperitoneal approach has some potential relative advantages and indications. These advantages include the following: (i) patients on peritoneal dialysis, who can continue peritoneal dialysis uninterrupted after the retroperitoneal approach and (ii) patients with extensive prior ipsilateral surgery in the quadrant of interest, which may result in problematic intra-abdominal peritoneal adhesions.

Contraindication of Laparoscopic Retroperitoneal Radical Nephrectomy

- Presence of a tumor thrombus
- Excessively large masses
- Inadequate cardiopulmonary reserve to tolerate CO₂ insufflation
- Bleeding diathesis

Although renal vein tumor thrombi have been successfully removed by a laparoscopic retroperitoneal approach, they should be approached with caution. The presence of an inferior vena cava tumor thrombus remains a firm contraindication. Renal masses larger than 10 cm are increasingly difficult to remove by the retroperitoneal technique. While there is no absolute size limitation, a mass larger than 10 cm should also be approached with caution.

PREOPERATIVE PREPARATION

A standard renal cell cancer metastatic workup is performed. Prior to surgery, the patient is assessed for surgical risk with a history and physical examination, routine blood work, and an electrocardiogram. Informed consent is then obtained. Bowel preparation is optional but no longer routinely necessary. Preoperative prophylactic antibiotics are administered and pneumatic compression stockings are utilized for deep vein thrombosis prevention. Foley catheters are routinely used while nasogastric tubes are not (Table 1).

Full flexion of the operating table with elevation of the kidney bar helps to optimize the space between the iliac crest and the lower ribs.

Although not essential, it is helpful to landmark the external surface anatomy with an operating room marking pen on the patient's abdomen.

PROCEDURE

Step 1: Patient Positioning

After establishing general anesthesia with endotracheal intubation and appropriate lines and monitoring devices, a Foley catheter is placed and pneumatic thromboembolic

FIGURE 1 ■ Patient is placed in the full flank position. Padding is placed under all pressure points. Patient is flexed and the kidney bar is raised to maximize the space between the lower ribs and the iliac crest. The patient is secured to the bed with three strips of tape placed circumferentially around the patient and table in the indicated positions. The primary camera port is placed at the tip of the 12th rib. The two working ports are placed at the angle of the 12th rib and psoas/paraspinal muscles and 3 cm above the iliac crest in the mid-axillary line.



FIGURE 2 ■ Optimized operating room configuration and surgical team positions for a right-sided retroperitoneal laparoscopic nephrectomy.

Occasionally, particularly in younger patients, the thoracolumbar fascia is too dense to be pierced with a fingertip. A hemostat is then employed to enter the retroperitoneal space.

Precise dissection between the psoas muscle and the posterior aspect of Gerota's fascia is critical. Failure to do so will adversely affect retroperitoneal balloon dilation.

Blind placement of the Veress needle can result in insufflation of retroperitoneal musculature or accidental pneumoperitoneum. The open Hasson technique is faster and safer and considered the preferred technique.

deterrent stockings are applied. The patient is then placed in the full flank position with the pathologic side up.

Full flexion of the operating table with elevation of the kidney bar helps to optimize the space between the iliac crest and the lower ribs.

Protective gel or foam padding is applied to all pressure points, the weight-bearing axilla is protected with an axillary roll and the limbs are positioned in an ergonomically acceptable position. The patient is then secured to the operative table with circumferential 3-in. surgical tape at the chest/shoulder, hip, and lower leg (Fig. 1). Alternatively, a surgical bed "bean bag," such as the Olympic Vac Pac, can be used to secure the patient to the operating table.

Although not essential, it is helpful to landmark the external surface anatomy with an operating room marking pen on the patient's abdomen highlighting the following:

- Both tips of 11th and 12th ribs
- The psoas muscle
- The edge of iliac crest
- Sites for trocar placement

The operating room and surgical team are positioned in the manner shown in Figure 2. A Mayo stand is positioned at the foot of the bed so that the nurse can organize equipment. The surgeon and assistant are positioned on the posterior or backside of the patient. The scrub nurse stands at the foot of the bed on the other side or abdominal side. Display monitors are positioned on either side of the patient. To minimize the clutter of tubes and equipment, it is helpful to organize the cautery cords, insufflation tubing, camera, and suction and irrigation tubing so that all tubes and cords pass off away from the surgeon and are clamped under one edge of the pocket drape on the patient's abdomen.

Step 2: Retroperitoneal Access

Access to the retroperitoneum is obtained using an open technique. A 1-1.5-cm incision is made in the skin just below the tip of the 12th rib. The muscle fibers below the fascia are bluntly separated with S-retractors until the thoracolumbar fascia is identified, which is then bluntly entered with a fingertip (18,25).

Occasionally, particularly in younger patients, the thoracolumbar fascia is too dense to be pierced with a fingertip. In such an instance, a hemostat is employed to enter the retroperitoneal space.

After entering the retroperitoneal space, blunt finger dissection is used to initially develop and expand the potential space (Fig. 3). The dissection proceeds anterior to the psoas muscle and posterior to Gerota's fascia until sufficient space has been created to allow for further mechanical expansion of the space.

Precise dissection between the psoas muscle and the posterior aspect of Gerota's fascia is critical. In fact, failure to do so will adversely affect retroperitoneal balloon dilation.

Alternatively, access to the retroperitoneum can be obtained using a closed technique with a Veress needle (4,5). The Veress needle is inserted into Petit's inferior lumbar triangle. CO₂ insufflation creates a pneumoretroperitoneum, which allows blind insertion of the primary trocar.

The blind placement of the Veress needle can occasionally result in insufflation of retroperitoneal musculature such as the quadratus lumborum or too deep placement of the needle, resulting in accidental pneumoperitoneum. For these reasons, the open Hasson technique for retroperitoneal access is faster and safer and considered the preferred technique.

Step 3: Balloon Dilation of the Retroperitoneal Space

Further dissection and expansion of the retroperitoneal space is accomplished using blunt camera dissection or by using a retroperitoneal balloon (20,21,26). The working space in the retroperitoneum can be created with blunt camera dissection between Gerota's fascia and the psoas muscle (6). While this technique obviates the need for additional potentially expensive equipment, it is hampered by the need for frequent cleaning of the camera lens and limited by the small space.

Utilization of a retroperitoneal balloon dilator to dissect the retroperitoneal connective tissue is a more efficacious and precise technique to quickly establish the working space in the retroperitoneum.

Gaur et al. originally described balloon dissection with a self-fashioned balloon created from a red rubber catheter and a glove finger secured to the catheter with a suture (1,15). Although economical, self-fashioned balloons are hampered by imprecise placement of the balloon because of flexibility of the catheter and the potential for rupture of the finger balloon with resultant radiolucent foreign material being deposited into the patient. For these reasons, commercial retroperitoneal balloon dilators commonly used for dilation of the retroperitoneum are the Pre-Peritoneal Distention Balloon^a and the Spacemaker^b (Fig. 4). The retroperitoneal balloon is placed into the retroperitoneal space at an oblique cephalad orientation. The balloon should be positioned anterior to the psoas muscle and posterior to Gerota's fascia in the space previously created by the blunt finger dissection (16,17).

Failure to position the balloon between the psoas and Gerota's fascia will result in dissection between the peritoneum and the anterior surface of Gerota's fascia, leaving the kidney in a posterior orientation adherent to the psoas muscle.

With proper balloon placement, the balloon dissection mobilizes the kidney and Gerota's fascia anteromedially, allowing posterior access to the renal hilum (Fig. 5). For an average-sized adult, the balloon is then inflated to 800 cc. Confirmation of balloon position within the retroperitoneum and the adequacy of the dissection are assessed by passing a laparoscope down the transparent balloon sheath (Fig. 4). Progressive sequential balloon dilation is performed in either the upper retroperitoneum to facilitate large upper pole tumor dissection or down toward the pelvis to facilitate dissection of the ureter as part of a nephroureterectomy.

Finger dissection and the balloon dilation in the proper surgical plane will allow the gas pressure obtained with the insufflation of the retroperitoneum to hold the kidney away from the surgeon, thus maintaining the working space and providing exposure to the renal hilum.

Step 4: Port Placement

The primary port or camera port is placed at the site of balloon dilator. While a reusable 10-mm Hasson type port secured with sutures can be used, nonsealing ports of this type will be problematic because of CO₂ leakage and CO₂ subcutaneous emphysema. As such, it is preferable to use a port with a sealing mechanism such as the 10- or 12-mm blunt-tip port (Fig. 6), which creates an airtight seal between an internal fascial balloon and an external foam ring. Pneumoretroperitoneum is then established with 15 mm Hg pressure of CO₂. Typically, only two other secondary ports are required.

A retroperitoneal balloon dilator to dissect the retroperitoneal connective tissue is a more efficacious and precise technique to establish working space in the retroperitoneum.

Failure to position the balloon between the psoas and Gerota's fascia will result in dissection between the peritoneum and the anterior surface of Gerota's fascia, leaving the kidney in a posterior orientation adherent to the psoas muscle.

Finger dissection and balloon dilation in the proper surgical plane allows the gas pressure obtained with insufflation of the retroperitoneum to hold the kidney away from the surgeon, maintaining the working space and providing exposure to the renal hilum.

FIGURE 3 ■ At the tip of the 12th rib, access is gained to the retroperitoneum by bluntly piercing the thoracolumbar fascia. Finger dissection is then performed to establish the posterior plane between Gerota's fascia and the psoas muscle, while also mobilizing the peritoneum anteromedially away from the kidney.



FIGURE 4 ■ Balloon dissector used for retroperitoneal dissection and creation of retroperitoneal space.

^aAutosuture, Norwalk, CT.

^bGSI, Palo Alto, CA.

Optimization of the positions for secondary ports is important due to the limited working space and potential for “clashing” of instruments.

Optimization of the positions for secondary ports is important due to the limited working space and potential for “clashing” of instruments. The secondary ports are placed under either direct vision or under bimanual control. One port is placed posterior at the inner angle of the 12th rib and the paraspinal muscles. An anterior port is placed approximately 3 cm superior to the iliac crest between the anterior and mid axillary line (Fig. 1). Placement of this port too close to the iliac crest will impede surgical dissection.

The secondary ports can be 5, 10, or 12 mm, disposable or reusable, depending on the clinical scenario.

A larger 12-mm port is placed on the ipsilateral side as the surgeon's dominant hand for clip application and vascular stapler application, and a smaller 5-mm port on the side of the surgeon's nondominant hand for retraction.

Step 5: Dissection and Ligation of the Renal Hilum

In comparison to the transperitoneal approach, the retroperitoneal approach allows the surgeon to achieve rapid and straightforward access to the renal hilum. The psoas is the most important early landmark to facilitate dissection.

Surgical orientation is achieved by orientating the psoas muscle in the horizontal plane, allowing the renal vessels to be orientated vertically.

After orienting the psoas muscle, the surgeon then looks for other surgical landmarks including: (i) the renal outline (easily appreciated), (ii) pulsations from the aorta or inferior vena cava, and (iii) the ureter (seen inferior to the kidney and medial to the psoas). Access to the renal hilum is initiated by dissecting in the fascial plane between the anteromedial aspect of the psoas muscle and posterior/inferior aspect of the kidney. The dissection is aided by the application of countertraction to the middle of the kidney with atraumatic laparoscopic forceps in the surgeon's nondominant hand. Dissection is accomplished with cautery or harmonic scalpel.

Dissection is performed one layer at a time, checking for the monophasic pulsations of the renal artery. The monophasic pulsations are in contradistinction to the biphasic pulsations seen from the inferior vena cava.

Once the artery is identified, it is mobilized by placing a right-angled instrument circumferentially around it. Branches of the renal artery are encountered if the dissection in the renal hilum occurs more distally. The artery is occluded with clips: three are placed on the aortic side and two on the kidney side, after which the artery is divided. The renal vein is identified anterior to the artery. Similarly, the vein is exposed with careful dissection until a right-angled instrument can be placed around it, giving enough exposure to accommodate an endo-GIA vascular stapler. The stapler is used to both occlude and ligate the vein (Fig. 7).

Surgical orientation is achieved by orientating the psoas muscle in the horizontal plane, allowing the renal vessels to be orientated vertically.

Dissection is performed one layer at a time, checking for the monophasic pulsations of the renal artery. The monophasic pulsations are in contradistinction to the biphasic pulsations seen from the inferior vena cava.

- When performing a left-sided nephrectomy, the adrenal, gonadal, and lumbar vein branches may also need to be clipped and divided.
- When performing a right-sided nephrectomy, great care in the vein dissection is required to ensure that the vein dissected is the renal vein and not the inferior vena cava, which on occasion can have the appearance of the renal vein.



FIGURE 5 ■ Retroperitoneal working space is created with balloon dissection through the primary port site.



FIGURE 6 ■ The blunt port with internal fascial balloon and an external sponge cuff. The balloon and sponge cuff create an airtight seal, thus minimizing CO₂ leakage and subcutaneous emphysema.

The surgeon is more likely to mistake the inferior vena cava for the renal vein if the dissection is too posterior.

Step 6: Mobilization of the Kidney

After the renal hilum dissection has been completed, the kidney is sequentially mobilized using blunt and sharp dissection.

Dissection is initiated at the upper pole. The surgeon will then need to decide whether the adrenal will be spared or removed en bloc with the kidney. While established oncologic principles need to be adhered to, it is often easier to remove the left adrenal en bloc with the kidney because of the adrenal vein drainage into the already divided renal vein.

On the right side, additional dissection is required to expose and allow ligation and division of the right adrenal vein as it enters the inferior vena cava. Regardless, meticulous hemostasis with electrocautery is advisable. Inferiorly, the mobilization is performed with cautery and blunt dissection along the psoas muscle. The dissection is taken up to the diaphragm.

Separating the anterior aspect of Gerota's fascia from the peritoneum without creating a hole in the peritoneum requires care and meticulous dissection.

An incidental peritoneotomy will greatly increase the difficulty of further dissection because the hole allows normalization of the pressure gradient between the peritoneum and the retroperitoneum. As a consequence, the surgically created working space in the retroperitoneum will collapse. The 10-mm fan retractor is a useful instrument to facilitate blunt dissection and mobilization. Once the upper pole is mobilized, attention is turned to the inferior pole. The ureter is easily identified on the psoas muscle. The ureter is mobilized and clipped superiorly and inferiorly and then divided. The gonadal vein is seen with the ureter and is doubly clipped and ligated. The lower pole mobilization is then completed using the psoas muscle as the margin of mobilization. Dissection proceeds until the kidney is completely mobilized.

Step 7: Entrapment and Removal of Specimen

Entrapment of the specimen within a bag for specimen removal is a technically challenging procedure. While bags without a delivery system such as the Lap Sac^c can be used, the relatively small space of the retroperitoneum combined with the limited port sites results in the entrapment procedure escalating an order of magnitude in difficulty compared to bags with a delivery system. The Endocatch I and Endocatch II bags^d, with their butterfly net type delivery hoop, aid in entrapment as the metal delivery ring holds open the plastic bag, allowing the specimen to be flipped into the open bag (Fig. 8).

In some instances, particularly when the specimen is very large, entrapment is facilitated by creating an intentional anterior peritoneotomy. The specimen is then negotiated into the larger space of the peritoneal cavity, resulting in easier entrapment.

After entrapment, the specimen is removed intact. The choice of the location for the specimen extraction incision is influenced by the size of the specimen, size of the patient, prior surgical history, and sex of the patient. Options include (i) enlargement of the primary camera port, (ii) a small posterior dorsolumbotomy incision, (iii) a Pfannenstiel incision, or, in a female, (iv) a vaginal extraction (7).

Step 8: Hemostasis and Closure

After removal of the kidney, careful inspection of the renal fossa at atmospheric pressure is necessary to ensure hemostasis. Once hemostasis is assured, the extraction incision is closed in layers. Ports 10 mm or larger are also closed with facial suture.

Dissection is initiated at the upper pole. The surgeon must then decide whether the adrenal will be spared or removed en bloc with the kidney. It is often easier to remove the left adrenal en bloc with the kidney because of the adrenal vein drainage into the already divided renal vein.

Separating the anterior aspect of Gerota's fascia from the peritoneum without creating a hole in the peritoneum requires care and meticulous dissection.

In some instances, particularly when the specimen is very large, entrapment is facilitated by creating an intentional anterior peritoneotomy. The specimen is then negotiated into the larger space of the peritoneal cavity, resulting in easier entrapment.

TECHNICAL CAVEATS AND TIPS

After access to the retroperitoneum has been achieved, precise finger dissection is critical to establish the proper surgical plane between the posterior reflection of Gerota's fascia and the anterior psoas muscle fascia.

^cCook, Bloomington, IN.

^dEthicon, Somerville, NJ.



FIGURE 7 ■ Division of the vascular pedicle. The renal artery has been ligated and divided with clips and the vascular stapler is positioned across the renal vein.



FIGURE 8 ■ Specimen is entrapped in the extraction bag with delivery ring to hold open the bag. This is accomplished by a scoop-and-roll technique.

Because the working space in the retroperitoneum is small, optimal placement of the secondary working ports is also critical.

Dissection of the renal hilum is aided by observing vascular pulsations.

Renal mobilization is accomplished by using a combination of sharp, blunt, and electrocautery dissection.

Failure to accurately initiate this surgical plane will complicate balloon dissection of the retroperitoneum by allowing the balloon dissection to occur anteriorly between peritoneum and Gerota's fascia. When finger dissection and balloon dissection occur in the proper plane, the kidney will be mobilized and rotated anteriorly, and later insufflation of the retroperitoneum will hold the kidney in this position. Surgeons with limited experience in retroperitoneoscopy may find it beneficial to mark out external landmarks (tip of the 11th and 12th ribs, anterior margin of the psoas muscle, and the iliac crest) and to use bimanual palpation of both the posterior abdominal wall and the kidney anteriorly to help establish the proper surgical plane for finger dissection.

Because the working space in the retroperitoneum is small, optimal placement of the secondary working ports is also critical.

The posterior port needs to be placed approximately 1.5 cm inferior to the 12th rib and approximately 1.5 cm above the psoas/paraspinal muscles. If the port is placed too close to either of these structures, it will limit mobility of the laparoscopic instruments. Likewise, if the anterior working port is placed too close to the iliac crest, it will also have limited mobility. The anterior port should be placed approximately 3 cm above the iliac crest in the mid-axillary line. If the anterior port is placed too far anteriorly without adequate prior finger dissection and mobilization of the peritoneum, the port may puncture the peritoneum.

Dissection of the renal hilum is aided by observing vascular pulsations.

Arterial pulsations are characteristically monophasic while venous pulsation or the pulsation of the inferior vena cava is typically biphasic. If the dissection occurs more distally into the renal hilum, multiple branches of the bifurcated renal artery are encountered, necessitating either more proximal dissection or clip occluding the branches individually. After clipping and dividing the renal artery, the renal vein should be collapsed. Failure of the vein to collapse may indicate additional renal arteries. Confirmation of additional renal arteries can be assessed by temporarily occluding the renal vein by passing a large right-angled dissector across the vein like a vascular Satinsky clamp.

Renal mobilization is accomplished by using a combination of sharp, blunt, and electrocautery dissection.

A 10-mm fan retractor opened slightly is a useful instrument to facilitate renal dissection and mobilization. Anterior dissection should be performed with precision and care so that a peritoneotomy is avoided. If an incidental peritoneotomy is made, the potential space in the retroperitoneum will collapse because of equalization of the pressure gradient across the peritoneum and retroperitoneum. In such an instance, further mobilization of the kidney will be difficult and tedious but may be aided by the insertion of a third working port to help hold back the peritoneum. Electrocautery applied to anterior structures should be used cautiously so as to avoid potential bowel injury.

With the laparoscope positioned looking down on the kidney and the extraction bag, entrapment is aided by lifting the kidney with the surgeon's nondominant hand so the bag can be deployed with the delivery ring under the kidney. Alternatively, if the specimen is large, entrapment is aided by creating an intentional peritoneotomy and entrapping the kidney in the peritoneal cavity.

SPECIFIC MEASURES TAKEN TO AVOID COMPLICATIONS

Possible complications from a retroperitoneal laparoscopic radical nephrectomy are subdivided into: (i) complications related to retroperitoneal access and insufflation, (ii) complications related to the renal hilar dissection, and (iii) complications related to renal mobilization (22).

Complications Related to Retroperitoneal Access and Insufflation

The creation of an incidental peritoneotomy may occur during initial access to the retroperitoneum or during overzealous balloon dilation.

If a hole in the peritoneum occurs early in the procedure, the surgeon may elect to convert the procedure to a transperitoneal approach.

Prevention of a peritoneotomy is achieved by careful finger dissection, avoiding overinflation of the dissection balloon, and identification of retroperitoneal landmarks. Another potential complication in this category is subcutaneous emphysema and complications related to extension of CO₂ gas through the tissues. On occasions, the CO₂ gas can tract extensively into the tissues, resulting in potential pneumomediastinum, pneumothorax, or extension of the gas into the tissue around the upper airway.

The most efficacious way to prevent extension of CO₂ gas through the tissues is to limit CO₂ gas insufflation to 12–15 mm Hg pressure, and with the use of a primary camera port with a mechanism to create an airtight seal between the retroperitoneum and the patient's external skin such as the blunt-tip port with its internal fascial balloon (Fig. 6).

Another mechanism that could result in a pneumothorax is during placement of the posterior port below the 12th rib. If the port is placed too close to the rib, the lower reflection of the pleura could be punctured by the port.

Placement of the posterior port 1.5 cm below the 12th rib and 4.5 cm above the psoas will result in safe port placement.

Complications Related to the Renal Hilar Dissection

Renal hilar complications can occur from bleeding, CO₂ gas embolus, or misidentification of the vascular structures Meraney et al. in 2002 (8). Reported an incidence of vascular complications of 1.7%.

Bleeding from the renal hilum is avoided by meticulous dissection with circumferential control and isolation of the vessels prior to applying clips or the vascular Endo-GIATM stapler.

The use of metal surgical clips to correct surgical bleeding should be done judiciously so that clip placement does not interfere with later division of the renal vein with the Endo GIA vascular stapler. Clips caught in the jaws of the stapler will prevent firing of the stapler.

If a hole is made in the renal vein and the insufflation pressure within the retroperitoneum exceeds the venous pressure, CO₂ embolization through the hole is possible. Prompt recognition of the injury is necessary so that the problem can be safely corrected. The vein should be compressed with an atraumatic forceps or alternatively compressed with a forceps padded with absorbable Surgicel[®] after which the vein is sealed and divided with an endo-GIA vascular stapler.

Vascular structures that may be confused for renal vessels include the inferior vena cava on the right side, which can, on occasion, have the appearance of the right renal vein, and the superior mesenteric artery, which potentially could be confused on the left side with the renal artery. Complications to these vessels are avoided by correctly identifying these vessels as nonrenal vessels by observing the vessels not entering the renal hilum.

Complications Related to Renal Mobilization

Finally, complications may occur during mobilization of the kidney. During mobilization, there exists the potential to damage structures around the kidney. The risk, however, is small (8). Such structures include the colon, the duodenum, the pancreas, the small bowel, the major vascular structures, the spleen, and the liver.

Injury to surrounding structures is avoided by maintaining surgical orientation, recognition of retroperitoneal landmarks, and meticulous dissection.

If a hole in the peritoneum occurs early in the procedure, the surgeon may elect to convert the procedure to a transperitoneal approach.

The most efficacious way to prevent extension of CO₂ gas through the tissues is to limit CO₂ gas insufflation to 12–15 mm Hg pressure, and with the use of a primary camera port with a mechanism to create an airtight seal between the retroperitoneum and the patient's external skin such as the blunt-tip port with its internal fascial balloon.

Placement of the posterior port 1.5 cm below the 12th rib and 4.5 cm above the psoas will result in safe port placement.

Bleeding from the renal hilum is avoided by meticulous dissection with circumferential control and isolation of the vessels prior to applying clips or the vascular Endo-GIA stapler.

If a hole is made in the renal vein and the insufflation pressure within the retroperitoneum exceeds the venous pressure, CO₂ embolization through the hole is possible. The vein should be compressed with an atraumatic forceps or alternatively compressed with a forceps padded with absorbable Surgicel[®] after which the vein is sealed and divided with an Endo-GIA vascular stapler.

[®]Ethicon, Somerville, NJ.

Injury to surrounding structures is avoided by maintaining surgical orientation, recognition of retroperitoneal landmarks, and meticulous dissection.

SUMMARY

- Despite the skepticism, the technique of retroperitoneal laparoscopic radical nephrectomy evolved into a standardized approach.
- The indications for laparoscopic retroperitoneal radical nephrectomy are similar to the indications for open radical nephrectomy.
- Precise dissection between the psoas muscle and the posterior aspect of Gerota's fascia is critical. In fact, failure to do so will adversely affect retroperitoneal balloon dilation.
- Because the working space in the retroperitoneum is small, optimal placement of the secondary working ports is also critical.
- Placement of the posterior port 1.5 cm below the 12th rib and 1.5 cm above the psoas will result in safe port placement.
- If a hole in the peritoneum occurs early in the procedure, the surgeon may elect to convert the procedure to a transperitoneal approach.
- The most efficacious way to prevent extension of CO₂ gas through the tissue is to limit CO₂ gas insufflation to 12–15 mm Hg pressure.
- Bleeding from the renal hilum is avoided by meticulous dissection with circumferential control and isolation of the vessels prior to applying clips or the vascular endo-GIA stapler.
- Injury to surrounding structures is avoided by maintaining surgical orientation, recognition of retroperitoneal landmarks, and meticulous dissection.

REFERENCES

1. Gaur DD, Rath SS, Ravandale AV, et al. A single-centre experience of retroperitoneoscopy using the balloon technique. *BJU Int* 2001; 87:602–606.
2. McDougall EM, Clayman RV. Laparoscopic nephrectomy for benign disease: comparison of the transperitoneal and the retroperitoneal approaches. *J Endourol* 1996; 10:45–49.
3. Rassweiler JJ, Fournara P, Weber M, et al. Laparoscopic nephrectomy: the experience of the laparoscopic working group of the German Urologic Association. *J Urol* 1998; 160:18–21.
4. McDougall EM, Clayman RV, Fadden PT. Retroperitoneoscopy: the Washington University Medical School experience. *Urology* 1994; 43:446–452.
5. Capelouto CC, Moore RG, Silverman SG, et al. Retro-peritoneoscopy: anatomical rationale for direct retroperitoneal access. *J Urol* 1994; 152:2008–2010.
6. Rassweiler JJ, Seemann O, Frede T, et al. Retroperitoneoscopy: experience with 200 cases. *J Urol* 1998; 160:1265–1269.
7. Gill IS, Cherullo EE, Meraney AM, et al. Vaginal extraction of the intact specimen following laparoscopic radical nephrectomy. *J Urol* 2002; 167(1):238–241.
8. Meraney AM, Samee AA, Gill IS. Vascular and bowel complications during retroperitoneal laparoscopic surgery. *J Urol* 2002; 168:1941–1944.
9. Abbou CC, Cicco D, Gasman D, et al. Retroperitoneal laparoscopic versus open radical nephrectomy. *J Urol* 1999; 161:1776–1780.
10. Cicco A, Salomon L, Hoznek A et al. Results of retroperitoneal laparoscopic radical nephrectomy. *J Endourol* 2001; 15(4):355–359.
11. Figenshau RS, Clayman RV, Kavoussi LR, et al. Retroperitoneal laparoscopic nephrectomy: laboratory and initial clinical experience. *J Endourol* 1991; 5:130.
12. Gaur DD. Laparoscopic operative retroperitoneoscopy: use of a new device. *J Urol* 1992; 148:1137–1139.
13. Gasman D, Saint F, Barthclemey Y, et al. Retroperitoneoscopy: a laparoscopic approach for adrenal and renal surgery. *Urology* 1996; 47:801–806.
14. Gaur DD, Agarwal DK, Purohit KC. Retroperitoneal laparoscopic nephrectomy: initial Case Report. *J Urol* 1993; 149(1):103–105.
15. Gaur DD. The accurate placement of the balloon for retroperitoneal dissection by the percutaneous method, ensuring that it expands in the right plane. *BJU Int* 1999; 84:1095–1096.
16. Gill IS. Retroperitoneal laparoscopic nephrectomy. *Urol Clin North Am* 1998; 25:343.
17. Gill IS, Munch LC, Lucas BA. Access technique for retroperitoneoscopy. *J Urol* 1996; 156:1120–1124.
18. Gill IS, Rassweiler JJ. Retroperitoneoscopic renal surgery: our approach. *Urology* 1994; 54:734–738.
19. Gill IS, Clayman RV, Albala DM, et al. Retroperitoneal and pelvic extraperitoneal laparoscopy: an international perspective. *Urology* 1998; 52: 566–571.
20. Gill IS, Schweizer D, Hobart MG, et al. Retroperitoneal laparoscopic radical nephrectomy: the Cleveland Clinic experience. *J Urol* 2000; 163:1665–1670.
21. Kerbl K, Figenshau RS, Clayman RV, et al. Retroperitoneal laparoscopic nephrectomy: laboratory and clinical experience. *J Urol* 1993; 7:23–26.
22. Kumar M, Kumar R, Hemal AK, et al. Complications of retroperitoneoscopic surgery at one centre. *BJU Int* 2001; 87:607–612.
23. Martin SF, Gill IS. Modified Pfannenstiel incision for intact specimen extraction after retroperitoneoscopic renal surgery. *Urology* 2003; 61(4):830–832.
24. Martin SF, Gill IS. Laparoscopic radical nephrectomy: retroperitoneal versus transperitoneal approach. *Curr Urol Rep* 2002; 3(2):164–171.
25. Ono Y, Katoh N, Kinkawa T, et al. Laparoscopic nephrectomy via the retroperitoneal approach. *J Urol* 1996; 156:1101–1104.
26. Rassweiler JJ, Henkel TO, Stoch C, et al. Retroperitoneal laparoscopic nephrectomy and other procedures in the upper retro peritoneum using a balloon dissection technique. *Euro Urol* 1994; 25:229–236.

LAPAROSCOPIC RADICAL NEPHRECTOMY: CURRENT STATUS

Isaac Yi Kim and Ralph V. Clayman

Department of Urology, University of California, Orange, California, U.S.A.

- INTRODUCTION
- SURGICAL APPROACHES
 - Transperitoneal Laparoscopic Radical Nephrectomy
 - Hand-Assisted Laparoscopic Radical Nephrectomy
 - Retroperitoneoscopic Radical Nephrectomy
- INTRAOPERATIVE AND PERIOPERATIVE RESULTS
- ONCOLOGIC OUTCOME
- COMPLICATIONS
- FUTURES
- SUMMARY
- REFERENCES
- COMMENTARY: R. C. Flanigan

INTRODUCTION

The first laparoscopic nephrectomy was successfully performed in an 85-year-old woman with a 3-cm solid renal mass at Washington University, St. Louis, Missouri in 1990 (1). Five ports and 6 hours and 45 minutes later, the specimen was removed by morcellation. Oncocytoma was the final diagnosis. Since this pioneering work, the urologic community has accepted laparoscopic radical nephrectomy as a viable surgical option for renal cell carcinoma. The technique itself has evolved into three categories based on surgical approaches including (i) the pure transperitoneal laparoscopic procedure, (ii) the hand-assisted laparoscopic procedure, and (iii) the retroperitoneal procedure.

SURGICAL APPROACHES

The comparison of standard transperitoneal laparoscopy, hand-assisted laparoscopy, and retroperitoneoscopy is shown in Table 1. Overall, the three approaches do not have any significant difference in estimated blood loss, complication rate, amount of analgesic used, length of hospital stay, and time for convalescence (2–5).

Transperitoneal Laparoscopic Radical Nephrectomy

The transperitoneal approach is the most widely used technique because it optimizes movements of instruments by offering a wide working space and providing maximum distance between working ports. Another potential advantage of the transperitoneal laparoscopic radical nephrectomy is that the procedure can easily be converted to a hand-assisted approach in difficult cases.

The advantages of the transperitoneal approach are most obvious in standard laparoscopic cases where a large specimen is entrapped and morcellated prior to removal to minimize the length of incision.

The main disadvantage of the standard transperitoneal laparoscopic radical nephrectomy is the nearly one hour longer operative time compared to the retroperitoneal and hand-assisted approaches (6).

In circumstances where the plan is to remove the specimen intact, some authors have advocated the use of either a hand-assisted transperitoneal or a retroperitoneal approach. Specimen entrapment, with the latter approach, is more difficult.

Hand-Assisted Laparoscopic Radical Nephrectomy

In hand-assisted laparoscopic radical nephrectomy, a 7–8 cm incision is usually required to accommodate the surgeon's nondominant hand.

The transperitoneal approach is the most widely used technique: It optimizes movements of instruments by offering a wide working space and maximum distance between working ports. The procedure can easily be converted to a hand-assisted approach in difficult cases.

The main disadvantage of the standard transperitoneal laparoscopic radical nephrectomy is the additional hour in operative time compared to the retroperitoneal and hand-assisted approaches.

TABLE 1 ■ Operative Results of Transperitoneal Laparoscopy, Hand-Assisted Transperitoneal Laparoscopy, and Retroperitoneoscopy for Nephrectomy in Patients with Renal Cell Cancer

	Transperitoneal laparoscopy	Hand-assisted transperitoneal laparoscopy	Retroperitoneoscopy
Numbers	16 ^a /43 ^b /13 ^c	12 ^d /22 ^a /8 ^c	12 ^d /45 ^b
OR time (hr)	4.5 ^a /3.4 ^b /2.8 ^c	4.0 ^d /3.4 ^a /2.8 ^c	4.3 ^d /2.6 ^b
Estimated blood loss (mL)	289 ^a /190 ^b /125 ^c	293 ^d /191 ^a /410 ^c	142 ^d /233 ^b
Mean morphine sulfate equivalent (mg)	30 ^a /26 ^b /23 ^c	35.7 ^d /31 ^a /41 ^c	24.5 ^d /21 ^b
Hospital stay (day)	2.4 ^a /1.7 ^b /1.3 ^c	4.4 ^d /2.7 ^a /2.6 ^c	3.6 ^d /1.6 ^b
Convalescence		75% ^d (at 2 wk)	77% ^d (at 2 wk)
Complications (major)	13% ^a /16% ^b /7.7% ^c	8% ^d /23% ^a /25% ^c	8% ^d /12% ^b
Complications (minor)	45% ^a /12% ^b /0% ^c	25% ^a /25% ^c	4% ^b

^aRef. 2.
^bRef. 3.
^cRef. 4.
^dRef. 5.
Abbreviation: OR, operating room.

Some authors have advocated the use of hand-assist devices because they can act as a bridge between open and purely laparoscopic surgery; to wit, in most circumstances, hand-assisted laparoscopic radical nephrectomy has reduced operating room time when compared to standard or, in some series, even retroperitoneal laparoscopic approaches.

Some authors have advocated the use of hand-assist devices because they can act as a bridge between open and purely laparoscopic surgery; to wit, in most circumstances, hand-assisted laparoscopic radical nephrectomy has reduced operating room time when compared to standard or, in some series, even retroperitoneal laparoscopic approaches (2,6,7).

Major disadvantages of the hand-assisted approach include difficult placements of working ports in small patients, hand fatigue, larger incisional scar, and increased rate of wound complications (8,9). Nevertheless, when compared to the standard laparoscopic approach, the use of the larger incision for the hand port did not translate into meaningful increases in the postoperative convalescence time (3,6,7,10). There are six types of commercially available hand ports at the present time. Although each device has its own merits, no clear pattern of preference was seen among laparoscopists (11). In general, we recommend a device that is self-coapting (e.g., LapDisc^a or GelPort^b), because this allows the surgeon to use either hand, eliminates the use of cuffs or sleeves, and provides rapid entry and exit.

Retroperitoneoscopic Radical Nephrectomy

The retroperitoneoscopic radical nephrectomy avoids the need to mobilize the colon and the surrounding organs in gaining access to the kidney while the renal artery is encountered early during the procedure.

Although hospital stay and convalescence are similar, operative times have been reported to be faster than the standard transperitoneal approach by as much as 30% (12). In patients who need peritoneal dialysis or have a history of multiple abdominal procedures, retroperitoneal radical nephrectomy is the surgical approach of choice.

The main disadvantage of the retroperitoneal approach is the small working space that largely precludes specimen entrapment and morcellation. As a result, the specimen is removed either transvaginally or with a muscle splitting flank or a Pfannenstiel incision (13,14). Also, most of these specimens are removed without first being entrapped in an impermeable sack; this practice risks possible wound contamination because the specimen is manipulated and pulled through a "tight" skin incision (15).

INTRAOPERATIVE AND PERIOPERATIVE RESULTS

In the world's literature, over 640 laparoscopic radical nephrectomies have been reported to date. The standard transperitoneal approach is the most commonly used technique, followed by hand-assisted, and lastly the retroperitoneoscopic method. Among the studies that have analyzed the operative results of laparoscopic radical nephrectomy (16–25),

Although hospital stay and convalescence are similar, operative times have been reported to be faster than the standard transperitoneal approach by as much as 30%. In patients who need peritoneal dialysis or have a history of multiple abdominal procedures, retroperitoneal retroperitoneoscopic radical nephrectomy is the surgical approach of choice.

^aEthicon Inc., Cincinnati, OH.

^bApplied Medical Resources, Rancho Santa Margarita, CA.

TABLE 2 ■ Comparison of Operative Results Between Laparoscopic Radical Nephrectomy and Open Radical Nephrectomy

	Dunn et al. (16)		Portis et al. (17)		Chan et al. (18)		Saika et al. (19)		Makhoul et al. (20)		Shuford et al. (21)	
Procedure	Lap ^a	Open	Lap ^b	Open	Lap ^c	Open	Lap ^d	Open	Lap ^e	Open	Lap ^f	Open
Number	61	33	64	69	67	54	195	68	39	26	33	41
OR time (min)	330	168	287	128	256	193	275.7	203.1	134	133	—	—
Estimated blood loss (mL)	172	451	219	354	289	309	248.5	482.0	133	357	246	371
Hospital stay (day)	3.4	5.2	4.8	7.4	3.8	7.2	—	—	5.5	8.8	1.7	3.6
Time to full convalescence (day)	25.2	56.7	—	—	—	—	22.7	58.7	—	—	—	—
Conversion rate (%)	1.6	—	—	—	1.5	—	3.6	—	—	—	3.3 ^g	—
Tumor size (cm)	5.3	7.4	4.3	6.2	5.1	5.4	3.7	4.4	3.93	4.8	4.6	7.4
Stage	T1, T2, T3	pT1, pT2, pT3	T1, T2	pT1, pT2	T1, T2, T3	pT1, pT2	pT1	pT1	pT1	pT1	—	—

^a55 transperitoneal, 3 retroperitoneal, and 3 combined transperitoneal and retroperitoneal laparoscopic radical nephrectomies.

^b52 transperitoneal and 12 retroperitoneal laparoscopic radical nephrectomies.

^c66 transperitoneal and 1 retroperitoneal laparoscopic radical nephrectomies.

^d177 transperitoneal and 18 retroperitoneal laparoscopic radical nephrectomies.

^eAll retroperitoneal laparoscopic radical nephrectomies.

^f15 transperitoneal, 18 hand-assisted laparoscopic radical nephrectomies.

^gConversion done electively for tumor extension into renal hilum.

Abbreviation: OR, operating room.

Overall, it takes longer to complete laparoscopic radical nephrectomy than open radical nephrectomy. However, laparoscopy groups tended to have smaller estimated blood loss, shorter length of hospital stay, and lower amount of analgesic use.

There are cosmetic advantages to laparoscopy; it was recently reported that a flank bulge following a standard flank incision was detected in almost 50% of patients.

Laparoscopy does not compromise oncologic outcome as long as the principles of surgical oncology are strictly followed.

Table 2 summarizes the six studies that compared the results of laparoscopic radical nephrectomy with those of contemporary series of open radical nephrectomy.

Overall, it takes longer to complete laparoscopic radical nephrectomy than open radical nephrectomy. However, laparoscopy groups tended to have smaller estimated blood loss, shorter length of hospital stay, and lower amount of analgesic use.

The time to convalescence for laparoscopy ranged from 23 to 25 days whereas that of the open procedure ranged from 57 to 59 days. The conversion rate to an open procedure was 1.5% to 3.6%.

The cosmetic advantage of laparoscopy is also evident as it was recently reported that a flank bulge following a standard flank incision was detected in almost 50% of patients (26).

ONCOLOGIC OUTCOME

The long-term follow-up data have clearly demonstrated that the results of laparoscopic and open retroperitoneoscopic radical nephrectomy are comparable (Table 3). The largest series to date was published by Saika et al. and showed that the five-year disease-specific survival was 94% in 195 patients treated with either a transperitoneal or a retroperitoneal laparoscopic radical nephrectomy for pathologic T1 renal cell carcinoma (19). Portis et al. (17) and Chan et al. (18) reported the five-year cancer-specific survival to be 98% and 86%, respectively, in smaller studies. The five-year disease-specific survival rate in two contemporary studies that examined the oncologic outcome after the traditional open nephrectomy for T1 renal cell carcinoma was 83% and 94% (27,28).

Laparoscopy does not compromise oncologic outcome as long as the principles of surgical oncology are strictly followed.

TABLE 3 ■ Comparison of Contemporary Oncological Outcome Data after Laparoscopic vs. Open Radical Nephrectomy

Authors	Approach	Patients	Mean follow-up (mo)	Stage	5-yr cancer-specific survival (%)
Chan et al. (18)	Lap	67	35.6	T1, T2	86
Portis et al. (17)	Lap	64	54	T1, T2	98
Saika et al. (19)	Lap	188	40	T1	94
Javidan et al. (27)	Open	205	—	T1	95
Tsui et al. (28)	Open	227	47	T1	83

In the literature, there are four cases of port-site seeding that have been reported after a laparoscopic radical nephrectomy for renal cell carcinoma; three cases involve morcellation of specimens and one case involves a recurrence at a hand-port site. In 2000, Fentie et al. reported the first recurrence in which the patient had a large Fuhrman grade IV/IV tumor, with sarcomatoid features (29); the specimen was entrapped and morcellated in a LapSac^c. The authors noted that there was no leakage of contents from the sack during the fragmentation procedure. Castilho et al. reported the second case in 2001 (30). In this case, the surgical team used a plastic entrapment device for intra-abdominal morcellation of a Grade II, T1 renal cell cancer in a patient with ascites. These same authors also reported the third occurrence in a letter to the editor, again in a Grade II, T1 patient (31). These last two cases demonstrate the dangers of morcellation in patients with ascites and of intra-abdominal morcellation in non-nylon re-enforced plastic sack. It is noteworthy that there has been not a single case of seeding noted in the Johns Hopkins, Washington University, or University of Nagoya experience despite over a decade of laparoscopic radical nephrectomy at all three institutions in more than 300 patients among whom the majority had the specimen entrapped and morcellated.

Recommendations to minimize the risk of tumor seeding and spillage during the morcellation process (32) follow:

Recommendations to minimize the risk of tumor seeding and spillage during the morcellation process.

- Only a LapSac should be used, for intra-abdominal morcellation.
- Morcellation should not be used if the patient has ascites.
- The surgical team must be vigilant in monitoring the pneumoperitoneum and LapSac during morcellation. Leakage from the sack should prompt immediate enlargement of the incision and intact removal.
- The neck of the sack should be triply draped.
- After morcellation, the surgeon and the assistant should change gloves and gowns and remove the three drapes that came into contact with the neck of the sack.
- The site of morcellation can be swabbed with Betadine after removal of the LapSac.

- Only a LapSac should be used, specifically for intra-abdominal morcellation, because it is constructed of a double layer of plastic and nondistensible nylon that is impermeable to bacteria and cells (33).
- Morcellation should not be used if the patient has ascites.
- The surgical team must be vigilant in monitoring the pneumoperitoneum and LapSac during morcellation; the entire process must be done under endoscopic control and any leakage seen from the sack should prompt immediate enlargement of the incision and intact removal.
- The neck of the sack should be triply draped.
- After morcellation, the surgeon and the assistant should change gloves and gowns and remove the three drapes that came into contact with the neck of the sack.
- The site of morcellation can be swabbed with Betadine after removal of the LapSac.

The lone case of hand-port site metastasis occurred in a patient with a 10 × 7 cm pT2 Fuhrman grade 3 renal cell carcinoma where the surgical team extracted the specimen without entrapment through an 8-cm midline incision (15). This report shows the potential danger of extracting untrapped specimens. Indeed, in the editorial comment immediately following the aforementioned report, Nakada suggested that an entrapment sack be used to extract all tumor-bearing specimens after hand-assisted laparoscopic radical nephrectomies (34).

COMPLICATIONS

At the beginning of the surgery, the surgical team must be prepared for the possibility that an emergent open conversion may be necessary at any point during the procedure. Therefore, a general laparotomy set with vascular clamps must be available during the entire operation. Complications associated with laparoscopic radical nephrectomy may be divided into three categories: access related, intraoperative, and postoperative. As with any surgical technique, laparoscopic radical nephrectomy is associated with a significant learning curve. In a multi-institutional review involving 185 patients, it was noted that 71% of complications occurred during the initial 20 cases at each institution (35).

The rate of major complications following laparoscopic nephrectomy has ranged from 3.3% to 15% (Table 4) (12,16,18,21,36–39).

In the largest series, Siqueira et al. reported on the experience at Indiana University with 213 standard transperitoneal laparoscopic nephrectomy cases; of these, there were 61 radical nephrectomies, 81 live donor nephrectomies, 55 simple nephrectomies, and 13 nephroureterectomies (36). In this study, the major complication rate was 7.5% and the open conversion rate was 6%. Access-related complications included abdominal wall hematoma and liver injury in one and two patients, respectively, while intraoperative complications occurred in 11 patients. Intraoperative complications were composed of uncontrollable bleeding, injuries to spleen, injuries to bowel, and failed entrapment in seven, one, two, and one patient(s), respectively. Open conversion was

^cCook Urological Inc., Spencer, IN.

TABLE 4 ■ Major Complication Rates after Laparoscopic Radical Nephrectomy

	Number	Procedure	Major complications (%)
Dunn et al. (16)	61	Transperitoneal	3 (10)
Chan et al. (18)	67	Transperitoneal	10 (15)
Siqueira et al. (36)	213	Transperitoneal	16 (7.5)
Wille et al. (37)	125	Transperitoneal	7 (5.6)
Shuford et al. (21)	33	Transperitoneal, hand-assisted	1 (3.3)
Patel and Leveillee (38)	60	Hand-assisted	3 (5)
Lee et al. (12)	54	Hand-assisted	7.4 (4)
Cicco et al. (39)	50	Retroperitoneal	2 (4)

performed emergently in five and electively in eight patients. Postoperatively, the authors noted one case each of a respiratory distress requiring an endotracheal intubation and a gastrointestinal bleeding secondary to an inflamed duodenal ulcer.

FUTURES

Laparoscopic radical nephrectomy is being applied in two new areas: cytoreductive surgery and tumors with renal vein and small inferior vena caval thrombi.

Walther et al. first noted that patients undergoing laparoscopic cytoreductive surgery for renal cell carcinoma came to be treated nearly 30 days earlier than patients who had traditional open procedures (40). Mosharafa et al. also reported similar findings (41).

In another area, to date, nine cases of laparoscopic treatment of patients with T3b (renal vein involvement) have been successfully undertaken; blood loss has averaged 350 cc with a 3.3-hours operative time and a 2.3-day hospital stay (42–45). Indeed Sundaram et al. have recently reported treating a small inferior vena caval thrombus laparoscopically (46).

To date, a subhepatic thrombus with cavotomy has not been done laparoscopically; but it is likely only a matter of time before this is accomplished, as laparoscopic radical nephrectomy with level II vena caval thrombectomy has been reported in an experimental porcine model (47).

It has been noted that patients undergoing laparoscopic cytoreductive surgery for renal cell carcinoma were treated nearly 30 days earlier than patients who had traditional open procedures.

To date, a subhepatic thrombus with cavotomy has not been done laparoscopically. It is likely only a matter of time before this is accomplished, as laparoscopic radical nephrectomy with level II vena caval thrombectomy has been reported in an experimental porcine model.

SUMMARY

- Significant progress has been made since the first case of laparoscopic nephrectomy 14 years ago.
- As demonstrated by numerous studies, laparoscopic radical nephrectomy has clearly decreased patient morbidity while duplicating the standards of the open procedure.
- The spread of laparoscopic renal surgery among many urologic surgeons has been aided by the development of hand-assisted techniques along with better modalities for achieving hemostasis (Hem-O-Lok clips, bipolar devices, harmonic shears, argon beam coagulation, etc.).
- At this time, laparoscopic radical nephrectomy has become a “new” standard surgical technique for treating patients with localized renal cell carcinoma and it is applicable to T1a (i.e., not amenable to a partial nephrectomy), all T1b, most T2 (i.e., tumor <15 cm), and T3a stages of renal cell carcinoma

REFERENCES

1. Clayman RV, Kavoussi LR, Soper NJ, et al. Laparoscopic nephrectomy: initial case report. *J Urol* 1991; 146:278–282.
2. Batler RA, Campbell SC, Funk JT, Gonzalez CM, Nadler RB. Hand-assisted vs. retroperitoneal laparoscopic nephrectomy. *J Endourol* 2001; 15:899–902.
3. Nelson CP, Wolf JS. Comparison of hand assisted versus standard laparoscopic radical nephrectomy for suspected renal cell carcinoma. *J Urol* 2002; 167:1989–1994.
4. Gill I, Strzempkowski B, Kaouk J, et al. Prospective randomized comparison: transperitoneal vs retroperitoneal laparoscopic radical nephrectomy. *J Urol* 2002; 167:abstract 78.
5. Baldwin DD, Dunbar JA, Parekh DJ, et al. Single-center comparison of pure laparoscopic, hand-assisted laparoscopic, and open radical nephrectomy in patients at high anesthetic risk. *J Endourol* 2003; 17:161–167.

6. Kercher KW, Joels CS, Matthews BD, Lincourt AE, Smith TI, Henriford BT. Hand-assisted surgery improves outcome for laparoscopic nephrectomy. *Am Surg* 2003; 69:1061–1066.
7. Wolf JS Jr. Hand-assisted laparoscopy: pro. *Urology* 2001; 58:310–312.
8. Okeke AA, Timoney AG, Keeley FX Jr. Hand-assisted laparoscopic nephrectomy: complications related to the hand-port site. *BJU Int* 2002; 90:364–367.
9. Gill IS. Hand-assisted laparoscopy: con. *Urology* 2001; 58:313–317.
10. Wolf JS Jr., Moon TD, Nakada SY. Hand assisted laparoscopic nephrectomy: comparison to standard laparoscopic nephrectomy. *J Urol* 1998; 160:22–27.
11. Stifelman M, Nieder AM. Prospective comparison of hand-assisted laparoscopic devices. *Urology* 2002; 59:668–672.
12. Lee SE, Ku JH, Kwak C, Kim HH, Paick SH. Hand assisted laparoscopic radical nephrectomy: comparison with open radical nephrectomy. *J Urol* 2003; 170:756–759.
13. Gill IS, Cherullo EE, Meraney AM, Borsuk F, Murphy DP, Falcone T. Vaginal extraction of the intact specimen following laparoscopic radical nephrectomy. *J Urol* 2002; 167:238–241.
14. Matin SR, Gill IS. Modified Pfannenstiel incision for intact specimen extraction after retroperitoneoscopic renal surgery. *Urology* 2003; 61:830–832.
15. Chen YT, Yang SSD, Hsieh CH, Wang CC. Hand port-site metastasis of renal-cell carcinoma following hand-assisted laparoscopic radical nephrectomy: case report. *J Endourol* 2003; 17:771–773.
16. Dunn MD, Portis AJ, Shalhav AL, et al. Laparoscopic versus open radical nephrectomy: a 9-year experience. *J Urol* 2000; 164:1153–1159.
17. Portis AJ, Yan Y, Landman J, et al. Long-term followup after laparoscopic radical nephrectomy. *J Urol* 2002; 167:1257–1262.
18. Chan DY, Cadeddu JA, Jarret TW, Marshall FF, Kavoussi LR. Laparoscopic radical nephrectomy: cancer control for renal cell carcinoma. *J Urol* 2001; 166:2095–2100.
19. Saika T, Ono Y, Hattori R, et al. Long-term outcome of laparoscopic radical nephrectomy for pathologic T1 renal cell carcinoma. *Urology* 2003; 62:1018–1023.
20. Makhoul B, De la Taille A, Vordos D, et al. Laparoscopic radical nephrectomy for T1 renal cancer: the gold standard? A comparison of laparoscopic vs open nephrectomy. *Br J Urol Int* 2004; 93:67–70.
21. Shuford MD, McDougall EM, Chang SS, LaFleur BJ, Smith JA, Cookson MS. Complications of contemporary radical nephrectomy: comparison of open vs laparoscopic approach. *Urol Oncol* 2004; 22:121–126.
22. Cadeddu JA, Ono Y, Clayman RV, et al. Laparoscopic nephrectomy for renal cell cancer: evaluation of efficacy and safety: a multicenter experience. *Urology* 1998; 52:773–777.
23. Ono Y, Kinukawa T, Hattori R, et al. Laparoscopic radical nephrectomy for renal cell carcinoma: a five year experience. *Urology* 1999; 53:280–286.
24. Barrett PH, Fentie DD, Taranger LA. Laparoscopic radical nephrectomy with morcellation for renal cell carcinoma: the Saskatoon experience. *Urology* 1998; 52:23–28.
25. Janetschek G, Jeschke K, Peschel R, Strohmeier D, Henning K, Bartsch G. Laparoscopic surgery for renal cell carcinoma: radical and partial nephrectomy. *J Endourol* 2000; 14(7 suppl):A45.
26. Chatterjee S, Nam R, Fleshner N, Klotz L. Permanent flank bulge is a consequence of flank incision for radical nephrectomy in one half of patients. *Urol Oncol* 2004; 22:36–39.
27. Javidan J, Stricker HJ, Tamboli P, et al. Prognostic significance of the 1997 TNM classification of renal cell carcinoma. *J Urol* 1999; 162:1277–1281.
28. Tsui K-H, Shvarts O, Smith RB, Figlin RA, deKernion JB, Belldgrun A. Prognostic indicators for renal cell carcinoma: a multivariate analysis of 643 patients using the revised 1997 TNM staging criteria. *J Urol* 2000; 163:1090–1095.
29. Fentie DD, Barrett PH, Taranger LA. Metastatic renal cell cancer after laparoscopic radical nephrectomy: long-term follow-up. *J Endourol* 2000; 14:407–411.
30. Castilho LN, Fugita OEH, Mitre AI, Arap S. Port site tumor recurrences of renal cell carcinoma after videolaparoscopic radical nephrectomy. *J Urol* 2001; 165:519.
31. Castilho LN, Fugita OEH, Mitre AI, Arap S. Report site recurrences of renal cell carcinoma after videolaparoscopic radical nephrectomy. *J Urol* 2001; 166:629–630.
32. Landman J, Clayman RV. Report site tumor recurrences of renal cell carcinoma after videolaparoscopic radical nephrectomy. *J Urol* 2001; 166:629–630.
33. Urban DA, Kerbl K, McDougall EM, Stone AM, Fadden PT, Clayman RV. Organ entrapment and renal morcellation: permeability studies. *J Urol* 1993; 150:1792–1794.
34. Nakada SY. Editorial comment for: Hand port-site metastasis of renal-cell carcinoma following hand-assisted laparoscopic radical nephrectomy: case report. *J Endourol* 2003; 17:774.
35. Gill IS, Kavoussi LR, Clayman RV, et al. Complications of laparoscopic nephrectomy in 185 patients: a multi-institutional review. *J Urol* 1995; 154:479–483.
36. Siqueira TM Jr., Kuo RL, Gardner TA, et al. Major complications in 213 laparoscopic nephrectomy cases: the Indianapolis experience. *J Urol* 2002; 168:1361–1365.
37. Patel VR, Leveillee RJ. Hand-assisted laparoscopic nephrectomy for stage T1 and large stage T2 renal tumors. *J Endourol* 2002; 17:379–383.
38. Cicco A, Salomon L, Hoznek A, et al. Results of retroperitoneal laparoscopic radical nephrectomy. *J Endourol* 2001; 15:355–359.
39. Wille AH, Roigas J, Deger S, Tullmann M, Turk I, Loening SA. Laparoscopic radical nephrectomy: techniques, results, and oncologic outcome in 125 consecutive cases. *Eur Urol* 2004; 45:483–489.
40. Walther MM, Lyne JC, Libutti SK, Linehan WM. Laparoscopic cytoreductive nephrectomy as preparation for administration of systemic interleukin-2 in the treatment of metastatic renal cell carcinoma: a pilot study. *Urology* 1999; 53:496–501.
41. Mosharafa A, Koch M, Shalhav A, et al. Nephrectomy for metastatic renal cell carcinoma: Indiana University experience. *Urology* 2003; 62:636–640.
42. Desai MM, Gill IS, Ramani AP, Matin SF, Kaouk JH, Campero JM. Laparoscopic radical nephrectomy for cancer with level I renal vein involvement. *J Urol* 2003; 169:487–491.
43. Savage SJ, Gill IS. Laparoscopic radical nephrectomy for renal cell carcinoma in a patient with level I renal vein tumor thrombus. *J Urol* 2000; 163:1243–1244.

44. McDougall EM, Clayman RV, Elashry OM. Laparoscopic radical nephrectomy for renal tumor: the Washington University experience. *J Urol* 1996; 155:1180–1185.
45. Hsu TH, Jeffrey RB Jr., Chon C, Presti JC Jr. Laparoscopic radical nephrectomy incorporating intra-operative ultrasonography for renal cell carcinoma with renal vein tumor thrombus. *Urology* 2003; 61:1246–1248.
46. Sundaram CP, Rehman J, Landman J, Oh J. Hand assisted laparoscopic radical nephrectomy for renal cell carcinoma with inferior vena caval thrombus. *J Urol* 2002; 168:176–179.
47. Fergany AF, Gill IS, Schweizer DK, et al. Laparoscopic radical nephrectomy with level II vena caval thrombectomy: survival porcine study. *J Urol* 2002; 168:2629–2631.

COMMENTARY

R. C. Flanigan

Department of Urology, Loyola University of Chicago, Chicago, Illinois, U.S.A.

Certainly no one should underestimate the current value of laparoscopic nephrectomy or the skill and foresight of those who developed this technique. Nor should we underestimate the potential benefits to a patient who may experience less morbidity after nephrectomy when it is accomplished laparoscopically. On the other hand, there remain several important unanswered questions regarding the use of laparoscopic nephrectomy:

1. Will it be widely available?
2. How does a clinician retain the necessary skills to perform it safely and effectively?
3. Are decisions concerning the appropriateness of nephron-sparing surgery versus laparoscopic nephrectomy being made appropriately?
4. What are the limits of laparoscopic nephrectomy; is it indicated for large or high-stage cancers?

In this excellent review, Drs. Kim and Clayman have detailed the current experience with the various laparoscopic approaches to nephrectomy. As with many other areas of emerging practices, the real problem with comparative analyses of techniques is patient selection. Comparing “contemporary” series of open and laparoscopic cases or even cases of hand-assisted versus pure laparoscopy, even when patients are “matched” for tumor size, etc., by definition excludes the thought process that caused the surgeon to select one technique over another. This being said, there does not seem to be a disadvantage in terms of cancer management of organ-confined renal cancers when laparoscopic nephrectomy is used. What are the limits of this technique? Recent experience suggests that in very experienced hands, large tumors (greater than 7 cm) can be treated with similar complication rates as that seen in smaller tumors. The real issue for the individual surgeon is to know his/her limits, i.e., patient selection is imperative.

Given the facts that (i) the average urologist currently performs one to two nephrectomies per year and (ii) urology does not have a “commonly performed” laparoscopic procedure (e.g., cholecystectomy in general surgery practice), how does a surgeon, even one who is adequately trained, maintain competency in laparoscopy nephrectomy? It seems that the only realistic answer to this problem is referral of these procedures to experienced laparoscopically trained urologists inside or outside of one’s practice.

Another area of concern is the dilemma of nephron-sparing surgery versus laparoscopic total nephrectomy. To date, nephron-sparing surgery seems to provide equal oncologic value in selected patients with localized renal cancer. What are the appropriate limits of nephron-sparing surgery and is it better for the patient to undergo a laparoscopic total nephrectomy or open nephron-sparing surgery? Patient selection, based on the depth of tumor involvement of the kidney, patient age, comorbidities, etc., is the key. Again the physician’s self-judgment of his/her ability to perform any procedure safely and effectively should direct the approach used.

Finally, what limits should we apply to laparoscopic nephrectomy? Recent data from institutions with a wide experience with laparoscopic nephrectomy suggests that tumors greater than 7 cm in diameter can be removed with similar safety (complication rates, blood loss, length of stay, etc.) as is seen with smaller tumors. On the other hand, when large tumors involve extension to adjacent organs, blood vessels, and/or lymphatics, laparoscopic techniques probably are not currently indicated.

In summary, although laparoscopic nephrectomy is a gold standard (along with open nephrectomy and nephron-sparing surgery) for the management of localized renal cancers, it cannot be said too often that patient selection and an honest appraisal of one's expertise with any procedure is the key to management.

The surgical approach to removal of renal tumors is, and will continue to be, a moving target, as new techniques and systemic therapies are developed. It would seem clear that the urologic community should embrace research, which will yield less invasive, more effective therapies for this disease, which kills over 10,000 Americans annually.

SMALL RENAL TUMORS: OVERVIEW AND MANAGEMENT BY ACTIVE SURVEILLANCE

Alessandro Volpe and Michael A. S. Jewett

Division of Urology, Department of Surgical Oncology, Princess Margaret Hospital and the University Health Network, University of Toronto, Toronto, Ontario, Canada

■ NATURAL HISTORY OF SMALL RENAL TUMORS
■ ACTIVE SURVEILLANCE OF SMALL RENAL TUMORS

■ SUMMARY
■ REFERENCES
■ COMMENTARY : Morton A. Bosniak

The increasing incidence of renal cell carcinoma has occurred in all age groups and in all clinical stages, but the greatest increase has been observed in localized tumors, which increased by 3.7% per year from 1973 to 1998.

There are numerous reports that the incidentally detected lesions are on average smaller and present at an earlier stage than those detected in symptomatic patients.

Small asymptomatic tumors are more frequently benign. If proven to be renal cell carcinoma, they are on average lower grade than symptomatic ones.

Malignant tumors of the kidney cause about 2% of cancer incidence and mortality in the United States. It was estimated that 31,900 new cases of kidney cancer were diagnosed in 2003 and there were 11,900 deaths (1,2).

Since 1950, there has been a 126% increase in the incidence of renal cell carcinoma in the United States (3). Between 1975 and 1995, the incidence has been increasing by 2.3% annually among white and 3.9% among black men (4). A raising trend has been observed worldwide and is due in part to the widespread use of new and improved noninvasive abdominal imaging modalities, such as ultrasonography, computed tomography, and magnetic resonance imaging (3–14). The number of abdominal radiological examinations has been increasing steadily in the last two decades and almost doubled between 1986 and 1994 (4).

The increasing incidence of renal cell carcinoma has occurred in all age groups and in all clinical stages, but the greatest increase has been observed in localized tumors, which increased by 3.7% per year from 1973 to 1998 (4,7).

Most renal cell carcinoma are now incidentally detected by imaging as small renal masses in asymptomatic patients, while historically almost 80% of renal tumors presented with flank pain and/or hematuria. In the early 1970s, the reported incidental detection rate was 7% to 13%, which has increased to 48% to 66% in the recent years (15–23). Tumor size at diagnosis has also substantially decreased over time. Series from the Memorial Sloan Kettering Cancer Center and the Mayo Clinic report that the mean size of resected renal tumors has dropped from 7.8 to 5.3 cm from 1989 to 1998, and that there was a 32% decrease in mean tumor size at the time of diagnosis, respectively (24,25).

There are numerous reports that the incidentally detected lesions are on average smaller and present at an earlier stage than those detected in symptomatic patients (7,11,13,14,16,19,20,25–32).

Tsui et al. reviewed the records of 633 consecutive patients who underwent surgical treatment for renal cell carcinoma at University of California, Los Angeles between 1987 and 1998. Stage I lesions were discovered in 62.1% of patients with incidental renal cell carcinoma and 23% with symptomatic renal cell carcinoma ($p = 0.001$). Mean tumor size was 5.1 cm versus 7.3 cm in incidental versus symptomatic cases ($p < 0.05$) (14). Patard et al. evaluated a series of 400 renal tumors and observed significantly smaller neoplasms in the incidentally detected group (5.7 cm vs. 8.7 cm; $p < 0.001$) (27).

Small asymptomatic tumors are more frequently benign. If proven to be renal cell carcinomas, they are on average lower grade than symptomatic ones (11,14,19,33–35).

Frank et al. recently reviewed the pathology of 2935 renal tumors at the Mayo Clinic and observed that as tumor size decreases there is a significant increase in the likelihood of having a benign tumor, a papillary compared to a clear cell histology and a low-grade compared to a high-grade malignancy. In their experience, 30% of tumors less than 4 cm in maximum dimension were benign and over 87% of those that were clear cell renal cell carcinoma were low-grade tumors (34).

Finally, several authors reported that small incidentally detected tumors are characterized by better survival outcomes (11,14,16,21,23,27,29,33,36). The five-year disease-free survival rate is 95% to 100% for incidental, less than 4 cm tumors treated with radical or partial nephrectomy (25,26,37). The first evidence of an association between tumor size

and prognosis was reported by Bell, who noted an increased rate of metastasis in patients found at postmortem to have renal cell carcinoma greater than 3 cm (38,39). Tumor size has always been incorporated in the tumor node metastasis staging system. In the 1997 version, the T1 stage was expanded from less than 2.5 to less than 7 cm, because the lower cutoff value was not associated with a significant difference in survival (40). The current version defines the cutoff point at 4 cm to subdivide stage T1 into T1a and T1b (41–43). Tumor size remains the most important prognostic factor for renal cell carcinoma.

NATURAL HISTORY OF SMALL RENAL TUMORS

Small renal neoplasms are generally removed soon after diagnosis. Therefore, their natural history has been historically poorly understood.

Small renal neoplasms are generally removed soon after diagnosis. Therefore, their natural history has been historically poorly understood.

In the landmark report of surveillance of kidney tumors, Bosniak et al. retrospectively reviewed the imaging of 40 incidentally detected, less than 3.5 cm renal masses that had been followed for a mean of 3.25 years. Twenty-six tumors were eventually removed after an average of 3.8 years and 84.6% of them were histologically renal cell carcinomas. Variable tumor growth behaviors were observed and the overall mean linear growth rate was 0.36 cm/yr (0–1.1 cm/yr). Nineteen tumors grew less than 0.35 cm/yr and no patient developed metastatic disease (44–46).


More recently, 17 small renal tumors in chronic haemodialysis patients with acquired cystic kidney disease were followed for a median of 2.1 years before performing nephrectomy. The overall growth rate, reported as volume, was again variable (0.07–17.34 cm³/yr) and significantly greater in high-grade carcinomas, while 65% of the tumors had a volume doubling time of more than a year (47).

In another retrospective study, Oda et al. observed 16 patients who were initially observed with incidentally diagnosed but histologically proven renal cell carcinoma. The tumor growth rate varied from 0.10 to 1.35 cm/yr and was significantly lower than that of metastatic renal cell carcinoma lesions observed in a second group of patients ($p = 0.016$) (48). Other authors have reported that localized primary tumors have a clinically significant lower rate of growth if compared to either primary advanced or metastatic lesions (7).

In the first prospective study of watchful waiting of renal tumors, we reported a series of 13 patients incidentally diagnosed with a small, less than 4 cm renal mass and followed expectantly because they were elderly or unfit for surgery. We hypothesized that the tumors that are destined to grow fast and possibly metastasize do so early, while most small tumors grow at a low rate or not at all (49).

More recently, we have reported the results of active surveillance of an expanded series of 32 renal masses in 29 patients (Fig. 1). Twenty-five tumors were solid and seven were complex cystic (four Bosniak III and three Bosniak IV) (50). The patients were prospectively followed with serial abdominal imaging for a mean of 27.9 months (5.3–143)

FIGURE 1 ■ Individual observed patterns of growth rate over time of 32 small renal masses managed with active surveillance. A summary curve indicating the average growth rate is superimposed (heavy line).



and each mass had at least three follow-up measurements. Tumor volume in addition to single and bidimensional diameters was calculated from each follow-up image or report. Nine masses in eight patients were surgically removed after an average of 38 months of follow-up because of the surgeon's concern or the patient's anxiety that the tumor was enlarging. All tumors were clear cell renal cell carcinoma except one which was an oncocytoma. The overall average growth rate, considering the cube root of the volume, was 0.1 cm/yr (not statistically significantly different from no growth; $p = 0.09$) and was not associated with either initial size ($p = 0.28$) or mass type ($p = 0.41$). Seven masses (22%) reached 4 cm in diameter after 12 to 85 months of follow-up. Eight (25%) doubled their volumes within 12 months. Overall, 11 (34%) fulfilled one of these two criteria of rapid growth. No patient progressed to metastatic disease, while two patients died of unrelated causes (51).

A similar experience has been recently reported by Kassouf et al., who serially imaged 24 patients with small renal masses. Most of the tumors did not demonstrate significant growth during the surveillance period. The mean growth rate of the five fast growing tumors was 0.49 cm/yr or 7.3 cm³/yr. The four tumors that were removed during the follow-up were all histologically renal cell carcinoma (three clear cell and one papillary type). No metastasis was documented (52).

ACTIVE SURVEILLANCE OF SMALL RENAL TUMORS

The standard of care for small localized renal neoplasms is either radical or partial nephrectomy (53,54).

The rationale for immediate surgery is that early detection and treatment of a small tumor will lead to an improved cancer-specific prognosis.

Nephron-sparing surgery for smaller renal cell carcinomas, originally proposed for patients with a solitary kidney, impaired renal function or bilateral tumors, is becoming the standard of care as an alternative to radical nephrectomy (25,42,43,55,56). Cancer-free survival appears equivalent (25). Laparoscopic partial nephrectomy is now widely performed and is perceived to be the preferred alternative to open partial nephrectomy (57,58). Although morbidity from nephrectomy has decreased with improved techniques, it is still significant and is reported to occur in 11% to 40% of cases in recent series (25,55,59–61).

The median age at diagnosis of renal cell carcinoma is 66 years (2). More incidental tumors are detected in the elderly who are more likely to undergo radiological examinations for other medical issues. These patients frequently have significant comorbidities and have a higher risk of perioperative mortality and morbidity. With aging populations and the increased use of imaging in developed countries, it is therefore reasonable to predict that the issue of appropriate management of small renal tumors will become even more important (17,62).

The lack of a decrease in the mortality of renal cell carcinoma in the last decades, despite the significant increase in the diagnosis of localized neoplasms, may imply that a proportion of small incidentally detected tumors have an indolent behavior (7). In fact, there has been a modest increase in mortality compared to incidence of renal cell carcinoma in the United States, which may be due to a lead time bias or may indicate that many small renal tumors have a long natural history and are not destined to progress, while the ones likely to do so are probably resected too late despite their localized radiographic appearance (2–4,63).

Reports from autopsy series performed before the widespread use of imaging show that 67% to 74% of renal cell carcinoma remained undetected until death and that only 8.9% to 20% of undiagnosed renal cell carcinoma were eventually responsible for the patient's death (5,64,65). This supports the hypothesis that many incidentally detected renal tumors grow slowly. Finally, some authors report that the observation that the age at diagnosis is lower in symptomatic than in incidental cases does not support the concept of incidental tumors as inevitable preclinical phase of the symptomatic ones (14,19,64,66).

There are few reports of watchful waiting of small renal masses in the literature. Most studies are retrospective and have a small sample size, but the results are consistent and provide a better understanding of the previously unknown natural history of renal tumors.

There is important variability in the growth patterns of small renal masses. A small number of tumors grow rapidly after diagnosis, but most of them have a natural history of slow growth and are not likely to metastasize (44,48,49,51,52). In our experience, only 34% renal masses had a clinically significant growth over time (51). The association between growth rate and tumor size at diagnosis was not found to be statistically significant (48,51). It is important to note that in all the series no tumor progressed with metastases during the surveillance period.

The standard of care for small localized renal neoplasms is either radical or partial nephrectomy.

There is important variability in the growth patterns of small renal masses. A small number of tumors grow rapidly after diagnosis, but most of them have a natural history of slow growth and are not likely to metastasize. In our experience, only 34% renal masses had a clinically significant growth over time. The association between growth rate and tumor size at diagnosis was not found to be statistically significant. It is important to note that in all the series no tumor progressed with metastases during the surveillance period.

A single or bidimensional diameter has been generally used to measure the tumor growth rate (44,48). We prefer to use tumor volume because we believe that it may better estimate the tumor cell burden. Small tumors are often spherical but may be ellipsoid, especially with increasing size. In our opinion, using three dimensions can therefore improve accuracy although error of measurement will be exponentially expressed (49,51).

In most studies, the small renal masses were radiologically consistent with renal cancer, but not all were histologically proven renal cell carcinoma. The accuracy of contemporary imaging modalities in the diagnosis of renal cell carcinoma is considered 85% to 90%, but this percentage may need to be revised downwards as recent reports suggest that the chance of benign pathology increases as the mass diameter decreases (34,67,68). Furthermore, the large majority of small renal cell carcinomas are low-grade tumors (34). This may explain why most small masses grow slowly or do not grow at all.

Based on these observations and interpretation of current data, it seems appropriate to reexamine the current practice of immediate surgery for all newly diagnosed small renal masses (19,44,45,48,49,63,66,69). In fact, many small incidentally discovered renal neoplasms may not be histologically or clinically malignant and therefore may not be an immediate threat to the patient's life. A period of initial observation with surgical treatment reserved for those tumors that exhibit fast growth, i.e. those that have rapid doubling times or whose volumes or bidimensional diameters reach a threshold demonstrated to be unsafe may be appropriate in patients who are elderly or infirm. This is the definition of active surveillance. In our study, we arbitrarily defined a fast growing mass as a mass that doubles its volume within one year and/or reaches 4 cm in maximum dimension (51). An upper limit of 3–4 cm in diameter is commonly used to identify the renal masses that are at very low risk of developing metastases and have a better survival rate (38,39,41,45,70–72). Further experience is required before we can define thresholds for treatment, but these appear to be conservative and reasonable upper limits for size and growth rate until which continued surveillance might be considered before triggering therapeutic intervention in selected patients.

Possible measurement error at imaging is a concern in the conservative management of patients with small renal tumors.

Several authors reported reproducible and accurate tumor volume measurements by the use of computed tomography scan and magnetic resonance imaging (73–76). A higher degree of inter- and intraobserver variability in measurements seems to occur with the use of ultrasonography (77,78). Edge detection of an irregular mass at imaging may be difficult or inaccurate, particularly when features such as cystic masses, haemorrhage, pyelonephritis, localization near or invasion of the collecting system, cysts or dilated calices adjacent to the tumor, and multiple cysts within the kidney are present (79). We have performed a study of inter- and intraobserver variability in computed tomography measurement of small renal masses and compared imaged with postoperative volumes (80). It is well known that these measurements may be different with a reduction in diameter after surgery, presumably largely due to initial ligation of the arterial blood supply with a decrease in kidney and tumor blood volume (74,81). We have demonstrated that the measurement of tumor dimension based on computed tomography and magnetic resonance imaging of the mass is an effective method of assessing tumor growth (80).

Masses with cystic components represent a special problem because there can be a significant difference between overall volume and tumor cell volume. Tumor growth rate can be easily either overestimated or underestimated if the volume of cystic fluid grows at a different rate than the tumor cell volume. Some authors observed that the prognosis for patients with cystic renal cell carcinoma is better than that for patients with solid tumors but, as the tumors were all managed by surgery, these reports do not give us information about the natural history of this type of tumor (82–85). In our experience, the complex cystic renal masses had a comparable growth rate compared to the solid ones ($p = 0.41$) (51).

Possible measurement error at imaging is a concern in the conservative management of patients with small renal tumors.

SUMMARY

- In the absence of other prognostic factors, the measurement of tumor growth rate may be helpful for initial conservative management of patients with small renal tumors.
- The risk of progression to metastatic disease during the surveillance period appears to be minimal, but longer follow-up is needed to confirm this observation.
- At the present time, active surveillance of small renal masses is an experimental approach that should only be considered for the elderly or patients with significant comorbidity.

■ New techniques of functional imaging or molecular and genomic studies, possibly using needle biopsies, may be useful in identifying small renal tumors with different aggressiveness and metastatic potential, therefore allowing the clinician to differentiate those that are likely to progress and require immediate surgery from those that are indolent and may benefit from active surveillance avoiding unnecessary surgery.

REFERENCES

1. Jemal A, Murray T, Samuels A, Ghafoor A, Ward E, Thun MJ. Cancer statistics, 2003. *CA Cancer J Clin* 2003; 53(1):5–26.
2. Ries LAG, Eisner MP, Kosary CL, et al. SEER Cancer Statistics Review 1973–1999. Bethesda, MD: National Cancer Institute, 2002.
3. Pantuck AJ, Zisman A, Beldegrun AS. The changing natural history of renal cell carcinoma. *J Urol* 2001; 166(5):1611–1623.
4. Chow WH, Devesa SS, Warren JL, Fraumeni JF Jr. Rising incidence of renal cell cancer in the United States. *JAMA* 1999; 281(17):1628–1631.
5. Wunderlich H, Schumann S, Jantitzky V, et al. Increase of renal cell carcinoma incidence in central Europe. *Eur Urol* 1998; 33(6):538–541.
6. Rofsky NM, Bosniak MA. MR imaging in the evaluation of small (< or = 3.0 cm) renal masses. *Magn Reson Imaging Clin N Am* 1997; 5(1):67–81.
7. Hock LM, Lynch J, Balaji KC. Increasing incidence of all stages of kidney cancer in the last 2 decades in the United States: an analysis of surveillance, epidemiology and end results program data. *J Urol* 2002; 167(1):57–60.
8. Mathew A, Devesa SS, Fraumeni JF Jr, Chow WH. Global increases in kidney cancer incidence, 1973–1992. *Eur J Cancer Prev* 2002; 11(2):171–178.
9. Lightfoot N, Conlon M, Kreiger N, et al. Impact of noninvasive imaging on increased incidental detection of renal cell carcinoma. *Eur Urol* 2000; 37(5):521–527.
10. Liu S, Semenciw R, Morrison H, Schanzer D, Mao Y. Kidney cancer in Canada: the rapidly increasing incidence of adenocarcinoma in adults and seniors. *Can J Public Health* 1997; 88(2):99–104.
11. Siemer S, Uder M, Humke U, et al. Value of ultrasound in early diagnosis of renal cell carcinoma. *Urologe A* 2000; 39(2):149–153.
12. Wills JS. The diagnosis and management of small (< or = 3 cm) renal neoplasms: a commentary. *Semin Ultrasound computed tomography MR* 1997; 18(2):75–81.
13. Porena M, Vespasiani G, Rosi P, et al. Incidentally detected renal cell carcinoma; role of ultrasonography. *J Clin Ultrasound* 1992; 20(6):395–400.
14. Tsui KH, Shvarts O, Smith RB, Figlin R, de Kernion JB, Beldegrun A. Renal cell carcinoma: prognostic significance of incidentally detected tumors. *J Urol* 2000; 163(2):426–430.
15. Skinner DG, Colvin RB, Vermillion CD, Pfister RC, Leadbetter WF. Diagnosis and management of renal cell carcinoma. A clinical and pathologic study of 309 cases. *Cancer* 1971; 28(5):1165–1177.
16. Konnak JW, Grossman HB. Renal cell carcinoma as an incidental finding. *J Urol* 1985; 134(6):1094–1096.
17. Shintaku I, Suzuki Y, Uchi K, Morita M, Terasawa Y. Characteristics of incidentally detected renal cell carcinoma by ultrasonography at health check-up. *Nippon Hinyokika Gakkai Zasshi* 2000; 91(2):43–48.
18. Russo P. Localized renal cell carcinoma. *Curr Treat Options Oncol* 2001; 2(5):447–455.
19. Luciani LG, Cestari R, Tallarigo C. Incidental renal cell carcinoma—age and stage characterization and clinical implications: study of 1092 patients (1982–1997). *Urology* 2000; 56(1):58–62.
20. Homma Y, Kawabe K, Kitamura T, et al. Increased incidental detection and reduced mortality in renal cancer—recent retrospective analysis at eight institutions. *Int J Urol* 1995; 2(2):77–80.
21. Bos SD, Mellema computed tomography, Mensink HJ. Increase in incidental renal cell carcinoma in the northern part of the Netherlands. *Eur Urol* 2000; 37(3):267–270.
22. Jayson M, Sanders H. Increased incidence of serendipitously discovered renal cell carcinoma. *Urology* 1998; 51(2):203–205.
23. Bretheau D, Lechevallier E, Eghazarian C, Grisoni V, Coulangue C. Prognostic significance of incidental renal cell carcinoma. *Eur Urol* 1995; 27(4):319–323.
24. Lau WK, Blute ML, Weaver AL, Torres VE, Zincke H. Matched comparison of radical nephrectomy vs. elective nephron-sparing surgery in patients with unilateral renal cell carcinoma and a normal contralateral kidney. *Mayo Clinic Proc* 2000; 75:1236.
25. Lee computed tomography, Katz J, Shi W, Thaler HT, Reuter VE, Russo P. Surgical management of renal tumors 4 cm. or less in a contemporary cohort. *J Urol* 2000; 163(3):730–736.
26. Licht MR, Novick AC, Goormastic M. Nephron sparing surgery in incidental versus suspected renal cell carcinoma. *J Urol* 1994; 152(1):39–42.
27. Patard JJ, Rodriguez A, Rioux-Leclercq N, Grille F, Lobel B. Prognostic significance of the mode of detection in renal tumours. *BJU Int* 2002; 90(4):358–363.
28. Russo P. Renal cell carcinoma: presentation, staging, and surgical treatment. *Semin Oncol* 2000; 27(2):160–176.
29. Thompson IM, Peek M. Improvement in survival of patients with renal cell carcinoma—the role of the serendipitously detected tumor. *J Urol* 1988; 140(3):487–490.
30. Marshall FF, Stewart AK, Menck HR. The National Cancer Data Base: report on kidney cancers. The American College of Surgeons Commission on Cancer and the American Cancer Society. *Cancer* 1997; 80(11):2167–2174.

31. Aso Y, Homma Y. A survey on incidental renal cell carcinoma in Japan. *J Urol* 1992; 147(2):340–343.
32. Katz DL, Zheng T, Holford TR, Flannery J. Time trends in the incidence of renal carcinoma: analysis of Connecticut Tumor Registry data, 1935–1989. *Int J Cancer* 1994; 58(1):57–63.
33. Sweeney JP, Thornhill JA, Graiger R, McDermott TE, Butler MR. Incidentally detected renal cell carcinoma: pathological features, survival trends and implications for treatment. *Br J Urol* 1996; 78(3):351–353.
34. Frank I, Blute ML, Cheville JC, Lohse CM, Weaver AL, Zincke H. Solid renal tumors: an analysis of pathological features related to tumor size. *J Urol* 2003; 170(6 Pt 1):2217–2220.
35. Dechet CB, Sebo T, Farrow G, Blute ML, Engen DE, Zincke H. Prospective analysis of intraoperative frozen needle biopsy of solid renal masses in adults. *J Urol* 1999; 162(4):1282–1284; discussion 84–85.
36. Kessler O, Mukamel E, Hadar H, Gillon G, Konechezky M, Servadio C. Effect of improved diagnosis of renal cell carcinoma on the course of the disease. *J Surg Oncol* 1994; 57(3):201–204.
37. Butler BP, Novick AC, Miller DP, Campbell SA, Licht MR. Management of small unilateral renal cell carcinomas: radical versus nephron-sparing surgery. *Urology* 1995; 45(1):34–40; discussion 40–41.
38. Bell ET. A classification of renal tumors with observations on the frequency of the various types. *J Urol* 1938; 39:238.
39. Bell ET. *Renal Disease*. 2d ed. Philadelphia: Lea and Febiger, 1950.
40. Guinan P, Sobin LH, Algaba F, et al. tumor node metastasis staging of renal cell carcinoma: Workgroup No. 3. Union International Contre le Cancer (UICC) and the American Joint Committee on Cancer (AJCC). *Cancer* 1997; 80(5):992–993.
41. Zisman A, Pantuck AJ, Chao D, et al. Reevaluation of the 1997 tumor node metastasis classification for renal cell carcinoma: T1 and T2 cutoff point at 4.5 rather than 7 cm. Better correlates with clinical outcome. *J Urol* 2001; 166(1):54–58.
42. Fergany AF, Hafez KS, Novick AC. Long-term results of nephron sparing surgery for localized renal cell carcinoma: 10-year followup. *J Urol* 2000; 163(2):442–445.
43. Hafez KS, Fergany AF, Novick AC. Nephron sparing surgery for localized renal cell carcinoma: impact of tumor size on patient survival, tumor recurrence and tumor node metastasis staging. *J Urol* 1999; 162(6):1930–1933.
44. Bosniak MA. Observation of small incidentally detected renal masses. *Semin Urol Oncol* 1995; 13(4):267–272.
45. Bosniak MA, Bimbaum BA, Krinsky GA, Waisman J. Small renal parenchymal neoplasms: further observations on growth. *Radiology* 1995; 197(3):589–597.
46. Bosniak MA, Krinsky GA, Waisman J. Management of small incidental renal parenchymal tumors by watchful-waiting in selected patients based on observations of tumor growth rates. *J Urol* 1996; 155(suppl):584A, abstract 1092.
47. Takebayashi S, Hidai H, Chiba T, Irisawa M, Matsubara S. Renal cell carcinoma in acquired cystic kidney disease: volume growth rate determined by helical computed tomography. *Am J Kidney Dis* 2000; 36(4):759–766.
48. Oda T, Miyao N, Takahashi A, et al. Growth rates of primary and metastatic lesions of renal cell carcinoma. *Int J Urol* 2001; 8(9):473–477.
49. Rendon RA, Stanietzky N, Panzarella T, et al. The natural history of small renal masses. *J Urol* 2000; 164(4):1143–1147.
50. Bosniak MA. The use of the Bosniak classification system for renal cysts and cystic tumors. *J Urol* 1997; 157(5):1852–1853.
51. Volpe A, Panzarella T, Rendon RA, Haider MA, Kondylis FI, Jewett MA. The natural history of incidentally detected small renal masses. *Cancer* 2004; 100(4):738–745.
52. Kassouf W, Aprikian AG, Laplante M, Tanguay S. Natural history of renal masses followed expectantly. *J Urol* 2004; 171(1):111–113; discussion 13.
53. Pantuck AJ, Zisman A, Rauch MK, Belldegrun A. Incidental renal tumors. *Urology* 2000; 56(2):190–196.
54. Reddan DN, Raj GV, Polascik TJ. Management of small renal tumors: an overview. *Am J Med* 2001; 110(7):558–562.
55. Uzzo RG, Novick AC. Nephron sparing surgery for renal tumors: indications, techniques and outcomes. *J Urol* 2001; 166(1):6–18.
56. Lerner SE, Hawkins CA, Blute ML, et al. Disease outcome in patients with low stage renal cell carcinoma treated with nephron sparing or radical surgery. *J Urol* 2002; 167(2 Pt 2):884–889; discussion 89–90.
57. Matin SF, Gill IS, Worley S, Novick AC. Outcome of laparoscopic radical and open partial nephrectomy for the sporadic 4 cm or less renal tumor with a normal contralateral kidney. *J Urol* 2002; 168(4 Pt 1):1356–1359; discussion 59–60.
58. Ogan K, Cadeddu JA. Minimally invasive management of the small renal tumor: review of laparoscopic partial nephrectomy and ablative techniques. *J Endourol* 2002; 16(9):635–643.
59. Mejean A, Vogt B, Quazza JE, Chretien Y, Dufour B. Mortality and morbidity after nephrectomy for renal cell carcinoma using a transperitoneal anterior subcostal incision. *Eur Urol* 1999; 36(4):298–302.
60. Fontaine E, Chretien Y. Systematic conservative surgery for kidney cancer smaller than 4 cm: multicenter study. *Prog Urol* 2001; 11(4):621–624.
61. Stephenson AJ, Hakimi AA, Snyder ME, Russo P. Complications of radical and partial nephrectomy in a large contemporary cohort. *J Urol* 2004; 171(1):130–134.
62. Tsuboi N, Horiuchi K, Kimura G, et al. Renal masses detected by general health checkup. *Int J Urol* 2000; 7(11):404–408.
63. Parsons JK, Schoenberg MS, Carter HB. Incidental renal tumors: casting doubt on the efficacy of early intervention. *Urology* 2001; 57(6):1013–1015.

64. Hajdu SI, Berg JW, Foote FW Jr. Clinically unrecognized, silent renal cell carcinoma in elderly cancer patients. *J Am Geriatr Soc* 1970; 18(6):443–449.
65. Hellsten S, Johnsen J, Berge T, Linell F. Clinically unrecognized renal cell carcinoma. Diagnostic and pathological aspects. *Eur Urol* 1990; 18(suppl 2):2–3.
66. Luciani LG. Re: Renal cell carcinoma: prognostic significance of incidentally detected tumors. *J Urol* 2001; 165(4):1223.
67. Steinberg AP, Lin CH, Matin S, et al. Impact of tumor size on laparoscopic partial nephrectomy: analysis of 163 patients AUA Annual Meeting. *J Urol* 2003; 169(suppl 4):174.
68. Novick AC. Management of the incidentally detected solid renal mass. *Semin Nephrol* 1994; 14(6):519–522.
69. Hernandez Jover D, de la Torre Holguera P, Alberola Bou J, Amores Cavera S. Small renal mass. Diagnostic management. *Arch Esp Urol* 2001; 54(6):593–601.
70. Frank I, Blute ML, Cheville JC, Lohse CM, Weaver AL, Zincke H. An outcome prediction model for patients with clear cell renal cell carcinoma treated with radical nephrectomy based on tumor stage, size, grade and necrosis: the SSIGN score. *J Urol* 2002; 168(6):2395–2400.
71. Walther MM, Choyke PL, Glenn G, et al. Renal cancer in families with hereditary renal cancer: prospective analysis of a tumor size threshold for renal parenchymal sparing surgery. *J Urol* 1999; 161(5):1475–1479.
72. Bosniak MA. The small (less than or equal to 3–0 cm) renal parenchyma tumor: detection, diagnosis, and controversies. *Radiology* 1991; 179(2):307–317.
73. Wheatley JM, Rosenfield NS, Heller G, Feldstein D, LaQuagjia MP. Validation of a technique of computer-aided tumor volume determination. *J Surg Res* 1995; 59(6):621–626.
74. Tann M, Sopov V, Croitoru S, et al. How accurate is helical computed tomography volumetric assessment in renal tumors? *Eur Radiol* 2001; 11(8):1435–1438.
75. Nawaratne S, Fabiny R, Brien JE, et al. Accuracy of volume measurement using helical computed tomography. *J Comput Assist Tomogr* 1997; 21(3):481–486.
76. Coulam CH, Bouley DM, Sommer FG. Measurement of renal volumes with contrast-enhanced magnetic resonance imaging. *J Magn Reson Imaging* 2002; 15(2):174–179.
77. Schlesinger AE, Hernandez RJ, Zerin JM, Marks TI, Kelsch RC. Interobserver and intraobserver variations in sonographic renal length measurements in children. *AJR Am J Roentgenol* 1991; 156(5):1029–1032.
78. Hederstrom E, Forsberg L. Accuracy of ultrasonography compared with urography in detection of intrarenal dilatation in children. *Ada Radiol Diugn (Stockh)* 1985; 26(2):201–207.
79. Yaycioglu O, Rutman MP, Balasubramaniam M, Peters KM, Gonzalez JA. Clinical and pathologic tumor size in renal cell carcinoma. difference, correlation, and analysis of the influencing factors. *Urology* 2002; 60(1):33–38.
80. Punnen S, Haider, MA, Lockwood G, Jewett MAS. Variability in size measurements of small renal masses on computed tomography imaging. *J Urol* 2004; 171(suppl 4):507.
81. Herr HW, Lee computed tomography, Sharma S, Hilton S. Radiographic versus pathologic size of renal tumors: implications for partial nephrectomy. *Urology* 2001; 58(2):157–160.
82. Onishi T, Oishi Y, Goto H, Tomita M, Abe K, Sugaya S. Cyst-associated renal cell carcinoma: clinicopathologic characteristics and evaluation of prognosis in 27 cases. *Int J Urol* 2001; 8(6):268–274.
83. Nassir A, Jollimore J, Gupta R, Bell D, Norman R. Multilocular cystic renal cell carcinoma: a series of 12 cases and review of the literature. *Urology* 2002; 60(3):421–427.
84. Koga S, Nishikido M, Hayashi T, Matsuya F, Saito Y, Kanetake H. Outcome of surgery in cystic renal cell carcinoma. *Urology* 2000; 56(1):67–70.
85. Corica FA, Iczkowski KA, Cheng L, et al. Cystic renal cell carcinoma is cured by resection: a study of 24 cases with long-term followup. *J Urol* 1999; 161(2):408–411.

COMMENTARY

Morton A. Bosniak

Department of Radiology, NYU Medical Center, New York, New York, U.S.A.

It is very appropriate (and admirable) that in this textbook on laparoscopic urology, a chapter and commentary on a nonsurgical approach to some tumors of the kidney are included. It is an inclusion that reminds us that even with these great advances in surgical (and ablative) techniques, a nonoperative management approach (at least initially) is justified and wise in some cases.

Whether one calls this initial nonsurgical management of some small renal neoplasms “active surveillance,” “watchful waiting (1,2),” or “expectant follow-up (3),” this approach to the small incidentally discovered renal neoplasm particularly in older and poor surgical risk patients by initially observing the lesion’s growth pattern, and therefore its potential, is a management strategy that should not be abandoned because of the emergence of laparoscopic partial nephrectomy, cryoablation, and radiofrequency ablation of small tumors. For while these techniques are less invasive and nephron sparing, they still are invasive with potential for complications.

In their chapter, Drs. Volpe and Jewett put forth a compelling presentation (with an extensive literature review) to justify “active surveillance” management of small renal masses in appropriate cases. This is an approach that many of us have practiced over the past many years (1) and I am aware of a large number of unreported cases that have been managed and are being managed in this fashion. The results of recently published studies on renal cancer growth further support this approach. While the use of a “watchful waiting” scheme of management has decreased somewhat over the past few years with the emergence of laparoscopic partial nephrectomy and ablative techniques, there still exists a sizeable population of elderly, poor surgical risk patients who will benefit from a noninvasive approach. As the population ages, there will be an increase in the number of elderly, poor surgical risk patients and some will be found to have incidentally discovered small lesions. The knowledge that it is “safe” to follow these patients expectantly will increase the use of this type of management. With the increasing amount of data accumulating on renal tumor growth, urologists can feel confident that a nonoperative approach with expectant follow-up can be instituted, which is safe and without risk to their patients.

When should a patient be managed by “active surveillance?” Obviously each case must be individualized with clinical and imaging factors taken into account. The obvious clinical factors are patient age, comorbidities, and potential life expectancy. The imaging factors include lesion size, imaging appearance, and the position of the lesion in the kidney.

1. It has been my experience that well-circumscribed, well-marginated, homogeneous lesions are more likely to have a slower growth pattern than irregularly marginated, necrotic, or markedly heterogeneous lesions (4).
2. Location of the lesion in the kidney might be important in some cases. Lesions that could be managed by partial nephrectomy should not be allowed to progress so that a total nephrectomy becomes necessary. This would be particularly relevant in a patient with a tumor in a single kidney, or in a patient with diminished renal function.
3. Cystic and solid tumors have different growth rates and using the same criteria of surveillance may not be appropriate for these lesions in my opinion. A 3.5 cm solid mass is more worrisome than an equal-sized cystic lesion and a malignant cystic lesion that is progressing may not grow in size but its solid components may be increasing within the cystic mass. Also there is a wide range in the appearance of cystic malignancies. Some have a large amount of solid tissue associated (Bosniak Category IV) while others have much more fluid and perhaps just thickened, enhancing wall or septae (Bosniak Category III) (5). In elderly, surgical risk patients, this type of Category III lesion might be managed by follow-up studies just as Category IIF lesions are managed (6). For these reasons, size may not be as an important factor as morphology in cystic malignancies and the progression of cystic tumors can be much more difficult to predict. There is little data on the growth of cystic malignancies though there is some evidence that cystic lesions are less aggressive than solid tumors as noted in Drs. Volpe’s and Jewett’s chapter and as suggested in the literature (7). And finally, two observations on the imaging of cystic masses; extensive necrosis in a malignancy should not be mistaken for a cystic neoplasm and calcification in the wall of a cyst is in itself not a sign of malignancy unless associated with contrast enhancement (8).

In those cases in which surgery is to be performed, it is essential that high-quality imaging studies are available with accurate, careful interpretation. We must be certain that the lesion being removed or ablated is truly a neoplasm. Most solid (enhancing) masses are renal cell carcinomas, although approximately 10% are oncocytomas and less than 1% are hamartomas without macroscopic fat. These latter two benign lesions cannot be diagnosed preoperatively. However, angiomyolipomas that contain just a tiny amount of fat should be recognized and do not need intervention (9,10) and “pseudoenhancement” of renal cysts needs to be appreciated so that a benign cyst is not mistakenly removed (11–13).

In conclusion, to cure a patient with a small renal cancer, surgical removal is definitive. But not all small renal tumors have to be removed to manage the patient correctly. By including Drs. Volpe's and Jewett's chapter and this commentary in this textbook, the Editor is reminding us that though laparoscopic urologic surgery is a great advance in the surgical treatment of renal tumors, there is still a place for "watchful waiting" or "active surveillance" in the management of appropriate cases. This noninvasive approach should not be abandoned or minimized in the management of some small renal neoplasms even in this age of laparoscopic urology.

REFERENCES

1. Bosniak MA. Observation of small incidentally detected renal masses. *Semin Urol Oncol* 1995; 13:267–272.
2. Bosniak MA, Birnbaum BA, Krinsky GA, Waisman J. Small renal parenchymal neoplasms: further observations on growth. *Radiology* 1995; 197:589–597.
3. Kassouf W, Aprikian A, LaPlante M, Tanquay S. Natural history of renal masses followed expectantly. *J Urol* 2004; 171:111–113.
4. Birnbaum BA, Bosniak MA, Krinsky GA, et al. Renal cell carcinoma: correlation of CT findings with nuclear morphology grading in 100 tumors. *Abdom Imaging* 1994; 19:262–266.
5. Bosniak MA. The current radiologic approach to renal cysts. *Radiology* 1986; 158:1–10.
6. Israel GM, Bosniak MA. Follow-up CT studies for moderately complex renal masses (Bosniak Category IIF). *Am J Roentgenol* 2003; 181:627–633.
7. Elbe JN, Bonsib SM. Extensively cystic renal neoplasms: cystic nephroma, cystic partially differentiated nephroblastoma, multilocular cystic renal cell carcinoma, and cystic hamartoma of renal pelvis. *Semin Diagn Pathol* 1998; 15:2–20.
8. Israel GM, Bosniak MA. Calcification in cystic renal masses: is it important in diagnosis? *Radiology* 2003; 226:47–52.
9. Bosniak MA, Megibow JA, Hulnick DH, et al. computed tomography diagnosis of renal angiomyolipoma: the importance of detecting small amounts of fat. *Am J Roentgenol* 1988; 151:497.
10. Jinzaki M, Tanimoto A, Narimatsu Y, et al. Angiomyolipoma: imaging findings in lesions with minimal fat. *Radiology* 1997; 205:497–502.
11. Birnbaum BA, Maki DD, Chakraborty DP, et al. Renal cyst pseudoenhancement: Evaluation with anthropomorphic body computed tomography phantom. *Radiology* 2002; 225:83–90.
12. Henegan JP, Spielman AL, Sheafor DH, et al. Pseudoenhancement of simple renal cysts: a comparison of single and multidetector helical computed tomography. *J Comput Assist Tomogr* 2002; 26:90–94.
13. Bosniak MA, Rofsky NM. Problems in the detection and characterization of small renal masses. *Radiology* 1996; 198:638–641.

LAPAROSCOPIC PARTIAL NEPHRECTOMY: TECHNIQUE

Jihad H. Kaouk

Section of Laparoscopic and Robotic Surgery, Glickman Urological Institute, Cleveland Clinic Foundation, Cleveland, Ohio, U.S.A.

- INTRODUCTION
- INDICATIONS AND CONTRAINDICATIONS
- PERIOPERATIVE PATIENT PREPARATION
 - Ureteral Catheterization
 - Patient Positioning
 - Preoperative and Intraoperative Imaging
- SURGICAL TECHNIQUES
 - Transperitoneal Approach
 - Retroperitoneal Approach
- ALTERNATIVE TECHNIQUES
 - Renal Hilar Clamping
 - Laparoscopic Renal Hypothermia
 - Hemostatic Techniques
- SUMMARY
- REFERENCES

INTRODUCTION

Over the last decade, indications for laparoscopy have evolved from ablative procedures to more complex reconstructive surgeries. Open partial nephrectomy remains the standard approach for localized kidney tumors when nephron-sparing surgery is indicated (1). Mounting experience in laparoscopic intracorporeal suturing and availability of refined laparoscopic vascular instruments facilitated the emergence of laparoscopic partial nephrectomy as a viable surgical approach for selected patients, wherein laparoscopic partial nephrectomy attempts to duplicate established principles of open surgical techniques (2).

Laparoscopic partial nephrectomy is a technically advanced procedure with challenges posed when accomplishing complete tumor excision, and securing renal parenchymal hemostasis in a limited time of warm ischemia. Achieving renal hypothermia remains a technical challenge.

INDICATIONS AND CONTRAINDICATIONS

The indications for laparoscopic partial nephrectomy have been expanded beyond small, exophytic, and peripheral renal tumors to include patients with more involved tumors placed deep in the kidney, abutting the collecting system or renal sinus, completely intraparenchymal, adjacent to the renal hilum, or tumor in a solitary kidney. Laparoscopic partial nephrectomy for such complex tumors is performed only when nephron sparing surgery is indicated. Contraindications for laparoscopic partial nephrectomy include renal vein thrombus, multiple (>2) renal tumors, uncorrectable bleeding diathesis, and a history of prior ipsilateral renal surgery. Relative contraindications for laparoscopic partial nephrectomy include morbid obesity and baseline azotemia (3).

PERIOPERATIVE PATIENT PREPARATION

Preoperative routine blood tests are performed with special attention to screening for bleeding tendency and evaluation of kidney function. Formal bowel preparation is not necessary and is thus limited to clear fluids and two bottles of magnesium citrate administered the evening before surgery. Adequate preoperative hydration is mandatory and parenteral broad-spectrum antibiotic is given on-call to the operating room.

Ureteral Catheterization

All patients are placed in the lithotomy position and ipsilateral ureteral catheterization is performed cystoscopically up to the renal pelvis.

Laparoscopic partial nephrectomy is a technically advanced procedure with challenges posed when accomplishing complete tumor excision, and securing renal parenchymal hemostasis in a limited time of warm ischemia. Achieving renal hypothermia remains a technical challenge.

All patients are placed in the lithotomy position and ipsilateral ureteral catheterization is performed cystoscopically up to the renal pelvis.

A 60 cc syringe with dilute indigo carmine dye (1 ampoule dye in 500 cc normal saline) is attached to the ureteral catheter and used during surgery to inject retrogradely and check for entry in the collecting system after excision of the kidney tumor. The ureteral catheter is kept for one to two days postoperatively if suture-repair of the collecting system is performed.

Patient Positioning

The patient is placed in the 90° flank position or in the 45° modified flank position depending on whether the retroperitoneal or the transperitoneal approach is employed, respectively. Pneumatic compressors are applied over both legs and the patient is taped to the operative table after carefully padding all bony prominences. The operative table is mildly flexed mainly during the retroperitoneal approach to increase the distance between the costal margin and the iliac crest (Fig. 1).

Preoperative and Intraoperative Imaging

Preoperative computed tomography with volume-rendered three-dimensional video reconstruction is performed to aid in surgical planning. Intraoperative flexible contact renal ultrasonography is performed to precisely determine tumor size, depth of intraparenchymal extension, distance from the collecting system, proximity to major renal vessels, and further evaluation of any suspicious satellite renal lesions. The renal capsule is incised circumferentially including a small margin of normal renal parenchyma surrounding the tumor under sonographic guidance (Fig. 2) (4).

SURGICAL TECHNIQUES

Selection of the laparoscopic approach is based upon tumor location to ensure adequate surgical exposure. The transperitoneal approach is preferred for anterior, anteriolateral, lateral, and apical tumors. The retroperitoneal approach is reserved for posterior or posterolateral tumors. The Cleveland Clinic technique of laparoscopic partial nephrectomy has been described previously (2). Operative steps include renal hilum cross-clamping after kidney mobilization and exposure of the tumor. Temporary hilar control provides a dry surgical field essential for accurate tumor excision and kidney reconstruction.

Transperitoneal Approach

For the transperitoneal approach, the patient is placed in the 45° modified flank position. The surgeon and the assistant stand facing the abdomen of the patient.

Step 1: Initial Access and Port Placement

Initially, peritoneal insufflation is performed by inserting a Veress needle into the ipsilateral lower abdominal quadrant along the mid-clavicular line. CO₂ insufflation is started and continued until a 15 mmHg pneumoperitoneum is achieved. The Veress needle is replaced by a 12 mm laparoscopic port into which a 10 mm laparoscopic telescope with a 30° angle lens is inserted. A total of four to five ports are employed. Under

FIGURE 1 ■ During retroperitoneal laparoscopic partial nephrectomy the patient is positioned in the 90° flank position. (A) Anterior view showing the arms placed on a double arm board in a neutral position. An axillary roll is placed and the patient is taped to the operating table. (B) Posterior view showing the operative table flexed and the kidney rest elevated to maximize the space between the iliac crest and the subcostal margin. Foam pads are placed under the hip, knees, and ankles. The head is supported to keep a neutral neck position. Similar patient positioning is needed during transperitoneal laparoscopic partial nephrectomy with some variation including tilting the patient to a 45° position and minimizing table flexion.

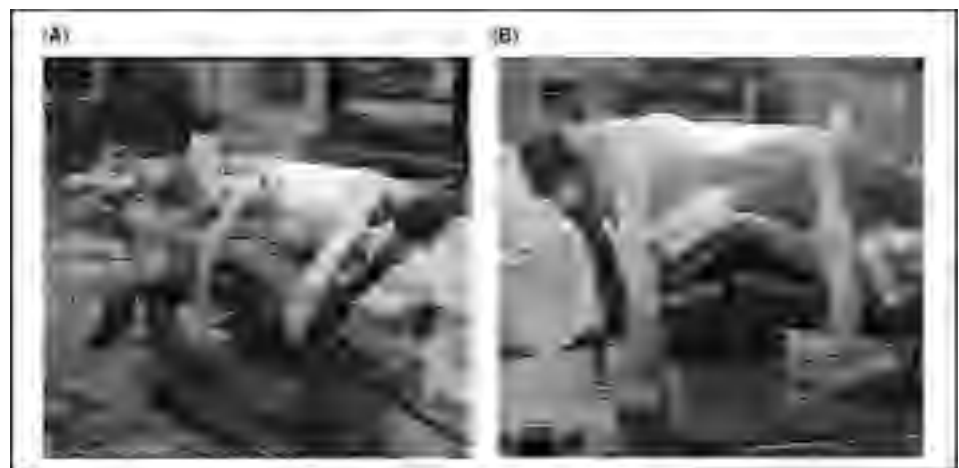




FIGURE 2 ■ (A) Intraoperative laparoscopic ultrasound is performed using a flexible ultrasound probe with a steerable tip. (B) Intraoperative illustration of excision margin planning using ultrasound guidance. *Abbreviations:* K, kidney; T, tumor.

During right partial nephrectomy, an additional 5 mm port is inserted at the subxiphoid location for cephalad retraction of the liver.

The port used to insert the Satinsky clamp is placed in the lower abdomen such that the Satinsky is applied parallel to the aorta and vena cava.

direct vision, a 12 mm port is placed at the lateral edge of the ipsilateral rectus muscle along the level of the 12th rib, and a 5 mm port at the angle of the costal margin with the lateral edge of the ipsilateral rectus muscle. The laparoscope is then shifted to the middle port.

During right partial nephrectomy, an additional 5 mm port is inserted at the subxiphoid location for cephalad retraction of the liver (Fig. 3).

Step 2: Preparation of the Renal Hilum

The colon is mobilized medially to expose the renal hilum. On the right side, gentle mobilization of the duodenum may be needed and the liver is retracted cephalad above the renal upper pole. The ureter is identified and dissected off the psoas muscle toward the renal hilum to avoid inadvertent clamping of the ureter along with the renal hilum. The renal artery and vein are not dissected individually and the renal hilum is clamped en bloc using a Satinsky clamp.

The port used to insert the Satinsky clamp is placed in the lower abdomen such that the Satinsky is applied parallel to the aorta and vena cava. Thick tissue surrounding the renal vessels should be dissected to avoid incomplete Satinsky occlusion (Fig. 4).

Step 3: Kidney Mobilization and Tumor Exposure

Gerota's fascia is incised and kidney is mobilized generously from within the Gerota, enough to expose the tumor and surrounding normal renal parenchyma. Fatty tissue covering the tumor is maintained en bloc with the tumor.

Step 4: Renal Hilar Clamping

After adequate hydration and intravenous administration of Mannitol (12.5 g), a Satinsky clamp is introduced through a separate port placed in the ipsilateral lower quadrant, and the renal hilum is clamped en bloc (Fig. 4). Care is taken to ensure that any accessory renal arteries or veins are included within the jaws of the clamp. If necessary, additional individual bulldog clamps can be employed.

Step 5: Tumor Excision

After renal hilar control, the tumor is excised including a margin of normal renal parenchyma. Cold endoshears is used to cut the renal parenchyma along the previously scored renal capsule (Fig. 5).

Step 6: Kidney Reconstruction and Hemostasis

Pelvicalyceal integrity is tested by retrograde injection of dilute indigo carmine through the previously placed ureteral catheter. Any entry is identified and is laparoscopically sutured using continuous 2-0 Vicryl suture on a computed tomography-1 needle in a watertight fashion (Fig. 6). Parenchymal hemostatic sutures are

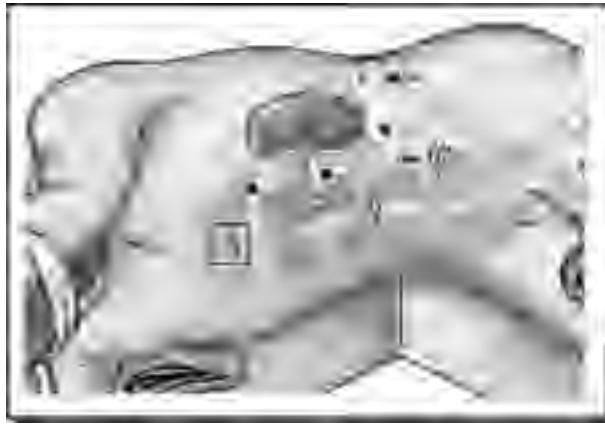

FIGURE 3 ■ Illustration of port positioning during laparoscopic left partial nephrectomy. The Satinsky port is placed in the lower abdominal quadrant such that the Satinsky is almost parallel to the aorta and vena cava. An additional 2 mm miniport (arrow) is placed in the lateral flank position for additional traction. During right partial nephrectomy, an additional subxiphoid port (X) is inserted for cephalad retraction of the liver.

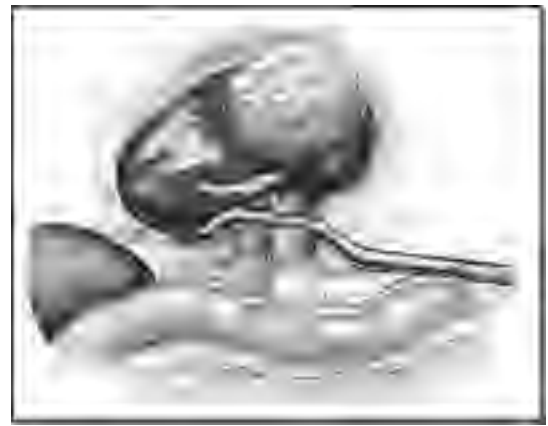

FIGURE 4 ■ Transperitoneal laparoscopic partial nephrectomy. Laparoscopic Satinsky clamp is used to control the renal hilum en bloc. Individual dissection of the renal artery and vein is not necessary. Intraoperative illustration of en bloc renal hilum clamping.

placed using GS-25 needle and 0 Vicryl suture over a prepared surgical bolsters (Fig. 7). The biologic hemostatic agent, Floseal, is layered directly onto the partial nephrectomy bed, deep to the surgical bolster. After securing hemostasis, renal hilum is unclamped and warm ischemia time is noted. Hemostasis is rechecked after desufflating the abdomen to zero intraperitoneal pressure for 10 to 15 minutes. Occasionally, bleeding temporarily tamponaded by pneumoperitoneal pressure can be unveiled and controlled (Fig. 8).

Step 7: Laparoscopic Exit

The excised renal tumor is entrapped within an Endocatch bag^a and extracted intact from the lower port site.

A Jackson-Pratt drain is placed if pelvicalyceal repair was performed. Ports are removed under vision after securing hemostasis.

Retroperitoneal Approach

During the retroperitoneal approach the patient is positioned in the standard 90° full flank position. The surgeon and the assistant stand facing the patient's back (5).

Step 1: Initial Access and Port Placement

A three-port technique is usually employed. The initial retroperitoneal access is achieved using the open (Hasson) technique. A 1.2 cm transverse skin incision is made at the tip of the 12th rib, and flank muscles are bluntly split. The thoracolumbar fascia is exposed and incised. Using blunt finger dissection, the retroperitoneum is entered and a space is developed anterior to the psoas muscle and posterior to Gerota's fascia. A balloon dilator is inserted in the created retroperitoneal space, and then inflated with 800 cc of air. The balloon is subsequently deflated and replaced with a 10 mm blunt tip cannula with a 30 cc balloon mounted tip which is cinched against the abdominal wall in an air tight fashion. CO₂ pneumoretroperitoneum is established at 15 mmHg, and a 30° lens laparoscope is introduced into the retroperitoneal space. Under direct vision, two secondary laparoscopic ports are placed. An anterior port is inserted 3 cm cephalad to the iliac crest along the anterior axillary line, and a posterior port is inserted at the junction of the lateral border of the erector spinae muscle with the undersurface of the 12th rib (Fig. 9).

A Jackson-Pratt drain is placed if pelvicalyceal repair was performed. Ports are removed under vision after securing hemostasis.

^aU.S. Surgical Corp., Norwalk, CT.

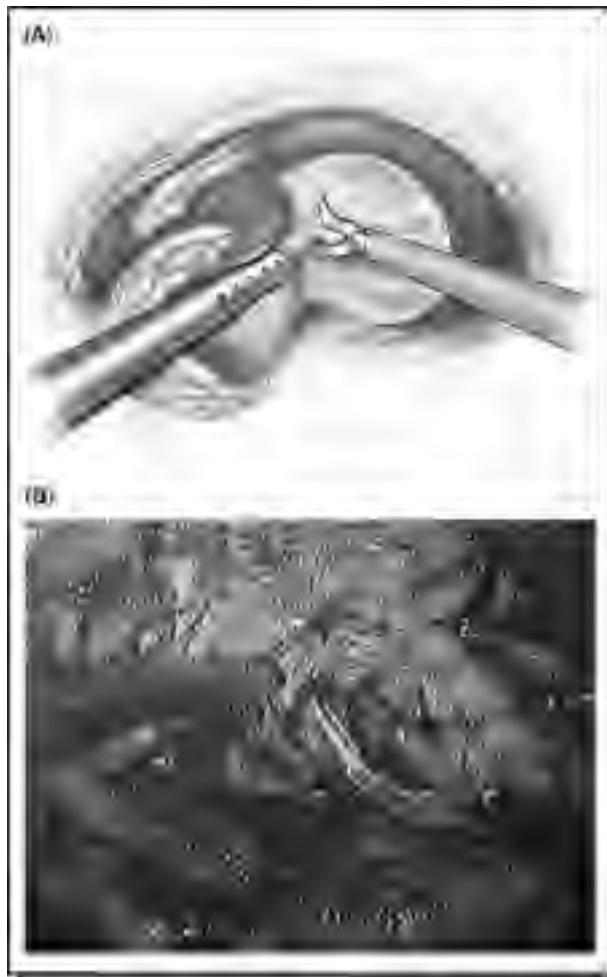


FIGURE 5 ■ Illustration (A) and intraoperative photo (B) of renal tumor excision with deliberate entering to the calyx abutting the tumor as necessary to maintain an adequate parenchymal margin.

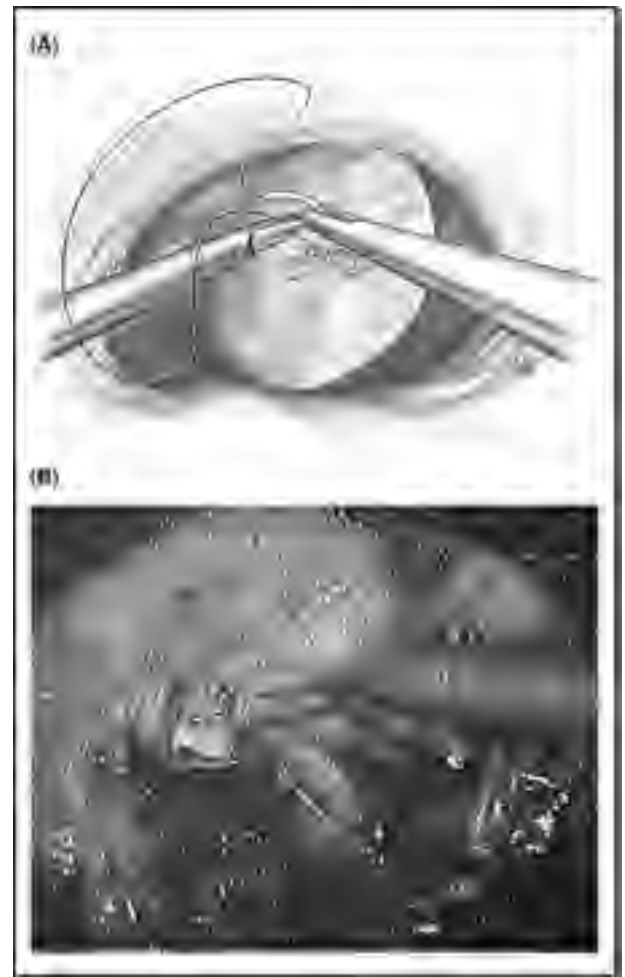


FIGURE 6 ■ Illustration (A) and intraoperative photo (B) showing suture repairing of any calyceal opening in a watertight fashion. After tumor excision, retrograde injection of methylene blue help identify and, later, confirm watertight repair of calyceal entry.

In contradistinction to the transperitoneal approach, identification and individual dissection of the renal artery and renal vein is the first surgical step in the retroperitoneal approach.

Step 2: Preparation of Renal Hilum

The renal hilum is put on stretch by anteriolateral retraction of the kidney. The renal artery and vein are individually dissected in preparation for temporary clamping.

Step 3: Kidney Mobilization and Tumor Exposure

In contradistinction to the transperitoneal approach, identification and individual dissection of the renal artery and renal vein is the first surgical step in the retroperitoneal approach.

The kidney is mobilized from within the Gerota's fascia in a fashion similar to the transperitoneal approach. Nevertheless, the retroperitoneal space is limited adding difficulty to the procedure.

Step 4: Renal Hilar Clamping

Bulldog clamps are placed on the renal artery and vein separately during a retroperitoneal partial nephrectomy (Fig. 10).

Step 5: Completion of Partial Nephrectomy

Following hilar control, surgical steps including tumor excision, reconstruction of the renal parenchyma and collecting system, tumor extraction, and laparoscopic exit are similar to the transperitoneal approach.

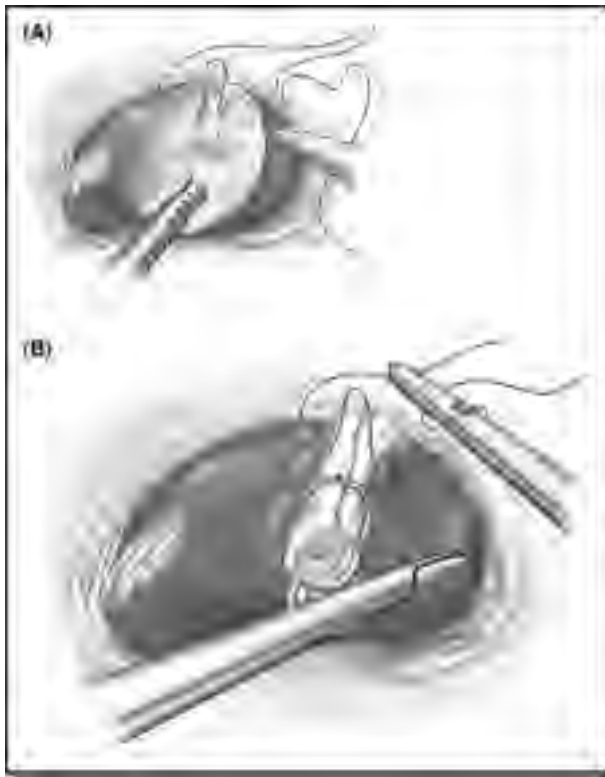


FIGURE 7 ■ (A) Hemostatic sutures are placed deep in the renal parenchyma using a CTX needle. The sutures are cinched tightly over prepared Surgicel® bolsters positioned in the parenchymal defect. (B) Intraoperative illustration of renal parenchymal repair.

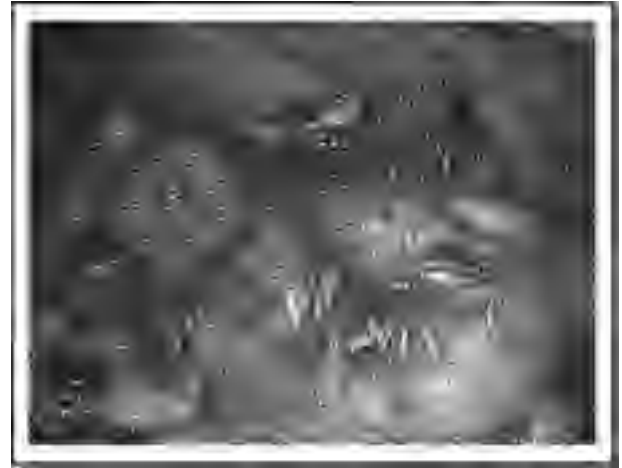

FIGURE 8 ■ Intraoperative photo of completed parenchymal suturing and unclamped renal hilum. Surgicel® bolsters fill the parenchymal defect at the site of excised renal tumor.

ALTERNATIVE TECHNIQUES

Renal Hilar Clamping

Renal hilar clamping is not necessary for every laparoscopic partial nephrectomy. Several centers have reported wedge-resection without hilar clamping for excision of small exophytic tumors with minimal parenchymal extension (6–8).



FIGURE 9 ■ Three ports are needed during retroperitoneal laparoscopic partial nephrectomy. The initial port is at the tip of the 12th rib. The posterior port is at the junction of the costal margin and the paraspinal muscle. The anterior port is 3–5 cm cephalad to anterior superior iliac spine.

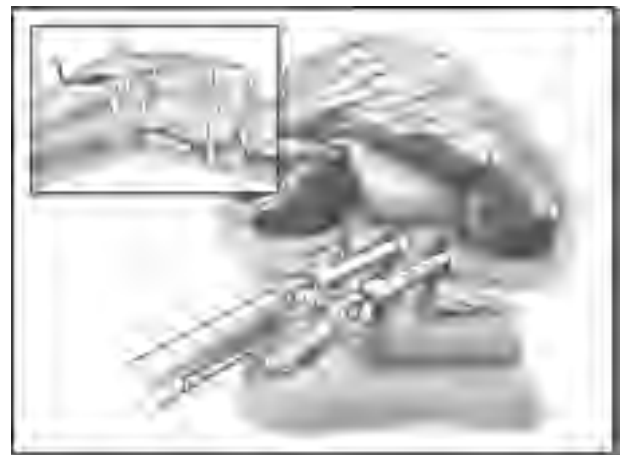


FIGURE 10 ■ During retroperitoneal laparoscopic partial nephrectomy laparoscopic bulldog clamps are used to clamp the renal artery and vein separately. Intraoperative illustration of the renal artery and vein individually dissected and controlled.

Although several novel techniques for achieving laparoscopic renal hypothermia have been investigated in the laboratory, a simple and reliable method has not been established yet.

Laparoscopic Renal Hypothermia

Reliable method of achieving renal hypothermia during laparoscopic partial nephrectomy remains a technical challenge. An accepted practice has been to limit warm renal ischemia to 30 minutes or less, beyond which ischemic renal injury is likely to occur, especially in the elderly or those with compromised baseline renal function.

Although several novel techniques for achieving laparoscopic renal hypothermia have been investigated in the laboratory, a simple and reliable method has not been established yet.

Currently reported techniques of laparoscopic hypothermia include renal cooling jacket, renal artery cold perfusion (9), and retrograde cold perfusion of the pelvicalyceal system through a ureteral catheter (10). At the Cleveland Clinic, laparoscopic renal hypothermia has been performed by the surface contact technique, akin to open surgery. Ice slush is instilled through a laparoscopic port into an Endocatch bag placed around the kidney. Using 600–750 cc of ice slush around the kidney, a nadir core renal parenchymal temperature of 5°C to 19°C was documented (11).

Hemostatic Techniques

Securing hemostasis during laparoscopic partial nephrectomy requires advanced laparoscopic skills and has thus limited the wider use of the laparoscopic approach for nephron-sparing surgery. Various techniques of parenchymal hemostasis have been reported in an attempt to establish a technically simpler method of securing hemostasis (12–14). Employment of laparoscopic harmonic scalpel, microwave coagulator, argon beam coagulator and application of fibrin glue may be helpful for mild parenchymal surface oozing.

The most effective method to control significant segmental parenchymal vessels remains the application of hemostatic parenchymal sutures duplicating the open surgical technique.

Vascular control by circumferential compression of the renal parenchyma using renal tourniquets and cable tie devices has been used during polar partial nephrectomies (15,16). Generally speaking the effectiveness of such devices is not clinically investigation. Other investigational hemostatic aids include prior microwave thermotherapy (17), or radiofrequency coagulation of the tumor with a needle probe followed by laparoscopic partial nephrectomy without hilar control (18). Laser tissue welding using human albumin as a solder to control bleeding and seal the collecting system during laparoscopic heminephrectomy system was described in the porcine model (19).

Potent bioadhesives may become an effective method for obtaining renal parenchymal hemostasis in the future.

The most effective method to control significant segmental parenchymal vessels remains the application of hemostatic parenchymal sutures duplicating the open surgical technique.

Potent bioadhesives may become an effective method for obtaining renal parenchymal hemostasis in the future.

SUMMARY

- The surgical technique for laparoscopic partial nephrectomy is now secure and reproducible.
- Effective duplication of standard open surgical principles is possible laparoscopically for select patients requiring nephron-sparing surgery.
- Laparoscopic partial nephrectomy is a technically advanced procedure requiring considerable laparoscopic skills and experience.
- Simplified methods for achieving renal hypothermia and securing hemostasis will facilitate wider dissemination of the laparoscopic approach.

REFERENCES

1. Uzzo RG, Novick AC. Nephron sparing surgery for renal tumors: indications, techniques, and outcomes. *J Urol* 2001; 166:6–18.
2. Gill IS, Desai MM, Kaouk JH, et al. Laparoscopic partial nephrectomy for renal tumor: duplicating open surgical techniques. *J Urol* 2002; 167:469–476.
3. Gill IS, Matin SF, Desai MM, et al. Comparative analysis of laparoscopic versus open partial nephrectomy for renal tumors in 200 patients. *J Urol* 2003; 170(1):64–68.
4. Coll DM, Uzzo RG, Herts BR, Davros WJ, Wirth SL, Novick AC. 3-dimensional volume rendered computerized tomography for preoperative evaluation and intraoperative treatment of patients undergoing nephron sparing surgery. *J Urol* 1999; 161(4):1097–1102.
5. Gill IS, Delworth MG, Munch LC. Laparoscopic retroperitoneal partial nephrectomy. *J Urol* 1994; 152:1539.
6. McDougall EM, Elbahnasy AM, Clayman RV. Laparoscopic wedge resection and partial nephrectomy—the Washington University experience and review of literature. *J Soc Laparoendosc Surg* 1998; 2:15.

7. Janetschek G, Abdelmaksoud AA. Laparoscopic wedge resection for renal cell carcinoma. *Curr Opin Urol* 2003; 13(3):203–208.
8. Kozlowski PM, Winfield HN. Laparoscopic partial nephrectomy and wedge resection for the treatment of renal malignancy. *J Endourol* 2001; 15(4):369–374.
9. Janetschek G, Abdelmaksoud A, Bagheri F, Al-Zahrani H, Leeb K, Gschwendtner M. Laparoscopic partial nephrectomy in cold ischemia: renal artery perfusion. *J Urol* 2004; 171(1):68–71.
10. Landman J, Venkatesh R, Lee D, et al. Renal hypothermia achieved by retrograde endoscopic cold saline perfusion: technique and initial clinical application. *Urology* 2003; 61(5):1023–1025.
11. Gill IS, Abreu S, Desai M, Steinberg A, Ng C, Banks K, Kaouk J. Laparoscopic ice slush renal hypothermia for partial nephrectomy: the initial experience. *J Urol* 2003; 170(1):52–56.
12. Hayakawa K, Baba S, Aoyagi T, et al. Laparoscopic heminephrectomy of a horse shoe kidney using microwave coagulator. *J Urol* 1999; 161(5):1559–1562.
13. Jackman SV, Cadeddu JA, Chen RN, Micali S, Moore RG, Kavoussi LR. Utility of the harmonic scalpel for laparoscopic partial nephrectomy. *J Endourol* 1998; 12(5):441–444.
14. Elashry OM, Wolf JS, Rayala HJ, McDougall EM, Clayman RV. Recent advances in laparoscopic partial nephrectomy: comparative study of electrosurgical snare electrode and ultrasound dissection. *J Endourol* 1997; 11(1):15–22.
15. Gill IS, Munch LC, Clayman RV, et al. A new renal tourniquet for open and laparoscopic partial nephrectomy. *J Urol* 1995; 154:1113.
16. Cadeddu JA, Corwin TS. Cable tie compression to facilitate laparoscopic partial nephrectomy. *J Urol* 2001; 165:177–178.
17. Terai A, Ito N, Yoshimura K, et al. Laparoscopic partial nephrectomy using microwave tissue coagulator for small renal tumors: usefulness and complications. *Eur Urol* 2004; 45(6):744–748.
18. Gettman MT, Bishoff JT, Su L-M, et al. Hemostatic laparoscopic partial nephrectomy: initial experience with the radiofrequency coagulation - assisted technique. *Urology* 2001; 58:8–11.
19. Ogan K, Jacomides L, Saboorian H, et al. Sutureless laparoscopic heminephrectomy using laser tissue soldering. *J Endourol* 2003; 17(5):295–300.

LAPAROSCOPIC PARTIAL NEPHRECTOMY: CURRENT STATUS

Massimiliano Spaliviero and Inderbir S. Gill

Section of Laparoscopic and Robotic Surgery, Glickman Urological Institute, Cleveland Clinic Foundation, Cleveland, Ohio, U.S.A.

- | | |
|---|--|
| ■ INTRODUCTION | ■ CENTRAL VS. PERIPHERAL TUMOR |
| ■ NEPHRON-SPARING SURGERY: CURRENT CONCEPTS | ■ HILAR CLAMPING VS. NON-CLAMPING |
| ■ NEPHRON-SPARING SURGERY: CURRENT INDICATIONS | ■ EFFECT OF TUMOR SIZE |
| ■ OPEN PARTIAL NEPHRECTOMY VS. LAPAROSCOPIC RADICAL NEPHRECTOMY | ■ LAPAROSCOPIC PARTIAL NEPHRECTOMY FOR CYSTIC MASSES |
| ■ LAPAROSCOPIC PARTIAL NEPHRECTOMY | ■ LAPAROSCOPIC PARTIAL NEPHRECTOMY FOR HILAR TUMORS |
| ■ RESULTS | ■ LAPAROSCOPIC PARTIAL NEPHRECTOMY IN THE SOLITARY KIDNEY |
| ■ MULTIPLE TUMORS | ■ TRANSPERITONEAL VS. RETROPERITONEAL LAPAROSCOPIC PARTIAL NEPHRECTOMY |
| ■ CONCOMITANT ADRENALECTOMY | ■ FINANCIAL ANALYSIS |
| ■ COMPLICATIONS | ■ HAND-ASSISTED LAPAROSCOPIC PARTIAL NEPHRECTOMY |
| ■ HEMOSTATIC AIDS AND IMPACT OF FLOSEAL | ■ FOLLOW-UP |
| ■ IMPACT OF WARM ISCHEMIA | ■ FUTURE DIRECTIONS: HYDRO-JET TECHNOLOGY |
| ■ LAPAROSCOPIC RENAL HYPOTHERMIA | ■ LASERS |
| ■ ONCOLOGIC OUTCOMES | ■ REFERENCES |
| ■ IMPACT OF PELVICALYCEAL SUTURE REPAIR | |
| ■ LAPAROSCOPIC HEMINEPHRECTOMY | |

INTRODUCTION

Epithelial tumors of the kidney account for 3% of all adult malignancies. Approximately 35,710 new renal cancer cases are estimated in the United States for the year 2004, and 12,480 patients will die of the disease (1). Occurring twice as often in men, it is the eighth and the 10th most common cancer in men and women, respectively (2).

Since the 1970s, the evaluation of unrelated abdominal complaints by widely available radiologic tests such as ultrasonography and computed tomography scan has led to a 2.3%–4.3% per year increase in detection of renal cancer case. As a consequence, the rate of incidental detection of small (≤ 4 cm) renal tumors of lower stage, with low metastatic potential has increased by 60%. This has led to an improvement in the five-year survival rates (3–5). During the past decade, the management of these small tumors has shifted gradually from radical nephrectomy to nephron-sparing surgery.

Clear cell carcinoma is the most common histologic type of renal cancer case (approximately 85% of renal neoplasm); it is typically sporadic, unifocal, and unilateral. Although papillary renal cancer case (10–15%) is more likely to be multifocal, it correlates with a better prognosis (90% five-year survival) compared with clear cell carcinoma. Other histologic types include chromophobe carcinomas (5% of renal cancer case; >90% long-term survival), collecting duct carcinoma (<1% of renal cancer case; in younger patients; more aggressive, survival <2 years in most patients). Usually considered benign tumors, renal oncocytomas are rarely metastatic (6).

Radical nephrectomy remains the cornerstone of curative treatment for this disease (7). However, comparably excellent results with nephron-sparing surgery for treatment of small, localized renal carcinoma have been reported.

NEPHRON-SPARING SURGERY: CURRENT CONCEPTS

Five-year survival rates after radical nephrectomy for stage I (T_1 – T_2) renal cancer case are 75% or more (8). Risk of recurrence is increased in patients with advanced stage T and positive lymph nodes.

Whenever preservation of functioning renal parenchyma is an important concern, nephron-sparing surgery is the preferred substitute for radical nephrectomy. The goal of nephron-sparing surgery is two-fold: (i) oncologically complete tumor excision, and (ii) preservation of a well-functioning renal remnant. Cancer-specific survival rates after nephron-sparing surgery for small (≤ 4 cm) renal cancer case are excellent (72–100%), and comparable to those obtained after radical nephrectomy (Table 1). At the same time, nephron-sparing surgery minimizes the risk of nephron loss (17).

Incidence of multifocal renal cancer case is 7–25%, with this incidence decreasing to 0–5% when the primary tumor is 4 cm or smaller in size. Risk of local recurrence after nephron-sparing surgery is less than 10% and is most likely a manifestation of previously undetected microscopic multifocal renal cancer case in the “normal” part of the kidney, i.e., the renal remnant (Table 2). Given concerns regarding renal cancer case multifocality, skeptics have raised the specter of parenchyma-sparing surgery to be cancer-sparing surgery. However, no linear or predictable relationship between multifocality and local recurrence has been reported (29).

To minimize local recurrences after nephron-sparing surgery, tumor excision including an adequate margin of normal parenchyma is essential (30,31). What constitutes an oncologically adequate width of parenchymal margin has been addressed recently. Long-term follow-up data confirm that a negative margin for tumor on histology is the primary criterion, with margin width having no practical consequence. Castilla et al. (32) found no correlation between long-term disease progression and width of the resection margin at a mean follow-up of 8.5 years. Other authors reported appropriate and comparable cancer control without local recurrence with resection margins ranging from 1 to 5 mm (33–37). Although surgical margin width appears to be ultimately irrelevant, during laparoscopic partial nephrectomy a margin of approximately 0.5 cm is aimed for to prevent inadvertent compromise of tumor margins.

A randomized controlled trial comparing radical and partial nephrectomy for small (< 4 cm) tumors showed similar median survival time at comparable follow-up (11). Belldgrun et al. (14) compared 146 patients undergoing nephron-sparing surgery for unilateral, solitary, or bilateral renal cancer case with a matched group of 125 patients who underwent radical nephrectomy for renal cancer case. In the partial nephrectomy group, survival in patients with T_2 versus T_1 lesions was 66% versus 100%, respectively ($p < 0.001$). Survival was comparable for patients with T_1 renal cancer case treated with either radical nephrectomy or nephron-sparing surgery, while survival was significantly better in patients with T_2 lesions treated with radical nephrectomy ($p = 0.001$). The authors concluded that nephron-sparing surgery benefits the select patient with localized unilateral renal cancer case less than 7 cm in size (ideally, < 4 cm). In patients with renal cancer case ≤ 4 cm in size, Lee et al. (15) reported a five-year disease-free survival rate of 96% after nephron-sparing surgery and 96% after radical nephrectomy, with no local recurrence in each group.

In a study of sporadic localized renal cancer case in 485 patients treated with nephron-sparing surgery, Hafez et al. (25) reported a five-year cancer-specific survival of 93%, with an renal cancer case recurrence rate of 10% (3.2% local recurrence; 5.8% metastatic disease).

TABLE 1 ■ Studies Comparing Renal Nephrectomy Versus Nephron-Sparing Surgery for Localized Renal Cancer Cases

Author	Radical nephrectomy		Nephron-sparing surgery	
	Total no. of pts.	% Cancer-specific 5-yr survival	Total no. of pts.	% Cancer-specific 5-yr survival
Butler et al. (9)	42	97	46	100
Lerner et al. (10)	209	89	185	89
D'Armiento et al. (11)	21	96	19	96
Indudhara et al. (12)	71	94	35	91
Barbalias et al. (13)	48	98.4	41	97.5
Belldgrun et al. (14)	125	91.2	146	98
Lee et al. (15)	183	95	79	95
Lau et al. (16)	164	97	164	98

Source: From Ref. 29.

TABLE 2 ■ Local Recurrence After Nephron-Sparing Surgery for Sporadic Renal Cancer Cases

Author	Total no. of pts.	No. LR (%)	No. isolated LR	No. LR + metastases
Jacobs et al. (18)	61	6 (10%)	5	1
Marberger et al. (19)	72	6 (8.3%)	3	3
Novick et al. (20)	100	9 (9%)	5	4
Morgan et al. (21)	104	6 (5.7%)	5	1
Steinbach et al. (22)	140	5 (3.6%)	5	0
Moll et al. (23)	142	2 (1.4%)	2	0
Licht et al. (24)	216	9 (4.2%)	3	6
Hafez et al. (25)	485	16 (3.2%)	7	9
Filipas et al. (26)	180	3 (1.7%)	3	0
McKiernan et al. (27)	292	7 (12%)	7	0
Ghavamian et al. (28)	76	7 (9.2%)	7	0

Source: From Ref. 8.

Reporting on a 10-year follow-up of patients treated with nephron-sparing surgery, Fergany et al. (38) documented cancer-specific survival of 88% at five and 73% at 10 years, respectively. Recurrences occurred locally (4%), at metastatic sites (21.5%), or combined (locally and distant metastases, in 6.5%). Cancer-specific survival in patients with unifocal, <4 cm tumor was 100% at 10 years with no local recurrence. Krejci and colleagues (39) documented a significantly inferior 10-year cancer-specific survival rate after nephron-sparing surgery for patients with clear cell renal cancer case compared to papillary/chromophobe renal cancer case (91.5% vs. 99%, $p = 0.029$). As such, these clinicopathologic features should be considered in preoperative decision-making, patient counseling, and surveillance.

NEPHRON-SPARING SURGERY: CURRENT INDICATIONS

Absolute indications include synchronous bilateral renal cancer case, tumor in solitary kidney (unilateral renal agenesis or previous contralateral nephrectomy), or unilateral tumor with poorly/nonfunctioning contralateral kidney, wherein radical nephrectomy would render the patient anephric (with a subsequent immediate need for dialysis) (40). As shown by Ghavamian et al. (28), open nephron-sparing surgery in a solitary kidney can be performed safely: 5- and 10-year cancer-specific survival rates were 80.7% and 63.7%, respectively, and local recurrence-free survival rates were 89.2% and 80.3%, respectively.

Relative indications for NS include clinical circumstances where the contralateral kidney is at threat or risk for future impaired function due to systemic disease: hereditary renal cancer case syndromes, genetic diseases increasing the risk of metachronous kidney cancer, diabetes, hypertension, stone disease, or renovascular disease. Elective indications for partial nephrectomy comprise small (≤ 4 cm) solid renal tumors or suspicious indeterminate cystic renal lesions with malignant potential in the presence of a normal contralateral kidney.

Comparing 164 radical nephrectomy versus 164 elective nephron-sparing surgery for renal cancer case, Lau et al. (16) reported a five-year cancer-specific survival of 97% and 98%, respectively. Ipsilateral adrenal fossa recurrence occurred in one patient after radical nephrectomy, while local recurrence occurred in four nephron-sparing surgery patients. Progression to renal insufficiency at 10 years (increase in serum creatinine >2 mg/dL) occurred in 22.4% of radical nephrectomy and 11.6% of nephron-sparing surgery cases ($p = 0.01$).

Elective nephron-sparing surgery in patients with a normal contralateral kidney remains somewhat controversial (41). In this setting, Novick (42) detailed the results of nephron-sparing surgery for unilateral localized renal cancer case in 315 patients with a normal opposite kidney. Accurate patient selection with small tumor size (<3.5 cm) resulted in a favorable mean cancer-specific survival rate of 95% (only two patients with local tumor recurrence) at approximately three years of follow-up after nephron-sparing surgery. Comparing radical nephrectomy versus elective nephron-sparing surgery in patients with a normal contralateral organ, Lerner et al. (10) reported five-year cancer-specific survival rates of 96% and 92%, respectively, concluding that radical

nephrectomy and nephron-sparing surgery achieve equivalent cure in select patients with renal cancer case. In a recent study by Herr (43), 10-year cancer-free survival rate after elective nephron-sparing surgery for small (mean size 3 cm), unifocal, low-grade and low-stage tumors and normal contralateral kidney was a robust 97%.

In patients with small (<4 cm), unilateral stage $T_{1-2}N_0M_0$ renal cancer case, Licht et al. (24) reported no postoperative tumor recurrences and a cancer-specific five-year survival rate of 100%. Considering that a significant 23% of 292 tumors preoperatively suspicious for malignancy were found to be benign on final histology, McKiernan et al. (27) recently emphasized their rationale of routinely performing partial nephrectomy.

The bulk of reported data indicate nephron-sparing surgery to be an acceptable therapeutic option with improved survival in patients with a single, small (<4 cm), low pathologic stage renal cancer case in the presence of a normal contralateral kidney. However, nephron-sparing surgery results may be somewhat less satisfactory in patients with larger (>4 cm) or multiple localized renal cancer case. In such patients, radical nephrectomy likely remains the treatment of choice when the opposite kidney is normal.

OPEN PARTIAL NEPHRECTOMY VS. LAPAROSCOPIC RADICAL NEPHRECTOMY

Laparoscopic radical nephrectomy is now an accepted option for treatment of $T_1-T_{3a}N_0M_0$ renal tumors (44). Laparoscopic radical nephrectomy is associated with diminished postoperative discomfort and shorter recovery compared with open surgery, while providing similar local control and oncologic cure rates.

Cadeddu et al. (45) reported a multi-institutional study of 157 patients undergoing LRN for clinical stage I (T_1-T_2) renal cancer case. The five-year actuarial disease-free rate for patients was 91%. Matin et al. (46) retrospectively compared outcomes of 35 LRN versus 82 open nephron-sparing surgery. Strict study inclusion criteria included patients with a solitary ≤ 4 cm renal tumor, normal serum creatinine, and normal contralateral kidney. Mean blood loss, operative time, narcotic use, and hospital stay were significantly decreased in the laparoscopic group. Patients undergoing open nephron-sparing surgery experienced a lesser postoperative increase in serum creatinine (0% vs. 25%, $p < 0.001$). The authors concluded that the significant short- and intermediate-term benefits of the laparoscopic approach as regards superior patient recovery and decreased morbidity should be weighed against the long-term advantage of better renal function associated with nephron-sparing surgery.

LAPAROSCOPIC PARTIAL NEPHRECTOMY

Laparoscopic partial nephrectomy is an emerging minimally invasive nephron-sparing alternative to open partial nephrectomy. However, before laparoscopic partial nephrectomy can be recommended for widespread use, reproducible technical, perioperative, pathologic, functional, and oncologic outcomes comparable to open partial nephrectomy must be confirmed. Advances in laparoscopic skills and technology have allowed efficacious achievement of renal hilar vascular control, renal hypothermia (if required), tumor excision, calyceal suture repair, and hemostatic parenchymal suture repair. As such, current laparoscopic partial nephrectomy techniques duplicate the established principles of open nephron-sparing surgery (47). Since its development in a porcine model by McDougall et al. (48), several successful clinical experiences of laparoscopic partial nephrectomy have been reported. The first application of transperitoneal laparoscopic partial nephrectomy was reported by Winfield et al. (49) in a woman with a stone-bearing lower pole calyceal diverticulum. Retroperitoneoscopic partial nephrectomy was first described by Gill and coworkers (50). Depending upon the radiologic features and location of the individual tumor, laparoscopic partial nephrectomy may be performed by the transperitoneal or the retroperitoneal approach (51).

Laparoscopic partial nephrectomy was initially limited to the treatment of select small, solitary, peripheral, superficial, exophytic tumor (49,50,52–56). With increasing experience, these indications have been carefully expanded to include patients with tumor infiltrating the parenchyma up to the collecting system or the renal sinus, completely intrarenal tumors, tumor abutting the renal hilum, tumor in a solitary kidney, large-size tumor requiring heminephrectomy, or a renal mass in the presence of concomitant renovascular disease (47,51,57).

Morbid obesity and the presence of more than two renal tumors increase the technical difficulty of performing laparoscopic partial nephrectomy. Relative contraindications for laparoscopic partial nephrectomy include a central intrarenal located tumor, and prior open kidney surgery. Current contraindications for laparoscopic partial nephrectomy include the presence of a renal vein thrombus, and a locally advanced tumor. Patients with impaired coagulation, such as hemorrhagic diathesis, platelet dysfunction due to azotemia, or anticoagulant therapy must be approached cautiously with adequate medical preparation to minimize their hemorrhagic risk (58). Patients with atherosclerotic renovascular disease or those with status post-percutaneous renal artery stenting are at increased risk of intimal injury during renal artery clamping. Adequate laparoscopic experience is necessary before embarking on laparoscopic partial nephrectomy.

A recent questionnaire-based survey assessed the current attitude of community urologists towards novel surgical options for renal cancers (59). An anonymous questionnaire was mailed to 174 members of the Minnesota Urological Society, with a response rate of 49%. Two clinical scenarios were proposed: (i) the case of a 6-cm lesion with no indication for nephron-sparing surgery, and (ii) the case of a 3-cm lower pole exophytic mass suitable for nephron-sparing surgery. In the first scenario, 14% of respondents would have offered laparoscopic surgery only, 43% open surgery only, and 43% either form of therapy. For the second scenario, 10% of responders would have offered minimally invasive treatment only, 55% open surgery only, and 35% either forms of therapy. In the latter scenario, laparoscopic partial nephrectomy would have been offered by 38% of respondents. The authors concluded that minimally invasive surgery for renal tumors is evolving into a standard of care, with a trend that is increasingly reaching the community urologist. Nevertheless, appropriately so, there remains a heavy reliance on referrals to select tertiary-referral centers with extensive laparoscopic experience.

RESULTS

The evolving worldwide experience with laparoscopic partial nephrectomy for tumor is listed in Table 3. A multicenter European experience in 53 patients was reported by Rassweiler et al. (61). The average tumor size was 2.3 cm (range, 1.1–5). Transperitoneal approach was used in 28% of cases. Mean operating time was 3.2 hours (range, 1.5–5.3), and estimated blood loss 725 mL (range, 20–1500). Intraoperative complications included pneumothorax in one patient, and bleeding in four, of whom two underwent open conversion. Postoperative complications included bleeding requiring reintervention in one patient, and urinary leak in five patients. Two patients with urinary leak also had concomitant bleeding and were treated with nephrectomy. Histology showed 37 pT₁ renal cancer case (69%), and 100% overall disease-free survival rate at three-year follow-up.

Jeschke et al. (62) reported outcomes of laparoscopic partial nephrectomy without hilar clamping in 51 patients with small (<2 cm), peripheral, exophytic, solid renal tumors. The Ultracision device^a was employed for tumor wedge resection, and hemostasis was achieved with bipolar coagulation with fibrin glue-coated cellulose. Mean

TABLE 3 ■ Worldwide Experience with Pure Laparoscopic Partial Nephrectomy (Series Involving More Than 10 Cases)

Author	No. of pts	Size	RCC	OR time	WI time	EBL	LOS	Compl.	Follow-up	Recurrence
Harmon et al. (60)	15	2.3	80	170		368	2.6	0	8	0
Janetschek et al. (53)	25	1.9	76	162		287	5.8	12	22.2	0
Rassweiler et al. (61)	53	2.3	69	191	—	725	5.4	28	24 ^a	0
Jeschke et al. (62)	51	2	76	132	—	282	5.8	10	34.2	0
Simon et al. (63)	19	2.1		130	—	120	2.2	26.3	8.7	
Kim et al. (64)	79	2.5	79	181.9	26.7	391.2	2.8	19.7	19.8	0
Gill et al. (65)	100	2.8 ^b	70	180 ^b	27.8	125 ^b	2 ^b	19	>7.2	0

^aMulti-institution experience.

^bMedian.

Abbreviations: RCC, renal cancer carcinoma; OR, operating room; EBL, estimated blood loss; LOS, length of stay; Compl, complications.

Source: From Ref. 58.

^aEthicon, Cincinnati, OH.

operative time was 2.2 hours (range, 1.2–5), mean blood loss was 282 mL (range, 20–800), and no open conversion was necessary. Complications occurred in 10% of patients, including pneumothorax (one), urinary leak (three), and late hemorrhage requiring open reintervention (one). Pathology confirmed renal cancer case in 76% of patients. At a mean follow-up of 34.2 months (range, 3–78), neither local recurrence nor distant metastasis occurred. One patient with papillary carcinoma presenting with metachronous de novo renal cancer case in the operated kidney one year after wedge resection was treated with laparoscopic radical nephrectomy.

Gill et al. (65) compared patients undergoing laparoscopic partial nephrectomy ($n = 100$) with open nephron-sparing surgery ($n = 100$) for a solitary ≤ 7 cm tumor. The median tumor size was 2.8 versus 3.3 cm in the laparoscopic versus open group, respectively ($p = 0.005$). The tumor was located centrally in 35% of cases in the laparoscopic group and in 33% of cases in the open group ($p = 0.83$). Indication for partial nephrectomy was imperative in 41% versus 54% of patients, respectively ($p = 0.001$). Comparing the laparoscopic and open groups, median surgical time (3 vs. 3.9 hrs; $p < 0.001$) and blood loss (125 vs. 250 mL; $p < 0.001$) were lesser in the laparoscopic group, while warm ischemia (warm ischemia) time was longer during laparoscopic partial nephrectomy (28 vs. 18 min; $p < 0.001$). Laparoscopic patients experienced less postoperative analgesia (20.2 vs. 252.5 mg of morphine sulfate equivalents; $p < 0.001$), shorter hospital stay (2 vs. 5 days; $p < 0.001$), and quicker convalescence (4 vs. 6 weeks; $p < 0.001$). Histology revealed renal cell carcinoma in 75% of patients in the laparoscopic group and 85% in the open group ($p = 0.003$). Positive surgical margins occurred in 3% and 0%, respectively ($p = 0.11$). Intraoperative and renal/urologic complications were higher in the laparoscopic (5% and 11%, respectively) versus open (0% and 2%, respectively) group ($p = 0.02$ and 0.01 , respectively). No local or port-site recurrence occurred in the laparoscopic group. Based on these data, the authors concluded that although open partial nephrectomy remained the standard nephron-sparing surgery for renal tumors, laparoscopic partial nephrectomy was emerging as an effective minimally invasive alternative. At the Cleveland Clinic, the senior author's experience with laparoscopic partial nephrectomy now exceeds 420 cases (Table 4). In the initial 300 patients (66), the indication for laparoscopic partial nephrectomy was imperative in 40% of patients, median warm ischemia time was 32 minutes, median operative time was 3.3 hours, and median hospital stay was 2.6 days. Pathology confirmed renal cell carcinoma in 71% of patients.

MULTIPLE TUMORS

Renal cell carcinoma may be multifocal at presentation in 6.5–25% of cases, and satellite tumors may be detected in 15.6% of cases (67,68). Although many consider radical nephrectomy (open or laparoscopic) as the standard of care for such cases, consensus is lacking. A recent report demonstrated the feasibility of performing minimally invasive nephron-sparing surgery in the setting of multiple renal tumors. A total of 27 multiple tumors in 13 patients were treated by a combination of minimally invasive treatments (69). The indication for nephron-sparing surgery was imperative in 92% of patients. Minimally invasive treatments performed included en bloc excision of adjacent tumors during laparoscopic partial nephrectomy (three); individual laparoscopic partial nephrectomy of discrete, distant masses (two); laparoscopic partial nephrectomy of one mass and laparoscopic cryoablation of the other (two); and laparoscopic cryoablation of all masses (six). Mean tumor size treated by laparoscopic partial nephrectomy was 2.5 cm (range, 1–4.1), mean size of masses treated by cryotherapy was 1.8 cm (range, 0.9–3.2), mean operative time was 4.3 hours, and mean blood loss was 169 mL. Mean warm ischemia time was 40 minutes in patients treated with laparoscopic partial nephrectomy for adjacent masses, and 30 minutes in patients undergoing laparoscopic partial nephrectomy and cryotherapy. No intraoperative complications occurred. Postoperative complications included pneumonia (one), deep venous thrombosis treated with systemic anticoagulation and vena cava filter (one), and sepsis (one). Pathology confirmed renal carcinoma in 83% of all excised specimens with negative margins. Core needle biopsies before cryoablation showed renal carcinoma in 54% of specimens. After a mean follow-up of 16.4 months (range, 1–54), disease did not recur either locally or systematically in any patient. A new ipsilateral, distant from cryotherapy site, tumor developed in one patient 54 months postoperatively. The authors concluded that the judicious combination of complementary minimally invasive techniques was safe and efficacious.

TABLE 4 ■ Laparoscopic Partial Nephrectomy at the Cleveland Clinic: Single-Surgeon Experience in the Initial 300 Cases

Parameter	No. (%)
Median age (years)	62
Male	178 (59%)
Median body mass index	28.2
Median ASA score	3
Median preoperative S-creatinine (mg/dL)	1
Right side	133 (44%)
Tumor type on CT (<i>n</i> = 276) ^a	
Exophytic	99 (36%)
Infiltrating up to sinus	86 (31%)
Infiltrating not up to sinus	80 (29%)
Completely intrarenal	11 (4%)
Tumor location (<i>n</i> = 259) ^a	
Peripheral	180 (69%)
Central	79 (31%)
Tumors abutting hilum (<i>n</i> = 211) ^a	13 (6%)
Laparoscopic approaches	
Transperitoneal	201 (67%)
Retroperitoneal	99 (33%)
Intraparenchymal extension (intraoperative ultrasonography) (<i>n</i> = 202) ^a (cm)	1.4
Median operative time (hours)	3.3
Median warm ischemia time (minutes)	32
En bloc clamping of renal hilum (laparoscopic Satinsky clamp)	215 (72%)
Median blood loss (mL)	150
Median % of tumor excision (surgeon perception)	20
Heminephrectomy	66 (22%)
Pelvicalyceal suture repair	236 (78%)
Overall intraoperative complication	17 (6%)
Hemorrhage	8 (2.7%)
Inferior epigastric artery injury	2 (0.7%)
Other	7 (2.3%)
Overall postoperative complication	34 (12%)
Hemorrhage	6 (2%)
Atelectasis	5 (1.7%)
Urine leak	4 (1.3%)
Atrial fibrillation	3 (1%)
Deep vein thrombosis	2 (0.6%)
Pleural effusion	2 (0.6%)
Pneumonia	2 (0.6%)
Renal insufficiency	3 (1%)
Other	7 (2.3%)
Overall late complications	30 (10%)
Hemorrhage	9 (3%)
Urine leak	6 (2%)
Congestive heart failure	2 (0.6%)
Deep vein thrombosis	2 (0.6%)
Renal insufficiency	2 (0.6%)
Sepsis	2 (0.6%)
Wound infection	2 (0.6%)
Other	5 (1.6%)
Hospital stay (days)	2.6
Renal cell carcinomas on pathology	211 (71%)
Positive surgical margin	3 (1%)
RCC	2 (0.6%)
Oncocytoma	1 (0.3%)

^aData were considered "not available" if the parameter was not clearly described in the CT report, intraoperative ultrasound report, or operative note.

Source: From Ref. 66.

CONCOMITANT ADRENALECTOMY

Incidence of adrenal involvement from renal cell carcinoma is 1–2% (70). Candidates for nephron-sparing surgery for an upper pole tumor may present with contiguous involvement of the adrenal gland (pT_{3a} tumor) or hematogenous involvement of the gland (M₁ tumors) (71). In such cases, partial or radical nephrectomy with concomitant adrenalectomy is indicated. Ramani et al. (72) reported concomitant ipsilateral adrenalectomy during laparoscopic partial nephrectomy in four patients with an upper pole renal tumor and suspected adrenal involvement. Preoperative three-dimensional computed tomography scan revealed renal tumor abutting the adrenal gland in three patients, and a 4-cm adrenal mass in one patient. Using a transperitoneal approach, en bloc adrenalectomy was performed first, followed by laparoscopic partial nephrectomy. The adrenal gland was maintained en bloc with the partial nephrectomy specimen. No intraoperative complication occurred, and open conversion was not necessary in any patient. Urinary leak occurred in one patient. One (25%) renal tumor was confirmed renal cancer case on pathology, while all adrenals (three normal adrenal glands and one adenoma) were free from malignant involvement. The authors highlighted some caveats, including adrenalectomy before laparoscopic partial nephrectomy to respect oncologic principles, no dissection between the adrenal and the renal upper pole to prevent tumor spillage and lymphatic violation, prevention of excessive manipulation of the reconstructed kidney to maintain renal parenchymal hemostasis, and limitation of warm ischemia to laparoscopic partial nephrectomy only.

COMPLICATIONS

Numerous studies regarding open nephron-sparing surgery present data on technical and renal-related complications secondary to partial nephrectomy (Table 5) (76,77). Urinary fistula is the most frequent complication following nephron-sparing surgery. Other complications include hemorrhage, ureteral obstruction, and acute or chronic renal insufficiency. Corman et al. (78) compared complications after open radical ($n = 1373$) and open partial ($n = 512$) nephrectomy. Analyzing surrogate-to-complication morbidities (progressive renal insufficiency, acute renal failure, UTI, prolonged ileus, postoperative transfusion requirement, and deep wound infection), no significant differences were detected ($p = 0.58$) between radical nephrectomy and nephron-sparing surgery in specific complication rates (Table 6).

The most common complications of laparoscopic partial nephrectomy include intraoperative or delayed hemorrhage, urine leak, and open conversion (Table 7). In the first 200 consecutive patients undergoing laparoscopic partial nephrectomy from August 1999 to January 2003 at the authors' institute (80), perioperative complications occurred in 66 patients (33%). Open conversion was required in two patients (1%) due to dense postsurgical adhesions (one), and persistent bleeding secondary to inadequate renal hilum clamping (one). Reoperative laparotomy was necessary in four patients (2%) for delayed hemorrhage after discharge (two), ischemia of the colon (one), and leakage from the ileoileal anastomosis in one patient undergoing laparoscopic ileal ureter for inadvertent ureteral injury during laparoscopic partial nephrectomy. Overall, hemorrhagic complications (Table 8) occurred in 19 patients (9.5%), of whom 18 required blood transfusion. Intraoperative hemorrhages ($n = 7$; 3.5%) were due to bulldog malfunction (three), Satinsky clamp malfunction (one), systemic coagulopathy (one), or inadequate control of multiple renal arteries (two). Intraoperative hemorrhage was managed with laparoscopic parenchymal suturing in five patients, laparoscopic radical nephrectomy in one patient with normal contralateral kidney, and emergent open conversion in one patient. Four patients (2%) developed postoperative bleeding from the partial nephrectomy bed at a mean interval of two days; all responded to conservative management. Delayed hemorrhagic complications after hospital discharge occurred in eight patients (4%) at a mean interval of 16 days (range, 6–30). Etiology of the delayed hemorrhage included vigorous exercise (one), accidental fall (one), coagulopathy (one), systemic heparinization (one), intraoperatively unrecognized splenic tear (one), or unknown (three). Patients with delayed hemorrhage were treated conservatively (four), or with percutaneous selective angioembolization (two); two patients underwent explorative laparotomy. Urinary leak occurred in nine patients (4.5%), eight (89%) of whom had intraoperative suture repair of pelvicalyceal entry during laparoscopic partial nephrectomy. Management included J-stenting in six patients, J-stenting and CT-guided drainage in two patients, or conservatively in one patient. Other urological complications occurred in 4.5% of patients and included transient renal

TABLE 5 ■ Open Partial Nephrectomy: Complications

Author	Total no. of patients	Urinary fistula (%)	Bleeding (%)	Acute hemodialysis (%)	Perioperative deaths (%)	Reoperation (%)
Marberger et al. (19)	72	6.5	4.3	4.3	2.2	2.2
Petritsch et al (73)	120	—	—	0.8	1.7	—
Morgan and Zincke (21)	104	3.3	1.1	1.1	2.2	—
Steinbach et al. (22)	140	2.1	1.4	—	1.4	1.4
Moll et al. (23)	152	6.7	3.7	—	—	0.6
Campbell et al. (74)	259	17.4	2.3	4.9	1.5	3.1
Polascik et al. (75)	67	9	0	0	1.5	0
Lerner et al. (10)	169	1.8	—	0	0.6	1.8
Belldegrun et al. (14)	146	1.4	2.1	—	2.1	2.1
Ghavamian et al. (28)	76	2.6	1.3	1.3	—	9.2

Source: From Ref. 41.

TABLE 6 ■ Comparison of Complications Between Open RN and Open NSS

Author	Total no. of pts	Open NSS: no. of compl. (%)	Open RN: no. of compl. (%)	p Value
Uzzo et al. (76)	80	4 (8%)	2 (7%)	>0.05
Lee et al. (15)	262	9 (11%)	25 (14%)	0.62
Lau et al. (16)	328	11 (6.7%)	10 (6%)	NS
Corman et al. (78)	1885	146 (10.5%)	68 (13.3%)	NS
Shekarriz et al. (77)	120	6 (10%)	2 (3.3%)	0.2

Abbreviation: NS, not significant; NSS, nephron-sparing surgery; RN, radical nephrectomy.
Source: From Ref. 77.

insufficiency (four), inferior epigastric artery injury (one), epididymitis (one), transient hematuria (one), and ureteral injury (one). Non-urological complication occurred in 15% of patients including pulmonary (ten), cardiovascular (nine), musculoskeletal (five), gastrointestinal (four), or septic (two).

Complications occurring after laparoscopic partial nephrectomy and laparoscopic radical nephrectomy for renal tumors ≤ 4.5 cm were recently assessed by Kim et al. (64). In the laparoscopic partial nephrectomy group ($n = 79$), mean operative time was 3 hours, mean warm ischemia time 26.4 minutes (range, 13–37), and mean blood loss 391.2 mL. Four patients (5.1%) had hemorrhages requiring blood transfusion, with one open conversion. Specific intraoperative complications during laparoscopic partial nephrectomy included one ureteral injury, one lumbar vein injury, and one splenic capsule injury treated laparoscopically. Two cases of postoperative urinary leak were treated conservatively with suction drains. However, comparing laparoscopic partial nephrectomy with the laparoscopic radical nephrectomy group, no significant differences were noted as regards specific complications. Positive surgical margin were detected in two laparoscopic partial nephrectomy patients (2.5%), of whom one underwent laparoscopic radical nephrectomy, while a 26-month disease-free follow-up was observed in the other patient.

HEMOSTATIC AIDS AND IMPACT OF FLOSEAL

The specific technical challenge of laparoscopic partial nephrectomy lies in achieving a bloodless operative field for precise tumor excision and pelvicalyceal repair followed by renal hemostasis in a time-sensitive manner, with the least possible compromise of renal function. Achieving prompt and durable hemostasis is of paramount importance. Several techniques of parenchymal hemostasis during laparoscopic partial nephrectomy have been reported with varying success, including cauterization of the cut surface with argon beam coagulation, electrocautery, harmonic scalpel, gelatin

TABLE 7 ■ Laparoscopic Partial Nephrectomy: Complications

	Ramani (79) (n = 200)	Kim et al. (64) (n = 79)	Jeschke et al. (62) (n = 51)	Rassweiler et al. (61) (n = 53)	Simon et al. (63) (n = 19)
% Open conversion	1	1	0	8	
Intraoperative					
Renal hemorrhage	6	4	—	4	—
Inferior epigastric artery injury	1	—	—	—	—
Lumbar vein tear	—	1	—	—	—
Splenic capsule tear	—	1	—	—	—
Ureteral injury	1	1	—	—	—
Tumor fragmentation	—	—	—	—	1
Bowel injury	1	—	—	—	—
Pleural injury	1	—	—	—	—
Transient pneumothorax	—	—	1	1	—
Postoperative					
Bleeding	5	—	1	1	1
Urinary leak	2	2	3	3	—
Urinary leak + bleeding	—	—	—	2	—
Acute renal failure	3	1	—	—	—
Atrial fibrillation	2	—	—	—	—
Atelectasis	3	1	—	—	1
Pneumonia	2	—	—	—	1
Dyspnea	—	—	—	—	1
Pleural effusion	1	—	—	—	—
Pulmonary embolism	1	—	—	—	—
Deep vein thrombosis	2	—	—	—	—
Colonic segmental ischemia	1	—	—	—	—
Prolonged ileus	1	—	—	—	—
Gluteal fasciotomy	1	—	—	—	—
Foley catheter clot	—	1	—	—	—
Total	34	12	5	11	5

sponges and fibrin glue application, microwave thermotherapy, ultrasonic surgical aspirator, laser (holmium:neodymium:YAG laser), or prior radiofrequency coagulation (62,80–86). Physical compression of the kidney using parenchymal tourniquets and cable tie devices has been described in an attempt to achieve regional vascular control during polar partial nephrectomies (48,88,89).

Gettman et al. (85) performed laparoscopic partial nephrectomy with the assistance of radiofrequency coagulation technique in 10 patients with a solid renal lesion. A spherical area of coagulation including both the lesion and a 1-cm margin (at least) of normal parenchyma was created by deploying a percutaneously positioned radiofrequency probe. After probe withdrawal, the lesion and 0.5–1 cm of normal parenchyma were excised using laparoscopic scissors or ultrasound shears. Median blood loss was 125 mL, and complete hemostasis was reported in all cases. However, insufficient deployment of the RF probe in one patient resulted in large blood loss (700 mL) due to incomplete coagulation of a margin. Thus, adjunctive agents (fibrin glue, argon beam coagulation, or oxidized cellulose) were necessary. Negative margins were confirmed by frozen section analysis of 5 mm cup biopsies from the surgical bed.

Biologic hemostatic agents have been employed to facilitate hemostasis during laparoscopic partial nephrectomy (90,91). Fibrin sealant (glutaraldehyde cross-linked fibers derived from bovine collagen) application facilitates the last step of the clotting cascade (fibrinogen to fibrin conversion). Further, cross-linking of soluble fibrin monomers creates an insoluble fibrin clot acting as a vessel sealant. The gelatin granules (500–600 μ m size) swell upon contact with blood and create a composite hemostatic plug with physical bulk that mechanically controls hemorrhage independently from the natural coagulation cascade (92).

Bak et al. (93) used gelatin matrix thrombin tissue sealant for achieving effective hemostasis during laparoscopic partial nephrectomy in six patients. Their technique consisted of thrombin gel slurry application to the cut parenchymal surface after tumor

TABLE 8 ■ Laparoscopic Partial Nephrectomy in 200 Patients: Causes of Hemorrhage

Intraoperative	7 (3.5%)
Bulldog clamp malfunction	3 (1.5%)
Multiple arteries	2 (1%)
Satinsky clamp malfunction	1 (0.5%)
Generalized non-renal bleed	1 (0.5%)
Postoperative	12 (6%)
Coagulopathy/azotemia	3 (1.5%)
Cause unknown	6 (3%)
Exercise/fall induced	2 (1%)
Splenic capsule tear	1 (0.5%)

Source: From Ref. 79.

resection, followed by a 1–2 minutes compression of the resected surface with a sponge stick. After releasing the previously positioned hilar clamp, hemostasis was obtained within 5–10 minutes. No bleeding occurred after clamp removal, and no blood transfusions were required. The collecting system was not entered in any patient. Median operative time was 3.2 hours (range, 1.5–3.9), median warm ischemia time was 13 minutes (range, 10–14), and median blood loss was 200 mL (range, 50–350). Although the use of this bioadhesive was reserved for selected, small, exophytic, superficial tumors not requiring pelvicalyceal entry, the results of this study, particularly as regards shortened warm ischemia time, were encouraging.

The capability of the biologic hemostatic sealant Floseal^{®b} in facilitating hemostasis during laparoscopic partial nephrectomy was recently evaluated at the authors' institute (94). After completing the initial 224 laparoscopic partial nephrectomies, from patient number 225 onwards the author's laparoscopic partial nephrectomy technique (51) was modified to incorporate topical application of the gelatin matrix thrombin sealant (Floseal) to cover the partial nephrectomy bed prior to sutured renorrhaphy over a bolster. The prepackaged hemostatic sealant comprised 1.5 cm³ of dry bovine-derived gelatin matrix provided in one syringe, and 5000 U.S. units of bovine-derived thrombin provided in a vial, which was drawn up in a second syringe. The two were admixed, thereby creating 4 cm³ of gelatin matrix thrombin slurry in a single syringe. This syringe was connected by luer lock to a 14Fr, 30 cm long reusable metal delivery cannula introduced into the abdomen through a 5 or 10/12 mm laparoscopic port. The slurry was layered directly onto the renal surface, covering the entire partial nephrectomy bed. Surgical bolster was then positioned and renorrhaphy sutures secured prior to hilar unclamping. Usually, two vials of Floseal were employed per patient. The gelatin matrix and thrombin slurry were used within 2–3 minutes of being admixed (if allowed to stand for a longer duration of time, the slurry becomes more viscid, making it difficult to inject through the metal cannula). Postoperative strict bed rest for 24–48 hours, followed by restricted activity for two weeks, was prescribed. The impact of Floseal on reducing hemorrhagic complications was evaluated by comparing two sequential groups of patients: group I = no Floseal ($n = 68$), and group II = with Floseal ($n = 63$). Group I (no Floseal) and group II (with Floseal) were comparable as regards tumor size, number of central tumors, and performance of pelvicalyceal suture repair (84% vs. 92%; $p = 0.16$). Intraoperative variables were also comparable as regards mean warm ischemia time (36.1 vs. 37.2 minutes; $p = 0.55$), blood loss (150 vs. 106 cm³; $p = 0.36$), operative time, and hospital stay. Compared to the no Floseal group, the Floseal group had significantly decreased overall complications (37% vs. 16%; $p = 0.008$), and tended towards a lower rate of hemorrhagic complications (12% vs. 3%), although this did not achieve statistical significance ($p = 0.08$). In the authors' experience, adjunctive use of gelatin matrix thrombin sealant substantially enhanced parenchymal hemostasis and decreased procedural and hemorrhagic complications to levels comparable with contemporary open partial nephrectomy series. As such, this gelatin matrix–thrombin tissue sealant has become a routine part of laparoscopic partial nephrectomy at our institution. However, we emphasize that ready facility with laparoscopic suturing is important to manage persistent hemorrhage occurring despite the use of gelatin matrix thrombin sealant.

Urena et al. (95) reported their initial experience with a monopolar radio frequency device^c to perform laparoscopic partial nephrectomy without clamping the renal vasculature. A monopolar device that uses radio frequency energy with low-volume saline irrigation (4–6 cm³/min) was employed for simultaneous blunt dissection, hemostasis, and coagulation (coagulation power of 80 W on a regular electrosurgical generator) of the renal parenchyma. Technical characteristics of this technology included precoagulation of soft tissue with simultaneous sealing of small-sized blood vessels, parenchymal thermal coagulation depth directly proportional to the type and duration of contact between the device and the parenchyma, and saline-facilitated energy transfer at the tissue–device interface preventing tissue desiccation and smoke production. The study was conducted on 10 patients with a mean tumor size of 3.9 cm (range, 2.1–8). Mean operative time was 3.9 hours (range, 2.4–4.7), and mean blood loss was 352 mL (range, 20–1000). Technical difficulties due to posterior tumor location led to open conversion in a morbidly obese patient. Blood transfusion was required in one case, and mean hospital stay was 1.7 days (range, 1–5). Postoperative complications included urinary leak managed by ureteral stenting in one patient. Pathology confirmed renal cancer case in

^bBaxter Healthcare, Deerfield, IL.

^cTissueLink, TissueLink Medical, Inc., Dover, U.K.

80% of patients, with negative margins in all cases; no interference with pathological evaluation of surgical margins due to tissue charring were reported.

IMPACT OF WARM ISCHEMIA

Hemostasis remains a primary task during laparoscopic partial nephrectomy. Temporary en bloc renal hilar clamping allows a bloodless field with enhanced visualization during tumor excision and renal repair. Supported by experimental and clinical data, several modalities of hilar control during laparoscopic partial nephrectomy have been advocated, including the clamping of the renal artery alone, both renal artery and vein, and intermittent occlusion (96–98). Advantages and disadvantages of these means are still debated (99,100), yet conclusive data are not available. Critical renal ischemia time has generally been considered to be a 30-minute cutoff (101). In this setting, eventual recovery requires three days. Laparoscopic partial nephrectomy may require somewhat longer ischemic times compared to open nephron-sparing surgery (65). Nevertheless, complete recovery of renal function after 60 minutes of warm ischemia has been reported (102,103).

Shekarritz et al. (104) prospectively evaluated the impact of warm ischemia on postoperative renal function in 17 patients undergoing transperitoneal laparoscopic partial nephrectomy with hilar clamping for exophytic tumors. Preoperative and postoperative differential glomerular filtration rate and renal function was evaluated in all patients by technetium-99-labeled diethylenetetraminepenta-acetic acid renal scans performed one month before and three months after laparoscopic partial nephrectomy. Mean operative time was 3.1 hours (range, 1.5–4.8), mean warm ischemia time 22.5 minutes (range, 10–44), mean blood loss 305 cm³ (range, 50–1000), and mean hospital stay 2.15 days (range, 1–3). Postoperative complications included pulmonary edema in one patient, and arterio-calyceal fistula in one patient. Preoperatively, mean creatinine was 0.89 mg/dL (range, 0.7–2), mean glomerular filtration rate in the target kidney was 75.56 mL/min (range, 39.4–105), and mean differential renal function of the target kidney was 50.2% (range, 43–58%). On postoperative evaluation at three months mean serum creatinine was 0.96 mg/dL (range, 0.7–1.9), mean glomerular filtration rate in the operated kidney was 72.03 mL/min (range, 31–101), and mean differential renal function in operative kidney was 48.07% (range, 39–63%). Hilar clamp time did not significantly correlate with change in renal function, or change in glomerular filtration rate. The authors concluded that temporary hilar clamping during laparoscopic partial nephrectomy with a mean warm ischemia time of 22.5 minutes was safe in patients with functioning contralateral kidney.

We evaluated the impact of renal hilar clamping-induced warm ischemia on renal function in 179 patients undergoing laparoscopic partial nephrectomy for tumor at our center (105). Attention was focused on 15 patients undergoing laparoscopic partial nephrectomy for tumor in a solitary kidney, and on 12 patients with both functioning kidneys who had objectively documented differential renal function (preoperative and one-month postoperative serum creatinine levels and radionuclide renal scans) undergoing unilateral laparoscopic partial nephrectomy. Overall mean warm ischemia time was 31 ± 10 minutes (range, 4–55). For further analysis, the entire study population was stratified according to (i) warm ischemia time (warm ischemia ≤ 30 minutes; warm ischemia ≥ 30 minutes); (ii) warm ischemia and age (\geq warm ischemia < 30 minutes; warm ischemia > 30 minutes; age < 70 years; age (70 years)); and (iii) warm ischemia and baseline serum creatinine (\geq warm ischemia < 30 minutes; warm ischemia > 30 minutes; serum creatinine < 1.5 mg/dL; serum creatinine (1.5 mg/dL)). In this study, no kidney was lost due to ischemic sequelae. The nadir postoperative serum creatinine in patients with a solitary kidney was commensurate with the approximate amount of renal parenchyma resected. Temporary postoperative hemodialysis was required after 60% laparoscopic heminephrectomy in one patient with a 6.5 cm tumor in a solitary kidney. Comparing preoperative and one-month postoperative renal scans in the 12 patients with both functioning kidneys, calculated reduction of function from baseline in the operated kidney was 29%. Expectedly, unilateral laparoscopic partial nephrectomy in the setting of bilateral functioning kidneys did not show significant impact on serum creatinine. The authors concluded that a warm ischemia time of approximately 30 minutes leads to minimal clinical sequelae.

LAPAROSCOPIC RENAL HYPOTHERMIA

Warm ischemia dramatically limits the time available to perform tumor resection and collecting system and parenchymal repair during laparoscopic partial nephrectomy,

forcing the surgeon to operate “under the gun” in a race against time. As such, techniques to achieve viable renal hypothermia by minimally invasive methods have been described. The initial described technique of laparoscopic renal hypothermia was reported by Gill et al. (106) first described the technique of laparoscopic renal hypothermia. Intracorporeal surface contact renal hypothermia was performed in 12 patients. After complete mobilization, the kidney was entrapped in an Endocatch-II bag^d, whose drawstring was cinched around the intact hilum. The renal hilum was then occluded with a Satinsky clamp; the bottom of the bag was retrieved through a 12 mm port site, opened, and 600–750 mL of ice-slush delivered into the bag with 30 mL syringes within a period of 4–7 minutes. Needle thermocouples confirmed achievement of protective levels of hypothermia, with core renal temperatures in the 5–19°C range.

Janetschek (107) achieved kidney cooling by continuous perfusion of 1000 mL of cold (4°C; perfusion rate = 50 mL/min) Ringer’s lactate through an angiocatheter placed into the clamped renal artery in 15 patients undergoing laparoscopic partial nephrectomy for renal cell carcinoma. At a parenchymal temperature of 25°C, a steady state was maintained by reducing the perfusion rate to 25–33 mL/min. Tumor excision was performed in a bloodless field. Mean ischemia time was 40 minutes (range, 27–103). Increased blood loss was noted in two initial patients: in one due to inadequate intraluminal balloon occlusion and in the other due to perfusion pump malfunction causing venous backflow from the injured renal vein. Blood transfusion was necessary in another patient. Reoperative laparoscopy was performed in one patient for postoperative hemorrhage. The feasibility and safety of cold ischemia via arterial perfusion during laparoscopic partial nephrectomy was demonstrated. However, since optimal hypothermic renoprotection from ischemia occurs with temperatures <15°C, these techniques need further refinement to deliver adequate levels of hypothermia.

Renal hypothermia has also been achieved by retrograde pelvicalyceal cold saline perfusion via a ureteral access sheath. Clinical application of this technique was described in a patient undergoing open radical nephrectomy. Cortical and medullary temperatures obtained were 24°C and 21°C, respectively, which are somewhat higher than optimal hypothermia temperature of 15°C (108).

ONCOLOGIC OUTCOMES

Tumor cell seeding is a major concern in laparoscopic surgery. The first reported cases of tumor seeding in urologic laparoscopy were noted after lymphadenectomy or node biopsies for bladder and prostate cancer in four and one patients, respectively. However, a specimen entrapment sac was not used in any of these initial cases (109). One of the most common sites of tumor seeding is the port where the specimen is retrieved. To date, a few cases of tumor seeding after laparoscopic renal surgery have been reported: three cases occurring after laparoscopic radical nephrectomy, and four cases after laparoscopic nephroureterectomy (61,110). Theoretically, tumor seeding during laparoscopic partial nephrectomy may occur due to high risk of tumor perforation or tumor cell spillage by contaminated instruments. In a recent survey undertaken by Micali et al. (111), 18,750 urologic laparoscopic procedures performed between 1990 and 2003 were considered, of which 10,912 were for tumor, and 555 were laparoscopic partial nephrectomies. Although the overall incidence of tumor seeding was 0.1% (13 of 10,912), no cases of tumor seeding after laparoscopic partial nephrectomy were noted in this study.

In order to become a standard procedure for the treatment of small renal tumors, long-term follow-up tumor-free survival rates of laparoscopic partial nephrectomy should approach those of open partial nephrectomy. However, results regarding local and distant cancer control have been excellent over the short- and intermediate-term follow-up available to date. Rassweiler et al. (61) reported no evidence of recurrent disease in 100% of 37 patients undergoing laparoscopic partial nephrectomy for stage T₁ renal cancer case at a mean follow-up of two years. Allaf et al. (112) evaluated oncological outcome of laparoscopic partial nephrectomy in 48 patients with pT₁ (42 patients, 87.5%) or pT_{3a} (six patients, 12.5%) renal carcinoma. Positive surgical margin rate was 2.1%. Histology demonstrated clear cell in 32 patients (67%), and papillary in 10 (21%). Laparoscopic extraction of a morcellated specimen was performed in 22.9% of cases. At a mean follow-up of 37.7 months (range, 22–84), no recurrences were noted

^dU.S. Surgical Corp., Norwalk, CT.

in 95.8% of patients. Local recurrence occurred at 18 months in a patient with von Hippel-Lindau disease, and at four years in the ipsilateral kidney of a patient who underwent laparoscopic partial nephrectomy with specimen morcellation for a pT₁ (2 cm) Fuhrman grade II clear cell tumor. From the oncological standpoint, these data are comparable with those after open nephron-sparing surgery.

IMPACT OF PELVICALYCEAL SUTURE REPAIR

Precise entry into the collecting system is often necessary to provide a safe margin of resection during laparoscopic excision of intraparenchymal, deeply infiltrating tumors. Desai et al. (47) compared the perioperative data of 27 patients undergoing laparoscopic partial nephrectomy with pelvicalyceal entry (group I) with 37 patients undergoing laparoscopic partial nephrectomy with no pelvicalyceal entry (group II). Mean depth of parenchymal tumor invasion was 1.5 ± 0.8 cm in group I and 0.9 ± 0.3 cm in group II. Precise intraoperative localization of collecting system entry during laparoscopic partial nephrectomy was obtained by retrograde injection of dilute indigo carmine through a previously placed ureteral catheter. Mean warm ischemia time was longer in group I versus group II (30.2 vs. 19.4 minutes; $p < 0.0001$). Pelvicalyceal suture repair was associated with longer hospital stay (3 vs. 1.8 days; $p = 0.003$). No patient undergoing pelvicalyceal entry and suture repair developed urinary leak. The authors concluded that, although laparoscopic partial nephrectomy for a tumor extending up to the collecting involves freehand laparoscopic suturing, resulting in somewhat longer, although acceptable, warm ischemia time good outcomes can be expected with a low incidence of urinary leakage.

Recently, Bove et al. (99) specifically evaluated the necessity of ureteral stenting for decreasing urinary leak after laparoscopic partial nephrectomy for single, localized, unilateral, sporadic, ≤ 4.5 cm renal tumors. Patients undergoing 5Fr open-ended ureteral catheter placement prior to laparoscopic partial nephrectomy (group I, $n = 54$) were compared with patients without ureteral catheter placement (group II, $n = 49$). Postoperative urinary leak (drain urinary output > 50 cm³ per 24 hours) occurred in one patient in each group. In both these patients, the pelvicalyceal system had been suture-repaired intraoperatively during laparoscopic partial nephrectomy. Both urinary leaks were successfully managed conservatively with suction drains. The authors concluded that preoperative placement of a ureteral catheter for retrograde injection to identify collecting system entry was not routinely necessary (62). However, at the Cleveland Clinic, we continue to routinely employ a ureteral catheter because of the following reasons: (i) it is the only way to precisely identify the location of pelvicalyceal entry, (ii) occasionally, pelvicalyceal entry can occur at two different locations, which would be difficult to locate precisely without retrograde injection after one entry site has been repaired, and (iii) retrograde injection allows testing the water-tightness of pelvicalyceal suture repair.

Alternative techniques of pelvicalyceal repair were proposed by other investigators, including sealing of the laparoscopic partial nephrectomy bed using oxidized regenerated cellulose mesh impregnated with gelatin resorcinol formaldehyde glue, and fibrin-impregnated hemostatic gauze or heat-activated tissue adhesive (54,61). In the former experience, postoperative urinoma occurred despite an indwelling double-J stent in 14% of patients; in the latter (a multi-institutional experience on 53 patients), 10% of patients who underwent laparoscopic partial nephrectomy required reintervention (nephrectomy, percutaneous drainage, or ureteral stenting) for postoperative urinoma formation (113).

LAPAROSCOPIC HEMINEPHRECTOMY

Our careful expansion of laparoscopic partial nephrectomy indications included select patients with more complex tumors such as upper pole tumor with concomitant adrenalectomy, tumor invading deeply into the parenchyma up to the collecting system or renal sinus, tumor abutting the renal hilum, tumor in a solitary kidney, and more recently, a tumor substantial enough to require heminephrectomy (47,72). Finelli et al. (114) evaluated technical efficacy and outcomes of laparoscopic heminephrectomy for large and/or deeply infiltrating tumors requiring a substantial resection (defined herein as $>30\%$) resection of the renal parenchyma. Since August 1999, 41 patients were deemed to have undergone laparoscopic heminephrectomy (group I). A contemporary group of 41 consecutive patients who underwent laparoscopic partial nephrectomy

(<30% resection) were retrospectively identified for comparison (group II). Preoperative patient demographics were similar, except for a higher BMI ($p = 0.02$) in group I. Group I had larger tumors (3.7 vs. 2.3 cm, $p < 0.001$), which were more commonly central (41% vs. 9.8%, $p = 0.001$) and more deeply infiltrating ($p < 0.001$) compared to group II. Group I underwent larger parenchymal resections ($p < 0.001$) and routine pelvicalyceal suture repair ($p = 0.002$). Warm ischemia time was longer in group I (39 vs. 33 minutes, $p = 0.02$); however, blood loss (150 vs. 100 mL, $p = 0.28$) and total operative time (3.7 vs. 3.2 hours, $p = 0.09$) were comparable between the groups. Analgesic requirements, hospital stay, overall complications, and postoperative serum creatinine were comparable between the groups. On histopathology, all 82 surgical margins were negative. The authors concluded that although laparoscopic heminephrectomy is an advanced procedure, it can be performed efficaciously with equivalent outcomes to outcomes equivalent to those of less substantial resections.

CENTRAL VS. PERIPHERAL TUMOR

Centrally located tumors typically require precise intracorporeal suturing and complex reconstruction. As such, in the past they have not been approached laparoscopically due to the added time constraints imposed by renal ischemia. Only a limited experience in eight patients with central tumors using a hand-assisted technique has been reported (115). Open partial nephrectomy remains the gold standard for the treatment of centrally located tumors (116,117). Frank et al. (118) specifically addressed the outcomes of pure laparoscopic partial nephrectomy for central tumors and compared with peripherally located tumors. In 363 patients undergoing laparoscopic partial nephrectomy, tumors were located centrally in 154 patients, and peripherally in 209. Central tumors were defined as tumors touching, abutting, or directly invading the collecting system on the preoperative three-dimensional computed tomography. Lesions with no contact with the pelvicalyceal system were classified as peripheral. Preoperative, intraoperative, postoperative, and pathologic data were compared. Central tumors were larger in size on preoperative imaging (median 3.0 vs. 2.4 cm, $p < 0.001$) and had larger specimens at surgery (median 43 vs. 22 g, $p < 0.001$) than peripheral tumors. Although blood loss was similar (150 cm³), central tumors required longer operative times (3.5 vs. 3 hours, $p = 0.008$), warm ischemia times (33.5 vs. 30.0 minutes, $p < 0.001$), and hospital stay (67 vs. 60 hours, $p < 0.001$). The incidence of margin positivity was 0.8% versus 1.7% ($p = 0.502$) for the central and peripheral groups. The median postoperative creatinine was 1.2 and 1.1 mg/dL for central and peripheral lesions, respectively. Intraoperative and late postoperative complications were comparable. However, there were more early postoperative complications in the central group (6% vs. 2%, $p = 0.05$).

HILAR CLAMPING VS. NON-CLAMPING

Guilloneau et al. (119) compared 12 patients undergoing laparoscopic partial nephrectomy with renal hilar clamping versus 16 patients undergoing laparoscopic partial nephrectomy without hilar control. The non-clamping group experienced significantly greater blood loss (708 vs. 270 mL; $p = 0.014$) and longer operative time (3 vs. 2 hours; $p = 0.004$) compared to laparoscopic partial nephrectomy with hilar clamping. Postoperative serum creatinine levels were not significantly different (1.3 vs. 1.45 mg/dL, respectively; $p = 0.08$) between groups. In another study, Kane et al. (120) compared 15 patients undergoing laparoscopic partial nephrectomy with arterial occlusion with 12 patients undergoing laparoscopic partial nephrectomy without arterial occlusion. A nonsignificant 10% postoperative increase of serum creatinine from preoperative baseline levels was observed in each group. Postoperative renal failure did not develop in any patient, and hemodialysis was not required. In nine patients, postoperative technetium-99 mercaptoacetyl triglycine renal scan revealed near equal split (49% vs. 51%) of postoperative renal function reflecting minimal impact of mean warm ischemia time of 43 minutes (range, 25–65). The authors concluded that temporary artery occlusion had no measurable negative effect on renal function.

EFFECT OF TUMOR SIZE

Steinberg et al. (Steinberg AP, Matin SF, Gill IS. Effect of tumor size on laparoscopic partial nephrectomy. Personal communication) evaluated the effect of tumor size by

retrospectively dividing 100 patients undergoing laparoscopic partial nephrectomy into three groups: patients with a tumor <2 cm in size (group I, $n = 15$); patients with a tumor size of 2–4 cm (group II, $n = 76$); and patients with a tumor size >4 cm (group III, $n = 9$). Comparing groups I, II, and III, increasing tumor size associated with significantly longer operative time (2.9 vs. 3.1 vs. 3.9 hours, respectively; $p = 0.03$), greater blood loss (75 vs. 150 vs. 200 mL, respectively; $p = 0.001$), more frequent need of collecting system entry and suture repair (47% vs. 64% vs. 89%, respectively; $p = 0.004$), and higher incidence of complications (13% vs. 25% vs. 33%, respectively; $p = 0.02$). No differences were noted in terms of warm ischemia time ($p = 0.65$) and hospital stay ($p = 0.16$). Pathology showed renal cancer case in 53%, 74%, and 67% of patients in group I, II, and III, respectively ($p = 0.33$). The authors concluded that laparoscopic partial nephrectomy could be performed safely and effectively for select patients with a tumor larger than 2 cm in size.

LAPAROSCOPIC PARTIAL NEPHRECTOMY FOR CYSTIC MASSES

Scant data are available as regards laparoscopic nephron-sparing surgery for cystic lesions. Many centers employ laparoscopic techniques for the management of symptomatic renal cysts. However, the risk of potential seeding of cells due to inadvertent tumor spillage during laparoscopic cyst manipulation remains a concern in laparoscopic partial nephrectomy for indeterminate renal cysts. Thirty-five patients with a complex renal cyst were evaluated laparoscopically by Santiago et al. (121). No local or distant recurrence was noted in all five patients (14%) with cystic renal cancer case after a mean follow-up of 20.2 months. The authors recently updated this experience and presented long-term follow-up results in 57 patients with indeterminate Bosniak II and III cystic lesions. None of the 11 patients (19%) found to have cystic renal cancer case had evidence of laparoscopic port site, renal fossa, local or distant recurrence at a mean follow-up of 40 months (122).

Spaliviero et al. (123) recently reported their experience with laparoscopic partial nephrectomy in 50 patients with a cystic renal lesion. Of 284 patients undergoing laparoscopic partial nephrectomy at the Cleveland Clinic since August 1999, 50 (19%) patients presented with a suspicious Bosniak \geq II cystic lesion on preoperative computed tomography scan (group I). Outcome data were retrospectively compared with 50 consecutive patients undergoing laparoscopic partial nephrectomy for a solid renal mass (group II). Mean tumor size was 3 cm in group I and 2.6 cm in group II ($p = 0.07$). Perioperative parameters were comparable in groups I and II. Final histopathology revealed renal cancer case in 20%, 25%, 46%, and 90% of patients with Bosniak II ($n = 10$), II ($n = 4$), III ($n = 13$), and IV ($n = 20$) cysts, respectively. All patients had negative surgical margin. Inadvertent intraoperative puncture/spillage of the cystic tumor did not occur in any instance in patients in group I. Mean follow-up was 14 months (range, 1 month to three years). The solitary recurrence in the entire series of 284 laparoscopic partial nephrectomy cases occurred in group I at one year in a patient who, despite negative surgical margins during initial laparoscopic partial nephrectomy, developed retroperitoneal recurrent disease that was resected open surgically at one year. The authors concluded that although laparoscopic partial nephrectomy nephrectomy for a suspicious cystic mass was feasible and efficacious, extreme caution and refined laparoscopic technique had to be exercised to prevent cyst rupture and local spillage.

LAPAROSCOPIC PARTIAL NEPHRECTOMY FOR HILAR TUMORS

Partial nephrectomy for hilar tumor represents a technical challenge not only for laparoscopic but also for open surgeons. Tumors located in the region of the renal hilum, in actual physical contact with the main renal vessels, have been considered by many to be beyond the scope of laparoscopic techniques. Further, the application of probe-ablative therapies such as cryoablation and radio frequency ablation for hilar tumors have the real potential of causing thermal injury to the renal vascular endothelium, resulting in thrombosis.

Gill et al. (124) recently reported the technical feasibility and perioperative outcomes of laparoscopic partial nephrectomy for hilar tumors. In 362 patients undergoing laparoscopic partial nephrectomy for tumor by a single surgeon between 01/2001 and 09/2004, 25 (6.9%) had a hilar tumor. Hilar tumor was defined as a tumor located in the renal hilum and demonstrated to be in physical contact with the renal artery and/or renal vein on preoperative three-dimensional computed tomography. En bloc hilar clamping with cold excision of tumor, including its delicate mobilization from the

renal vessels, followed by sutured renal reconstruction was performed routinely. Laparoscopic surgery was successful in all cases, without any open conversion or operative reintervention. Mean tumor size was 3.7 cm (range, 1–10.3); four patients (16%) had a solitary kidney, and indication for laparoscopic partial nephrectomy was imperative in 10 (40%). Pelvicalyceal repair was performed in 22 patients (88%); mean warm ischemia time was 36.4 minutes (range, 27–48), blood loss was 231 cm³ (range, 50–900), total operative time was 3.6 hours (range, 2–5), and hospital stay was 3.5 days (range, 1.5–6.7). Histopathology confirmed renal cancer case in 17 patients (68%), all with negative margins. Hemorrhagic complications occurred in three patients (12%), all in 2002 or prior. No kidney was lost for technical reasons. The authors offered five specific caveats for performing laparoscopic partial nephrectomy in the setting of a hilar tumor: (i) preoperative three-dimensional computed tomography scan with 3 mm cuts and video rendering to accurately assess (a) laparoscopic resectability as regards anatomic characteristics of the tumor and (b) the individual surgeon's comfort level in performing laparoscopic partial nephrectomy for that particular tumor; (ii) considerable dissection of the renal artery and/or vein towards the renal sinus to dissect the tumor off the renal vessels prior to hilar clamping; (iii) tumor excision to be performed in a preplanned manner from a lateral to medial direction to allow safer initial renal parenchymal and subsequent tumor retraction out of the partial nephrectomy bed (on occasion, direct feeding blood vessels entering the tumor directly from the main renal artery and/or vein can be identified, clipped, and divided); (iv) dedicated inspection to identify any arteriotomy, venotomy, or pelvicalyceal entry, and its precise suture repair, with routine use of Floseal as a hemostatic adjunct, as needed; (v) extreme care during sutured renal reconstruction not to compromise the main arterial blood supply and venous drainage of the renal remnant.

LAPAROSCOPIC PARTIAL NEPHRECTOMY IN THE SOLITARY KIDNEY

A patient with a renal tumor in a solitary kidney has an absolute indication for nephron-sparing surgery. Scant data are available in this regard. Gill et al. (65), measuring serum creatinine results in a cohort of eight patients with a solitary kidney who underwent laparoscopic partial nephrectomy for renal tumor, examined the effects of laparoscopic partial nephrectomy on renal function. Analysis of serum creatinine on postoperative day 1 and the repeat serum creatinine value within 30 days showed a mean change of 0.07 mg/dL after 30 days, which was comparable to open surgery.

Bhayani et al. (125) reported laparoscopic partial nephrectomy in four patients with a tumor in a solitary kidney. All four patients had undergone prior contralateral radical nephrectomy for renal cell carcinoma. Mean tumor size was 2.2 cm (range, 1.8–2.8). A transperitoneal approach was employed in all instances. Mean operative time was 4.2 hours, mean warm ischemia time 15 minutes (range, 7–28), mean blood loss 395 mL (range, 100–800), and mean hospital stay three days (range, 2–4). No perioperative complications occurred. Pathology confirmed renal cancer case in 75% of cases, all with negative margins. No evidence of disease had been detected at a mean follow-up of 17 months (range, 3–35). The mean preoperative baseline serum creatinine was 1.5 mg/dL (range, 1.0–1.8). Postoperative return to baseline creatinine required three days in three patients, and longer in one patient (six postoperative weeks). As previously assessed (9), none of the patients presented long-term change in renal function.

TRANSPERITONEAL VS. RETROPERITONEAL LAPAROSCOPIC PARTIAL NEPHRECTOMY

Ng et al. (126) has been recently retrospectively compared the outcomes of 100 transperitoneal and 63 retroperitoneal laparoscopic approach to partial nephrectomy for tumor. Choice of laparoscopic approach was dictated primarily by tumor location: transperitoneal laparoscopic partial nephrectomy for anterior or lateral lesions and retroperitoneal laparoscopic partial nephrectomy for posterior or posterolateral lesions. The approaches differed primarily by technique of hilar control since en bloc hilar control was achieved with a Satinsky clamp during transperitoneal laparoscopic partial nephrectomy, while during retroperitoneal laparoscopic partial nephrectomy individual control of renal artery and vein was obtained with two bulldog clamps. retroperitoneal laparoscopic partial nephrectomy was employed to manage 77% of posterior tumors,

whereas 97% of anterior tumors were managed with transperitoneal laparoscopic partial nephrectomy. Transperitoneal laparoscopic partial nephrectomy was associated with significantly larger tumors (3.2 vs. 2.5 cm, $p < 0.001$), more calyceal suture repairs (79% vs. 57%; $p = 0.004$), longer ischemia time (31 vs. 28 minutes; $p = 0.04$), longer operative time (3.5 vs. 2.9 hours; $p < 0.001$), and longer hospital stay (2.9 vs. 2.2 days; $p < 0.01$) compared to retroperitoneal laparoscopic partial nephrectomy. Blood loss, perioperative complications, postoperative serum creatinine, analgesic requirements, and histologic outcomes were comparable between the groups. The authors concluded that limited retroperitoneal space makes retroperitoneal laparoscopic partial nephrectomy technically more challenging but provides superior access to posterior, particularly posteromedial, lesions. However, whenever feasible, they preferred the transperitoneal approach for laparoscopic partial nephrectomy because of its larger working area for intracorporeal renal reconstruction. Also, transperitoneal laparoscopic partial nephrectomy was the preferred approach for all anterior or lateral tumors, as well as large or deeply infiltrating posterior tumors that required substantive guillotine resection (heminephrectomy).

FINANCIAL ANALYSIS

Data comparing cost effectiveness of laparoscopic versus open approach to renal tumor resection are scant. During laparoscopic partial nephrectomy, increased costs due to longer operating room time and more expensive equipment may be balanced by shorter length of hospital stay and shorter convalescence time. Retrospective case-matched studies comparing open radical nephrectomy versus open partial nephrectomy costs have shown comparable hospital costs ($p = 0.81$) (77).

Steinberg et al. (127) from Cleveland performed a preliminary, retrospective comparison of the financial data of 15 patients undergoing laparoscopic partial nephrectomy versus 15 patients undergoing open partial nephrectomy. All patients in the two groups had a normal contralateral kidney, comparable tumor size (2.4 cm in the laparoscopic partial nephrectomy group vs. 2.5 cm in the open group, $p = 0.50$), and uncomplicated perioperative course. When compared to the open group, the laparoscopic partial nephrectomy group was associated with 20.1% greater intraoperative costs ($p < 0.001$) and 55% lesser postoperative costs ($p < 0.001$). Overall, hospital costs for laparoscopic partial nephrectomy were 15.6% lesser than open surgery ($p = 0.002$).

HAND-ASSISTED LAPAROSCOPIC PARTIAL NEPHRECTOMY

In order to simplify and increase viability of laparoscopic partial nephrectomy, some surgeons have employed a hand-assisted laparoscopic approach of nephron-sparing surgery. Stifelman and colleagues (128) reported their experience with hand-assisted laparoscopic partial nephrectomy (without hilar clamping) in 11 patients. Direct parenchymal compression through the hand port, argon-beam coagulator, and adjunctive agents (e.g., oxidized cellulose) were employed to control hemostasis. Mean operative time was 4.5 hours, mean blood loss 319 mL, and mean hospital stay 3.3 days. One patient required open conversion.

Comparing 10 LPNs (hand-assisted in eight patients) with a matched group of open partial nephrectomies, Wolf et al. (81) reported longer operative times (+24%) and increased blood loss in the hand-assisted group. However, pain medication requirements (−62%), hospital stay (−43%), and convalescence (−64%) were lesser in the hand-assisted group. In another study, Brown et al. (115) reviewed their initial series of 30 hand-assisted laparoscopic partial nephrectomy, comparing the results of central (<5 mm from the collecting system or hilum; $n = 8$) versus peripheral ($n = 22$) lesions. After tumor excision using endoscopic cold scissors, argon beam coagulation followed by fibrinogen-soaked sponge application (subsequently activated with thrombin) was employed to control hemostasis. No hilar clamping was performed. As regards the entire series, mean tumor size was 2.6 cm (range, 1–4.7), mean blood loss 415 mL (range, 50–2100), and mean operative time 3.6 hours (range, 90–332). When compared with peripheral lesions, centrally located lesions were associated with greater blood loss (240 ± 113 vs. 894 ± 552 cm³, respectively), and higher rate of blood transfusion (9.1% vs. 50%, respectively) due to intraoperative or delayed hemorrhage, or symptomatic anemia. Resection of the laparoscopic partial nephrectomy bed was necessary in five

cases due to positive initial resection margin on frozen section (100% negative margin after re-resection). Considering the 3–4-fold increase in blood loss, transfusion rate, and a urinary leak associated with laparoscopic partial nephrectomy for central lesion, the authors suggested the utility of hilar clamping in this setting.

FOLLOW-UP

Patients undergoing laparoscopic nephron-sparing surgery for renal cancer case are advised to return for initial follow-up four weeks postoperatively. At that time, physical examination to exclude surgical complications, serum hemoglobin and hematocrit to assess recovery of perioperative blood loss, serum creatinine measurement, and a MAG-3 radionuclide renal scan are obtained to document renal function and anatomy. In patients with impaired overall renal function, a renal ultrasound or a magnetic resonance imaging is performed instead of the renal scan.

Hafez et al. (129) developed guidelines for long-term surveillance after nephron-sparing surgery for renal cancer case. Tumor recurrence patterns after nephron-sparing surgery for sporadic localized renal cancer case were analyzed in 327 patients. renal cancer case recurred postoperatively in 11.7% of patients. According to initial pathologic tumor stage, they reported the incidence of postoperative local tumor recurrence and metastatic disease as follows: 0% and 4% for T₁ renal cancer case, 2% and 5.3% for T₂ renal cancer case, 8.2% and 11.5% for T_{3a} renal cancer case, and 10.6% and 14.9% for T_{3b} renal cancer case. They recommended a surveillance scheme including annual evaluation of medical history, physical examination, and selected blood studies (serum calcium, alkaline phosphatase, liver function tests, blood urea nitrogen, serum creatinine, and electrolytes). A 24-hour urinary protein measurement should be obtained in patients with a solitary remnant kidney to screen for hyperfiltration nephropathy. Patients who undergo nephron-sparing surgery for pT₁ renal cancer case do not require radiographic imaging postoperatively. A yearly chest radiograph is recommended after nephron-sparing surgery for pT₂ or pT₃ renal cancer case. Abdominal computed tomography scanning is indicated every two years in patients with pT₂ renal cancer case, and every six months for two years, then every two years in patients with pT₃ renal cancer case.

FUTURE DIRECTIONS: HYDRO-JET TECHNOLOGY

Future directions include potentially bloodless renal parenchymal incision without hilar clamping with the use of hydro-jet technology. This technology employs a high-pressure water jet to perform selective tissue dissection in a relatively bloodless manner. Spared intrarenal vessels may then be controlled with clips or bipolar coagulation, and the renal collecting system suture repaired (130). Basting et al. (131) reported the initial clinical experience using water jet resection in 24 patients undergoing open surgery for renal-cell carcinoma, nephrolithiasis, complicated cysts, or oncocytoma. The hydro-jet device produces parenchymal incision along the desired line without violating the intrarenal vasculature and collecting system. Resection time ranged from 14 to 40 minutes, and intraoperative blood loss was reportedly minimal. No significant postoperative complications occurred. Histologic investigation of tissue samples with standard light microscopy after hematoxylin–eosin staining demonstrated sharp tissue incision with no thermal alterations or deep necrosis and only a small disruption zone at the dissection margins. The authors concluded for the efficacy of water jet dissection in organ-sparing kidney surgery. Recent series regarding the use of hydro-jet during laparoscopic partial nephrectomy in the animal model showed promising results. Shekarriz et al. (130) and Corvin et al. (132) have recently performed detailed evaluations of the hydro-jet device in the porcine animal model. Moinzadeh et al. (133) staged bilateral laparoscopic partial nephrectomy without renal hilar vessel control using the Helix Hydro-jet^{®d} in a survival bovine model. Parenchymal hydro-dissection was performed with a high velocity ultracoherent saline stream at 450 pounds per square inch (psi) through a small nozzle with integrated suction at the tip. The denuded intrarenal parenchymal blood vessels were precisely coagulated with a bipolar instrument (BIClamp^{®d}) and transected. All LPNs were completed successfully without open conversion. Eighteen of 20 LPNs (90%) were performed without hilar clamping. Mean hydro-jet partial nephrectomy time was 63 minutes (range, 13–150), estimated blood

^dERBE, Tübingen, Germany.

loss was 174 cm³ (range, 20–750), and mean volume of normal saline used for hydrodissection was 260 cm³ (range, 50–1250). Pelvicalyceal suture repair was necessary in five of 10 (50%) chronic kidneys. Follow-up involved biochemical, radiologic, and histopathologic evaluation at designated euthanasia intervals (one, two weeks, and one, two, and three months). No animal developed a urinary leak. Histological sections from the acute specimen revealed a thin (1 mm) layer of adherent coagulum at the amputation site with minimal thermal artifact. At two weeks, a layer of adherent fibroinflammatory pseudomembrane with giant cell reaction was seen.

However, clinical application of such a technology in the laparoscopic environment is still awaited (134).

LASERS

The first use of laser technology for organ surgery in the animal model was over 30 years ago. Since then, there had been significant improvement in laser technology as well as in understanding of the laser's mechanism of action. Laser partial nephrectomy using a variety of lasers has been described (135–141). The initial animal experiments were performed open surgically, most with hilar clamping.

More recently, Ogan et al. (140) at the University of Texas Southwestern investigated lasers for laparoscopic partial nephrectomy in five farm pigs undergoing bilateral laparoscopic partial nephrectomy using a 980-nm diode laser. Mean operative time was 2.1 hours, including a mean lasing time of 84 minutes. Adjunctive hemostatic clips were required in three cases to control the larger, more centrally located vessels. The use of fibrin glue in all cases prevented the assessment of the sealing effect of the laser on the collecting system. Histological analysis of the chronic specimens revealed a necrotic margin of 3–5 mm at two weeks. Subsequently, the same group of investigators employed clinically the 2100 nm wavelength pulsed Ho:YAG laser to perform laparoscopic partial nephrectomy in one adult male with a complex cyst, one pediatric patient with a nonfunctioning lower pole duplicated system, and one adult male with a 2.5 cm exophytic renal tumor (141). Estimated blood loss in the two adult patients was <50 and 500 cm³, respectively. Fibrin glue, oxidized cellulose, and argon beam coagulator were used, and hilar clamping was not performed. No complications were reported. Thereafter, these authors tested the feasibility of laser tissue welding for laparoscopic partial nephrectomy in five pigs (142). An in-house solder consisting of 30% human serum albumin was concentrated to 50%. Chromophore indocyanine green was added to allow selective absorption of an 800-nm laser. After hilar clamping, the lower pole of the porcine kidney was resected with cold endoshears. The albumin solder was dripped onto the cut surface of the kidney, and laser soldering performed. Reportedly an albumin mixture covering was created over the treated surface of the vessels as well as the collecting system. Estimated blood loss was 43 cm³, with a warm ischemia time of 11.7 minutes. None of the chronic kidneys had evidence of urinary leak on ex vivo retrograde pyelogram at two weeks. Gross and histologic examination revealed the solder adherent to the parenchymal surface. The acute extension of the cauterized area into the renal parenchyma was 0.5 mm. Data on the extent of cautery on the chronic specimen were not provided.

Moinzadeh (143) investigated the technical feasibility and short-term outcomes of potassium-titanyl-phosphate laser laparoscopic partial nephrectomy without vascular hilar clamping in the survival, robust calf model. Bilateral transperitoneal laser LPNs of the mid/lower pole was performed using the 80 W potassium-titanyl-phosphate laser on six Jersey calves, each weighing 76–94 kg. The left kidney (*n* = 6) of each calf underwent chronic laparoscopic partial nephrectomy with one-month follow-up, while the right kidney (*n* = 6) underwent acute laparoscopic partial nephrectomy with immediate euthanasia. Two techniques, ablative vaporization (*n* = 5), and wedge resection (*n* = 7), were evaluated. Renal parenchymal resection and hemostasis were achieved solely with the laser, without any adjunctive hemostatic sutures or bioadhesives. All 12 procedures were successful laparoscopically without open conversion, 11 of which (92%) without hilar clamping. Mean total operative time was 2.9 hours (range, 1.5–5), and blood loss was 119 cm³ (range, 25–300). Mean lasing time was 56 minutes (range, 20–100), with an average energy use of 54 kJ. Any pelvicalyceal entry was efficiently suture repaired laparoscopically with a running vicryl stitch. Mean preoperative and postoperative hemoglobin (10.38 and 10.52 g/dL) and serum creatinine (0.46 and 0.4 mg/dL) were similar. Retrograde pyelography, renal arteriography, and histologic analyses showed no evidence of urinary leak or arteriovenous fistula at one-month follow-up. Shortcomings of such technique included considerable smoke generation during laser laparoscopic

partial nephrectomy (no irrigation of the smoke away from the working field possible as during underwater procedures) leading to increased operative time and higher CO₂ inflow-rate requirement necessitating two insufflators. However, the authors anticipated smoke evacuation to be less of a problem in the clinical setting, given the smaller peritoneal volume in the human (~3 L) as compared to the calf (~10 L).

REFERENCES

1. Jemal A, Tiwari RC, Murray T, et al. Cancer statistics, 2004. *CA Cancer J Clin* 2004; 54:8.
2. Surveillance, Epidemiology, and End Results (SEER) Program (www.seer.cancer.gov) SEER*Stat Database: Incidence - SEER 9 Regs Public-Use, Nov 2002 Sub (1973–2000), National Cancer Institute, DCCPS, Surveillance Research Program, Cancer Statistics Branch, released April 2003, based on the November 2002 submission.
3. Chow WH, Devesa SS, Warren JL, et al. Rising incidence of renal cell cancer in the United States. *JAMA* 1999; 281:1628.
4. Kessler O, Mukamel E, Hadar H, et al. Effect of improved diagnosis of renal cell carcinoma on the course of the disease. *J Surg Oncol* 1994; 57:201.
5. Thompson IM, Peek M. Improvement in survival of patients with renal cell carcinoma—the role of the serendipitously detected tumor. *J Urol* 1988; 140:487.
6. Martel CL, Lara PN. Renal cell carcinoma: current status and future directions. *Crit Rev Oncol Hematol* 2003; 45:177.
7. Robson J, Churchill BM, Anderson W. The results of radical nephrectomy for renal cell carcinoma. *J Urol* 1969; 101:297.
8. Novick A C, Campbell S C. Renal Tumors. In: Walsh PC, Retik AB, Vaughan ED, Wein AJ, eds. *Campbell's Urology*. 8th Ed: 2672, Saunders, Philadelphia, 2002.
9. Butler BP, Novick AC, Miller DP, et al. Management of small unilateral renal cell carcinomas: radical versus nephron-sparing surgery. *Urology* 1995; 45:34.
10. Lerner SE, Hawkins CA, Blute ML, et al. Disease outcome in patients with low stage renal cell carcinoma treated with nephron sparing or radical surgery. *J Urol* 1996; 155:1868.
11. D'Armiento M, Damiano R, Feleppa B, et al. Elective conservative surgery for renal carcinoma versus radical nephrectomy: a prospective study. *Br J Urol* 1997; 79:15.
12. Indudhara R, Bueschen AJ, Urban DA, et al. Nephron-sparing surgery compared with radical nephrectomy for renal tumors: current indications and results. *South Med J* 1997; 90:982.
13. Barbalias GA, Liatsikos EN, Tsintavis A, et al. Adenocarcinoma of the kidney: nephron-sparing surgical approach vs. radical nephrectomy. *J Surg Oncol* 1999; 72:156.
14. Belldgrun A, Tsui KH, deKernion JB, et al. Efficacy of nephron-sparing surgery for renal cell carcinoma: analysis based on the new 1997 tumor-node-metastasis staging system. *J Clin Oncol* 1999; 17:2868.
15. Lee CT, Katz J, Shi W, et al. Surgical management of renal tumors 4 cm or less in a contemporary cohort. *J Urol* 2000; 163:730.
16. Lau WK, Blute ML, Weaver AL, et al. Matched comparison of radical nephrectomy vs. nephron-sparing surgery in patients with unilateral renal cell carcinoma and a normal contralateral kidney. *Mayo Clin Proc* 2000; 75:1236.
17. Ghavamian R, Zincke H. Nephron-sparing surgery. *Curr Urol Rep* 2001; 2:34.
18. Jacobs SC, Berg SI, Lawson RK. Synchronous bilateral renal cell carcinoma: total surgical excision. *Cancer* 1980; 46:2341.
19. Marberger M, Pugh RC, Auvert J, et al. Conservation surgery of renal carcinoma: the EIRSS experience. *Br J Urol* 1981; 53:528.
20. Novick AC, Streem S, Montie JE, et al. Conservative surgery for renal cell carcinoma: a single-center experience with 100 patients. *J Urol* 1989; 141:835.
21. Morgan WR, Zincke H. Progression and survival after renal-conserving surgery for renal cell carcinoma: experience in 104 patients and extended followup. *J Urol* 1990; 144:852.
22. Steinbach F, Stockle M, Muller SC, et al. Conservative surgery of renal cell tumors in 140 patients: 21 years of experience. *J Urol* 1992; 148:24.
23. Moll V, Becht E, Ziegler M. Kidney preserving surgery in renal cell tumors: indications, techniques and results in 152 patients. *J Urol* 1993; 150:319.
24. Licht MR, Novick AC, Goormastic M. Nephron sparing surgery in incidental versus suspected renal cell carcinoma. *J Urol* 1994; 152:39.
25. Hafez KS, Fergany AF, Novick AC. Nephron sparing surgery for localized renal cell carcinoma: impact of tumor size on patient survival, tumor recurrence and TNM staging. *J Urol* 1999; 162:1930.
26. Filipas D, Fichtner J, Spix C, et al. Nephron-sparing surgery of renal cell carcinoma with a normal opposite kidney: long-term outcome in 180 patients. *Urology* 2000; 56:387.
27. McKiernan J, Yossepowitch O, Kattan MW, et al. Partial nephrectomy for renal cortical tumors: pathologic findings and impact on outcome. *Urology* 2002; 60:1003.
28. Ghavamian R, Cheville JC, Lohse CM, et al. Renal cell carcinoma in the solitary kidney: an analysis of complications and outcome after nephron-sparing surgery. *J Urol* 2002; 168:454.
29. Uzzo RG, Novick AC. Nephron-sparing surgery for renal tumors: indications, techniques and outcomes. *J Urol* 2001; 166:6.
30. Cheng WS, Farrow GM, Zincke H. The incidence of multicentricity in renal cell carcinoma. *J Urol* 1991; 146:1221.
31. Kletscher BA, Qian J, Bostwick DG, et al. Prospective analysis of multifocality in renal cell carcinoma: influence of histological pattern, grade, number, size, volume and deoxyribonucleic acid ploidy. *J Urol* 1995; 153:904.

32. Castilla EA, Liou LS, Abrahams NA, et al. Prognostic importance of resection margin width after nephron-sparing surgery for renal cell carcinoma. *Urology* 2002; 60:993.
33. Piper NY, Bishoff JT, Magee C, et al. Is a 1-CM margin necessary during nephron-sparing surgery for renal cell carcinoma? *Urology* 2001; 58:849.
34. Li QL, Guan HW, Zhang QP, et al. Optimal margin in nephron-sparing surgery for renal cell carcinoma 4 cm or less. *Eur Urol* 2003; 44:448.
35. Sutherland SE, Resnick MI, MacLennan GT, et al. Does the size of the surgical margin in partial nephrectomy for renal cell cancer really matter? *J Urol* 2002; 167:61.
36. Zucchi A, Mearini L, Mearini E, et al. Renal cell carcinoma: histological findings on surgical margins after nephron sparing surgery. *J Urol* 2003; 169:905.
37. Novick AC, Strem SB. *Surgery of The Kidney*. In: Walsh PC, Retik AB, Vaughan ED, Wein AJ (Ed). *Campbell's Urology*. 7th Ed: 3008, Saunders, Philadelphia, 1998.
38. Fergany AF, Hafez KS, Novick AC. Long-term results of nephron sparing surgery for localized renal cell carcinoma: 10-year followup. *J Urol* 2000; 163:442.
39. Krejci KG, Blute ML, Cheville JC, et al. Nephron-sparing surgery for renal cell carcinoma: clinicopathologic features predictive of patient outcome. *Urology* 2003; 62:641.
40. Gilbert SM, Russo P, Benson MC, et al. The evolving role of partial nephrectomy in the management of renal cell carcinoma. *Curr Oncol Rep* 2003; 5:239.
41. van Ophoven A, Tsui KH, Shvarts O, et al. Current status of partial nephrectomy in the management of kidney cancer. *Cancer Control* 1999; 6:560.
42. Novick AC. Partial nephrectomy for renal cell carcinoma. *Urology* 1995; 46:149.
43. Herr HW. Partial nephrectomy for unilateral renal carcinoma and a normal contralateral kidney: 10-year followup. *J Urol* 1999; 161:33.
44. Gill IS, Meraney AM, Schweizer DK, et al. Laparoscopic radical nephrectomy in 100 patients: a single center experience from the United States. *Cancer* 2001; 92:1843.
45. Cadeddu JA, Ono Y, Clayman RV, et al. Laparoscopic nephrectomy for renal cell cancer: evaluation of efficacy and safety: a multicenter experience. *Urology* 1998; 52:773.
46. Matin SF, Gill IS, Worley S, et al. Outcome of laparoscopic radical and open partial nephrectomy for the sporadic 4 cm or less renal tumor with a normal contralateral kidney. *J Urol* 2002; 168:1356.
47. Desai MM, Gill IS, Kaouk JH, et al. Laparoscopic partial nephrectomy with suture repair of the pelvicalyceal system. *Urology* 2003; 61:99.
48. McDougall EM, Clayman RV, Chandhoke PS, et al. Laparoscopic partial nephrectomy in the pig model. *J Urol* 1993; 149:1633.
49. Winfield HN, Donovan JF, Godet AS, et al. Laparoscopic partial nephrectomy: initial case report for benign disease. *J Endourol* 1993; 7:521.
50. Gill IS, Delworth MG, Munch LC. Laparoscopic retroperitoneal partial nephrectomy. *J Urol* 1994; 152:1539.
51. Gill IS, Desai MM, Kaouk JH, et al. Laparoscopic partial nephrectomy for renal tumor: duplicating open surgical techniques. *J Urol* 2002; 167:469.
52. McDougall EM, Elbahnasy AM, Clayman RV. Laparoscopic wedge resection and partial nephrectomy—the Washington University experience and review of the literature. *JSL* 1998; 2:15.
53. Janetschek G, Jeschke K, Peschel R, et al. Laparoscopic surgery for stage T1 renal cell carcinoma: radical nephrectomy and wedge resection. *Eur Urol* 2000; 38:131.
54. Hoznek A, Salomon L, Antiphon P, et al. Partial nephrectomy with retroperitoneal laparoscopy. *J Urol* 1999; 162:1922.
55. Kaouk JH, Gill IS. Laparoscopic partial nephrectomy: a new horizon. *Curr Opin Urol* 2003; 13:215.
56. Bernardo NO, Gill IS. Laparoscopic partial nephrectomy: current status. *Arch Esp Urol* 2002; 55:868.
57. Steinberg AP, Abreu SC, Desai MM, et al. Laparoscopic nephron-sparing surgery in the presence of renal artery disease. *Urology* 2003; 62:935.
58. Gill IS. Minimally invasive nephron-sparing surgery. *Urol Clin North Am* 2003; 30:551.
59. Best S, Ercole B, Lee C, et al. Minimally invasive therapy for renal cell carcinoma: is there a new community standard? *Urology* 2004; 64:22.
60. Harmon WJ, Kavoussi LR, Bishoff JT. Laparoscopic nephron-sparing surgery for solid renal masses using the ultrasonic shears. *Urology* 2000; 56:754.
61. Rassweiler JJ, Abbou C, Janetschek G, et al. Laparoscopic partial nephrectomy. The European experience. *Urol Clin North Am* 2000; 27:721.
62. Jeschke K, Peschel R, Wakonig J, et al. Laparoscopic nephron-sparing surgery for renal tumors. *Urology* 2001; 58:688.
63. Simon SD, Ferrigni RG, Novicki DE, et al. Mayo Clinic Scottsdale experience with laparoscopic nephron sparing surgery for renal tumors. *J Urol* 2003; 169:2059.
64. Kim FJ, Rha KH, Hernandez F, et al. Laparoscopic radical versus partial nephrectomy: assessment of complications. *J Urol* 2003; 170:408.
65. Gill IS, Matin SF, Desai MM, et al. Comparative analysis of laparoscopic versus open partial nephrectomy for renal tumors in 200 patients. *J Urol* 2003; 170:64.
66. Spalivier M, Finelli A, Moizadeh A, et al. Laparoscopy partial nephrectomy: trends assessment in tumor selection and outcomes in 300 cases. *J urol* 2005; 173(suppl)A835:227.
67. Baltaci S, Orhan D, Soyupek S, et al. Influence of tumor stage, size, grade, vascular involvement, histological cell type and histological pattern on multifocality of renal cell carcinoma. *J Urol* 2000; 164:36.
68. Gohji K, Hara I, Gotoh A, et al. Multifocal renal cell carcinoma in Japanese patients with tumors with maximal diameters of 50 mm or less. *J Urol* 1998; 159:1144.
69. Steinberg AP, Kilciler M, Abreu SC, et al. Laparoscopic nephron-sparing surgery for two or more ipsilateral renal tumors. *Urology* 2004; 64:255.
70. Sagalowsky AI, Kadesky KT, Ewalt DM, et al. Factors influencing adrenal metastasis in renal cell carcinoma. *J Urol* 1994; 151:1181.

71. Gill IS, McClennan BL, Kerbl K, et al. Adrenal involvement from renal cell carcinoma: predictive value of computerized tomography. *J Urol* 1994; 152:1082.
72. Ramani AP, Abreu SC, Desai MM, et al. Laparoscopic upper pole partial nephrectomy with concomitant en bloc adrenalectomy. *Urology* 2003; 62:223.
73. Petritsch PH, Rauchenwald M, Zechner O, et al. Results after organ-preserving surgery for renal cell carcinoma. An Austrian multicenter study. *Eur Urol* 1990; 18:84.
74. Campbell SC, Novick AC, Strem SB, et al. Complications of nephron sparing surgery for renal tumors. *J Urol* 1994; 151:1177.
75. Polascik TJ, Pound CR, Meng MV, et al. Partial nephrectomy: technique, complications and pathological findings. *J Urol* 1995; 154:1312.
76. Uzzo RG, Wei JT, Hafez K, et al. Comparison of direct hospital costs and length of stay for radical nephrectomy versus nephron-sparing surgery in the management of localized renal cell carcinoma. *Urology* 1999; 54:994.
77. Shekarriz B, Upadhyay J, Shekarriz H, et al. Comparison of costs and complications of radical and partial nephrectomy for treatment of localized renal cell carcinoma. *Urology* 2002; 59:211.
78. Corman JM, Penson DE, Hur K, et al. Comparison of complications after radical and partial nephrectomy: results from the National Veterans Administration Surgical Quality Improvement Program. *BJU Int* 2000; 86:782.
79. Ramani AP, Desai MM, Steinberg AP, et al. Complications of laparoscopic partial nephrectomy in 200 cases. *J Urol* 2005; 173:42.
80. Ramani AP. 200 complication.
81. Hayakawa K, Baba S, Aoyagi T, et al. Laparoscopic heminephrectomy of a horseshoe kidney using microwave coagulator. *J Urol* 1999; 161:1559.
82. Jackman SV, Cadeddu JA, Chen RN, et al. Utility of the harmonic scalpel for laparoscopic partial nephrectomy. *J Endourol* 1998; 12:441.
83. Elashry OM, Wolf JS Jr., Rayala HJ, et al. Recent advances in laparoscopic partial nephrectomy: comparative study of electrosurgical snare electrode and ultrasound dissection. *J Endourol* 1997; 11:15.
84. Yoshimura K, Okubo K, Ichioka K, et al. Laparoscopic partial nephrectomy with a microwave tissue coagulator for small renal tumor. *J Urol* 2001; 165:1893.
85. Gettman MT, Bishoff JT, Su LM, et al. Hemostatic laparoscopic partial nephrectomy: initial experience with the radiofrequency coagulation-assisted technique. *Urology* 2001; 58:8.
86. Mabjeesh NJ, Avidor Y, Matzkin H. Emerging nephron sparing treatments for kidney tumors: a continuum of modalities from energy ablation to laparoscopic partial nephrectomy. *J Urol* 2004; 171:553.
87. Janetschek G, Daffner P, Peschel R, et al. Laparoscopic nephron sparing surgery for small renal cell carcinoma. *J Urol* 1998; 159:1152.
88. Gill IS, Munch LC, Clayman RV, et al. A new renal tourniquet for open and laparoscopic partial nephrectomy. *J Urol* 1995; 154:1113.
89. Cadeddu JA, Corwin TS. Cable tie compression to facilitate laparoscopic partial nephrectomy. *J Urol* 2001; 165:177.
90. Finelli A, Gill IS. Laparoscopic partial nephrectomy: contemporary technique and results. *Urol Oncol* 2004; 22:139.
91. Richter F, Schnorr D, Deger S, et al. Improvement of hemostasis in open and laparoscopically performed partial nephrectomy using a gelatin matrix-thrombin tissue sealant (FloSeal). *Urology* 2003; 61:73.
92. Shekarriz B, Stoller ML. The use of fibrin sealant in urology. *J Urol* 2002; 167:1218.
93. Bak JB, Singh A, Shekarriz B. Use of gelatin matrix thrombin tissue sealant as an effective hemostatic agent during laparoscopic partial nephrectomy. *J Urol* 2004; 171:780.
94. Gill IS, Ramani AP, Spalivier M, et al. Improved hemostasis during laparoscopic partial nephrectomy using gelatin matrix thrombin sealant. *Urol* 2005; 65:463.
95. Urena R, Mendez F, Woods M, et al. Laparoscopic partial nephrectomy of solid renal masses without hilar clamping using a monopolar radio frequency device. *J Urol* 2004; 171:1054.
96. Johnston GS, Murphy GP, Schirmer HK. Alterations in 203-Hg isotopic kinetics in experimental renal ischemia: correlation with renal hemodynamics and metabolism. *J Urol* 1966; 96:606.
97. Wolf JS Jr., Seifman BD, Montie JE. Nephron sparing surgery for suspected malignancy: open surgery compared to laparoscopy with selective use of hand assistance. *J Urol* 2000; 163:1659.
98. Frank RS, Frank TS, Zelenock GB, et al. Ischemia with intermittent reperfusion reduces functional and morphologic damage following renal ischemia in the rat. *Ann Vasc Surg* 1993; 7:150.
99. Wilson DH, Barton BB, Parry WL, et al. Effects of intermittent versus continuous renal arterial occlusion on hemodynamics and function of the kidney. *Invest Urol* 1971; 8:507.
100. McLoughlin GA, Heal MR, Tyrell IM. An evaluation of techniques used for the production of temporary renal ischaemia. *Br J Urol* 1978; 50:371.
101. Sasaki T, Ohsawa S, Ogawa M, et al. Postoperative renal function after an abdominal aortic aneurysm repair requiring a suprarenal aortic cross-clamp. *Surg Today* 2000; 30:33.
102. Ward JP. Determination of the optimum temperature for regional renal hypothermia during temporary renal ischaemia. *Br J Urol* 1975; 47:17.
103. Novick AC. Renal hypothermia: in vivo and ex vivo. *Urol Clin North Am* 1983; 10:637.
104. Shekarriz B, Shah G, Upadhyay J. Impact of temporary hilar clamping during laparoscopic partial nephrectomy on postoperative renal function: a prospective study. *J Urol* 2004; 172:54.
105. Desai MM, Gill IS, Ramani AP, et al. The impact of warm ischaemia on renal function after laparoscopic partial nephrectomy. *BJU Int* 2005; 95:377.
106. Gill IS, Abreu SC, Desai MM, et al. Laparoscopic ice slush renal hypothermia for partial nephrectomy: the initial experience. *J Urol* 2003; 170:52.
107. Janetschek G, Abdelmaksoud A, Bagheri F, et al. Laparoscopic Partial Nephrectomy In Cold Ischemia: Renal Artery Perfusion. *J Urol* 2004; 171: 68.

108. Landman J, Venkatesh R, Lee D, et al. Renal hypothermia achieved by retrograde endoscopic cold saline perfusion: technique and initial clinical application. *Urology* 2003; 61:1023.
109. Tsivian A, Sidi AA. Port site metastases in urological laparoscopic surgery. *J Urol*, 2003; 169:1213.
110. Fentie DD, Barrett PH, Taranger LA. Metastatic Renal Cell Cancer After Laparoscopic Radical Nephrectomy: Long-Term Follow-Up. *J Endourol*. 2000; 14: 407.
111. Micali S, Celia A, Bove P, et al. Tumor seeding in urological laparoscopy: an international survey. *J Urol* 2004; 171:2151.
112. Allaf ME, Bhayani SB, Rogers C, et al. Laparoscopic partial nephrectomy: evaluation of long-term oncological outcome. *J Urol* 2004; 172:871.
113. Bove P, Bhayani SB, Rha KH, et al. Necessity of ureteral catheter during laparoscopic partial nephrectomy. *J Urol* 2004; 172:458.
114. Finelli A, Gill IS, Desai MM, et al. Laparoscopic heminephrectomy for tumor urol 2005; 65:473.
115. Brown JA, Hubosky SG, Gomella LG, et al. Hand assisted laparoscopic partial nephrectomy for peripheral and central lesions: a review of 30 consecutive cases. *J Urol* 2004; 171:1443.
116. Drachenberg DE, Mena OJ, Choyke PL, et al. Parenchymal sparing surgery for central renal tumors in patients with hereditary renal cancers. *J Urol* 2004; 172:49.
117. Hafez KS, Novick AC, Butler BP. Management of small solitary unilateral renal cell carcinomas: impact of central versus peripheral tumor location. *J Urol* 1998; 159:1156.
118. Frank I, Colombo JR Jr, Rubinsrein M, et al. Laparoscopic partial nephrectomy for centrally located renal tumors. *J urol* 2006; 175:849.
119. Guillonneau B, Bermudez H, Gholami S, et al. Laparoscopic partial nephrectomy for renal tumor: single center experience comparing clamping and no clamping techniques of the renal vasculature. *J Urol* 2003; 169:483.
120. Kane CJ, Mitchell JA, Meng MV, et al. Laparoscopic partial nephrectomy with temporary arterial occlusion: description of technique and renal functional outcomes. *Urology* 2004; 63:241.
121. Santiago L, Yamaguchi R, Kaswick J, et al. Laparoscopic management of indeterminate renal cysts. *Urology* 1998; 52:379.
122. Limb J, Santiago L, Kaswick J, et al. Laparoscopic evaluation of indeterminate renal cysts: long-term follow-up. *J Endourol* 2002; 16:79.
123. Spaliviero M, Herts Br, Magi Cralluzzic C, et al. Laparoscopic partial nephrectomy for cystic masses. *J urol* 2005; 174:614.
124. Gill IS, Colombo JR, Jr., Frank I, et al. Laparoscopic partial nephrectomy for hilar tumors. *J urol* 2005; 174:850.
125. Bhayani SB, Allaf ME, Link RE, et al. Laparoscopic partial nephrectomy in patients with neoplasia in a solitary kidney. *Urology* 2004; 64:35.
126. Ngcs, Ramani AP, Desai MM, et al. Transperitoneal vs. Retroperitoneal Laparoscopic Partial Nephrectomy: Patient selection and perioperative outcomes. *J urol* 2005; 174: 846.
127. Steinberg AP, Desai MM, Matin S, et al. Financial analysis of Laparoscopic vs. open partial nephrectomy. *J Endourol* 2002; 16(suppl): A158.
128. Stifelman MD, Sosa RE, Nakada SY, et al. Hand-assisted laparoscopic partial nephrectomy. *J Endourol* 2001; 15:161.
129. Hafez KS, Novick AC, Campbell SC. Patterns of tumor recurrence and guidelines for followup after nephron sparing surgery for sporadic renal cell carcinoma. *J Urol* 1997; 157:2067.
130. Shekarritz H, Shekarritz B, Upadhyay J, et al. Hydro-jet assisted laparoscopic partial nephrectomy: initial experience in a porcine model. *J Urol* 2000; 163:1005.
131. Basting RF, Djakovic N, Widmann P. Use of water jet resection in organ-sparing kidney surgery. *J Endourol* 2000; 14:501.
132. Corvin S, Oberneder R, Adam C, et al. Use of hydro-jet cutting for laparoscopic partial nephrectomy in a porcine model. *Urology* 2001; 58:1070.
133. Moinzadeh A, Hasan W, Spaliviero M, et al. Water Jet Assisted Laparoscopic Partial Nephrectomy Without Hilar Clamping In The Calf Model. *J Urol* 2005; 174: 317.
134. Ogan K, Cadetdu JA. Minimally invasive management of the small renal tumor: review of laparoscopic partial nephrectomy and ablative techniques. *J Endourol* 2002; 16:635.
135. Hughes BF, Scott WW. Preliminary report on the use of a CO₂ laser surgical unit in animals. *Invest Urol* 1972; 9:353.
136. Meiraz D, Peled I, Gassner S, et al. The use of the CO₂ laser for partial nephrectomy: an experimental study. *Invest Urol* 1977; 15:262.
137. Benderev TV, Schaeffer AJ. Efficacy and safety of the Nd:YAG laser in canine partial nephrectomy. *J Urol* 1985; 133:1108.
138. Landau ST, Wood TW, Smith JA Jr. Evaluation of sapphire tip Nd:YAG laser fibers in partial nephrectomy. *Lasers Surg Med* 1987; 7:426.
139. Taari K, Salo JO, Rannikko S, et al. Partial nephrectomy with a combined CO₂ and Nd:YAG laser: experimental study in pigs. *Lasers Surg Med* 1994; 14:23.
140. Ogan K, Wilhelm D, Lindberg G, et al. Laparoscopic partial nephrectomy with a diode laser: porcine results. *J Endourol* 2002; 16:749.
141. Lotan Y, Gettman MT, Ogan K, et al. Clinical use of the holmium: YAG laser in laparoscopic partial nephrectomy. *J Endourol* 2002; 16:289.
142. Ogan K, Jacomides L, Saboorian H, et al. Sutureless laparoscopic heminephrectomy using laser tissue soldering. *J Endourol* 2003; 17:295.
143. Moinzadeh A, Gill IS, Rubinstien M, et al. Potassium-Titanyl-Phosphate Laser Laparoscopic Partial Nephrectomy Without Hilar Clamping In The Survival Calf Model *J Urol* 2005; 174:1110-1114.

RENAL CRYOABLATION: TECHNIQUE AND RESULTS

Murali K. Ankem

Department of Urology, Louisiana State University Health Sciences Center, and Overton Brooks VA Medical Center, Shreveport, Louisiana, U.S.A.

Stephen Y. Nakada

Division of Urology, Department of Surgery, University of Wisconsin School of Medicine and Public Health, Madison, Wisconsin, U.S.A.

- INTRODUCTION
- PATIENT SELECTION: INDICATIONS AND CONTRAINDICATIONS
- PREOPERATIVE PREPARATION
- TECHNIQUE
 - Operating Room Setup
 - Patient Positioning
 - Trocar Placement
- INSTRUMENT LIST
- TECHNICAL CAVEATS AND TIPS
- RESULTS
- SUMMARY
- REFERENCES

The American Cancer Society estimated the incidence of new renal cancer cases and deaths for the year 2004 at 22,080 and 7870, respectively.

Nephron-sparing surgery has emerged as a preferred option in the treatment of most renal tumors less than 4 cm in patients with an existing or potential compromise of renal function and in select tumors with a normal contralateral kidney. Long-term cancer control and renal function after partial nephrectomy has been reported as being similar to radical nephrectomy.

The benefits of nephron sparing minimally invasive therapies include maximal renal sparing, decreased morbidity, decreased hospital stay, and shorter recovery.

Cryoablation is the destruction of cells by consecutive rapid freeze and thaw cycles leading to complete and reproducible necrosis of renal parenchyma occurring at temperatures of -19.4°C or less.

INTRODUCTION

The American Cancer Society estimated the incidence of new renal cancer cases and deaths for the year 2004 at about 22,080 and 7870, respectively (1).

Historically, a large number of new renal cancer cases were diagnosed at an advanced stage; however, as a result of new noninvasive imaging modalities, there has been an increase in the number of incidentally detected renal masses. Radical nephrectomy has been the gold standard for the management of renal cancers since its description by Robson et al. (2), but as the transition to diagnosis of asymptomatic smaller renal masses occurred, surgical treatment of renal masses also evolved.

Nephron-sparing surgery has emerged as a preferred option in the treatment of most renal tumors less than 4 cm in patients with an existing or potential compromise of renal function and in select tumors with a normal contralateral kidney (3–5). Long-term cancer control and renal function after partial nephrectomy has been reported as being similar to radical nephrectomy (3,4).

Myriad nephron sparing minimally invasive treatment options are being advocated for treatment of carefully selected patients. These include laparoscopic partial nephrectomy and needle-invasive or noninvasive ablative procedures such as cryoablation, radiofrequency, high-intensity focused ultrasound, interstitial laser, microwave thermotherapy, and photon irradiation.

The benefits of nephron sparing minimally invasive therapies include maximal renal sparing, decreased morbidity, decreased hospital stay, and shorter recovery.

Cryoablation is the oldest and most well studied of all the needle-invasive and noninvasive modalities. Cryoablation is the destruction of cells by consecutive rapid freeze and thaw cycles leading to complete and reproducible necrosis of renal parenchyma occurring at temperatures of -19.4°C or less (6).

Temperature monitoring using thermocouples during porcine renal cryosurgery demonstrated complete homogeneous necrosis of tissues reaching temperatures of -19.4°C or lower. Distance beyond the cryoprobe and direct visualization of the iceball proved to be less reliable predictors of tissue necrosis (7). Renal cryoablation has been reported via open (8,9), laparoscopic (10,11), and percutaneous surgery (12).

Liquid nitrogen or argon gas is circulated through vacuum-insulated probes and forced through a small aperture at the tip of the probe.

Rapid freezing causes:

- Cytotoxic intracellular and extracellular ice crystals increasing the extracellular osmotic concentration resulting in pH changes, protein denaturing and mechanical disruption of cellular membranes.
- Acute injury to the vasculature causing hyperpermeability of the microcirculation, which results in thrombosis, vascular occlusion, ischemia, and edema leading to delayed cell death (13,14).

Alternately, cellular damage may be produced by vascular injury or freezing induced immunological sensitization. This immunological sensitization is a novel concept and it has been recently shown that cryoablation of advanced renal cancer may have a survival advantage compared to nephrectomy in murine model by Hedican et al. (15).

PATIENT SELECTION: INDICATIONS AND CONTRAINDICATIONS

Laparoscopic cryoablation is ideal for small volume renal cortical masses, suspicious for renal cell carcinoma, less than 4 cm (Table 1).

Indications for renal cryoablation include:

- Renal mass lesion less than 4 cm
- Elderly patients with comorbidities particularly hypertension, diabetes, renal stones, renal insufficiency, cerebrovascular accidents, and congestive heart failure—poor surgical candidates
- Solitary kidney with peripheral renal mass less than 4 cm
- Transplant kidney with peripheral renal mass less than 4 cm
- von Hippel-Lindau with metachronous renal cell cancers

Contraindications to renal cryoablation include locally advanced and/or metastatic disease and uncorrected bleeding disorders. Laparoscopic or percutaneous cryoablation should be approached cautiously in patients with renal lesions close to renal hilum and pelvicalyceal system. However, Sung et al. showed intentional freezing of collecting system did not result in urinary leak (24).

Intraoperative ultrasound should be performed to rule out multifocal lesions where multiple probes or an alternative treatment modality (i.e., open or laparoscopic radical nephrectomy) could be considered.

To some, cystic renal masses are not ideal for renal cryoablation secondary to decompression of cysts, which might lead to instability of probes and imperfect freezing.

Intraoperative ultrasound should be performed to rule out multifocal lesions where multiple probes or an alternative treatment modality (i.e., open or laparoscopic radical nephrectomy) could be considered.

The preoperative preparation for renal cryoablation is the same as for open or laparoscopic approach.

PREOPERATIVE PREPARATION

The preoperative preparation for renal cryoablation is the same as for open or laparoscopic approach.

Thorough history and physical examination is mandatory. A complete blood count, basic metabolic panel, urine analysis, and culture are routinely performed.

TABLE 1 ■ Laparoscopic Cryoablation Clinical Series

Year	Author	No. of tumors	Tumor size (cm)	OR time (min)	Blood loss (cc)	Mean follow-up (mo)	Recurrences	Complications
1998	Gill (10)	11	2.3	144	75	3	0	0
1999	Bishoff (16)	8	2	—	140	7.7	0	0
2000	Rodriguez (17)	3	2.2	234	111	14.2	0	0
2000	Gill (18)	34	2.3	174	66.8	16.2	0	0
2003	Lee (19)	20	2.6	305	92.5	14.2	1	1
2003	Colon (20)	8	2.6	120	102.5	—	0	0
2003	Nadler (21)	15	2.15	260	67	37	1	2
2003	Moon (22)	16	2.6	188	40	9.6	0	1
2004	Gill (23)	56	2.3	180	—	36	2	4
2004	Wisconsin (unpublished data)	31	2.54	136	57	14.3	2	1
Total	10	202	2.099	193.4	83.5	16.9	6	9

Abbreviation: OR, operating room.

Patients should be informed about the potential for performing a radical nephrectomy laparoscopic or open if the situation demands.

Metastatic evaluation usually includes a chest radiograph and abdominal computed tomography scan. A bone scan is reserved for patients with abnormal calcium and/or alkaline phosphatase levels. Magnetic resonance imaging is indicated in patients with contrast allergy or renal insufficiency. The majority of these patients may require preoperative clearance from an internist or a specialist for the comorbidities. Patients should sign an informed consent, which includes a detailed discussion about the limitations, expectations, and possible complications.

Patients should be informed about the potential for performing a radical nephrectomy laparoscopic or open if the situation demands.

We routinely perform bowel preparation with 300 mL of magnesium citrate with clear liquid diet a day prior to surgery and usually admit patients on the day of surgery. Patients are usually typed but not cross-matched for blood. Coordinating the procedure with an experienced radiologist in intraoperative laparoscopic ultrasound is often helpful.

TECHNIQUE

At our center, cryoablation is performed for tumors 4 cm or less in size. Many cystic and hilar lesions are excluded. Laparoscopy is used to expose the renal mass, using a transperitoneal approach for anterior/anterolateral tumors, and retroperitoneal for posterior/posterolateral tumors.

Operating Room Setup

The patient position and approach depends upon the exact location of the renal mass. The patient is placed in flank position with the affected side up. The primary surgeon, the first assistant, and the scrub nurse stand facing the abdomen (transperitoneal approach) or facing the spine (retroperitoneal approach). The second assistant (optional) will be on the opposite side. The monitor towers are stationed at the patient's shoulders and angled slightly toward the feet at an eye level comfortable to the operating personnel. The tower containing the laparoscopic insufflator, light source, and camera should be across the primary surgeon to facilitate monitoring of the pressure recordings. The harmonic and electrocautery generator units are at the patient's feet across from the primary surgeon. The suction irrigator/aspirator system is hung on the anesthetic pole on the side of the primary surgeon at the head of the table. The scrub nurse's Mayo stand is placed directly above the patient's legs and the remaining laparoscopic instruments are placed on another table in an L-shaped configuration for easy access (Fig. 1).

Patient Positioning

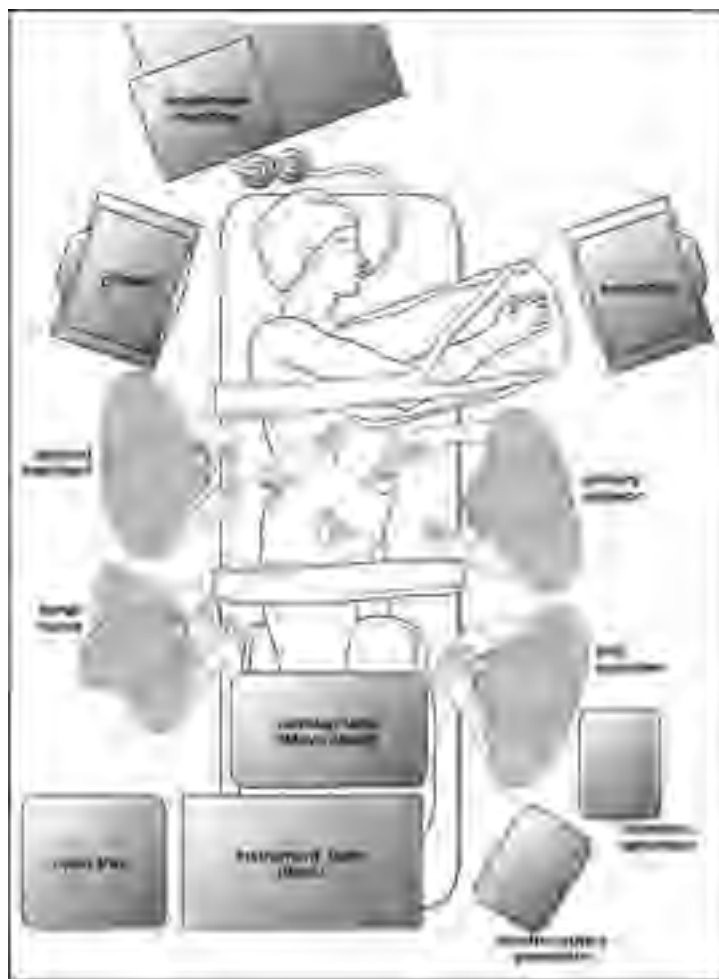
The operation table is padded with two layers of foam to provide adequate padding and minimize the risk of neuromuscular injury. After induction of anesthesia, placement of Foley catheter, and orogastric tube the patient is placed in semiflank position (15–20° from vertical) for transperitoneal approach or full flank position for retroperitoneal approach with the kidney rest at the level of twelfth rib. Kidney rest is elevated minimally and the table is flexed slightly to increase the space between the rib cage and the iliac crest. The down leg is flexed and the upper leg is placed straight with three or more pillows between the legs oriented at right angles to the legs. Venodynes and stockings are routinely used to prevent deep venous thrombosis. Two arm boards are placed side by side at the level of shoulder with foam padding. A soft foam axillary roll is positioned two fingerbreadths below the axilla to prevent brachial plexopathy. Three or more pillows are placed inline between the upper extremities to support the upper arm. The safety strap is applied over the lower extremities at the level of calves. A cautery pad is strapped on the upper thigh and a 3-inch wide cloth tape is used to strap the patient from the edge of the table to the opposite edge of the table. The upper torso is stabilized by using 3-in. wide cloth tape from the edge of the table at the level of shoulders and is split into two strips past the elbows and is attached to either side of the arm boards. Care is taken to reposition all electrocardiogram leads, wires, and intravenous lines so that they are not under the patient at any point. A pneumatic warming device may be used on the upper torso to prevent hypothermia (Fig. 2).

Trocar Placement

Transperitoneal Approach

Peritoneal insufflation is obtained by inserting a Veress needle midway between the umbilicus and the superior iliac crest just lateral to the rectus muscle. The abdomen is insufflated up to 15-mmHg pressure and then a 10-mm or 5-mm nonbladed trocar is passed in

FIGURE 1 ■ Suggested operating room setup for laparoscopic transperitoneal cryoablation.



We have a low threshold to use an open Hasson cannula technique for the abdomens with a history of previous surgery and if complicated adhesions are anticipated (Fig. 3).

to the abdomen using an optiview system for the camera, depending on the surgeon's choice of using 5- or 10-mm telescope. A second 10-mm port is placed at the lateral margin of the umbilicus and the third port is placed in a subcostal position, just lateral to midline, halfway between the xiphoid and the umbilicus. The second and third ports could be 5 or 10 mm depending the side of the lesion and the dominant hand of the surgeon. An additional 5-mm port may be necessary on the right side to retract the inferior margin of the liver, about two fingerbreadths below the costal margin in the mid-axillary line.

We have a low threshold to use an open Hasson cannula technique for the abdomens with a history of previous surgery and if complicated adhesions are anticipated (Fig. 3).

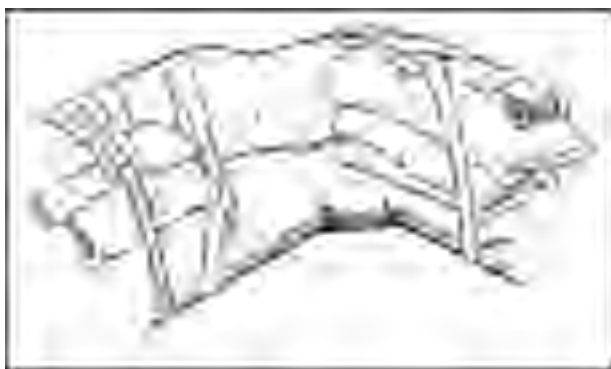

FIGURE 2 ■ Patient's positioning for laparoscopic transperitoneal cryoablation.



FIGURE 3 ■ Trocar placement for transperitoneal approach.

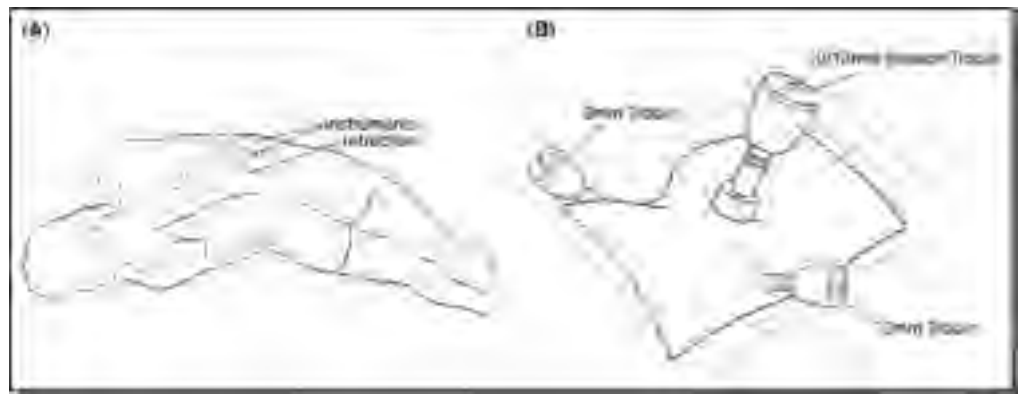


FIGURE 4 ■ Trocar placement for retroperitoneal approach. (A) Place 3 trocars lateral to the erector spinae muscle just below the 12th rib, (B) three fingerbreadths above the iliac crest in the anterior axillary line.

We found it is not necessary to use a balloon for formal dilatation of the retroperitoneal space, as we have not needed that much working space for renal cryoablation.

Retroperitoneal Approach

The open Hasson canula technique is routinely used. A horizontal 2-cm incision is placed 1 cm below and lateral to the tip of the twelfth rib. Then the latissimus dorsi muscle fibers are bluntly separated and retroperitoneum entered by opening the anterior lamella of the thoracolumbar fascia. Blunt finger dissection is performed to develop space by pushing the peritoneum away from the psoas major muscle. We found it is not necessary to use a balloon for formal dilatation of the retroperitoneal space, as we have not needed that much working space for renal cryoablation.

Alternatively, a trocar mounted balloon^a could be used to develop adequate working space by instilling 800 to 1000 cc as described by Gill and his associates. A 10-mm blunt tip trocar^a is placed after removing the balloon dissection device and it is secured by inflating the internal retention balloon and cinching external foam cuff. A Hasson cannula could also be used and it is tightly fixed by using fascial sutures around the trocar. Two more secondary ports are placed under vision, one 5-mm trocar is placed three fingerbreadths above the iliac crest in the anterior axillary line and the other 5-mm trocar is placed lateral to the erector spinae muscle just below the twelfth rib (Fig. 4A and B).

Exposure of the Lesion

The camera is inserted via the lower quadrant port and the surgeon operates with the subcostal and periumbilical ports in the transperitoneal approach. The Harmonic scalpel^{TM a} is typically used to incise the line of Toldt and for subsequent exposure of the renal mass through the Gerota's fascia.

Intrarenal lesions need intraoperative ultrasound to locate the lesions and exclude multicentric lesions.

Intrarenal lesions need intraoperative ultrasound to locate the lesions and exclude multicentric lesions. Ultrasound can also assess for other lesions in the remainder of the kidney. Extensive mobilization of colon, spleen, ureter, and hilum is not necessary. In the retroperitoneal approach, the camera is inserted via the middle port and surgeon operating through the medial and lateral ports. Maintaining the orientation and identifying the psoas major muscle are very important in this approach. We routinely use laparoscopic ultrasound to help localize the renal mass and Gerota's fascia is incised and the renal mass is dissected by opening the perinephric fat. Once the renal lesion is identified and well exposed, the cryoablation technique is similar in both approaches. After finishing the procedure, hemostasis should be checked by lowering the pneumoperitoneum to 5 mmHg and the larger abdominal ports are closed using a port closure device. We perform a simple closure of retroperitoneal ports.

INSTRUMENT LIST

- 10- or 5-mm laparoscope (0° and 30°)
- Maryland dissector

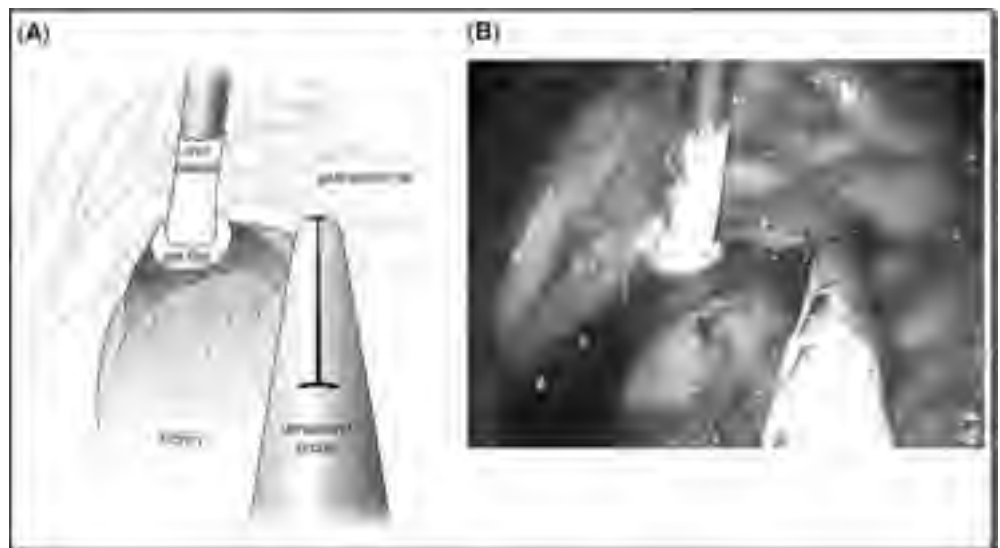
^aEthicon, Somerville, NJ.

- Diamond flex triangle retractor^b
- Veress needle
- Three nonbladed 10/12-mm trocars, one 5-mm nonbladed trocar
- Blunt tip trocar
- Trocar mounted preperitoneal balloon dilator^d
- 10-mm Optiview introducing cannula^e
- Endoshears
- 5-mm harmonic shears
- Irrigator-aspirator
- 10-mm clip applier and vascular stapler in the room available
- 10-mm right angle dissector
- Carter-Thomason fascial closure device^c
- 4-0-monocryl sutures
- Flexible 10-mm laparoscopic ultrasound probe with ultrasound machine
- Biopsy gun
- Surgicel^d, Tisseel^e, argon beam coagulator
- Two laparoscopic needle drivers
- Cryoprobes: 2.4, 3.0, 5 mm, Cryomachine (Accuprobe^f)
- Benzoin, steristrips 1/4 in., three band aids
- Standard open tray for flank surgery

Cryoablation is performed using an argon gas-based system that operated on Joule-Thompson principle (Accuprobe). Cryoprobes are available in diameters of 2.4 (sharp tip), 3.0, and 5.0 mm (blunt tips). The number and size of probes used in a case vary depending on the size and site of the tumor. The smaller probes (2.4 and 3.0 mm) are often passed percutaneously as a result of the relatively short shaft length; the 5-mm probe can be placed percutaneously or via a port.

- Once exposed and verified by the ultrasound examination of the lesion, the tumor is biopsied prior to cryoablation.
- Under direct laparoscopic and ultrasound guidance, the tumor is punctured with an appropriate sized probe and cryoablation is initiated using two 10-minute freeze cycles followed by passive thaws.
- The freeze cycle is continued to 1 cm beyond the tumor margin.
- The cryolesion is monitored with real time ultrasonography (Fig. 5).

FIGURE 5 ■ Picture showing renal cryoablation in progress (A) with real-time ultrasound monitoring (B).



^bGenzyme Surgical Products, Tucker, GA.

^cInlet Medical, Eden Prairie, MN.

^dEthicon, Somerville, NJ.

^eBoxter Healthcare, Dearfield, IL.

^fEndocare, Irvine, CA.

FIGURE 6 ■ Pre-and postoperative magnetic resonance imaging scans showing an exophytic enhancing renal mass (left) and nonenhancing cryoablated lesion.



When cryoprobes are placed percutaneously, a 14 French red rubber catheter tubing is placed around the probe to protect skin and abdominal wall from cryoinjury. Before removal, passive thawing is allowed until the probe loosened spontaneously, and a piece of tightly rolled surgicel is placed into the cryoprobe defect, or an injection of Tisseel¹ is performed and held with direct pressure for 5 to 10 minutes. Next, the insufflation pressure is reduced to 5 mmHg to confirm hemostasis. Postoperatively, serial hematocrits are obtained for the first 24 hours. Magnetic resonance imaging is obtained at 3, 6, 9, and 12 months and then annually. We obtain magnetic resonance imaging scans with T1, T2 weighted, and gradient echo images performed before, during and after intravenous administration of gadolinium (Fig. 6).

Failure of cryolesion regression after six months warrants renal biopsy, possible repeat cryoablation, or partial/radical nephrectomy.

Failure of cryolesion regression after six months warrants renal biopsy, possible repeat cryoablation, or partial/radical nephrectomy.

RESULTS

To date, our series at the University of Wisconsin (unpublished data) includes 31 patients with a mean follow-up of 14.3 months (range, 1–39). There were 21 men and 10 women, 16 tumors were on the right and 15 on the left side. Eighteen patients were treated retroperitoneal and 13 transperitoneally. The mean tumor size was 2.54 cm. A double freeze, active thaw technique was utilized with two 10-minute freeze cycles. Mean operating time was 136 minutes and the mean blood loss was 57 mL. The hospital stay was 1.9 days. Global complication rate was 6%. One patient with postoperative hemorrhage

TECHNICAL CAVEATS AND TIPS

- Careful preoperative planning regarding the approach, number, size, and placement of cryoprobes is advantageous.
- The specific choices of probe number and size depends on the size and site of the renal mass lesion.
- Hilar lesions, lesions close to pelvi-caliceal system and cystic lesions are generally avoided in our practice.
- Liberal use of intraoperative ultrasound imaging by an experienced radiologist is very valuable in localizing the lesion and to rule out multicentric lesions.
- Adequate mobilization of kidney and exposure of renal mass makes subsequent planning and placement of cryoprobes safer and more reliable.
- The importance of placing more than one cryoprobe to achieve adequate coverage of the whole tumor could not be over emphasized. We believe most of the recurrent tumors are persistent tumors, which were missed in the earlier freezing.
- We also believe that a margin of 10 mm is necessary to achieve adequate and dependable cell death.
- We routinely perform double freeze and thaw cycles of 10 minutes duration each to achieve our goal of complete destruction of malignant cells.
- Venous bleeding is usually encountered and can be controlled by pressure, packing with surgicel and fibrin sealants.
- Adequate hemostasis should be ensured at intra-abdominal pressures of 5 mmHg before concluding the procedure.
- Patients should be advised to avoid strenuous activity for the next two weeks to prevent postoperative hemorrhage.

underwent nephrectomy and one patient had change of mental status secondary to narcotics. Three patients died of unrelated causes. Three lesions showed peripheral enhancement at the previously cryoablated site. One patient with peripheral rim enhancement with an increase in size of the cryoablated site with nodular enhancement in the subsequent follow-up scans and biopsy consistent with active disease underwent partial nephrectomy. The other two patients had no further nodular enhancement with decrease in size of the cryoablated site (25).

Gill and coworkers (23) reported their three-year follow-up of laparoscopic renal cryoablation in 56 patients. All patients were treated with a double freeze-thaw cycle, under laparoscopic and ultrasonographic guidance. Follow-up consisted of magnetic resonance imaging on postoperative day 1 and at months 3, 6, 12 and semiannually thereafter until the cryolesion was no longer visible. In addition, computed tomography guided biopsies of all patients were performed at six months postoperatively. Mean patient age was 65 years. Mean preoperative tumor size was 2.3 cm (range, 1.5–3.7). Follow-up biopsies post cryoablation showed residual tumor in two patients (3.6%). New renal lesions developed at a different site in 3 patients (5.4%). At three years the overall patient survival and cryoablation-specific survival was 89% and 100%, respectively.

A meta-analysis of the clinical laparoscopic cryoablation series reported so far showed that the mean tumor size was between 2.0 and 2.54 cm (10,16–23). The recurrence rate is low, anywhere between zero and two cases per series. Shingleton et al. (26) reported their experience and analyzed the possible causes for the persistence of the tumor (14%) requiring retreatment. Large tumor size and tumor masses abutting the pelvi-calyceal system or the renal vessels were found to be the major causes of failures. Tumor size (2/14) and location (11/14) were found to be the most important factors leading to treatment failures.

Complications of renal cryoablation are similar to partial nephrectomy, but special precautions should be taken to avoid unnecessary morbidity. Renal lacerations, perinephric hemorrhages, liver laceration, pancreatic injury, ureteroelvic junction stricture, and complete bowel obstruction have been reported (9,12,18,19,27,28).

The cytotoxic effect and durability of cryoablation appears promising. However, the ideal cryogenic probe system and optimal mode of delivery have yet to be defined. Intra and extracorporeal monitoring of cryolesions is still evolving and its accuracy is dependent on the skill and experience of the surgeon. There are not enough data regarding the treatment of tumor margins in the larger lesions and the safety of cryoablation for the lesions near the collecting system and renal hilum.

The next major challenge is the evaluation of clinical results. Limited postcryoablation imaging and biopsy results have been reported. Decrease in size of the tumor/absence of growth and lack of enhancement on computed tomogram/Magnetic resonance imaging may be viewed as oncological success. Rukstalis et al. (9) recommend routine follow-up biopsy although to date only six months biopsy data are available. Serial biopsies at regular intervals are ideal but an optimal biopsy schedule is yet to be determined and biopsies are not without sampling errors and patient morbidity. Computed tomography-guided percutaneous cryoablation is also available in many centers.

Complications of renal cryoablation are similar to partial nephrectomy, but special precautions should be taken to avoid unnecessary morbidity. Renal lacerations, perinephric hemorrhages, liver laceration, pancreatic injury, ureteroelvic junction stricture, and complete bowel obstruction have been reported.

SUMMARY

- Cryoablation is the most studied of the needle ablative therapies.
- Clinical studies have shown promising short-term results and acceptable safety profile.
- Cryoablation of renal lesions is minimally invasive, safe, and effective for peripheral lesions less than 3 to 4 cm in size in carefully selected individuals.
- More data are required to provide reliable treatment of tumor margins for larger lesions and the safety of using ablative techniques near collecting system and renal hilum.
- Watch for computed tomography-guided percutaneous cryoablation.

ACKNOWLEDGMENTS

The authors gratefully acknowledge Drs. T.D. Moon and S.P. Hedican for contributing cases to this series and Dr. F.T. Lee for his valuable expert imaging help in performing the cryoablation procedure. The authors sincerely thank Mr. Nick Weber (Department of Surgery, Publications) and Mrs. Betsy True (Medical Illustration) for the surgical diagrams.

REFERENCES

1. American Cancer Society. Facts and Figures, 2004.
2. Robson CJ, Churchill BM, Anderson W. The results of radical nephrectomy for renal cell carcinoma. *J Urol* 1969; 101:297–301.
3. Fergany AF, Hafez KS, Novick AC. Long term results of nephron sparing surgery for localized renal cell carcinoma: 10 year follow-up. *J Urol* 2000; 163:442–445.
4. Uzzo RG, Novick AC. Nephron sparing surgery for renal tumors: indications, techniques and outcomes. *J Urol* 2001; 166:6–18.
5. Butler BP, Novick AC, Miller DP, Campbell SA, Licht MR. Management of small unilateral renal cell carcinomas: radical versus nephron-sparing surgery. *Urology* 1995; 45(1):34–40; discussion 40–41.
6. Chosy SG, Nakada SY, Lee FT, Warner TF. Monitoring renal cryosurgery: predictors of tissue necrosis in swine. *J Urol* 1998; 159:1370–1374.
7. Nakada SY, Lee FT, Warner T, Chosy SG, Moon TD. Laparoscopic cryosurgery of the kidney in the porcine model: an acute histological study. *Urology* 1998; 51:161–166.
8. Delworth MG, Pisters LL, Fornage BD, von Eisenbach AC. Cryotherapy for renal cell carcinoma and angiomyolipoma. *J Urol* 1996; 155:252–254.
9. Rukstalis DB, Khorsandi M, Garcia FU. Clinical experience with open renal cryoablation. *Urology* 2001; 57:34–39.
10. Gill IS, Novick AC, Soble JJ. Laparoscopic renal cryoablation: initial clinical series. *Urology* 1998; 52:543–551.
11. Lowry PS, Nakada SY. Renal cryotherapy: 2003 Clinical status. *Curr Opin Urol* 2003; 13:193–197.
12. Shingleton WB, Sewell PE. Percutaneous renal tumor cryoablation with magnetic resonance imaging guidance. *J Urol* 2001; 165:773–776.
13. Shinohara S, Carroll PR. Cryotherapy for prostate cancer. In: Walsh PC, Retik AB, Vaughn ED, Wein AJ, eds. *Campbell's Urology*. 8th ed. Philadelphia: WB Saunders Co., 2002:3171–3181 (Vol. 4, Chapter 93).
14. Hoffmann NE, Bischof JC. The cryobiology of cryosurgical injury. *Urology* 2002; 60:40–49.
15. Hedican SP, Wilkinson ER, Lee FT, Warner TF, Nakada SY. Cryoablation of advanced renal cancer has survival advantages in a murine model compared to nephrectomy. *J Urol* 2004; 171(4 suppl):Abstract No. 778.
16. Bishoff JT, Chen RB, Lee BR, et al. Laparoscopic renal cryoablation: acute and long-term clinical, radiographic, and pathologic effects in an animal model and application in a clinical trial. *J Endourol* 1999; 13(4):233–239.
17. Rodriguez R, Chan DY, Bishoff JT, et al. Renal ablative cryosurgery in selected patients with peripheral renal masses. *Urology* 2000; 55(1):25–30.
18. Gill IS, Novick AC, Meraney AM, et al. Laparoscopic renal cryoablation in 32 patients. *Urology* 2000; 56(5):748–753.
19. Lee DI, McGinnis DE, Feld R, Strup SE. Retroperitoneal laparoscopic cryoablation of small renal tumors: intermediate results. *Urology* 2003; 61(1):83–88.
20. Colon I, Fuchs GJ. Early experience with laparoscopic cryoablation in patients with small renal tumors and severe co-morbidities. *J Endourol* 2003; 17(6):415–423.
21. Nadler RB, Kim SC, Rubenstein JN, Yap RL, Campbell SC, User HM. Laparoscopic renal cryosurgery: the Northwestern experience. *J Urol* 2003; 170(4 Pt 1):1121–1125.
22. Moon TD, Lee FT, Hedican SP, Lowry PS, Nakada SY. Laparoscopic cryoablation under sonographic guidance for the treatment of small renal tumors. *J. Endourol*. In press.
23. Spaliviero M, Moinzadeh A, Gill IS. Laparoscopic cryotherapy for renal tumors. *Technol Cancer Res Treat* 2004; 3(2):177–180.
24. Sung GT, Gill IS, Hsu TH, et al. Effect of intentional cryo-injury to the renal collecting system. *J Urol* 2003; 170(2 Pt 1):619–622.
25. Ankem MK, Moon TD, Hedican SP, Lee FT, Sadowski EA, Nakada SY. Is peripheral rim enhancement a sign of a recurrence of renal cell carcinoma post cryoablation. *J Urol* 2004; 171(4 suppl): Abstract no. 1914.
26. Shingleton WB, Duncan W, Sewell PE. Percutaneous renal tumor cryoablation-results in the first 90 patients. *J Urol* 2004; 171(4 suppl):Abstract no. 1751.
27. Harada J, Dohi M, Mogami T. Initial experience of percutaneous renal cryosurgery under the guidance of horizontal open Magnetic resonance imaging system. *Radiat Med* 2001; 19:291–296.
28. Campbell SC, Krishnamurthi V, Chow G. Renal cryosurgery: experimental evaluation of treatment parameters. *Urology* 1998; 52:29–33.

RENAL RADIOFREQUENCY ABLATION: TECHNIQUE AND RESULTS

Edward D. Matsumoto

Division of Urology, Department of Surgery, McMaster University, Hamilton, Ontario, Canada

Jeffrey A. Cadeddu

Department of Urology, University of Texas Southwestern Medical Center, Dallas, Texas, U.S.A.

- | | |
|---|--|
| ■ INTRODUCTION | ■ RADIOFREQUENCY ABLATION FOLLOW-UP |
| ■ MECHANISM OF ACTION | ■ PROS AND CONS |
| ■ PATIENT SELECTION: INDICATION AND CONTRAINDICATIONS | ■ TECHNICAL CAVEATS/TIPS |
| ■ PREOPERATIVE PREPARATION | ■ RESULTS: EXPERIMENTAL STUDIES |
| ■ LAPAROSCOPIC RADIOFREQUENCY ABLATION TECHNIQUE | ■ RESULTS: CLINICAL STUDIES |
| ■ PERCUTANEOUS RADIOFREQUENCY ABLATION TECHNIQUE | ■ SUMMARY |
| | ■ REFERENCES |
| | ■ COMMENTARY: Harrison K. Rhee and John A. Libertino |

INTRODUCTION

Technological advances are changing the way renal tumors are diagnosed and treated. Many are now discovered incidentally with increasing use of diagnostic imaging modalities such as ultrasound, computed tomography, and magnetic resonance imaging (1,2). At the same time, advances in laparoscopy and minimally invasive surgery are changing the way renal tumors are treated, with reduced morbidity and more rapid recovery, while striving to maintain oncologic efficacy. First performed in 1990 by Clayman et al., laparoscopic nephrectomy demonstrated the feasibility of minimally invasive renal surgery (3). Subsequently, laparoscopic radical nephrectomy for renal tumors was demonstrated to be technically feasible and oncologically effective (4,5). Concurrently, nephron-sparing surgery, in the form of open or laparoscopic partial nephrectomy, has been shown to be a safe therapeutic alternative for the treatment of small renal tumors (<4 cm) (6–9).

Ablative treatments for renal cell carcinoma are currently being developed further reducing the morbidity associated with nephron-sparing surgery. These treatments also present a reduced technical challenge when compared to more conventional partial nephrectomy. Cryoablation (10–12) and radiofrequency ablation (13–15) currently comprise the ablative modalities that are in clinical use, although promising modalities such as high-intensity–focused ultrasound (16,17) and stereotactic radiosurgery (18) are under development. The purpose of this chapter is to discuss radiofrequency ablation treatment and results.

MECHANISM OF ACTION

Radiofrequency ablation uses monopolar alternating electric current delivered directly into the target tissue, where the native impedance of the tissue leads to heat generation. Where heating is sufficient, lethal temperatures are produced and the tissue is ablated. Specifically, a radiofrequency electrode is positioned into the target tissue and a grounding pad placed on the body. A computer-controlled generator applies alternating electrical current with a frequency within the radio segment of the electromagnetic spectrum. This current flows from the probe to the grounding pad. The radiofrequency voltage creates an electric field that exerts a force on the ions within the tissue fluid adjacent to the electrode causing them to vibrate as the current alternates polarity. Frictional dissipation of this ionic current causes heating of the tissues as an inverse function of tissue impedance. Heat is not directly supplied by the probe itself (19). The heating of tissue decreases with distance from the probe ($\text{heat} = \text{length}/\text{radius}$) and relies on the thermal conductance

properties of the treated tissue (20,21). The treatment zone is that area that achieves temperatures sufficient for cell death by either of these two mechanisms. Overall, heat distribution in the tissue surrounding the probe is a function of tissue impedance, native tissue temperature, thermal conductivity, and heat loss through the circulation.

The exact mechanism of cell death caused by radiofrequency ablation is not completely understood. Most investigators believe thermal effects are the source of tissue injury, although the direct effect of the electrical field on the tissues is unknown (22). Heating of tissues to temperatures greater than 60°C routinely leads to desiccation and coagulative necrosis (23). Exposure to high temperatures also has direct effects on cellular components including the cell membrane, cytoskeleton, and nucleus. At supraphysiologic temperatures fluidity of the cell membrane increases, altering the kinetics of membrane proteins. These temperatures also denature the proteins that make up the cytoskeleton effecting cellular architecture. In the nucleus, high temperatures significantly impair deoxyribonucleic acid replication, in addition, cellular metabolism and electrophysiology are adversely affected by the high temperatures created during ablation (22). radiofrequency ablation also has a direct effect on tissue perfusion by causing microvascular and arteriolar occlusion within the ablated zone leading to ischemia of treated tissues (24). The overall effect is a predictable zone of necrosis surrounding the radiofrequency probe.

PATIENT SELECTION: INDICATION AND CONTRAINDICATIONS

General indications for radiofrequency ablation of renal tumors are the same as with conventional nephron-sparing surgery and include the following: contrast-enhancing (≥ 10 –12 Hounsfield units), small renal masses (< 4 cm), tumor in solitary kidney, bilateral tumors, and renal insufficiency.

General indications for radiofrequency ablation of renal tumors are the same as with conventional nephron-sparing surgery and include the following: contrast-enhancing (≥ 10 –12 Hounsfield units), small renal masses (< 4 cm), tumor in solitary kidney, bilateral tumors, and renal insufficiency.

Contraindications for laparoscopic radiofrequency ablation generally are ones that prevent the creation of a pneumoperitoneum including multiple adhesions, history of peritonitis, and difficulty with ventilation. Contraindications for a percutaneous radiofrequency ablation approach include anterior renal tumors, colon or small bowel within 1 cm of the tumor, a large spleen or liver interfering with probe passage, and tumors immediately adjacent to the ureter or the renal pelvis (15).

PREOPERATIVE PREPARATION

Magnetic resonance imaging or computed tomography utilizing 3-mm axial cuts with and without enhancing contrast is used to delineate the tumor. If planning a percutaneous approach, a computed tomography in a prone or flank position can be helpful in avoiding needle access problems on the day of the procedure (15). In particular, it may reveal an impediment to the potential needle pathway by bowel or other organs. The prone position may also shift the kidney anteriorly to allow access to a tumor that otherwise would have been inaccessible on the supine view.

Preoperative preparations include blood coagulation screening, urine cultures, electrolytes, and creatinine. Patients are instructed to take a bowel preparation solution, such as magnesium citrate, the day before surgery.

LAPAROSCOPIC RADIOFREQUENCY ABLATION TECHNIQUE

The laparoscopic approach to radiofrequency ablation of a small renal mass is indicated for anterior, medial, and some lateral renal tumors where the ureter, colon, or small bowel are within 1 cm of the tumor and risk injury.

The laparoscopic approach to radiofrequency ablation of a small renal mass is indicated for anterior, medial, and some lateral renal tumors where the ureter, colon, or small bowel are within 1 cm of the tumor and risk injury.

In addition, the path for percutaneous radiofrequency needle placement for a posterior renal tumor is occasionally impeded by a large spleen, liver lobe, or lung parenchyma. In these cases, if radiofrequency ablation is intended, a laparoscopic approach is indicated.

The patient is positioned in a modified flank position, and three or four transperitoneal laparoscopic trocars are placed as with laparoscopic nephrectomy. The kidney is then mobilized within Gerota's fascia, and the tumor is identified and evaluated with laparoscopic ultrasound. The tumor is exposed and the overlying fat is excised and sent for pathologic analysis.

We use the radiofrequency interstitial tumor ablation Model 1500X electrosurgical generator and 15-gauge Starburst XL probe^a that is a dry-probe, temperature-based

^aRITA Medical Systems, Inc., Mountain View, CA.

system. This radiofrequency system is Food and Drug Administration-approved for the ablation of all soft tissue tumors. The probe consists of nine active tines, five of which also contain a thermistor. The probe is introduced percutaneously at a location that permits near-perpendicular insertion into the renal tumor (Fig. 1). The tines are deployed to a diameter that ablates a zone 0.5 to 1.0 cm greater than the tumor diameter measured on computed tomography and intraoperative ultrasound, in order to ensure complete coagulation of both the tumor and a margin of normal kidney parenchyma. The Starburst XL design is particularly well suited for kidney tumor ablation. The tines deploy in a forward direction from the needle tip so that when the probe is placed perpendicular to the tumor surface, the surgeon can be confident that the greatest energy is deposited at the deep tumor margin—the region of highest blood flow and most likely site of incomplete ablation.

Energy is maintained at less than 150 W until the average temperature of the tines reached a target temperature of 105°C (per the manufacturer's recommendation). Once the target temperature is reached, it is maintained for three to eight minutes, depending on the size of the tumor (Table 1). At no time during treatment is the impedance allowed to exceed 80 ohms. The lesion created by the radiofrequency probe is a direct function of its deployed diameter and the minimum time activated (Table 1). As such, real-time ultrasound monitoring of the ablation is not necessary because activating the probe for longer periods of time does not change the lesion size. After a 30-second cool down period, a second cycle is performed using the same settings, tine deployment, and time. If the tumor is not spherical or larger than 4 cm, the probe is repositioned and tines redeployed.

An advantage of the temperature-based system is that during the cool down period, passive tissue temperatures are monitored in real time. If the treated tissue maintains a temperature above 65°C to 70°C, the surgeon should be confident that cell death has occurred.

Following treatment, the tract is ablated as the probe is withdrawn to prevent bleeding and to minimize the risk of tumor seeding. Track ablation is stopped once the probe is withdrawn from the kidney.

Based on our laboratory experience, the renal hilum should not be occluded during laparoscopic ablation (23). Although it likely increases the ablation diameter and shortens the time to reach the target temperature by eliminating the circulatory heat sink, there is a risk of intravascular thrombus propagation and unpredictable normal parenchyma damage.

Depending on tumor size and location, the ablated tumor can be left either in situ or excised. Tumors that are endophytic or located in the mid-pole are left in situ with our protocol. In these cases, diagnostic biopsies are taken after ablation using a laparoscopic 5-mm toothed biopsy forceps (Fig. 1). Biopsies are not taken before ablation to minimize the risk of bleeding and tumor seeding (25). Tumors that are exophytic or in a favorable polar location can be completely excised in a hemostatic fashion without hilar

An advantage of the temperature-based system is that during the cool down period, passive tissue temperatures are monitored in real time. If the treated tissue maintains a temperature above 65°C to 70°C, the surgeon should be confident that cell death has occurred.

FIGURE 1 ■ (A) The tines are deployed beside the tumor to check appropriate ablation diameter. (B) The probe is inserted perpendicular to the tumor. Tines are deployed and confirmed with a laparoscopic ultrasound. (C) The ablation is underway. (D) The ablated renal tumor after a biopsy.

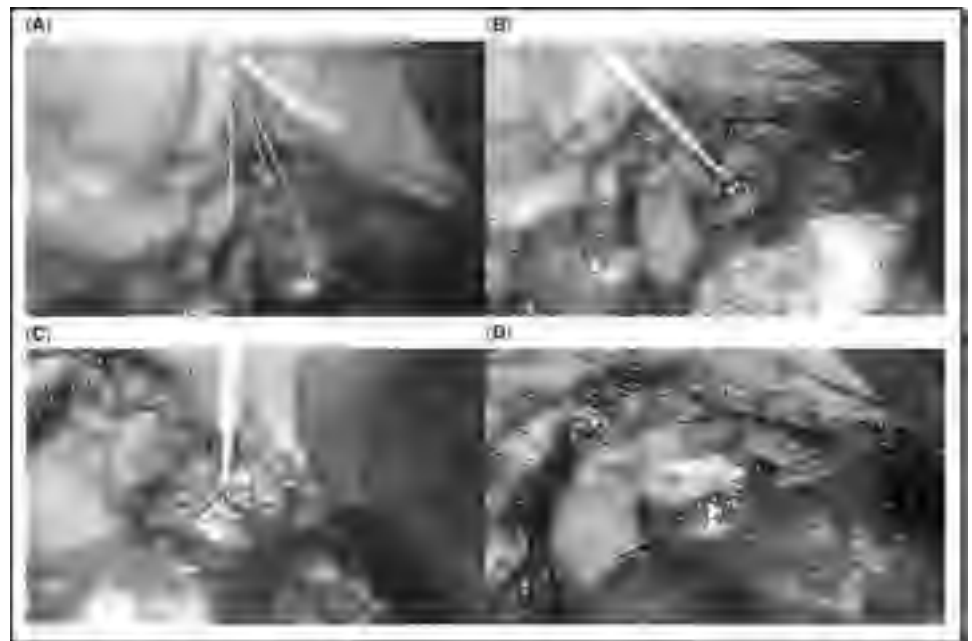


TABLE 1 ■ Renal Tumor Radio Frequency Ablation Settings

Tumor size (cm)	Target temperature (°C)	Time at target temperature (min)	No. of cycles
<1.0	105	3	1(2)
1.0–2.0	105	5	2
2.0–3.0	105	7	2
3.0–4.0	105	8	2

TABLE 2 ■ Summary of Laparoscopic RFA

Port placement as per standard laparoscopic nephrectomy or partial with 12-mm port in lower abdomen to accommodate laparoscopic US probe

Use laparoscopic US to localize tumor

Start dissecting Gerota's off of tumor, beginning at medial edge

Completely expose tumor surface

Hilar dissection, mobilization of kidney is unnecessary

Posterior located tumor can be approached via retroperitoneoscopy

RFA probes should be used according to manufacturer's instructions

RITA XL probes are inserted perpendicular into the tumor

Tines are deployed to diameter 0.5 cm beyond tumor diameter as measured on preoperative CT

Laparoscopic US is used to confirm deployment of tines

Ablate according to tumor size (Table 1)

Abbreviations: RFA, radiofrequency ablation; CT, computed tomography; US, ultrasound.

occlusion (26). The specimen is placed in a laparoscopic bag and extracted through one of the trocar sites at the conclusion of the case. Adjunctive hemostatic measures, such as argon beam coagulation, fibrin glue, and/or oxidized cellulose can be applied in these cases to prevent delayed bleeding (Table 2).

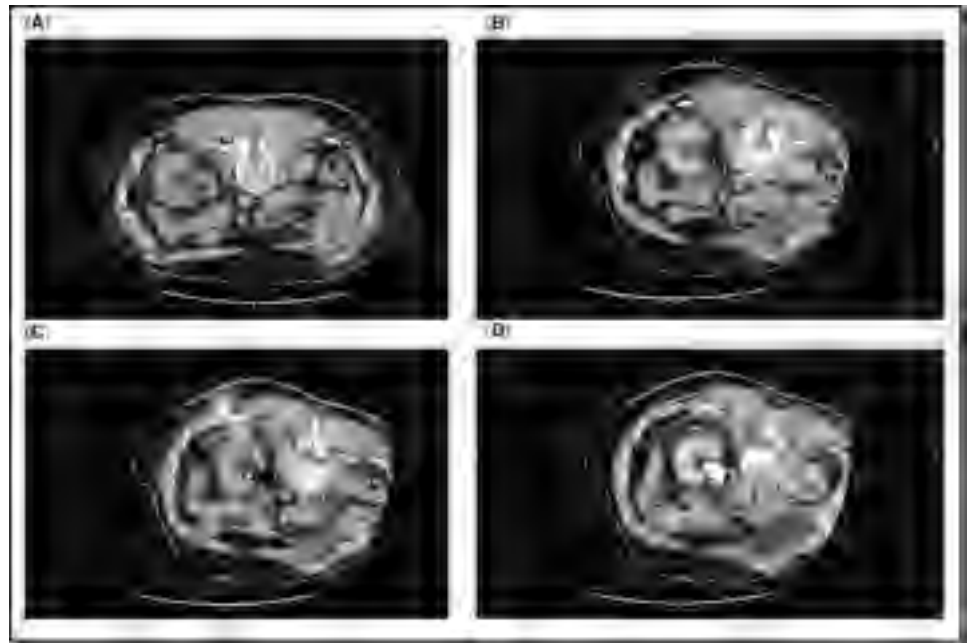
PERCUTANEOUS RADIOFREQUENCY ABLATION TECHNIQUE

Percutaneous radiofrequency ablation can be performed under intravenous sedation and local anesthesia or general anesthesia. We prefer general anesthesia, as kidney location can be contrasted and is reproducible expediting the procedure. After induction of anesthesia, a parenteral intravenous antibiotic is administered, an orogastric tube placed and a urethral catheter inserted. The patient is then placed prone or in a flank position on the computed tomography gantry with arms secured to ensure clearance through the scanner.

With the assistance of an interventional radiologist, intravenous contrast is first administered to accurately image the lesion. If iodinated contrast is contraindicated, a small dose of gadolinium can be administered. Alternative, ultrasound guidance may be employed. However, we discourage its routine use due to the technology's inherent resolution variability. First, a 20-gauge Chiba needle is usually directed to the peripheral rim of the renal tumor as a "finder needle." Placement is confirmed with repeat computed tomography imaging. An 18-gauge core biopsy needle is passed adjacent to the Chiba needle into the peripheral margin of the tumor. Following computed tomography confirmation of positioning, multiple tissue cores are obtained. A radiofrequency interstitial tumor ablation Starburst XL probe is then placed along side the Chiba needle to the same depth. When repeat computed tomography imaging demonstrates adequate positioning of the radiofrequency probe, the tip is advanced to just within the peripheral tumor margin and the Chiba needle is withdrawn. We prefer the "finder needle" technique to minimize the number of radiofrequency probe positioning attempts and thereby the risk of peri-lesion breeding and, "theoretical," tumor cell spillage. Similar to the laparoscopic technique, the tines of the radiofrequency probe are then deployed for an ablation diameter approximately 0.5 to 1.0 cm beyond the computed tomography-measured tumor diameter. Prior to ablation, successful deployment of the radiofrequency tines is confirmed by repeat computed tomography imaging which should demonstrate coverage of the entire tumor as well as a rim of normal parenchyma at the deep tumor margin (Fig. 2).

Radiofrequency ablation is performed utilizing the same protocol as described for the laparoscopic radiofrequency ablation. If adequate tumor coverage is not accomplished because of tumor size or shape, the radiofrequency probe is repositioned in a different portion of the tumor for a second round of treatment. Following the ablation, the probe is withdrawn slowly through Gerota's fat in "track ablate" mode to prevent bleeding and the "theoretical" risk of tumor seeding. In this mode, the probe track is heated to 75°C or greater. Immediate postablation contrast computed tomography imaging is repeated to assess whether the mass has been successfully ablated (Table 3).

FIGURE 2 ■ (A) A small left posterior renal tumor is seen in the noncontrast phase while the patient is prone. (B) Contrast has been given and the patient is slightly rotated to optimize probe angle. (C) The tumor has been targeted and the tines are deployed beyond the tumor margin. (D) The postablation defect. Note the lack of contrast uptake by the lesion.



RADIOFREQUENCY ABLATION FOLLOW-UP

Standard follow-up of patients includes computed tomography or magnetic resonance imaging with and without intravenous contrast at 6 weeks, 6 months, 12 months, and then every 6 months thereafter. With increasing experience, we anticipate that less frequent imaging will be necessary. Ablation is successful if the lesion along with a margin of normal parenchyma no longer enhances on contrast imaging (<10 – 12 HU). For treatment failures, our protocol is either to retreat or surgical extirpation. This decision is based on the location of the failure, the response to the original treatment and the patient's health and preference. For the radiofrequency-assisted partial nephrectomy group, surveillance is similar to that of conventional partial nephrectomy patients.

PROS AND CONS

Laparoscopic radiofrequency ablation has the advantage of approaching anteriorly located tumors safely and easier than percutaneous radiofrequency ablation. Also bowel and ureter that abut a tumor can be mobilized to prevent burn injuries.

During laparoscopic radiofrequency ablation, incisional biopsies, which have a higher diagnostic rate than needle core biopsies, can also be obtained using a laparoscopic 5-mm cup biopsy instrument (25).

Percutaneous radiofrequency ablation has the advantage of an outpatient procedure that avoids a pneumoperitoneum, which may be poorly tolerated by select

During laparoscopic radiofrequency ablation, incisional biopsies which have a higher diagnostic rate than needle core biopsies can also be obtained using a laparoscopic 5-mm cup biopsy instrument.

TABLE 3 ■ Summary of Percutaneous RFA

Obtain prone CT prior to ablation day to rule out any impediment for the ablation needle path
Ensure that bowel and ureter are not abutting the tumor
Use an 18-gauge needle to seek out tumor location on CT
Deploy tines and confirm tine coverage of tumor
Tru-cut biopsy can be obtained once RFA probe position is confirmed
Ablated according to manufacturer's recommendation
Track ablation while removing probe, stop ablation before probe starts coming through abdominal wall to prevent burn injuries
Obtain final contrast-enhanced CT to confirm ablation

Abbreviations: RFA, radiofrequency ablation; CT, computed tomography.

patients. Also, computed tomography guidance provides greater resolution than ultrasound guidance, which is important for probe placement and confirmation of tine deployment. Smaller endophytic tumors are also better visualized with computed tomography.

TECHNICAL CAVEATS/TIPS

- There are a few important technical caveats to facilitate laparoscopic radiofrequency ablation.
- Ultrasound is essential to localize the tumor and to gauge the deployment of the tines during laparoscopic radiofrequency ablation.
- However, monitoring the ablation lesion is not necessary, because setting the tines to the desired diameter on the probe handle will ensure appropriate heat distribution to the tumor (27).

Only dissection of Gerota's fascia is necessary to expose the tumor surface. Hilar dissection is unnecessary, which minimizes the risk of vascular injury. A separate abdominal wound should be made with a No. 11 blade to allow perpendicular trajectory of the radiofrequency ablation probe into the center of the exposed renal tumor. If necessary, some perirenal fat or laparoscopic pledgets can be used to prop the kidney up to optimize probe angle. Track ablation should be utilized while removing the probe from the tumor on completion of the ablation. Finally, we recommend injecting fibrin glue down the ablation track for tumors that are close to the collecting system. This may prevent urine leaks.

RESULTS: EXPERIMENTAL STUDIES

Zlotta et al. first described the use of radiofrequency ablation to ablate human renal tumors in an ex vivo model and subsequently ablated human tumors in vivo immediately prior to nephrectomy (28). Although the results were encouraging the authors called for animal experiments to better characterize the effects of radiofrequency ablation on renal tissue. Walther et al. performed a similar study treating 14 tumors (none greater than 4 cm in size) in four patients with radiofrequency ablation just before surgical excision (29). No toxicity related to radiofrequency ablation was observed. They reported subtle detectable changes in treated tissue, but importantly cited that the excision immediately after ablation did not allow enough time necessary for the changes of coagulation necrosis to be seen. Gill et al. performed laparoscopic and percutaneous impedance-based radiofrequency ablation in a porcine model (24). In this report the authors described the acute ultrasonic appearance of radiofrequency ablation lesions as an irregular hyperechoic area that could not be reproducibly identified. Arteriograms demonstrated occlusion of the intrarenal vessels in the areas of radiofrequency ablation, with a normal appearance of the remainder of the vessels. Later, this same group published the acute and chronic histopathologic effects of impedance-based radiofrequency ablation on renal tissue, observing extensive coagulative necrosis and marked inflammation in the areas of treatment (30). Early radiofrequency ablation-mediated changes consisted of blurring of chromatin, increased cytoplasmic eosinophilia, loss of cell border integrity, and interstitial hemorrhage. As time progressed there was degeneration of nuclear and cellular features and an inflammatory infiltrate at the border of the lesion. Ultimately they observed spontaneous resorption and autoamputation of the treated portion of the kidney. Corwin et al. (23) evaluated the tissue effects of temperature-based radiofrequency ablation with and without hilar occlusion. This study investigated the effect of any heat sink phenomenon due to renal blood flow in a porcine model (23). Acutely they observed coagulative necrosis within the ablated lesion with preserved renal architecture and minimal cellular changes, consisting of loss of distinct cytoplasmic borders, variable appearance of nuclei, and increased eosinophilia.

Importantly, nicotinamide adenine dinucleotide staining confirmed complete nonviability in all parts of the radiofrequency ablation lesion. Although hilar clamping caused a slight increase in lesion size, the difference was not statistically significant. Furthermore, clamping did not appear to have any effect on tumor viability within the radiofrequency ablation lesion, as complete cell death occurred regardless of hilar occlusion. However, in some cases, hilar occlusion resulted in unpredictable lesion size and large parenchymal infarction.

Little experimental data exist regarding the oncologic adequacy of radiofrequency ablation as a primary treatment for renal tumors. The lack of comparable animal models for renal cell carcinoma makes this difficult to obtain. Nakada and coworkers evaluated the efficacy of radiofrequency ablation, cryoablation, and radical nephrectomy as treatment for implanted VX2 tumors, an aggressive tumor model, in rabbits (31). They found radiofrequency ablation, cryoablation, and nephrectomy to be equally efficacious in treating these tumors when compared to untreated controls. Our group has reported a case of nephrectomy for ureteropelvic junction almost one year after radiofrequency ablation of a renal tumor in a human patient. Microscopic examination demonstrated a giant cell reaction in the area of the ablated tumor with no evidence of residual renal cell carcinoma (32).

A study by Rehman et al. recently compared the effects of microwave, cryoablation, impedance and temperature-based mono- and bipolar radiofrequency ablation, and liquid and gel chemoablation on porcine kidneys (33). Of all the techniques tested, temperature-based radiofrequency ablation (radiofrequency interstitial tissue ablation system) and cryotherapy were the only two methods to result in complete tissue necrosis with no skip areas. The authors concluded that with current technology, cryotherapy and multitime temperature-based radiofrequency ablation were the only modalities that offer complete necrosis within the sphere of treatment.

RESULTS: CLINICAL STUDIES

Radiofrequency ablation moved quickly from experimental studies to utilization in clinical series. Zlotta et al. (28) and Walther et al. (29) performed radiofrequency ablation in human patients prior to nephrectomy or partial nephrectomy demonstrating its safety in a small number of patients. Later, McGovern et al. reported the first use of radiofrequency ablation with the intent to treat renal carcinoma in 1999 (34). This patient, an elderly individual who refused surgery for a growing 3.5 cm enhancing mass, had a 17-gauge radiofrequency ablation probe placed percutaneously under ultrasound guidance and the tumor treated for 12 minutes. Contrast-enhanced computed tomography scan two hours after the ablation showed a nonenhancing region in the treated area enveloping the previously enhancing tumor. Contrast-enhanced computed tomography at one and three months confirmed nonenhancement in the treated region. The authors cited the need for extended follow-up to determine long-term efficacy. They later reported their experience treating nine tumors in eight patients (including the initial patient above) with a range of tumor sizes of 1.2 to 5 cm, including three lesions smaller than 3 cm and six lesions larger (35). The seven patients with normal renal function were imaged at six-month intervals. Two larger tumors (4.4 and 5.0 cm) demonstrated persistent enhancement and were treated with additional radiofrequency ablation. With a mean follow-up of 10.3 months (range, 3–21) no patient had manifestations of renal cell carcinoma.

Hall et al. recently reported an innovative combination of embolization with polyvinyl alcohol and percutaneous radiofrequency ablation in a 67-year-old patient with a 2.5 × 3.0 cm tumor in a solitary kidney (36). A computed tomography scan performed at eight weeks post ablation showed a complete lack of contrast enhancement in the treated area. At three months post ablation, a biopsy revealed fibrous tissue and necrotic cellular debris with no evidence of malignancy. We have successfully employed this same technique in a few central or large (≥ 4 cm) tumors to reduce the circulatory heat sink.

Pavlovich et al. reported a series of 24 percutaneous temperature-based ablations in 21 patients using ultrasound and computed tomography guidance (14). With a mean tumor diameter of 2.4 cm, and no tumors exceeding 3 cm, 19 ablations were considered satisfactory at the time of treatment based on reaching and maintaining a tissue temperature of 70°C at all probes during therapy. Follow-up with contrast-enhanced computed tomography was performed at two months with 19 tumors free of enhancement (18 tumors that were thought to be satisfactorily treated and 1 tumor that did not meet the target temperature criteria.) Effects on the kidney were reported in 17 patients, with no change in serum creatinine identified but microscopic proteinuria (1+) appearing in four patients two months after radiofrequency ablation. They concluded that percutaneous radiofrequency ablation was well tolerated but required further evaluation to determine long-term efficacy. The same group recently published the results of familial renal tumors treated with a higher power generator (200 W) (37). Seventeen patients with a total of 24 hereditary renal tumors ranging from 1.2 to 2.85 cm were treated with the Cool-tip Radiofrequency System^b. Nine were treated laparoscopically and eight

^bRadionics, Burlington, MA.

percutaneously. At a median follow-up of just over one year, the median tumor or thermal lesion diameter decreased from 2.26 to 1.62 cm. Only one centrally located lesion (4%) demonstrated contrast enhancement (greater than 10 HU) at 12 months. One patient developed a ureteropelvic junction obstruction, which was repaired at nine months with excision of the previously ablated tumor. There was no evidence of viable tumor tissue on pathological examination.

Our group has reported the results of 13 tumors less than 4 cm in diameter (mean size, 2.4 cm) treated with computed tomography-guided percutaneous radiofrequency ablation and 13 patients with 17 tumors (mean tumor size, 1.96 cm) treated with laparoscopic radiofrequency ablation (15,26). The laparoscopic group included patients with tumors treated and left in situ and other patients who had the tumor treated and excised, known as radiofrequency ablation-assisted laparoscopic partial nephrectomy. In the percutaneous group, 12 of the 13 tumors were completely ablated with the first treatment, as evidenced by absence of enhancement on follow-up computed tomography imaging. The one tumor that demonstrated enhancement of a residual peripheral rim on a six-week computed tomography scan was retreated with radiofrequency ablation. Follow-up contrast-enhanced computed tomography imaging shows no persistent enhancement of this tumor. In the laparoscopic in situ group at least six-month follow-up was available in eight patients, with all eight showing no evidence of tumor. One patient in the radiofrequency ablation-assisted laparoscopic partial nephrectomy group showed a margin positive for ablated tumor cells, i.e., the tumor cells were present at the surgical margin, but these tumor cells appeared to be ablated by the radiofrequency ablation treatment. This patient continued to be disease-free at one-year follow-up. We have seen one patient with disease recurrence in the treatment bed. This patient was initially treated with cryotherapy and suffered a recurrence prompting percutaneous radiofrequency ablation. Although initial follow-up imaging after radiofrequency ablation demonstrated no contrast enhancing lesions, later studies revealed an enhancing nodule. This nodule has since been retreated with radiofrequency ablation. Similar to the experience of Pavlovich et al., we have not identified any significant changes in renal function or blood pressure attributable to radiofrequency ablation (38). Our series has since grown to over 100 patients, with only two treatment failures and one local recurrence after a mean follow-up of 14 months. There has been no evidence of distant metastasis. Three deaths have occurred, unrelated to the renal tumor (stroke, primary lung cancer and pneumonia).

Recently, a number of groups have published additional results using image-guided percutaneous radiofrequency ablation to treat small renal tumors (Table 4). Although follow-up has been short, averaging nine months, the success rate has ranged 81% to 100%.

Although these studies and others are encouraging, some investigators have questioned the totality of tumor destruction with radiofrequency ablation and which patients are appropriate candidates for radiofrequency ablation. Rendon et al. performed impedance-based radiofrequency ablation followed by either immediate nephrectomy or nephrectomy one week after ablation (42). Of the five tumors followed by immediate nephrectomy, hematoxylin and eosin stained sections in four showed histologic evidence of peripheral tumor viability in approximately 5% of the tumor volume. Of the six tumors followed by one-week delayed nephrectomy, three demonstrated residual viable tumor at the periphery. These areas of tumor viability may have been eliminated by the creation of larger areas of ablation extending beyond the tumor. They concluded that radiofrequency ablation is a promising technique but raised questions concerning the ideal size and location of tumors eligible for such treatment. Michaels et al. treated 15 patients with 20 tumors with temperature-based radiofrequency ablation immediately prior to partial nephrectomy (43). They observed areas of morphologically unchanged tumor by standard hematoxylin and eosin staining in all 20 specimens, and evidence of

Recently, a number of groups have published additional results using image-guided percutaneous radiofrequency ablation to treat small renal tumors. Although follow-up has been short, averaging nine months, the success rate has ranged 81% to 100%.

TABLE 4 ■ Recent Percutaneous Radiofrequency ablation Series

Studies	Tumors treated	Approach/technology	Mean follow-up (range) (mo)	Outcome
Su et al. (39)	35	PC/TB (18) and IB (17)	9 (0-23)	11/13 (with 12 mo follow-up) no enhancement
Mayo-Smith et al. (40)	32	PC/IB	9 (1-36)	26/32 no enhancement
Farrell et al. (41)	35	PC/TB (12) and IB (23)	9 (1-23)	35/35 no enhancement

Abbreviations: PC, percutaneous; TB, temperature based; IB, impedance-based with cool-tip.

nicotinamide adenine dinucleotide activity in four of the five specimens evaluated. In contrast to the study above, they observed these areas of viability within the ablation defect. They concluded that current radiofrequency ablation regimens are ineffective for total tumor destruction, though they acknowledged that their conclusion was based only on immediate removal of the tumor. In contrast, Matlaga et al. similarly studied tumors that had been treated with radiofrequency ablation prior to radical or partial nephrectomy with dramatically different results (35). In their series of 10 patients, 8 demonstrated complete tumor nonviability based on hematoxylin and eosin staining as well as nicotinamide adenine dinucleotide staining. Two tumors showed evidence of viability. However, the authors noted that failure of radiofrequency ablation was expected in both cases, as one tumor did not reach adequate temperatures during treatment and the other was too large (8 cm in diameter) to be treated with the probes they employed during the studies. They concluded that radiofrequency ablation does completely ablate renal tumors with minimal collateral damage to surrounding renal tissue.

SUMMARY

- To date, radiofrequency ablation results are promising and demonstrate excellent intermediate-term efficacy.
- The ability to perform radiofrequency ablation both percutaneously under computed tomography guidance and laparoscopically makes it a versatile tool in the management of small renal masses.
- As we gain better understanding of the management of small renal masses, the role of ablative technologies such as radiofrequency ablation will be better defined.

REFERENCES

1. Smith SJ, Bosniak MA, Megibow AJ, Hulnick DH, Horii SC, Raghavendra BN. Renal cell carcinoma: earlier discovery and increased detection. *Radiology* 1989; 170:699.
2. Jayson M, Sanders H. Increased incidence of serendipitously discovered renal cell carcinoma. *Urology* 1998; 51:203.
3. Clayman RV, Kavoussi LR, Soper NJ, et al. Laparoscopic nephrectomy: initial case report. *J Urol* 1991; 146:278.
4. Chan DY, Cadeddu JA, Jarrett TW, Marshall FF, Kavoussi LR. Laparoscopic radical nephrectomy: cancer control for renal cell carcinoma. *J Urol* 2001; 166:2095.
5. Cadeddu JA, Ono Y, Clayman RV, et al. Laparoscopic nephrectomy for renal cell cancer: evaluation of efficacy and safety: a multicenter experience. *Urology* 1998; 52:773.
6. Beldegrun A, Tsui KH, deKemion JB, Smith RB. Efficacy of nephron-sparing surgery for renal cell carcinoma: analysis based on the new 1997 tumor-node-metastasis staging system. *J Clin Oncol* 1999; 17:2868.
7. Lee computed tomography, Katz J, Shi W, Thaler HT, Reuter VE, Russo P. Surgical management of renal tumors 4 cm. or less in a contemporary cohort. *J Urol* 2000; 163:730.
8. Herr HW. Partial nephrectomy for unilateral renal carcinoma and a normal contralateral kidney: 10-year followup. *J Urol* 1999; 161:33; discussion 34–35.
9. Fergany AF, Hafez KS, Novick AC. Long-term results of nephron sparing surgery for localized renal cell carcinoma: 10-year followup. *J Urol* 2000; 163:442.
10. Shingleton WB, Farabaugh P, Hughson M, Sewell PE Jr. Percutaneous cryoablation of porcine kidneys with magnetic resonance imaging monitoring. *J Urol* 2001; 166:289.
11. Gill IS, Novick AC, Meraney AM, et al. Laparoscopic renal cryoablation in 32 patients. *Urology* 2000; 56:748.
12. Lee DI, McGinnis DE, Feld R, Strup SE. Retroperitoneal laparoscopic cryoablation of small renal tumors: intermediate results. *Urology* 2003; 61:83.
13. Gervais DA, McGovern FJ, Wood BJ, Goldberg SN, McDougal WS, Mueller PR. Radio-frequency ablation of renal cell carcinoma: early clinical experience. *Radiology* 2000; 217:665.
14. Pavlovich CP, Walther MM, Choyke PL, et al. Percutaneous radio frequency ablation of small renal tumors: initial results. *J Urol* 2002; 167:10.
15. Ogan K, Jacomides L, Dolmatch BL, et al. Percutaneous radiofrequency ablation of renal tumors: technique, limitations, and morbidity. *Urology* 2002; 60:954.
16. Paterson radiofrequency, Barret E, Siqueira TM Jr, et al. Laparoscopic partial kidney ablation with high intensity focused ultrasound. *J Urol* 2003; 169:347.
17. Kohnnann KU, Michel MS, Gaa J, Marlinghaus E, Alken P. High intensity focused ultrasound as noninvasive therapy for multilocal renal cell carcinoma: case study and review of the literature. *J Urol* 2002; 167:2397.
18. Ponsky LE, Crownover RL, Rosen MJ, et al. Initial evaluation of Cyberknife technology for extracorporeal renal tissue ablation. *Urology* 2003; 61:498.
19. Cosman ER, Nashold BS, Ovelman-Levitt J. Theoretical aspects of radiofrequency lesions in the dorsal root entry zone. *Neurosurgery* 1984; 15:945.
20. Patel VR, Leveille RJ, Hoey MF, Herron AJ, Zaias J, Hulbert JC. Radiofrequency ablation of rabbit kidney using liquid electrode: acute and chronic observations. *J Endourol* 2000; 14:155.
21. Organ LW. Electrophysiologic principles of radiofrequency lesion making. *Appl Neurophysiol* 1976–1977; 39:69.

22. Haines DE. The pathophysiology of radiofrequency lesion formation. In: Zipes DP, ed. *Catheter Ablation of Arrhythmias*. Armonk, New York: Futura Publishing Company, Inc., 1994.
23. Corwin TS, Lindberg G, Traxer O, et al. Laparoscopic radiofrequency thermal ablation of renal tissue with and without hilar occlusion. *J Urol* 2001; 166:281.
24. Gill IS, Hsu TH, Fox RL, et al. Laparoscopic and percutaneous radiofrequency ablation of the kidney: acute and chronic porcine study. *Urology* 2000; 56:197.
25. Margulis V, Matsumoto ED, Lindberg G, et al. Acute histologic effects of temperature-based radiofrequency ablation on renal tumor pathologic interpretation. *Urology*. 2004; 64(4):660–663.
26. Jacomides L, Ogan K, Watumull L, Cadeddu JA. Laparoscopic application of radio frequency energy enables in situ renal tumor ablation and partial nephrectomy. *J Urol* 2003; 169:49; discussion 53.
27. Ogan K, Roberts WW, Wilhelm DM, et al. Infrared thermography and thermocouple mapping of radiofrequency renal ablation to assess treatment adequacy and ablation margins. *Urology* 2003; 62:146.
28. Zlotta AR, Wildschutz T, Raviv G, et al. Radiofrequency interstitial tumor ablation is a possible new modality for treatment of renal cancer: ex vivo and in vivo experience. *J Endourol* 1997; 11:251.
29. Walther MC, Choyke PL, Libutti SK. A phase 2 study of radiofrequency interstitial tissue ablation of localized renal tumors. *J Urol* 2000; 163:1424.
30. Hsu TH, Fidler ME, Gill IS. Radiofrequency ablation of the kidney: acute and chronic histology in porcine model. *Urology* 2000; 56:872.
31. Jerde TJ, Johnson CD, Lee FT, Warner TF, Nakada SY. Efficacy of therapeutic techniques for implanted VX2 carcinoma in rabbits kidneys: comparison between radiofrequency, cryoablation and nephrectomy (abstract). *J Urol* 2000; 163:8.
32. Johnson DB, Saboorian MH, Duchene DA, Ogan K, Cadeddu JA. Nephrectomy after radiofrequency ablation-induced ureteropelvic junction obstruction: potential complication and long-term assessment of ablation adequacy. *Urology* 2003; 62:351.
33. Rehman J, Landman J, Lee D, et al. Needle-based ablation of renal parenchyma using microwave, cryoablation, impedance- and temperature-based monopolar and bipolar radiofrequency, and liquid and gel chemoablation: laboratory studies and review of the literature. *J Endourol* 2004; 18:83.
34. McGovern FJ, Wood BJ, Goldberg SN, Mueller PR. Radiofrequency ablation of renal cell carcinoma via image guided needle electrodes. *J Urol* 1999; 161:599.
35. Matlaga BR, Zagoria RJ, Woodruff RD, Torti FM, Hall MC. Phase II trial of radio frequency ablation of renal cancer: evaluation of the kill zone. *J Urol* 2002; 168:2401.
36. Hall WH, McGahan JP, Link DP, deVere White RW. Combined embolization and percutaneous radiofrequency ablation of a solid renal tumor. *AJR* 2000; 174:1592.
37. Hwang JJ, Walther MM, Pautler SE, et al. Radio frequency ablation of small renal tumors: intermediate results. *J Urol* 2004; 171:1814.
38. Johnson DB, Taylor GD, Lotan Y, Sagalowsky AI, Koenemann KS, Cadeddu JA. The effects of radio frequency ablation on renal function and blood pressure. *J Urol* 2003; 170:2234.
39. Su LM, Jarrett TW, Chan DY, Kavoussi LR, Solomon SB. Percutaneous computed tomography-guided radiofrequency ablation of renal masses in high surgical risk patients: preliminary results. *Urology* 2003; 61:26.
40. Mayo-Smith WW, Dupuy DE, Parikh PM, Pezzullo JA, Cronan JJ. Imaging-guided percutaneous radiofrequency ablation of solid renal masses: techniques and outcomes of 38 treatment sessions in 32 consecutive patients. *AJR* 2003; 180:1503.
41. Farrell MA, Charboneau WJ, DiMarzio DS, et al. Imaging-guided radiofrequency ablation of solid renal tumors. *AJR* 2003; 180:1509.
42. Rendon RA, Kachura JR, Sweet JM, et al. The uncertainty of radio frequency treatment of renal cell carcinoma: findings at immediate and delayed nephrectomy. *J Urol* 2002; 167:1587.
43. Michaels MJ, Rhee HK, Mourtzinos AP, Summerhayes IC, Silverman ML, Libertino JA. Incomplete renal tumor destruction using radiofrequency interstitial ablation. *J Urol* 2002; 168:2406; discussion 2409–2410.

COMMENTARY

Harrison K. Rhee and John A. Libertino

Lahey Clinic Medical Center, Burlington, Massachusetts, U.S.A.

Several treatments have been challenging open radical nephrectomy, the gold standard treatment for renal cell carcinoma. Open partial nephrectomy has been shown to have similar oncologic results while preserving nephron mass and renal function. Laparoscopic radical nephrectomy has been shown to have less morbidity than open radical nephrectomy and is quickly becoming the treatment of choice for those masses not amenable to partial nephrectomy. Specialized centers have been pushing the forefront of minimally invasive, extirpative surgery with the routine use of laparoscopic partial nephrectomy. Research into nonextirpative, ablative techniques such as cryoablation and radio frequency ablation has given urologists even more treatment options when addressing renal lesions. The ultimate goal of each of these techniques is

to effectively eradicate tumors with maximal oncologic efficacy while minimizing morbidity and mortality. The aforementioned procedures have certain difficulties with each of those tasks, and radiofrequency ablation is no exception.

Avoiding significant open or laparoscopic surgery is the major benefit of radiofrequency ablation. This benefit includes decreased blood loss, lower analgesia requirement, shorter hospital stay, quicker return to normal activities, and preservation of nephron mass when compared with radical nephrectomy. Rare complications such as extension of the coagulation lesion into surrounding organs or thrombosis of major renal vessels have been avoided with selection of small, peripheral, posterior tumors. While the benefits of this therapy may outweigh the need for surgical resection in the patient with significant comorbidities, the majority of patients with renal masses require a procedure with established, long-term cure rates.

Despite the benefits of radiofrequency ablation, treatment efficacy has not been fully established. Technology to evaluate radiofrequency ablation in real time is not currently adequate to determine the true extent of lesions at the time of treatment. Data from several groups has shown that persistent or new enhancement on computed tomography scan after treatment mandate two or more total treatments for primary radiofrequency ablation failures. Also, the use of nonenhancement of the lesion on computed tomography scan after treatment does not fully establish the treatment margins as adequately as histology. Clinical trials where tissue is immediately resected after treatment have shown conflicting results regarding histologic evidence of cell viability. Because treatment effects may not be fully realized on immediate examination, we believe that further data needs to be gathered with treatment and delayed resection for pathologic evaluation. This should be correlated with contrast-enhancement evaluation on computed tomography-scan because the ultimate goal would be to evaluate treatment efficacy by noninvasive means.

Several situations may push radiofrequency ablation up the treatment algorithm. As mentioned, in those patients with comorbidities that preclude surgical resection with open or laparoscopic radical or partial nephrectomy, radiofrequency ablation may be a viable treatment alternative. This group of patients may be the ideal group for radiofrequency ablation therapy although long-term, disease-free follow-up may not be easily evaluated secondary to non-disease-specific mortality. Laparoscopic partial nephrectomy demands excellent skills including the very difficult task of intracorporeal suturing for reconstruction of the collecting system and for ligation of bleeding vessels. Therefore, a potential use of radiofrequency ablation may be as an intraoperative adjunct to this procedure by facilitating hemostasis and decreasing blood loss. radiofrequency ablation treatment of lesions may preclude the need for hemostatic suturing and allow a clean operative field for further closure of the surgical defect.

Further long-term results regarding overall survival, disease-free survival, morbidity, and mortality need to be established across institutions to fully compare this technique to current therapies of surgical resection. As further data regarding the clinical significance of small renal lesions becomes available, the utility of minimally invasive, nonextirpative, ablative therapies such as radio frequency ablation may become more clear. Until these data become available, radiofrequency ablation will remain an investigational modality that should only be offered to those patients who are unable to undergo surgical resection.

LAPAROSCOPIC RADICAL NEPHROURETERECTOMY: TECHNIQUES FOR THE MANAGEMENT OF DISTAL URETER AND BLADDER CUFF

Gary W. Chien, Marcelo A. Orvieto, and Arie L. Shalhav
*Section of Urology, University of Chicago Pritzker School of Medicine,
Chicago, Illinois, U.S.A.*

- | | |
|--|---|
| <ul style="list-style-type: none"> ■ INTRODUCTION ■ TECHNIQUES FOR MANAGEMENT OF DISTAL URETER AND BLADDER CUFF <ul style="list-style-type: none"> GIA Staple Division Following Transurethral Dissection Laparoscopic Pluck Technique Intravesical Laparoscopic Method Transurethral "Intussusception" Technique | <p>Hand-Assisted Techniques</p> <ul style="list-style-type: none"> ■ OPEN MANAGEMENT OF THE DISTAL URETER AND BLADDER CUFF FOLLOWING LAPAROSCOPIC RADICAL NEPHROURETERECTOMY ■ SUMMARY ■ REFERENCES ■ COMMENTARY: John M. Fitzpatrick |
|--|---|

INTRODUCTION

The standard surgical treatment of upper tract urothelial carcinoma is radical nephroureterectomy with complete excision of the ipsilateral bladder cuff. This was proposed by Kimball and Ferris in 1933 (1), after the authors found a high incidence of tumor in the remaining ureter following a radical nephrectomy for upper tract urothelial carcinoma. Some 40 years later, Strong and Pearse in 1976 quantified an average of 30% recurrence rate of urothelial carcinoma in the ureteral stump when incomplete nephroureterectomy was performed (2). Thus, a radical nephroureterectomy with complete excision of the bladder cuff is the standard surgical treatment of upper tract urothelial carcinoma (3,4).

In the open approach, the kidney is removed along with the ureter and its bladder cuff. The surgery can be performed with one large incision to remove the kidney, the ureter, and the bladder cuff. This is achieved through a midline or thoracoabdominal incision. Alternatively, two separate incisions can be made, i.e., a flank or subcostal and a Gibson incision.

Laparoscopic nephroureterectomy is becoming increasingly common as laparoscopic radical nephrectomy has now become the "gold standard" for the treatment of localized renal cell carcinoma (5). The advantages of laparoscopic radical nephrectomy over the open approach can also be applied to the laparoscopic nephroureterectomy. These include less intraoperative blood loss, less postoperative pain, faster recovery, and better cosmesis. However, to date there are few series reported with long-term follow-ups (6).

Although rare case reports of trocar site recurrence have been reported (7), the more crucial issue regarding oncologic control of laparoscopic nephroureterectomy is the management of the distal ureter and the bladder cuff.

As surgeons are attempting to keep the procedure as minimally invasive as possible, multiple techniques have been described.

TECHNIQUES FOR MANAGEMENT OF DISTAL URETER AND BLADDER CUFF

To decrease the morbidity of nephroureterectomy, various endoscopic methods have been described for the management of the distal ureter and the bladder cuff. McDonald et al. (1953) first described the "pluck" technique in which the ipsilateral ureteral orifice was resected via a transurethral approach (8). Once the distal ureter was disconnected from the bladder, the bladder defect was fulgurated. The nephrectomy portion of the

Although rare case reports of trocar site recurrence have been reported, the more crucial issue regarding oncologic control of laparoscopic nephroureterectomy is the management of the distal ureter and the bladder cuff.

surgery was then performed in an open fashion via a flank or subcostal incision, and the disconnected ureter was “plucked” out together with its bladder cuff.

Because the distal ureter, which is resected, is left open, the “pluck” method has been criticized for tumor seeding in the retroperitoneum, which has been documented (9,10).

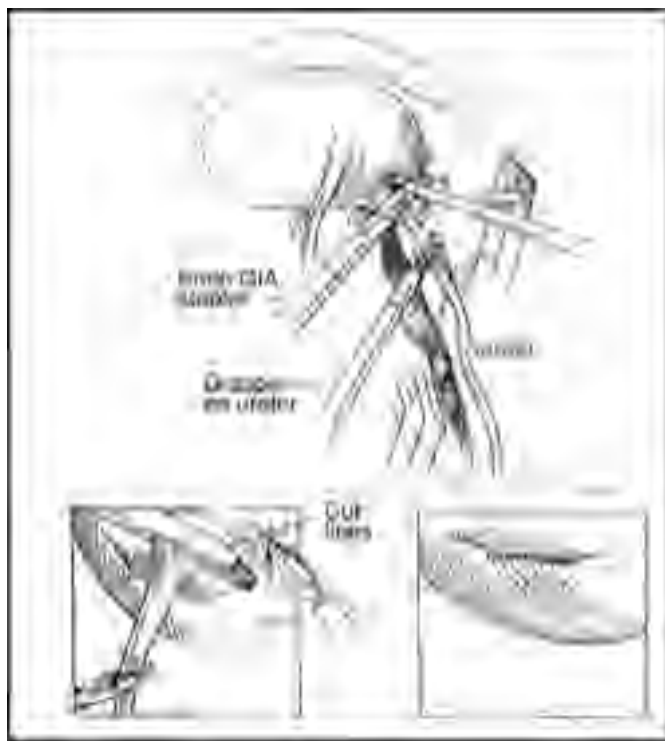
For laparoscopic nephroureterectomy, numerous methods have been described for the management of the distal ureter, all with a goal to achieve a minimally invasive technique while not compromising the oncologic efficacy. These techniques each present with their advantages but also with their shortcomings.

GIA Staple Division Following Transurethral Dissection

In 1991, Clayman et al. reported the first laparoscopic nephroureterectomy (11). For the management of the distal ureter and bladder cuff, the authors described placing a 7 French ureteral catheter (5 mm diameter and 10 cm length) with an occlusion balloon cystoscopically under fluoroscopic guidance. The balloon was inflated with contrast material. Then, the bladder cuff was created transurethrally until 1 cm of ureteral tunnel was developed. The occlusion balloon prevents tumor seeding prior to the laparoscopic nephroureterectomy. The ureter was laparoscopically dissected down to the detrusor muscle. The ureter was retracted cranially and the bladder cuff was divided with a laparoscopic endoscopic gastrointestinal anastomosis (Endo-GIA) stapler (Fig. 1). The bladder was then tested for water-tightness. In a series of 25 patients at a mean follow-up of two years, the Washington University Group reported a 23% recurrence in the bladder and 15% in the retroperitoneum (12). One patient had urine leakage from the stapled line, which resolved with conservative management.

The advantage of this technique is that intraoperative urine extravasation and the theoretical tumor seeding in the retroperitoneum is minimized due to occlusion with a balloon, then closure with a stapler. There are several disadvantages, including the need to perform fluoroscopy, with repositioning of the patient. Also, injury to the contralateral ureter can occur during stapling of the ipsilateral bladder cuff, because it is not visualized in an extravesical approach. Moreover, it is difficult to assess whether an adequate margin of the bladder cuff has been resected in an extravesical approach, and there is a potential of leaving viable urothelial tissue within the staple line. This tissue may not be visible during cystoscopic examination; thus it cannot be evaluated on follow-up. The theoretical risk of developing bladder stones is concerning, although this has not been shown to occur in the pig model (13) or in humans up to seven years (12).

FIGURE 1 ■ Diagram demonstrating the use of Endo-GIA for stapling the bladder cuff. Source: From Ref. 28



Laparoscopic Pluck Technique

The “pluck” method was adopted by Keeley and Tolley (14). The authors performed 25 laparoscopic nephroureterectomy in this fashion with a mean follow-up of 32.9 months (15). Sixteen percent of the patients had died of the disease, and the bladder/retroperitoneal recurrence rates were not reported. As mentioned previously, because the ureteral orifice is not occluded during transurethral resection, the retroperitoneum near the resected orifice may be seeded during the nephrectomy by tumor-laden urine. Furthermore, because the distal ureter is not marked, i.e., with suture or clip, it is difficult to assess whether the entire ureter with its bladder cuff is removed when it is plucked.

Intravesical Laparoscopic Method

Gill et al. described a method using two needlescopic ports inserted suprapubically into the bladder (Fig. 2) (16). The bladder is distended with irrigation. Under cystoscopic visualization, two 5-mm balloon tipped ports are inserted suprapubically into the bladder one fingerbreadth superior to the pubic bone on either side of the midline. A 5-mm Endoloop^{®a} is inserted through the port on the same side as the affected ureter, and the loop is positioned around the ureteral orifice. A 6 French ureteral catheter is then passed retrograde over a glide wire into the targeted renal pelvis. The bladder cuff is resected transurethrally with electrocautery using a Collins knife. The ureteral orifice is tented by a grasper from one of the ports, and an Endoloop is used to cinch down and occlude the ureter via the second port. The distal ureter with its bladder cuff is dissected with the Collins knife, using anterior retraction with a grasper. The bladder cuff is circumferentially detached in a full thickness manner, en bloc with the intramural ureter. Continuous wall suction to both suprapubic ports are used to minimize extraperitoneal irrigant absorption. Once completed, the patient is repositioned, the remaining nephrectomy is then performed laparoscopically via a retroperitoneoscopic approach.

In a series of 42 patients from the Cleveland Clinic with a mean follow-up of 11.1 months, there was a 23% recurrence rate in the bladder and none in the retroperitoneum (17). One patient experienced extraperitoneal fluid extravasation, which resolved with conservative drainage.

The advantage of this technique compared to the pluck procedure is that urine extravasation from the affected kidney is minimized by obstructing the ureter with an endoloop, thus decreasing the risk for tumor seeding. Also, with an anterior retraction using the Endoloop, cystoscopic mobilization of the ureter is performed more extensively, and subsequent plucking of the ureter is facilitated. The disadvantage is that irrigant extravasation may cause possible hyponatremia during a long procedure. Also, the patient must be repositioned intraoperatively, lengthening the total surgical time. This procedure is technically difficult and requires a vast laparoscopic experience.

FIGURE 2 ■ Intravesical method demonstrating two needlescopic ports inserted suprapubically into bladder. The Endoloop is cinched down to occlude the ureter, after the bladder cuff is resected with electrocautery.



^aEthicon, Somerville, NJ.

Transurethral “Intussusception” Technique

A novel technique of managing the distal ureter and bladder cuff during an open radical nephroureterectomy was introduced by Angulo et al. (18). The “intussusception” technique was performed by placing a ureteral stone basket into the ureter of the affected side. A standard open radical nephroureterectomy is performed, and the stone basket is advanced to the proximal ureter with clips just proximal to the basket. The ureter is transected just distal to the clips, and the stone basket is advanced into the retroperitoneum and opened. The ureteral wall tissue is insinuated into the basket, which is placed on gentle traction. The ureter is then intussuscepted in its entirety into the bladder. The ureter is detached from the bladder with a transurethral resectoscope using a Collins knife (Fig. 3) (18).

The authors reported no complications in their series of 21 patients, with a mean follow-up of 44.6 months. Twenty percent of the patients had recurrence in bladder and none in the retroperitoneum (18). However, this procedure can only be used for renal pelvic tumors, as it may lead to seeding if the tumor is in the ureter. Moreover, the “stripping” of ureter may leave residual tissue behind if it is torn. Once torn, it may be difficult to retrieve it in the retroperitoneum. This occurred in 9.5% (2/21) of the patients in the authors’ series. In addition, a large defect is left in the bladder, necessitating prolonged bladder drainage.

Hand-Assisted Techniques

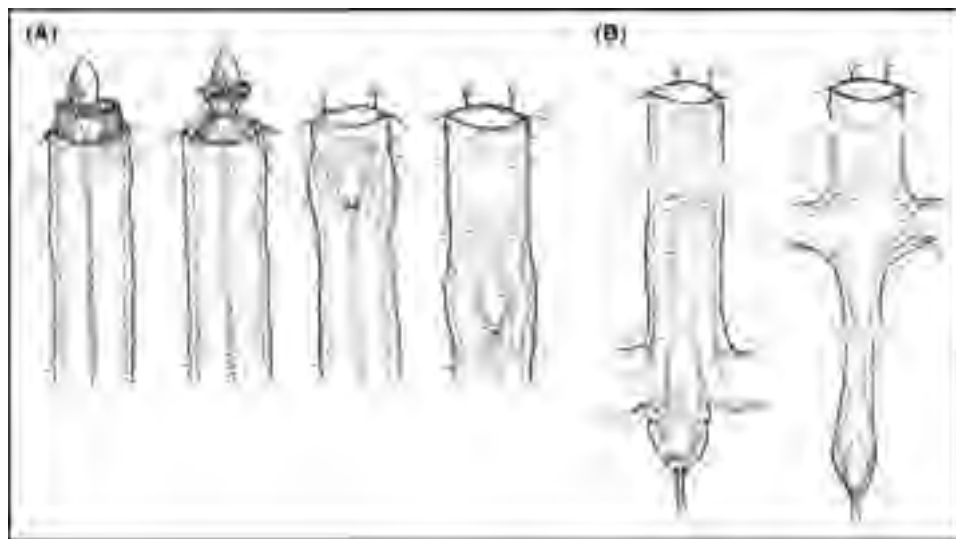
Hand-assisted laparoscopic nephroureterectomy has been advocated by some (19–22), because it provides the surgeon with tactile sensation and an incision adequate for intact specimen removal. Herein, we present two hand-assisted laparoscopic nephroureterectomy techniques.

Intravesical Technique

Gonzalez et al. described making a midline, periumbilical incision, which was used as the hand-assisted port (20). Prior to the dissection of the kidney, two large clips were placed on the proximal ureter to prevent any potential tumor spillage during nephrectomy. For the distal ureter, a suprapubic 10-mm laparoscopic trocar is placed, and a 24-French nephroscope is placed through the trocar. The distal ureter is resected using a Collins knife, with the aid of the surgeon’s hand to elevate the ipsilateral hemitrigone into view. Once the bladder cuff is free, the surgeon’s hand was used to remove the specimen intact (Fig. 4). Neither the suprapubic cystotomy nor the bladder cuff resection site was closed with suture. Foley catheter was removed by day 10 postoperatively.

The advantages with this technique are that because it is hand assisted, only one trocar site is necessary transvesically to resect the bladder cuff. No patient repositioning is necessary for a transurethral procedure. However, because the authors report only one case of this method, the oncologic efficacy of this technique is not evaluated.

FIGURE 3 ■ (A) “Intussusception” technique demonstrating the ureter which is sectioned below the ureteropelvic junction. The tip of the catheter is tied to the proper ureter and later intussuscepted when the catheter is pulled out. (B) The catheter is retracted on a light tension until the ureter is totally everted in a tent fashion. A transurethral resection is then performed around the everted ureteral orifice.



Modified Pluck Technique

Another similar method utilizing a modification of the pluck technique was introduced by Wong and Leveillee (21). The ureter is clipped and dissected distal to the intramural hiatus prior to any kidney dissection. A transperitoneal hand-assisted laparoscopic nephroureterectomy is then performed. Subsequently, by placing the ureter on tension with the surgeon's hand, the remaining ureteral dissection is performed transurethrally with a Collins knife. The complete specimen is then removed en bloc through the hand port. Again, the bladder is not closed, and a cystogram is performed on the seventh postoperative day; if it is normal, the catheter is removed.

The authors recently presented a mean follow-up of 13.2 months on 27 patients (22). Ten patients have had intravesical recurrences (37%) and no retroperitoneal recurrence was noted. The advantage to this approach is that no additional incision is made to resect the distal ureter and the bladder cuff. Further, the authors describe a modified dorsal lithotomy position where the laparoscopic and transurethral surgeries can be performed simultaneously without repositioning (Fig. 5). The theoretical risk of tumor spillage/seeding from the resected ureter is minimized because the distal ureter is clipped prior to any kidney dissection. The disadvantages of this procedure can also be associated with those of the pluck technique. The bladder is left open to heal by secondary intention. Although not mentioned in the authors' description, the simultaneous laparoscopic and transurethral procedures likely presents with technical difficulty during surgery.

Although each one of the above mentioned techniques has its advantages, they all present with their own shortcomings. Technical shortcomings include incomplete resection of the ureteral orifice, tumor spillage, an open bladder left to heal by secondary intention, exposed staples, trapped mucosa within staple lines, leaking trocars, and time-consuming patient repositioning/draping. The most important issue for the management of the distal bladder cuff is its oncologic efficacy.

In a review of the world literature, selected series of laparoscopic nephroureterectomy are outlined in Table 1. The mean follow-up ranged from 11.1 to 32.9 months with the bladder recurrence rate ranging from 10.5% to 50% (12,15,17,19,22,25,26). Although this is comparable to the well-published rates of 21% to 23% in the open series (23,24), more studies with a longer follow-up and a larger number of patients are needed to demonstrate adequate cancer control of the various modalities in distal ureter treatment.

For this and the fact that urothelial carcinoma is an aggressive tumor, we still advocate an open Gibson incision with the standard approach of transvesical bladder cuff resection, following a laparoscopic nephrectomy. Through this incision we remove the intact specimen, including the kidney, ureter, and the bladder cuff.

The most important issue for the management of the distal bladder cuff is its oncologic efficacy.

OPEN MANAGEMENT OF THE DISTAL URETER AND BLADDER CUFF FOLLOWING LAPAROSCOPIC RADICAL NEPHROURETERECTOMY

During the operation, the anesthetized patient is first placed in a modified 45° lateral decubitus position at the chest and 30° at the pelvis with the table flexed at the flank and no kidney rest. The abdomen, genitalia, and the flank are prepped and

FIGURE 4 ■ Surgeon's left hand through hand assist port is used to push hemitrigone upward toward abdominal wall to facilitate bladder cuff resection using the Collins knife.

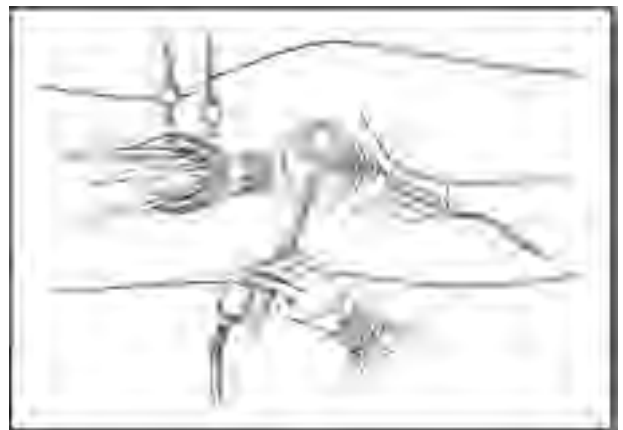

FIGURE 5 ■ Patient in a modified dorsal lithotomy position, allowing simultaneous hand-assisted laparoscopic nephroureterectomy and access to urethra. *Source:* From Ref. 21.



draped in the standard surgical fashion. A urinary catheter is placed on the surgical field prior to the start of surgery. Then, a transperitoneal laparoscopic radical nephrectomy is performed. We believe the transperitoneal, rather than the retroperitoneal access is a superior approach for laparoscopic renal cancer surgery. It allows for a wider space to maneuver, thus allowing for a radical nephrectomy to be performed without violating the Gerota's fascia. Early clipping of the ureter immediately following division of the renal pedicle will prevent tumor cells in the urine from flowing down the ureter.

Once the laparoscopic radical nephrectomy and dissection of the ureter down to the bladder have been performed, the trocars are removed and the pneumoperitoneum released. The operating table is then turned laterally so that the patient is more supine. Of note, the patient is not repositioned. The exposure of the bladder is performed by making a classic 12 to 15 cm Gibson. The space of Retzius is entered extraperitoneally. The anterolateral aspect of the bladder and the intramural ureter are dissected. The bladder is filled with 240 mL of sterile water through the urinary catheter until it is visually distended. An anterior 4-cm longitudinal cystotomy is made, and the bladder is exposed with self-retaining retractors. A 3-0 Vicryl (polyglactin 901) suture is placed through the ureteral orifice and tied. With an anterior retraction on the suture, the ureteral orifice with a 2 cm bladder cuff is encircled and dissected with electrocautery. This is performed in a retrograde fashion until the ureteral dissection connects with the plane of the antegrade, or laparoscopic, dissection of the ureter. Once freed, a 10 cm peritoneotomy is made just superior to the bladder. The kidney is grasped and removed intact with the ureter and its bladder cuff en bloc. The ureteral orifice defect and the anterior cystotomy are closed in two layers, followed by closure of the peritoneotomy. An abdominal extraperitoneal drain is placed, and typically removed on postoperative day 2 when the drain output is less than 50 mL per eight hours. The patients are advanced to regular diet as tolerated, and are discharged home by postoperative day 2 or 3. An indwelling urinary catheter

TABLE 1 ■ Selected Recent Series of Laparoscopic Nephroureterectomy

Authors	No. of patients	Approach	Management of distal ureter	Mean follow-up time (mo)	Recurrence in bladder (%)	Recurrence in retroperitoneum (%)
McNeill et al. (2000) (15)	25	Transperitoneal	Pluck	32.9	N/A (16% died)	N/A
Gill et al. (2000) (17)	42	Retroperitoneal	Transvesical	11.1	23	0
Shalhav et al. (2001) (12)	25	Transperitoneal	Stapled	24	23	15
Jarrett et al. (2001) (27)	24	HAL-NU:20	Open: 20	24.2	16.7	4.2
		Transperitoneal: 4	Stapling: 4			
Stifelman et al. (2001) (25)	11	HAL-NU	Transvesical	13	27.3	N/A
Klinger et al. (2003) (26)	19	Transperitoneal: 14	Open	22	10.5	N/A
		Retroperitoneal: 5				
Villicana et al. (2004) (22)	27	HAL-NU	Pluck	13.2	37	0

Abbreviation: HAL-NU, hand-assisted laparoscopic nephroureterectomy.

is left in the bladder for five days, at which time a cystogram is performed. If the cystogram shows no extravasation, it is removed.

The postoperative follow-up protocol includes cystoscopy and urine sampling for cytology every three months for two years, every six months for two years, and then annually if no bladder tumor recurs. Baseline abdominal computerized tomography is performed two to three months postoperatively. Chest X-ray and abdominal computed tomography with intravenous contrast are performed yearly for five years, then biannually.

SUMMARY

- Various minimally invasive methods in the treatment of the distal ureter and bladder cuff during laparoscopic nephroureterectomy have been described.
- Although each one of the techniques has its advantages, they all present with their own shortcomings.
- The most important issue for the management of the distal bladder cuff is its oncologic efficacy.
- Longer follow-up with larger series of patients is needed to assure their oncologic efficacy. Until then, the open approach to the management of the distal ureter and bladder cuff following a laparoscopic nephrectomy remains the standard of care.

REFERENCES

1. Kimball FN, Ferris HV. Papillomatous tumor of the renal pelvis associated with similar tumors of the ureter and bladder: a review of the literature and report of two cases. *J Urol* 1933; 31:257.
2. Strong DW, Pearse HD. Recurrent urothelial tumors following surgery for transitional cell carcinoma of the upper urinary tract. *Cancer* 1976; 38(5):2173–2183.
3. Murphy DM, Zincke H, Furlow WL. Management of high grade transitional cell cancer of the upper urinary tract. *J Urol* 1981; 125:25–29.
4. Krogh J, Kvist E, Rye B. Transitional cell carcinoma of the upper urinary tract: prognostic variables and post-operative recurrences. *Br J Urol* 1991; 67:32–36.
5. DeKernion J. "Management of Renal Cell Carcinoma" Plenary Session. AUA Annual Meeting, San Francisco, California, May 8–13, 2004.
6. Steinberg JR, Matin SF. Laparoscopic radical nephroureterectomy: dilemma of the distal ureter. *Curr Opin Urol* 2004; 14:61–65.
7. Ong AM, Bhayani SB, Pavlovich CP. Trocar site recurrence after laparoscopic nephroureterectomy. *J Urol* 2003; 170:1301.
8. McDonald HP, Upchurch WE, Sturdevant CE. Nephroureterectomy: a new technique. *J Urol* 1952; 67(6):804–808.
9. Hetherington JW, Ewing R, Philip NH. Modified nephroureterectomy: a risk of tumour implantation. *Br J Urol* 1986; 58:368.
10. Jones DR, Moisey CU. A cautionary tale of the modified "pluck" nephroureterectomy. *Br J Urol* 1993; 71:486.
11. Clayman RV, Kavoussi LR, Figenshau RS, Chandhoke PS, Albala DM. Laparoscopic nephroureterectomy: initial clinical case report. *JLS* 1991; 1(6):343–349.
12. Shalhav AS, Dunn MD, Portis AJ, Elbahnasy AM, McDougall EM, Clayman RV. Laparoscopic nephroureterectomy for upper tract transitional cell cancer: the Washington University experience. *J Urol* 2001; 163:1100–1104.
13. Kerbl K, Chandhoke P, McDougall E, Figenshau RS, Stone AM, Clayman RV. Laparoscopic stapled bladder closure: laboratory and clinical experience. *J Urol* 1993; 149:1437–1440.
14. Keeley FX, Tolley DA. Laparoscopic nephroureterectomy: making management of upper-tract transitional-cell carcinoma entirely minimally invasive. *J Endourol* 1998; 12(2):139–141.
15. McNeill SA, Chrisofos M, Tolley DA. The long-term outcome after laparoscopic nephroureterectomy: a comparison with open nephroureterectomy. *BJU Int* 2000; 86:619–623.
16. Gill IS, Soble JJ, Miller SD, Sung GT. A novel technique for management of the en bloc bladder cuff and distal ureter during laparoscopic nephroureterectomy. *J Urol* 1999; 161:430–434.
17. Gill IS, Sung GT, Hobart MG, et al. Laparoscopic radical nephroureterectomy for upper tract transitional cell carcinoma: the Cleveland Clinic experience. *J Urol* 2000; 163:1513–1522.
18. Angulo JC, Hontoria J, Sanchez-Chapado M. One-incision nephroureterectomy endoscopically assisted by transurethral ureteral stripping. *Urol* 1998; 52:203–207.
19. Landman J, Lev RY, Bhayani S, et al. Comparison of hand assisted and standard laparoscopic radical nephroureterectomy for the management of localized transitional cell carcinoma. *J Urol* 2002; 167:2387–2391.
20. Gonzalez CM, Batler RA, Schoor RA, Hairston JC, Nadler RB. A novel endoscopic approach towards resection of the distal ureter with surrounding bladder cuff during hand assisted laparoscopic nephroureterectomy. *J Urol* 2001; 165:483–485.
21. Wong C, Leveillee RJ. Hand-assisted laparoscopic nephroureterectomy with cystoscopic en bloc excision of the distal ureter and bladder cuff. *J Endourol* 2002; 16(6):329–333.
22. Villicana P, Siddiq FM, Lopez-Pujals A, Bird VG, Leveillee RJ. Hand-assisted laparoscopic nephroureterectomy with simultaneous cystoscopic excision of ureter bladder closure is not neces-

- sary. Abstract presented at the American Urological Association Annual Meeting, San Francisco, California May 8–13, 2004.
23. Hall MC, Womack S, Sagalowsky AI, Carmody T, Erickstad MD, Roehrborn CG. Prognostic factors, recurrence, and survival in transitional cell carcinoma of the upper urinary tract: a 30-year experience in 252 patients. *Urol* 1998; 52:594–601.
 24. Cozad SC, Smalley SR, Austenfeld M, Noble M, Jennings S, Raymond R. Transitional cell carcinoma of the renal pelvis or ureter: patterns of failure. *Urol* 1995; 46:796–800.
 25. Stifelman MD, Hyman MJ, Shichman S, Sosa RE. Hand-assisted laparoscopic nephroureterectomy versus open nephroureterectomy for the treatment of transitional-cell carcinoma of the upper urinary tract. *J Endourol* 2001; 15(4):391–395.
 26. Klinger HC, Lodde M, Pycha A, Remzi M, Janetschek G, Margberger M. Modified laparoscopic nephroureterectomy for treatment of upper urinary tract transitional cell cancer is not associated with an increased risk of tumour recurrence. *Eur Urol* 2003; 44:442–447.
 27. Jarrett TW, Chan DY, Cadeddu J, Kavoussi LR. Laparoscopic nephroureterectomy for the treatment of transitional cell carcinoma of the upper urinary tract. *Urology* 2001; 57:448–453.
 28. Shalhav AL, et al. Laparoscopic nephroureterectomy for upper tract transitional cell cancer: technical aspects. *J Endourol* 1998; 12:345–353.

COMMENTARY

John M. Fitzpatrick

Department of Surgery, University College Dublin, Dublin, Ireland

The minimally invasive treatment of urological disease has advanced considerably in the last 25 years. Those of us who remember open nephrolithotomies being performed on the same kidney for the third or fourth time will have seen the full extent to which invasive surgery has in many areas become a thing of the past. The new dawn of minimally invasive surgery in urology was heralded by the advent of percutaneous nephrolithotomy developed by Wickham, Marberger, and Alken in Europe and Segura and Clayman in the United States. In a relatively short time, this became the standard way of removing stones from the kidney.

However, extracorporeal shock wave lithotripsy was introduced at almost the same time, and with this new, all-encompassing technology, we felt that nothing else was required to treat stones. However, it became clear that the best way of clearing the kidney of large stones was a combination of shock wave lithotripsy and percutaneous nephrolithotomy. In other words, minimally invasive surgery still had a very important role to play.

Laparoscopic surgery was popularized in general surgery and urology at more or less the same time. Clayman and his colleagues developed a technique for nephrectomy and nephroureterectomy, and Gill popularized the techniques of radical nephrectomy and partial nephrectomy. What became clear was that to learn these techniques required intensive training and mentoring. The fact that these techniques have become so widely popular is testament to the skill and patience of these opinion leaders.

The benefit to patients of the laparoscopic approach has been made clear in a large number of publications. The fact that laparoscopic radical nephroureterectomy is, in fact, an endoscopic re-creation of the open procedure makes it easy to understand these advantages. The major limitation, apart from the loss of three-dimensional visualization and of tactile properties, is the use of a phrase that I do not like—the “learning curve.” I believe that most urologists realize that the concept of a learning curve can be avoided by careful tuition and mentoring.

In the future, it is likely that every department will have a section of laparoscopic urology. My belief is that this will continue to grow and that the science will be developed with the improvement of technology. Whether robotic surgery will interfere with this progress remains to be seen. It behooves us all to encourage the development of laparoscopic urology, which is definitely a benefit to our patients.

LAPAROSCOPIC RADICAL NEPHROURETERECTOMY: CURRENT STATUS

Surena F. Matin

Department of Urology, The University of Texas M.D. Anderson Cancer Center, Houston, Texas, U.S.A.

- | | |
|---|---|
| <ul style="list-style-type: none"> ■ INTRODUCTION ■ NEPHRECTOMY ■ THE CURRENT STATUS OF LAPAROSCOPIC RADICAL NEPHROURETERECTOMY, DISTAL URETERECTOMY, AND BLADDER CUFF EXCISION ■ MORBIDITY ASSOCIATED WITH LAPAROSCOPIC RADICAL NEPHROURETERECTOMY ■ ONCOLOGIC EFFICACY | <ul style="list-style-type: none"> ■ ADJUNCTIVE PROCEDURES DURING LAPAROSCOPIC RADICAL NEPHROURETERECTOMY: LYMPHADENECTOMY AND ADRENALECTOMY ■ LOCAL RECURRENCES: PORT SITE AND URETERAL STUMP ■ SUMMARY ■ REFERENCES ■ COMMENTARY: J. deKernion |
|---|---|

INTRODUCTION

Transitional cell carcinoma of the renal pelvis and ureter, or upper tract transitional cell carcinoma, is an uncommon disease for which specific epidemiologic data are not available (1). Tumor stage and grade remain the major prognosticators of recurrence and survival. The upper urinary tract may have patchy involvement by carcinoma in situ, and multifocality is common (2,3). Carcinoma in situ of the upper urinary tract has an incidence of 23% in nephroureterectomy specimens, and the incidence of upper tract transitional cell carcinoma appears to be increasing (4). Of patients with a history of bladder transitional cell carcinoma, 4% to 21% develop upper tract transitional cell carcinoma during 15-year follow-up (5,6). Conversely, approximately 25% to 75% of patients first presenting with upper tract transitional cell carcinoma subsequently develop de novo bladder transitional cell carcinoma (7,8). Patients with a history of transitional cell carcinoma in any location have a high risk of subsequent recurrence in a residual ureteral orifice or retained ureteral stump (8). Endoscopic and laparoscopic techniques have dominated efforts to minimize the morbidity associated with radical removal of the kidney, ureter, and bladder cuff for treatment of upper tract transitional cell carcinoma. Because the first endourologic approach to the distal ureter was proposed in 1952 (9), numerous other minimally invasive approaches to the distal ureter and bladder cuff have been described (10). Clayman et al. reported the first laparoscopic approach to nephroureterectomy in 1991 (11). These initial procedures had long operative times, but patients experienced less perioperative morbidity than those undergoing open nephroureterectomy (12). Approximately 400 patients have been reported as having undergone the procedure via conventional transperitoneal (13–17), conventional retroperitoneal (18–21), hand-assisted transperitoneal (22–25), and hand-assisted retroperitoneal (26,27) approaches with a variety of laparoscopic, endoscopic, and open surgical methods for excision of the distal ureter and bladder cuff. Few publications have reported the long-term results of therapy for upper tract transitional cell carcinoma in a substantial number of patients (2); fewer still have reported the long-term results of laparoscopic radical nephroureterectomy. Most of the literature on laparoscopic radical nephroureterectomy is dominated by small, single-institution series of 25 or fewer patients, with a handful of larger series (14–16,18,23,27). This chapter will review the current status of laparoscopic radical nephroureterectomy, in specific regard to the various approaches to the upper tract and bladder cuff, morbidity, oncologic outcomes, port site, and ureteral stump recurrences.

NEPHRECTOMY

The findings of contemporary single-institution series describing the most clinically significant experience with laparoscopic radical nephroureterectomy are listed in Table 1 and are stratified by type of laparoscopic approach. To date, no prospective randomized

studies comparing conventional and hand-assisted laparoscopic radical nephroureterectomy have been performed. Retrospective studies have found that operative times for the conventional approach are longer than are those for the hand-assisted approach, that blood loss, narcotic use, and hospitalization are equivalent for the two approaches, but that convalescence is longer in those undergoing hand-assisted laparoscopic radical nephroureterectomy (29). Laparoscopic nephrectomy has been found to cost 21% less than open and hand-assisted laparoscopic nephrectomy, a finding that is likely applicable to laparoscopic radical nephroureterectomy (30). A hand-assisted approach for laparoscopic radical nephroureterectomy may be cumbersome because the incision is often too high for adequate distal ureter and bladder dissection or too low for comfortable renal dissection, causing substantial ergonomic discomfort to the surgeon (27).

Various rationales for the use of either the transperitoneal or retroperitoneal approach exist (31). Concerns regarding tumor spillage in the peritoneal cavity with the transperitoneal approach have not been documented in the literature, although this remains a real possibility. Transperitoneal laparoscopy has not been found to result in a significant incidence of postoperative ileus in comparison to retroperitoneal laparoscopy (Table 1). This is possibly because of the minimal bowel manipulation that occurs even with the transperitoneal laparoscopic approach. A randomized prospective trial of laparoscopic transperitoneal versus retroperitoneal radical nephrectomy identified only a faster operative time and easier control of the renal vessels as advantages of the retroperitoneal approach, and no difference in the rates of postoperative ileus (32). The hand-assisted retroperitoneal approach is relatively novel and unlikely to become widely used. Experience with this operation remains limited to a few institutions in Asia. Laparoscopic radical nephroureterectomy has been found to be marginally (6%) more economically efficient than open nephroureterectomy at centers where laparoscopy is routinely performed (33). With the continued decline in operative times and reduced reliance on disposable equipment, the cost of laparoscopic radical nephroureterectomy will continue to decrease.

Differences between laparoscopic approaches to the upper urinary tract during laparoscopic radical nephroureterectomy likely reflect different practice patterns, variable definitions of outcome, small numbers of patients, and the influence of the learning curve rather than clinically relevant differences in technique. In general, the retroperitoneal approach avoids entry into the peritoneal cavity, provides faster access to the renal vessels, and has a shorter operative time. Limited data suggest that hand-assisted laparoscopic radical nephroureterectomy is associated with a shorter learning period and operative time but at the potential cost of a longer convalescence, higher operative expenses, and reduced ergonomic comfort for the surgeon. Overall, recent data demonstrate that laparoscopic radical nephroureterectomy can be feasibly performed, with overall favorable

TABLE 1 ■ Perioperative Results from Large International Series of Laparoscopic Radical Nephroureterectomy, According to Laparoscopic Approach

Author, year (Ref.)	No. of patients	Mean OR time (hr)	Mean EBL (mL)	Mean open conversion rate (%)	Complications (%)		Mean LOS (day)	Mean convalescence (wk)
					Minor	Major		
Conventional transperitoneal								
Keeley, 1998 (13)	22	2.6	—	13.6	27 (overall)		5.5	—
McNeill, 2000 (14)	25	2.7	—	12	16 (overall)		5	—
Shalhav, 2000 (15)	25	7.7	189	0	40	8	3.6	2.8
Jarrett, 2001 (16)	25	5.5	440	4	12	24	4	—
Conventional retroperitoneal								
Gill, 2000 (18)	42	3.7	242	4.8	12 (overall)		2.3	8
Matsui, 2002 (20)	17	4	151	—	12 (overall)		2.7	2
Yoshino, 2003 (21)	23	4.8	304	4.3	8.7 (overall)		—	2.6
Hand-assisted transperitoneal								
Stifelman, 2000 (25)	22	4.5	180	0	4.5 (overall)		4.5	2.7
McGinnis, 2001 (23)	29	6.2	541	—	22 (overall)		5.5	—
Wong, 2002 (24)	14	—	—	—	0 (overall)		2	3
Hand-assisted retroperitoneal								
Uozumi, 2002 (26)	10	4.4	462	0	30	20	—	—
Kawauchi, 2003 (27)	34	3.9	236	3	5.9	5.9	13	3.4

Abbreviations: OR, operating room; EBL, estimated blood loss; LOS, length of hospital stay.

Source: Modified from Ref. 28.

perioperative outcomes, regardless of the type of laparoscopic approach used for the nephrectomy portion of the procedure.

THE CURRENT STATUS OF LAPAROSCOPIC RADICAL NEPHROURETERECTOMY, DISTAL URETERECTOMY, AND BLADDER CUFF EXCISION

A variety of different methods for excising the distal ureter and bladder cuff during conventional and hand-assisted laparoscopic radical nephroureterectomy have been described. The findings of contemporary single-institution series describing the most clinically significant experience with laparoscopic radical nephroureterectomy are listed in Table 2, stratified by type of distal ureter and bladder cuff approach. These methods can generally be classified into five typical approaches as listed in Table 3, although various other modifications have been described in the literature. In 1952, McDonald et al. described the first endoscopic method of distal ureter and bladder cuff excision, which was performed on a patient presenting with extensive tumor in a residual ureter after having already undergone nephrectomy (9). The ureter was disconnected from the bladder by transurethral resection also known as the “pluck” procedure) of the perimeatal bladder and intramural ureter. The open distal end of the ureter was sealed with fulguration, and the remaining detached ureter was then “plucked” through the open incision by traction. This technique and its various modifications have been described in several contemporary series of laparoscopic radical nephroureterectomy (13,14,37,38). Local recurrences after transurethral resection of the ureteral orifice have been reported in several publications (see the section Local Recurrences: Port Site and Ureteral Stump). It is unlikely that fulguration provides a meaningful seal against urinary leakage, and the risk of leaving a discontinuous, isolated segment of ureter in the extraperitoneal space exists. This approach may be useful for patients who have no ureteral or bladder tumors and have undergone pelvic surgery such that an additional lower abdominal incision would add substantial morbidity.

In 1953, McDonald described another endoscopic technique of distal ureterectomy, in which cystoscopic incision of the perimeatal bladder wall is performed and a ureteral catheter is placed. During nephrectomy, the ureter is divided, and the residual segment is tied tightly to the ureteral catheter with a suture. The ligated ureter is stripped, or intussuscepted, through the urethra by traction on the ureteral catheter (39). In 1983, Clayman et al.

TABLE 2 ■ Results of Laparoscopic Radical Nephroureterectomy According to Distal Ureter Approach

Author (Ref.)	No. of patients	Cuff technique complications	Positive margins (%)	Cancer-specific survival rate (%)	Recurrences (%)		LOS (day)	Follow-up (mo)
					Local pelvis	Bladder		
Open								
Klingler (34)	19	0	0	—	0	—	8.1	22.1
Matsui (20)	17	0	—	— ^a	6	29	2.7	8.8
Uozumi (26)	10	0	0	—	—	—	—	—
Laparoscopic stapling								
Yoshino (21)	23	0	—	91.3 ^b	0	17.4	—	19
Jarrett (16) ^c	25	—	4	—	—	—	4	24.2
Shalhav (15)	25	Bladder leak in one patient	—	77	15	23	3.6	24
TURUO								
Kawauchi (27)	34	0	—	88	0	9	13	13.1
Wong (24)	14	—	—	—	—	14.3	2	8
McNeill (14)	25	—	—	83 ^b	—	—	5	33
TUDL								
Matin and Gill (35)	36	Extraperitoneal fluid extravasation in first patient	1	79	0	9	2.3	23
Stifelman (25)	22	0	0	—	—	18.2	4.1	13

Abbreviations: LOS, length of hospital stay; TURUO, transurethral resection of ureteral orifice; TUDL, transurethral detachment and ligation.

^aNo significant difference in disease-specific survival between open and laparoscopic groups ($P = 0.6775$); no exact numbers provided.

^bSurvival calculated from data provided.

^cSurgical data not stratified by approach to distal ureter.

Source: Modified from Ref. 36.

TABLE 3 ■ Indications and Contraindications for Various Approaches to Distal Ureter and Bladder Cuff Excision

Technique	Indications	Contraindications
Transurethral resection	Renal pelvic tumor with difficult pelvic anatomy	Prior pelvic radiation Distal or intramural ureteral tumor CIS of upper urinary tract or nonvisualized lower ureter Active bladder disease
Intussusception	Renal pelvic tumor with difficult pelvic anatomy	Any ureteral tumor Any CIS of bladder or upper tract; or Active bladder disease
Laparoscopic stapling	Renal pelvic, proximal, or mid ureteral tumor	Distal or intramural ureteral tumor; or Perimeatal bladder tumor
Transurethral detachment and ligation (Cleveland Clinic technique)	Renal pelvic, proximal, mid ureteral or distal (not intramural) ureteral tumor	Intramural ureter tumor; or Active bladder disease Avoid active bladder disease
Open transvesical	Any UTCC Distal or intramural ureteral tumor Invasive distal ureteral tumor	
Open extravesical	Renal pelvic, proximal, mid, and distal ureteral tumor Distal ureteral tumor or CIS	Invasive intramural ureteral tumor Untreated perimeatal bladder tumor

Abbreviations: UTCC, upper tract transitional cell carcinoma; CIS, carcinoma in situ.

described 18 patients who underwent this procedure during open nephroureterectomy; 14 of them were followed up for five years with no local recurrences (40). The use of this method is still occasionally reported in contemporary series of laparoscopic radical nephroureterectomy (27).

Laparoscopic stapling of the distal ureter and associated bladder cuff is a newer technique that is performed in conjunction with cystoscopic unroofing and scarification of the ureteral orifice (15,16). Stone encrustation along the staple line has not been a problem on long-term follow-up in the limited number of patients who have undergone the procedure, although the staples may be visible on cystoscopy (15,41). The small segment of tissue within the incorporated staple line on the specimen side is unavailable for pathologic evaluation of margins, whereas at the other end, the same tissue remains viable and a potential source of extravesical recurrence (42). This method has the unique advantage of keeping the urinary tract closed, which may be advantageous for patients with a history of radiation therapy, or other risk factors for prolonged leakage, and for those in whom urine or irrigant extravasation must be avoided (15).

A novel method of en bloc transurethral detachment and ligation was described in 1999 (43). A ureteral catheter is initially threaded through an Endoloop[®] tie^a and into the ureter. The bladder cuff is circumferentially incised, and the intramural ureter is dissected using a Collins knife aided by two suprapubic, transvesically placed 5 mm laparoscopic ports. The endoloop is then used to ligate the ureter against the catheter, preventing spillage from the upper urinary tract into the extravesical space during the subsequent laparoscopic approach. In the initial set of patients, no differences in the rates of bladder, local, or distant recurrence were noted between those undergoing laparoscopic and open nephroureterectomy after 11 months (18). An analysis of 59 cases with two years of follow-up revealed the transurethral detachment and ligation technique to be oncologically feasible, and was associated with significantly fewer positive margins and local recurrences than laparoscopic stapling (35). A variation of the transurethral detachment and ligation technique has also been described in a smaller number of patients undergoing hand-assisted laparoscopic radical nephroureterectomy (44). This method, in general, comes closest to mimicking the classic open approach of distal ureter and bladder cuff resection, but requires a variety of instruments, can be technically challenging, requires patient repositioning, and is contraindicated in patients with active bladder disease.

Open dissection remains one of the most common methods of excising the distal ureter and bladder cuff. Patient repositioning is usually not required, and this one incision is used for simultaneous intact extraction of the en bloc specimen. An open approach may

^aEthicon, Somerville, NJ.

be performed transvesically or extravesically, usually via a low Gibson, modified Pfannenstiel, or lower midline incision. Some surgeons insert a ureteral catheter at the beginning of the procedure to facilitate dissection, but it is usually not necessary. Care must be taken to avoid injury to the contralateral ureteral orifice. Note that, even with open nephroureterectomy, a residual ureteral stump has been reported in up to half of patients (45), with recurrences in the stump occurring in 30% to 64% of these cases (3,46). Thus, an open approach does not guarantee complete ureteral resection or negative margins. In particular, an extravesical approach performed by palpation only risks a residual stump (Fig. 1). Contemporary pathologic practice does not typically identify or confirm the presence of bladder mucosa at the distal margin of resection; it is thus the surgeon's responsibility to visually confirm the presence of this tissue during open, laparoscopic, or endoscopic surgery (Fig. 2).

At our institution, most patients undergo cystoscopy and transurethral resection of tumor within 24 to 48 hours prior to surgery. Those found to have bladder tumors are given intravesical Mitomycin-c (40 mg) in the recovery room immediately following transurethral resection of tumor. Our routine practice includes intact, en bloc specimen extraction with an open bladder technique, usually via a lateral extraperitoneal approach typically used for extravesical dissection. However, the superior vesical artery and the lateral pedicle of the bladder are first fully divided, allowing the entire intramural ureter to be readily dissected down to the ureteral hiatus. The bladder is then opened using Metzenbaum scissors or electrocautery, the bladder cuff is excised under direct vision, and formal bladder repair is performed (Fig. 2). Thus, visual resection of the entire cuff is performed. Such dissection may be difficult in obese patients, in those who have undergone pelvic surgery, and in the setting of prior pelvic radiation. Open transvesical excision by bisecting the bladder is the primary technique used when tumors are located in the intramural ureter, or in cases of suspected invasion of the distal/intramural ureter. The influence of selection factors notwithstanding, caution should be exercised when performing a transurethral resection or stapling procedure for excision of the distal ureter and bladder cuff. However, these alternatives provide the surgeon with operative flexibility and are viable options in individual cases of anatomic difficulty. The number and variety of approaches to excision of the distal ureter and bladder cuff and the absence of a standardized approach attest to the difficulty of integrating surgical anatomy with transitional cell carcinoma biology. Additional indications and contraindications for these techniques based on patient and tumor factors are presented in Table 3.

MORBIDITY ASSOCIATED WITH LAPAROSCOPIC RADICAL NEPHROURETERECTOMY

In comparison to open surgery, minor complications after laparoscopic radical nephroureterectomy have been reported in 6% to 40% of patients and major complications in 6% to 24% of patients (Table 1). Open nephroureterectomy has been associated with a 29% overall complication rate (15,18). Patients undergoing laparoscopic radical nephroureterectomy experience fewer pulmonary complications than those undergoing

FIGURE 1 ■ Retrograde ureterogram after radical open nephroureterectomy showing residual 5-cm ureteral stump.

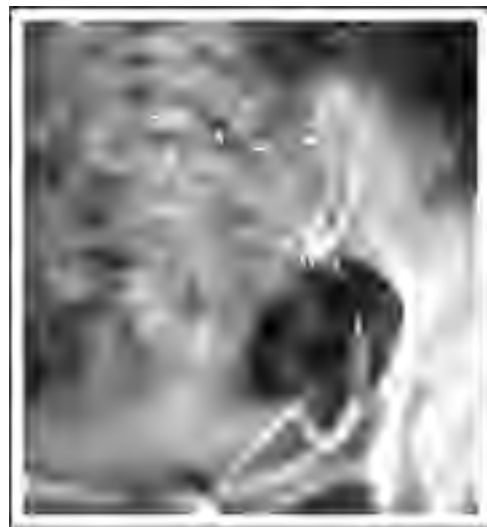
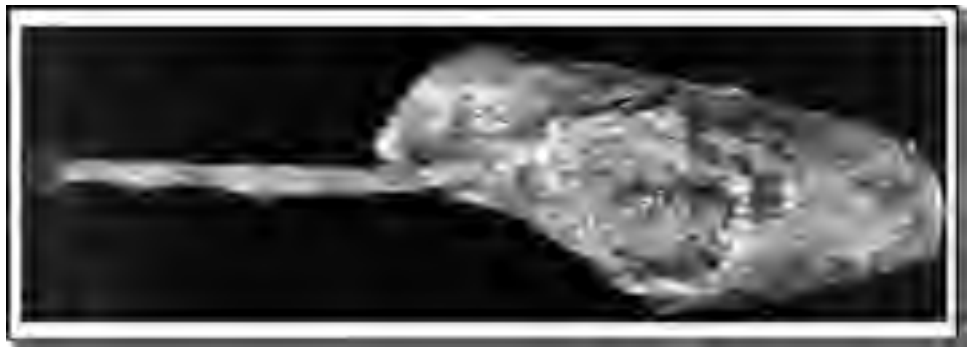
FIGURE 2 ■ Radical nephroureterectomy performed laparoscopically with open bladder cuff resection. The renal pelvis is bisected, showing multiple papillary tumors, and the bladder cuff is evident.



open nephroureterectomy, possibly as a result of reduced splinting, improved ambulation, and reduced narcotic usage postoperatively (13,15). This benefit is highly relevant in this population, which has a high incidence of tobacco use. Perioperative morbidity and mortality rates after laparoscopic or open nephroureterectomy are probably higher than those encountered with other forms of elective surgery, a difference that is likely attributable to the interrelated causative factors of heavy tobacco exposure and advanced age (7,13,14).

ONCOLOGIC EFFICACY

Table 4 lists the histopathologic results of specimens obtained via laparoscopic radical nephroureterectomy from large single-institution published series, representing a total of 198 international patients. Most lesions in these patients (52–94%) were high grade. Most patients with low-stage, low-grade transitional cell carcinoma of the upper urinary tract have favorable long-term outcomes after nephroureterectomy, whereas those with high-stage, high-grade disease have significantly poorer survival rates (2,4). One- and two-year follow-up data thus far show cancer-specific survival rates of 63% to 97% in 154 patients after laparoscopic radical nephroureterectomy compared with 53% to 87% in 156 patients after open nephroureterectomy followed up for 1.5 to 4 years (Table 5). Positive margin rates have not been consistently reported by all institutions but appear to be equivalent for the few studies reporting results of both approaches. Bladder recurrence rates in the open (24–64%) and laparoscopic (9–54%) groups were within expected ranges. Rates of local and distant recurrence were likewise comparable between open (0–24% and 0–23%, respectively) and laparoscopic (0–15% and 0–23%, respectively) groups. All patients who underwent open nephroureterectomy had longer follow-up. This lead-time bias accounts for the perceived higher rates of bladder, local, and distant recurrence in these open cohorts (Table 5). In one of the largest published series of open nephroureterectomy, Hall et al. (2) reported five-year disease-specific survival rates of 100%, 92%, 73%, and 41% in 252 patients with stage Ta/Tis, T1, T2, and T3 disease, respectively (Fig. 3). While most recurrences for this disease tend to occur within the first two years, follow-up for laparoscopic radical nephroureterectomy is limited, not only temporally but also by small patient numbers, and the availability of long-term data will be critically important in unequivocally establishing oncologic efficacy. The data thus far, however, supports its continued selective application.

ADJUNCTIVE PROCEDURES DURING LAPAROSCOPIC RADICAL NEPHROURETERECTOMY: LYMPHADENECTOMY AND ADRENALECTOMY

Up to one-third of patients who undergo nephroureterectomy may be found to have lymph node metastasis (48). No specific data are available to assess the impact of lymphadenectomy for upper tract transitional cell carcinoma during laparoscopic radical nephroureterectomy. However, data from open series and data from the treatment of bladder transitional cell carcinoma, from which some of the natural history of disease can be extrapolated, suggest an important role for lymphadenectomy in these cases. In one respect this role may be only limited to staging. This would strongly influence consideration of follow-up imaging and adjuvant strategies because patients with lymph

TABLE 4 ■ Histopathologic Results from Eight Contemporary International Single-Institution Series of Laparoscopic Radical Nephroureterectomy

	Author, year (Ref.)							
	McNeill, 2000 (14)	Shalhav, 2000 (15)	Jarrett, 2001 (16)	McGinnis, 2001 (23)	Stifelman, 2001 (44)	Matsui, 2002 (20)	Yoshino, 2003 (21)	Matin, 2004 (35)
Number	25	25	25	30	11	17	23	60
PSM (%)	—	— ^a	4	0	0	—	—	8.3
pTis (%)	—	—	—	—	73 (pTa–pT1)	—	17	6.7
PTa (%)	—	—	40	23	—	—	22	30
pT1 (%)	0	—	28	27	—	53 (≤pT1)	22	13
pT2 (%)	4	—	8	10	27 (≥pT2)	12	4	5
pT3 (%)	36	—	20	37	—	23	30	31.7
pT4 (%)	—	—	0	0	—	0	4	8.3
Grade 1	20	28	20	—	18	6	9	13
Grade 2	24	—	32	—	—	35	52	26
Grade 3	52	52 (≥G2)	44	—	82 (≥G2)	59	39	60.7

^aFour patients underwent morcellation; surgical margins were negative in all others.

Source: Modified from Ref. 28.

node metastasis have a high risk of distant failure and are unlikely to be cured by surgery alone. In another respect, lymphadenectomy may have a therapeutic role in a subset of patients, as those found to have minimal nodal disease are potentially curable (49). As lymphadenectomy adds minimal morbidity and because preoperative imaging can miss minimal nodal disease, our routine practice has been to perform a regional lymphadenectomy in patients undergoing laparoscopic radical nephroureterectomy, either en bloc with the renal specimen or as a separate procedure. Involvement of the adrenal by transitional cell carcinoma, on the other hand, is very unusual. If preoperative computed tomography scan shows no abnormalities of the adrenal and if deemed surgically feasible, sparing of the adrenal during laparoscopic radical nephroureterectomy appears reasonable in most cases.

LOCAL RECURRENCES: PORT SITE AND URETERAL STUMP

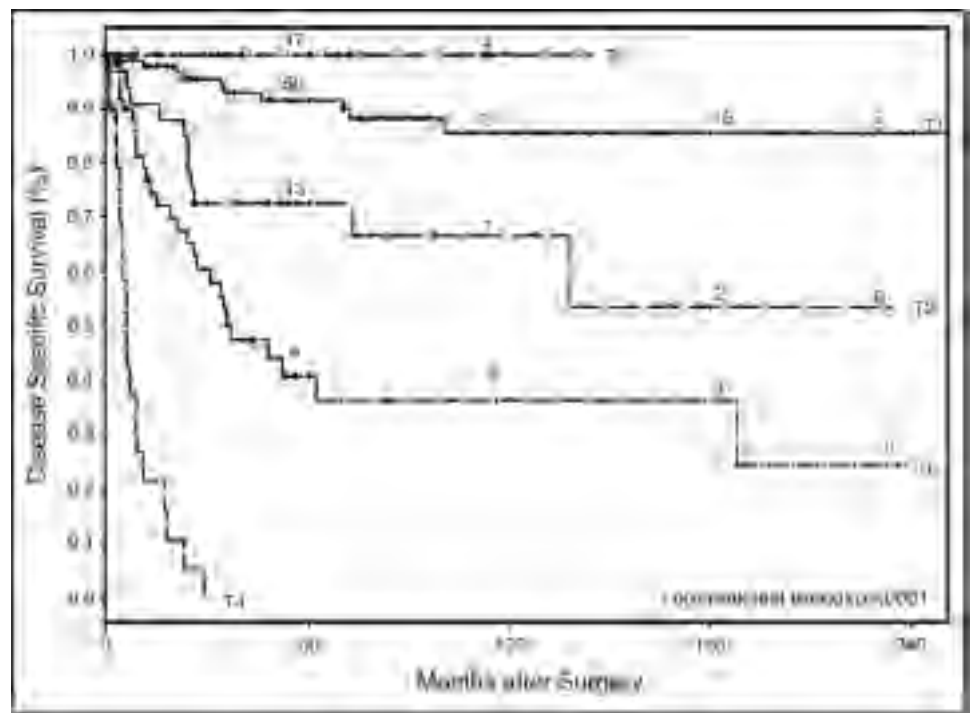
Port site metastasis is a rare event. Biologic, pathophysiologic, and technical factors can facilitate its occurrence, particularly in diseases such as transitional cell carcinoma that

TABLE 5 ■ Results of Studies Comparing Laparoscopic and Open Nephroureterectomy for Upper Urinary Tract Transitional Cell Carcinoma

Author, year (Ref.)	Approach	No. of patients	Positive margins (%)	Recurrences (%)				Cancer-specific survival rate (%)	Mean follow-up (mo)
				Port site	Bladder	Local	Distant		
Gill et al., 2000 (18)	Lap	42	7	0	23	—	8.6	97	11
	Open	35	15	—	37	—	13	87	34
McNeill et al., 2000 (14)	Lap	25	—	0	—	—	—	83 ^a	33
	Open	42	—	—	—	—	—	77 ^a	42
Shalhav et al., 2000 (15)	Lap	25	—	0	23	15	23	77	24
	Open	17	—	—	46	—	23	77	43
Stifelman et al., 2001 (44) ^b	Lap	11	—	0	55	—	9	63 ^a (RFS)	13
	Open	11	9	—	64	—	—	63 ^a (RFS)	17
Matsui et al., 2002 (20)	Lap	17	—	1 ^c	29	6	—	— ^d	8.8
	Open	17	—	—	24	24	12	—	23
Kawauchi et al., 2003 (27)	Lap	34	—	—	9	—	6	88 ^a (RFS)	13.1
	Open	34	—	—	38	—	9	53 ^a (RFS)	48.8

^aSurvival rate calculated from data in the publication.
^bResults calculated from data in the publication.
^cSee Ref. 47 and Table 6.
^dNo significant difference in disease-free survival rate between open and laparoscopic groups ($P = 0.6775$).
Abbreviations: Lap, laparoscopic nephroureterectomy; Open, open nephroureterectomy; RFS, recurrence-free survival.
Source: Modified from Ref. 28.

FIGURE 3 ■ Stage dependent disease-specific survival after nephroureterectomy for upper tract transitional cell carcinoma.
Source: From Ref. 2.



have a propensity for local implantation (50,51). There have been seven reported cases of port site recurrence of transitional cell carcinoma, only three of which occurred during laparoscopic radical nephroureterectomy for suspected transitional cell carcinoma (Table 6) (47,56–58). Of the remaining four, two occurred during laparoscopic pelvic lymph node dissection (59,60), one after laparoscopic biopsy of bladder transitional cell carcinoma (51), and one after nephrectomy for tuberculous kidney harboring unsuspected transitional cell carcinoma (58). The three cases of port site metastasis during laparoscopic radical nephroureterectomy represent less than 1% of all reported cases of laparoscopic radical nephroureterectomy (14–16,18,20,21,24, 26,27,29,44).

Less recognized but possibly more clinically significant is disseminated recurrences after endoscopic excision of the distal ureter and bladder cuff, procedures that predate laparoscopic techniques (52–55). Recurrences after transurethral resection of the ureteral orifice are the most frequently reported. This procedure may be associated with irrigant extravasation, urine spillage from the upper urinary tract into the extraperitoneal space despite attempted “sealing” by fulguration (which is unlikely to provide effective sealing), and residual discontinuous segments of the distal ureter. All these events increase the risk of extravesical tumor recurrence, resulting in iatrogenic T3–4 disease that may not be seen cystoscopically or radiographically (51). At particular risk are patients whose upper urinary tract has not been completely evaluated: an occult distal ureteral tumor or ureteral carcinoma in situ may be present in addition to an obvious renal pelvic tumor. carcinoma in situ of the ureter may not be visible endoscopically or radiographically. Also, patients with distal or intramural ureteral tumors are poor candidates for any form of endoscopic resection of the distal ureter (13,14); in particular, those with possible invasive distal ureteral tumors are best served by an open transvesical technique (Table 3).

The outcome in these cases is often grave, the clinical experience is limited, and the optimal choice of therapy is unclear (Table 6). In the absence of distant disease, wide surgical excision appears to offer a chance at a disease-free interval. Radiation therapy for pelvic extravesical disease occurring at the endoscopic site appears to be uniformly followed by death, although local palliation may be provided. In the presence of additional distant disease, an initial trial of up-front systemic therapy may be most preferable, with additional therapy rendered depending on the response to therapy.

TABLE 6 ■ Recurrences Associated with Laparoscopic and Endoscopic Approaches for Upper Tract Transitional Cell Carcinoma

Author, year (Ref.)	Nephrectomy technique	Bladder cuff technique	Pathologic findings (R: renal pelvis; U: ureter)	Adjuvant therapy	Time to recurrence (mo), symptoms	Recurrence site	Treatment of recurrence	Last follow-up, status
Hetherington et al., 1986 (52)	Open	Transurethral resection	R: P4G3 U: negative	No	5, pain	Pelvic extravesical	Radiation therapy	9 mo, DOD
Hetherington et al., 1986 (52)	Open	Transurethral resection	R: P1G1 U: negative	No	9, hematuria	Pelvic extravesical	Radiation therapy	15 mo, DOD
Abercrombie et al., 1988 (37)	Open	Transurethral resection	R: P1G1 U: unknown	No	3, unknown	Intravesical at endoscopic site	TUR	96 mo, NED
Jones and Moisey, 1993 (53)	Open	Transurethral resection	R: PxG3Nx U: PxG3 R+	No	3, asymptomatic	Bladder base at endoscopic site	Radiation therapy	Unknown
Arango et al., 1997 (54)	Open	Transurethral resection	R: stage 1 U: negative	No	7, pain	Endoscopic site	Salvage cystectomy, chemotherapy	3 mo, DOD
Fernandez Gomez et al., 1998 (55)	Open	Transurethral resection	R: P3G3N0 U: PaG3	No	4, pain	Pelvic extravesical at endoscopic site	Anterior exenteration, chemotherapy	9 mo, NED
Ahmed et al., 1998 (56)	Laparoscopic trans-peritoneal ^a	Transurethral resection	R: P3G3 U: unknown	No	8, pain	Periumbilical port site, retroperitoneum, liver	Chemotherapy	Unknown
Ong et al., 2003 (57)	Laparoscopic retro-peritoneal ^a	Unknown ^b	R: P1G3, +CIS U: unknown	No	12, asymptomatic	Trocar sites, three tumors	Wide excision	NED at 6 mo
Matsui et al., 2004 (47)	Laparoscopic retro-peritoneal ^a	Open	R: P3 squamous cell carcinoma	Chemotherapy	6, asymptomatic	Trocar site	Wide	NED at 6 mo excision

^aNone of the specimens in these cases were morcellated.
^bPresumably open method; ureteral stent placed after ureteroscopy 1 wk previously was seen protruding from the ureter during surgery.
Abbreviations: DOD, died of disease; NED, no evidence of disease; TUR, transurethral resection.

SUMMARY

It is now accepted that laparoscopic radical nephroureterectomy results in less blood loss, less postoperative pain, faster oral intake recovery, shorter hospitalization, and a more rapid recovery than does open nephroureterectomy (14,15,18,20,27,44,61). The morbidity rate after laparoscopic radical nephroureterectomy in this classically high-risk population likewise appears consistently favorable. No studies have shown a clear-cut advantage of the transperitoneal or retroperitoneal approach. Differences in perioperative outcomes between laparoscopic techniques have been investigated in a limited number of retrospective studies (Table 1), but it is still unclear how clinically significant these differences are. Limited published data suggests that hand-assisted laparoscopic radical nephroureterectomy is more expensive but that the cost may be offset by shorter operative times.

The most challenging aspect of laparoscopic radical nephroureterectomy is excision of the distal ureter and bladder cuff. A variety of endoscopic, laparoscopic, and open methods may be used, but they have not been prospectively studied. The high prevalence of multifocal disease and carcinoma in situ in patients with upper tract transitional cell carcinoma should be considered in planning any endourologic or laparoscopic approach to the distal ureter and bladder cuff (4,7,35,62). Caution is warranted with transurethral resection procedures, as these are the most commonly associated with disseminated recurrence. Even with the open approach, complete excision is not guaranteed if performed blindly. Despite the considerable improvement in perioperative outcomes with laparoscopic radical nephroureterectomy, long-term oncologic follow-up data are not yet available, and intermediate-term follow-up data remain limited. The data suggest that survival rates for patients with low-stage, low-grade disease are favorable, whereas patients with high-stage, high-grade disease continue to experience markedly diminished survival, a finding consistent with results found with open surgery. If one were to extrapolate recent bladder cancer treatment data on the optimal use of neoadjuvant therapy for patients at high risk, it would seem that patients with high-grade, high-stage

tumors are probably best served by neoadjuvant chemotherapy, considering especially the significant reduction of renal reserve that occurs following nephrectomy, necessitating lower doses of chemotherapy and thus lower treatment efficacy. The role of laparoscopic radical nephroureterectomy in the postchemotherapy setting is largely uninvestigated, and will probably be evaluated at only a few centers of excellence.

REFERENCES

1. American Cancer Society: Cancer facts and figures 2003. Available at: <http://www.cancer.org>. Accessed February 23, 2004.
2. Hall MC, Womack S, Sagalowsky AI, et al. Prognostic factors, recurrence, and survival in transitional cell carcinoma of the upper urinary tract: a 30-year experience in 252 patients. *Urology* 1998; 52:594.
3. Kakizoe T, Fujita J, Murase T, et al. Transitional cell carcinoma of the bladder in patients with renal pelvic and ureteral cancer. *J Urol* 1980; 124:17.
4. Munoz JJ, Ellison LM. Upper tract urothelial neoplasms: incidence and survival during the last 2 decades. *J Urol* 2000; 164:1523.
5. Herr HW, Cookson MS, Soloway SM. Upper tract tumors in patients with primary bladder cancer followed for 15 years. *J Urol* 1996; 156:1286.
6. Huguet-Perez J, Palou J, Millan-Rodriguez F, et al. Upper tract transitional cell carcinoma following cystectomy for bladder cancer. *Eur Urol* 2001; 40:318.
7. Messing EM. Urothelial tumors of the urinary tract. In: Wein AJ, ed. *Campbell's Urology*. Vol. 4. 7th ed. Philadelphia: Saunders, 2002:2765–2773.
8. Koga F, Nagamatsu H, Ishimaru H, et al. Risk factors for the development of bladder transitional cell carcinoma following surgery for transitional cell carcinoma of the upper urinary tract. *Urol Int* 2001; 67:135.
9. McDonald HP, Upchurch WE, Surdevant CE. Nephroureterectomy: a new technique. *J Urol* 1952; 67:804.
10. Laguna MP, de la Rosette JJ. The endoscopic approach to the distal ureter in nephroureterectomy for upper urinary tract tumor. *J Urol* 2001; 166:2017.
11. Clayman RV, Kavoussi LR, Figenschau RS, et al. Laparoscopic nephroureterectomy: initial clinical case report. *J Laparoendosc Surg* 1991; 1:343.
12. McDougall EM, Clayman RV, Elashry O. Laparoscopic nephroureterectomy for upper tract transitional cell cancer: the Washington University experience. *J Urol* 1995; 154:975.
13. Keeley FX Jr, Tolley DA. Laparoscopic nephroureterectomy: making management of upper-tract transitional-cell carcinoma entirely minimally invasive. *J Endourol* 1998; 12:139.
14. McNeill SA, Chrisofos M, Tolley DA. The long-term outcome after laparoscopic nephroureterectomy: a comparison with open nephroureterectomy. *BJU Int* 2000; 86:619.
15. Shalhav AL, Dunn MD, Portis AJ, et al. Laparoscopic nephroureterectomy for upper tract transitional cell cancer: the Washington University experience. *J Urol* 2000; 163:1100.
16. Jarrett TW, Chan DY, Cadeddu JA, et al. Laparoscopic nephroureterectomy for the treatment of transitional cell carcinoma of the upper urinary tract. *Urology* 2001; 57:448.
17. Chueh SC, Chen J, Hsu WT, et al. Hand assisted laparoscopic bilateral nephroureterectomy in 1 session without repositioning patients is facilitated by alternating inflation cuffs. *J Urol* 2002; 167:44.
18. Gill IS, Sung GT, Hobart MG, et al. Laparoscopic radical nephroureterectomy for upper tract transitional cell carcinoma: the Cleveland Clinic experience. *J Urol* 2000; 164:1513.
19. Goel A, Hemal AK, Gupta NP. Retroperitoneal laparoscopic radical nephrectomy and nephroureterectomy and comparison with open surgery. *World J Urol* 2002; 20:219.
20. Matsui Y, Ohara H, Ichioka K, et al. Retroperitoneoscopy-assisted total nephroureterectomy for upper urinary tract transitional cell carcinoma. *Urology* 2002; 60:1010.
21. Yoshino Y, Ono Y, Hattori R, et al. Retroperitoneoscopic nephroureterectomy for transitional cell carcinoma of the renal pelvis and ureter: Nagoya experience. *Urology* 2003; 61:533.
22. Chen J, Chueh SC, Hsu WT, et al. Modified approach of hand-assisted laparoscopic nephroureterectomy for transitional cell carcinoma of the upper urinary tract. *Urology* 2001; 58:930.
23. McGinnis DE, Trabulsi EJ, Gomella LG, et al. Hand-assisted laparoscopic nephroureterectomy: description of technique. *Tech Urol* 2001; 7:7.
24. Wong C, Leveillee RJ. Hand-assisted laparoscopic nephroureterectomy with cystoscopic en bloc excision of the distal ureter and bladder cuff. *J Endourol* 2002; 16:329.
25. Stifelman MD, Sosa RE, Andrade A, et al. Hand-assisted laparoscopic nephroureterectomy for the treatment of transitional cell carcinoma of the upper urinary tract. *Urology* 2000; 56:741.
26. Uozumi J, Fujiyama C, Meiri H, et al. Hand-assisted retroperitoneoscopic nephroureterectomy for upper urinary-tract urothelial tumors. *J Endourol* 2002; 16:743.
27. Kawauchi A, Fujito A, Ukimura, O, et al. Hand assisted retroperitoneoscopic nephroureterectomy: comparison with the open procedure. *J Urol* 2003; 169:890.
28. Matin, S. F. Laparoscopic radical nephroureterectomy: current status. *BJU Int*, In press, 2004.
29. Landman J, Lev RY, Bhayani, S, et al. Comparison of hand assisted and standard laparoscopic radical nephroureterectomy for the management of localized transitional cell carcinoma. *J Urol* 2002; 167:2387.
30. Baldwin DD, Dunbar JA, Parekh DJ, et al. Single-center comparison of purely laparoscopic, hand-assisted laparoscopic, and open radical nephrectomy in patients at high anesthetic risk. *J Endourol* 2003; 17:161.
31. Matin SF, Gill IS. Laparoscopic radical nephrectomy: retroperitoneal versus transperitoneal approach. *Curr Urol Rep* 2002; 3:164.

32. Desai M, Gill I, Matin S, et al. Retroperitoneal versus transperitoneal laparoscopic radical nephrectomy: prospective randomized comparison. In preparation.
33. Meraney AM, Gill IS. Financial analysis of open versus laparoscopic radical nephrectomy and nephroureterectomy. *J Urol* 2002; 167:1757.
34. Klingler HC, Lodde M, Pycha A, et al. Modified laparoscopic nephroureterectomy for treatment of upper urinary tract transitional cell cancer is not associated with an increased risk of tumour recurrence. *European Urology* 2003; 44:442.
35. Matin S, Gill IS. Recurrence and survival following laparoscopic radical nephroureterectomy with various forms of bladder cuff control. *J Urol*. In press.
36. Steinberg JR, Matin S. F. Laparoscopic radical nephroureterectomy: dilemma of the distal ureter. *Current Opinion in Urology* 2004; 14:61.
37. Abercrombie GF, Eardley I, Payne SR, et al. Modified nephro-ureterectomy. Long-term follow-up with particular reference to subsequent bladder tumours. *Br J Urol* 1988; 61:198.
38. Palou J, Caparros J, Orsola A, et al. Transurethral resection of the intramural ureter as the first step of nephroureterectomy. *J Urol* 1995; 154:43.
39. McDonald DF. Intussusception ureterectomy: method of removal of ureteral stump at time of nephrectomy without additional incision. *Surg Gynecol Obstetr* 1953; 97:565.
40. Clayman RV, Garske GL, Lange PH. Total nephroureterectomy with ureteral intussusception and transurethral ureteral detachment and pull-through. *Urology* 1983; 21:482.
41. Baughman SM, Sexton W, Bishoff JT. Multiple intravesical linear staples identified during surveillance cystoscopy after laparoscopic nephroureterectomy. *Urology* 2003; 62:351.
42. Venkatesh R, Rehman J, Lee D, et al. Cell viability within the stapled tissue following laparoscopic tissue stapling in a porcine model. *J Urol* 2003; 169:150.
43. Gill IS, Soble JJ, Miller SD, et al. A novel technique for management of the en bloc bladder cuff and distal ureter during laparoscopic nephroureterectomy. *J Urol* 1999; 161:430.
44. Stifelman MD, Hyman MJ, Shichman S, et al. Hand-assisted laparoscopic nephroureterectomy versus open nephroureterectomy for the treatment of transitional-cell carcinoma of the upper urinary tract. *J Endourol* 2001; 15:391.
45. Strong DW, Pearse HD, Tank ES, et al. The ureteral stump after nephroureterectomy. *J Urol* 1976; 115:654.
46. Strong DW, Pearse HD. Recurrent urothelial tumors following surgery for transitional cell carcinoma of the upper urinary tract. *Cancer* 1976; 38:2173.
47. Matsui Y, Ohara H, Ichioka K, et al. Abdominal wall metastasis after retroperitoneoscopic assisted total nephroureterectomy for renal pelvic cancer. *J Urol* 2004; 171:793.
48. Komatsu H, Tanabe N, Kubodera S, et al. The role of lymphadenectomy in the treatment of transitional cell carcinoma of the upper urinary tract. *J Urol* 1997; 157:1622.
49. Miyake H, Hara I, Gohji K, et al. The significance of lymphadenectomy in transitional cell carcinoma of the upper urinary tract. *Br J Urol* 1998; 82:494.
50. Pearlstone DB, Feig BW, Mansfield PF. Port site recurrences after laparoscopy for malignant disease. *Semin Surg Oncol* 1999; 16:307.
51. Andersen JR, Steven K. Implantation metastasis after laparoscopic biopsy of bladder cancer. *J Urol* 1995; 153:1047.
52. Hetherington JW, Ewing R, Philp NH. Modified nephroureterectomy: a risk of tumour implantation. *Br J Urol* 1986; 58:368.
53. Jones DR, Moisey CU. A cautionary tale of the modified "pluck" nephroureterectomy. *Br J Urol* 1993; 71:486.
54. Arango O, Bielsa O, Carles J, et al. Massive tumor implantation in the endoscopic resected area in modified nephroureterectomy. *J Urol* 1997; 157:1839.
55. Fernandez Gomez JM, Barmadah SE, Perez Garcia J, et al. Risk of tumor seeding after nephroureterectomy combined with endoscopic resection of the ureteral meatus. *Archivos Espanoles de Urologia* 1998; 51:829.
56. Ahmed I, Shaikh NA, Kapadia CR. Track recurrence of renal pelvic transitional cell carcinoma after laparoscopic nephrectomy. *Br J Urol* 1998; 81:319.
57. Ong AM, Bhayani SB, Pavlovich CP. Trocar site recurrence after laparoscopic nephroureterectomy. *J Urol* 2003; 170:1301.
58. Otani M, Irie S, Tsuji Y. Port site metastasis after laparoscopic nephrectomy: unsuspected transitional cell carcinoma within a tuberculous atrophic kidney. *J Urol* 1999; 162:486.
59. Stolla V, Rossi D, Bladou F, et al. Subcutaneous metastasis after celioscopic lymphadenectomy for vesical urothelial carcinoma. *Eur Urol* 1994; 26:342.
60. Altieri V, Darmiento M, DeSio M, et al. Can laparoscopic lymphadenectomy disseminate bladder cancer? *Acta Urol Ital* 1998; 12:231.
61. Dunn MD, Shalhav AL, McDougall EM, et al. Laparoscopic nephrectomy and nephroureterectomy for renal and upper tract transitional cell cancer. *Semin Laparosc Surg* 2000; 7:200.
62. Yip SK, Tan YH, Cheng WS. Re: Comparison of hand assisted and standard laparoscopic radical nephroureterectomy for the management of localized transitional cell carcinoma. *J Urol* 2003; 169:1474.

COMMENTARY

J. deKernion

Department of Urology, UCLA Medical School, Los Angeles, California, U.S.A.

Laparoscopic nephroureterectomy is a natural outgrowth of the parent procedure laparoscopic radical nephrectomy. Currently, in practice locations that have the necessary expertise, it is the method of choice for confined tumors of the renal pelvis and ureter. The procedure has not received the same warm embrace as laparoscopic nephrectomy, primarily because of the requirement for complete removal of the ureter with a cuff of bladder. Nonetheless, at our institution, barring any specific contraindications, it is the preferred method of managing these kinds of malignancies.

The authors of the chapter discuss the benefits and limitations quite thoroughly. In my view, the primary benefits are the more rapid recovery and return to normal activity and less postoperative pain. We and others have modified the open operation to minimize morbidity. In my experience, unless the tumor is very large and invading outside of the collecting system, blood loss is very minimal, and I doubt that the laparoscopic technique has any significant advantage over the open method in that respect. A small flank incision, combined with a small muscle-splitting or midline suprapubic incision, is often adequate for these tumors. However, even with the modified incisions and modern improved pain management, there is a slightly longer hospitalization and longer interval of disability than one sees with laparoscopic nephroureterectomy.

As nicely discussed in this chapter, the potential "Achilles' heel" of the procedure is the necessity for the removal of the bladder cuff. Many methods have been described. I am very concerned about simply pulling up the bladder and applying a staple line. I have suggested a modification, which is basically the technique I use when performing the open procedure. The ureter is kept under traction and carefully dissected down into the muscle of the bladder until a large funnel-shaped section of the bladder mucosa is free circumferentially. One can then apply a clamp and divide the bladder mucosa with certain removal of not only the ureteral orifice but also of the surrounding bladder mucosa and submucosa. An alternative method is to simply make a small, muscle-splitting, McBurney-type incision for removal of the kidney and dissect the distal ureter through the same incision. Whatever technique is utilized, the laparoscopic nephroureterectomy is only acceptable if it achieves the same cancer control end result as can be achieved by the open technique.

Another issue of concern to me is that of the regional lymph node dissection. For renal pelvic tumors on the left side, this is very straightforward and requires only the removal of the hilar and periaortic lymph nodes. However, on the right side, the lymph node drainage of the kidney is such that the nodes behind the cava and in the interaortocaval region are the ones that would be most likely involved. This poses greater technical difficulty for the laparoscopist. The same concerns exist for tumors in the mid or distal ureters, because the adjacent lymph nodes should be excised. Certainly, node dissection is only important in patients with high-grade or large invasive tumors.

Tumors that seem to invade through the renal pelvis or the ureter still may be managed best by the open technique, which would allow for more extensive dissection and frozen-section monitoring. However, as the laparoscopic surgeons gain more skill, they may indeed be able to manage such patients with equal success as the traditional surgeon.

As for the future, some consensus has to be reached about the most appropriate methods for managing the distal ureter and its insertion into the bladder. Those techniques that assure complete removal of the ureter, including the orifice and a cuff of bladder, should be adopted, and the others should be abandoned. The issue of lymph node dissection must be confronted. The development of more sensitive and accurate radiolabeling imaging techniques may resolve this issue for us. Until then, the laparoscopic surgeon must be willing to perform appropriate staging, regional lymph node dissection for

patients with high-grade tumors. Admittedly, the value of modern adjuvant chemotherapy in these circumstances has not been clearly defined, but knowledge of the lymph node status gives the urologic oncologist valuable information for making that decision. Large, high-grade lesions, which may invade through the ureter or collecting system, should probably still be managed by the open technique, because inadvertent spillage of tumor in these patients can result in local recurrence.

Laparoscopic nephroureterectomy has already largely replaced the open technique in most institutions. It is the method of choice for patients in whom there is no contraindication, and who harbor tumors that are amenable to the laparoscopic approach.

KIDNEY CANCER SPECIMEN EXTRACTION: INTRACORPOREAL MORCELLATION

Maxwell V. Meng

*Department of Urology and UCSF Comprehensive Cancer Center,
University of California School of Medicine, San Francisco, California, U.S.A.*

- | | |
|---|---|
| <ul style="list-style-type: none"> ■ INTRODUCTION ■ BACKGROUND ■ DESCRIPTION OF METHOD <ul style="list-style-type: none"> Entrapment Devices Introduction of LapSac® Opening Bag and Specimen Entrapment Bag Exteriorization and Draping Specimen Morcellation | <ul style="list-style-type: none"> ■ OUTCOMES OF MORCELLATION <ul style="list-style-type: none"> Cancer Outcomes Pain and Convalescence ■ PATHOLOGIC CONSIDERATIONS <ul style="list-style-type: none"> Diagnosis Tumor Staging ■ SUMMARY ■ REFERENCES |
|---|---|

INTRODUCTION

The laparoscopic approach to the removal of solid organs has evolved over the past decade. Within the genitourinary system, the most significant impact has been for upper urinary tract tumors, and currently laparoscopic radical nephrectomy and nephroureterectomy are well accepted for renal and urothelial malignancies, respectively. Recent data from multiple centers have demonstrated both the safety of the procedures and excellent long-term cancer outcomes (1–3).

Despite the increased application of the minimally invasive approach and excellent descriptions of the various surgical techniques, debate persists regarding the optimal method of specimen retrieval. Some perform intact specimen removal from an extended port site, lower abdominal incision, or the vagina (4–6); others remove the kidney piecemeal after intracorporeal fragmentation within an impermeable bag (7,8).

BACKGROUND

The minimally invasive approach was initiated for the diagnosis and management of pelvic conditions, and primarily developed and propagated by gynecologic surgeons. In parallel fashion, the early considerations for specimen handling and extraction were within the realm of the gynecologists. Issues of specimen removal were relevant for both laparoscopy and transvaginal surgery in the removal of the entire uterus or after myomectomy for fibroids.

Descriptions of piecemeal removal of the uterus, using a minimally invasive technique, date back to the late 1800s. These methods of uterine removal involved the bivalving, intramyometrial coring, or wedge morcellation of the uterus through the transvaginal route (9–11). Subsequently, laparoscopy was employed to either facilitate the transvaginal operation or completely perform the hysterectomy or myomectomy (12). The specimen was typically quite large and therefore required fragmentation to preserve the benefits of improved cosmesis and shorter convalescent time. Typically, the tissue was cut or fragmented within the peritoneal cavity and the pieces removed through a trocar or a minilaparotomy incision. Specialized laparoscopic instruments were developed to facilitate the tissue retrieval, such as a manual tissue punch with the instrument shaft containing the cored fragments. The instrument has been modified with motorization of the cylindrical blade (13). The currently available commercial morcellators, designed for gynecologic applications, include the manual serrated edged macro-morcellator^a, Moto-Drive serrated edged macro-morcellator, and electro-mechanical Steiner morcellator.^b Nevertheless, the methods remain tedious

^aWISAP, München, Germany.

^bKarl Storz, Tuttlingen, Germany.

and time-consuming; moreover, it is important to note that the application pertained solely to extirpative laparoscopy for benign uterine diseases and morcellation was performed without specimen isolation. Thus, issues of tumor dissemination have been secondary in the removal of uterine tissue.

Several principles and lessons emerge from the existing experience. First, little data address the application of laparoscopy to the removal of solid organs harboring tumor. The majority of minimally invasive procedures involved either the uterus or spleen, where malignant diseases were excluded. In most cases, simple morcellation without an entrapment sac was performed. Second, previous studies raise significant concerns regarding cellular seeding or spillage. Cases of endometriosis and retained tissue fragments, as well as splenosis, have been reported after intraperitoneal morcellation of the uterus and spleen, respectively (14–16). In addition, dissemination of uterine cancer has been reported after morcellation of a specimen with unsuspected adenocarcinoma (17). Third, one must be cautious and adhere to basic oncologic principles. Although laparoscopic hysterectomy is increasingly applied for lower stage endometrial, cervical, and ovarian carcinoma, additional studies are needed to confirm the efficacy and appropriateness. However, what is clear is that essential elements cannot be overlooked, including lymphadenectomy and careful pathologic examination of the specimen. Thus, laparoscopic hysterectomy for endometrial cancer entails intact specimen retrieval through the vagina and accurate staging, impacting subsequent therapy. The role of specimen morcellation for laparoscopic nephrectomy remains to be completely evaluated. Fourth, adjacent structures must be protected and iatrogenic injury considered during the morcellation process. Injuries have been reported to vasculature, bladder, ureter, and bowel during both manual and electrical morcellation of the uterus.

DESCRIPTION OF METHOD

Over the past decade, the operative techniques of laparoscopic nephrectomy and nephroureterectomy have evolved, with reductions in operative time and morbidity. This has been facilitated by advances in instrumentation as well as surgeon experience. However, the methods of specimen morcellation and extraction have changed very little and are described in the following sections.

Entrapment Devices

Two primary devices are commercially available for containing the kidney specimen—the LapSac^{®c} and EndoCatch Gold^{®d}. The LapSac is available in several sizes, summarized in Table 1. The bag is constructed of two layers, an outer nylon and an inner polyurethane coating, with a polypropylene drawstring. In addition, integral tabs are located on opposite sides of the bag. The LapSac is supplied sterile and intended for one-time use only. The disposable EndoCatch system consists of a pouch contained within a shaft, 11.5 inch in length. The mouth of the pouch is 2.5 inch wide, attached to a continuous ring to facilitate opening, and 6 in. in length. The device is available with shaft diameters of both 10 and 15 mm, with a larger bag.

Both devices are currently used to entrap renal specimens; the use of other, homemade tools (e.g., gloves and sealable bags) has been reported but may only have the benefit of reduced costs and is untested. Advantages of the EndoCatch include the ease of introduction through a trocar, and the deployment mechanism and ring to open the mouth and keep it open. The choice of device for entrapment during intact specimen removal is a matter of surgeon preference. However, to date, morcellation within the EndoCatch cannot be advocated, and we recommend using the LapSac for this purpose.

In our experience, as well as that of others, the dual layer construction of the LapSac is more resistant to perforations. While the EndoCatch pouch is slightly distensible and susceptible to tearing, the LapSac material is more rigid. The manufacturers of the EndoCatch report that the material is impervious to “infectious cells of 0.027 microns in diameter,” but the permeability to cancer cells is unknown (18). Urban et al. have examined this issue for the LapSac. After high-speed electrical tissue morcellation of a porcine kidney, a total of 20 apparently intact LapSacs were tested for permeability to bovine serum albumin, indigo carmine, or murine bladder tumor cells (19). In all tests,

TABLE 1 ■ LapSac[®] Specifications

Dimensions (inches)	Volume (mL)
2 × 5	50
4 × 6	200
5 × 8	750
8 × 10	1500

To date, morcellation within the EndoCatch[®] cannot be advocated, and we recommend using the LapSac[®] for this purpose.

^cCook Urological, Spencer, IN.
^dU.S. Surgical, Corp., Norwalk, CT.

there was no increase in dialysis of substance through the bag over time, up to 18 hours. In one case, a single tumor cell was noted on the hemocytometer at both one and three hours, and was thought to represent contamination given the lack of increasing numbers of cells over time as would be expected from ongoing leakage via a perforation.

Introduction of LapSac®

The LapSac is packaged as a flattened sheet and an introducer is required to aid in placing the bag intracorporeally (Fig. 1). The introducer is a stainless steel instrument with two prongs (25.5cm) and an aluminum handle. One prong is introduced into the LapSac, opposite the side where the drawstring exits. Then, the bag is tightly rolled around the introducer to create a small-diameter cylinder. The entire unit of bag and introducer is introduced into the abdomen through the largest trocar, preferably 11 or 12mm, after the specimen is placed lower in the abdomen. The bag is grasped with atraumatic forceps and slid off the introducer, aided by an in-and-out pushing motion of the introducer. Once the bag and string are entirely within the body, it is unrolled in the upper abdomen on either the spleen or liver for the left and right side, respectively.

Opening Bag and Specimen Entrapment

The mouth of the bag is opened using a grasper on each of the tabs (i.e., anterior and posterior), and the specimen is placed into the bag. Some advocate the placement of an additional port to facilitate triangulation of the mouth. However, we routinely perform transperitoneal laparoscopic radical nephrectomy using four ports, and are able to entrap the kidney using a total of three instruments. Although this can be a challenging task, coordination between the surgeon and the assistant can reduce the time to under a minute or two.

Maneuvers to aid specimen manipulation, particularly with larger masses, include placing the patient in the Trendelenberg position, obtaining a firm grasp on Gerota's fascia distant from the tumor, and dragging the specimen as far into the bag as possible prior to releasing the forceps; then, the remainder of the specimen can be maneuvered by pushing with the grasper. In addition, we utilize the largest LapSac in nearly all situations.

Several groups have reported techniques to simplify specimen entrapment using the LapSac. Sundaram et al. described threading a hydrophilic guidewire through the holes surrounding the mouth of the bag, alongside the existing drawstring (20). After intracorporeal introduction, the elasticity of the wire helps open the mouth of the bag while the rigidity eases positioning. Pautler et al. constructed a reusable instrument, similar to the EndoCatch, to which the LapSac is attached using a Prolene suture threaded through the drawstring-holes (21). The bag is rolled around the instrument, inserted through a port, and deployed within the body, opening the ring (15 cm diameter) along with the mouth of the bag. Similarly, User and Nadler adapted the EndoCatch II device for the LapSac (22). After removal of the original sack from a 15 mm instrument, the large LapSac (8 × 10 in.) is fixed circumferentially to the ring with silk sutures, and the drawstring is tied to the deployment suture on the EndoCatch. The LapSac is then tightly rolled around the closed ring and drawn into the shaft, aided by lubrication; the preparation time was reported to be 10 to 15 minutes. The modified device is introduced directly through the skin at the site of the largest port and opened, simultaneously expanding the flexible ring and mouth of the LapSac. Retraction of the plunger pulls the drawstring, closing the bag, and the silk sutures are either broken or cut to allow bag closure.

Bag Exteriorization and Draping

The drawstring and then the edges of the LapSac are withdrawn through the skin. If desired, the skin as well as the underlying fascia can be incised to increase access to the specimen within the bag. Expansion to 2–3 cm permits easier morcellation and extraction of larger fragments; however, the port site then necessitates closure. We meticulously drape around the exteriorized bag, minimizing skin exposure and potentially reducing the likelihood of tumor seeding. The skin is covered using polyethylene film^e and a second layer of surgical towels is clipped around the LapSac. Several surgical clamps are securely fixed to the edges of the bag to provide upward traction.

^e3M Health Care, St. Paul, MN.

Principles during the morcellation process:

- CO₂ insufflation is continued to maintain pneumoperitoneum, increasing the intra-abdominal space and distance of the specimen/bag from adjacent structures. This may help prevent injury to nearby organs and vessels.
- Morcellation should be carried out under direct laparoscopic vision.
- After complete specimen removal, the instruments used for morcellation are isolated, the drapes around the port are removed, and surgical gowns and gloves are changed prior to fascia/skin closure.

None of the currently available devices to facilitate morcellation is ideal and all should be used cautiously in clinical situations.

Specimen Morcellation

A number of methods exist to fragment the specimen within the LapSac. After completion, we examine the tissue fragments and attempt to separate gross tumor from normal renal parenchyma and perinephric fat. Finally, we inspect the bag for unsuspected perforation.

We routinely perform manual morcellation using a ringed forceps, where there are no sharp edges or teeth within the jaws. It is introduced through the externalized LapSac mouth and repeatedly applied to the specimen, yielding small fragments. Others have utilized Kelly clamps, Krause forceps, or placental clamps. We prefer avoiding instruments with narrow or pointed tips, which may inadvertently damage or perforate the bag. During manual morcellation, we maintain upward traction on the LapSac to fix the specimen close to the abdominal wall as well as to minimize folds of the material, which may be caught within the morcellating instrument. In addition, we prevent fluid produced during the process from spilling outside the bag.

Manual morcellation can be tedious and time consuming. In an early series, the reported median time required for kidney entrapment and morcellation was 42 and 53 minutes, respectively (8). Thus, alternative methods and equipment have been tested. Initially, a high-speed electrical laparoscopic morcellator was commonly used, but is currently unavailable. The device consisted of a recessed blade that cut tissue directly in contact with the tip, and fragments were evacuated via suction attached to the handle. Other similar instruments have been adapted. The Steiner morcellator was described in 1993 for the rapid laparoscopic removal of tissues from the abdomen (13). The cylindrical instrument consists of (i) a coring knife at the end that is (ii) rotated by an electrical microengine. Tissue is brought into contact with the exposed cutting tip using a grasper through the center of the instrument. The electrical prostate morcellator (VersaCut^{TM f}) has been applied to renal specimens. The instrument is designed for intravesical morcellation of prostatic tissue after laser enucleation, with an exposed side-cutting blade. Without a fluid-filled environment, the shaft rapidly overheats and ceases to function.

Landman et al. compared the high-speed electrical laparoscopic to the Steiner and prostate morcellators on porcine kidneys in an ex vivo model, using both the LapSac and EndoCatch and various media (i.e., fluid, no fluid, CO₂) (23). The Steiner morcellator was most rapid and yielded the largest mean fragment size (2.97 g). The single case of bag perforation occurred with the high-speed electrical laparoscopic in the neck of the LapSac, and was thought to be due to thermal damage. Integrity of the EndoCatch was apparently maintained with both the Steiner and prostate morcellators, as assessed by permeability to dilute indigo carmine. Although the environment did not affect performance of the high-speed electrical laparoscopic, Parekh et al. suggested that the safety of the Steiner device was increased by morcellation within a fluid-filled LapSac (24).

More recently, Cai et al. morcellated porcine kidneys using the prostate morcellator (25). Introduction and internal visualization using a nephroscope increased morcellation time (86.9 minutes) but reduced LapSac perforation (10%) compared with direct insertion of the device and external (laparoscopic) visualization (47.1 minutes and 0.015 g fragments). Manual morcellation with a ring forceps was most rapid (15.1 minutes), resulted in larger fragments (1.36 g), and did not damage the bag. Thus, manual morcellation was superior to the electrical prostate morcellator in all aspects.

Interest has developed in the use of water jet technology to aid laparoscopic operations, primarily partial nephrectomy. The device uses high-pressure fluid flow to cut the parenchyma of organs, with preservation of vascular structures. Due to limitations of all electrical morcellators, Varkarakis et al. designed a device to apply a high-pressure (1200–1500 psi) saline stream for specimen ablation and removal (26). In a porcine model, advantages of water jet over manual morcellation included shorter time (5.65 minutes vs. 11.91 minutes) and reduced time per gram of tissue removed (1.42 sec/g vs. 2.98 sec/g). Renal parenchyma and fat were easily fragmented, and collagenous tissue was subsequently removed manually. However, evidence of microscopic perforation of the LapSac was present in 80% of the water jet group. In addition, pathologic evaluation, including cytology, was impossible with the foamy product of water jet morcellation.

None of the currently available devices to facilitate morcellation is ideal and all should be used cautiously in clinical situations. Even with the use of the LapSac and

^fLumenis, Santa Clara, CA.

direct observation of morcellation, small perforations occur frequently; the neck of the bags can also be damaged from the heat produced from rapidly rotating shafts. Thus, we continue to manually morcellate specimens when indicated. Landman et al. describe a modified method of manual morcellation using the EndoCatch sack, preferred because of the deployment ring (27). Through a 3 cm incision, manual morcellation was performed with direct observation of the specimen, and only visible portions of the kidney were grasped. There was no case of bag perforation and mean morcellation time in 12 patients was 11 minutes. This technique appears safe and rapid, and we also increase the incision length to allow “finger fragmentation” and removal of larger pieces. However, the benefit of easier specimen entrapment must be weighed against weaker bag material.

OUTCOMES OF MORCELLATION

Morcellation avoids the need for a larger incision and may maximize the minimally invasive approach. Improved cosmesis is a clear advantage of specimen fragmentation and piecemeal removal. Another potential benefit is the reduction of incisional hernias. Elashry et al. observed postoperative hernias in 17% of patients after intact kidney removal (28). Examination of the literature on laparoscopic donor nephrectomy and hand-assisted nephrectomy reveals that the incidence ranges from 0.6% to 5%, while port site hernia is nearly absent if one uses nonbladed trocars (29–31). However, theoretical limitations are associated with the process and other morbidity benefits remain to be proven.

Cancer Outcomes

A major concern of morcellation is cancer recurrence and port site metastasis. Recent data do not suggest that specimen morcellation for renal cell carcinoma compromises oncologic efficacy. Several centers performing laparoscopic radical nephrectomy combined with piecemeal specimen retrieval have reported excellent long-term outcomes, comparable to open radical nephrectomy (Table 2) (1,2,32,33). The process of morcellation, when performed appropriately, after laparoscopic nephrectomy improved outcome.

Three cases of port site metastasis have been documented after laparoscopic nephrectomy and specimen morcellation for renal carcinoma (Table 3) (33–35). In two cases, tumor (high grade, advanced stage) and patient (cirrhosis and ascites) characteristics likely contributed to the situation. In the other case, no risk factor or explanation is available and the potential etiology may have been unrecognized bag perforation during morcellation. There are no case reports of port site recurrence after laparoscopic radical nephrectomy and intact specimen retrieval, although the omission of a bag has been associated with port site recurrence after laparoscopic surgery for urothelial carcinoma and prostate cancer (36).

TABLE 2 ■ Oncologic Outcome After Laparoscopic Radical Nephrectomy and Specimen Morcellation

Author	N	Size (cm)	Follow-up (mo)	Cancer-specific survival (5 yr)
Portis et al. (2)	64	4.3	54 (median)	98%
Chan et al. (1)	67	5.1	44 (mean)	95%
Ono et al. (32)	85	3.1	29 (median)	95%
Fentie et al. (7,33)	57	4.5	33 (mean)	95% ^a

^aNot 5-yr actuarial survival.

TABLE 3 ■ Port Site Recurrence After Laparoscopic Nephrectomy and Specimen Morcellation for Renal Cell Carcinoma

Author	Stage/grade	Time to recurrence (mo)	Risk factor	Outcome
Fentie et al. (33)	T3N0/grade 4	25	Tumor features	Alive (35 mo)
Castilho et al. (34)	T1N0/grade 2	5	Cirrhosis/ascites	Dead (8 mo)
Landman and Clayman (35)	T1N0/grade 2	12	—	—

Ultimately, the role of specimen fragmentation in tumor seeding at the port site remains controversial and requires further investigation.

Ultimately, the role of specimen fragmentation in tumor seeding at the port site remains controversial and requires further investigation. Morcellation should be performed meticulously and cautiously, and the balance of risks and benefits should be discussed with the patient prior to the operation.

Pain and Convalescence

It was previously thought that patients undergoing specimen morcellation had reduced pain and more rapid recovery compared to intact removal, and the early experience confirmed this assumption (8). In a cohort of patients undergoing laparoscopic cytoreductive nephrectomy prior to immunotherapy, the group who had the specimen morcellated had reduced postoperative narcotic use, shorter duration of hospitalization, and earlier time to interleukin-2 administration.

Subsequent comparisons have not demonstrated a significant difference between intact and morcellated kidney retrieval. The technique of the group from Nagoya, Japan has evolved from transperitoneal laparoscopy with intact extraction to retroperitoneoscopy to the current transperitoneal approach with fractionation. A retrospective analysis suggested that pain and convalescence were similar in the intact (29 mg morphine equivalent and 22.7 days) and fractionated (29 mg and 23.3 days) groups (37). Although it is difficult to compare data between various centers, the reported outcomes of intact specimen removal after retroperitoneal nephrectomy from the Cleveland Clinic compare favorably to all morcellation series, with low analgesic requirements (22 mg morphine equivalent), hospitalization (1.6 days), and convalescent time (4.2 weeks) (3). The mean incision size was 6.7 cm and morbidity was minimized using a muscle-splitting technique.

Dunn et al. also retrospectively reviewed patients undergoing laparoscopic radical nephrectomy and nonrandomized selection of intact or morcellated retrieval (38). Intact retrieval ($n = 21$) was comparable to morcellation ($n = 39$) in nearly all parameters measured, including hours to ambulation and oral intake, analgesic use, duration of hospitalization, and time to convalescence. The only significant difference was longer operative time in the intact group, likely reflecting the learning curve of laparoscopic nephrectomy because most intact removals were performed early in the series.

Gettman et al. prospectively examined the differences between retrieval methods in 12 patients undergoing transperitoneal laparoscopic nephrectomy (39). The two groups were similar with respect to pain and activity scores during the early postoperative period (1–14 days), and time to return to normal activity was not significantly different. The primary difference observed was the incision length (7.6 cm vs. 1.2 cm, $p < 0.05$). A larger prospective study was reported by Hernandez et al. (40). Although incision length was again shorter in the morcellated group (1.2 cm vs. 7.1 cm intact, $p < 0.001$), no differences in operative time, narcotic requirement, and length of hospital stay were noted. Thus, it is likely that the exact method of specimen removal after laparoscopic nephrectomy has little impact on early postoperative morbidity and that both methods are clearly superior to open radical nephrectomy as measured by subjective and objective parameters.

Thus, it is likely that the exact method of specimen removal after laparoscopic nephrectomy has little impact on early postoperative morbidity and that both methods are clearly superior to open radical nephrectomy as measured by subjective and objective parameters.

PATHOLOGIC CONSIDERATIONS

The inability to perform traditional pathological examination of the morcellated renal specimen has been used to support intact specimen removal (Fig. 2). Several aspects and limitations deserve consideration, including establishing a histologic diagnosis, assessment of surgical margins, and determination of tumor stage.

Diagnosis

Laparoscopic radical nephrectomy is frequently indicated for solid renal masses and the suspicion of malignancy. In these cases, the identification of renal carcinoma, or absence of tumor, is critical for accurate diagnosis, patient counseling and follow-up, and determination of prognosis. In over 160 cases of laparoscopic radical nephrectomy with morcellation for suspected cancer at the University of California San Francisco, a histologic diagnosis could not be made in a single patient. In this case, preoperative imaging revealed a solid, enhancing 3 cm mass. After morcellation and retrieval, no tissue fragments were grossly suspicious for tumor and eventually complete processing and examination of the entire morcellated specimen did not show any renal pathology. Others have also observed the occasional inability to confirm a preoperatively




FIGURE 1 ■ LapSac® (5 × 8 inches) and an example of laparoscopic introducer.[§]

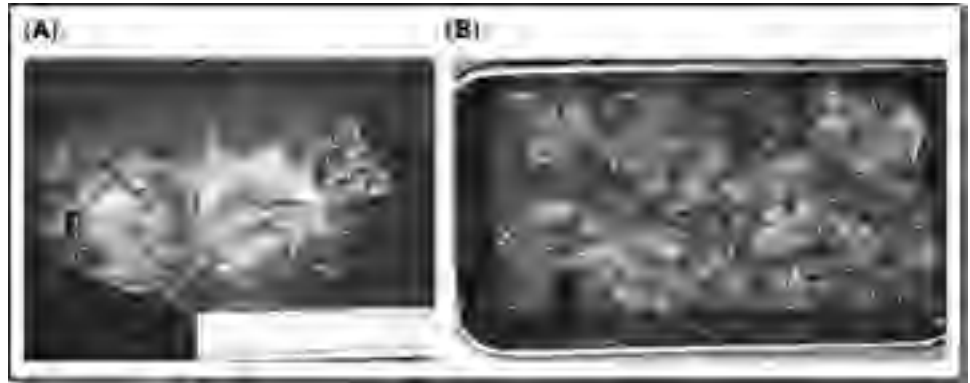


FIGURE 2 ■ (A) Intact kidney with grossly visible tumor. (B) Appearance of a kidney with mass after laparoscopic nephrectomy and manual morcellation.

The morcellated specimen should be processed and examined, in its entirety if necessary, to identify any abnormal renal histopathology.

suspected malignancy. Barrett et al. identified no abnormal pathological findings in 3 of 66 morcellated specimens (5%), while Dunn et al. reported one case (3%) without a diagnosis (7,38). The morcellated specimen should be processed and examined, in its entirety if necessary, to identify any abnormal renal histopathology.

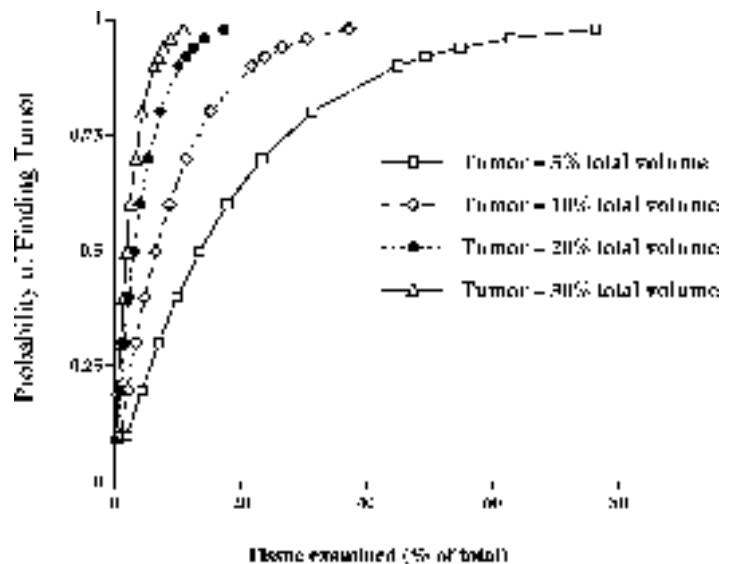
As illustrated in Figure 2, disruption of the renal architecture creates difficulty in sampling the morcellated specimen. In the intact specimen, only a small portion of the entire specimen requires preparation and examination for diagnosis and staging. Typically, several sections are taken from the mass itself, the margins of resection and renal vein, and any lymph nodes. In contrast, no standard or systematic method of specimen processing and analysis have been established after morcellation. To facilitate pathological analysis, a mathematical model has been proposed to guide the study of morcellated renal specimens. If no grossly abnormal fragments can be selected, a sizeable quantity of tissue is often submitted, but it is not feasible or practical to routinely examine the entire specimen. The basic question is “How much tissue does the pathologist need to prepare and examine for a diagnosis to be made?” Formal probability theory, using the hypergeometric distribution, describes the probability of randomly selecting a portion of desired sample (i.e., tumor) from a total population (i.e., entire specimen) containing a fixed fraction of desired sample (41). Figure 3 illustrates the model for tumors comprising specific fractions of the entire specimen. As expected, examining an increasing percentage of the specimen increases the probability of finding tumor. The model assumes random sampling of the specimen. In some cases, the specimen can be fractionated on the basis of gross appearance, helping focus the search for tumor and decreasing the amount of tissue that needs to be examined. This effectively reduces the total volume of specimen and shifts the sampling curve in Figure 3 to the left. Tables 4 to 6 summarize the data in another fashion, describing the quantity of tissue that must be sampled to ensure a diagnosis at 50%, 75%, and 95% confidence levels. These findings have yet to be validated in prospective studies. Nevertheless, the model provides a framework for both the surgeon and the pathologist with which to approach the pathologic examination of fractionated specimens. Additional factors of time, cost, and manpower will impact the actual protocols at individual institutions.

Landman et al. studied the pathologic findings after in vitro electrical morcellation of both Formalin-fixed and fresh radical nephrectomy specimens (42). Ten sections from each specimen were submitted for evaluation and provided the pathologic data. Tumor histology, grade, and stage were all evaluable and accurate when compared with analysis of intact tissue in 13 of 14 cases. It was recommended that “multiple sections from the morcellated specimen should be submitted.”

To improve pathologic diagnosis, Pautler et al. proposed that needle biopsy could be performed after specimen entrapment in a retrieval bag, but prior to morcellation (43). Needle biopsy material, obtained after five passes, yielded congruent diagnoses in 89% of patients; however, morcellated tissue was sufficient for diagnosis in all 15 cases and the needle biopsies did not provide additional information. The relatively large lesions (mean smallest dimension 8.6 cm) likely increased biopsy accuracy of the random sampling, and the utility for smaller lesions remains unclear. In addition, blind needle biopsy raises concern for potential bag perforation.

[§]Karl Storz, Tuttlingen, Germany.

FIGURE 3 ■ Pathologic sampling model based on the hypergeometric distribution. The probability of identifying tumor plotted as a function of amount of tissue sampled for various tumor/total specimen fractions.



We have attempted to complement the diagnosis on histology by examining cytological findings in bag washings after morcellation (44). The LapSac was rinsed ex vivo with 30 mL of normal saline and the fluid sample was processed using routine cytologic protocols. In all 22 cases, cellular material was obtained and subject to examination. Concordant benign histology and cytology findings were observed in all nine patients without renal cell carcinoma, while cytology detected confirmed renal carcinoma in 69% of cases. Despite the reduced sensitivity, positive bag cytology permitted easy detection

TABLE 4 ■ Nomogram Providing the Volume of Morcellated Tissue (in mL) which Must Be Analyzed to Identify a Portion of the Lesion with 95% Certainty, Based on Total Specimen Volume and Tumor Volume

Tumor volume (mL)	Specimen volume (mL)				
	100	200	300	400	500
1	96	191	286	381	474
5	45	90	135	180	225
10	25	51	77	103	129
20	13	27	41	55	69
30	9	19	29	39	49
50	5	11	16	23	29

TABLE 5 ■ Nomogram Providing the Volume of Morcellated Tissue (in mL) which Must Be Analyzed to Identify a Portion of the Lesion with 75% Certainty, Based on Total Specimen Volume and Tumor Volume

Tumor volume (mL)	Specimen volume (mL)				
	100	200	300	400	500
1	76	151	226	301	376
5	24	48	73	97	121
10	13	26	39	52	65
20	7	13	20	27	33
30	4	9	13	18	22
50	2	5	8	11	13

TABLE 6 ■ Nomogram Providing the Volume of Morcellated Tissue (in mL) which Must Be Analyzed to Identify a Portion of the Lesion with 50% Certainty, Based on Total Specimen Volume and Tumor Volume

Tumor volume (mL)	Specimen volume (mL)				
	100	200	300	400	500
1	51	101	151	201	251
5	13	26	39	52	65
10	7	14	20	27	34
20	4	7	10	14	17
30	2	5	7	9	12
50	1	3	4	6	7

and classification of carcinoma into both type and grade. Moreover, in three cases of cancer (23%), cytology provided additional information compared to histology alone, including higher tumor grade and mixed pathology. Advantages of bag cytology include simplicity of specimen acquisition, standard technique of processing, and incorporation during assessment for perforation. Further investigation is required to assess whether the potential information provided by an additional test is useful and cost-effective.

Tumor Staging

The over-riding controversy regarding specimen morcellation is the reduced ability to determine tumor stage. While the importance of histologic diagnosis is well-accepted, the clinical utility of precise pathologic staging is less clear.

Proponents of intact specimen extraction cite the inaccuracy of staging by preoperative imaging studies (3). Computed tomography overestimated and understaged tumors in 10% and 9% of patients, respectively. It is assumed that morcellation destroys the ability to identify pathologic features such as invasion into the renal vein, perinephric fat, and adrenal gland. However, Landman et al. suggested that morcellated fragments can yield evidence of perinephric fat involvement (100%) and rein vein thrombus (100%) (42). Pautler et al. also provided evidence that perinephric invasion can be identified after manual morcellation, although the true accuracy cannot be determined (43). We have made similar observations, with identification of higher pathologic stage despite morcellation.

The imprecision of clinical staging based on imaging compared to pathologic staging of an intact specimen will always remain. Furthermore, adverse pathologic features such as extension into fat or the renal vein are associated with worse oncologic outcomes. This information is important for determining surveillance regimens as well as patient counseling. However, outside of clinical trials, adjuvant therapy is not currently indicated in these situations. Therefore, the actual clinical impact of not recognizing microscopic fat invasion is limited. Indeed, the excellent five-year outcomes of the laparoscopic approach, with morcellation, for smaller renal tumors confirm the efficacy of the operation and absence of clinical implication. If more advanced stage is suspected on imaging studies and consideration of adjuvant therapy is dependent on this information, intact specimen retrieval should be performed. Future molecular characterization and stratification of renal tumors, and less dependence on pathologic stage, may predict recurrence or need for secondary treatment and shift preference toward morcellation.

In addition to affecting accurate pathologic staging, morcellation also obscures the nature of surgical margin status. Similar to higher pathologic stage, the presence of a positive surgical margin does not necessarily change postoperative treatment but would potentially increase the frequency of subsequent imaging. Nevertheless, accurate evaluation of surgical margins plays several roles. Negative surgical margins confirm the oncologic adequacy of the laparoscopic approach to the kidney with tumor. The excellent cancer outcomes, without significant rates of local tumor recurrence, indirectly indicate that the laparoscopic technique has not been associated with increased rates of positive surgical margins. This may be important to document as the techniques are increasingly performed (i) by those less experienced with laparoscopy, and (ii) in patients with larger and more advanced cancers. A positive surgical margin portends a worse prognosis and allows appropriate counseling of the patient, while the confirmation of a negative surgical margin is reassuring to both the patient and physician.

Few studies have addressed the question of surgical margin status in morcellated laparoscopic specimens. In an in vitro model, various substances were tested for their ability to mark the margins of bovine kidneys prior to manual morcellation (45). Undiluted india ink was superior to methylene blue and indigo carmine with respect to covering the surface, retention after washing, and microscopically visible after routine processing and hematoxylin-eosin staining. India ink is clinically safe and has been extensively used in vivo in humans. Overall, accurate pathologic study of renal specimens will become more crucial as minimally invasive surgery grows, and novel and alternative methods of determining surgical margin as well as biological behavior are necessary.

The over-riding controversy regarding specimen morcellation is the reduced ability to determine tumor stage.

Future molecular characterization and stratification of renal tumors, and less dependence on pathologic stage, may predict recurrence or need for secondary treatment and shift preference toward morcellation.

Overall, accurate pathologic study of renal specimens will become more crucial as minimally invasive surgery grows, and novel and alternative methods of determining surgical margin as well as biological behavior are necessary.

SUMMARY

- The ability to remove the entire kidney laparoscopically, and widespread dissemination of the technique, has created the dilemma of specimen retrieval.

- Current data indicate that careful manual morcellation is safe and does not compromise oncologic outcomes, but only further observation will confirm this.
- When performed properly, specimen morcellation after laparoscopic nephrectomy is acceptable, and is particularly appropriate in those undergoing cytoreductive nephrectomy prior to systemic immunotherapy.
- The impacts of morcellation on pathological assessment are primarily theoretical and do not typically alter treatment schemes.
- The primary benefit of specimen morcellation is cosmetic. After laparoscopic nephrectomy, the exact method of specimen handling is likely unimportant with respect to pain and convalescence.
- The decision of how to remove the kidney is ultimately based on patient and surgeon preference and made after thorough discussion of the relevant issues.

REFERENCES

1. Chan DY, Cadeddu JA, Jarrett TW, Marshall FF, Kavoussi LR. Laparoscopic radical nephrectomy: cancer control for renal cell carcinoma. *J Urol* 2001; 166:2095.
2. Portis AJ, Yan Y, Landman J, et al. Long-term followup after laparoscopic radical nephrectomy. *J Urol* 2002; 167:1257.
3. Gill IS, Meraney AM, Schweizer DK, et al. Laparoscopic radical nephrectomy in 100 patients: a single center experience from the United States. *Cancer* 2001; 92:1843.
4. Gill IS, Cherullo EE, Meraney AM, Borsuk F, Murphy DP, Falcone T. Vaginal extraction of the intact specimen following laparoscopic radical nephrectomy. *J Urol* 2002; 167:238.
5. Matin SF, Gill IS. Modified Pfannenstiel incision for intact specimen extraction after retroperitoneoscopic renal surgery. *Urology* 2003; 61:830.
6. Savage SJ, Gill IS. Intact specimen extraction during renal laparoscopy: muscle-splitting versus muscle-cutting incision. *J Endourol* 2001; 15:165.
7. Barrett PH, Fentie DD, Taranger LA. Laparoscopic radical nephrectomy with morcellation for renal cell carcinoma: the Saskatoon experience. *Urology* 1998; 52:23.
8. Walther MM, Lyne JC, Libutti SK, Linehan WM. Laparoscopic cytoreductive nephrectomy as preparation for administration of systemic interleukin-2 in the treatment of metastatic renal cell carcinoma: a pilot study. *Urology* 1999; 53:496.
9. Pryor WR. *The Treatment of Pelvic Inflammations Through the Vagina*. Philadelphia: W.B. Saunders, 1899:209–215.
10. Lash AF. A method for reducing the size of the uterus in vaginal hysterectomy. *Am J Obstet Gynecol* 1941; 42:452.
11. Kovac SR. Intramyometrial coring as an adjunct to vaginal hysterectomy. *Obstet Gynecol* 1986; 67:131.
12. Melose MA, Melosi MA III. Laparoscopic hysterectomy with bilateral salpingo-oophorectomy using a single umbilical puncture. *N J Med* 1991; 88:721.
13. Steiner RA, Wight E, Tadir Y, Haller U. Electrical cutting device for laparoscopic removal of tissue from the abdominal cavity. *Obstet Gynecol* 1993; 81:471.
14. al-Ahmadi M, Brundage S, Brody F, Jacobs L, Sackier JM. Splenosis of the mesoappendix: case report and review of the literature. *J R Coll Surg Edinb* 1988; 43:200.
15. Sepilian V, Della Badia C. Iatrogenic endometriosis caused by uterine morcellation during a supracervical hysterectomy. *Obstet Gynecol* 2003; 102:1125.
16. Hutchins FL, Reinhoehl EM. Retained myoma after laparoscopic supracervical hysterectomy with morcellation. *J Am Assoc Gynecol Laparosc* 1998; 5:293.
17. Schneider AL. Recurrence of unclassifiable uterine cancer after modified hysterectomy with morcellation. *Am J Obstet Gynecol* 1997; 177:478.
18. EndoCatch Gold product information. Available at: www.autosuture.com/products/endocatch-gold/ (accessed on June 1, 2004).
19. Urban DA, Kerbl K, McDougall EM, Stone AM, Fadden PT, Clayman RV. Organ entrapment and renal morcellation: permeability studies. *J Urol* 1993; 150:1792.
20. Sundaram CP, Ono Y, Landman J, Rehman J, Clayman RV. Hydrophilic guidewire technique to facilitate organ entrapment using a laparoscopic sack during laparoscopy. *J Urol* 2002; 167:1376.
21. Pautler SE, Harrington FS, McWilliams GW, Walther MM. A novel laparoscopic specimen entrapment device to facilitate morcellation of large renal tumors. *Urology* 2002; 59:591.
22. User HM, Nadler RB. Novel technique of renal entrapment for morcellation. *J Urol* 2003; 169:2287.
23. Landman J, Collyer WC, Olweny E, Andreoni C, McDougall E, Clayman RV. Laparoscopic renal ablation: an in vitro comparison of currently available electrical tissue morcellators. *Urology* 2000; 56:677.
24. Parekh AR, Moran ME, Newkirk RE, Desai PJ, Calvano CJ. Tissue removal utilizing Steiner Morcellator within a LapSac: effects of a fluid-filled environment. *J Endourol* 2000; 14:185.
25. Cai Y, Jacobson A, Marcovich R, et al. Electrical prostate morcellator: an alternative to manual morcellation for laparoscopic nephrectomy specimens? An in vitro study. *Urology* 2003; 61:1113.
26. Varkarakis JM, McAllister M, Ong AM, et al. Evaluation of water jet morcellation as an alternative to hand morcellation of renal tissue ablation during laparoscopic nephrectomy: an in vitro study. *Urology* 2004; 63:796.
27. Landman J, Venkatesh R, Kibel A, Vanlangendonck R. Modified renal morcellation for renal cell carcinoma: laboratory experience and early clinical application. *Urology* 2003; 62:632.
28. Elashry OM, Giusti G, Nadler RB, McDougall EM, Clayman RV. Incisional hernia after laparoscopic nephrectomy with intact specimen removal: caveat emptor. *J Urol* 1997; 158:363.

29. Jacobs SC, Cho E, Dunkin BJ, et al. Laparoscopic live donor nephrectomy: the University of Maryland 3-year experience. *J Urol* 2000; 164:1494.
30. Ratner LE, Montgomery RA, Kavoussi LR. Laparoscopic live donor nephrectomy: the four year Johns Hopkins University experience. *Nephrol Dial Transplant* 1999; 14:2090.
31. Shekarriz B, Gholami SS, Rudnick DM, Duh QY, Stoller ML. Radially expanding laparoscopic access for renal/adrenal surgery. *Urology* 2001; 58:683.
32. Ono Y, Kinukawa T, Hattori R, Gotoh M, Kamihira O, Ohshima S. The long-term outcome of laparoscopic radical nephrectomy for small renal cell carcinoma. *J Urol* 2001; 165:1867.
33. Fentie DD, Barrett PH, Taranger LA. Metastatic renal cell cancer after laparoscopic radical nephrectomy: long-term follow-up. *J Endourol* 2000; 14:407.
34. Castilho LN, Fugita OE, Mitre AI, Arap S. Port site tumor recurrences of renal cell carcinoma after videolaparoscopic radical nephrectomy. *J Urol* 2001; 165:519.
35. Landman J, Clayman RV. Re: Port site tumor recurrences of renal cell carcinoma after videolaparoscopic radical nephrectomy. *J Urol* 2001; 166:629.
36. Tsivian A, Sidi AA. Port site metastases in urological laparoscopic surgery. *J Urol* 2003; 169:1213.
37. Ono Y, Kinukawa T, Hattori R, et al. Laparoscopic radical nephrectomy for renal cell carcinoma: a five-year experience. *Urology* 1999; 53:280.
38. Dunn MD, Portis AJ, Shalhav AL, et al. Laparoscopic versus open radical nephrectomy: a 9-year experience. *J Urol* 2000; 164:1153.
39. Gettman MT, Napper C, Corwin TS, Cadeddu JA. Laparoscopic radical nephrectomy: prospective assessment of impact of intact versus fragmented specimen removal on postoperative quality of life. *J Endourol* 2002; 16:23.
40. Hernandez F, Rha KH, Pinto PA, et al. Laparoscopic nephrectomy: assessment of morcellation versus intact specimen extraction on postoperative status. *J Urol* 2003; 170:412.
41. Meng MV, Koppie TM, Stoller ML. Pathologic sampling of laparoscopically morcellated kidneys: a mathematical model. *J Endourol* 2003; 17:229.
42. Landman J, Lento P, Hassen W, Unger P, Waterhouse R. Feasibility of pathological evaluation of morcellated kidney after radical nephrectomy. *J Urol* 2000; 164:2086.
43. Pautler SE, Hewitt SM, Linehan WM, Walther MM. Specimen morcellation after laparoscopic radical nephrectomy: confirmation of histologic diagnosis using needle biopsy. *J Endourol* 2002; 16:89.
44. Meng MV, Miller TR, Cha I, Stoller ML. Cytology of morcellated renal specimens: significance in diagnosis and dissemination. *J Urol* 2003; 169:45.
45. Meng MV, Koppie TM, Duh Q-Y, Stoller ML. Novel method of assessing surgical margin status in laparoscopic specimens. *Urology* 2001; 58:677.

LAPAROSCOPIC RETROPERITONEAL LYMPH NODE DISSECTION TECHNIQUE

Nasser Albqami and Günter Janetschek

Department of Urology, KH der Elisabethinen, Teaching Hospital of University of Innsbruck, Linz, Austria

- | | |
|--|--|
| <ul style="list-style-type: none"> ■ INTRODUCTION ■ THERAPEUTIC CONCEPTS AND PATIENT SELECTION <ul style="list-style-type: none"> Nonseminomatous Germ Cell Tumors Clinical Stage I ■ CAVEATS <ul style="list-style-type: none"> Nonseminomatous Germ Cell Tumors Clinical Stage II ■ CONTRAINDICATIONS FOR LAPAROSCOPIC RETROPERITONEAL LYMPH NODE DISSECTION ■ PREOPERATIVE PREPARATION ■ TEMPLATES <ul style="list-style-type: none"> Right Template Left Template | <ul style="list-style-type: none"> ■ PATIENT POSITIONING ■ TROCAR PLACEMENT AND PNEUMOPERITONEUM ■ PROCEDURE <ul style="list-style-type: none"> Transperitoneal Laparoscopic Retroperitoneal Lymph Nodes Dissection ■ EXTRAPERITONEAL APPROACH <ul style="list-style-type: none"> General Technique and Patient Position Extraperitoneal Space Preparation Trocar Placement The Template Dissection ■ TECHNICAL CAVEATS ■ SUMMARY ■ REFERENCES |
|--|--|

INTRODUCTION

Testicular cancer, the most common tumor in men between 15 and 35 years of age, evoked widespread interest because the dramatic improvement in survival mainly achieved with the combination of improved diagnostic techniques, tumor markers availability, effective chemotherapeutic regimens, and modifications of surgical techniques led to the decrease in patients mortality from more than 50% before 1970 to less than 5% in 1997 (1).

With all means of imaging techniques available currently, 25% to 30% of patients with testicular cancer will be understaged while some of these patients will be overstaged (2). Retroperitoneal lymphadenectomy is the most sensitive and specific method for testicular cancer staging and has also a therapeutic value. Because open retroperitoneal lymph node dissection failed to cure all patients with metastatic nonseminomatous germ cell tumors, all our clinical stage I patients diagnosed as pathologic stage II received chemotherapy as the definitive treatment.

Open surgical retroperitoneal lymph node dissection associates with substantial morbidity with overall relapse rates up to 55% if employed as a single therapeutic measure (3,4). We have replaced open surgical retroperitoneal lymph node dissection by laparoscopic retroperitoneal lymph node dissection because it showed decreased postoperative morbidity, quicker convalescence, and improved cosmetic results. Its diagnostic accuracy equals that of the open approach (5,6). Laparoscopic retroperitoneal lymph node dissection is considered a safe method for low stage germ cell tumors with minimal invasiveness (7,8).

THERAPEUTIC CONCEPTS AND PATIENT SELECTION

Nonseminomatous Germ Cell Tumors Clinical Stage I

Surveillance, risk-adapted primary chemotherapy, and retroperitoneal lymphadenectomy are advocated for the management in this stage, although with overall disagreement on the optimal treatment regimen (9,10).

- *If surveillance is opted:*
15% to 20% of patients will relapse (11,12). Death rates are up to 10% in the relapsing patients (13). The primary advantage of surveillance is to avoid the morbidity of open surgery, which is minimized by the introduction of the modified unilateral retroperitoneal lymph node dissection and the nerve-sparing technique, which is feasible by laparoscopic means.

Because open retroperitoneal lymph node dissection failed to cure all patients with metastatic nonseminomatous germ cell tumors, all our clinical stage I patients diagnosed as pathologic stage II received chemotherapy as the definitive treatment.

- *If risk-adapted primary chemotherapy is opted:*
In several studies involving more than 200 high-risk patients with nonseminomatous germ cell tumors of the testes (embryonic carcinoma as the primary tumor or tumors with vascular or lymphatic invasions) treated with two cycles of bleomycin, etoposide, and cisplatin (BEP) a relapse rate of 2.7% was found . Median follow-up in some studies approached eight years (11,14).

CAVEATS

- The risk of slow growing retroperitoneal teratomas.
 - The risk of chemoresistant cancer relapses.
 - Follow-up protocol is not clear.
 - A total of 4% to 50% of patients in this group will be overtreated.
 - Relapse in patients under treatment because they are considered low-risk.
-
- *Retroperitoneal lymphadenectomy:*
Laparoscopic retroperitoneal lymph node dissection is our preferred choice because it has equal diagnostic accuracy, but lower morbidity than open surgery. At the time of this writing, 103 patients with clinical stage I disease underwent laparoscopic retroperitoneal lymph node dissection between August 1992 and June 2004 with a mean follow up of 62 months (range, 6–113) (Table 1).
All patients diagnosed having nonseminomatous germ cell tumors clinical stage I are candidates for diagnostic laparoscopic retroperitoneal lymph node dissection as the first line of management. Laparoscopic retroperitoneal lymph node dissection is followed by surveillance if the retroperitoneal lymph nodes histology is negative or two cycles of chemotherapy if lymph nodes metastases are found.

All patients diagnosed having nonseminomatous germ cell tumors clinical stage I are candidates for diagnostic laparoscopic retroperitoneal lymph node dissection as the first line of management. This is followed by surveillance if the retroperitoneal lymph nodes histology is negative or two cycles of chemotherapy if lymph nodes metastases are found.

Nonseminomatous Germ Cell Tumors Clinical Stage II

Neither retroperitoneal lymphadenectomy nor chemotherapy alone can be expected to be curative in this stage.

Classical options for the management of nonseminomatous germ cell tumors stage II:

- If tumor markers are negative, retroperitoneal lymph node dissection followed by (i) surveillance if histology is negative or (ii) two cycles of chemotherapy in cases of positive histology.
- Primary chemotherapy. If tumor markers normalize, surgical removal of residual retroperitoneal masses is performed.

In an attempt to reduce the morbidities of this combined treatment, we have reduced the dose of chemotherapy from the usual three to four cycles to two cycles for clinical stage IIB disease which is obviously the minimum dose required for complete tumor control (10). Chemotherapy in these patients is followed by laparoscopic retroperitoneal lymph node dissection even if there is no residual tumor clinically.

At the time of this writing, 42 patients with clinical stage IIB disease treated with two cycles of primary chemotherapy underwent laparoscopic retroperitoneal lymph

TABLE 1 ■ Laparoscopic Retroperitoneal Lymph Node Dissection: Results of 103 Stage I Patients

No. of patients	Histology findings (clinical stage I)	Adjuvant treatment	Recurrences
103	26 patients (25.2%) active tumor (pathologic stage II)	2 cycles bleomycin, etoposide, and cisplatin	No
	77 patients (74.8%) no tumor found (pathologic stage I)	No	5 recurrences (4.9%) →3 pulmonary →1 contralateral retroperitoneal nodes (pathologic review was false negative) →1 tumor marker recurrence 5 patients lost follow-up

TABLE 2 ■ Laparoscopic Retroperitoneal Lymph Node Dissection: Results of Stage IIB and IIC Patients

No. of patients	Histology findings (clinical stage II)	Adjuvant treatment	Recurrences
42	16 patients (38%) mature teratoma	No	→1 to external iliac lymph nodes
IIB	26 patients (62%) no tumor found	No	No
17	10 patients (58.8%) no tumor found	No	No
	5 patients (29.4%) mature teratoma	No	→1 retrocaval (outside the surgical field)
IIC	1 patient (5.9%) active tumor	2 cycles chemo	No
	1 patient (5.9%) seminoma	2 cycles chemo	No

node dissection between February 1995 and June 2004 with a mean follow up of 53 months while 17 patients clinical stage IIC disease had three to four cycles of primary chemotherapy followed by laparoscopic retroperitoneal residual mass excision over the same period (Table 2).

All patients diagnosed having nonseminomatous germ cell tumors clinical stage IIA, or IIB with positive tumor markers, are treated with two cycles of chemotherapy bleomycin, etoposide, and cisplatin followed by laparoscopic retroperitoneal lymph node dissection.

If indicated, laparoscopic excision of residual retroperitoneal masses in selected patients with nonseminomatous germ cell tumors clinical stage IIC treated with a minimum of three cycles of chemotherapy is feasible (5,15).

CONTRAINDICATIONS FOR LAPAROSCOPIC RETROPERITONEAL LYMPH NODE DISSECTION

Contraindications for laparoscopic retroperitoneal lymph node dissection include:

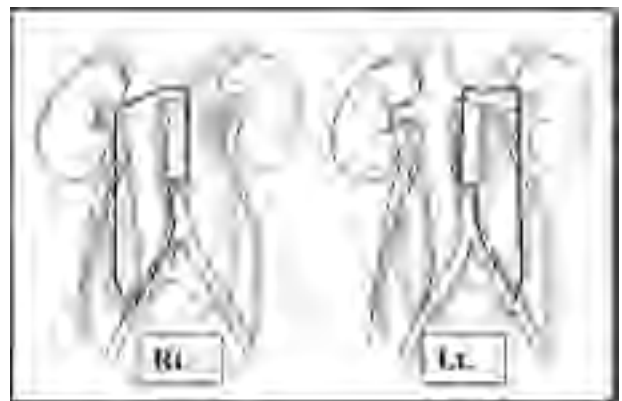
- Elevated tumor markers
- Severe pulmonary fibrosis that prevents pneumoperitoneum
- Uncontrolled bleeding diathesis
- Patients with a high body mass index benefit more from laparoscopy than slim patients as regards postoperative pain and morbidity, but do not experience more complications (16). Although laparoscopic retroperitoneal lymph node dissection may be technically more challenging in obese patients, so far we had no conversion to open surgery in this patient population.

All patients diagnosed having nonseminomatous germ cell tumors clinical stage IIA, or IIB with positive tumor markers, are treated with two cycles of chemotherapy bleomycin, etoposide, and cisplatin followed by laparoscopic retroperitoneal lymph node dissection. If indicated, laparoscopic excision of residual retroperitoneal masses in selected patients with nonseminomatous germ cell tumors clinical stage IIC treated with a minimum of three cycles of chemotherapy is feasible.

PREOPERATIVE PREPARATION

Preoperative preparation includes:

- Low-fat diet started one week preoperatively and continued two weeks postoperatively to prevent chylous ascites
- Typing and cross-matching of two units of blood
- Bowel preparation with clear liquid diet and oral laxatives the day before surgery
- Low-dose systemic antibiotics on call to surgery.

FIGURE 1 ■ Stage I lymph node templates.

If all lymphatic tissues within the templates are excised, there is a minimal risk of metastasis being overlooked.

TEMPLATES

Weissbach and Boedefeld defined templates that included practically all primary landing sites of lymph node metastases occurring in patients with stage I nonseminomatous germ cell tumors (17). The right template comprises 97% of all the primary landing sites of lymph node metastases while the left template comprises 95% of all the primary landing sites of lymph node metastases in this stage (Fig. 1).

If all lymphatic tissues within the templates are excised, there is a minimal risk of metastasis being overlooked.

Right Template

The right template includes:

- Interaortocaval lymph nodes
- Pre-aortic tissue between the left renal vein and the inferior mesenteric artery
- Precaval tissue
- All tissues lateral to the vena cava and the right common iliac artery
- The right ureter, which represents the lateral border of the dissection.

Left Template

The left template includes:

- Periaortic tissue between the left renal vein and the inferior mesenteric artery
- All tissue lateral to the aorta and the left common iliac artery
- The left ureter, which represents the lateral border of the dissection
- Interaortocaval lymph nodes and the lymphatic tissue ventral to the aorta below the inferior mesenteric artery, which are preserved.

The authors had investigated the primary lymphatic metastatic spread in 139 patients with testicular cancer. All solitary metastases were detected ventral to the lumbar vessels whereas metastases dorsal to the lumbar vessels were only detected in 3 out of 25 patients with multiple metastases who had ventral metastases as well. Therefore it was concluded that the primary landing sites were invariably located ventral to the lumbar vessels whereas dorsal metastases resulted from further tumor spread (18). As a result, we no longer routinely transect lumbar vessels for removal of dorsally located lymphatic tissue. This is not required for the diagnostic retroperitoneal lymph node dissection in clinical stage I disease and has made the laparoscopic procedure easier, faster, and safer.

PATIENT POSITIONING

- After general anesthesia is established, a nasogastric tube and a urinary bladder catheter are placed.
- The patient is placed with the ipsilateral side elevated 45° off the operating table, so that he can be brought into supine or lateral decubitus positions by rotating the table without repositioning
- The table is flexed at the umbilicus and if necessary, the Trendelenburg's or anti-Trendelenburg's positions are used (Fig. 2).



FIGURE 2 ■ Patient positioning.

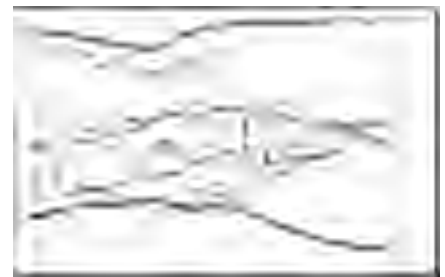

FIGURE 3 ■ Trochar placement.

TROCAR PLACEMENT AND PNEUMOPERITONEUM

- A Veress needle is routinely used for the initial stab incision to create pneumoperitoneum, whereas Hasson cannula is used only if indicated.
- 5-mm and 10-mm trocars are used
- The primary-port trocar (for the laparoscope) is placed at the umbilicus.
- Two secondary trocars are inserted at the lateral edge of the rectus muscle 8 cm above and below the umbilicus.
- A fourth trocar is placed at the anterior axillary line in the best point for retraction (Fig. 3).

PROCEDURE

Transperitoneal Laparoscopic Retroperitoneal Lymph Nodes Dissection (4,19)

Right Side

Care must be taken during dissection of the spermatic vein where it drains into the vena cava as rupture may occur.

- The peritoneum is incised at the internal inguinal ring then along the line of Toldt from the cecum to the right colic flexure (Fig. 4).
- Cephalic dissection is carried out parallel to the transverse colon and lateral to the duodenum along the vena cava up to the hepatoduodenal ligament. Caudally, the dissection is continued along the spermatic vessels down to the internal inguinal ring (Figs. 5 and 6).
- The colon, duodenum, and the head of pancreas are reflected medially until the anterior surface of the vena cava, aorta, and left renal vein are completely exposed (Fig. 7).
- The spermatic vein is dissected free along its entire course, clipped, and transected (Figs. 6–8).
- Care must be taken during dissection of the spermatic vein where it drains into the vena cava as rupture at this point may occur.



FIGURE 4



FIGURE 5



FIGURE 6



FIGURE 7



FIGURE 8



FIGURE 9

Lower border of left renal vein must be completely free because it might be easily injured during dissection of the interaortocaval lymph node package from caudal to cephalic direction.

Lymphatic tissues in this area are dense and care must be taken to prevent injury of the inferior mesenteric artery, which constitutes a landmark to preserve the left sympathetic nerves.

- The spermatic artery is clipped and transected at its crossing over the vena cava.
- Dissection of the right template starts at this point.
- Cranial to caudal the lymphatic tissue overlying the vena cava is split open; then the lateral and anterior surfaces of the vena cava are dissected free (Fig. 9).
- Subsequently, both renal veins are dissected free.
- Lymphatic tissue overlying the right common iliac artery is incised up to the origin of the inferior mesenteric artery.
- Cephalad to the inferior mesenteric artery dissection is continued upward along the left margin to the aorta. Thereby the ventral surface of the aorta is completely freed (Fig. 10).
- Lower border of left renal vein must be completely free at this point because it might be easily injured during the dissection of the interaortocaval lymph node package from caudal to cephalic direction (Fig. 10).
- Spermatic artery is now clipped at its origin (Fig. 11).
- A Fan retractor is used to retract the liver while dissecting the cranial portion of the template.
- Cranial to caudal the interaortocaval space is dissected, starting from the lower edge of the right renal artery down to the lumbar vessels and the lymphatic tissue is removed step by step (Fig. 12).
- The distal border of the dissection is the point where the ureter crosses the iliac vessels (Fig. 13).
- The lymphatic tissue is clipped distally (Fig. 13) and the dissection is continued cephalic until the lymphatic package is freed.
- Lymphatic tissues in this area are dense and care must be taken to prevent injury of the inferior mesenteric artery, which constitutes a landmark to preserve the left sympathetic nerves.
- The lumbar veins are exposed, but they are only transected in exceptional cases (Fig. 14).
- The right renal vein and artery is exposed lateral to the vena cava, which delineates the cranial border of the dissection (Fig. 15).
- The lymph nodes lateral to the vena cava and medial to the ureter are dissected free.
- The nodal package will be completely free and can be removed within a specimen retrieval bag.
- Drains are not required.
- Colon and duodenum are returned to their anatomic position and secured with one suture laterally and tied extracorporeal.

Left Side

- After incising the line of Told starting from the left colonic flexure down to the pelvic brim and distally along the spermatic vein to the internal inguinal ring, the splenocolic ligament is transected and the colon is dissected until the anterior surface of the aorta is exposed (Fig. 16).
- As an option one may leave the splenocolic ligament intact and incise the peritoneum lateral to the spleen all the way up to the diaphragm. Thereby the spleen and the tail of the pancreas are reflected medially.



FIGURE 10



FIGURE 11

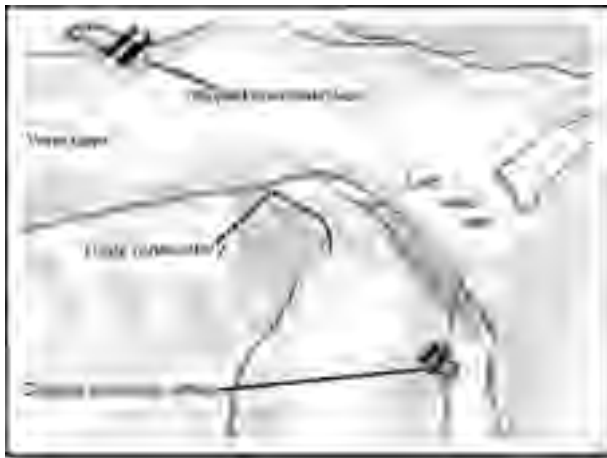


FIGURE 12

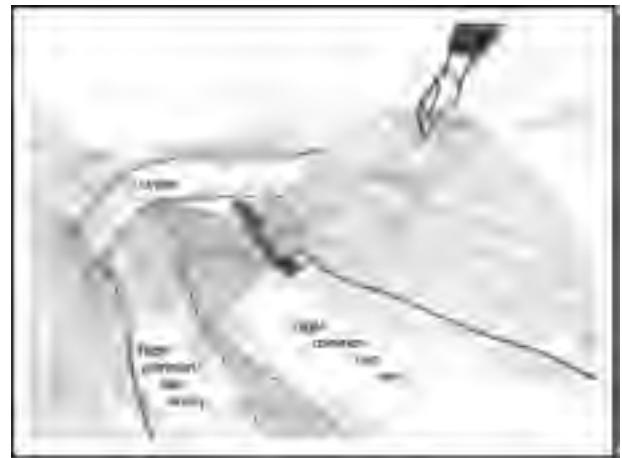


FIGURE 13



FIGURE 14

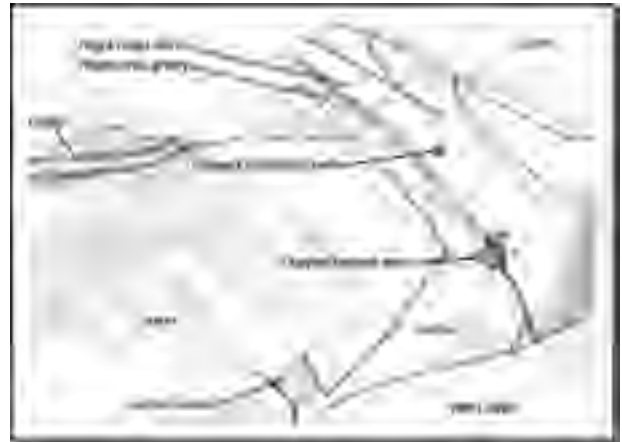


FIGURE 15

Dissection of the lymphatic template is started distally at the crossing of the ureter with the common iliac vessels.

- Normally the colon falls away from the operative field and retractors are only required in exceptional cases.
- The spermatic vein is dissected along its entire course from the internal inguinal ring up to the renal vein and excised. The ureter laterally is then identified and separated from the lymphatic tissue with care to preserve its blood supply (Fig. 17).
- The left renal vein is then completely freed at this point (Fig. 18).
- Lymphatic tissues overlying the common iliac artery are split open.
- Dissection of the lymphatic template is started distally at the crossing of the ureter with the common iliac vessels.
- The dissection is continued cephalad circumventing the inferior mesenteric artery on the left side and preserving it.
- Cephalad to the inferior mesenteric artery dissection is continued along the medial border of the aorta up to the left renal vein.
- The spermatic artery is clipped at its origin and transected (Fig. 19).
- The lateral surface of the aorta is dissected down to the origin of the lumbar arteries.
- The lumbar vein, which is draining into the left renal vein, is approached and transected between clips to gain access to the left renal artery (Figs. 20 and 21).
- The lumbar vessels are dissected and separated from the lymphatic tissue to the point at which they disappear in the layer between the spine and psoas muscle (Fig. 21).
- Lateral to that point the sympathetic chain is encountered.
- Although the left postganglionic fibers are readily identified, they are not preserved in template dissection because the right sympathetic chain remains intact providing undisturbed antegrade ejaculations.
- The nodal package will be completely free at this point and can be retrieved (Fig. 22).
- The colon is secured in its anatomic position with an extracorporeal tied suture.



FIGURE 16

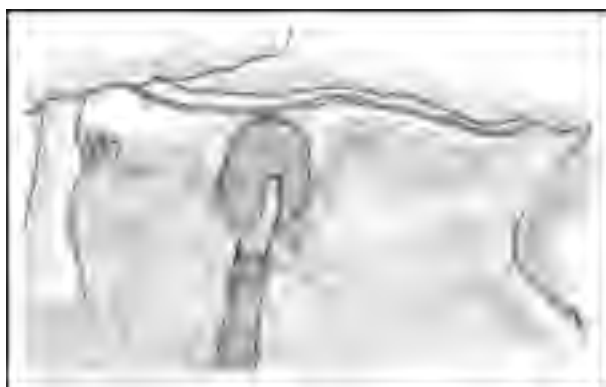


FIGURE 17

EXTRAPERITONEAL APPROACH (20)

General Technique and Patient Position

- The patient is placed supine under general anesthesia with the arms and legs apart (Fig. 23).
- The patient is placed close to the table edge.
- The surgeon stands ipsilateral to the tumor next to the assistant who holds the camera.
- A video monitor on the opposite side provides a comfortable view for each operator (Fig. 2).
- Although, the Trendelenburg's position is not necessary, slightly tilting the opposite side of the table lateral may sometimes be helpful.
- The trocar set consists of 10-mm balloon trocar, 10-mm trocar with reducer and a 5-mm ancillary operative trocar.
- The instrument set includes a 10-mm 0-degree video laparoscope, an irrigation suction device, two atraumatic grasping forceps, a bipolar forceps, monopolar scissors, a clip applier, and an endoscopic bag for lymph node removal.

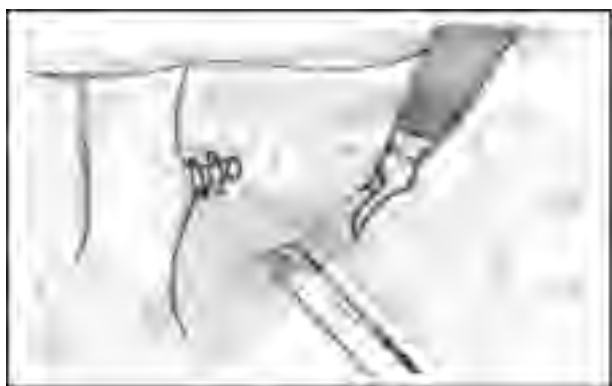

FIGURE 18

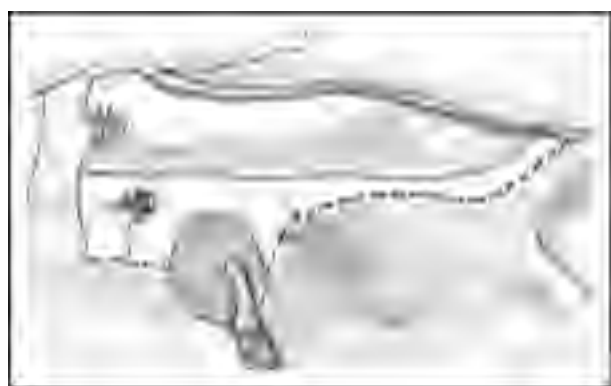

FIGURE 19

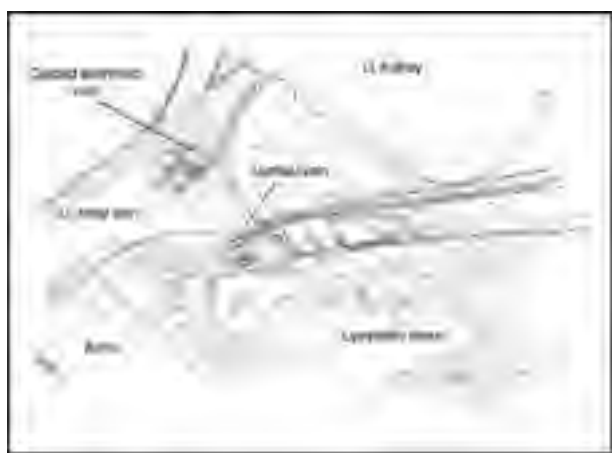


FIGURE 20

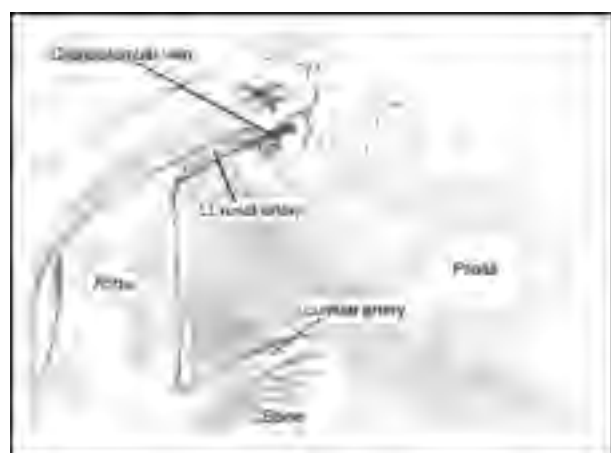


FIGURE 21



FIGURE 22




FIGURE 23

Extraperitoneal Space Preparation

- A maximum of 2-cm transverse incision is made ipsilateral to the tumor two finger breadth medial to the anterior iliac spine on the mid clavicular line high in the iliac fossa.
- The abdominal wall muscles are divided along their fibers until the peritoneum is visible.
- Bluntly, the peritoneum is progressively separated from the muscles using your forefinger until you can palpate the psoas muscle posterior, the lumbar spine medial, and the pulsation of the common iliac artery caudal.

Lymphatic tissues in this area are dense and care must be taken to prevent injury of the inferior mesenteric artery, which constitutes a landmark to preserve the left sympathetic nerves.

Trocar Placement

- A 10-mm operative trocar is introduced in the extra peritoneal space on the mid axillary line midway between the 11th rib and the iliac crest which is controlled by the finger through the iliac incision.
- Gas insufflations is connected to this trocar.
- The laparoscope is introduced through this trocar and under direct vision the forefinger completes the dissection of the extra peritoneal space as high as possible.
- At the anterior axillary line approximately 5 cm above and 3 to 4 cm medial to the operative trocar a 5 mm trocar is introduced under double control of the forefinger and the laparoscope.
- Through the iliac incision under direct vision a blunt tip 10-mm trocar is introduced and the distal balloon is inflated.
- Care in trocar placement and dissection is important because peritoneal perforation will result in pneumoperitoneum, which may preclude continuation of the planned procedure.
- The iliac trocar is used for the laparoscope and the other two are operative ports.
- The extra peritoneal space is developed until the ipsilateral great vessels are reached and the ureter is visible.
- If possible the ureter remains attached with the gonadal vessels on the posterior peritoneum.

The Template Dissection

The dissection technique is similar to that of the transperitoneal approach with some modifications.

Left Para-Aortic Dissection

No dissection is done along the anterior wall of the aorta below the origin of the inferior mesenteric artery, so that the superior hypogastric nerve plexus is not injured.

Posterior division of the lumbar arteriovenous vessels is not necessary and retrovascular lymphadenectomy may be performed by skipping between the lumbar pedicles.

- Lateral and upward the peritoneum is separated from the psoas muscle to enlarge the working space.
- The peritoneum and the duodenum are separated cranially from the anterior aspect of the great vessels until the left renal vein is completely visible.
- The lymphatic fat pad is then grasped and gently separated from the aorta by blunt and sharp dissection from the psoas muscle and sympathetic chain posteriorly, and the peritoneum and ureter anterolateral.
- Dissection progresses close to the ventral adventitial layer of the great vessels starting from the origin of the left common iliac artery up to the left renal vein.
- Posterolateral the left sympathetic chain and main postganglionic fibers arising from the second or third lumbar sympathetic ganglia to join the superior hypogastric plexus are carefully isolated from the lymphatic tissue and preserved.
- Cranially the left spermatic artery is controlled with bipolar coagulation at its origin and divided, then with bipolar coagulation the left renal vein is progressively dissected and the spermatic vein is clipped and divided close to the renal vein.

Avoid injury of a possible low renal artery or a lumbar vein during this dissection.

Early division of the right spermatic vessels is necessary to have the best exposure.

Avoid injury to the lumbar vessels or right renal artery while dissecting behind the left renal vein.

Right Para-Aortic Dissection

- As on the left side, you start dissecting from the right common iliac vessels in a cranial direction to free the lateral and anterior surfaces of the vena cava then the medial part of the aorta up to the left renal vein.
- All lymphatic tissue anterior, lateral, and posterior to the vena cava must be removed.
- On the left side the lumbar veins are respected as much as possible.
- Posterior vena caval dissection provides access to the interaortocaval nodes and facilitates their elevation from the perivertebral plane while sparing the main postganglionic nerves arising from the second or third right sympathetic ganglia.
- The intervacular dissection is finished anteriorly between the two great vessels and up to the left renal vein.

Resection of the Spermatic Vessels and Final Steps

- Resection of the spermatic vessels is the ultimate step.
- The lumbar portion of the vascular pedicle is freed from the posterior peritoneum down to where it joins the ureter.
- Now the instruments will be rearranged and the surgeon will use the iliac port for his instruments and the flank port for the laparoscope.
- The spermatic vessels will be dissected down to the distal ligature and completely removed extraperitoneally.
- The lymphatic tissue and the spermatic vessels are placed in an endoscopic bag and extracted through the iliac incision.
- Drainage is not necessary.

TECHNICAL CAVEATS

- Adequate homeostasis is of a crucial importance. Even minimal bleedings must be controlled and stopped instantly to provide a bloodless surgical field. The quality of the dissection had improved significantly since the introduction of grasping forceps for bipolar coagulation and dissection. These instruments are ideal for the dissection of delicate vessels such as the vena cava and renal veins. Broader bipolar forceps allows precise hemostasis without damaging the surrounding structures. The Harmonic scalpel may be used as well for a bloodless transection of the lymphatic tissue.
- A protruding[®] segment of bowel can cause insufficient exposure and may render the operation difficult, dangerous, and even impossible. The fan retractor used for the liver can retract the duodenum as well. Retraction of the bowel can be achieved by a surgical sponge held with a traumatic grasper. An additional trocar can be inserted in the midline just caudal to the costal margin for the introduction of a second fan retractor if required in exceptional cases. Exposure could be achieved in all instances and we have never converted to open surgery because of insufficient exposure.
- Acute bleeding is the most frequent complication. A small surgical sponge that is held with a traumatic grasper can be a substitute for the surgeon's finger to be used for dissection, retraction, or pressure to control bleeding vessels so that subsequent measures can be taken without the pressure of time. Small defects in veins and even the vena cava can be sealed by direct application of fibrin. A larger defect is approximated with an atraumatic grasper with or without the use of endoscopic clips even if they are not placed appropriately and tend to fall off then the defect is sealed by fibrin. The strength of the repair should be enhanced by the additional use of surgicel (oxidized regenerated cellulose) or similar hemostatic substances such as tachocomb. In exceptional conditions laparoscopic vascular suture repairs are feasible if needed (5,15,21).
- Instruments for general and vascular surgery must be available in the operating room in the event of bleeding that may not be controlled by endoscopic means.

SUMMARY

- To lower morbidity, retroperitoneal lymphadenectomy was modified over the past 35 years from extended suprahilar to bilateral infrahilar. Subsequently, a modified unilateral approach and then nerve-sparing procedures were refined.
- These operative refinements were not associated with increase in relapse rates.
- Significant factors for relapse include pathological stage ($p < 0.001$) and adjuvant chemotherapy in stage II disease ($p < 0.001$) (3).
- The future in this field may encompass the development of a technique that could exactly locate a sentinel lymph node for testicular cancer. Thereby the retroperitoneal lymph node dissection, with its diagnostic accuracy and its therapeutic value, could be applied to selected patients only (22, 23).

REFERENCES

1. Bost GJ, Motzer RJ. Testicular germ-cell cancer. *N Engl J Med* 1997; 337:242–253.
2. Bussar-Matz R, Weissbach L. Retroperitoneal lymph node staging of testicular tumours. TNM Study Group. *Br J Urol* 1993; 72:234–240.
3. Donhue JP, Thornhill JA, Foster RS, Roland RG, Bihle R. Retroperitoneal lymphadenectomy for clinical stage A testis cancer (1965–1989): modification of technique and impact on ejaculation. *J Urol* 1993; 149:243–237.
4. Williams SD, Stablein DM, Einhorn LH, et al. Immediate adjuvant chemotherapy versus observation with treatment at relapse in pathological stage II testicular cancer. *N Engl J Med* 1987; 317:1433–1438.
5. Steiner H, Peschel R, Janetschek G, et al. Long-term result of laparoscopic retroperitoneal lymph node dissection: a single-center 10 years experience. *Urology* 2004; 63:550–555.
6. Corvin S, Kuczyk M, Anastasiadis A, Stenzl A. Laparoscopic retroperitoneal lymph node dissection for nonseminomatous testicular carcinoma. *World J Urol* 2004; 22:33–36.
7. Rassweiler JJ, Frede T, Lenz E, Seemann O, Alken P. Long-term experience with laparoscopic retroperitoneal lymph node dissection in the management of low-stage testis cancer. *Eur Urol* 2000; 37:251–260.
8. Bhayani SB, Allaf ME, Kavoussi LR. Laparoscopic retroperitoneal lymph node dissection for clinical stage I nonseminomatous germ cell testicular cancer: current status. *Urol Oncol* 2004; 22:145–148.
9. Rassweiler JJ, Seemann O, Henkel TO, Stock C, Frede T, Alken P. Laparoscopic retroperitoneal lymph node dissection for non seminomatous germ cell tumour: indication and limitation. *J Urol* 1996; 156:1108–1113.
10. Janetschek G. Laparoscopic retroperitoneal lymph node dissection. *Urol Clin North Am* 2001; 28:107–114.
11. Laguna MP, Klepp O, Horwich A, et al. Guidelines on Testicular Cancer. European Association of Urology Update, March 2004.
12. Sogani PC, Perrotti M, Herr HW, Fair WR, Thaler HT, Bosl G. Clinical stage I testis cancer: long-term outcome of patients on surveillance. *J Urol* 1998; 159:855–858.
13. Nicolai R, Pizzocaro G. A surveillance study of clinical stage I non-seminomatous germ cell tumours of the testis: 1-year follow up. *J Urol* 1995; 154:1045–1049.
14. Gullen MH, Stenning SP, Parkinson MC, et al. High-risk stage I non-seminomatous germ cell tumours of the testis. A Medical Research Council Report. *J Clin Oncol* 1996; 14:1106–1113.
15. Janetschek G, Hobisch A, Hittmair A, Holtl L, Peschel R, Bartsch G. Laparoscopic retroperitoneal lymphadenectomy after chemotherapy for stage IIB Nonseminomatous Testicular carcinoma. *J Urol* 1999; 161:477–481.
16. Klingler HC, Remzi M, Janetschek G, Marberger M. Benefits of laparoscopic renal surgery are more pronounced in patients with a high body mass index. *Europ Urol* 2003; 43:522–527.
17. Weissbach L, Boedefeld EA. Testicular tumour study group: localization of solitary and multiple metastases in stage II non seminomatous testis tumour as basis for modified staging lymph node dissection in stage I. *J Urol* 1987; 138:77–82.
18. Holtl L, Peschel R, Knapp R, et al. Primary lymphatic metastatic spread in testicular cancer occurs ventral to the lumbar vessels. *Urology* 2002; 59:114–118.
19. Janetschek G, Peschel R, Bartsch G. Laparoscopic retroperitoneal lymph node dissection. *Atlas Urol Clin North Am* 2000; 8:71–90.
20. Le Blanc E, Caty A, Dargent D, Querleu D, Mazeman E. Extraperitoneal laparoscopic para-aortic lymph node dissection for early stage non seminomatous germ cell tumour of the testis with introduction of a nerve sparing technique description and results. *J Urol* 2001; 165:89–92.
21. Janetschek G, Hobisch A, Peschel R, Bartsch G. Laparoscopic retroperitoneal lymph node dissection. *Urology* 2000; 55:136–140.
22. Sotoh M, Ito A, Mitsuzuka K, et al. Sentinel node detection and extraperitoneal laparoscopic retroperitoneal lymph node dissection under gamma probe guidance with clinical stage I testicular cancer. *J Endourol* 2003; 17(suppl):A67.
23. Pizzocaro G, Nicolai R, Salvioni R. Evaluation and controversies in management of low-stage non-seminomatous germ cell tumours of the testis. *World J Urol* 1994; 12:113–119.

CHAPTER 52

LAPAROSCOPIC RETROPERITONEAL LYMPH NODE DISSECTION FOR CLINICAL STAGE I NONSEMINOMATOUS GERM CELL TESTICULAR CANCER: CURRENT STATUS

Sam B. Bhayani and Louis R. Kavoussi

Johns Hopkins Medical Institutions, Baltimore, Maryland, U.S.A.

- INTRODUCTION
- DIFFERENCES IN LAPAROSCOPIC RETROPERITONEAL LYMPH NODE DISSECTIONS
- EFFICACY OF TREATMENT OPTIONS
- COMPLICATIONS OF LAPAROSCOPIC RETROPERITONEAL LYMPH NODE DISSECTION
- POSTCHEMOTHERAPY LAPAROSCOPIC RETROPERITONEAL LYMPH NODE DISSECTION
- SUMMARY
- REFERENCES
- COMMENTARY: Jerome P. Richie

INTRODUCTION

Clinical stage I nonseminomatous germ cell tumors can be approached by several successful treatment strategies.

Surveillance, primary chemotherapy, and open retroperitoneal lymph node dissection all demonstrate equivalent outcomes when applied appropriately. As such, morbidity of the treatment becomes the major factor when selecting treatment.

Surveillance fundamentally depends upon dedicated follow up that may be challenging in a younger patient population. Failure to detect recurrence early results in the suboptimal outcome compared with other treatment options. Primary chemotherapy, largely used in Europe, has equal efficacy as the open retroperitoneal lymph node dissection, and additionally will treat disease outside of the retroperitoneum (1). However, long-term side effects of primary chemotherapy remain, including cardiac toxicity, infertility, and late hematological malignancy.

Despite the proven efficacy of open retroperitoneal lymph node dissection, approximately 70% of patients have pathologically negative nodes, and may derive no therapeutic benefit from surgery (2–5).

Although the long-term morbidity of open retroperitoneal lymph node dissection is minimal, the procedure relies on a large and cosmetically undesirable incision, with significant convalescence times and permanent physical scars.

Laparoscopic retroperitoneal lymph node dissection was developed to allow for the diagnostic and therapeutic benefits of open retroperitoneal lymph node dissection, without its inherent morbidity. It may represent a minimally invasive alternative to open retroperitoneal lymph node dissection and primary chemotherapy. Proponents of the procedure are demonstrating its efficacy as a replacement for open retroperitoneal lymph node dissection (6).

DIFFERENCES IN LAPAROSCOPIC RETROPERITONEAL LYMPH NODE DISSECTIONS

Laparoscopic retroperitoneal lymph node dissection may be used as a staging or a therapeutic procedure.

As most patients undergoing open retroperitoneal lymph node dissection or chemotherapy are treated unnecessarily (as they have no metastases), a minimally morbid approach to staging the retroperitoneum is highly attractive. In European series, laparoscopic retroperitoneal lymph node dissection serves this purpose and helps delineate those who have metastases and require chemotherapy versus those who may be more safely observed.

Surveillance, primary chemotherapy, and open retroperitoneal lymph node dissection all demonstrate equivalent outcomes when applied appropriately. As such, morbidity of the treatment becomes the major factor when selecting treatment.

Despite the proven efficacy of open retroperitoneal lymph node dissection, approximately 70% of patients have pathologically negative nodes, and may derive no therapeutic benefit from surgery.

Laparoscopic retroperitoneal lymph node dissection may represent a minimally invasive alternative to open retroperitoneal lymph node dissection and primary chemotherapy.

Laparoscopic retroperitoneal lymph node dissection may be used as a staging or therapeutic procedure.

TABLE 1 ■ Treatment Options for Clinical Stage I Nonseminomatous Germ Cell Tumors

Treatment	Typical recurrence (%)	Recurrence treated with	Success rate (%)	Advantages	Disadvantages
Surveillance	30	3 cycles chemotherapy	>95	No patients treated unnecessarily	Requires rigorous follow-up; 3 cycles of chemotherapy significantly more toxic than 2
Primary chemotherapy	<5	Chemotherapy or surgery	>95	No invasive procedures	70% of patients treated unnecessarily
Open retroperitoneal lymph node dissection	<5	Chemotherapy	>95	Accurate staging	70% patients treated unnecessarily with laparotomy incision, 30% of pIIa patients recur
Staging laparoscopic retroperitoneal lymph node dissection with 2 cycles of chemotherapy for positive nodes	<5	Chemotherapy or surgery	>95	Accurate staging with advantages of laparoscopy	Patients with positive nodes receive 2 treatments (laparoscopy and chemotherapy)
Therapeutic laparoscopic retroperitoneal lymph node dissection	<5	Chemotherapy	>95	Accurate staging with advantages of laparoscopy	Most patients have received chemotherapy due to philosophy of oncologists; without chemotherapy results should mirror open retroperitoneal lymph node dissection. More studies needed

Abbreviation: RPLND, retroperitoneal lymph node dissection.

As a staging procedure, laparoscopic retroperitoneal lymph node dissection is typically performed without retrocaval or retroaortic dissection, and is used to delineate pathologic status. The therapeutic efficacy of this more limited dissection is unknown.

As a staging procedure, laparoscopic retroperitoneal lymph node dissection is typically performed without retrocaval or retroaortic dissection, and is used to delineate pathologic status (7). The therapeutic efficacy of this more limited dissection is unknown. As a therapeutic procedure, laparoscopic retroperitoneal lymph node dissection is also effective.

This approach, currently used at Johns Hopkins, limits relapses to outside the template, and may be offered as a singular, primary treatment option, analogous to open retroperitoneal lymph node dissection. Patients with pathological stage II disease can then be observed or treated with chemotherapy per their preference.

The goal of the therapeutic laparoscopic retroperitoneal lymph node dissection is to limit retroperitoneal relapse. All nodal tissue within the template must be excised, including retroaortic and retrocaval tissue.

EFFICACY OF TREATMENT OPTIONS

The goal of the therapeutic laparoscopic retroperitoneal lymph node dissection is to limit retroperitoneal relapse. All nodal tissue within the template must be excised, including retroaortic and retrocaval tissue.

All treatments of clinical stage I nonseminomatous germ cell are effective (Table 1). As such, the choice for treatment is ultimately dependent on patient preference and

Laparoscopic staging retroperitoneal lymph node dissection can evaluate for metastases with minimal long-term morbidity, but requires two cycles of adjuvant chemotherapy. Therapeutic laparoscopic retroperitoneal lymph node dissection offers all the advantages of open retroperitoneal lymph node dissection without the incision, but studies often include treatment with chemotherapy and randomized studies are lacking.

comfort with treatment modalities. Surveillance has the advantage of having no patients unnecessarily treated. The main disadvantage is the three cycles of chemotherapy involved for recurrence, and compliance with the rigorous followup schedule. Primary chemotherapy unnecessarily treats 70% of patients who garner no advantage because they harbor no metastases. These patients are exposed to the long-term toxicity of the chemotherapeutic agents. Open retroperitoneal lymph node dissection has the same disadvantage of over treatment and additionally patients have the lifelong cosmetic disadvantage of the open incision. Furthermore, 30% of patients with metastases will recur and require chemotherapy.

Laparoscopic staging retroperitoneal lymph node dissection can evaluate for metastases with minimal long-term morbidity, but requires two cycles of adjuvant chemotherapy. Therapeutic laparoscopic retroperitoneal lymph node dissection offers all the advantages of open retroperitoneal lymph node dissection without the incision, but studies often include treatment with chemotherapy and randomized studies are lacking.

Unfortunately, high volume centers treating testis cancer have been slow to adopt laparoscopic techniques and as such, comparing the efficacy of open retroperitoneal lymph node dissection to laparoscopic retroperitoneal lymph node dissection is difficult and requires indirect measures. These comparisons are confounded by surgical differences between the major centers performing laparoscopic retroperitoneal lymph node dissection, and by philosophical differences with regard to postoperative chemotherapy.

All laparoscopic retroperitoneal lymph node dissections are not equal. In the Austrian series, laparoscopic retroperitoneal lymph node dissection in the clinical stage I patient is performed as a staging tool, and nodes are not routinely removed posterior to the lumbar vessels. The rationale for performing this more limited retroperitoneal lymph node dissection relies on the lack of an isolated retrocaval or retroaortic positive node based on pathological analyses of the authors' series (7,8). Furthermore, as the procedure is performed as a staging procedure, the goal is to identify patients who require chemotherapy, and then treat those with positive nodes. In the Johns Hopkins experience, the procedure has evolved. Initially, the procedure was aborted if multiple positive nodes were found, because chemotherapy would be instituted in these cases (9). Because technological advances in instrumentation, suturing, and hemostasis have evolved, a traditional approach is the norm. Currently, an exact replication of the open template is performed on all patients with clinical stage I nonseminomatous germ cell, with complete excision of retroaortic and retrocaval tissue, thus rendering the procedure both a staging and therapeutic procedure.

Despite the more complete lymphatic excision of therapeutic laparoscopic retroperitoneal lymph node dissection, it is the philosophy of some medical oncology departments to routinely give two cycles of chemotherapy in all patients with positive nodes at lymph-adenectomy, rather than risk the chance of recurrence and progression and later treatment with a higher dose of chemotherapy. It is unknown if the long-term sequelae with a modified chemotherapy regimen is similar to that seen with traditional three cycles.

From a surgical perspective, laparoscopic retroperitoneal lymph node dissection should duplicate the open template to maintain established oncological principles, particularly if a patient with pathological stage II disease should choose observation rather than adjuvant treatment.

Use of adjuvant chemotherapy has elicited a major concern: is the laparoscopic retroperitoneal lymph node dissection an adequate "clean-out" of the retroperitoneum or is the chemotherapy masking retroperitoneal nodes that were missed? This question can be answered with another method to compare the open and laparoscopic retroperitoneal lymph node dissection: examination of the patients with pathologic stage I disease. If the laparoscopic retroperitoneal lymph node dissection were inadequate, certainly patients would be misdiagnosed with pathological stage I disease, and the positive lymph nodes in the retroperitoneum would be missed, thus leading to a retroperitoneal recurrence. This supposition has not occurred, because no retroperitoneal recurrences have been reported in our experience or from recent University of Washington data (6,10).

Despite the indirect efficacy of laparoscopic retroperitoneal lymph node dissection, a randomized direct comparison to open retroperitoneal lymph node dissection is theoretically the best approach to establish equal efficacy. Such a comparison has not been performed with other accepted laparoscopic procedures such as tubal ligation, cholecystectomy, gastric fundoplication, adrenalectomy, nephrectomy, or nephroureterectomy.

From a surgical perspective, laparoscopic retroperitoneal lymph node dissection should duplicate the open template to maintain established oncological principles, particularly if a patient with pathological stage II disease should choose observation rather than adjuvant treatment.

With these procedures, it has been apparent that the laparoscopic approach differs from the open approach primarily with regard to access of the abdomen, and intra-abdominal manipulations are similar, if not exact. The oncological community has not assessed laparoscopic retroperitoneal lymph node dissection with these same standards, but ultimately, as more centers offer therapeutic laparoscopic retroperitoneal lymph node dissection, the procedure is likely to replace the open procedure as a new standard to treat clinical stage I nonseminomatous germ cell.

The major complication reported during laparoscopic retroperitoneal lymph node dissection is hemorrhage.

Lymphocele formation is also a complication, more commonly seen in early experience.

Retrograde ejaculation has been reported at a rate similar to that seen with open retroperitoneal lymph node dissection.

Postchemotherapy retroperitoneal lymph node dissection should be attempted only by experienced laparoscopists, and patients should be aware of the possibility of open conversion.

COMPLICATIONS OF LAPAROSCOPIC RETROPERITONEAL LYMPH NODE DISSECTION

The major complication reported during laparoscopic retroperitoneal lymph node dissection is hemorrhage (6,9).

Early in the experience of the procedure hemorrhage necessitated conversion to an open procedure and occasionally blood transfusion. These complications reflect a different era of laparoscopic surgery, in which instrumentation, suturing technology, and hemostatic aids were not available. Currently, techniques have been developed to deal with potential hemorrhage.

Lymphocele formation is also a complication, more commonly seen in early experience. As with open surgery, this can be avoided with careful clipping of lymphatic channels.

Retrograde ejaculation has been reported at a rate similar to that seen with open retroperitoneal lymph node dissection (6).

POSTCHEMOTHERAPY LAPAROSCOPIC RETROPERITONEAL LYMPH NODE DISSECTION

Postchemotherapy laparoscopic retroperitoneal lymph node dissection is considered a different surgery than the version used for clinical stage I nonseminomatous germ cell. The dissection is more extensive, and more difficult secondary to residual masses and tissue reaction to chemotherapeutic agents. In one series of seven patients, a 42% major complication rate was reported (11). This was the initial series, and involved the learning curve with the procedure. In another series of 68 patients, a 0% complication rate was reported (8). The dissection boundaries in the latter series are unclear. Larger studies with long-term outcomes are needed to evaluate the ultimate efficacy of this approach. Duplication of the open dissection and template is essential.

Postchemotherapy retroperitoneal lymph node dissection should be attempted only by experienced laparoscopists, and patients should be aware of the possibility of open conversion.

SUMMARY

- Laparoscopic retroperitoneal lymph node dissection for the treatment of clinical stage I nonseminomatous germ cell has evolved into an excellent alternative to traditional modes of therapy.
- The procedure can replicate the advantages of open retroperitoneal lymph node dissection without the morbidity of a large incision.
- Although all treatment modalities are effective in low stage nonseminomatous germ cell, laparoscopic retroperitoneal lymph node dissection offers a minimally invasive approach to the disease.
- Further studies comparative studies of primary chemotherapy, open retroperitoneal lymph node dissection, and laparoscopic retroperitoneal lymph node dissection are needed from high volume centers to elucidate differences in therapy.

REFERENCES

1. Jones RH, Vasey PA. Part I: testicular cancer—management of early disease. *Lancet Oncol* 2003; 4(12):730–737.
2. Foster RS, Donohue JP. Retroperitoneal lymph node dissection for the management of clinical stage I nonseminoma. *J Urol* 2000; 163(6):1788–1792.

3. Donohue JP, Thornhill JA, Foster RS, Rowland RG, Bihle R. Primary retroperitoneal lymph node dissection in clinical stage. A nonseminomatous germ cell testis cancer. Review of the Indiana University experience 1965–1989. *Br J Urol* 1993; 71(3):326–335.
4. Richie JP. Clinical stage I testicular cancer: the role of modified retroperitoneal lymphadenectomy. *J Urol* 1990(Nov); 144(5):1160–1163.
5. Sternberg CN. The management of stage I testis cancer. *Urol Clin North Am* 1998; 25(3):435–449.
6. Bhayani SB, Ong A, Oh WK, Kantoff PW, Kavoussi LR. Laparoscopic retroperitoneal lymph node dissection for clinical stage I nonseminomatous germ cell testicular cancer: a long-term update. *Urology* 2003; 62(2):324–327.
7. Janetschek G, Peschel R, Hobisch A, Bartsch G. Laparoscopic retroperitoneal lymph node dissection. *J Endourol* 2001; 15(4):449–453; discussion 453–455.
8. Steiner H, Peschel R, Janetschek G, et al. Long term results of laparoscopic retroperitoneal lymph node dissection: a single center 10 year experience. *Urology* 2004; 63(3):550–555.
9. Nelson JB, Chen RN, Bishoff JT, et al. Laparoscopic retroperitoneal lymph node dissection for clinical stage I nonseminomatous germ cell testicular tumors. *Urology*. 1999; 54(6):1064–1067.
10. Porter J. Laparoscopic retroperitoneal lymph node dissection. In: Smith AD, eds. *Smith's Textbook of Endourology*. BC Decker 2006.
11. Palese MA, Su LM, Kavoussi LR. Laparoscopic retroperitoneal lymph node dissection after chemotherapy. *Urology* 2002; 60(1):130–134.

COMMENTARY

Jerome P. Richie

Harvard Medical School, Boston, Massachusetts, U.S.A.

The exceedingly high likelihood of cure for patients with clinical stage I non-seminomatous germ cell tumor dramatically increases the import of potential morbidity, quality of life, and long-term side effects of the treatment regimen. The rigorous follow-up schedule for surveillance and the need for chemotherapy in approximately 25% of patients limit this appealing option to patients with very favorable characteristics. Primary chemotherapy may overtreat many patients and long-term side effects of primary chemotherapy have not been elucidated.

Standard template and nerve-sparing retroperitoneal lymph node dissection has proven efficacy as both a staging and a therapeutic modality, providing important information about retroperitoneal nodal involvement and curing the vast majority of patients without the need for chemotherapy. To date, laparoscopic retroperitoneal lymph node dissection (retroperitoneal lymph node dissection) is a staging modality, but has not proven itself to have therapeutic efficacy. Until longer-term studies can demonstrate that laparoscopic retroperitoneal lymph node dissection is as effective therapeutically as open retroperitoneal lymph node dissection (avoiding the need for chemotherapy postoperatively), laparoscopic retroperitoneal lymph node dissection will still be considered an extension of staging techniques.

Complications of laparoscopic retroperitoneal lymph node dissection, including hemorrhage or chylous ascites, have decreased in incidence in centers of excellence. Nonetheless, because of the relative rarity of patients with low-stage testicular tumor, a steep learning curve may preclude general application of these techniques.

The potential reduction in morbidity, shorter length of stay, and avoidance of a large midline abdominal incision are appealing features of laparoscopic retroperitoneal lymph node dissection, but proof of therapeutic efficacy will be mandatory before this type of procedure can be considered equivalent to open retroperitoneal lymph node dissection.

LAPAROSCOPIC PELVIC LYMPHADENECTOMY FOR PROSTATE AND BLADDER CANCER

Antonio Finelli

Section of Laparoscopic and Minimally Invasive Surgery, University of Toronto, Toronto, Ontario, Canada

- INTRODUCTION
- PROSTATE CANCER
 - Current Status of Pelvic Lymph Node Dissection in Disease Management
 - Laparoscopic Technique
 - Outcomes
- SUMMARY: PELVIC LYMPH NODE DISSECTION FOR PROSTATE CANCER
- BLADDER CANCER
 - Current Status of Pelvic Lymph Node Dissection in Disease Management

- Laparoscopic Technique
- Outcomes

- SUMMARY: PELVIC LYMPH NODE DISSECTION FOR BLADDER CANCER
- PORT-SITE TUMOR SEEDING AND LOCAL RECURRENCE
- SUMMARY
- REFERENCES

INTRODUCTION

Surgery is an effective form of treatment for most localized solid tumors of the genitourinary system. However, lymph node metastases are a significant prognostic factor in urologic malignancy and lymphadenectomy is therapeutic in certain instances. With the advent of laparoscopy, pelvic lymphadenectomy became a popular and frequently performed procedure for staging prostate cancer in the 1990s. Laparoscopy has continued to gain momentum in the management of urologic tumors and laparoscopic radical cystectomy with complete intracorporeal urinary diversion has become a reality. The role of pelvic lymphadenectomy in the management of prostate cancer, as well as bladder cancer, continues to be defined.

PROSTATE CANCER

Current Status of Pelvic Lymph Node Dissection in Disease Management

While there is no consensus in the literature, the most common pelvic lymph node dissection performed for prostate cancer is a limited obturator lymph node dissection (1,2). The obturator space is bound caudally by the pubic bone, cranially by the bifurcation of common iliac artery, laterally by the external iliac vessels and inferiorly by the obturator nerve. Although it is generally believed that the obturator space is the primary landing site of prostate cancer nodal metastasis, anatomical series have demonstrated that the primary landing site may actually be in the internal iliac lymph node chain (3,4). Studies utilizing radioisotope guided dissection have confirmed the heterogeneous nature of prostatic lymph node drainage (5,6).

Historically, prostate cancer series have included a relatively high rate (up to 29%) of patients with pelvic lymph node metastasis (7). However, with stage migration in the prostate specific antigen era, contemporary open radical prostatectomy series have positive lymph node detection rates below 6% (8–10). To further stratify patients at risk for lymph node metastases, low risk and high-risk categories have been defined. Preoperative prostate specific antigen ≤ 10 ng/mL, Gleason Sum ≤ 6 , and clinical stage $\leq T_1c$ is considered low risk whereas, high risk patients have a prostate specific antigen > 10 and/or Gleason ≥ 7 and/or clinical stage $\leq T_2$ (10–12). Since the likelihood of lymph node metastases is low ($<2\%$), pelvic lymph node dissection is often omitted in the low-risk patients.

Recently, there have been studies supporting a more extended pelvic lymph node dissection in the management of prostate cancer (13,14). In a series of 365 patients undergoing extended pelvic lymph node dissection, 88 (24%) of patients had positive lymph nodes (13). Interestingly, of the 88 patients with positive nodes, 51 (58%) had

Recently, there have been studies supporting a more extended pelvic lymph node dissection in the management of prostate cancer.

nodal metastases along the internal iliac artery. Furthermore, 17 (19%) of the patients had nodal involvement only in this location and thus, it was concluded that a standard limited obturator lymph node dissection would have missed 19% of patients with node positive disease. In a similar study, 203 consecutive patients (103 extended pelvic lymph node dissection and 100 standard lymphadenectomy) were evaluated post radical retropubic prostatectomy (14). The incidence of lymph node metastases was 26% in the extended lymphadenectomy group versus 12% in the standard group ($p < 0.03$). In the extended pelvic lymph node dissection group, 26 patients (42%) had nodal metastases outside the standard template and of these patients, 9 (34%) had lymph nodes positive only outside the standard template. Using a cutoff off prostate specific antigen ≤ 10.5 ng/mL and biopsy obtained Gleason Sum ≤ 6 , 139 patients (68.5%) would be classified as low risk. If this cohort had not undergone any lymphadenectomy, only four patients would have been missed (false negative rate 2.4%). Thus, the authors of this study concluded that extended lymph node dissection should be performed for highrisk patients only thereby increasing the detection of positive nodes by 14%. Bader et al. (15) presented follow-up data on a series of 92 patients with metastatic nodes at the time of prostatectomy. Over a median follow-up of 45 months, 21 patients (23%) had prostate specific antigen recurrence free survival. Whilst this report does not convincingly demonstrate improved survival over an intermediate follow-up, extended pelvic lymph node dissection may benefit a small percentage of patients.

Laparoscopic Technique

Laparoscopic pelvic lymphadenectomy was one of the original laparoscopic urologic procedures described in 1991 (16,17).

Concomitant pelvic lymph node dissection can be performed during either transperitoneal or extraperitoneal laparoscopic radical prostatectomy (18). If the lymphadenectomy is being performed in conjunction with radical prostatectomy, the port placement should be that preferred for laparoscopic prostatectomy. Most commonly, a five-port "fan" or "horseshoe" distribution is used. After pneumoperitoneum is established, 10-mm trocars are placed at the umbilicus and at the lateral edge of the right rectus muscle. A 5-mm port is placed one fingerbreadth medial and cephalad to the anterior superior iliac spine. Two 5-mm ports are then placed in comparable positions on the left side. If a separate staging laparoscopic pelvic lymph node dissection is being performed, a diamond configuration is utilized with 10-mm trocars placed at the umbilicus and 5 cm above the pubic symphysis in the midline. Additional 5-mm ports are placed bilaterally in the midclavicular line near McBurney's point.

Orientation is initially achieved by noting external iliac artery pulsations and the anatomic location of the internal ring. The peritoneum overlying the external iliac artery and/or on the external iliac vein is opened sharply. A combination of blunt and sharp dissection is used to skeletonize the posterior surface of the external iliac vein, dissecting the obturator node packet off the pelvic sidewall in the direction of the pubic bone. Once the obturator nerve is clearly identified along the posterior edge of the lymph node packet, the distal aspect of the nodal packet can be safely clipped and divided at the pubic bone. Throughout the dissection, the obturator nerve is kept in view. The nodal packet is gently dissected and reflected cephalad toward the bifurcation of the common iliac vein. The nodal packet is clipped parallel to the obturator nerve, detached and extracted with an endoscopic spoon biopsy forceps.

Outcomes

More than 20 publications since 1992 have addressed the outcomes of laparoscopic pelvic lymph node dissection (19–26). Historically, laparoscopic pelvic lymph node dissection had been compared to open pelvic lymph node dissection and minilaparotomy pelvic lymph node dissection, but currently staging pelvic lymph node dissection is rarely performed as an independent procedure. Thus, the majority dissections are performed through a midline incision during retropubic prostatectomy or laparoscopically with ports placed in anticipation of performing radical prostatectomy.

In general, the efficacy of laparoscopic pelvic lymph node dissection is comparable to open pelvic lymph node dissection.

Parra et al. (22) demonstrated a comparable yield of lymph nodes (10.7 vs. 11) for laparoscopic and open pelvic lymph node dissection, respectively. Kerbl et al. (20) compared 30 patients undergoing laparoscopic pelvic lymph node dissection with 16 patients undergoing open pelvic lymph node dissection. Laparoscopy was associated with a longer operating time (199 minutes vs. 102 minutes), and a 13% complication rate. Herrell et al. (24) compared laparoscopic pelvic lymph node dissection to open and minilaparotomy pelvic lymph node dissection. The three groups had equivalent staging efficacy, but

Concomitant pelvic lymph node dissection can be performed during either transperitoneal or extraperitoneal laparoscopic radical prostatectomy.

In general, the efficacy of laparoscopic pelvic lymph node dissection is comparable to open pelvic lymph node dissection.

The rate of complications associated with laparoscopic pelvic lymph node dissection ranges from 0% to 22% as opposed to 0% to 13% for open pelvic lymph node dissection. However, these reports were published between 1992 and 1997 and with greater laparoscopic experience, one would anticipate diminished complication rates.

laparoscopic and minilaparotomy pelvic lymph node dissection were associated with decreased length of hospital stay and complications. Laparoscopic pelvic lymph node dissection required a longer operative time.

Stone et al. (25) compared modified ($N = 150$) with extended laparoscopic pelvic lymph node dissection ($N = 39$). This study revealed the feasibility of laparoscopic extended pelvic lymph node dissection for prostate cancer wherein the obturator, hypogastric, common and external iliac nodes were retrieved. However, the extended group had an increased complication rate, 36% versus 2%. Presently, limited pelvic lymph node dissection for laparoscopic radical prostatectomy adds approximately 30 minutes to the operating time.

The rate of complications associated with laparoscopic pelvic lymph node dissection ranges from 0% to 22% as opposed to 0% to 13% for open pelvic lymph node dissection (19–26). However, these reports were published between 1992 and 1997 and with greater laparoscopic experience, one would anticipate diminished complication rates.

In a series of 100 consecutive laparoscopic pelvic lymph node dissection, the rate of complication was 25% for the first 20 cases and 5% for the subsequent 80 cases (21). Complications in contemporary series compare favorably with prior published open series (27).

SUMMARY: PELVIC LYMPH NODE DISSECTION FOR PROSTATE CANCER

- Currently, controversy regarding pelvic lymph node dissection for prostate cancer is focused on the issue of which patients should have a pelvic lymphadenectomy and whether it should be limited or extended, rather than laparoscopic versus open.
- The development of nomograms and preoperative predictive models have aided in identifying low risk patients, decreasing the necessity for unnecessary pelvic lymph node dissection.
- Further studies are required to clarify the exact extent of lymph node dissection in higher risk patients.

BLADDER CANCER

Current Status of Pelvic Lymph Node Dissection in Disease Management

Review of contemporary cystectomy series demonstrates a lymph node positive rate of ~25% (28,29). There is evidence to support the therapeutic role of pelvic lymph node dissection in bladder cancer.

In a large cohort of patients undergoing radical cystectomy and pelvic lymph node dissection, patients with pN+ disease ($N = 244$), experienced 5- and 10-year recurrence-free survival rates of 35% and 34%, respectively (28). Both the anatomic extent of lymphadenectomy (30–32) and the number of nodes involved with metastatic disease are regarded as important independent factors (32–34). Patients with fewer than four lymph nodes involved with metastases fare better than those with five or more positive nodes (33).

Classically, the boundaries of a pelvic lymph node dissection for bladder cancer include the genitofemoral nerve laterally, bladder medially, node of Cloquet distally and the bifurcation of the common iliac artery proximally. Skinner described an extended dissection that includes the lymphatic tissue 2–3 cm above the aortic bifurcation (35).

Although the proximal extent of lymphadenectomy for bladder cancer continues to be debated, all patients undergoing cystectomy with curative intent should have a bilateral pelvic lymph node dissection since bladder tumors metastasize bilaterally even if they are focal and unilateral (36,37).

In an anatomic mapping study of lymph nodes removed during extended pelvic lymph node dissection for bladder cancer, it was demonstrated that in 29 patients who only had metastases to one lymph node, this solitary involved node was never in the presacral, paracaval, interaortocaval or paraaortic areas (37). Furthermore, metastases to the paraaortic, interaortocaval, or paracaval regions only occurred when nine or more lymph nodes from more distal landing zones were positive (37). Thus, the majority of patients with proximal lymph node metastases have more distal disease.

Recently, there has been an attempt to determine the minimum number of lymph nodes that should be removed and examined. An earlier report, demonstrated a cancer-specific survival of 65% versus 51% when 15 lymph nodes or more were removed at cystectomy compared to 15 or less, respectively (31). More recent studies have also found that the number of lymph nodes retrieved, regardless of whether metastases were diagnosed, correlated with survival (32,34). Herr et al. (32) demonstrated improved local control and an overall survival advantage for both pN+ and pN0 patients when more than 11 and 8 lymph nodes were removed, respectively.

Review of contemporary cystectomy series demonstrates a lymph node positive rate of ~25%. There is evidence to support the therapeutic role of pelvic lymph node dissection in bladder cancer.

Although the proximal extent of lymphadenectomy for bladder cancer continues to be debated, all patients undergoing cystectomy with curative intent should have a bilateral pelvic lymph node dissection since bladder tumors metastasize bilaterally even if they are focal and unilateral.

There is evidence to support a more extensive lymphadenectomy and thus, patients undergoing laparoscopic radical cystectomy with curative intent should have a meticulous pelvic lymph node dissection with at least 15 lymph nodes removed and examined.

We elect to perform pelvic lymph node dissection after cystectomy in order not to compromise tissue planes.

A review of patients undergoing radical cystectomy and pelvic lymph node dissection from the National Cancer Institute Surveillance, Epidemiology and End Results database confirmed the correlation between number of lymph nodes removed and survival (34). The authors concluded that a minimum of 10 to 14 nodes should be examined (34). To further discriminate survival and local control outcomes, the concepts of ratio-based lymph node staging (38) and lymph node density (28) were proposed. A cut-point of 20% correlated with a statistically significant improvement in recurrence-free survival at 10 years. Furthermore, improved survival has been reported in patients with grossly positive nodes undergoing an extended pelvic lymph node dissection (39).

There is evidence to support a more extensive lymphadenectomy and thus, patients undergoing laparoscopic radical cystectomy with curative intent should have a meticulous pelvic lymph node dissection with at least 15 lymph nodes removed and examined.

Laparoscopic Technique

Our technique of laparoscopic radical cystectomy with completely intracorporeal construction of urinary diversion (40) and laparoscopic extended pelvic lymph node dissection have previously been described (41). With the patient in a modified dorsal lithotomy position, a transperitoneal five-port technique is employed. A modification for extended pelvic lymph node dissection involves placing the primary port in a supra-umbilical position to facilitate proximal dissection to the aortic bifurcation. Cystectomy is performed initially, followed by pelvic lymph node dissection beginning with the right side. We elect to perform pelvic lymph node dissection after cystectomy in order not to compromise tissue planes.

The patient is tilted 30° up on the right side and with 30° Trendelenburg. Although we prefer J-hook electrocautery as our primary instrument of dissection, coagulating laparoscopic endoshears with or without bipolar electrocautery is also effective. The lateral border of the dissection is developed medial to the genitofemoral nerve exposing the iliopsoas muscle. The fibroareolar and lymphatic tissue packet is lifted en bloc off the surface of the iliopsoas and swept medially, posterior to the external iliac artery and vein after the tissue anterior to the external iliac artery and vein is individually split longitudinally using J-hook electrocautery. The external iliac vein typically appears flat with standard (15 mmHg) pneumoperitoneum pressures. To enhance visualization of the vein and its edges the pneumoperitoneum pressure can be decreased to 5 mmHg. The obturator lymph node tissue is carefully dissected off the obturator nerve and maintained in continuity with the tissue that had been dissected off the external iliac artery and vein. A large clip is applied distally, and endoshears, are used to release the lymphatic tissue packet from this location.

One of the initial steps in laparoscopic radical cystectomy is dissection and transection of the ureters. The transected ureters are mobilized away and tacked to the sidewall facilitating cephalad dissection along the common iliac artery during pelvic lymph node dissection. The common iliac artery is circumferentially mobilized and retracted with a vessel loop to improve access to the lymphatic tissue in the area immediately distal to the aortic bifurcation. Upon completion of the proximal dissection, the specimen is immediately placed in an impermeable sac. Throughout the dissection, care must be taken to avoid cutting into any enlarged lymph node(s). Lymphadenectomy is similarly performed on the left side, but with the patient now tilted 30° up on that side. For the left-sided pelvic lymph node dissection, the surgeon may stand on the right side of the patient.

Outcomes

Although laparoscopic radical cystectomy has been the discussion of several reports, little attention has been given to the yield and extent of lymphadenectomy. We recently reviewed our technique and results with laparoscopic extended pelvic lymph node dissection (41). Initially, the bifurcation of the common iliac arteries constituted our proximal border (Group I). Commencing August 2002, our dissection included tissue overlying the proximal common iliac artery to the aortic bifurcation (Group II). The extended dissection required an additional 1 to 1.5 hours of operative time. Median number of nodes removed was 3 and 21 for Groups I and II, respectively ($p = 0.001$). Three patients in each group had pN+ disease. During extended pelvic lymph node dissection, an injury to a deep pelvic vein, managed with intracorporeal suturing, resulted in a 200 mL blood loss. Two other patients in this group developed deep venous thrombosis. There were no port site recurrences over a mean follow-up of 11 months (range, 2–43).

SUMMARY: PELVIC LYMPH NODE DISSECTION FOR BLADDER CANCER

- All patients undergoing radical cystectomy with curative intent should have a pelvic lymph node dissection.
- A minimum of 10 to 14 lymph nodes should be removed and microscopically examined.
- Although the proximal border of the lymphadenectomy is trending to migrate cephalad, with documented evidence of improved survival as more lymph nodes are removed, the true benefit of an extended dissection has not been demonstrated with well-designed prospective trials.
- For the time being, albeit a limited experience, laparoscopic extended pelvic lymphadenectomy is feasible and results in nodal yields that are commensurate with current recommendations from conventional open surgical series.
- Ours is only the initial experience and corroborating data from other centers are necessary before laparoscopic extended pelvic lymph node dissection can be considered to be adequate.

PORT-SITE TUMOR SEEDING AND LOCAL RECURRENCE

Issues of tumor spillage and port site seeding have been raised as concerns regarding the oncologic safety of laparoscopic surgery. Specifically, after pelvic lymphadenectomy, there have been four reported cases of tumor recurrence at a port site (42). Three of the cases occurred after staging lymphadenectomy for bladder cancer (43) and the other after pelvic lymph node dissection for prostate cancer (44). In the cases associated with bladder cancer, the specimens were directly extracted through a port rather than placed in impermeable sacs. Furthermore, the cases were high grade invasive transitional cell carcinoma and associated with other predisposing events such as concomitant transurethral resection of bladder tumor, concomitant bladder dome biopsy, and insertion of a suprapubic tube because of hemorrhage during transurethral resection of bladder tumor and ruptured tumor bearing lymph nodes (43).

Care should be taken to avoid incision into tumor-bearing nodes, especially in the setting of high-grade disease. Also, all lymphatic tissue should be immediately placed in an impermeable sac.

Care should be taken to avoid incision into tumor-bearing nodes, especially in the setting of high-grade disease. Also, all lymphatic tissue should be immediately placed in an impermeable sac.

SUMMARY

- Currently, limited laparoscopic pelvic lymphadenectomy can be performed with comparable efficiency to open surgery. In the management of prostate cancer there is a vast experience with laparoscopic pelvic lymph node dissection. However, laparoscopic extended pelvic lymph node dissection for bladder cancer is a relatively recent development and further experience will be required to better define its role.
- In general, surgical times for limited laparoscopic lymphadenectomy are equivalent or longer depending on the procedure and the experience of the surgeon.
- Pelvic lymph node dissection for staging and prognosis, as is usually the case for prostate cancer, is not as technically demanding as a lymphadenectomy with therapeutic potential. As such, during radical cystectomy with curative intent, an honest effort must be made to perform as meticulous and rigorous an anatomic lymphadenectomy as is carried out with open surgery.
- We believe that with growing experience and instrument development, laparoscopic extended pelvic lymph node dissection will be performed with equal efficacy to the open procedure.

REFERENCES

1. Bluestein DL, Bostwick DG, Bergstralh EJ, Oesterling JE. Eliminating the need for bilateral pelvic lymphadenectomy in select patients with prostate cancer. *J Urol* 1994; 151(5):1315–1320.
2. Gibbons RP. The contemporary incidence of lymph node metastases in prostate cancer: implications for laparoscopic lymph node dissection. *J Urol* 1994; 151(4):1031–1032.
3. Raghavaiah NV, Jordan WP Jr. Prostatic lymphography. *J Urol* 1979; 121(2):178–181.
4. Gil-Vernet JM. Prostate cancer: anatomical and surgical considerations. *Br J Urol* 1996; 78(2): 161–168.
5. Wawroschek F, Vogt H, Wengenmair H, et al. Prostate lymphoscintigraphy and radio-guided surgery for sentinel lymph node identification in prostate cancer. Technique and results of the first 350 cases. *Urol Int* 2003; 70(4):303–310.
6. Wawroschek F, Vogt H, Weckermann D, Wagner T, Hamm M, Harzmann R. Radioisotope guided pelvic lymph node dissection for prostate cancer. *J Urol* 2001; 166(5):1715–1719.
7. Gervasi LA, Mata J, Easley JD, et al. Prognostic significance of lymph nodal metastases in prostate cancer. *J Urol* 1989; 142(2 Pt 1):332–336.

8. Bishoff JT, Reyes A, Thompson IM, et al. Pelvic lymphadenectomy can be omitted in selected patients with carcinoma of the prostate: development of a system of patient selection. *Urology* 1995; 45(2):270–274.
9. Han M, Partin AW, Pound CR, Epstein JI, Walsh PC. Long-term biochemical disease-free and cancer-specific survival following anatomic radical retropubic prostatectomy. The 15-year Johns Hopkins experience. *Urol Clin North Am* 2001; 28(3):555–565.
10. Clark T, Parekh DJ, Cookson MS, et al. Randomized prospective evaluation of extended versus limited lymph node dissection in patients with clinically localized prostate cancer. *J Urol* 2003; 169(1):145–147; discussion 147–148.
11. Partin AW, Kattan MW, Subong EN, et al. Combination of prostate-specific antigen, clinical stage, and Gleason score to predict pathological stage of localized prostate cancer. A multi-institutional update. *JAMA* 1997; 277(18):1445–1451.
12. Narayan P, Fournier G, Gajendran V, et al. Utility of preoperative serum prostate-specific antigen concentration and biopsy Gleason score in predicting risk of pelvic lymph node metastases in prostate cancer. *Urology* 1994; 44(4):519–524.
13. Bader P, Burkhard FC, Markwalder R, Studer UE. Is a limited lymph node dissection an adequate staging procedure for prostate cancer? *J Urol* 2002; 168(2):514–518; discussion 518.
14. Heidenreich A, Varga Z, Von Knobloch R. Extended pelvic lymphadenectomy in patients undergoing radical prostatectomy: high incidence of lymph node metastasis. *J Urol* 2002; 167(4):1681–1686.
15. Bader P, Burkhard FC, Markwalder R, Studer UE. Disease progression and survival of patients with positive lymph nodes after radical prostatectomy. Is there a chance of cure? *J Urol* 2003; 169(3):849–854.
16. Schuessler WW, Vancaille TG, Reich H, Griffith DP. Transperitoneal endosurgical lymphadenectomy in patients with localized prostate cancer. *J Urol* 1991; 145(5):988–991.
17. Flowers JL, Feldman J, Jacobs SC. Laparoscopic pelvic lymphadenectomy. *Surg Laparosc Endosc* 1991; 1(2):62–70.
18. Steinberg AP, Gill IS. Laparoscopic radical prostatectomy: progress, problems, and promise. *Contemp Urol* 2002; 14(5):34–49.
19. Doublet JD, Gattegno B, Thibault P. Laparoscopic pelvic lymph node dissection for staging of prostatic cancer. *Eur Urol* 1994; 25(3):194–198.
20. Kerbl K, Clayman RV, Petros JA, Chandhoke PS, Gill IS. Staging pelvic lymphadenectomy for prostate cancer: a comparison of laparoscopic and open techniques. *J Urol* 1993; 150(2 Pt 1):396–398; discussion 399.
21. Lang GS, Ruckle HC, Hadley HR, Lui PD, Stewart SC. One hundred consecutive laparoscopic pelvic lymph node dissections: comparing complications of the first 50 cases to the second 50 cases. *Urology* 1994; 44(2):221–225.
22. Parra RO, Andrus C, Boullier J. Staging laparoscopic pelvic lymph node dissection: comparison of results with open pelvic lymphadenectomy. *J Urol* 1992; 147(3 Pt 2):875–878.
23. Schuessler WW, Pharand D, Vancaille TG. Laparoscopic standard pelvic node dissection for carcinoma of the prostate: is it accurate? *J Urol* 1993; 150(3):898–901.
24. Herrell SD, Trachtenberg J, Theodorescu D. Staging pelvic lymphadenectomy for localized carcinoma of the prostate: a comparison of 3 surgical techniques. *J Urol* 1997; 157(4):1337–1339.
25. Stone NN, Stock RG, Unger P. Laparoscopic pelvic lymph node dissection for prostate cancer: comparison of the extended and modified techniques. *J Urol* 1997; 158(5):1891–1894.
26. Winfield HN, Donovan JF, See WA, et al. Laparoscopic pelvic lymph node dissection for genitourinary malignancies: indications, techniques, and results. *J Endourol* 1992; 6:103.
27. Vallancien G, Cathelineau X, Baumert H, Doublet JD, Guillonnet B. Complications of transperitoneal laparoscopic surgery in urology: review of 1,311 procedures at a single center. *J Urol* 2002; 168(1):23–26.
28. Stein JP, Cai J, Groshen S, Skinner DG. Risk factors for patients with pelvic lymph node metastases following radical cystectomy with en bloc pelvic lymphadenectomy: concept of lymph node density. *J Urol* 2003; 170(1):35–41.
29. Vieweg J, Gschwend JE, Herr HW, Fair WR. The impact of primary stage on survival in patients with lymph node positive bladder cancer. *J Urol* 1999; 161(1):72–76.
30. Poulsen AL, Horn T, Steven K. Radical cystectomy: extending the limits of pelvic lymph node dissection improves survival for patients with bladder cancer confined to the bladder wall. *J Urol* 1998; 160(6 Pt 1):2015–2019; discussion 2020.
31. Leissner J, Hohenfellner R, Thuroff JW, Wolf HK. Lymphadenectomy in patients with transitional cell carcinoma of the urinary bladder; significance for staging and prognosis. *BJU Int* 2000; 85(7):817–823.
32. Herr HW, Bochner BH, Dalbagni G, Donat SM, Reuter VE, Bajorin DF. Impact of the number of lymph nodes retrieved on outcome in patients with muscle invasive bladder cancer. *J Urol* 2002; 167(3):1295–1298.
33. Stein JP, Lieskovsky G, Cote R, et al. Radical cystectomy in the treatment of invasive bladder cancer: long-term results in 1,054 patients. *J Clin Oncol* 2001; 19(3):666–675.
34. Konety BR, Joslyn SA, O'Donnell MA. Extent of pelvic lymphadenectomy and its impact on outcome in patients diagnosed with bladder cancer: analysis of data from the Surveillance, Epidemiology and End Results Program data base. *J Urol* 2003; 169(3):946–950.
35. Skinner DG. Management of invasive bladder cancer: a meticulous pelvic node dissection can make a difference. *J Urol* 1982; 128(1):34–36.
36. Smith JA Jr., Whitmore WF Jr. Regional lymph node metastasis from bladder cancer. *J Urol* 1981; 126(5):591–593.
37. Leissner J, Ghoneim MA, Abol-Enein H, et al. Extended radical lymphadenectomy in patients with urothelial bladder cancer: results of a prospective multicenter study. *J Urol* 2004; 171(1):139–144.
38. Herr HW. Superiority of ratio based lymph node staging for bladder cancer. *J Urol* 2003; 169(3):943–945.

39. Herr HW, Donat SM. Outcome of patients with grossly node positive bladder cancer after pelvic lymph node dissection and radical cystectomy. *J Urol* 2001; 165(1):62–64; discussion 64.
40. Gill IS, Fergany A, Klein EA, et al. Laparoscopic radical cystoprostatectomy with ileal conduit performed completely intracorporeally: the initial 2 cases. *Urology* 2000; 56(1):26–29; discussion 29–30.
41. Finelli A, Gill IS, Desai MM, Moinzadeh A, Magi-Galluzzi C, Kaouk JH. Laparoscopic extended pelvic lymphadenectomy for bladder cancer: technique and initial outcomes. *J Urol* 2004; 172(5 part 1):1809–12.
42. Rassweiler J, Tsivian A, Kumar AV, et al. Oncological safety of laparoscopic surgery for urological malignancy: experience with more than 1,000 operations. *J Urol* 2003; 169(6):2072–2075.
43. Elbahnasy AM, Hoenig DM, Shalhav A, McDougall EM, Clayman RV. Laparoscopic staging of bladder tumor: concerns about port site metastases. *J Endourol* 1998; 12(1):55–59.
44. Bangma CH, Kirkels WJ, Chadha S, Schroder FH. Cutaneous metastasis following laparoscopic pelvic lymphadenectomy for prostatic carcinoma. *J Urol* 1995; 153(5):1635–1636.

LAPAROSCOPIC RADICAL CYSTECTOMY (PROSTATE SPARING)

Xavier Cathelineau, Carlos Arroyo, François Rozet, Eric Barret, and Guy Vallancien

Institut Montsouris, Université Pierre et Marie Curie, Paris, France

- INTRODUCTION
- PATIENT SELECTION: INDICATIONS AND CONTRAINDICATIONS
- PREOPERATIVE PREPARATION
- DETAILED LAPAROSCOPIC TECHNIQUE
 - Laparoscopic Cystectomy
- DESCRIPTION OF TECHNICAL MODIFICATIONS
- TECHNICAL TIPS
- SPECIFIC MEASURES TAKEN TO AVOID COMPLICATIONS
 - Perioperative Complications
 - Postoperative Complications
- POSTOPERATIVE EVALUATION
- RESULTS
- DISCUSSION
 - Risk of Prostate Cancer
- SUMMARY
- REFERENCES

INTRODUCTION

Radical cystectomy is currently the treatment of choice for invasive bladder cancer and recurrent refractory cases of superficial transitional cell carcinoma (1). However, the procedure influences significantly the quality of life of these patients, especially their sexual and urinary functions. Although current oncological treatments tend to balance the benefits associated with a radical surgery and bladder preservation modalities such as chemotherapy and external beam radiation, cancer control is still inadequate compared to the surgical results (2). With the above concept, partial cystectomy has been described in many centers. However, there is an increased danger of local recurrence and the development of synchronous prostate cancer (3).

We commenced performing prostate-sparing radical cystectomy in selected patients since 1992, in order to improve the functional results while maintaining similar oncological control as compared to radical cystoprostatectomy (4).

The open prostate-sparing cystectomy technique has been modified and used by other teams as well (5–7). Benefiting from experience gained after performing regularly laparoscopic radical prostatectomy, we have developed a laparoscopic approach for this procedure and have done over 30 cases with satisfactory clinical and functional results (8).

PATIENT SELECTION: INDICATIONS AND CONTRAINDICATIONS

Because of the oncologic risks associated with any surgical technique, especially if it involves a functional and organ-sparing technique, as well as an associated potential higher risk, it cannot be overemphasized that nerve and prostate-sparing cystectomy is not indicated in every patient with invasive bladder cancer requiring a cystectomy. Laparoscopic prostate-sparing radical cystectomy should be reserved for very selected patients that meet not only the regular preoperative criteria, but most importantly strict clinical and laboratory criteria (9).

Because of the oncologic risks associated with performing a prostate-sparing technique, candidates must not suffer any form of erectile dysfunction and must be completely continent; otherwise this procedure offers no benefit.

Concerning the surgical technique, patients should have a complete medical history with physical exam, including digital rectal exam and recent cystoscopy. The laboratory panel must include renal function exams and prostate specific antigen and percentage free prostate specific antigen. Finally, the imaging studies must include a computerized tomography and if possible an intravenous urography.

We commenced performing prostate-sparing radical cystectomy in selected patients since 1992, in order to improve the functional results while maintaining similar oncological control as compared to radical cystoprostatectomy.

Laparoscopic prostate-sparing radical cystectomy should be reserved for very selected patients that meet not only the regular preoperative criteria, but most importantly strict clinical and laboratory criteria.

TABLE 1 ■ Candidate Patients for Laparoscopic Prostate-Sparing Cystectomy Should Comply with the Following Criteria

No brain aneurysm or intracranial tumors
Continent
Potent
Bladder cancer: pTa, pT1, pT2
Tumor located at least 5 mm away from bladder neck
No tumor involvement of the prostatic urethra
No prostate cancer
Total prostate specific antigen ≤ 3ng/dL
Free prostate specific antigen > 12%
Normal transrectal ultrasound
If any of these are abnormal then perform transrectal prostate biopsy

The best indications for a prostate-sparing cystectomy are: a potent and continent patient with no contraindications for laparoscopic procedures, with a pTa, pT1 or pT2 bladder tumor that is located far from the bladder neck, with no risk of prostate cancer and no urethral CIS.

TABLE 2 ■ Various Steps Involved in the Laparoscopic Prostate Sparing Cystectomy

Trocar placement
Bilateral pelvic lymphadenectomy
Bilateral ureteric dissection
Vas deferens and seminal vesicle dissection
Opening of the Retzius space
Division of the lateral bladder vascular pedicles
Incision of the anterior surface of the prostate below the bladder neck
Bladder neck closure
Placement of the bladder in an extraction bag
Laparoscopic simple prostatectomy
Extraction of surgical specimens
Open "Z" neo-bladder enterocystoplasty
Uretero-ileal anastomosis and stent placement
Prostato-ileal anastomosis
Drains and Foley catheter placement

Patients with an abnormal digital exam or a prostate specific antigen over 3 ng/mL, or a low percent free prostate specific antigen (<12%) or hypoechoic area on transrectal ultrasound, must undergo a series of prostatic biopsies to exclude prostate cancer.

Finally and most importantly, the bladder tumor characteristics should be strict; such as not being located in or within 10 mm the bladder neck, nor in the prostatic urethra. The histology of the bladder cancer should be transitional cell carcinoma and it must comply with the regular indications for a radical cystectomy and a continent diversion (Table 1).

The best indications for a prostate-sparing cystectomy are: a potent and continent patient with no contraindications for laparoscopic procedures, with a pTa, pT1 or pT2 bladder tumor that is located far from the bladder neck, with no risk of prostate cancer and no urethral carcinoma-in-situ.

Concerning the laparoscopic approach, regular preoperative evaluation, involves excluding absolute anesthetic contraindications for laparoscopic procedures, which also applies to this procedure: intracranial surgical history, brain aneurysm or previous intracranial tumors. There are also some relative anesthetic contraindications that involve respiratory insufficiency such as severe emphysema, severe cardiac insufficiency, and glaucoma. Finally, there are certain patients that will make the procedure more difficult and could be considered, depending on the surgeons experience as relative surgical contraindications, these include: morbid obesity, previous pelvic or abdomen radiotherapy, and history multiple abdominal surgeries.

PREOPERATIVE PREPARATION

Our routine preoperative preparation includes antithrombotic prophylaxis with low-molecular-weight heparin, which is administered subcutaneously the night before surgery and elastic stockings the morning of the surgery. Antibiotic prophylaxis is started during the induction of anaesthesia, and consists of Cefotetan 2 g intravenously. There is no need of bowel preparation before surgery; however, a low residue diet can be recommended five days before surgery. Concerning the skin, the patient's abdomen is not routinely shaved and the patient takes a bath the morning of the surgery with Betadine®.

The surgery is performed under general anesthesia following all the classical anesthesiologic principles. During the induction, Propofol™ (2 mg/kg) is used and transoperative maintenance is done with Desflurane™ or Sevoflurane™ gas, and muscle relaxation by curarization with Atracurium™ (0.5 mg/kg) during the induction and maintained at 0.3mg/kg/hr. Finally, perioperative analgesia is provided with Sufentanil™.

One important aspect of surgery is patient positioning to avoid the risks associated with a prolonged surgery. The position used is the decubitus position with the lower limbs; the arms strapped along the body so as not to obstruct the surgeon or assistant. Abundant cushioning should be placed to avoid pressure injuries and Velcro straps are applied across the shoulders to maintain the patient's position during the surgery and allow a 30° Trendelenburg tilt, which will be maintained throughout the surgery.

DETAILED LAPAROSCOPIC TECHNIQUE

Prostate-sparing radical cystectomy can be divided into a laparoscopic cystectomy and an open lower urinary tract reconstruction. Each stage can then be further broken down into the following steps (Table 2):

Laparoscopic Cystectomy

Step 1: Placement of Five Trocars Transperitoneally

1. 10 mm trocar is placed in the umbilicus for the introduction of the camera. The surgeon will work on the left of the patient with two 5 mm trocars that are placed above and medial to the iliac spine and another between the lateral and umbilical port. The trocars for the assistant will include a 5 mm trocar that is placed above and medial to the right iliac spine at MacBurney's point and a second 10 mm trocar on the pararectal line between the umbilical and lateral port on the right (Fig. 1).




FIGURE 1 ■ The first trocar position variation involves placement of all the ports as high as possible with respect to the umbilicus, the left side ports are used by the surgeon and the right side by the assistant.




FIGURE 2 ■ The triangular trocar variation involves placement of the surgeon ports on the left side between the umbilical port and the left iliac spine and the other two-thirds of the distance between the umbilical port and the suprapubic rim along the midline.

2. An optional trocar placement involves changing the surgeons trocars using a triangulation position. They are introduced, midway between the umbilical port and left iliac spine and the other two-thirds of the distance between the umbilical port and the suprapubic rim along the midline (Fig. 2).

Step 2: Bilateral Pelvic Lymphadenectomy with Frozen Section Analysis

This is performed along the external iliac vessels, in order to remove all the lymph nodes for frozen section analysis. The limits of the lymph node dissection include the level of the ureter as it crosses the common iliac artery, the genitofemoral nerve laterally and the external iliac and obturator fossa lymph nodes and circumflex iliac vein distally, which comprise the external iliac vessels and obturator fossa.

Step 3: Bilateral Ureteric Dissection

The peritoneal incision used during the lymphadenectomy is extended downward in order to expose and dissect the ureters, which are transacted bilaterally near their entry to the bladder. The distal end of the ureters is sent for frozen section to ensure a healthy surgical margin. Both ureters are ligated with security Hem-O-Lok™ clips.

Step 4: Vas Deferens and Seminal Vesicle Dissection

The vas deferens and seminal vesicles are dissected. The peritoneum is opened along the pouch of Douglas, to gain access to the vas deferens, which are traced deeply, to reach the anterior surface of the seminal vesicles, which are completely liberated from the surrounding anterior aspect of the Denonvillier fascia, allowing their adequate preservation.

Step 5: Opening of the Retzius Space

This is done to free the bladder from the abdominal wall and retropubic space, which will allow an excellent view of the bladder and prostate, making it possible to identify the bladder neck.

Step 6: Division of the Lateral Bladder Pedicles

The lateral bladder pedicles are divided. By retracting medially the bladder wall, the lateral vascular pedicles can be dissected and freed using monopolar and bipolar diathermy.

Step 7: Incision of the Anterior Surface of the Prostate

This is performed at least 5 mm distal to the bladder neck to ensure adequate surgical margins. This incision is completed posteriorly in order to allow the bladder to be separated completely. It is important to perform this incision along the prostatic adenoma, making sure that the bladder neck is completely resected (Fig. 3).

FIGURE 3 ■ Prostate capsule after simple prostatectomy performed laparoscopically; it is cut 5 mm below the bladder neck. This allows the prostate capsule to be spared with the seminal vesicles and vas deferens, without controlling the deep dorsal vein plexus. Lateral view, the dotted line shows the resection area.



FIGURE 4 ■ Transverse view. The prostate capsule after the simple prostatectomy performed laparoscopically; it is cut below the bladder neck. This allows the preservation of the neurovascular bundles.

Step 8: Bladder Neck Closure

The bladder neck is closed. This must be performed immediately after completing the bladder neck dissection, in order to avoid any possible tumor cell spillage. We routinely do this with an intracorporeal “X” suture with 2-0 Vicryl on a 36 mm needle.

Step 9: Specimen Entrapment

The bladder is then placed in a surgical specimen extraction bag.

Step 10: Laparoscopic Simple Prostatectomy

This removes all of the adenomatous gland and leaves the prostatic urethra “intact” and can be performed with bipolar diathermy or with the harmonic scalpel. The specimen is placed in an Endobag (Fig. 4).

Step 11: Extraction of the Surgical Specimens

Both tissues, the bladder and prostate adenoma, are extracted through a small infra-umbilical midline incision.

Step 12: Open Enterocystoplasty

The enterocystoplasty is performed following open surgical principles. A 40 cm ileal segment is isolated and detubularized leaving 3 cm on either end for the ureteroileal anastomosis. The detubularized ileal segment is remodeled using a Z technique into a neobladder (Fig. 5).

Step 13: Ureteroileal Anastomosis

Both ureters are spatulated to allow a side-to-end anastomosis to the nondetubularized ends of the neobladder. Bilateral stents are left on either side for seven days.

Step 14: Prostatoileal Anastomosis

This is performed from the lowest portion of the enteroplasty to the prostatic capsule with interrupted 3/0 Vicryl sutures. The integrity of the anastomosis is confirmed by filling the neobladder with 200 mL of saline.

Step 15: Drains and Foley Catheter Placement

Finally, two suction drains are left in the pelvic cavity and the pouch of Douglas. The Foley catheter is left in the urethra for nine days.

DESCRIPTION OF TECHNICAL MODIFICATIONS

At our center, we modified the surgical technique previously described to render this technique easier to reproduce. Two major modifications include the type of simple

FIGURE 5 ■ Lower urinary tract reconstruction with the “Z” ileal neobladder.



prostatectomy, and the approach for the anastomosis during the lower urinary reconstruction.

In the beginning of our experience we performed a transurethral resection of the prostate extending from the bladder neck to the verumontanum at the beginning of the surgery. Specimens of the prostatic urethra and transition zone were sent in separate containers for frozen section examination before proceeding with the cystectomy. However, currently we have noted that performing a simple prostatectomy after the bladder dissection offers the benefit of the complete prostatic urothelium for histopathologic analysis, and can be done without compromising the surgical results and not increasing significantly the surgical time. However, both options are feasible and the surgeon should select either, according to preference.

The second variation of the technique is the option, after the neobladder construction, of performing the neobladder prostate capsule anastomoses and ureter-neobladder anastomosis laparoscopically by closing the midline incision. We have performed these anastomoses by open and laparoscopic approaches, and have seen that the laparoscopic technique at this stage of the operation does not modify significantly the results and could result in a longer surgical time and a difficult procedure, especially concerning the neobladder-prostate capsule anastomosis (4).

Guazzoni et al. have recently described the laparoscopic approach for a nerve- and seminal-sparing cystectomy, doing one week before the surgery a transurethral resection of the prostate and transectioning the bladder vascular pedicles with Endo-GIA. In our experience, this stapler is not necessary as described in our technique, due to its cost and risk of malfunction, and because we deem bipolar diathermy sufficient (10).

There are no other laparoscopic prostate-sparing techniques described in the literature; however, there have been some techniques applied through an open approach that propose some variations concerning the prostate-sparing dissection planes. These modifications will be described briefly because they are performed by an open technique; however, they could eventually be performed laparoscopically also.

Colombo et al. have reported a similar technique to ours, except for the fact that they perform cystectomy extraperitoneally. After the completion of cystectomy, they open the peritoneum and perform the ileal bladder reconstruction and anastomosis with two semicircular running sutures (11).

Meinhardt and Horenblas have performed a technique in which the prostate and seminal vesicles are preserved allowing the neobladder to be anastomosed to the lateral edge of the prostate; however, they do not specify any further details (12).

Ghanem has proposed ligating the anterior prostatic veins and incising the prostate capsule transversely 0.5 cm below the bladder neck, as in retropubic prostatectomy to allow a dissection of the prostatic adenoma attached to the bladder, and continuing a circumferential incision from the anterior transverse incision of the prostatic capsule, to complete the cysto-prostatic-adenomectomy (Table 3) (13).

Spitz et al. described a technique for nonurothelial tumors, and mentioned the variation of an incision of the endopelvic fascia adjacent to the prostate and ligation of the anterior and lateral aspects of the prostate proximal to the puboprostatic ligaments, controlling the dorsal venous complex and the incision of the prostatic stroma at the level of the urethra. This prostate transection is continued posteriorly without compromising the ejaculatory ducts (14).

TABLE 3 ■ European Groups that Perform Open or Laparoscopic Prostate-Sparing Cystectomy

Center	No. of patients	Continence (%)	Erections (%)
Montsouris	132	100	84
Colombo	41	100	100
Horenblas	39	70	70
Sèbe	34	90	88
Coulanges	25	93	86
Meinhardt	24	96	83
Ghanem	4	100	75

All of these open technique variations can be easily applied to the laparoscopic approach; however, the choice of technique depends on the surgeon's personal experience.

TECHNICAL TIPS

- When opening the Retzius space, it is not necessary to open the endopelvic fascia, because the prostate capsule is not manipulated in this technique. Avoiding the incision of the endopelvic fascia ensures that the neurovascular bundles of the prostate are left undisturbed, as well as the surrounding tissues, which being intact serve as support for the prostate.
- During the incision of the bladder vascular pedicle with bipolar diathermy, it is important to take adequate time to ensure that no postoperative bleeding occurs from these vessels.
- The bladder neck can be identified by mild traction on the Foley catheter, which makes evident the prostatovesical junction anteriorly. Another option is to visualize the perivesical fat, which does not extend into the prostate and makes a subtle bladder neck delineation. Finally, if neither of the above is useful, a Benique dilator can be introduced and visualized inside the bladder; however, we must keep in mind that the bladder neck is higher than the tip of the metal dilator.
- To perform the bladder neck incision, it is done along the prostatic adenoma, 10 mm below the bladder neck, ensuring that a complete resection of the bladder neck is performed, thereby diminishing the risk positive margins along the lower portion of the surgical specimen.
- After the bladder is completely liberated, the bladder neck closure must be performed immediately after completing the bladder neck dissection, and introduced into an extraction bag without any excessive pressure on the bladder. All this is done to avoid any possible tumor cell spillage, although the risk is low considering that the bladder has been completely emptied of any remaining urine with the Foley catheter and the ureters have been long since ligated and transected.
- When performing the simple prostatectomy, the distal portion of the incision along the prostatic urethra must not be beyond the verumontanum, in order to avoid any damage to the sphincter.

SPECIFIC MEASURES TAKEN TO AVOID COMPLICATIONS

Complications involved in laparoscopic surgery of the lower urinary tract are mainly the same as those involved with open surgery (15). We describe the transoperative (divided according to the different surgical steps) and postoperative complications.

Perioperative Complications

Perioperative complications are associated with the patient position (such as compartment syndromes and neurologic sequelae secondary to prolonged compression), insufflations (vascular or intestinal injuries), and those associated with intestinal displacement during the laparoscopic stage. These complications can be prevented by carefully positioning the patient with enough cushioning of the dependent areas, by avoiding excessive pressure on the abdominal wall when introducing the insufflation needle, and finally by managing the gastrointestinal tract with blunt instruments and carefully.

Postoperative Complications

Postoperative complications are associated with the different stages of the surgery, and include hematomas resulting from inadequate use of diathermy during dissection, and lymphocele, which is usually rare because the operation is performed transperitoneally and, as such, is reabsorbed by the peritoneum. Wound infections are not due to the intestinal content and should not influence this complication. Neobladder stenosis is rare but can be the result of an incision too low along the prostate or an inadequate anastomosis. Urine leak is due to damage of the tissues in the anastomosis or an inefficient suture, which can be verified transoperatively by filling the neobladder with saline solution. Intestinal fistulae can occur if the entero-entero anastomosis is not carefully performed or there is an ischemic lesion on the ileal wall.

POSTOPERATIVE EVALUATION

The follow-up protocol that we routinely use includes a complete physical exam with digital rectal exam, complete blood analysis with a special interest in urine analysis, serum creatinine, total prostate-specific antigen and free prostate-specific antigen, chest X-rays and computed tomography scan of the abdomen every six months for the first three years, and yearly afterwards. Continence is evaluated using a mailed questionnaire, evaluating their use of protection pads. We define erectile function according to their ability to perform intercourse.

Continence and potency are assessed by the patients (16,17), using mailed questionnaires. Patients are considered continent only when they do not use any pads. They are strictly instructed during the first postoperative year to empty the bladder once or twice at night in order to achieve adequate nighttime continence. Potency is strictly defined as the ability to maintain an unassisted erection sufficient for intercourse. Partial potency is defined as the ability to achieve but not maintain erection long enough for satisfactory intercourse without the use of any device or medications. Patients unable to achieve an erection, as well as those using medications or devices to stimulate erection, are considered as impotent.

RESULTS

In our experience, the oncologic and functional results of our laparoscopic series are comparable to that of the open approach series, with the added benefit of a diminished bleeding and less need of postoperative analgesics.

During the last 12 years 132 patients have undergone a prostate-sparing cystectomy in our department (4). The first 107 procedures were performed with open approach, and the last 25 using laparoscopic-assisted technique. In our experience, the oncologic and functional results of our laparoscopic series are comparable to that of the open approach series, with the added benefit of a diminished bleeding and less need of postoperative analgesics.

From March 2002 to March 2004, we employed the laparoscopic prostate-sparing technique in 25 patients. The average age was 60 (range, 43–77 years), 20/25 of the patients had a history of smoking as a risk factor. The different pathologic postoperative stages were pT1 = 8, pT2 = 8, pT3 = 8, pT4 = 1 involving the prostate neck (N0, M0). They all had negative surgical margins and no lymph nodes with metastasis. The histopathologic grade was moderate in 6 and high grade in 19. Mean operating time including the neobladder reconstruction was 4.75 hours (range, 3.3–6.3 hours) and mean intraoperative blood loss was 640 cc (range, 200–1500 cc) with transfusion required in six patients. The surgery was successfully completed as described with the laparoscopic and open stages in all of the patients, without any transoperative complications or conversions (Table 4). After performing the neobladder anastomosis laparoscopically in five patients, we did not observe any significant advantage for the surgical technique, and decided to continue performing the neobladder-prostatic anastomosis through the infraumbilical incision by an open technique. Overall, this offers the advantage of preventing any traction on the abdominal wall and hence minimizes postoperative pain. All of our patients were followed up for the first 24 hours in the intensive care unit according to hospital policy without any complications, except for a sinus tachycardia, which resolved without any sequelae. In all, the laparoscopic approach offered diminished bleeding and less postoperative pain.

Among the postoperative complications there was one intestinal subocclusion, one urinary fistula and one pelvic lymphocele. The average follow-up of these patients was 9.7 months (range, 3–27 months). There have been two metastatic progressions (at five and eight months) and one local recurrence (six months after the surgery); the three patients have been submitted to chemotherapy following a methotrexate, vinblastine, adriamycin and cisplatin scheme with good results. All of the patients are alive except for a T3a patient who died seven months after the surgery due to cancer progression. Interestingly, this same patient in the final pathology analysis was reported with a small prostatic adenocarcinoma with a Gleason 3+3 in the resected prostatic adenoma, which was not diagnosed during the frozen section study; he was managed with hormone therapy. Concerning renal function, creatinine levels have been maintained and have not varied significantly (average of 97 mmol/L before and 102 mmol/L after the surgery). This figure also applies to the prostate specific antigen, although a slight decrease was detected after the surgery (from 2 ng/mL before to 0.6 ng/mL after the surgery), which was mainly due to the simple adenomectomy. Finally, concerning functional results, all our patients

TABLE 4 ■ Patient Characteristics, Clinical Tumor Stage, and Tumor Grade of Initial Experience Performing Laparoscopic Prostate-Sparing Cystectomy

	Laparoscopic
No. of patients	25
Age	59.8 (range, 43–77)
Date of surgery	03/02–03/04
Follow-up	9.7 m (range, 3–27)
Smoking habit	Positive in 20
Stage	
T0	2
Ta	2
CIS	2
T1	2
T2a	6
T2b	2
T3a	8
T3b	–
T4 (prostate)	1
Grade	
G1	–
G2	6
G3	19

Abbreviation: CIS, carcinoma-in-situ.

achieved satisfactory daytime and nighttime continence, without using any pad after surgery. Nighttime continence is complete; however, seven patients developed nocturia between one and three per night. No patient has presented with urinary retention, 21 patients (84%) maintained their preoperative sexual potency, and four alluded to a decrease in their erectile function postoperatively. All of our patients have retrograde ejaculation after surgery, which is related to the simple prostatectomy.

DISCUSSION

The current standard of care for muscle invasive and refractory superficial high-grade organ-confined bladder cancer is radical cystoprostatectomy (18). This procedure removes the bladder, prostate, seminal vesicles and vas deferens, and involves a deep pelvic dissection with a significant risk of damage to the pelvic nerves as well as extensive manipulation of the external sphincter (19). This explains why it is associated with a considerable degree of incontinence (5–18%) when a neobladder is constructed and erectile dysfunction (75–80%) (20–22). These functional results explain why more conservative techniques are constantly being explored. The goal is to preserve the urethral sphincter and neurovascular bundles, which will impact on the functional results for these patients (23).

With the above in mind, the laparoscopic prostate-sparing cystectomy was developed at our Institute.

Laparoscopic prostate-sparing cystectomy is associated with the potential risk of developing prostate cancer, carcinoma in situ of the prostatic urethra, transitional cell cancer of the prostatic ducts or glands, and prostatic invasion by bladder cancer, which as a group might influence the oncologic control obtained with this procedure (24).

Laparoscopic prostate-sparing cystectomy is associated with the potential risk of developing prostate cancer, carcinoma in situ of the prostatic urethra, transitional cell cancer of the prostatic ducts or glands, and prostatic invasion by bladder cancer, which as a group might influence the oncologic control obtained with this procedure.

Risk of Prostate Cancer

Kabalin et al. (25) reported a 38% incidence of occult prostate cancer in cystoprostatectomy specimens but only 1.9% of these had tumors exceeding 0.1 cc in volume. Moreover, their study was performed before the prostate specific antigen era and patients were excluded from their analysis if they had an abnormal digital rectal exam. Our patients were assessed carefully preoperatively to exclude the risk of prostate cancer (26). Patients with an abnormal digital rectal examination, total prostate specific antigen > 3 ng/mL, or percent free prostate specific antigen <12% underwent prostatic biopsies. Preoperatively, frozen sections of the transitional zone were routinely done. These frozen sections were initially of the transurethral resection chips, before the laparoscopic procedure was started; afterwards in our experience, the complete transitional zone was analyzed after the simple prostatectomy in the laparoscopic approach. In our series, two cases were not completed because they had positive frozen section for prostate cancer, and the procedure was completed with a radical cystoprostatectomy. The simple prostatectomy that we currently perform laparoscopically (27) allows complete removal of the transitional zone, improving the reliability of pathologic analysis, which with our strict follow-up protocol of digital rectal examination, and total and free prostate specific antigen every six months, leads to an early detection of any de novo prostate cancer, giving enough time for the patient to be treated successfully with either of the different modalities (external beam radiotherapy, transrectal focused ultrasound, brachytherapy or hormonal treatment). In our experience, two de novo prostate cancers have been diagnosed at three and five years after the prostate-sparing procedure and have been treated successfully, one with external beam radiation and the other by transrectal high intensity energy ultrasound.

Risk of Urethral Carcinoma in Situ and Prostatic Transitional Cell Carcinoma

Matzkin et al. reported a 25% incidence of prostatic transitional cell carcinoma in 86 patients (28). Wood et al. indicated that most of the transitional cell carcinoma seen in cystoprostatectomy specimens was in the prostatic urethra (29). Using our laparoscopic technique, the simple prostatectomy removes completely the prostatic urethra and the transitional zone. Lebet et al. reported no urethral recurrence at 10 years in patients who underwent cystectomy when no tumor was found on frozen section in the prostatic urethra (30,31). Among the 107 patients who underwent open prostate-sparing cystectomy, transitional cell carcinoma recurred in the prostatic fossa in two cases and was managed successfully with transurethral resection. Up to now, no recurrence

has occurred among the last 25 patients who have undergone the laparoscopic prostate-sparing cystectomy with simple prostatectomy.

Prostatic Invasion

Prostatic invasion occurs by carcinoma-in-situ, ductal invasion or stromal invasion (secondary to ductal invasion or primary by direct extravesical tumoral extension). Cookson et al. (32) reported a 15.6% incidence of prostatic invasion by bladder cancer, with an increased risk when carcinoinsitu or multifocality exists (>30%) and decreased risk in absence of carcinoinsitu and multifocality (4.5%). A 5–10 mm safety margin beyond the bladder neck is ensured with our technique. Moreover, frozen section was performed of the prostatic capsule in patients with higher risk tumors, which were close to the trigone.

Oncologic Results

The five years global survival according to the stage are reported Figure 6 and Table 5 for the overall series of 132 patients including open and laparoscopic approach. The five years' recurrence-free survival, isolated local recurrence and distant metastases rates reported (Tables 6 and 7), show comparable data between our series and those published by Studer et al. with 507 patients who underwent radical cystoprostatectomy without any adjuvant or neoadjuvant treatment (33). Stein et al. (34) reported a lower rate of distant metastases (13% for stage = pT2 N0) in 1054 patients who underwent cystoprostatectomy, but 25% of them received adjuvant or neoadjuvant therapies (radiotherapy or chemotherapy).

Benefits of Laparoscopic Approach

The feasibility of the laparoscopic radical cystectomy has been previously described (35–37) and shown to incorporate the advantages offered by minimally invasive surgery with earlier postoperative recovery, less need for pain relief and diminished blood loss. This is confirmed as well in our experience, as well as the fact that while performing the lower urinary tract reconstruction completely intracorporeally can be done,

FIGURE 6 ■ Five-year global survival according to the pathologic stage for patients undergoing open (107) and laparoscopic (25) prostate-sparing cystectomy.




TABLE 5 ■ Five Year Global Survival According to Pathologic Stage for Patients Undergoing Open (107 patients) and Laparoscopic (25 patients) Prostate-Sparing Cystectomy

Pathological stage	Tumor nodes metastases 2002 stage distribution (%)	5-yr global survival (%)
pT0	2	100
pTa, 1	18	96
pT2	44	85
pT3	23	74
N+	13	54

TABLE 6 ■ Four-Year Metastasis Rate for the Overall Series of 132 Patients Including Open and Laparoscopic Approach for Prostate-Sparing Cystectomy

Pathologic stage	Metastasis at 4 yr (%)
pT1, G3	13
pT2	28
pT3	33
N+	70

TABLE 7 ■ Four-Year Local Relapse Rate for the Overall Series of 132 Patients Including Open and Laparoscopic Approach

Pathologic stage	Local relapse at 4 yr (%)
pT1, G3	4
pT2	5
pT3	8.5
N+	0

this does not offer significant advantages for the patient and does increase the surgical difficulty and time.

Functional Results

We have shown in our previously published series (4) of 100 patients who underwent open prostate-sparing cystectomy showed a high rate of continence and maintenance of erectile function. The laparoscopic approach equals these results and those of other published reports, with 100% continence in our series versus 93% in those of Hollowell et al. (38), and 85% preservation of erectile function in our laparoscopic group versus 82% in the open series. These results are so much better than those of the traditional radical cystoprostatectomy (39). The impact on the patient's overall quality of life cannot be overemphasized.

SUMMARY

- There is a growing interest in this surgical procedure, which preserves the prostatic capsule and neurovascular bundles and presents a good option for highly selected patients. It allows a faster recovery of continence and erectile function, although retrograde ejaculation is a limiting factor for fertility potential.
- The laparoscopic technique reproduces the open technique with the added advantage of earlier postoperative recovery and less pain inherent to this approach.
- In order to avoid performing this procedure in cases that require a more radical approach, the need for a careful patient selection for this technique cannot be overemphasized.
- There is still need for longer follow-up and larger series of patients to confirm the overall oncologic outcome. Summarily, the need to ensure the patient's safety is paramount.

REFERENCES

- Stein JP. Contemporary concepts of radical cystectomy and the treatment of bladder cancer. *J Urol* 2003; 169:116–117.
- Menon M, Hemal AK, Tewari A, Shrivastava A, et al. Robot-assisted radical cystectomy and urinary diversion in female patients: technique with preservation of the uterus and vagina. *J Am Coll Surg* 2004; 198:386–396.
- Sweeney P, Kursh ED, Resnick MI. Partial cystectomy. *Urol Clin North Am* 1992; 19(4):701–711.
- Vallancien G, Abou EFH, Cathelineau X, et al. Cystectomy with prostate sparing for bladder cancer in 100 patients: 10 year experience. *J Urol* 2002; 168:2413–2417.
- Schilling A, Friesen A. Transprostatic selective cystectomy with an ileal bladder. *Eur Urol* 1990; 18:253–257.
- Hauri JH. Nerve and seminal sparing radical cystectomy with orthotopic urinary diversion for select patients with superficial bladder cancer: an innovative surgical approach. *J Urol* 2001; 166:1402.
- Colombo R, Bertini R, Salonia A, Filipo L, Pozzo FD, et al. Nerve and seminal sparing radical cystectomy with orthotopic urinary diversion for select patients with superficial bladder cancer: an innovative surgical approach. *J Urol* 2001; 165:51–55.
- Guillonneau B, El-Fettouh H, Baumert H, et al. Laparoscopic radical prostatectomy: oncological evaluation after 1,000 cases at Montsouris Institute. *J Urol* 2003; 61:266.
- Sebe P, Taxer O, Cussenot O, Haab F, Thibault P, Gattegno B. Cystectomie avec conservation prostatique dans le traitement des tumeurs de vessie: bases anatomiques, techniques chirurgicales, indications et résultats. *Progr Urol* 2003; 13:1279–1285.
- Guazzoni G, Cestari A, Colombo R, Lazzeri M, Montorsi F, et al. Laparoscopic nerve- and seminal-sparing cystectomy with orthotopic ilial neobladder: the first three cases. *Eur Urol* 2003; 44:567–572.
- Colombo R, Bertini R, Salonia A, et al. Overall clinical outcomes after nerve and seminal sparing radical cystectomy for the treatment of organ confined bladder cancer. 2004; 171:1819–1822.
- Meinhardt W, Horenblas S. Sexuality preserving cystectomy and neobladder: functional results of a neobladder anastomosis to the prostate. *Eur Urol* 2003; 43:646–650.
- Ghanem AN. Experience with capsule sparing cystoprostatectomy for orthotopic bladder replacement: overcoming the problems of impotence, incontinence and difficult urethral anastomosis. *BJU Int* 2002; 90:617.
- Spitz A, Stein JP, Lieskovsky G, Skinner DG. Orthotopic urinary diversion with preservation of erectile and ejaculatory function in men requiring radical cystectomy for nonurothelial malignancy: a new technique. *J Urol* 1999; 161:1761–1764.
- Vallancien G, Cathelineau X, Baumert H, Doublet JD, Guillonneau B. Complications of transperitoneale laparoscopic surgery in urology: review of 1,311 procedures at a single center. *J Urol* 2002; 168:2326.
- Dutta SC, Chang SS, Coffey CS, et al. Health related quality of life assessment after radical cystectomy: comparison of ileal conduit with continent orthotopic neobladder. *J Urol* 2002; 168:164–167.

17. Chang SS, Cookson MS, Baumgartner RC, Wells N, Smith JA. Analysis of early complications after radical cystectomy: results of a collaborative care pathway. *J Urol* 2002; 167:2012–2016.
18. Schlegel PN, Walsh PC. Neuroanatomical approach to radical cystoprostatectomy with preservation of sexual function. *J Urol* 1987; 138:1402.
19. Bassi P, Ferrante GD, Piazza N, Spinadin R, Carando R, et al. Prognostic factors of outcome after radical cystectomy for bladder cancer: a retrospective study of a homogeneous patient cohort. *J Urol* 1999; 161:1494–1497.
20. Schover LR, Evans R, Von Eschenbach A. Sexual rehabilitation and male radical cystectomy. *J Urol* 1986; 136:1015–1017.
21. Studer UE, Danuser H, Merz VW, Springer JP, Zingg EJ. Experience in 100 patients with an ileal low pressure bladder substitute combined with an afferent tubular isoperistaltic segment. *J Urol* 1995; 154:49–56.
22. Zerbib B, Thirouard D, Conaury S, Thiounn N, Flam T, Debre E. Evolution des techniques chirurgicales et resultants des cystectomies a vise curative pour cancer de la vessie. A propos de 106 cas. *Cancer Radiother* 1998; 2:505–511.
23. Turner WH, Danuser H, Moehrle K, Studer UE. The effect of nerve sparing cystectomy technique on post-operative continence after orthotopic bladder substitution. *J Urol* 1997; 158:2118–2122.
24. Rassweiler J, Tsivian A, Kumar R, et al. Oncological safety of laparoscopic surgery for urological malignancy: experience with more than 1,000 operations. *J Urol* 2003; 169:2072–2075.
25. Kabalin JH, McNeal JE, Price HM, Freiha FS, Stamey TA. Unsuspected adenocarcinoma of the prostate in patients undergoing cystoprostatectomy for other causes: incidence, histology and morphometric observations. *J Urol* 1989; 141(5):1091–1094.
26. Bonnal JL, Inani J, Maidenbergh M, Theodore C, Mauroy B. Association neoplasie vesicale et neoplasie prostatique: conduite a tenir. *Prog Urol* 2003; 13:1286–1289.
27. Velthoven RV, Peltier A, Laguna MP, Piechaud T. Laparoscopic extraperitoneal adenomectomy (Millin): pilot study on feasibility. *Eur Urol* 2004; 45:103–109.
28. Matzkin H, Soloway MS, Hardeman S. Transitional cell carcinoma of the prostate. *J Urol* 1991; 146(5):1207–1212.
29. Wood DP Jr., Montie JE, Pontes JE, VanderBrug Medendorp S, Levin HS. Transitional cell carcinoma of the prostate in cystoprostatectomy specimens removed for bladder cancer. *J Urol* 1989; 141(2):346–349.
30. Lebreton T, Herve JM, Barre P, et al. Urethral recurrence of transitional cell carcinoma of the bladder. Predictive value of preoperative latero-montanal biopsies and urethral frozen sections during prostatic cystectomy. *Eur Urol* 1998; 33(2):170–174.
31. Nixon RG, Chang SS, Lafleur BJ, Smith JA, Cookson MS. Carcinoma in situ and tumor multifocality predict the risk of prostatic urethral involvement at radical cystectomy in men with transitional cell carcinoma of the bladder. *J Urol* 2002; 167:502–505.
32. Revelo MP, Cookson MS, Chang SS, Shook MF, Smith JA Jr., Shappell SB. Incidence and location of prostate and urothelial carcinoma in prostates from cystoprostatectomies: implications for possible apical sparing surgery. *J Urol* 2004; 171:646–651.
33. Madersbacher S, Hochreiter W, Burkhard F, et al. Radical cystectomy for bladder cancer today—a homogeneous series without neoadjuvant therapy. *J Clin Oncol* 2003; 21(4):690–696.
34. Stein JP, Lieskovsky G, Cote R, et al. Radical cystectomy in the treatment of invasive bladder cancer: longterm results in 1,054 patients. *J Clin Oncol* 2001; 19:666–675.
35. Gill IS, Kaouk JH, Meraney AM, Desai MM, Ulchaker JC, et al. Laparoscopic radical cystectomy and continent orthotopic ileal neobladder performed completely intracorporeally: the initial experience. *J Urol* 2002; 168:13–18.
36. Turk I, Deger S, Winkelmann B, Schonberger B, Loening S. Laparoscopic radical cystectomy with continent urinary diversion (rectal sigmoid pouch) performed completely intracorporeally: the initial 5 cases. *J Urol* 2001; 165:1863–1866.
37. Gupta NP, Gill IS, Fergany A, Nabi G. Laparoscopic radical cystectomy with intracorporeal ileal conduit diversion: five cases with a 2-year follow-up. *BJU Int* 2002; 90:391–396.
38. Hollowell CMP, Christiano AP, Ateinber GD. Technique of Hautmann ileal neobladder with chimene modification: interim results in 50 patients. *J Urol* 2000; 163:47.
39. Stein JP, Skinner DG. Results with radical cystectomy for treating bladder cancer: a “reference standard” for high-grade, invasive bladder cancer. *BJU Int* 2003; 92(1):12–17.

LAPAROSCOPIC RADICAL CYSTECTOMY: TECHNIQUE

Karim A. Touijer

Department of Urology, Sidney Kimmel Center for Prostate and Urologic Cancers, Memorial Sloan-Kettering Cancer Center, New York, New York, U.S.A.

Stephen J. Savage

Department of Urology, Medical University of South Carolina, Charleston, South Carolina, U.S.A.

<ul style="list-style-type: none"> ■ INTRODUCTION ■ PATIENT SELECTION ■ PREOPERATIVE PATIENT PREPARATION ■ SURGICAL TECHNIQUE <ul style="list-style-type: none"> Patient Positioning Port Placement ■ LAPAROSCOPIC RADICAL CYSTECTOMY IN THE MALE PATIENT <ul style="list-style-type: none"> Posterior Peritoneal Incision (Pouch of Douglas to Ureters) Further Dissection and Transection of the Ureters Control of the Posterior Vesical Pedicle 	<ul style="list-style-type: none"> Anterior Approach and Development of the Retzius Space Transection of the Vesical and Prostatic Vascular Pedicle Apical Dissection ■ LAPAROSCOPIC RADICAL CYSTECTOMY IN THE FEMALE PATIENT ■ ROBOT-ASSISTED LAPAROSCOPIC RADICAL CYSTECTOMY ■ URINARY DIVERSIONS ■ CONCLUSION ■ REFERENCES
---	---

INTRODUCTION

Radical cystectomy is the most effective treatment for patients with organ-confined muscle-invasive or recurrent high-grade bladder cancer. The laparoscopic approach to radical cystectomy with urinary diversion is the culmination of many advances in the growing field of minimally invasive urology. However, experience with this technique remains limited. After initial experience in experimental porcine models (1,2), data are now becoming available on small series of completely intracorporeally performed laparoscopic radical cystectomy with a variety of urinary diversions (3–5).

PATIENT SELECTION

Bladder cancer is a potentially lethal disease; the patient's prognosis is partially dictated by the quality of the cystectomy and extent of the lymphadenectomy (6–9). The introduction of the laparoscopic approach with its potential low morbidity profile is, in part, an effort to preserve high quality of care while minimizing the often debilitating effects of cystectomy and permitting more patients the opportunity to undergo this potentially lifesaving procedure. This approach should by no means compromise the oncologic quality of radical cystectomy. Laparoscopic radical cystectomy is still in its early stages, and its long-term advantages and disadvantages are poorly defined. Therefore, patient selection is paramount to a successful laparoscopic radical cystectomy program.

Patients with bulky and locally advanced primary disease are not good candidates for laparoscopic radical cystectomy. Prior pelvic radiation therapy, prior prostate surgery, extensive transperitoneal surgery, and/or low ability to tolerate prolonged pneumoperitoneum (i.e., chronic obstructive pulmonary disease) constitute relative contraindications to laparoscopic radical cystectomy at this time. The laparoscopic approach for the treatment of invasive bladder cancer is promising, and with the accumulated experience its indications will continue to safely expand.

PREOPERATIVE PATIENT PREPARATION

Preoperatively patients receive a mechanical bowel preparation, identical to that for open surgery. Thromboprophylaxis is ensured by sequential compressive devices on both lower extremities and low-molecular-weight heparin administered prior to surgery, then daily afterwards until discharge from the hospital. Thromboprophylaxis is essential given the multiple risk factors, including oncologic surgery, pelvic surgery, laparoscopy, and prolonged operative time. Patients also receive antibiotic prophylaxis.

SURGICAL TECHNIQUE

Patient Positioning

The patient is positioned in a low lithotomy position or a supine position with the lower extremities apart on spreader bars to allow access to the perineum. Both arms are set alongside the body and the patient is secured to the operating table with surgical tape. A right-handed surgeon stands on the patient's left with the assistant on the opposite side; the monitor is placed between the patient's legs, at the surgeon's eye level and as close as necessary (Fig. 1). The operating table is placed in a steep Trendelenburg position during surgery.

Port Placement

The pneumoperitoneum is obtained through a Veress needle and set at a pressure of 12 mmHg. A five to six-port fan-shaped transperitoneal approach is used. First a 12 mm port is inserted supraumbilically and used for the laparoscope. The peritoneal contents are examined for trocar injury and evidence of metastasis, and then the remaining four to five ports are placed under visual control (Fig. 2).

A bilateral pelvic lymphadenectomy is performed either initially or after the cystectomy is completed. The authors' preference is to perform the lymphadenectomy after the cystectomy, prior to specimen extraction in the male, and following specimen extraction in the female (Fig. 3). The lymphadenectomy is often extended to at least the common iliac bifurcation and often to the aortic bifurcation. Laparoscopic bilateral pelvic lymphadenectomy is described elsewhere in this book and will not be covered here Table 1.

LAPAROSCOPIC RADICAL CYSTECTOMY IN THE MALE PATIENT (Table 1)

Posterior Peritoneal Incision (Pouch of Douglas to Ureters)

The sigmoid colon is retracted gently by the assistant, moving any redundant rectum cephalad. In rare cases, a redundant sigmoid colon can be retracted cephalad using a silk



FIGURE 1 ■ Operating room setup demonstrating patient in lithotomy with position of robotic arm camera holder.

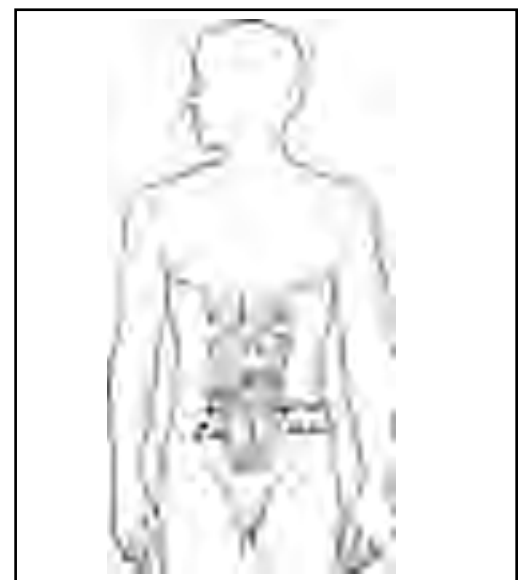
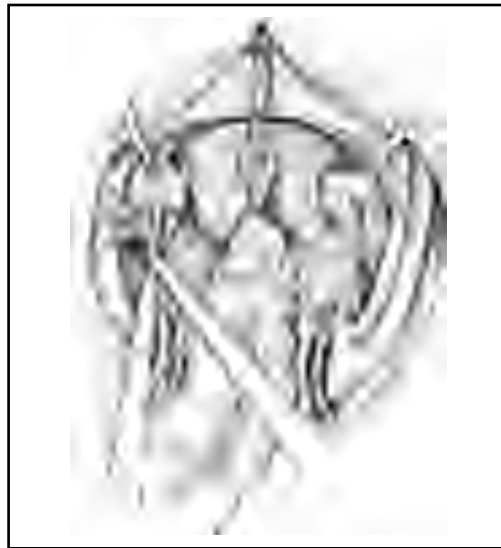

FIGURE 2 ■ Schematic of port placement and port size for laparoscopic radical cystectomy.

TABLE 1 ■ Surgical Steps of Laparoscopic Radical Cystectomy

	Technical steps
First step	Posterior peritoneal incision to access through the cul-de-sac of Douglas
Second step	Dissection of the ureters
Third step	Control of the posterior vesical pedicle
Fourth step	Anterior approach and development of the Retzius space
Fifth step	Transection of the lateral vesical and prostatic vascular pedicles
Sixth step	Apical dissection, transection, and specimen entrapment
Seventh step	Bilateral pelvic lymph node dissection

**FIGURE 3 ■** Pelvis after cystectomy, showing completed right-side pelvic lymphadenectomy and dissection for left-sided pelvic lymphadenectomy.**FIGURE 4 ■** Initial posterior peritoneal incision to access posterior cul-de-sac. The dotted line illustrates planned continued incision of posterior peritoneum overlying the ureter and lateral pedicle.

retraction suture placed through the tenia coli and brought through the skin with a suture passer. The surgeon incises the posterior vesical peritoneum transversally approximately 2 cm above the recess of the pouch of Douglas. This dissection should follow the inferior peritoneal flap; it exposes the outlines of the vesicular complex formed by the vasa deferentia and seminal vesicles. The incision is carried proximally near the lateral pelvic sidewall and to the pelvic brim in order to expose the ureters (Fig. 4).

The seminal vesicular complex is seen through Denonvilliers' fascia. Unlike laparoscopic radical prostatectomy, the vesicular complex is not mobilized but left en-bloc with the bladder. Denonvilliers fascia should be respected at this level and opened lower and closer to the prostate. At that location, Denonvilliers fascia is incised medially and horizontally, bringing into view the prerectal fatty tissue. Dissection is then taken in the plane between the posterior aspect of the prostate and the anterior rectal wall as far as the prostatic apex. This dissection separates the rectum from the posterior and lateral vascular pedicles of the bladder and prostate.

Further Dissection and Transection of the Ureters

The ureters are identified as they cross the iliac vessels and dissected down to the bladder. The ureters are clipped distally (Fig. 5). During this dissection care is taken to leave ample tissue around the ureter and thus preserve its vascular supply. Laparoscopically, it is possible to dissect the ureters closer to the bladder than during open surgery. However, one must be sure to get negative surgical margins. Therefore, once the ureters are divided, the distal ureteral margins are sent for frozen section pathologic analysis with the right and left ureter marked separately. The clips are left on the ureter to allow dilation for later anastomosis. A long stay suture is passed through the distal ureter to facilitate later identification and traction. It is prudent to complete the cephalad ureteral dissection at this point. The limit of ureteral dissection is typically 4–5 cm where it crosses the iliac artery.



FIGURE 5 ■ Transection of right ureter demonstrating clips on either side with stay suture through proximal end.



FIGURE 6 ■ Posterior pedicle dissection showing Endo-GIA on right posterior pedicle with care taken not to transect the distal ureteral stump.

Control of the Posterior Vesical Pedicle

The bladder is pulled anteriorly and the rectum retracted posteriorly. This maneuver exposes the posterior vesical pedicle, which is controlled by either Endo-GIA^a staplers (vascular 2.5 mm stapler), Harmonic scalpel, surgical clips, bipolar cautery, or a combination (Fig. 6) (4,10,11). After complete transection of the posterior pedicle, the bladder has only lateral, anterior, and apical attachments.

Anterior Approach and Development of the Retzius Space

The bladder is filled with 120–200 mL of saline to help delineate its contours. The peritoneum is opened from one umbilical ligament to the other and the incision is extended upward to include the urachus, which is divided near the umbilicus (Fig. 7). The anterior surface of the bladder is mobilized and the prevesical and preprostatic space entered. The endopelvic fascia exposed is opened, uncovering the levator ani fibers. The latter are bluntly pushed away from the prostate; the puboprostatic ligaments are divided, giving clear access to the dorsal venous complex, which is ligated with 2/0 Vicryl on an SH needle. Transection of the dorsal venous complex is left for the final apical dissection. Once completed, this step provides adequate space for accurate control of the lateral vascular pedicle.

Transection of the Vesical and Prostatic Vascular Pedicle

At this point the bladder is pulled laterally and the rectum posteriorly to expose the lateral pedicle. The vascular control can be performed by either Endo-GIA staplers, harmonic scalpel, surgical clips, bipolar cautery, or a combination (Fig. 8). The unincised peritoneal lining includes the vas deferens, which is secured during the complete transection. If non-nerve-sparing surgery is employed, the transection can simply be taken down to the prostatic apex. If a nerve sparing dissection is planned, the nerves must be teased off the base of the prostate and seminal vesicles as in laparoscopic radical prostatectomy.

Apical Dissection

The bladder is pulled cephalad; the dorsal venous complex is incised in a tangential fashion to avoid iatrogenic incision into the prostate at the apex. Gradually an avascular plane of dissection situated between the dorsal venous complex and the urethra is developed. Alternatively, if a nonorthotopic diversion is planned, one can use the Endo-GIA staplers to control the dorsal venous complex. The proximal aspect of the urethra

^aU.S. Surgical Corp., Norwalk, CT.

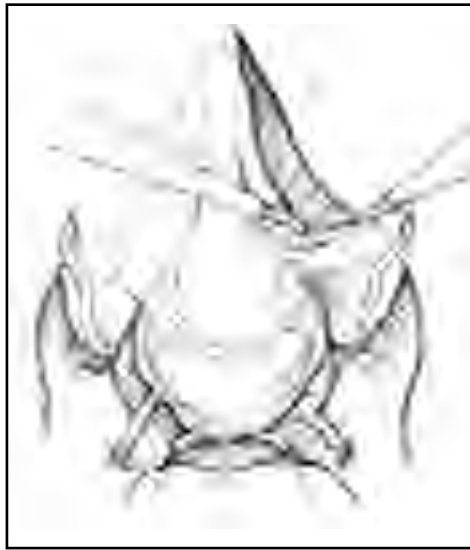

FIGURE 7 ■ Schematic illustrating the peritoneal incision prior to entry into the prevesical space. The incision is carried anteriorly to include the urachus.

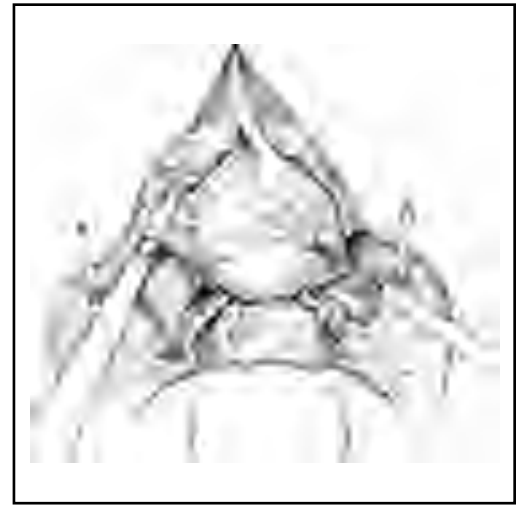

FIGURE 8 ■ Lateral pedicle transection with Endo-GIA. Contralateral traction is provided to help delineate the space.

is either clipped or sutured to prevent tumor spillage and the urethra is divided (Fig. 9), freeing the surgical specimen, which will be placed in a laparoscopy bag. The empty pelvis is now prepared for a lymphadenectomy (Fig. 10).

LAPAROSCOPIC RADICAL CYSTECTOMY IN THE FEMALE PATIENT

In women, the procedure is very similar to a laparoscopic-assisted vaginal hysterectomy, which our gynecologic colleagues have been performing for some time. Posteriorly, the peritoneum is incised at the level of the rectovesical cul-de-sac and the posterior vaginal wall is mobilized off the rectum. After control and division of the vesical vascular pedicle and the broad ligaments, a sponge stick is inserted in the posterior vaginal cul-de-sac to expose the area of vaginotomy and to help delineate the plane of excision of the anterior vaginal wall. Once freed, the surgical specimen is retrieved through the vaginal vault.




FIGURE 9 ■ Transection of posterior urethra and rectourethralis after securing bladder neck.

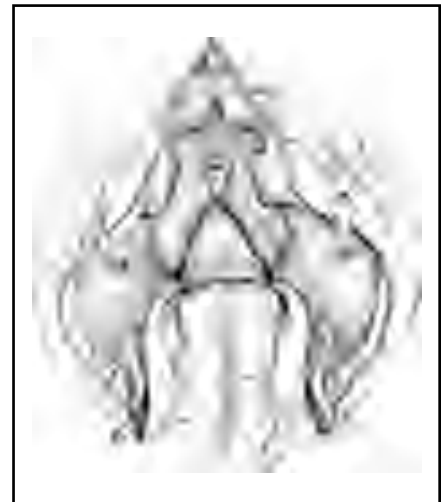


FIGURE 10 ■ View of empty pelvis after cystectomy and prior to pelvic lymphadenectomy.

ROBOT-ASSISTED LAPAROSCOPIC RADICAL CYSTECTOMY

The advent of the robotic technology has allowed many surgeons to translate standard surgical movements to the laparoscopic arena. After initial application in an animal study (12), robot-assisted radical cystectomy has been reported in the clinical setting (13–16). By allowing additional degrees of freedom of movement and a comfortable working position, the robotic assistance provides novice laparoscopy surgeons ease in suturing and knot tying. The general approach to the procedure, however, is the same.

URINARY DIVERSIONS

The urinary diversion may be an ileal conduit, an Indiana pouch, a Camey II performed extracorporally, an orthotopic ileal neobladder with Studer limb, or a rectal sigmoid pouch performed intracorporeally (4,5). These techniques are expertly described elsewhere in the text.

CONCLUSION

The small number of patients in current reported series and the short follow-up precludes any definitive morbidity or oncologic outcome analysis. The feasibility of the procedure has certainly been established. Only detailed analysis and follow-up will determine whether the short-term benefits become greater as more laparoscopic radical cystectomies are performed, and whether they attain the same oncologic efficacy as standard methods.

REFERENCES

1. Kaouk JH, Gill IS, Desai MM, et al. Laparoscopic orthotopic ileal neobladder. *J Endourol* 2001; 15:131.
2. Fergany AE, Gill IS, Kaouk JH, Meraney AM, Hafez KS, Sung GT. Laparoscopic intracorporeally constructed ileal conduit after porcine cystoprostatectomy. *J Urol* 2001; 166:285.
3. Abdel-Hakim AM, Bassiouny F, Abdel Azim MS, et al. Laparoscopic radical cystectomy with orthotopic neobladder. *J Endourol* 2002; 16:377.
4. Gill IS, Kaouk JH, Meraney AM, et al. Laparoscopic radical cystectomy and continent orthotopic ileal neobladder performed completely intracorporeally: the initial experience. *J Urol* 2002; 168:13.
5. Turk I, Deger S, Winkelmann B, Schonberger B, Loening SA. Laparoscopic radical cystectomy with continent urinary diversion (rectal sigmoid pouch) performed completely intracorporeally: the initial 5 cases. *J Urol* 2001; 165:1863.
6. Herr HW. Superiority of ratio based lymph node staging for bladder cancer. *J Urol* 2003; 169:943.
7. Herr HW. Extent of surgery and pathology evaluation has an impact on bladder cancer outcomes after radical cystectomy. *Urology* 2003; 61:105.
8. Herr H, Lee C, Chang S, Lerner S. Standardization of radical cystectomy and pelvic lymph node dissection for bladder cancer: a collaborative group report. *J Urol* 2004; 171:1823.
9. Herr HW, Faulkner JR, Grossman HB, Natal C RB, devere White R, Sarosdy MF, Crawford ED. Surgical factors influence bladder cancer outcomes: a cooperative group report. *J Clin Oncol* 2004; 22(14):2781–2789.
10. Simonato A, Gregori A, Lissiani A, Bozzola A, Galli S, Gaboardi F. Laparoscopic radical cystoprostatectomy: a technique illustrated step by step. *Eur Urol* 2003; 44:132.
11. Sorcini A, Tuerk I. Laparoscopic radical cystectomy with ileal conduit urinary diversion. *Urol Oncol* 2004; 22:149.
12. Gill IS, Sung GT, Hsu TH, Meraney AM. Robotic remote laparoscopic nephrectomy and adrenalectomy: the initial experience. *J Urol* 2000; 164:2082.
13. Menon M, Hemal AK, Tewari A, et al. Nerve-sparing robot-assisted radical cystoprostatectomy and urinary diversion. *BJU Int* 2003; 92:232.
14. Menon M, Hemal AK, Tewari A, et al. Robot-assisted radical cystectomy and urinary diversion in female patients: technique with preservation of the uterus and vagina. *J Am Coll Surg* 2004; 198:386.
15. Beecken WD, Wolfram M, Engl T, et al. Robotic-assisted laparoscopic radical cystectomy and intra-abdominal formation of an orthotopic ileal neobladder. *Eur Urol* 2003; 44:337.
16. Rimington P, Dasgupta P. Laparoscopic and robotic radical cystectomy. *BJU Int* 2004; 93:460.

LAPAROSCOPIC BOWEL SURGERY: GENERAL CONSIDERATIONS

Anthony J. Senagore

*Department of Colorectal Surgery, Cleveland Clinic Foundation,
Cleveland, Ohio, U.S.A.*

- INTRODUCTION
- PATIENT SELECTION: INDICATIONS
AND CONTRAINDICATIONS
- PERIOPERATIVE CARE
- OPERATIVE TECHNIQUES
Right Colectomy

- Sigmoid/Left Colectomy
- TECHNICAL CAVEATS/TIPS
- SUMMARY
- REFERENCES

Modified use of these resective techniques can be implemented for reservoir construction in urologic procedures.

INTRODUCTION

Data are slowly accumulating supporting the concept that the laparoscopic approach to colectomy offers significant early advantages for the management of most colorectal pathology. Data exist regarding the benefits of laparoscopic management of colon cancer and large polyps, diverticulitis, and inflammatory bowel disease. Modified use of these resective techniques can be implemented for reservoir construction in urologic procedures.

The cost-effectiveness of laparoscopic colectomy is related primarily to reductions in duration of hospitalization and a lower incidence of cardiopulmonary complications that lead to a reduced utilization of postoperative diagnostic and therapeutic investigations (1). The earlier recovery of the patient coupled with an earlier return to normal activity offers other potential cost savings to society at large (2).

Initial concerns with laparoscopic colorectal surgery related to technical difficulty, steeper learning curves, a need for specialized instrumentation and longer operating times. Secondary concerns have developed including increased hospital costs, questions about real improvements in outcome and concerns regarding safety in neoplastic disease (3). These factors have led to the slower dissemination of the technique compared to other advanced laparoscopic procedures such as Nissen fundoplication or splenectomy (4). Recent reports of "fast track" care for colectomy patients have further blurred the distinctions between outcome of laparoscopic and open colectomy because of the perception that length of stay can be dramatically reduced with open surgery. However, the majority of data report shorter duration of hospitalization for laparoscopic colectomy compared to open surgery (5-9).

PATIENT SELECTION: INDICATIONS AND CONTRAINDICATIONS

We have taken the approach that laparoscopic colectomy can be broadly applied to colorectal pathology so all patients are considered potential candidates for a laparoscopic approach. However, after initial visualization of the abdominal cavity a determination is quickly made regarding the appropriateness of proceeding. This could be based upon a larger than expected mass or worse than anticipated adhesions. Exclusions from an attempted laparoscopic colectomy are body mass index >35, and prior major abdominal surgeries (exclusive of hysterectomy, cholecystectomy, or appendectomy).

PERIOPERATIVE CARE

All patients receive a mechanical bowel preparation consisting of a clear liquid diet for 24 hours preoperatively and 3 oz of FLEETS Phosphosoda™ administered the afternoon

prior to surgery. Intravenous prophylactic cefuroxime 1 g and metronidazole 500 mg one hour prior to the procedure is administered to all nonallergic patients. A urinary catheter is inserted at surgery and removed the following morning. The perioperative care plan includes the following: preemptive analgesia with oral Voltaren^{®a} 50 mg the day before surgery; nasogastric tubes and drains are not employed routinely; and analgesia consisting of patient-controlled epidural (bupivacaine/fentanyl) or intravenous morphine for 12 to 18 hours. All patients are offered a full liquid diet as the first meal following surgery. Thereafter, dietary intake is ad libitum with no specific restrictions. Patients are encouraged to ambulate as soon as possible after the procedure, with a minimum of five walks outside the room the first postoperative day. The first postoperative morning patients are converted to oral analgesics that include hydroxycodone (one or two tablets every 6 hours) and Voltaren 50 mg TID. The intravenous catheters are removed the first postoperative morning unless the patient is nauseated or distended. Discharge criteria include the tolerance of three general meals without nausea or vomiting, absence of abdominal distention, adequate oral analgesia, and passage of flatus.

It appears that the combination of a lesser degree of trauma with laparoscopy, early feeding, and aggressive ambulation dramatically reduces the risk of postoperative ileus and allows for early discharge after laparoscopic colectomy.

It appears that the combination of a lesser degree of trauma with laparoscopy, early feeding, and aggressive ambulation dramatically reduces the risk of postoperative ileus and allows for early discharge after laparoscopic colectomy.

OPERATIVE TECHNIQUES

Right Colectomy

The operative steps (Table 1) for laparoscopic right colectomy and recommended time for completion are as follows: (5) (i) open insertion of the umbilical port for establishment of pneumoperitoneum and peritoneal inspection (two to five minutes); (ii) placement of a 12 mm port 2 cm medial to the left anterior superior iliac spine, a 5 mm port 2 cm medial to the right anterior superior iliac spine, and a 5 mm port laterally on the left side just rostral to the umbilicus, all under direct vision with pneumoperitoneum (2–10 minutes, if adhesions from prior surgeries require lysis prior to port insertion); (iii) elevation of the right colic pedicle allows dissection beneath the vessels with identification of the origin of the right colic artery and the duodenum (15–20 minutes); (iv) elevation of the right colon and proximal transverse colon off the retroperitoneum (5–10 minutes); (v) release of the hepatic flexure to mid transverse colon (15–20 minutes); (vi) division of the lateral peritoneal reflection and ligament of Treitz (10–15 minutes); (vii) exteriorization of the specimen through a 4 to 6 cm umbilical incision with use of a wound protector (Protractor^{TMb}) (two to five minutes); and (viii) extracorporeal bowel division and ileocolic anastomosis (5–10 minutes).

If the intended procedure is to mobilize the right colon rather than resect bowel then the following step modifications are used; division of the peritoneum lateral to the colon and medial mobilization of the right colon without ligation of the vessels. The remainder of the procedure is similar as bowel transection and construction of an ileocolic anastomosis is performed extracorporeally in the interest of cost-effectiveness.

Sigmoid/Left Colectomy

The operative steps (Table 2) for laparoscopic colectomy for the sigmoid or left colon and recommended times for completion are: (i) open insertion of the umbilical port for

TABLE 1 ■ Steps for Laparoscopic Right Colectomy

Open insertion of the umbilical port for establishment of pneumoperitoneum
Placement of a 12-mm port 2 cm medial to the left anterior superior iliac spine; a 5-mm port 2 cm medial to the right anterior superior iliac spine; and a 5-mm port laterally on the left side just rostral to the umbilicus
Elevation of the right colic pedicle from the retroperitoneum with ligation of the right colic artery
Elevation of the right colon and proximal transverse colon off the retroperitoneum
Release of the hepatic flexure to mid transverse colon
Division of the lateral peritoneal reflection and ligament of Treitz
Exteriorization of the specimen through a 4 to 6 cm umbilical midline incision
Extracorporeal bowel division and ileocolic anastomosis

^aNovartis, East Hanover, NJ.
^bWeck Closure Systems, Research Triangle Park, NC.

TABLE 2 ■ Steps for Laparoscopic Sigmoid/Left Colectomy

Open insertion of the umbilical port for establishment of pneumoperitoneum
Placement of a 12-mm port 2 cm medial to the right anterior superior iliac spine; a 5-mm port 2 cm medial to the left anterior superior iliac spine; and a 5-mm port laterally on the right side just rostral to the umbilicus
Mobilization of the mesosigmoid and mesorectum from the right side for identification of the left ureter and subsequent intracorporeal division of the vessels
Mobilization of the sigmoid and descending colon laterally up to the splenic flexure and medially off Gerota's fascia
Mobilization of the proximal rectum with division of the rectosigmoid junction with a linear endoscopic stapler
Division of the mesorectum at the distal resection site with control of vessels via bipolar cautery or vascular clips
Exteriorization of the specimen through a left lower quadrant muscle splitting incision for specimen resection and anvil placement within the proximal colon
Reestablishment of pneumoperitoneum and circular-stapled colorectal anastomosis

establishment of pneumoperitoneum and peritoneal inspection (two to five minutes); (ii) placement of a 12 mm port 2 cm medial to the right anterior superior iliac spine, a 5 mm port 2 cm medial to the left anterior superior iliac spine, and a 5 mm port laterally on the right side just rostral to the umbilicus, all under direct vision with pneumoperitoneum (two to five minutes); (iii) mobilization of the mesosigmoid and mesorectum from the right side for identification of the left ureter and subsequent intracorporeal division of the vessels (10–20 minutes); (iv) mobilization of the sigmoid and descending colon laterally up to the splenic flexure and medially off Gerota's fascia (10–20 minutes); (v) mobilization of the proximal rectum with division of the rectosigmoid junction with a linear endoscopic stapler (10–12 minutes); (vi) division of the mesorectum at the distal resection site with control of vessels via bipolar cautery or vascular clips (15–25 minutes); (vii) exteriorization of the specimen through a left lower quadrant muscle splitting incision for specimen resection and anvil placement within the proximal colon (15–20 minutes); and (viii) reestablishment of pneumoperitoneum and circular-stapled anastomosis (10–15 minutes). This approach allows the patient to be placed head up for dissection of the flexure at a time when pelvic visualization has already been sacrificed, rather than changing the patient's position during the earlier dissection and losing time with each loss of exposure. If a left colectomy is required then the head up position can be used prior to making the exteriorizing incision that will generally be a short midline at the umbilicus as used for right colectomy (see above). If the sigmoid colon will be used for bladder augmentation or reservoir construction then Step 3 is modified by not dividing the vascular pedicle. The mesenteric mobilization will allow easy reach of the bowel to the pelvis.

Instrumentation for the procedure has been standardized. Reusable ports, graspers, laparoscopic scissors, and cautery (monopolar and bipolar) are used. The fascia at the umbilical port site is approximated around the port via a pursestring suture of 0-polyglycolic acid suture to prevent air leaks. This suture is tied at the end of the case to close the fascial defect. The 12 mm port site is closed with 0-polyglycolic acid suture at the end of the case using a reusable fascial closure instrument. The wound is closed in layers with running 0-polyglycolic acid suture prior to reestablishing pneumoperitoneum. All skin incisions are closed with running subcuticular 4-0 polyglycolic acid suture.

TECHNICAL CAVEAT/TIP

The major pitfalls associated with laparoscopic colectomy are prolonged attempts at performing laparoscopic colectomy despite failure to progress, failure to identify key retroperitoneal structures (particularly the ureter and duodenum), and iatrogenic injuries to viscera.

The steps described above are meant to serve as guidelines for the surgeon to ensure that progress is indeed being made. Failure to identify key structures or to mobilize the bowel safely is an indication that the procedure should be converted to open. The typical conversion rate for major colon resection should be approximately 10%. It is

better to err on the side of safety. Iatrogenic damage to viscera should be a rare event indeed in the hands of an experienced laparoscopic surgeon. Even adherent viscera that must be incised can be repaired laparoscopically; however it is key to observe the operative field at all times to avoid unrecognized damage that then falls out of the visual field. It is also important that the bowel be completely mobilized to allow performance of a tension free anastomosis and to allow the bowel to reach into the pelvis if required for urologic reconstruction.

SUMMARY

- Modified use of colorectal laparoscopic techniques can be employed by urologists for bowel work and reservoir construction.
- Bowel division and reanastomosis is typically performed extracorporeally through a 4 to 6 cm umbilical incision.
- A standardized protocol of preemptive and perigesative analgesia, early feeding, and aggressive ambulation minimizes the risk of postoperative ileus.
- Early in the urologist's experience, teaming up with a laparoscopic colorectal surgeon could allow smooth incorporation of urologic bowel work.

REFERENCES

1. Young-Fadok TM, HallLong K, McConnell EJ, Gomez Rey G, Cabanela RL. Advantages of laparoscopic resection for ileocolic Crohn's disease. Improved outcomes and reduced costs. *Surg Endosc* 2001; 15(5):450–454.
2. Senagore AJ, Duepre HJ, Delaney CP, Dissanaik S, Brady KM, Fazio VW. Cost structure of laparoscopic and open sigmoid colectomy for diverticular disease: similarities and differences. *Dis Colon Rectum* 2002; 45(4):485–490.
3. Delaney CP, Kiran RP, Senagore AJ, Brady K, Fazio VW. Case-matched comparison and financial outcome after laparoscopic or open colorectal surgery. *Ann Surg* 2003; 238(1):67–72.
4. Franklin ME Jr, Rosenthal D, Abrego-Medina D, et al. Prospective comparison of open vs. laparoscopic colon surgery for carcinoma. Five-year results. *Dis Colon Rectum* 1996; 39(10 suppl):S35–S46.
5. Young-Fadok TM, Nelson H. Laparoscopic right colectomy: five-step procedure. *Dis Colon Rectum* 2000; 43(2):267–271; discussion 271–3.
6. Goh YC, Eu KW, Seow-Choen F. Early postoperative results of a prospective series of laparoscopic vs. Open anterior resections for rectosigmoid cancers. *Dis Colon Rectum* 1997; 40(7):776–780.
7. Lacy AM, Garcia-Valdecasas JC, Delgado S, et al. Laparoscopy-assisted colectomy vs. open colectomy for treatment of non-metastatic cancer: a randomized trial. *Lancet* 2002; 359(9325):2224–2229.
8. Delaney CP, Fazio VW, Senagore AJ, Robinson B, Halverson AL, Remzi FH. 'Fast track' postoperative management protocol for patients with high co-morbidity undergoing complex abdominal and pelvic colorectal surgery. *Br J Surg* 2001; 88(11):1533–1538.
9. Chapman AE, Levitt MD, Hewett P, Woods R, Sheiner H, Maddern GJ. Laparoscopic-assisted resection of colorectal malignancies: a systematic review. *Ann Surg* 2001; 234(5):590–606.

LAPAROSCOPIC URINARY DIVERSION

David Canes, Harrison K. Rhee, and Ingolf Tuerk

Lahey Clinic Medical Center, Institute of Urology, Burlington, Massachusetts, U.S.A.

- INTRODUCTION
- INDICATIONS AND CONTRAINDICATIONS
- A: NONCONTINENT URINARY DIVERSIONS
- ILEAL CONDUIT
 - Lap-Assisted Ileal Conduit Urinary Diversion
 - Patient Preparation
 - Radical Cystectomy
 - Transposition of Left Ureter
 - Harvesting Small Bowel
 - Restoring Bowel Continuity
 - Ureteroileal Anastomoses
 - Creation of Ileal Stoma
 - Closure and Drains
 - Postoperative Period
- PURE LAPAROSCOPIC ILEAL CONDUIT URINARY DIVERSION
 - Harvesting Small Bowel
 - Restoring Bowel Continuity
 - Creation of Ileal Stoma
 - Ureteroileal Anastomoses
 - Closure and Drains
 - Postoperative Period
 - Cutaneous Ureterostomy
 - Ileovesicostomy
- B: CONTINENT URINARY DIVERSION
- ORTHOTOPIC NEOBLADDER
 - Lap-Assisted Orthotopic Ileal Neobladder
 - Patient Preparation
 - Radical Cystectomy
 - Transposition of Left Ureter
 - Harvesting Small Bowel
 - Restoring Bowel Continuity
 - Creation of Neobladder
 - Urethronovesical Anastomosis
 - Ureteroneovesical Anastomoses
 - Closure and Drains
 - Postoperative Period
- PURE LAPAROSCOPIC ORTHOTOPIC ILEAL NEOBLADDER
 - Harvesting Small Bowel
 - Restoring Bowel Continuity
 - Creation of Neobladder
 - Urethronovesical Anastomoses
 - Ureteroneovesical Anastomoses
 - Closure and Drains
 - Postoperative Period
 - Rectosigmoid Pouch
- LAPAROSCOPIC MAINZ II POUCH (SIGMA-RECTUM POUCH)
 - Patient Preparation
 - Radical Cystectomy
 - Creation of Sigmoid Pouch
 - Ureteral Reimplantation
 - Closure and Drains
 - Postoperative Period
 - Continent Catheterizable Stomal Reservoirs
- FUTURE DIRECTIONS
- SUMMARY
- REFERENCES
- COMMENTARY: John P. Stein
- COMMENTARY: Urs E. Studer

INTRODUCTION

In an astonishingly short period of time, laparoscopic reconstructive urology has become a feasible option for the experienced laparoscopist. The evolution from purely extirpative laparoscopic procedures to the creation of complex urinary diversions completely intracorporeally has been rapid. As urologists' experience with laparoscopic prostatectomy expanded, the additional control of the vesical pedicles with stapling devices brought laparoscopic radical cystectomy within reach. Subsequent construction of a urinary diversion remains a significant challenge. The past decade has witnessed profound strides in laparoscopic reconstructive urology since 1992 when Parra et al. performed the first laparoscopic cystectomy for recurrent pyocystitis in a 27-year-old paraplegic woman who already had an ileocolonic reservoir with a continent stoma created five months earlier. That same year, the first laparoscopic-assisted ileal conduit was reported by Kozminski and Partamian, where a cystectomy was not performed.

Currently, many of the commonly employed urinary diversions have been demonstrated to be technically possible laparoscopically owing to a series of well-designed animal experimental models, followed by clinical experience, increasing facility with intracorporeal suturing techniques, and the continual refinement of laparoscopic instrumentation. The various types of urinary diversions that have been

TABLE 1 ■ Summary of Published Approaches to Selected Urinary Diversions

	Pure	Assisted
<i>Noncontinent diversions</i>		
Ileal conduit	✓	✓
Cutaneous ureterostomy		✓
Ileovesicostomy	✓	✓
<i>Continent diversions</i>		
Ileal neobladder	✓	✓
Rectosigmoid pouch	✓	✓
Cutaneous catheterizable reservoir		✓
Mitrofanoff urinary stoma	✓	✓

Note: A check mark indicates the procedure has been performed either purely laparoscopically or laparoscopic-assisted.

performed laparoscopically can be subdivided into noncontinent urinary diversions (cutaneous ureterostomy, incontinent ileovesicostomy, ileal conduit) and continent urinary diversions (rectosigmoid pouch, catheterizable reservoir, and orthotopic neobladder). Because each of these techniques is in evolution, there is no universally agreed upon technique. Tables 1 and 2 summarize the published approaches to particular urinary diversions to date.

INDICATIONS AND CONTRAINDICATIONS

Following radical cystectomy, and in certain cases for benign conditions, the flow of urine is directed either through a conduit, the so-called noncontinent diversion, or a continent reservoir. The latter includes continent reservoirs with catheterizable stomas in which a low-pressure reservoir is fashioned from a detubularized bowel segment. When the urethra is not involved with cancer, appropriate patients may have a reservoir attached to their native urethra as an orthotopic neobladder. The latter is the gold-standard urinary diversion for patients undergoing radical cystectomy for muscle invasive bladder cancer.

General guidelines for choosing the type of laparoscopic urinary diversion best suited to each patient do not differ from their open surgical indications.

There are technical advantages specific to certain laparoscopic procedures, however, particularly in regards to bowel fixation and ease of suturing. The choice of bowel segment is made with careful consideration of expected metabolic disturbances as they interact with existing medical conditions, as with open surgery.

At all times, sound oncologic principles and the creation of an appropriate urinary diversion suited to the individual patient take precedence. If the surgeon is unable to perform the desired diversion by laparoscopic techniques, open surgery should be employed.

In cases of locally advanced pelvic malignancy, urinary diversion may be indicated without cystectomy. The remainder of patients include those with neurogenic bladder with chronic catheterization, refractory hemorrhagic cystitis, or other conditions in which the bladder may be left in situ while urinary flow is diverted.

Complex reconstructive laparoscopic surgery begins with careful patient selection. In cases where urinary diversion is required following radical cystectomy, exclusion criteria for the cystectomy portion of the procedure will generally dominate the decision process. Common exclusion criteria for laparoscopic surgery in general will apply. Multiple prior abdominal surgeries portend extensive adhesions and usually preclude laparoscopic access; however, on an individual basis, prior surgery is only a relative contraindication. Obesity must also be evaluated in each individual case. For instance, the exact distribution of subcutaneous abdominal fat differs amongst individuals. In cases where the fat is heavily distributed in the lower abdominal and suprapubic regions, excessive traction on trocars to obtain optimal instrument angles may be a limiting factor. As in open surgery, significant obesity may prevent adequate creation of an everted stoma without excessive mesenteric tension. Prior abdominal or pelvic radiation therapy is also a relative contraindication to laparoscopic urinary diversion but may influence the choice of bowel segment.

General guidelines for choosing the type of laparoscopic urinary diversion best suited to each patient do not differ from their open surgical indications.

At all times, sound oncologic principles and the creation of an appropriate urinary diversion suited to the individual patient take precedence. If the surgeon is unable to perform the desired diversion by laparoscopic techniques, open surgery should be employed.

TABLE 2 ■ Important Reports of Laparoscopic Urinary Diversion

Year	Author	Case profile	n	Male/female	Urinary diversion	Specimen retrieval	Complete intracorporeal?	Operative time (hrs)	No. of ports	LOS (day)	Firsts
1992	Kozminski, Partamian	No cystectomy	1	M	Ileal conduit	n/a	No	6.3	5	7	First lap ileal conduit
1995	Bajadaz	TCC	1	F	Ileal conduit	R flank mini-lap	No (right/left extended port sites)	8.0	5	Not specified	First lap radical cystectomy and ileal conduit
1995	Puppo	TCC	5	F	Cutaneous ureterostomy (1), ileal conduit (4)	Transvaginal (4), midline lap (1)	No (mini-lap at stoma site)	6-9	5	7-18	
1999	Denewer	TCC (5), SCC (2), verrucous (2), anaplastic (1)	10	M (9), F (1)	Sigmoid pouch	Infraumbilical midline	No (infraumbilical midline)	2.6 for laparoscopic portion, 55 minutes for pouch	4	10-13	
2000	Gill	TCC	2	M	Ileal conduit	Extended port site	Yes	10-11.5	6	6	First LRC ileal conduit completely intracorporeally
2000	Potter	Neurogenic bladder	1	M	Ileal conduit	n/a	Yes	4.5	5	Not specified	
2001	Tuerk	TCC	5	M (3), F (2)	Sigma rectum (Mainz II)	None (transrectal)	Yes	7.4	6	10	First LRC with intracorporeal continent urinary diversion
2002	Abdel-Hakim	TCC (8), SCC (1)	9	M (8), F (1)	Ileal orthotopic neobladder (modified Caley II)	Abdominal incision	No	8.3 mean	5-6	Not specified	
2002	Gaboardi	TCC	1	M	Ileal orthotopic neobladder	Supraumbilical incision	No	7.5	5	7	
2002	Gill	TCC	3	M (2), F (1)	Studer orthotopic neobladder (2), Indiana pouch (1)	Extended port site	Yes (orthotopic neobladder); no (Indiana Pouch)	7-10.5	6-7	5-12	First complete intracorporeal LRC with orthotopic neobladder
2002	Peterson	TCC	1	M	Ileal conduit	Hand port	No (hand port)	7.0	4 + hand	7	Only report of hand-assisted LRC with ileal conduit
2003	Balaji	Radiation cystitis (2), TCC (1)	3	M (2), F (1)	Ileal conduit	Extended port site	Yes	11.5 mean for all three, 10.4 for diversion in 2 patients undergoing diversion alone	5 (robotic)	5-10	First complete intracorporeal robotic LRC
2003	Hemal	TCC (9), SCC (1)	10	M (9), F (1)	Ileal conduit	Infraumbilical midline	No (infraumbilical midline)	6.48 mean	5-6	10.8 mean	
2003	Menon	TCC	17	M (14), F (3)	Ileal conduit (3), W-pouch (10), double chimney (2), T-pouch (2)	Suprapubic incision	No	2.3 robotic radical cystectomy, 2 ileal conduit, 2.8	6 (robotic)	Not specified	
2004	Menon	TCC	3	F	Ileal conduit (1), W-pouch (1), T-pouch (1)	Infraumbilical midline	No	orthotopic neobladder 3 robotic radical cystectomy, 2.16 ileal conduit, 3 orthotopic neobladder	5	5-8	

Abbreviations: Lap, laparoscopy; LRC, laparoscopic radical cystectomy.

A: NONCONTINENT URINARY DIVERSIONS

ILEAL CONDUIT

Kozminski and Partamian performed the first laparoscopic-assisted ileal conduit diversion in 1992. Their procedure did not include a cystectomy.

Sanchez de Badajoz et al. reported the first laparoscopic combined radical cystectomy and laparoscopic-assisted ileal conduit in 1995 in a 64-year-old woman with high-grade muscle invasive transitional cell carcinoma.

Ileal conduit urinary diversion is commonly employed and has few short-term complications. Initial isolated reports and clinical series describing laparoscopic ileal conduit urinary diversion took advantage of the fact that radical cystectomy specimens are often removed through laparotomy incisions, and therefore used open-assisted or mini-laparotomy techniques.

Kozminski and Partamian performed the first laparoscopic-assisted ileal conduit diversion in 1992. Their procedure did not include a cystectomy. A total of five port sites were used, one of which served as the stoma site. Both ureters were mobilized and transected laparoscopically, whereas isolation of the ileal segment, restoration of small bowel continuity, and bilateral ureteroileal anastomoses were all performed extracorporeally by elevating a small loop of ileum through a port site. The stoma was fashioned last. Operative time was 6 hours and 20 minutes.

Sanchez de Badajoz et al. reported the first laparoscopic combined radical cystectomy and laparoscopic-assisted ileal conduit in 1995 in a 64-year-old woman with high-grade muscle invasive transitional cell carcinoma. Again, an open-assisted approach was used to create the ileal conduit; however, two trocar sites were used to externalize the bowel segment instead of one. The ileal loop was first extracted through an extended right-sided flank incision, where the ileal segment was isolated, bowel continuity was restored, and the ipsilateral ureteroileal anastomosis performed. The contents were then placed back into the peritoneal cavity and brought out a left-sided extended trocar incision for the second ureteroenteric anastomosis. The authors note that their technique requires less mobilized ureteral length, and maintains the ileal segment in a transverse lie. In 1994, the same group reported a case in which no cystectomy was performed for a patient with a solitary left kidney who had previously undergone a partial cystectomy and adjuvant radiotherapy. The single ureteroileal anastomosis was performed through a widened left-sided port site, which also served as the eventual stoma site. Operative time was four hours. Puppo and colleagues reported mini laparotomy at a single stoma site in another four patients following laparoscopically assisted transvaginal radical cystectomy in 1995. In 2002, Peterson and colleagues reported the first case of laparoscopic hand-assisted radical cystectomy with ileal conduit.

They employed four laparoscopic ports and one infraumbilical hand port. Following radical cystectomy, pneumoperitoneum was released and the hand port ring was left in place for skin retraction. The ileal loop was delivered through this incision, and a Wallace ureteroileal anastomosis was subsequently performed. In this particular case, a separate stoma site was created due to an impractical location of their existing right-sided 12-mm port site. Operative time was seven hours, blood loss was 750 mL.

Hemal et al. published their series of 10 patients who underwent laparoscopic radical cystectomy and ileal conduit reconstructed through an infraumbilical incision through which the specimen had been retrieved. A right-sided 12-mm port site was used for the stoma site. Mean operative time was 6.5 hours. They concluded that the extracorporeal reconstruction of the ileal conduit was advantageous in two respects: (1) decreased operative time, and (2) decreased cost, particularly in obviating the need for stapling devices to restore ileal continuity.

Currently, laparoscopic radical cystectomy, bilateral pelvic lymphadenectomy, and ileal conduit can be performed using a mini-lap technique with operative times comparable to open surgery.

Sorcini and Tuerk reported a case in which the operative time was less than five hours. The first two reports of complete intracorporeal techniques for ileal conduit diversion were in 2000 by Potter et al. (without cystectomy) as well as Gill et al. (following radical cystoprostatectomy).

Potter and colleagues performed laparoscopic ileal conduit without cystectomy as a treatment for neurogenic bladder in a 28-year-old man. Five port sites were used, and total operative time was 4.5 hours. With the ileal segment pulled out through the eventual stoma site, a Babcock clamp was negotiated down and through ileotomies, the ureters were pulled into the conduit, and a modified Bernstein anastomosis was performed. The patient had anastomotic edema in the short term, but long-term patency at five years.

Currently, laparoscopic radical cystectomy, bilateral pelvic lymphadenectomy, and ileal conduit can be performed using a mini-lap technique with operative times comparable to open surgery.

Gill et al. reported the first two cases of completely intracorporeal laparoscopic radical cystoprostatectomy, bilateral pelvic lymphadenectomy, and ileal conduit urinary diversion.

Gill et al. reported the first two cases of completely intracorporeal laparoscopic radical cystoprostatectomy, bilateral pelvic lymphadenectomy, and ileal conduit urinary diversion.

This clinical report was elegantly substantiated first in a porcine model, where the technique was refined in 10 pigs. Preservation of renal function was preserved in surviving animals, and although six animals developed stomal stenosis at the skin, unique healing characteristics of porcine skin were postulated to account for this observation. In their subsequent clinical report in two men, operative times were 11.5 and 10 hours, and blood loss was 1200 and 1000 mL, respectively. A six-port transperitoneal approach was used. The most salient feature of Gill's technique involved initial creation of the stoma, which effectively anchors the external end of the ileal segment, greatly facilitating freehand intracorporeal suturing of the ureteroileal anastomosis. In addition, laparoscopic optical magnification afforded precise mucosa-to-mucosa approximation. Although operative times were lengthy, this important study demonstrated that this complex ablative and reconstructive urologic procedure was feasible laparoscopically. As expected, further experience shortened operative times, and unpublished data mentioned in an accompanying editorial comment suggested that subsequent cases were performed in less than eight hours, and as short as 6.5 hours in one patient.

This was performed in three patients, two with radiation cystitis and one with transitional cell carcinoma. Still early in the learning curve, the mean operative time was 11.5 hours. Mean blood loss was 250 mL. Similar to the technique described by Gill et al., the stoma was created first, and Bricker-type ureteroileal anastomoses were created using the DaVinci robot.

LAP-ASSISTED ILEAL CONDUIT URINARY DIVERSION

At the authors' institution, laparoscopic radical cystoprostatectomy proceeds laparoscopically, while the ileal conduit and stoma are created through a mini laparotomy. Several institutions perform a totally intracorporeal laparoscopic ileal conduit diversion. This technique is described below.

Patient Preparation

Informed consent is obtained with a discussion of risks including but not limited to adjacent organ injury and unrecognized bowel injury. Patients are made aware that safety is paramount, and open conversion may be required for completion of the planned procedure. Patients undergo a full mechanical bowel preparation at home with 4 L of polyethylene glycol one day prior to surgery. Oral antibiotics covering normal intestinal flora are also given. The patient is admitted the morning of surgery. Preoperative antibiotic prophylaxis with a second-generation cephalosporin at induction of anesthesia continues for the first postoperative day. Lower extremity compressive devices are applied. Once general anesthesia is induced, the gastric contents are emptied with a nasogastric tube, which remains in place postoperatively. A 16-French Foley catheter is placed to drain the bladder.

Radical Cystectomy

Radical cystectomy proceeds as described elsewhere. Several specific points deserve attention:

1. *Laparoscopic access:* Pneumoperitoneum is obtained through a standard Veress technique. A primary 10-mm trocar is placed at the umbilicus. An additional four trocars are placed in a fan-shaped distribution. Two 10-mm trocars are placed at the lateral pararectal line 10 cm above the pubic symphysis, and two 5-mm trocars 2–3 cm medial and superior to the anterior-superior iliac spines.
2. *Ureteral dissection:* Ureters are clipped and transected close to their insertion into the bladder. This greatly facilitates subsequent identification and atraumatic laparoscopic manipulation.
3. Two different colored 4-0 Vicryl holding sutures are placed at the distal ends of the ureters.
4. *Vascular pedicle control:* The vascular pedicles of the bladder and prostate are controlled with serial applications of an Endo-GIA laparoscopic stapler.

Two different colored 4-0 Vicryl holding sutures are placed at the distal ends of the ureters.

5. *Specimen retrieval:* Once the bladder is fully excised, it is placed into a laparoscopic retrieval bag. In female patients, the specimen can be retrieved immediately through an opening in the anterior vaginal wall. In male patients, the specimen bag can be placed aside during the next steps of the operation. Once the abdomen is incised for creation of ileal conduit, the specimen can then be removed.

Transposition of Left Ureter

The ureters are dissected for a distance sufficient to reach the proximal end of the loop. Care is taken to preserve periureteral tissue and thus the ureteral vascular supply. The sigmoid colon is retracted superiorly and anteriorly. Blunt dissection is used to develop a tunnel posterior to the sigmoid mesocolon and anterior to the sacrum. The left ureter is passed under the sigmoid colon using the previously placed holding suture. Ureteral length is once again confirmed to assure that both ureters reach the proximal portion of the ileal segment in order to avoid undue tension on the anastomoses. Proximal dissection of the left ureter will provide the further length needed to reach the urinary diversion.

Harvesting Small Bowel

When a right-sided trocar site coincides with the desired stoma site, the trocar site is extended 4.5 cm. When the stoma site is separate from all trocars, a 4.5-cm infraumbilical incision is made. The specimen is retrieved. The color-coded ureteral holding sutures are exteriorized. A 15-cm segment of ileum is selected with care to spare 15–20 cm proximal to the ileocecal junction. The efferent limb should reach the previously marked stoma site without undue tension or mesenteric kinking. The segment of bowel is delivered through the incision and isolated with a GIA stapler by transecting proximally and distally. The mesentery is divided below with care to preserve the major mesenteric vasculature. The isolated segment is dropped posteriorly.

A previously marked stoma site away from desired trocar sites should not compromise optimal port placement (Fig. 1).

A previously marked stoma site away from desired trocar sites should not compromise optimal port placement.

Restoring Bowel Continuity

The stapled edges of the distal and proximal ileum are removed sharply. Applications of a GIA 55-mm stapler are used to create a side-to-side, functional end-to-end anastomosis along the antimesenteric border of the small bowel. The open end of the anastomosis is then closed using a TA 55-mm stapler. The end staple line is imbricated with interrupted, absorbable suture. The window through the mesentery is then closed with interrupted absorbable suture to prevent internal hernia formation.

Ureteroileal Anastomoses

Gentle traction on the ureteral holding sutures pulls the distal ureters into the operative field. The ureters are gently spatulated for approximately 1 cm. Bilateral ureteral 6-French single “J” stents are passed into the renal pelvis. The ureters are sequentially implanted into the proximal end of the ileal segment in a standard Bricker fashion. The apices are fixed to the bowel using three interrupted 4-0 polyglactin sutures. The remainder of the ureteral implantation is performed using a running 4-0 polyglactin suture. The proximal end of the ileal conduit is replaced into the abdominal cavity. The ureteral stents are exteriorized through the ileal segment.

Creation of Ileal Stoma

The rectus fascia is partially closed, leaving space through which the conduit passes. The ileal segment is secured to the fascia using interrupted 2-0 polyglactin sutures. The stoma is matured in the standard open fashion.

Closure and Drains

In the obese patient, ureteroileal anastomoses performed through an incision may require excessive proximal ureteral mobilization. In these cases, the stoma is matured first, and the ureteroileal anastomoses are performed completely intracorporeally.

The ureters and ileal diversion are inspected for any undue tension. Once meticulous hemostasis is assured, a flat Jackson-Pratt drain is placed through a lateral 5-mm trocar site into the small pelvis. The port sites are closed in the usual fashion with fascial closure for all sites 10 mm and greater under direct vision with 0-polyglactin.

In the obese patient, ureteroileal anastomoses performed through an incision may require excessive proximal ureteral mobilization. In these cases, the stoma is matured first, and the ureteroileal anastomoses are performed completely intracorporeally.

FIGURE 1 ■ Port placement, standard five- or six-port “fan” or “V”-shaped configuration.

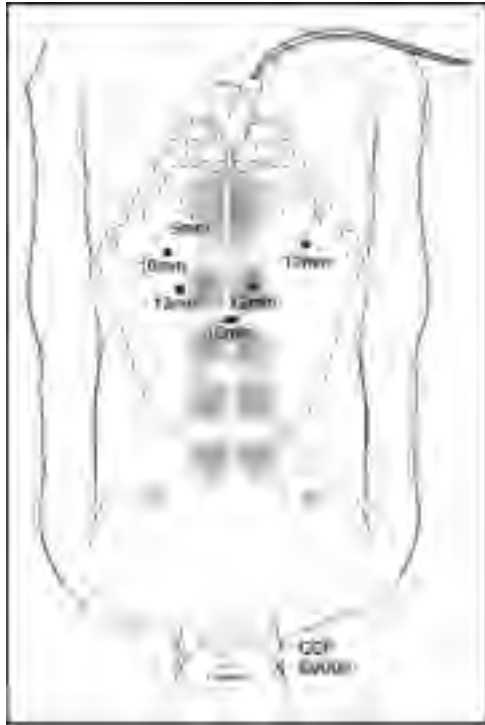


FIGURE 2 ■ Stented, bilateral ureteroileal anastomoses and ileal conduit diversion: completion of reconstruction.

Postoperative Period

Postoperative management is as with the comparable open procedure. Patients receive prophylaxis for deep venous thrombosis and ambulation is begun on the first postoperative day. The nasogastric tube is removed once bowel function returns, and the diet is advanced accordingly. The drain is removed once output diminishes. The stents are removed between postoperative days 10 and 12 (as outpatient procedure).

PURE LAPAROSCOPIC ILEAL CONDUIT URINARY DIVERSION

Preoperative preparation and laparoscopic radical cystectomy are performed as described above. The left ureter is transposed to the right side posterior to the sigmoid colon.

Harvesting Small Bowel

A 15-cm segment of ileum is selected with care to spare the distal 15–20 cm proximal to the ileocecal junction. The efferent limb should reach the abdominal wall corresponding to the previously marked stoma site without undue tension or mesenteric kinking. The segment of bowel is isolated with an endoscopic GIA stapler by transecting proximally and distally. The mesentery is divided below these areas with care to preserve the major mesenteric vasculature. Endoscopic staplers, the harmonic scalpel, or serial application of laparoscopic clips can be used to transect the mesentery with complete hemostasis. The isolated segment is dropped posteriorly.

Restoring Bowel Continuity

The stapled edges of the distal and proximal ileum are removed sharply. Applications of an endoscopic GIA stapler are used to create a side-to-side, functional end-to-end anastomosis along the antimesenteric border of the small bowel. The open end of the anastomosis is then closed using an endoscopic TA stapler. The end staple line is imbricated intracorporeally with interrupted, absorbable suture. The window through the mesentery is then closed with interrupted absorbable suture to prevent internal hernia formation.

Creation of Ileal Stoma

A previously marked stoma site away from desired trocar sites should not compromise optimal port placement (Fig. 1).

A previously marked stoma site away from desired trocar sites should not compromise optimal port placement.

The previously marked stoma site is matured in the standard everting fashion. The ileal segment is secured to the fascia using interrupted 2-0 polyglactin sutures.

Ureteroileal Anastomoses

Gentle traction on the ureteral holding sutures pulls the distal ureters to the proximal end of the ileal segment. The ureters are spatulated for approximately 1 cm. Then 6-French single "J" stents are grasped by a laparoscopic right angle clamp, and inserted through the stoma into the conduit lumen. The right angle clamp tents the ileal loop at the desired ileotomy site. A laparoscopic electrosurgical J-hook is used to create the ileotomy and the stent is delivered into the abdominal cavity. The ureters are sequentially implanted in a standard Bricker fashion. The apices are fixed to the bowel using three interrupted 4-0 poliglecaprone sutures. The remainder of the ureteral implantation is performed using a running 4-0 poliglecaprone suture. The stent is passed into the renal pelvis on each side when 80% of the anastomosis is complete (Fig. 2).

Creating the stoma first greatly facilitates intracorporeal suturing of the ureteroileal anastomosis by providing a point of fixation for the ileal segment.

Creating the stoma first greatly facilitates intracorporeal suturing of the ureteroileal anastomosis by providing a point of fixation for the ileal segment.

Closure and Drains

The ureters and ileal diversion are inspected for any undue tension. The abdominal cavity is irrigated with sterile antibiotic solution. Once meticulous hemostasis is assured, a flat Jackson-Pratt drain is placed through a lateral 5-mm trocar site into the pelvis. The port sites are closed in the usual fashion with fascial closure for all sites 10 mm and greater under direct vision with 0-polyglactin.

Postoperative Period

Postoperative management is as with the comparable open procedure. Patients receive prophylaxis for deep venous thrombosis and ambulation is begun on the first postoperative day. The nasogastric tube is removed once bowel function returns, and the diet is advanced accordingly. The drain is removed once output diminishes. The stents are removed between postoperative days 10 and 12.

Cutaneous Ureterostomy

This technique is covered elsewhere in this book, but is included for the sake of completeness. In patients with advanced bladder cancer or other pelvic malignancy, a palliative urinary diversion such as a cutaneous ureterostomy may be considered as an alternative to percutaneous nephrostomy tube drainage, or where such drainage may be poorly tolerated long term. Patients may be candidates to undergo general anesthesia but comorbidities preclude extensive or prolonged surgery. In other instances, palliative diversion may be advised prior to planned pelvic radiation.

Two studies have reported this procedure laparoscopically. In 1995, Loisesides et al. performed a laparoscopic transperitoneal cutaneous ureterostomy on a 59-year-old patient with a solitary functioning kidney. Repeated percutaneous nephrostomy access had exhausted this option, and after successful urinary diversion, dialysis was avoided at 18 months follow-up. In another report, Puppo et al. described their experience with videoendoscopic cutaneous ureterostomy in nine patients, six of which were performed bilaterally. The procedure was performed transperitoneally in five patients, and via a retroperitoneal approach in the remaining four.

Ileovesicostomy

For patients requiring noncontinent urinary diversion with an intact but abnormally functioning bladder, ileovesicostomy is an alternative. Hsu et al. reported a laparoscopic ileovesicostomy performed for a 58-year-old woman with multiple sclerosis and a chronic indwelling catheter. A five-port transperitoneal approach was used. The ileal segment was extruded through an extended infraumbilical port site, harvested, and intestinal continuity was restored extracorporeally. After reintroducing the proximal end into the peritoneal cavity, pneumoperitoneum was re-established and the ileovesical anastomosis was performed from the spatulated ileum to a U-shaped vesicostomy using laparoscopic freehand suturing techniques. A loop stoma was created last, for a total four-hour operative time. Abrahams et al. reported a single case of pure laparoscopic ileovesicostomy in 2003 for a 46-year-old quadriplegic man with neurogenic bladder and recurrent urinary tract infections. Their four-port transperitoneal approach took 4.5 hours. The Endo-GIA stapler was used for ileal segment isolation and restoration of bowel continuity. Freehand suturing was employed for the ileovesical anastomosis; however, there was no bladder or ileal spatulation.

Abrahams and colleagues cite reduced mesenteric tension and bowel manipulation as some of the benefits of pure laparoscopic approach to ileovesicostomy.

Abrahams and colleagues cite reduced mesenteric tension and bowel manipulation as some of the benefits of pure laparoscopic approach to ileovesicostomy.

Most patients motivated and healthy enough to undergo an extensive or prolonged laparoscopic procedure will also be those desiring the long-term quality of life benefits of a continent urinary diversion as well as the short-term recovery benefits of a laparoscopic approach.

Gill et al. published the initial two cases of completely intracorporeal laparoscopic radical cystectomy and orthotopic Studer pouch in a 42-year-old woman and 57-year-old man, respectively.

B: CONTINENT URINARY DIVERSION

Most patients motivated and healthy enough to undergo an extensive or prolonged laparoscopic procedure will also be those desiring the long-term quality of life benefits of a continent urinary diversion as well as the short-term recovery benefits of a laparoscopic approach.

ORTHOTOPIC NEOBLADDER

From a quality-of-life perspective, orthotopic neobladder is arguably the ideal form of urinary diversion in the appropriate patient. Using either small bowel or sigmoid colon, the orthotopic neobladder is the method of choice for diverting the urine in men and women undergoing radical prostatectomy for muscle invasive transitional cell carcinoma. Increasing facility with the urethrovaginal anastomosis derives directly from experience with laparoscopic radical prostatectomy. The operation is technically demanding and sits on the cutting edge of laparoscopic reconstructive surgery. Kaouk and Gill et al. performed the initial experimental study of laparoscopic orthotopic neobladder in 12 pigs in 2001. They created an ileal neobladder with Studer limb extension, and the entire procedure was performed intracorporeally in all cases. Each of the anastomosis was created with freehand suturing techniques, and none strictured as assessed by both radiographic and postmortem study. Mean operative time was 5.4 hours, with minimal blood loss. Late complications included one port site abscess, and two cases of *Escherichia coli* pyelonephritis causing azotemia in two animals, one of which died at three months.

Gill et al. published the initial two cases of completely intracorporeal laparoscopic radical cystectomy and orthotopic Studer pouch in a 42-year-old woman and 57-year-old man, respectively.

A five-port transperitoneal technique was employed for the cystectomy portion, and a sixth low midline port was added to complete the urinary diversion. Operative times were 8.5 (solitary kidney) and 10.5 hours, respectively, with blood loss from 200 to 400 mL. Specimen retrieval was performed through an extended umbilical port site incision in both cases. Oncologic specimens had pathologically negative margins, and both patients achieved complete daytime continence.

The only other published case of complete intracorporeal orthotopic neobladder following laparoscopic radical cystectomy is from Beecken and colleagues, who performed the procedure with robotic assistance. In this 58-year-old man, a Hautmann ileal neobladder was created, and the entire procedure lasted 8.5 hours. The patient had good oncologic and functional outcomes at five months follow-up.

The remainder of the literature consists of open-assisted approaches to the orthotopic neobladder. Preceded by cadaveric studies, Gaboardi et al. performed a laparoscopic radical cystectomy, pelvic lymphadenectomy, and ileal orthotopic neobladder (U-configuration), in a 72-year-old man for BCG refractory T₁G₃ transitional cell carcinoma. After the cystectomy, specimen was extracted through a 5-cm supraumbilical incision, the ileal segment was isolated extracorporeally, and the neobladder was partially fashioned. They proceeded to perform the ureteroileal and urethroileal anastomoses laparoscopically. Operative time was less than the pure laparoscopic technique previously described, at 7.5 hours. Blood loss was 350 mL and the patient was discharged on postoperative day 7.

Gaboardi et al. made several important observations about combining the advantages of minimally invasive laparoscopy with open surgery, not just with respect to time saved, the ease of bowel transillumination with exteriorization of the ileal segment, and the avoidance of peritoneal soilage during bowel detubularization. Although larger series will be required, the small laparotomy did not seem to negate the advantages of the laparoscopic portion of the procedure.

A report by Abdel-Hakim et al. expanded published experience with a larger series of nine patients who underwent open-assisted laparoscopic orthotopic neobladder following radical cystectomy. Their ileal configuration was a Y-pouch (modified Camey II). The first three patients underwent open ileal exclusion and ileoileal anastomosis via an infraumbilical midline incision. The urethral and ureteral anastomoses were also performed through this incision. As operative times for the cystectomy portion shortened, the extracorporeally prepared Y-pouch was reintroduced for the following six patients, pneumoperitoneum re-established, and the anastomoses were completed laparoscopically. Mean operative time was 8.3 hours. In these patients, a right-sided 12-mm port extension was instead chosen for specimen extraction and neobladder creation.

Similar conclusions have been made regarding the advantages of employing a mini-laparotomy for the reconstruction of the urinary diversion when the primary intracorporeal surgery is robot-assisted.

Menon and colleagues reported 17 patients (14 men, 3 women) who underwent robot-assisted radical cystectomy, with urinary diversion performed through a mini-laparotomy incision. All but three (ileal conduit) had orthotopic neobladders including the W-pouch, double chimney, and T-pouch.

Menon and colleagues reported 17 patients (14 men, 3 women) who underwent robot-assisted radical cystectomy, with urinary diversion performed through a mini-laparotomy incision. All but three (ileal conduit) had orthotopic neobladders including the W-pouch, double chimney, and T-pouch.

Average operative time for the orthotopic neobladder portion of the procedure was 2.8 hours. The same group later reported robotic radical cystectomy in three more women, two of whom had orthotopic neobladders (W-pouch, T-pouch). The urinary diversion in these two took 190 and 170 minutes. In all 19 cases, isolation of the ileal segment, restoration of bowel continuity, detubularization, and pouch configuration was performed extracorporeally through a limited suprapubic incision.

Finally, as a reminder of the innovative combinations possible amongst techniques, Guazzoni et al. performed an open-assisted orthotopic W-shaped neobladder in three patients. Following laparoscopic cystectomy, bowel exclusion, restoration of bowel continuity, pouch construction, and ureteroileal anastomoses were performed open through a 7-cm periumbilical incision. For the remainder of the procedure, including urethrovaginal anastomosis, this incision was converted to a hand port. Mean operative time was 7.4 hours.

Although the choice of a particular neobladder configuration assumes less importance for an open-assistance technique, the particular choice of ileal pouch assumes greater importance when the reconstruction occurs purely laparoscopically. The Studer neobladder is a practical choice in this regard. This remains an assumption, as Gill et al. and Beecken have reported the only cases of purely laparoscopic orthotopic neobladder (Studer pouch and Hautmann neobladder, respectively).

LAP-ASSISTED ORTHOTOPIC ILEAL NEOBLADDER

At the authors' institution, laparoscopic radical cystoprostatectomy proceeds laparoscopically, while the ileal neobladder is created through a mini laparotomy. Others perform a totally intracorporeal laparoscopic neobladder. This technique is also described.

Patient Preparation

Informed consent is obtained with a discussion of risks including but not limited to adjacent organ injury and unrecognized bowel injury. Patients are made aware that safety is paramount, and open conversion may be required for completion of the planned procedure. Patients undergo a full mechanical bowel preparation with oral antibiotics covering normal intestinal flora on the day prior to surgery. Preoperative antibiotic prophylaxis with an intravenous second-generation cephalosporin is given at induction of anesthesia and continues for the first postoperative day. Lower extremity compressive devices are applied. Once general anesthesia is induced, the gastric contents are emptied with a nasogastric tube, which remains in place postoperatively.

Radical Cystectomy

Radical cystectomy proceeds as described elsewhere. Several specific points deserve attention:

1. *Laparoscopic access:* Pneumoperitoneum is obtained through a standard Veress technique. A primary 10-mm trocar is placed at the umbilicus. An additional four trocars are placed in a fan-shaped distribution. Two 10-mm trocars are placed at the lateral pararectal line 10 cm above the pubic symphysis, and two 5-mm trocars 2–3 cm medial and superior to the anterior-superior iliac spines.
2. *Ureteral dissection:* Ureters are clipped and transected close to their insertion into the bladder. This greatly facilitates subsequent identification and atraumatic laparoscopic manipulation.
3. Two different colored 4-0 Vicryl holding sutures are placed at the distal ends of the ureters.
4. *Vascular pedicle control:* The vascular pedicles of the bladder and prostate are controlled with serial applications of an Endo-GIA laparoscopic stapler.
5. *Specimen retrieval:* Once the bladder is fully excised, it is placed into a laparoscopic retrieval bag. Once the abdomen is incised for creation of neobladder, the specimen can then be removed.

Two different colored 4-0 Vicryl holding sutures are placed at the distal ends of the ureters.

Transposition of Left Ureter

The ureters are dissected proximally for a length sufficient to reach the proximal end of the ileal segment. Care is taken to preserve periureteral tissue and thus the ureteral

vascular supply. The sigmoid colon is retracted superiorly and anteriorly. Blunt dissection is used to develop a tunnel posterior to the sigmoid mesocolon and anterior to the sacrum. The left ureter is passed under the sigmoid colon using the previously placed holding suture. Ureteral length is once again confirmed to assure that both ureters reach the proximal portion of the ileal segment in order to avoid undue tension on the anastomoses.

Harvesting Small Bowel

When a right-sided trocar site coincides with the desired stoma site, the trocar site is extended 4.5 cm. The specimen is retrieved. The color-coded ureteral holding sutures are identified. A 65-cm segment of ileum is selected with care to spare the 15–20 cm proximal to the ileocecal junction. The mid-portion of the segment should reach the urethral stump without undue tension or mesenteric kinking. The segment of bowel is delivered through the incision and isolated with a GIA stapler by transecting proximally and distally. The mesentery is divided below with care to preserve the major mesenteric vasculature. The isolated segment is dropped posteriorly.

Restoring Bowel Continuity

The stapled edges of the distal and proximal ileum are removed sharply. Applications of a GIA 55 mm are used to create a side-to-side, functional end-to-end anastomosis along the antimesenteric border of the small bowel. The open end of the anastomosis is then closed using a TA 55-mm stapler. The end staple line is imbricated with interrupted, absorbable suture. The window through the mesentery is then closed with interrupted absorbable suture to prevent internal hernia formation.

Creation of Neobladder

This portion of the procedure continues extracorporeally. The staple lines are removed and the lumen of the bowel is cleansed using a suction-irrigation device. Care is taken to preserve the proximal 10 cm as a Studer limb. The remainder of the segment is incised along its antimesenteric side using monopolar electrocautery. The posterior plate of the neobladder is created by suturing the medial edges of the detubularized bowel in a running fashion with 2-0 polyglactin such that the bowel forms a “J” configuration.

The anterior plate of the neobladder is closed using another running 2-0 polyglactin suture. The anterior enterotomy is left open for approximately 3 cm at its inferior most portion in order to create the urethrovaginal anastomosis.

The neobladder is reintroduced into the abdominal cavity. The lower midline incision is closed using a 0- polyglactin suture, pneumoperitoneum is re-established, and the camera is replaced. The urethrovaginal anastomosis is performed intracorporeally.

Urethrovaginal Anastomosis

The most dependent portion of the detubularized ileum is identified and brought down to the urethral stump. The mesentery is confirmed to be without kinks or undue tension. If additional length is needed, the mesenteric division can be carefully extended.

The anastomosis is started at the 6 o'clock position with two running 2-0 poliglecaprone sutures in a parachute fashion and extended to the 12 o'clock position on either side. The sutures are then tied to each other. Once the anastomosis is finished, a 22-French Foley catheter is placed.

Ureteroneovaginal Anastomoses

The following two options are available: (i) Reopen the infraumbilical incision, deliver the Studer limb extracorporeally, and perform the anastomosis in an open fashion. (ii) Particularly in obese patients, bilateral anastomoses are performed completely intracorporeally (see later).

In the former case, gentle traction on the ureteral holding sutures pulls the distal ureters into the operative field. The ureters are spatulated for approximately 1 cm. Bilateral ureteral 6-French single “J” stents are passed into the renal pelvis. The stents are exteriorized through the wall of the neobladder and then through one of the lateral 5 mm port sites. The ureters are sequentially implanted into the proximal portion of the ileal segment in a standard Bricker fashion. The apices are fixed to the bowel using three interrupted 4-0 poliglecaprone sutures. The remainder of the ureteral implantation is performed using a running 4-0 poliglecaprone suture. The Studer limb is replaced into the abdominal cavity. The ureteral stents are drawn through separate ileotomies in the neobladder wall and are exteriorized through the lateral 5-mm port sites.

The following two options are available: (i) Reopen the infraumbilical incision, deliver the Studer limb extracorporeally, and perform the anastomosis in an open fashion. (ii) Particularly in obese patients, bilateral anastomoses are performed completely intracorporeally.

Closure and Drains

The ureters and neobladder are inspected in situ. Once meticulous hemostasis is assured, a flat Jackson-Pratt drain is placed through a lateral 5-mm trocar site into the small pelvis. The port sites are closed in the usual fashion with fascial closure for all sites 10 mm and greater under direct vision with 0-polyglactin.

Postoperative Period

Postoperative management is as with the comparable open procedure. Patients receive prophylaxis for deep venous thrombosis and ambulation is begun on the first postoperative day. The nasogastric tube is removed once bowel function returns, and the diet is advanced accordingly. The drain is removed once output diminishes. The stents are removed between postoperative days 10 and 12. The Foley catheter is removed one day after stent removal.

PURE LAPAROSCOPIC ORTHOTOPIC ILEAL NEOBLADDER

Preoperative preparation and laparoscopic radical cystectomy are performed as previously described. The left ureter is transposed to the right side posterior to the sigmoid colon.

Harvesting Small Bowel

A 65-cm segment of ileum is selected with care to spare the distal 15–20 cm proximal to the ileocecal junction. The mid portion of the segment should reach the urethral stump without undue tension or mesenteric kinking. The ileum is isolated with an endoscopic GIA stapler by transecting proximally and distally. The mesentery is divided below these areas with care to preserve the major mesenteric vasculature. Endoscopic staplers, the harmonic scalpel, or serial application of laparoscopic clips can be used to transect the mesentery with complete hemostasis. The isolated segment is dropped posteriorly.

Restoring Bowel Continuity

The stapled edges of the distal and proximal ileum are removed sharply. Applications of an endoscopic GIA stapler are used to create a side-to-side, functional end-to-end anastomosis along the antimesenteric border of the small bowel. The open end of the anastomosis is then closed using an endoscopic TA stapler. The end staple line is imbricated intracorporeally with interrupted, absorbable suture. The mesenteric window through the mesentery is closed with interrupted absorbable suture to prevent internal hernia formation.

Creation of Neobladder

The staple lines are removed and the lumen of the bowel is cleansed using a suction—irrigation device. Care is taken to preserve the proximal 10 cm as a Studer limb. The remaining 55 cm is incised along its antimesenteric side using monopolar electrocautery, endoshears, and/or harmonic scalpel. The posterior plate of the neobladder is created by suturing the medial edges of the detubularized bowel in a running fashion with 2-0 polyglactin such that the bowel forms a “J” configuration (Fig. 3A).

Urethronovesical Anastomoses

The anterior plate of the neobladder is partially closed using another running 2-0 polyglactin suture. Before completion of the anterior wall, both ileoureteral stents are delivered into the Studer limb and retrieved into the peritoneal cavity through two separate ileotomy incisions at the proposed site of ureteroneovesical anastomoses. The anterior enterotomy is left open at its inferior-most portion in order to create the urethronovesical anastomosis.

The most dependent portion of the ileal plate is delivered to the urethral stump. The anastomosis is started at the 6 o'clock position with two running 2-0 poliglecaprone sutures in a parachute fashion and extended to the 12 o'clock position on either side. The sutures are then tied to each other. Once the anastomosis is finished, a 22-French Foley catheter is placed (Fig. 3B).

Ureteroneovesical Anastomoses

Gentle traction on the ureteral holding sutures pulls the distal ureters into the operative field. The ureters are spatulated for approximately 1 cm. Bilateral ureteral 6-French single “J” stents are passed into the renal pelvis. The stents are exteriorized through the wall of the neobladder and then through one of the lateral 5-mm port sites. The ureters are sequentially implanted into the proximal portion of the ileal segment in a standard Bricker fashion. The apices are fixed to the bowel using three interrupted 4-0 poliglecaprone

FIGURE 3 ■ (A) Completed posterior neobladder plate and suturing of urethro-neovesical anastomosis. (B) Anterior suture line and completed neobladder with drains.

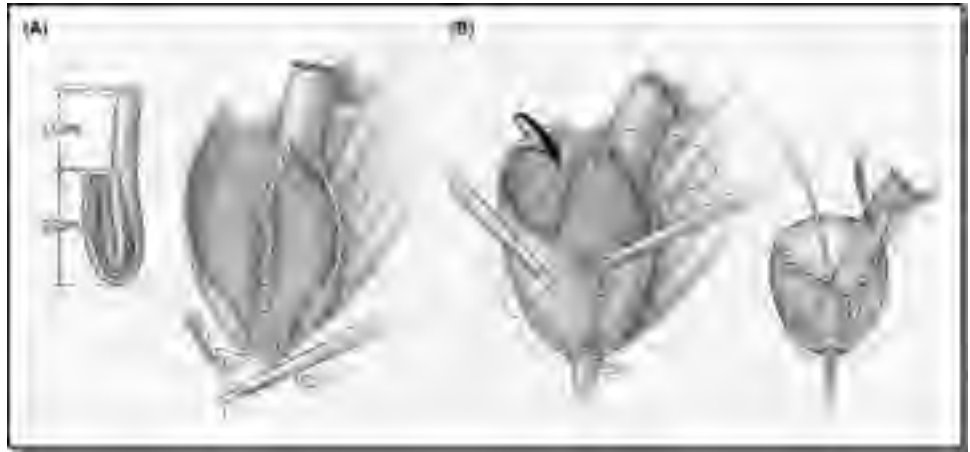



FIGURE 4 ■ Completed neobladder in the pelvis.



sutures. The remainder of the ureteral implantation is performed using a running 4-0 poliglecaprone suture (Figs. 3B and 4).

Closure and Drains

The ureters and ileal neobladder are inspected in situ for any undue tension. Once meticulous hemostasis is assured, a flat Jackson-Pratt drain is placed through a lateral 5-mm trocar site into the small pelvis. The port sites are closed in the usual fashion with fascial closure for all sites 10 mm and greater under direct vision with 0-polyglactin.

Postoperative Period

Postoperative management is as with the comparable open procedure. Patients receive prophylaxis for deep venous thrombosis and ambulation is begun on the first postoperative day. The nasogastric tube is removed once bowel function returns, and the diet is advanced accordingly. The drain is removed once output diminishes. The stents are removed between postoperative days 10 and 12. The Foley catheter is removed one day following stent removal.

Rectosigmoid Pouch

The rectosigmoid pouch (Mainz Pouch II), first described by Fisch et al. in 1993, is distinct from the largely abandoned ureterosigmoidostomy. Serious hyperchloremic metabolic acidosis, recurrent pyelonephritis, renal calculi, and the development of secondary malignancies at the anastomosis were responsible for aversion to the classic ureterosigmoidostomy. For the Mainz II pouch, the bowel is left in continuity, the colon is detubularized along its antimesenteric border proximal and distal to the rectosigmoid junction, and a pouch is created using a side-to-side anastomosis. The pouch is fixed to the sacral promontory, and a competent anal sphincter provides the continence mechanism. Fisch demonstrated in a series of 47 patients that a low-pressure system is achieved, and all but one patient was continent day and night.

This option is particularly well suited for patients with contraindications to urethral anastomosis, precluding safe creation of an orthotopic neobladder.

The Mainz II pouch is a well-accepted alternative in women in Europe, the Middle East, and North Africa. Contraindications to the rectosigmoid pouch include: (i) incompetent anal sphincter, (ii) distal colonic disease (polyps, diverticuli), (iii) prior radiation, and (iv) planned radiation.

In 2000, Tuerk et al. were the first to report laparoscopic radical cystectomy with rectosigmoid pouch entirely intracorporeally in five patients.

The Mainz II pouch is a well-accepted alternative in women in Europe, the Middle East, and North Africa. Contraindications to the rectosigmoid pouch include: (i) incompetent anal sphincter, (ii) distal colonic disease (polyps, diverticuli), (iii) prior radiation, and (iv) planned radiation.

In a porcine model, Trinchieri et al. described the first experimental laparoscopic construction of a ureterosigmoidostomy. An antirefluxing ureteroileal anastomosis was created along the taenia coli. In 1995, Anderson and colleagues performed laparoscopic rectosigmoid pouch continent urinary diversion in 10 pigs. In this series, pouch creation and bilateral ureteral anastomoses were performed extracorporeally. Mean operative time was 122 minutes, and the pouches performed well (maximal pressure <20 cmH₂O, capacity 360 cm³). They had disappointing results, however, with regard to calculi formation on exposed titanium staple line, as well as ureteroenteric anastomotic strictures. In order to test ureteral anastomotic techniques, the authors performed different techniques on each side. The right ureteral anastomosis used an antirefluxing “dunk” technique where 1 cm of distal ureter is passed through an enterotomy and the ureteral adventitia is tacked to the bowel serosa externally. Postoperatively, 11% of these became obstructed. The left ureter was anastomosed in a simple end to side fashion, and 33% of these stenosed. No stents were used in either case.

Denewer et al. employed the same technique in a clinical series of 10 patients. After completing the cystectomy, an 8 cm infraumbilical mini-laparotomy was used to perform a side-to-side sigmoid pouch (stapling technique) with an intussuscepted antireflux valve. Mean operative time was 160 minutes for the laparoscopic portion and 55 minutes for the continent pouch. The staple line was not assessed postoperatively for stone formation.

In 2000, Tuerk et al. were the first to report laparoscopic radical cystectomy with rectosigmoid pouch entirely intracorporeally in five patients. Mean operative time was 7.4 hours, with average blood loss of 245 mL. All patients were discharged postoperatively by day 10, and all reported complete daytime and night time continence. The pouch was constructed using absorbable suture in lieu of stapling to avoid the risk of staple line stone formation. The distinct advantage of this technique over open-assisted counterparts is transanal specimen retrieval following bowel detubularization, or via the opened vagina in women, avoiding an abdominal incision. Furthermore, the sigmoid and rectum have posterior attachments that keep them still and facilitate laparoscopic suturing. The length of suture lines is also significantly less than for an ileal neobladder.

Concerns over carcinogenesis warrant specific attention in this context. Atta described the preliminary results in 15 patients with a detubularized ureterosigmoidostomy and demonstrated that patients passed urine and feces separately. Although the reservoir described by Atta differs slightly from the Mainz II, in that the detubularization extends to the rectal ampulla and the left colon orifice is fixed in continuity with the posterior wall of the rectal ampulla. However, our clinical experience has shown that many patients with the Mainz II pouch report separate passage of urine and feces as well. The risk of interval development of adenocarcinoma, therefore, is theoretically lower. Surveillance pouchoscopy should still be employed until more data are available.

LAPAROSCOPIC MAINZ II POUCH (SIGMA-RECTUM POUCH)

Patient Preparation

Prior to creation of a rectosigmoid pouch, anal continence should be assured. The sphincteric mechanism is tested by instilling 250 mL of fluid into the rectum. The patient must hold this for 2 to 3 hours. Preoperative sigmoidoscopy is performed to exclude colonic disease including polyposis and diverticulosis. Informed consent is obtained with a discussion of risks including but not limited to adjacent organ injury and unrecognized bowel injury. Patients are made aware that safety is paramount, and open conversion may be required for completion of the planned procedure. Patients undergo a full mechanical bowel preparation and oral antibiotics covering normal intestinal flora are given on the day prior to surgery. Preoperative antibiotic prophylaxis with an intravenous second-generation cephalosporin is given at induction of anesthesia and continues for the first postoperative day. Lower extremity compressive devices are applied. Once general anesthesia is induced, the gastric contents are emptied with a nasogastric tube, which remains in place postoperatively. The legs are gently abducted and a 26-French rectal tube is placed.

Radical Cystectomy

Radical cystectomy proceeds as described elsewhere. Several specific points deserve attention:

1. *Laparoscopic access:* Pneumoperitoneum is obtained through a standard Veress technique. A primary 10-mm trocar is placed at the umbilicus. An additional four trocars are placed in a fan-shaped distribution. Two 10-mm trocars are placed at the lateral pararectal line 10 cm above the pubic symphysis, and two 5-mm trocars 2–3 cm medial and superior to the anterior-superior iliac spines.
2. *Ureteral dissection:* Ureters are clipped and transected close to their insertion into the bladder. This greatly facilitates subsequent identification and atraumatic laparoscopic manipulation.
3. *Vascular pedicle control:* The vascular pedicles of the bladder and prostate are controlled with serial applications of an Endo-GIA laparoscopic stapler.
4. *Specimen retrieval:* Once the bladder is fully excised, it is placed into a laparoscopic retrieval bag. Once the colon is incised for creation of rectosigmoid pouch, the specimen can then be removed through the anus.

Creation of Sigmoid Pouch

The lateral attachments of the sigmoid colon are dissected free to allow for limited manipulation. The amount of dissection required for the cystectomy portion of the procedure usually allows enough mobility. The sigmoid colon is then incised along its antimesenteric borders using a monopolar hook electrocautery. Individual anatomic variations determine the distal extent of the detubularizing incision. Care is taken to insure that the length of distal incision will correspond to the proximal incision once the pouch is created. The specimen bag is now removed transanally. The posterior walls of the sigmoid colon are anastomosed intracorporeally using a running 3-0 polyglyconate suture. This forms the posterior plate of the pouch.

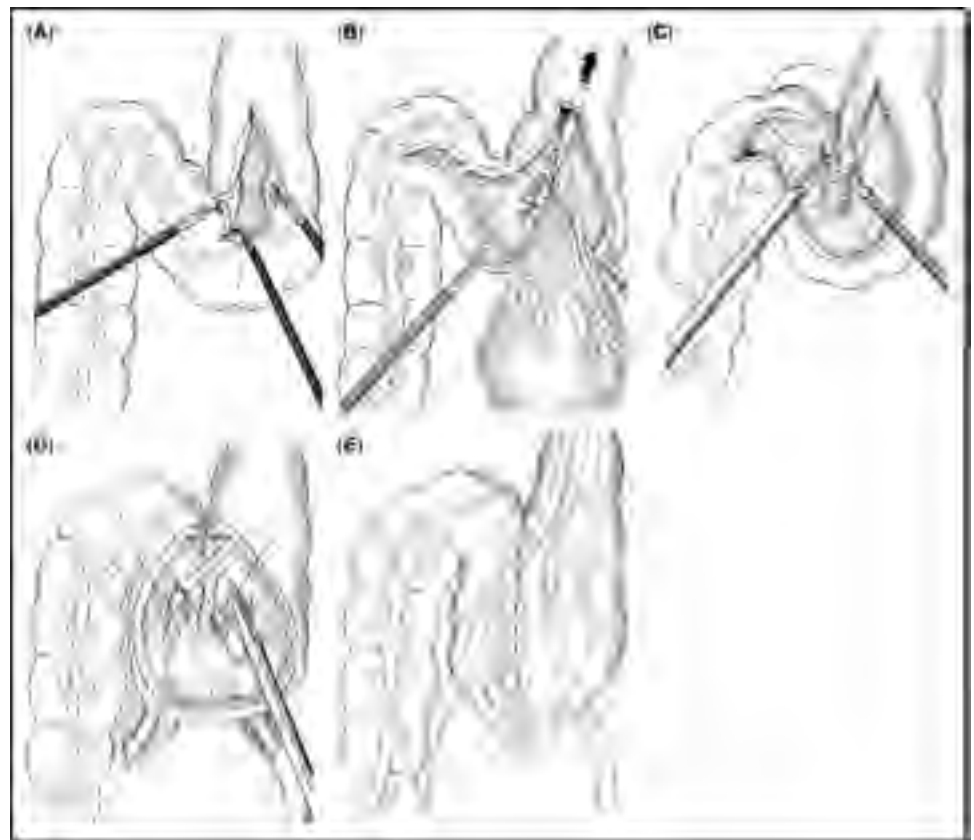
Native sigmoid fixation facilitates intracorporeal suturing (Fig. 5).

Native sigmoid fixation facilitates intracorporeal suturing.

Ureteral Reimplantation

The ureters are carefully spatulated along their anterior surface for 1 cm. Two incisions are made through the posterior wall of the sigmoid to accommodate the left and right

FIGURE 5 ■ (A) Antimesenteric incision starting at rectosigmoid junction. (B) Transanal specimen retrieval in endoscopy bag. (C) Side-to-side anastomosis of posterior wall of pouch. (D) Submucosal ureteral implantation. (E) Completed ureterosigmoid diversion.



ureters. The incisions are made such that each ureter has approximately 3 cm of length in the pouch for the creation of submucosal tunnels. The submucosal tunnels are created sharply in a superior to inferior fashion. The ureters are pulled through the neo-orifices and secured with a single 4-0 polyglecaprone suture. Eight French monopigtail stents are placed into each ureter and externalized through the anus. The distal margins of each ureter are anastomosed to the sigmoid mucosa using a combination of interrupted and running 4-0 polyglyconate suture. The sigmoid mucosa is then closed over the distal segments of the ureters using running 4-0 polyglyconate suture.

Closure and Drains

The anterior edges of the sigmoid pouch are anastomosed using a running 3-0 polyglyconate suture. The 26 French rectal tube is used to instill 250 mL of sterile normal saline to check for any large leak from the pouch. Figure-of-eight interrupted 3-0 polyglyconate sutures reinforce any areas of leak. Once hemostasis is assured, a single Jackson-Pratt drain is placed into the pelvis through one of the lateral 5-mm trocar sites. Hemostasis is verified, and trocars are removed under direct vision. The port site incisions are closed in the normal fashion with deep fascial sutures for all port sites greater than or equal to 10 mm diameter.

Postoperative Period

Patients receive prophylaxis for deep venous thrombosis, and early ambulation is encouraged. The nasogastric tube is removed once bowel function returns, and diet is then advanced. The Jackson-Pratt drain is removed once output remains minimal. The ureteral stents are removed on postoperative day 8 and the rectal tube is removed on postoperative day 9.

Continent Catheterizable Stomal Reservoirs

When continent catheterizable stomal reservoirs is desired, preoperative preparation and patient selection parallels that of their open counterparts. First and foremost, patients must be motivated and intact cognitively and physically, without restrictions imposed by neurologic injury or neurodegenerative disorders that would impair coordination necessary for clean intermittent catheterization.

Mitrofanoff Urinary Stoma

Many of the reports of appendicovesicostomy urinary diversion are found in the pediatric population, and are comprised largely of lap-assisted procedures affording initial appendiceal and cecal mobilization, followed by lower abdominal incisions for urinary reconstruction. Jordan and Winslow, who performed the procedure in a 15-year-old girl with bilateral ectopic ureterocele and an obliterated bladder neck, described laparoscopic appendicovesicostomy in 1993. Open assistance was required to fashion the appendiconeocystostomy. Van Savage and Slaughenhaupt later described a similar lap-assisted approach to appendicovesicostomy in three obese women, with laparoscopic mobilization of the appendix and right colon, and a Pfannensteil incision for construction of the urinary diversion. Hedican et al. described the use of laparoscopy in eight patients (mean age, 13.4 years) requiring either an ileal or appendiceal Mitrofanoff, with or without an antegrade continent enema in eight patients with neurogenic bladder and bowel. A lower abdominal incision was used for part of the reconstructive procedure. Cadeddu and Docimo reported a similar series of 11 pediatric patients with neurogenic bladder and bowel in 1999, where laparoscopic-assisted approach was again utilized. A continent urinary diversion was created in seven of these patients through a Pfannenstiell or low midline incision, including appendiceal, tapered ileal, or sigmoid Mitrofanoff urinary stoma positioned at the umbilicus.

The first two completely intracorporeal case reports of laparoscopic appendicovesicostomy were reported almost simultaneously. In April 2004, Pedraza et al. reported their success with the DaVinci robotic system, with a four-port transperitoneal approach. Although total operative time was six hours, the anastomosis took 25 minutes. The patient was discharged on postoperative day 4. One month later, Casale and colleagues reported the feasibility of pure laparoscopic appendicovesicostomy. The case involved a four-year old girl with the VATER malformation and associated neurogenic bladder. A four-port transperitoneal approach was also used; total operative time was 198 minutes, and the patient was discharged home on the third postoperative day.

Other Procedures

Pomel and Castaigne recently reported laparoscopic hand-assisted Miami pouch in a 45-year-old woman following anterior pelvic exenteration. The initial cervical cancer invaded into the bladder. The patient underwent combined chemotherapy and radiation, resulting in total incontinence secondary to a vesicovaginal fistula, with residual local disease. A five-port transperitoneal approach was used, and following anterior pelvic exenteration the right colon, terminal ileum, and cecum were mobilized laparoscopically. The Miami pouch was created through a 4-cm mini laparotomy incision. The ileal conduit portion was sutured to the umbilicus. Total operative time was six hours.

Gill and coworkers reported a laparoscopic radical cystectomy and Indiana pouch urinary diversion with a continent, catheterizable stoma. Orthotopic neobladder was not advised due to prostatic urethral tumor involvement. The pouch was created extracorporeally by exteriorizing the ileocecal segment through a 2–3 cm extension of a right pararectus port incision. In contrast to open-assisted techniques for ileal conduit urinary diversions in which the ureters are commonly delivered through the incision with the bowel segment to perform the anastomosis, the pouch was reintroduced into the abdomen and subsequent ureteroileal anastomoses were performed intracorporeally. The continent stoma was created at the umbilicus. Total operative time was seven hours with 300 mL blood, and the patient was discharged after six days.

There is little doubt, considering the technical feasibility of a wide range of techniques that have been demonstrated, that the laparoscopic or open-assisted approach will be extended to the many variations of cutaneous continent urinary diversions not mentioned herein.

There is little doubt, considering the technical feasibility of a wide range of techniques that have been demonstrated, that the laparoscopic or open-assisted approach will be extended to the many variations of cutaneous continent urinary diversions not mentioned herein.

FUTURE DIRECTIONS

Considerable progress has taken place in the short time since Parra's simple cystectomy in 1992 to the complex reconstructive laparoscopy of today. Advances in this arena are a true testimony to the logical and elegant progression from the porcine and cadaveric technical models to the initial clinical cases. Small series of laparoscopic urinary diversion have shown acceptable functional outcomes, which need to be substantiated by larger published series with long-term follow-up. We are no longer exploring the feasibility of these complex laparoscopic procedures, but rather refining the techniques in order to decrease operative time.

The debate between pure laparoscopy and open assistance continues. Those groups who have demonstrated the feasibility of pure laparoscopic techniques have truly pushed the frontiers further than previously imagined. As is often the case, giant leaps hasten the acceptance of small strides. Even if these "laparoscopic-only" approaches do not become common practice, these innovative groups have made the broader community receptive to laparoscopic-assisted approaches, which have become increasingly widespread.

Considering the innovation we have recently witnessed, it is easy to envision that in the near future, laparoscopic reconstructive techniques will catch up to open surgery. Will we then avert the entire debate? In the near future, further experience with free-hand suturing and refined intracorporeal anastomotic and reconstructive suturing technology will allow complex reconstructions to be performed as quickly as with open surgery. Then the choice between open assistance and pure laparoscopy will become one of surgeon preference rather than an issue of technical complexity and decreased operative time. Existing reviews of this topic have recognized that continued refinement of laparoscopic dissolvable staples is one example of a device that would bring us a step further in that direction. Furthermore, robotic surgery has already enhanced the surgeon's performance by simplifying complex maneuvers. Robotic technology therefore holds great promise and potential to effortlessly facilitate the dexterity and flexibility of open surgery. This field will continue to narrow the time gap between open and laparoscopic surgery.

Currently, this technical debate exists within the walls of specialized academic centers. It is clear that the next challenge will be to extend experience into the broader urologic community. In the near future, open-assisted laparoscopic urinary diversion is likely to be the technique of choice to facilitate this transition.

The debate between pure laparoscopy and open assistance continues.

SUMMARY

- The benefits of laparoscopic surgery are well recognized, but few have been subjected to rigorous scientific analysis.
- The theoretical benefits to patients of decreased insensible losses and subsequent early postoperative fluid shifts and fewer instances of ileus as a consequence of less direct bowel manipulation with the laparoscopic approach await scientific substantiation.
- Small clinical series have shown comparable functional and oncologic outcomes for radical cystectomy and urinary diversion between the open and laparoscopic approaches. We eagerly await the results of larger series with long-term follow-up.
- Feasibility of these complex laparoscopic procedures has already been established. Technical refinements are ongoing in order to decrease operative time and increase efficiency.
- The debate between pure laparoscopic and open-assisted procedures to perform urinary diversion continues.

REFERENCES

Reviews

1. Anderson KR, Clayman RV. Laparoscopic lower urinary tract reconstruction. *World J Urol* 2000; 18(5):349–354.
2. Fergany AF, Novick AC, Gill IS. Laparoscopic urinary diversion. *World J Urol* 2000; 18(5):345–348.
3. Kaouk JH, Gill IS. Laparoscopic reconstructive urology. *J Urol* 2003; 170(4 Pt 1):1070–1078.
4. Moinzadeh A, Gill IS. Laparoscopic radical cystectomy with urinary diversion. *Curr Opin Urol* 2004; 14(2):83–87.
5. Rimington P, Dasgupta P. Laparoscopic and robotic radical cystectomy. *BJU Int* 2004; 93(4):460–461.

Historical Interest

6. Parra RO, Andrus CH, Jones JP, Boullier JA. Laparoscopic cystectomy: initial report on a new treatment for the retained bladder. *J Urol* 1992; 148(4):1140–1144.

Ileovesicostomy

7. Abrahams HM, Rahman NU, Meng MV, Stoller ML. Pure laparoscopic ileovesicostomy. *J Urol* 2003; 170(2 Pt 1):517–518.
8. Hsu TH, Rackley RR, Abdelmalak JB, Tchertgen MB, Madjar S, Vasavada SP. Laparoscopic ileovesicostomy. *J Urol* 2002 Jul; 168(1):180–181.

Continent Catheterizable Reservoirs

9. Cadeddu JA, Docimo SG. Laparoscopic-assisted continent stoma procedures: our new standard. *Urology* 1999; 54(5):909–912.
10. Casale P, Feng WC, Grady RW, Joyner BD, Lee RS, Mitchell ME. Intracorporeal laparoscopic appendicovesicostomy: a case report of a novel approach. *J Urol* 2004; 171(5):1899.
11. Hedican SP, Schulam PG, Docimo SG. Laparoscopic assisted reconstructive surgery. *J Urol* 1999; 161(1):267–270.
12. Jordan GH, Winslow BH. Laparoscopically assisted continent catheterizable cutaneous appendicovesicostomy. *J Endourol* 1993; 7(6):517–520.
13. Monti PR, Lara RC, Dutra MA, de Carvalho JR. New techniques for construction of efferent conduits based on the Mitrofanoff principle. *Urology* 1997; 49(1):112–115.
14. Pedraza R, Weiser A, Franco I. Laparoscopic appendicovesicostomy (Mitrofanoff procedure) in a child using the da Vinci robotic system. *J Urol* 2004; 171(4):1652–1653.
15. Pomel C, Castaigne D. Laparoscopic hand-assisted Miami pouch following laparoscopic anterior pelvic exenteration. *Gynecol Oncol* 2004; 93(2):543–545.
16. Siqueria TM Jr., Paterson RF, Kuo RL, Kaefer M, Cheng L, Shalhav AL. Laparoscopic ileocystoplasty and continent ileovesicostomy in a porcine model. *J Endourol* 2003; 17(5):301–305.
17. Van Savage JG, Slaughenhaupt BL. Laparoscopic-assisted continent urinary diversion in obese patients. *J Endourol* 1999; 13(8):571–573.

Cutaneous Ureterostomy

18. Loisesides P, Grasso M, Lui P. Laparoscopic cutaneous ureterostomy: technique for palliative upper urinary tract drainage. *J Endourol* 1995; 9(4):315–317.
19. Puppo P, Ricciotti G, Bozzo W, Pezzica C, Geddo D, Perachino M. Videoendoscopic cutaneous ureterostomy for palliative urinary diversion in advanced pelvic cancer. *Eur Urol* 1995; 28(4):328–333.

Experimental Studies

20. Anderson KR, Fadden PT, Kerbl K, McDougall EM, Clayman RV. Laparoscopic assisted continent urinary diversion in the pig. *J Urol* 1995; 154(5):1934–1938.
21. Fergany AF, Gill IS, Kaouk JH, Meraney AM, Hafez KS, Sung GT. Laparoscopic intracorporeally constructed ileal conduit after porcine cystoprostatectomy. *J Urol* 2001; 166(1):285–288.
22. Kaouk JH, Gill IS, Desai MM, et al. Laparoscopic orthotopic ileal neobladder. *J Endourol* 2001; 15(2):131–142.
23. Sanchez de Badajoz E, del Rosal Samaniego JM, Gomez Gamez A, Burgos Rodriguez R, Vara Thorbeck C. Laparoscopic ileal conduit. *Arch Esp Urol* 1992; 45(8):761–764.

24. Trinchieri A, Zanetti G, Montanari E, et al. Experimental and clinical urinary diversion. *Ann Urol (Paris)* 1995; 29(2):113–116.

Ileal Conduit

25. Balaji KC, Yohannes P, McBride CL, Oleynikov D, Hemstreet GP III. Feasibility of robot-assisted totally intracorporeal laparoscopic ileal conduit urinary diversion: initial results of a single institutional pilot study. *Urology* 2004; 63(1):51–55.
26. Gill IS, Fergany A, Klein EA, et al. Laparoscopic radical cystoprostatectomy with ileal conduit performed completely intracorporeally: the initial 2 cases. *Urology* 2000; 56(1):26–29; discussion 29–30.
27. Hemal AK, Singh I, Kumar R. Laparoscopic radical cystectomy and ileal conduit reconstruction: preliminary experience. *J Endourol* 2003; 17(10):911–916.
28. Kozminski M, Partamian KO. Case report of laparoscopic ileal loop conduit. *J Endourol* 1992; 6:147–150.
29. Peterson AC, Lance RS, Ahuja S. Laparoscopic hand assisted radical cystectomy with ileal conduit urinary diversion. *J Urol* 2002; 168(5):2103–5; discussion 2105.
30. Potter SR, Charambura TC, Adams JB II, Kavoussi LR. Laparoscopic ileal conduit: five-year follow-up. *Urology* 2000; 56(1):22–25.
31. Puppo P, Perachino M, Ricciotti G, Bozzo W, Gallucci M, Carmignani G. Laparoscopically assisted transvaginal radical cystectomy. *Eur Urol* 1995; 27(1):80–84.
32. Sanchez de Badajoz E, Gallego Perales JL, Reche Rosado A, Gutierrez de la Cruz JM, Jimenez Garrido A. Laparoscopic cystectomy and ileal conduit: case report. *J Endourol* 1995; 9(1):59–62.
33. Sorcini A, Tuerk I. Laparoscopic radical cystectomy with ileal conduit urinary diversion. *Urol Oncol* 2004; 22(2):149–152.
34. Vara-Thorbeck C, Sanchez-de-Badajoz E. Laparoscopic ileal-loop conduit. *Surg Endosc* 1994; 8(2):114–115.

Rectosigmoid pouch

35. Atta MA. Detubularized isolated ureterosigmoidostomy: description of a new technique and preliminary results. *J Urol* 1996; 156(3):915–919.
36. Denewer A, Kotb S, Hussein O, El-Maadawy M. Laparoscopic assisted cystectomy and lymphadenectomy for bladder cancer: initial experience. *World J Surg* 1999; 23(6):608–611.
37. Fisch M, Wammack R, Steinbach F, Muller SC, Hohenfellner R. Sigma-rectum pouch (Mainz pouch II). *Urol Clin North Am* 1993; 20(3):561–569.
38. Turk I, Deger S, Winkelmann B, Schonberger B, Loening SA. Laparoscopic radical cystectomy with continent urinary diversion (rectal sigmoid pouch) performed completely intracorporeally: the initial 5 cases. *J Urol* 2001; 165(6 Pt 1):1863–1866.

Orthotopic Neobladder

39. Abdel-Hakim AM, Bassiouny F, Abdel Azim MS, et al. Laparoscopic radical cystectomy with orthotopic neobladder. *J Endourol* 2002; 16(6):377–381.
40. Beecken WD, Wolfram M, Engl T, et al. Robotic-assisted laparoscopic radical cystectomy and intra-abdominal formation of an orthotopic ileal neobladder. *Eur Urol* 2003; 44:337–339.
41. Gaboardi F, Simonato A, Galli S, Lissiani A, Gregori A, Bozzola A. Minimally invasive laparoscopic neobladder. *J Urol* 2002; 168(3):1080–1083.
42. Gill IS, Kaouk JH, Meraney AM, et al. Laparoscopic radical cystectomy and continent orthotopic ileal neobladder performed completely intracorporeally: the initial experience. *J Urol* 2002; 168(1):13–18.
43. Guazzoni G, Cestari A, Colombo R, et al. Laparoscopic nerve- and seminal-sparing cystectomy with orthotopic ileal neobladder: the first three cases. *Eur Urol* 2003; 44:567–572.
44. Menon M, Hemal AK, Tewari A, et al. Nerve-sparing robot-assisted radical cystoprostatectomy and urinary diversion. *BJU Int* 2003; 92(3):232–236.
45. Menon M, Hemal AK, Tewari A, et al. Robot-assisted radical cystectomy and urinary diversion in female patients: technique with preservation of the uterus and vagina. *J Am Coll Surg* 2004; 198(3):386–393.

COMMENTARY

John P. Stein

Department of Urology, Keck School of Medicine of the University of Southern California, Los Angeles, California, U.S.A.

This is a well-written, comprehensive chapter on laparoscopy and reconstructive urology as it applies to urinary diversion. As with any laparoscopic technique or application, the astute surgeon recognizes that the laparoscopic approach should mimic the open procedure regarding the basic principles and fundamentals of surgery. The authors maintain this surgical philosophy throughout the chapter. Several important concepts of this chapter regarding laparoscopic urinary diversion must be emphasized.

It appears that laparoscopic urinary diversion is a reasonable option for the “experienced laparoscopist.” With improvements in laparoscopic instrumentation

along with increased experience and skill level in intracorporal suturing, a greater number of surgeons will be able to perform laparoscopic forms of urinary diversion. However, it must be emphasized that lower urinary tract reconstruction can even be technically challenging open operations and must not be underestimated, particularly from a laparoscopic perspective. These procedures require an experienced and dedicated laparoscopic surgeon.

The authors appropriately state that a particular surgeon's confidence level with the urinary diversion technique (open or laparoscopic) should not dictate the decision process. Rather, the oncologic principles, patient selection, and patient preference should be the guiding factors. Proper informed consent for all forms of urinary diversion is mandatory. This consent process will collectively allow the patient and physician to make a well-informed decision regarding the form of urinary reconstruction that is best suited for that particular individual.

The ureteral dissection and manipulation is an important step in urinary diversion. The authors comment on atraumatically handling the ureter with holding sutures. This is critical, as the ureter should never be handled with pickups forceps, which could jeopardize the delicate blood supply. Although not specifically addressed in the chapter, the harvesting of the ureter is also an important component. Maintaining the lateral vascular supply emanating from the gonadal vessels is important to prevent ischemia to the distal ureter and will help reduce issues of ureterointestinal strictures. This is particularly important in patients who have received previous radiation therapy to the pelvis.

Regarding the ileal conduit, the authors emphasize on creating the stoma initially which anchors the ileal segment and facilitates intracorporal suturing of the ureterointestinal anastomosis. In addition, the authors state that the proximal and distal ends of the ileal conduit are transected with the GIA stapler. However, if there remain exposed staples to the urinary constituents, this may lead to the development of conduit stone formation in the future. It may be best to simply exclude the proximal staple line with an absorbable suture.

I read with great interest on the authors' technique regarding radical cystectomy and orthotopic diversion. Although not specifically mentioned, there is a growing body of data and sound evidence to suggest that a properly performed lymphadenectomy is an important component of the surgical procedure and the long-term outcomes of patients with high-grade, invasive bladder cancer. The consideration of a more extended lymphadenectomy particularly in high-risk patients with bladder cancer is important. Furthermore, from a technical perspective, when performing a radical cystectomy for bladder cancer, care should be taken to avoid spilling any bladder contents during the procedure, which could ultimately lead to tumor spill and possibly a local recurrence, which generally is a lethal event.

The authors provide the background and technical description of laparoscopy-assisted and pure laparoscopic orthotopic neobladder reconstruction. The authors appropriately comment that orthotopic diversion "sits on the cutting-edge of laparoscopic reconstructive surgery." The laparoscopy-assisted technique is facilitated with a minilaparotomy for neobladder construction. It is clear that pure laparoscopic orthotopic reconstruction is technically more challenging and requires an experienced laparoscopist to perform. It may be advisable that surgeons interested in orthotopic laparoscopic urinary diversion start with the laparoscopy-assisted approach prior to embarking on the pure laparoscopic procedures.

The indications and technique of the rectosigmoid urinary diversion are also well described by the authors in this chapter. This form of lower urinary tract reconstruction is more commonly performed in European countries where orthotopic diversion remains controversial in women. It is my belief, however, that in the properly selected female individuals, the orthotopic neobladder is the urinary diversion of choice and provides excellent functional results. It is emphasized that all patients requiring cystectomy should be properly informed of the various forms of lower urinary tract reconstruction.

The future application of laparoscopy and urinary diversion will continue to grow. I believe laparoscopic techniques must attempt to mimic the open techniques with regard to surgical and oncologic principles. With improvements in technique, equipment, and instrumentation, along with the evolution of robotic technology,

I believe this field will continue to grow. Furthermore, it is clear that a greater number of surgeons are performing laparoscopic surgery and, with more experience, some of the more difficult reconstructive procedures will be more commonly performed with this approach. I believe it will be the dedicated laparoscopist who intensely focuses in this surgical approach who will develop the laparoscopic experience and expertise to perform and improve upon the various forms of urinary diversion. The laparoscopic surgeon must have an understanding of the history and general principles of lower urinary tract reconstruction as well as the anatomical approach that is critical to ensuring the optimal clinical and oncologic outcomes in patients requiring urinary diversion. Incredible strides have been made in the field of laparoscopy over the past 15 years and it appears that these improvements will continue to evolve with time in their application to urinary diversion.

COMMENTARY

Urs E. Studer

Department of Urology, University of Bern,
Bern, Switzerland

This is an impressive overview on how fast literally every form of urinary diversion has been performed by dedicated laparoscopic surgeons. While complete intracorporeal construction of urinary diversions have been successfully performed, the procedure may be facilitated either by doing the diversion hand assisted through a minilaparotomy or by exteriorization of the bowel segment used for construction of the reservoir. The use of robotic surgery is another evolving technique that should make the procedures easier for the surgeon and thus shorten the operative time.

In the reports on the feasibility of various forms of laparoscopic urinary diversions, much emphasis is placed on the surgical time. When compared to open surgery, it is generally longer, even in the hands of experienced surgeons. This, however, must not necessarily be a disadvantage. This initial shortcoming was the basis of many forms of innovative research to shorten and facilitate laparoscopic surgery. These techniques will ultimately also facilitate and be used in open surgery. Besides introducing new instruments that had been developed for laparoscopic surgery in open surgery, the advantages of laparoscopic surgery, e.g., decreased tissue trauma, also stimulate the open surgeons to further refine their technique, which ultimately benefits the patient. The current status shows a rapidly evolving technique, with benefits for the patients undergoing laparoscopic urinary diversion, often hand assisted or with a minilaparotomy, not being overwhelming for the moment and being somewhat compensated by a prolonged anesthesia time. These momentary shortcomings, however, are the motor for further improvements, from which, very likely, not only laparoscopic surgery but also robotic surgery and even classical open surgery will further benefit.

The future will be bright, provided the following points are kept in mind:

- The authors' advice in the introduction—that the laparoscopic surgery must be governed by the laws of oncological surgery.
- The patient must receive the type of urinary diversion that fits his/her condition best and not one that is more easily feasible by laparoscopic surgery.
- Errors committed earlier with open surgery should not be repeated. Only spheroidal reservoirs have the best pressure characteristics and the optimal ratio between volume and the (reabsorbing) intestinal mucosa used for its construction. Funnel-shaped outlets for orthotopic bladder substitutes must be avoided to prevent kinking of the reservoir outlet. No antireflux mechanisms with a high probability of complications should be used. Ischemia

and exposure of mesenchymal tissue to urine must be avoided to prevent strictures.

- The use of laparoscopic techniques should not compromise the long-term results, e.g., by damaging neurovascular bundles or heat damage to sensitive tissues such as anastomotic areas by electrocautery. The best possible functional long-term result counts and not the hospital stay or the operative time.
- All new developments should focus only on possible long-term patient benefit. Techniques that demand a long learning curve for the surgeon, for which many patients would have to pay with (increased) long-term morbidity, would be unethical.
- The ultimate goal must be the development of techniques that can not only be performed by artists in the field, but that can also be used by the majority of surgically active urologists.
- Not everything that is new is necessarily better.

If these points are kept in mind, the future developments in endoscopic surgery will be rapid and convincing. Refinements of robotic surgery should allow some replacement of laparoscopic surgery. While the costs for laparoscopic or robotic surgery are actually of some concern, a drop in costs can be expected as soon as the techniques are widely used. As soon as further developments show the advantages of minimal invasive surgery as convincingly as it had been shown for replacing open (partial) nephrectomy with laparoscopic surgery, this will also become standard procedure for urinary diversion.

LAPAROSCOPIC SURGERY FOR BLADDER CANCER: CURRENT STATUS

Osamu Ukimura and Inderbir S. Gill

Section of Laparoscopic and Robotic Surgery, Glickman Urological Institute, Cleveland Clinic Foundation, Cleveland, Ohio, U.S.A.

■ INTRODUCTION	Laparoscopic-Assisted Laparoscopic Radical Cystectomy
■ HISTOLOGIC AND EXPERIMENTAL BACKGROUND	Robot-Assisted Laparoscopic Radical Cystectomy
■ CLINICAL SERIES	Hand-Assisted Laparoscopic Radical Cystectomy
Purely Laparoscopically Completed	Prostate-Sparing Laparoscopic Radical Cystectomy
Orthotopic Ileal Neobladder or Ileal Loop: Cleveland Clinic Experience	■ INTERNATIONAL REGISTRY AND FUTURE DIRECTION
Purely Laparoscopically Completed	■ SUMMARY
Continent Urinary Diversion: Charite Hospital Experience	■ REFERENCES

INTRODUCTION

Radical cystectomy is the established, standard treatment for patients with organ-confined, muscle-invasive, or recurrent high-grade bladder cancer. The optimal goals of the therapy for bladder cancer can include achieving excellent long-term oncologic outcomes as well as improved quality of life, coupled with the evolved urinary diversion.

The potential advantages of laparoscopic surgery are decreased blood loss, avoidance of certain laparotomy, less postoperative pain, less morbidity, early return to full activity, and better cosmesis. Following recent establishment of laparoscopic upper urinary tract and prostate surgery with a noteworthy decrease in patients' morbidity, a natural progression has been made to applying the laparoscopic technique to bladder surgery. Although the most challenging aspect of laparoscopic surgery for bladder carcinoma is reconstructive procedures, Gill et al. reported initial laparoscopic radical cystectomy with either ileal conduit or orthotopic urinary diversion (Studer pouch), with entire procedure being performed purely intracorporeally, in 2000 and 2001, respectively (1,2). Achieved decrease of blood loss in laparoscopic radical cystectomy (~300–400 cc) is considered to be due to clear visualization and delicate hemostatic handling of the bladder pedicles using linear stapling devices, with the tamponade effect afforded by the CO₂ pneumoperitoneum pressure.

Open radical cystectomy with urinary diversion provides accepted oncologic outcomes (Table 1) (3); however, it is a major demanding surgery for patients, involving long postoperative recovery. In the outcomes of the recent largest series in 1054 patients undergoing open radical cystectomy and urinary diversion of conduit ($n = 267$, 25%), ureterosigmoidostomy ($n = 17$, 2%), continent cutaneous ($n = 372$, 35%), or orthotopic ($n = 398$, 38%), with a median follow-up of 10.2 years, there were 27 (3%) perioperative deaths, with a total of 292 (28%) early complications (4). Distant recurrence was reported in 234 patients (22%) and local recurrence in 77 patients (7%). Overall recurrence-free survival at 5 and 10 years was 68% and 66%, respectively. Patients with fewer than five positive lymph nodes, undergoing their proposed extended pelvic iliac lymph node dissection approach, had significantly better survival rates than those with five or more lymph nodes involved ($p = 0.003$) (4).

The laparoscopic radical cystectomy with urinary diversion is a recently emerged surgery, requiring advanced laparoscopic training. As recent growing experiences were published from the major medical centers throughout the world, minimally invasive surgery for bladder carcinoma and urinary diversion reconstruction is gaining acceptance. During the initial part of the learning curve, laparoscopic radical cystectomy should be reserved for nonobese patients with organ-confined, nonbulky bladder cancer without preoperative radiographic and clinical findings of concomitant pelvic lymphadenopathy.

As recent growing experiences were published from the major medical centers throughout the world, minimally invasive surgery for bladder carcinoma and urinary diversion reconstruction is gaining acceptance. During the initial part of the learning curve, laparoscopic radical cystectomy should be reserved for nonobese patients with organ-confined, nonbulky bladder cancer without preoperative radiographic and clinical findings of concomitant pelvic lymphadenopathy.

TABLE 1 ■ Laparoscopic Radical Cystectomy and Lymphadenectomy: Oncologic Outcomes

Author (yr)	No. of patients	Technique (reconstruction)	Margins	Lymphadenectomy (n node, range)	Mean (range) months at stated follow-up	N Overall survival
Puppo (1995)	5	Lap (extra)	Not stated	Limited (not stated)	10.8 (6–18)	5
Denewer (1999)	10	Lap (extra)	Not stated	Limited (not stated)	Not stated	9
Turk (2001)	5	Lap (purely intra)	5/5 negative	Limited (not stated)	Not stated	5
Abdel-Hakim (2002)	9	Lap (extra)	9/9 negative	Limited (n = 2–4)	Not stated	9
Simonato (2003)	10	Lap (extra)	10/10 negative	Limited (not stated)	12.3 (5–18)	10
Menon (2003)	17	Robot (extra)	17/17 negative	Limited (n = 4–27)	(2–11)	17
Hemal (2004)	11	Lap (extra)	10/11 negative	Limited (not stated)	18.4 (1–48)	10
Basillotte (2004)	13	Lap (extra)	12/13 negative	Limited (not stated)	Not stated	13
Taylor (2004)	5	HAL (extra)	4/5 negative	Extended (not stated)	Not stated	5
Gill (2004)	22	Lap (purely intra)	21/22 negative	11/22 extended (n = 21, 6–30)	11 (2–43)	18
Cathelineau (2005)	84	Lap (extra)	All negative	Not stated	18 (1–44)	All (83% disease-free)

Source: From Ref. 3.

HISTOLOGIC AND EXPERIMENTAL BACKGROUND

In 1992, Parra et al. (5) documented the initial case report of laparoscopic simple cystectomy in female patient suffering from recurrent pyocystis of retained bladder in a 27-year-old paraplegic woman who had already undergone open surgical urinary diversion a few months earlier. The operative time was 130 minutes. The authors described postoperative hospital stay of five days, which was significantly less than that in five similar patients undergoing open cystectomy for vesical empyema in whom the mean hospital stay was 20.6 days. In 1992, Kozminski and Partamian (6) described the first case report of laparoscopically assisted ileal conduit construction, with the bowel anastomosis and both Bricker ureteroileal anastomosis performed extracorporeally through extended port sites. In 1995, Sanchez de Badajoz et al. (7) described the first case of laparoscopic-assisted radical cystectomy with an ileal conduit performed extracorporeally in a 64-year-old woman who had invasive bladder carcinoma. The authors discussed that recuperation was unusually fast and painless, and little postoperative analgesia was required. In 1999, Denewer et al. (8) conducted a series of 10 patients undergoing laparoscopic-assisted cystectomy with open surgical sigmoid pouch, including two patients subjected to primary treatment for bladder tumor, but seven patients to salvage options as well as one to a palliative option after unsuccessful courses of radiotherapy for bladder malignancy.

Although the above reports established laparoscopic feasibility of certain portions of laparoscopic cystectomy or urinary diversion, it was not until 2000 that entire laparoscopic radical cystectomy and completely intracorporeal ileal conduit urinary diversion was employed clinically in two male patients with bladder cancer, following a successful pilot study in 10 pigs by Cleveland Clinic. Similarly, in author's institution, the completely intracorporeal orthotopic ileal neobladder was initially developed successfully in animal study using 12 pigs (10), followed by clinical application of orthotopic urinary diversion in one man and in one woman, and an Indiana pouch in one man (2).

In 2000, Turk et al. described laparoscopic radical prostatectomy with Mainz II pouch entirely intracorporeally also in three men and two women with bladder cancer (11). These reports demonstrated that reconstruction of bowel could be performed with purely intracorporeal freehand suturing techniques.

CLINICAL SERIES

Purely Laparoscopically Completed Orthotopic Ileal Neobladder or Ileal Loop: Cleveland Clinic Experience

Gill et al. reported completely intracorporeal techniques in a manner duplicating open surgical principles can be performed for laparoscopic radical cystectomy with ileal conduit as well as with orthotopic continent urinary diversion (Studer pouch), in 2000 and 2002, respectively (1,2). Specifically, laparoscopic radical cystectomy respects established oncologic principles of wide margin resection in open radical cystectomy, and we have obtained negative margins in all but one of total 33 laparoscopic radical cystectomy performed to date. Mean estimated blood loss was 490 mL. There were no intraoperative complications

Although the above reports established laparoscopic feasibility of certain portions of laparoscopic cystectomy or urinary diversion, it was not until 2000 that entire laparoscopic radical cystectomy and completely intracorporeal ileal conduit urinary diversion was employed clinically in two male patients with bladder cancer, following a successful pilot study in 10 pigs by Cleveland Clinic. Similarly, in author's institution, the completely intracorporeal orthotopic ileal neobladder was initially developed successfully in animal study using 12 pigs, followed by clinical application of orthotopic urinary diversion in one man and in one woman, and an Indiana pouch in one man.

Oncologic outcomes of the initial 22 patients with mean follow-up of 11 months (range 2–43) were that 21 (95%) had negative margin, six (27%) had positive lymph nodes, three (14%) died of distant recurrence, and one local recurrence (4.5%) in case with pT4N2 with lung metastasis (alive, undergoing chemotherapy) was noted.

The median number ($n = 21$) of nodes retrieved in the author's series and anatomical boundaries of the surgical procedure (bilaterally skeletonizing the genitofemoral nerve, external iliac artery, external iliac vein, obturator nerve, hypogastric artery, common iliac artery, and pubic bone) were commensurate with those of current recommendation for open surgery. No patient developed port site or no local recurrence over the short follow-up of 11 months (range, 2–43 months).

The complications of the initial 22 cases of laparoscopic radical cystectomy, all with intracorporeally created urinary diversion, were summarized in six major (27%) and nine minor (41%) complications.

All had negative surgical margins, and an average of 10 lymph nodes (range, 5–16) were removed, resulting in positive lymph nodes in three patients (25%). No patients developed local recurrence. Three (25%) developed systematic disease (two in bone and one in liver and lung) at a median follow-up of 33 months (median time to progression), 22 months; and two (17%, pT3aG3 and pT3aG3N1) of the three patients died of the metastatic disease 15 and 24 months after surgery.

necessary to convert to open. Laparoscopic-magnified image provides excellent mucosa-to-mucosa precision during creation of an orthotopic neobladder, and during urethraileal and ureteroileal anastomosis. Although our initial operative times were around 10 hours, current operative time decreased to 8.5 hours with additional 1.5 hours by extended laparoscopic lymphadenectomy. The cystectomy part of the procedure now comprises approximately two hours.

Oncologic outcomes of the initial 22 patients with mean follow-up of 11 months (range, 2–43) were that 21 (95%) had negative margin, six (27%) had positive lymph nodes, three (14%) died of distant recurrence, and one local recurrence (4.5%) in case with pT4N2 with lung metastasis (alive, undergoing chemotherapy) was noted.

Importantly, radical cystectomy can provide not only an accurate pathological evaluation of the primary bladder cancer but also the assessment of regional lymph nodes involvement. There is increasing evidence to support extensive and meticulous dissection to enhance nodal yield, and oncologic outcomes. Herr et al. (12) reported regarding the impact of numbers of lymph nodes retrieved on outcomes of open radical cystectomy; patients with positive lymph nodes had significantly better survival when greater than 11 lymph nodes were retrieved for examination, and patients with negative lymph nodes had better survival when eight or greater lymph nodes were evaluated. Technique and initial outcomes of laparoscopic extended lymphadenectomy for bladder cancer was reported recently from Cleveland Clinic (13).

The median number ($n = 21$) of nodes retrieved in the author's series and anatomical boundaries of the surgical procedure (bilaterally skeletonizing the genitofemoral nerve, external iliac artery, external iliac vein, obturator nerve, hypogastric artery, common iliac artery, and pubic bone) were commensurate with those of current recommendation for open surgery. No patient developed port site or no local recurrence over the short follow-up of 11 months (range, 2–43 months) (13).

Laparoscopic radical cystectomy is a complex procedure and requires advanced laparoscopic expertise; as such, a critical appraisal of the attendant complications is essential.

The complications of the initial 22 cases of laparoscopic radical cystectomy, all with intracorporeally created urinary diversion, were summarized in six major (27%) and nine minor (41%) complications (13,14).

The major complications, all of which required reoperation, were small bowel obstruction ($n = 3$, 14%), ureteroileal anastomotic leak ($n = 1$, 4.5%), urethrovaginal fistula ($n = 1$, 4.5%), and bowel perforation with delayed death ($n = 1$, 4.5%). Minor complications were mainly related to prolonged ileus ($n = 6$, 28%), all of which were conservatively managed, deep venous thrombosis ($n = 2$, 9%) that was managed by thrombolytics administration, and postoperative bleed ($n = 1$, 4.5%) that was laparoscopically suture repaired.

Purely Laparoscopically Completed Continent Urinary Diversion: Charite Hospital Experience

The first purely laparoscopically completed continent urinary diversion (rectosigmoid pouch) was reported by Turk et al. in 2001 (11). The authors demonstrated that purely laparoscopic reconstructed rectosigmoid pouch was feasible and safe with the same functional outcomes as after open Mainz II procedure. Recently, among their 20 laparoscopic radical cystectomy series, this group documented the oncologic and functional data of 12 patients undergoing laparoscopic rectosigmoid pouch creation for continent urinary diversion with follow-up for longer than two years (range, 13–42 months, median 33) (15). Median operative time was 485 minutes (range, 365–830); median blood loss was 200 mL (range 190–800); median hospital stay was 15 days (range, 11–30); two patients required reoperation due to persistent leakage of the pouch and rectovaginal fistula, respectively. Unilateral hydronephrosis with loss of the renal function was found in one.

All had negative surgical margins, and an average of 10 lymph nodes (range, 5–16) were removed, resulting in positive lymph nodes in three patients (25%). No patients developed local recurrence. Three (25%) developed systematic disease (two in bone and one in liver and lung) at a median follow-up of 33 months (median time to progression), 22 months; and two (17%, pT3aG3 and pT3aG3N1) of the three patients died of the metastatic disease 15 and 24 months after surgery. All patients were continent during the day. Eleven patients were continent at night, but one was using two or five pads per night.

Laparoscopic-Assisted Laparoscopic Radical Cystectomy

In 2002, Gaboardi et al. (16) introduced the laparoscopic-assisted technique of laparoscopic radical cystectomy with ileal neobladder, in which extracorporeal restoring of intestinal

TABLE 2 ■ Operative Outcomes of Reconstructive Urinary Diversion

Author (yr)	Puppo (1995)	Denewer (1999)	Turk (2001)	Abdel-Hakim (2002)	Simonato (2003)	Menon (2003)	Hemal (2004)	Basillotte (2004)	Taylor (2004)	Gill (2004)
Number of patients	5	10	5	9	10	17	11	13	8	22
Technique	Transvaginal and laparoscopic-assisted (extra) ileal conduit	Laparoscopic-assisted (extra) Sigmoid-pouch, 10 (extra)	Purely intracorporeal laparoscopic Rectal-sigmoid-pouch, 5 (Purely intra)	Laparoscopic-assisted (extra) Orthotopic, 9 (extra)	Laparoscopic-assisted (extra) Orthotopic, 6 sigmoid-ureterostomy, 2 cutaneous-ureterostomy, 2 (extra)	Robot-assisted (extra) Orthotopic, 14 ileal conduit, 3 (extra)	Laparoscopic-assisted (extra) ileal conduit, 11 (extra)	Laparoscopic-assisted (extra) Orthotopic, 13 (extra)	Hand-assisted (extra) ileal conduit, 8 (extra)	Purely intracorporeal laparoscopic ileal conduit, 14 orthotopic, 6 (intra) Indiana, 2 (extra)
Type of urinary diversion	Cutaneous, 1									
Mean (range) operative duration (hr)	7.2 (6-9)	3.6 (3.3-4.1)	7.4 (6.9-7.9)	8.3 (6.5-12)	Orthotopic, 7.1 sigmoid-ureterostomy, 5.8 cutaneous-ureterostomy, 4.7	Orthotopic, 5.1 ileal conduit, 4.3	6.1 (4.3-8)	8.0 hrs (± 77 min)	6.7 (5.5-7.7)	8.6
Blood loss (mL), transfusion	3 pts transfused 2-6 units	Transfused mean 2.2 unit, range 2-3	245 (190-300)	150-500	310 (220-440)	<150	530 (300-900)	1000 \pm 414	637 (400-1000), transfused in 2 pts	490
Ileus (day)	2.6 (2-4)	Not stated	Not stated	Not stated	3.3 (1-5)	Not stated	Not stated	Not stated	1 prolonged	6 prolonged ileus, 3 bowel obstruction
Length of stay (day)	10.6 (7-18)	10-13	10 (in all 5)	Not stated	Orthotopic, 8.1 sigmoid-ureterostomy, 8 cutaneous-ureterostomy, 5	Not stated	10.5	5.1 \pm 1.2	6.4 (3-10)	Not stated
Time to oral intake (day)	2-4	Not stated	Liquid 3	3	3-6	Not stated	Not stated	Liquid 2.8, solid 4.1	4.5 (3-8)	8
Time to return to work (day)	Not stated	Not stated	Not stated	Not stated	Not stated	Not stated	26	11.0 \pm 1.9	21-28	Not stated
Functional outcomes	4/5 discharged with no post operative complications, 1 discharged after 18 days due to obesity and diabetic problems	All continence, 1 ureterosigmoid urine leak, 1 pyelonephritis	All 5 with continent and no obstruction of upper urinary tract in urogram on 10th post operative day	No complications in pouchogram on 10th post operative day	2 bilateral hydronephrosis and metabolic acidosis, 1 monolateral hydronephrosis	13 bilharziasis with periureteric, perivesicular and perivesical scarring	All had normal renal function and preserved upper urinary tracts	1 ureteral obstruction, 1 bladder neck contracture, 1 obturator nerve paresis	1 upper gastrointestinal bleed, 1 rectal injury and ileus	1 ureteroileal leak, 1 urethrovaginal fistula

Source: From Ref. 3.

In their six cases experience of laparoscopic-assisted laparoscopic radical cystectomy with orthotopic ileal neobladder, operative time was reported, 360 to 510 minutes (mean, 425); estimated blood loss, 220 to 440 mL (mean, 311); ileus day, three to five days (mean, 3.7); and hospital stay, seven to nine days (mean, 8.1). All six patients were alive during follow-up of 5 to 15 months (mean, 9.3), however, despite negative surgical margins two (33%) patients (T1N0G3+Cis and T2aN0G2-3) had metastatic diseases at six months after surgery.

The authors concluded that laparoscopic-assisted approach contributes to decreased postoperative pain and quicker recovery with similar complication rate to open approach. It should be noted that in this study, the reconstructive portion was performed through a 15-cm low Pfannenstiel incision.

In the initial experiences of 11 patients who underwent laparoscopic radical cystectomy and an open-hand sewn ileal conduit from 1999 to 2002, Hemal et al. reported one (9%) case with positive margin and other five (45%) cases of procedure-specific complications.

In 2003, the first case report of daVinci-assisted laparoscopic cystectomy with intracorporeally created ileal neobladder (Hautmann) was described by Beecken et al., resulting in operative time of 8.5 hours.

continuity and partial construction of the posterior plate of ileal neobladder with 25-cm loop was performed through a 5-cm supraumbilical incision that is necessary to remove the surgical specimen. Following closing the supraumbilical incision and recreation of pneumoperitoneum, the urethra-neobladder anastomosis, ureteral anastomosis, and closing of the remained anterior neobladder wall were completed intracorporeally. The authors discussed extracorporeally detubularization of the ileal loop may prevent fecal contamination of the abdominal cavity, and open-assisted ileal-to-ileal anastomosis of the posterior plate with reapproximation of mesenteric margin may prevent intestinal mechanical obstruction.

In their six cases experience of laparoscopic-assisted laparoscopic radical cystectomy with orthotopic ileal neobladder, operative time was reported, 360 to 510 minutes (mean, 425); estimated blood loss, 220 to 440 mL (mean, 311); ileus day, three to five days (mean, 3.7); and hospital stay, seven to nine days (mean, 8.1). All six patients were alive during follow-up of 5 to 15 months (mean, 9.3), however, despite negative surgical margins two (33%) patients (T1N0G3+Cis and T2aN0G2-3) had metastatic diseases at six months after surgery (17).

The authors concluded that laparoscopic-assisted approach contributes to decreased postoperative pain and quicker recovery with similar complication rate to open approach. It should be noted that in this study, the reconstructive portion was performed through a 15-cm low Pfannenstiel incision.

Among total 10 cases of their laparoscopic radical cystectomy series with different urinary diversions, two cases of completely intracorporeally created sigmoid ureterostomy were noted with an operative time of 300 to 390 minutes (Table 2) (3).

In the initial experiences of 11 patients who underwent laparoscopic radical cystectomy and an open-hand sewn ileal conduit from 1999 to 2002, Hemal et al. reported one (9%) case with positive margin and other five (45%) cases of procedure-specific complications (18).

The authors described three intraoperative complications including injury to the external iliac vein ($n = 1$) and a small rectal tear ($n = 2$), all repaired by laparoscopic freehand suturing. Other laparoscopic surgical complications were subcutaneous emphysema ($n = 1$), and hypercarbia ($n = 1$) necessitating conversion to open surgery. The authors discussed that laparoscopic radical cystectomy was associated with complications similar to those seen with other laparoscopic and open surgery procedures, especially during the initial experience.

In 2004, Basillote et al. retrospectively compared perioperative outcomes of radical cystectomy with ileal neobladder between 11 men who underwent open approach and 13 men who underwent laparoscopic-assisted approach (19). The authors suggested laparoscopic approach provided significant decrease in postoperative pain, represented by parenteral morphine equivalent use (mg); open, 144 versus laparoscopy, 61, $p = 0.04$, as well as provided significant quicker recovery, represented by (i) start of oral liquids (days); open, 5 versus laparoscopy, 2.8, $p = 0.004$, (ii) start of oral solids (days); open, 6.1 versus laparoscopy, 4.1, $p = 0.002$, (iii) hospital stay (days); open, 8.4 versus laparoscopy, 5.1, $p = 0.0004$, (iv) lights work back (days); open, 19 versus laparoscopy, 11, $p = 0.0001$, without a significant increase in operative time (open, 7.2 hours vs. laparoscopy 8 hours, $p = 0.5$) and with similar complication rate (open, one major and five minor vs. laparoscopy, four major and two minor).

In the initial experiences of 11 patients who underwent laparoscopic radical cystectomy and an open-hand sewn ileal conduit from 1999 to 2002, Hemal et al. reported one (9%) case with positive margin and other five (45%) cases of procedure-specific complications (18).

As such, an ileal loop or orthotopic neobladder could be completed purely laparoscopically or in an open fashion through an enlarged extraction incision. Proponents of the open-assisted approach refer its decreased operative time for performing the neobladder when compared to the purely intracorporeal procedure. Retrospective or prospective data comparing between intracorporeal and open-assisted approach are not yet available.

Robot-Assisted Laparoscopic Radical Cystectomy

Three-dimensional stereoscopic vision, and multiangled movement with endowrist instruments are advantages for robotic-assisted surgery, although they are cost-intensive tools available in specialized centers alone.

In 2003, the first case report of daVinci-assisted laparoscopic cystectomy with intracorporeally created ileal neobladder (Hautmann) was described by Beecken et al., resulting in operative time of 8.5 hours (20).

The feasibility of robot-assisted laparoscopic cystectomy with intracorporeal created ileal conduit was reported in two men and one woman by Balaji et al., although mean operative time was more than 10 hours (691 minutes); mean estimated blood loss,

250 mL; and hospital stay, 7.3 days (21). Menon et al. reported technical feasibility of nerve-sparing robot-assisted radical cystectomy with extracorporeally created urinary diversion in 14 men and 3 women (22). Mean blood loss was less than 150 mL, and operative time for robotic radical cystectomy, extracorporeal ileal conduit, and extracorporeal orthotopic neobladder were 140, 120, and 168 minutes, respectively, although 13 (76%) patients had associated bilharziasis, with significant periureteric, perivesicular, and perivesical scarring. The functional and oncological data in this series were awaited.

The authors concluded that laparoscopic-assisted approach contributes to decreased postoperative pain and quicker recovery with similar complication rate to open approach. It should be noted that in this study, the reconstructive portion was performed through a 15-cm low Pfannenstiel incision.

Hand-Assisted Laparoscopic Radical Cystectomy

The first case report of hand-assisted laparoscopic radical cystectomy with ileal conduit was described by Peterson et al. in 2002 (23). Operative time was seven hours with 750 mL of blood loss. McGinnis et al. described the first series of seven patients undergoing hand-assisted laparoscopic radical cystectomy and ileal conduit. Mean operative time was 7.6 hours, blood loss was 420 mL, and hospital stay was 4.6 days (24). In 2004, Taylor et al. documented nonrandomized comparison between hand-assisted laparoscopic radical cystectomy and open cystectomy in eight cases each (25).

The author reported significant difference was observed only in the mean postoperative parenteral analgesia administration; hand-assisted, 31 mg versus open, 149 mg ($p = 0.01$); however, no statistical differences in others, including (i) operative time; hand-assisted, 403 minutes versus open, 420 minutes ($p = 0.7$), (ii) blood loss; hand-assisted, 637 mL versus open, 957 mL ($p = 0.2$), (iii) hospital stay; hand-assisted, 6.4 days versus open, 9.8 days ($p = 0.06$), (iv) regular diet; hand-assisted, 4.5 days versus 7.9 days ($p = 0.05$).

Prostate-Sparing Laparoscopic Radical Cystectomy

Prostate- and seminal-sparing cystectomy may be an option in young patients whose preservation of urinary continence and sexual potency are fundamental (26). In carefully selected patients, this procedure was proposed in open surgically resulting in more than 90% of patients being potent, while nearly all are totally continent, with no additional oncologic risk. In 2003, Guazzoni et al. reported the initial three cases of laparoscopic nerve- and seminal-sparing cystectomy with extracorporeally created orthotopic ileal neobladder (27). The operative time was 410 to 480 minutes, blood loss was 150–300 mL, and hospital stay was eight to nine days. All three patients were fully continent and had normal sexual functions at three months after surgery.

Cathelineau et al. reported the largest experience with laparoscopic radical cystectomy in 84 patients, including cystoprostatectomy in 31, and prostate-sparing cystectomy in 40 (28).

All patients had negative surgical margins. Pathologic staging comprised pT_a pT₁ {13}, pT₂ {59}, pT₃ {11}, and pT₄ {1}, and tumor grades were grade 1 {1}, grade 2 {13}, and grade 3 {17}. Seven patients had positive lymph nodes; numbers of retrieved nodes were not reported. Median surgical time was 4.3 hours; a median blood loss was 550 cc; median hospital stay was 12 days, with requiring parenteral narcotics for 24 hours postoperatively in 58% of patients. Urinary diversion was reconstructed extracorporeally with orthotopic bladder in 51 and ileal conduit in 33 patients. Postoperative complications were reported in 15 patients, including urinary tract infection {8}, pelvic hematoma {3}, urinary fistula {2}, pulmonary embolism {1}, and pyelonephritis {1}.

At an average follow up of 18 months (range 1–44 months), all 84 patients were alive at last follow up, and 83% were disease-free without any evidence of trocar or extraction site seeding. Eight patients developed metastatic disease, and five developed local recurrence.

INTERNATIONAL REGISTRY AND FUTURE DIRECTION

There is no current universally established approach for the reconstructive component of this surgery. Indication for choosing the type of laparoscopic urinary diversion that is best suited to a patient is not different from that of open surgery.

To define the laparoscopic radical cystectomy can be a viable alternative to standard open radical cystectomy, careful prospective and long-term evaluation of oncologic and functional outcomes will be necessary. Recently created International Registry for Laparoscopic Radical Cystectomy has been established by Gill and coworkers to facili-

The author reported significant difference was observed only in the mean postoperative parenteral analgesia administration; hand-assisted, 31 mg versus open, 149 mg ($p = 0.01$); however, no statistical differences in others, including (i) operative time; hand-assisted, 403 minutes versus open, 420 minutes ($p = 0.7$), (ii) blood loss; hand-assisted, 637 mL versus open, 957 mL ($p = 0.2$), (iii) hospital stay; hand-assisted, 6.4 days versus open, 9.8 days ($p = 0.06$), (iv) regular diet; hand-assisted, 4.5 days versus 7.9 days ($p = 0.05$).

Cathelineau et al. reported the largest experience with laparoscopic radical cystectomy in 84 patients, including cystoprostatectomy in 31, and prostate-sparing cystectomy in 40.

At an average follow up of 18 months (range 1–44 months), all 84 patients were alive at last follow up, and 83% were disease-free without any evidence of trocar or extraction site seeding. Eight patients developed metastatic disease, and five developed local recurrence.

To define the laparoscopic radical cystectomy can be a viable alternative to standard open radical cystectomy, careful prospective and long-term evaluation of oncologic and functional outcomes will be necessary. Recently created International Registry for Laparoscopic Radical Cystectomy has been established by Gill and coworkers to facilitate development of this emerging field in a cohesive manner by optimizing operative techniques, establishing standardized critical care postoperative pathways, and prospectively collecting oncologic, functional, and quality-of-life outcomes data.

Complications were reported intraoperatively in 25 (8%), postoperatively in 75 (24%), and in a delayed fashion in 49 (16%). Positive surgical margins were in 11 patients (4%). In mean follow-up of 18 months (range 0.5–68) among 292 patients (95%) with available information, the overall and cancer-specific survival was 80% and 94%, respectively. There were local recurrences in 20 patients (7%), systemic recurrences in 20 patients (7%), and no port site recurrences.

In the future, laparoscopic radical cystectomy will evolve into a technically optimal combination, with intracorporeal performance of the radical cystectomy, including extended pelvic lymphadenectomy, ureteral mobilization, and selection of the appropriate bowel segment. Majority of the reconstructive procedures, creation of the bowel reservoir, and ureterointestinal anastomoses are likely to be performed extracorporeally through a minilaparotomy. In patients undergoing orthotopic reconstruction, the urethroenteric anastomosis will then be completed intracorporeally.

tate development of this emerging field in a cohesive manner by optimizing operative techniques, establishing standardized critical care postoperative pathways, and prospectively collecting oncologic, functional, and quality-of-life outcomes data (3).

The International Registry database involved nine international centers with published experience in laparoscopic radical cystectomy of at least 10 cases. From December 1999 to July 2005, 308 patients underwent laparoscopic radical cystectomy in 244 males and 64 females with a mean age of 65 years old. Preoperatively, concomitant carcinoma in situ was in 18%, and preoperative computed tomography indicated pelvic lymphadenopathy in 3% and perivesical fat involvement in 8%. Laparoscopic radical cystectomy procedures included cystoprostatectomy (69%), prostate-sparing cystectomy (11%), female anterior pelvic exenteration (14%), and female radical cystectomy (6%). Pelvic lymphadenectomy was performed in 91% of the patients (the mean number of lymph nodes nine, ranged 2–36), revealing nodal involvement on pathology in 52 patients (17%). The types of urinary diversion included orthotopic neobladder (56%) and ileal conduit (38%), which were reconstructed extracorporeally in 89% and intracorporeally in 11%. Mean operating room time was 6.3 hours {1.6–13.8}, and blood loss was 660 cc {50–5000} with 10 patients electively converted to open surgery because of extensive tumor.

Complications were reported intraoperatively in 25 (8%), postoperatively in 75 (24%), and in a delayed fashion in 49 (16%). Positive surgical margins were in 11 patients (4%). In mean follow-up of 18 months (range 0.5–68) among 292 patients (95%) with available information, the overall and cancer-specific survival was 80% and 94%, respectively. There were local recurrences in 20 patients (7%), systemic recurrences in 20 patients (7%), and no port site recurrences.

Because the most technically challenging of laparoscopic radical cystectomy is the reconstructive urinary diversion, the majority of centers preferably perform the urinary diversion extracorporeally through a minilaparotomy incision. Published literatures reported that perioperative outcomes of extracorporeal versus intracorporeal reconstruction of urinary diversion are likely very similar, albeit with shorter operative times and less requirement of advanced laparoscopic skills in the extracorporeal technique.

In the future, laparoscopic radical cystectomy will evolve into a technically optimal combination, with intracorporeal performance of the radical cystectomy, including extended pelvic lymphadenectomy, ureteral mobilization, and selection of the appropriate bowel segment. Majority of the reconstructive procedures, creation of the bowel reservoir, and ureterointestinal anastomoses are likely to be performed extracorporeally through a minilaparotomy. In patients undergoing orthotopic reconstruction, the urethroenteric anastomosis will then be completed intracorporeally.

SUMMARY

- Minimally invasive surgery for bladder cancer and urinary diversion is increasingly gaining acceptance at select institutions across the world.
- Long-term oncologic outcomes of laparoscopic radical cystectomy are limited; however, the currently available perioperative and short-term oncologic outcomes are encouraging.
- Laparoscopic radical cystectomy should include extended pelvic lymphadenectomy mirroring the template of open surgery.
- Laparoscopic approach contributes to decreased postoperative pain and quicker recovery with similar complication rate to open surgery.
- Reconstructive creation of the bowel reservoir and ureterointestinal anastomoses are preferably performed extracorporeally through a minilaparotomy, and then, in patients undergoing orthotopic reconstruction, the urethroenteric anastomosis is completed intracorporeally.
- An international registry of laparoscopic radical cystectomy has been established by the author to facilitate development of this emerging field in a cohesive manner to optimize operative techniques, establishing standardized critical care postoperative pathways, and prospectively collecting oncologic, functional, and quality-of-life outcomes data.

REFERENCES

1. Gill IS, Fergany A, Klein EA, et al. Laparoscopic radical cystoprostatectomy with ileal conduit performed completely intracorporeally: the initial 2 cases. *Urology* 2000; 56:26–30.
2. Gill IS, Kaouk JH, Meraney AM, et al. Laparoscopic radical cystectomy and continent orthotopic ileal neobladder performed completely intracorporeally: the initial experience. *J Urol* 2002; 168:13–18.

3. Ukimura O, Moinzadeh A, Gill IS. Laparoscopic radical cystectomy and urinary diversion. *Curr Urol Rep* 2005; 6:118–121.
4. Stein JP, Lieskovsky G, Cote R, et al. Radical cystectomy in the treatment of invasive bladder cancer: long-term results in 1,054 patients. *J Clin Oncol* 2001; 19:666–675.
5. Parra RO, Andrus CH, Jones JP, Boullier JA. Laparoscopic cystectomy: initial report on a new treatment for the retained bladder. *J Urol* 1992; 148:1140–1144.
6. Kozminski M, Partamian KO. Case report of laparoscopic ileal loop conduit. *J Endourol* 1992; 6:147–150.
7. Sanchez de Badajoz E, Gallego Perales JL, Reche Rosado A, Gutierrez de la Cruz JM, Jimenez Garrido A. Laparoscopic cystectomy and ileal conduit: case report. *J Endourol* 1995; 9:59–62.
8. Denewer A, Kotb S, Hussein O, El-Maadawy M. Laparoscopic assisted cystectomy and lymphadenectomy for bladder cancer: initial experience. *World J Surg* 1999; 23:608–611.
9. Fergany AF, Gill IS, Kaouk JH, Meraney AM, Hafez KS, Sung GT. Laparoscopic intracorporeally constructed ileal conduit after porcine cystoprostatectomy. *J Urol* 2001; 166:285–288.
10. Kaouk JH, Gill IS, Desai MM, et al. Laparoscopic orthotopic ileal neobladder. *J Endourol* 2001; 15:131–142.
11. Turk I, Deger S, Winkelmann B, Schonberger B, Loening SA. Laparoscopic radical cystectomy with continent urinary diversion (rectal sigmoid pouch) performed completely intracorporeally: the initial 5 cases. *J Urol* 2001; 165:1863–1866.
12. Herr HW, Bochner BH, Dalbagni G, Donat SM, Reuter VE, Bajorin DF. Impact of the number of lymph nodes retrieved on outcome in patients with muscle invasive bladder cancer. *J Urol* 2002; 167:1295–1298.
13. Finelli A, Gill IS, Desai MM, Moinzadeh A, Magi-Galluzzi C, Kaouk JH. Laparoscopic extended pelvic lymphadenectomy for bladder cancer: technique and initial outcomes. *J Urol* 2004; 172:1809–1812.
14. Sharp et al. *J Urol* 2003; 169(suppl) (Abstracts: AUA Annual Meeting).
15. DeGer S, Peters R, Roigas J, Wille AH, Tuerk IA, Loening SA. Laparoscopic radical cystectomy with continent urinary diversion (rectosigmoid pouch) performed completely intracorporeally: an intermediate functional and oncologic analysis. *Urology* 2004; 64:935–939.
16. Gaboardi F, Simonato A, Galli S, Lissiani A, Gregori A, Bozzola A. Minimally invasive laparoscopic neobladder. *J Urol* 2002; 168:1080–1083.
17. Simonato A, Gregori A, Lissiani A, Bozzola A, Galli S, Gaboardi F. Laparoscopic radical cystoprostatectomy: a technique illustrated step by step. *Eur Urol* 2003; 44:132–138.
18. Hemal AK, Kumar R, Seth A, Gupta NP. Complications of laparoscopic radical cystectomy during the initial experience. *Int J Urol* 2004; 11:483–488.
19. Basillote JB, Abdelshahid C, Ahlering TE, Shanberg AM. Laparoscopic assisted radical cystectomy with ileal neobladder: a comparison with the open approach. *J Urol* 2004; 172:489–493.
20. Beecken WD, Wolfram M, Engl T, et al. Robotic-assisted laparoscopic radical cystectomy and intra-abdominal formation of an orthotopic ileal neobladder. *Eur Urol* 2003; 43:37–39.
21. Balaji KC, Yohannes P, McBride CL, Oleynikov D, Hemstreet GP III. Feasibility of robot-assisted totally intracorporeal laparoscopic ileal conduit urinary diversion: initial results of a single institutional pilot study. *Urology* 2004; 3:51–55.
22. Menon M, Hemal AK, Tewari A, et al. Nerve-sparing robot-assisted radical cystoprostatectomy and urinary diversion. *BJU Int* 2003; 92:232–236.
23. Peterson AC, Lance RS, Ahuja S. Laparoscopic hand assisted radical cystectomy with ileal conduit urinary diversion. *J Urol* 2002; 168:2103–2105.
24. McGinnis DE, Hubosky SG, Bergmann LS. Hand-assisted laparoscopic cystoprostatectomy and urinary diversion. *J Endourol* 2004; 18:383–386.
25. Taylor GD, Duchene DA, Koeneman KS. Hand assisted laparoscopic cystectomy with minilaparotomy ileal conduit: series report and comparison with open cystectomy. *J Urol* 2004; 172:1291–1296.
26. Vallancien G, Abou El Fettouh H, Cathelineau X, Baumert H, Fromont G, Guillonnet B. Cystectomy with prostate sparing for bladder cancer in 100 patients: 10-year experience. *J Urol* 2002; 168:2413–2417.
27. Guazzoni G, Cestari A, Colombo R, et al. Laparoscopic nerve- and seminal-sparing cystectomy with orthotopic ileal neobladder: the first three cases. *Eur Urol* 2003; 44:567–572.
28. Cathelineau X, Arroyo C, Rozet F, Barret E, Vallancien. Laparoscopic assisted radical cystectomy: the montsouris experience after 84 cases. *Eur Urol* 2005; 47:780–784.

TRANSPERITONEAL LAPAROSCOPIC RADICAL PROSTATECTOMY: TECHNICAL VARIATIONS, ONCOLOGIC AND FUNCTIONAL RESULTS, AND TRAINING

Jens J. Rassweiler, Tibet Erdogan, Marto Sugiono,
Marzel Hrutza, and Dogu Teber

Department of Urology, SLK Heilbronn Hospital, Heilbronn, Germany

- THE HISTORY OF LAPAROSCOPIC RADICAL PROSTATECTOMY
- INDICATIONS OF LAPAROSCOPIC RADICAL PROSTATECTOMY
- SPECIFIC CONTRAINDICATIONS
 - Problematic Conditions
- LAPAROSCOPIC TRANSPERITONEAL ASCENDING RADICAL PROSTATECTOMY (THE HEILBRONN TECHNIQUE)
 - Armamentarium
 - Patient Preparation
 - Trocar Placement
 - Access to Retzius Space
 - Santorini Plexus Control and Transection
 - Apical Dissection
 - Bladder Neck Incision
 - Division of Cranial Pedicles and Seminal Vesicle Dissection
 - Urethrovesical Anastomosis
 - Reconstruction of the Bladder Neck
 - Specimen Retrieval
- LAPAROSCOPIC TRANSPERITONEAL DESCENDING RADICAL PROSTATECTOMY (THE MONTSOURIS TECHNIQUE)
 - Trocar Positioning
 - Posterior Approach
- TECHNICAL VARIATIONS
 - Trocar Positioning
 - Access in Laparoscopic Radical Prostatectomy
 - Control of Vascular Structures
 - Anastomosis
- RESULTS
 - Perioperative Outcomes
 - Pathologic Assessment of Follow-up
 - Functional Assessments and Outcomes
 - Recovery of Continence
 - Recovery of Sexual Potency
- TRAINING
 - Training for Vascular Control and Reconstructive Parts of Laparoscopic Radical Prostatectomy
- SUMMARY
- REFERENCES
- COMMENTARY: Guy Vallancien

The goals of laparoscopic radical prostatectomy, as in retropubic radical prostatectomy, are lifelong oncological control of localized prostate carcinoma while maintaining continence and potency functions with minimizing of operative morbidity that contribute to a global quality of life.

THE HISTORY OF LAPAROSCOPIC RADICAL PROSTATECTOMY

The goals of laparoscopic radical prostatectomy, as in retropubic radical prostatectomy, are lifelong oncological control of localized prostate carcinoma while maintaining continence and potency functions with minimizing of operative morbidity that contribute to a global quality of life.

Transperitoneal laparoscopic radical prostatectomy with ascending approach was first performed by Schuessler et al. (1) and presented in 1992. However, the technical difficulties did not allow widespread application of this procedure. An initial series with nine patients was published in 1997 by the same authors, but they concluded that the procedure was not feasible due to the excessive operation time and multiple technical difficulties (2). The authors stated “laparoscopic radical prostatectomy is not efficacious alternative to open radical prostatectomy as curative treatment of clinically localized prostate cancer.”

Subsequently, Rabbay et al. (3) successfully performed laparoscopic radical prostatectomy with an extraperitoneal access in two patients. In 1993, Kavoussi et al. (4) performed laparoscopic approach to the seminal vesicles as a helpful tool during perineal radical prostatectomy or when treating primary seminal vesicle pathologic conditions. Following the technical modifications of Gaston with a similar transperitoneal dissection of the seminal vesicles in December 1997, Guillonnet and Vallancien promoted

this procedure based on the same principle and published the “Montsouris technique” in 1998 with 40 patients (5). Subsequently, another center from Paris (Creteil) committed to the similar technique and both centers were able to report more competitive operation times of 3–4 hours after considerable experience (6,7). In 1999, Rassweiler et al. developed the transperitoneal ascending laparoscopic technique similar to the classic anatomic radical prostatectomy in 1999 and published this technique as the “Heilbronn technique” with 100 patients (8). Basically, this approach consists of an ascending part, with early division of the urethra and posterolateral dissection of the prostate, followed by the incision of the bladder neck and dissection of the cranial part of the seminal vesicles and vasa deferentia (8).

In 2001, Bollens et al. (9) published a standardized technique of extraperitoneal laparoscopic radical prostatectomy shifting from their initial experience with the transperitoneal approach. These authors emphasized that the main reasons for the extraperitoneal approach were the comparability with the open counterpart (i.e., retropubic descending radical prostatectomy) and potential disadvantages of the transperitoneal route associated with the risk of bowel injury or peritonitis in case of urine extravasation. Laparoscopic radical prostatectomy has become a worldwide accepted alternative to open surgery at centers of expertise using different modifications (Table 1).

In the meantime, several studies have been published about perioperative morbidity or the impact of technical modifications on short-term results; however, there are only few reports concerning the long-term functional and oncological outcome. This is mainly related to the fact that only a limited number of centers of expertise (i.e., Bordeaux, Paris-Montsouris, Paris-Creteil, Heilbronn, Berlin, Bruxelles, and Cleveland) might be able to present such results with an adequate follow-up. With the evolution in laparoscopic technology and proficiency, laparoscopic radical prostatectomy is now useful not only with its surgical outcomes but also with the oncologic and functional results (11). Laparoscopy can be considered feasible if it improves operative and postoperative morbidity and allows a better preservation of periprostatic vascular, muscular, and neurovascular structures by providing better visualization and optical magnification. Nowadays, transperitoneal laparoscopic radical prostatectomy has been increasingly accepted providing similar function and oncologic results as open radical prostatectomy (12–14).

INDICATIONS OF LAPAROSCOPIC RADICAL PROSTATECTOMY

The indications for the radical laparoscopic prostatectomy are the same as that for the open procedures including treatment of men with localized prostate carcinoma and a life expectancy of 10 years or more.

Laparoscopic radical prostatectomy has become a worldwide accepted alternative to open surgery at centers of expertise using different modifications.

The indications for the radical laparoscopic prostatectomy are the same as that for the open procedure including treatment of men with localized prostate carcinoma and a life expectancy of 10 years or more.

TABLE 1 ■ History and Technical Modifications of Laparoscopic Radical Prostatectomy

Author	Comment
Schuessler et al. (1)	The first reported case underwent laparoscopic radical prostatectomy
Kavoussi et al. (4)	Laparoscopic approach to seminal vesicles for its diseases and perineal radical prostatectomy with dissection of these structures
Schuessler et al. (2)	Laparoscopic radical prostatectomy is not alternative to open counterpart due to technical difficulty and longer operation time
Rabboy et al. (3)	Feasible to perform extraperitoneal laparoscopic radical prostatectomy with 2 cases
Gaston (1997) (10)	The model of retrovesical dissection of seminal vesicles and vas deferens was first proposed
Guilloeneau and Vallancien (7)	As a feasible alternative, Transperitoneal laparoscopic radical prostatectomy was promoted as the “Montsouris technique” based on the same principle previously described by Gaston
Abbou et al. (6)	At another center in Paris, the “Creteil” technique committed to a similar technique of transperitoneal laparoscopic radical prostatectomy
Rassweiler et al. (8)	Described as the “Heilbronn technique”, basically consists of an ascending part which is similar to the open counterpart
Bollens et al. (9)	A standardized technique of extraperitoneal laparoscopic radical prostatectomy shifting from their initial experience with the transperitoneal approach

The goal must be eradication of the disease. There is no rigid age limit for radical prostatectomy and a patient should not be deprived of this procedure based on age alone. Due to the lengthy course of prostate cancer, the age and comorbid conditions of the patient are the most important determinants of the benefits of treatment.

The clinical stage has influence in the outcomes of the radical prostatectomy, together with the Gleason score and the preoperative prostate-specific antigen. The Gleason score is an important prognostic factor, but it cannot be used to determine prognosis or to justify management. Also prostate-specific antigen cannot definitively distinguish the stage of the cancer in an individual patient and should not be used alone as a contraindication to definitive treatment. The final decision must be taken with the consent of the patient after the explanation of likelihood of success and complications of each procedure.

SPECIFIC CONTRAINDICATIONS

There is no specific contraindication for laparoscopic surgical approach for localized prostate cancer apart from open surgery. There are four absolute contraindications not only for laparoscopic radical prostatectomy but also for the other laparoscopic surgical approaches: abdominal wall infection, generalized peritonitis, bowel obstruction, and an uncorrected coagulopathy (15).

Problematic Conditions

In obese patients, creation of access might be more difficult while the body habitus of the patient usually does not influence the laparoscopic approach to pelvic region. The thickness of the abdominal wall diminishes the available length of the trocars and consequently the ability to reach deeply situated structures with the instruments.

Previous abdominal surgery or radiotherapy sometimes leads to parietal or intestinal adhesions, which may represent increase risks during access to the Retzius' space.

Periprosthetic fibrosis increases the difficulty of dissecting the prostate, particularly its posterior wall. This situation is often observed after neoadjuvant hormonal therapy, repeated transrectal biopsies, previous inflammation of prostate, and finally transurethral resection of the prostate or open adenectomy of prostate. However, even the patient following external radiotherapy (i.e., salvage prostatectomy) has been treated laparoscopically (16).

LAPAROSCOPIC TRANSPERITONEAL ASCENDING RADICAL PROSTATECTOMY (THE HEILBRONN TECHNIQUE)

The principal goal of the Heilbronn technique (ascending-laparoscopic radical prostatectomy) was to transfer as much of the technical steps of the well-established and perfected classic retropubic radical prostatectomy to the laparoscopic armamentarium.

Armamentarium

We use standard equipment for laparoscopy, including high-flow insufflator, xenon-light source, three-chip charge coupled device camera, and a high-frequency generator for mono- and bipolar coagulation. A voice-controlled robot is utilized to maneuver the telescope (Table 2). A rectal balloon is used for rectal identifications. The retracting forceps are kept in place by a mechanical articulated arm (Martin arm). The main parts of the operation are carried out by use of a bipolar forceps and Metzenbaum endoscissors. Endoscopic suturing is performed with a fine needle holder providing a scissors-like handle. A special endo-peanut-sponge holder is used for bladder retraction. For vascular control, we use 10-mm clip-applicator, and for nerve-sparing technique, we use a 5-mm clip-applicator. We also use an applicator for placement of lockable polyurethane clips (Hem-O-Lok). For the urethral stump, we use a special designed open tip 20-French bougie.

Patient Preparation

The patient is put in deflected supine position with the arms at the sides and the legs adducted. Additionally, a 30-degree Trendelenburg decline supported with inflatable balloon pillow was placed under the patient's buttocks, which displaces the bowel cephalad by gravity. The abdomen is shaved from the costal margins to the pubic bone. A rectal balloon catheter is placed and inflated with 70 cm³. Before trocar placement, a 16-French Foley catheter is inserted under sterile conditions and blocked with 15 cm³ saline. The procedure can be divided into several important steps.

TABLE 2 ■ Armamentarium of Laparoscopic Radical Prostatectomy in Heilbronn Experience

Name	No.	Notes	Manufacturer	Manufacturer number
<i>Equipment:</i>				
Light source	1	Xenon light source 615, power ~70%	Storz	
Digital camera system	1	IMAGE1™	Storz	22200020
High-flow insufflator, Laparomat	1	Flow 20 L/min	Storz	Thermoflator 264320 20
Video monitor	1	Sony	Storz	
HF generator Erbotom Diathermy	1	Monopolar max 90 W, bipolar max 50 W (separate foot pedals for monopolar and bipolar)	Erbe	ICC 350
Martin retractor (holder): Arm	1	Fixing retracting forceps	Martin	1591001
Screw				1591051
Aesop “3000,” voice- controlled robot	1		Computer Motion	
Air gun	1	Used to inflate the dorsal balloon	Storz	27660
<i>General set:</i>				
Dorsal balloon	1	2 sizes are needed	Rusch	815000
Light cable	1		Storz	495 NCS
Optic (telescope)	1	10 mm, 30°	Storz	26003 BA
Gas tube:	1			
Filter	1		MTP (Storz)	031122-01
Luer lock adaptor	1		Storz	600007
Monopolar cable	1	Used with scissors	Storz	26002 ML
Bipolar cable	1	Used with special endodissector	Aesculap	GN 073
Suction-irrigation device	1	5 mm	Storz	26173 BN
Ring head organ grasper	2	“Krause” for mechanical morcelation	Aesculap	SB 51386
Sharp towel holder	2	“Tuch-kleme”	Aesculap	BF 433
Ruler (20 cm)	1	“Sargel” for measuring sutures length	Sulzer	95.00.03
Veress needle 2.1-mm	1		Wolf	8302.12
12.5-mm metal trocar	1	For camera and retrieval	Storz	HZ 30107
Sharp introducer for 12.5-mm trocar	1		Storz	30107 P
Valve for 12.5 mm trocar with rubber cap 60/13	1		Storz	30107 M1
Sheath reducer with rubber cap 60/10 for 12.5-mm trocar	1	12 mm	Storz	30140 HE
10-mm metal trocar	2		Storz	30103 HZ
Sharp introducer for 10-mm trocar	2		Storz	30103 P
Valve for 10-mm trocar with rubber cap 60/10	2		Storz	30103 M1
Sheath reducer with rubber cap 50/4 or 10-mm trocar	2		Storz	30140 DB
5-mm metal trocar	3		Storz	30160 M
Sharp introducer for 5-mm trocar	3		Storz	30160 P
Valve for 5-mm trocar with rubber cap 50/4	3		Storz	30160 M1
Sheath reducer with rubber cap 50/2.6 for 5-mm trocar	1	Mainly for pediatric use	Storz	30140 KA
Double cup reducer: 13/10, 13/5 for 12.5-mm trocar	1		Storz	30142 HB
Cup reducer: 10/5 for 10-mm trocar	2		Storz	30141 HB
Rubber cups: 60/13, 50/4, 60/10	3		Storz	
Endoscissors:	2	5 mm	Storz	
Inner part				34310 MS
Shaft				33300
Handle				33121

(Continued)

TABLE 2 ■ Continued

Name	No.	Notes	Manufacturer	Manufacturer number
5-mm endo-right angle:	1		Storz	
Inner part				33310 R
Shaft				33300
Handle				33121
10-mm endo-right angle:	1		Storz	
Inner part				30420 RG
Shaft				33500 PV
Handle				33131
5-mm endo-dissector:	2		Storz	
Inner part				33310 MD
Shaft				33300
Handle				33121
5-mm self-retained endograsper:	2		Storz	
Inner part				33310 G
Shaft				33300
Handle				33123
5-mm atraumatic clamp:	1	Used to hold the kidney or intestine	Storz	
Inner part				33310C
Shaft				30512
Handle				30525 S
10-mm 120° endodissect “Abbou”:	1		Aesculap	
Inner part				PO 661 R
Shaft				PM 975 R
Handle				PO 950 R
10-mm 120° endodissect “Rassweiler”:	1		Storz	
Inner part				33510 MLL
Shaft				33500 PV
Handle				33131
Endo peanut sponge holder (grasper self-retained):	1		Storz	
Inner part				33310 PT
Shaft				32121 K
Handle				32121 H
Bipolar dissector (310-mm long):	1	The hole instrument	Aesculap	PM 401 R
Inner part				PM 431 R
Shaft				PM 973 R
Handle				PM 450 R
10-mm endo-single stapler	1	Medium size, charge single staple each time	Ethicon	LC 3010 R
5-mm endo-needle	1	For puncturing cysts	Storz	26175 P
10-mm endo stapler Challenger-Ti	1	With magazines of 8 medium to large size clips	Aesculap	PL 536 R
Carter-Thomasson fascial closure device	1	Reusable instrument for fascia closure		
Instrument brush	1	For cleaning		
<i>Exclusive for laparoscopic radical prostatectomy:</i>				
Needle holder 5-mm	1	Non-self-retaining scissors-like handles	Dufner	26918-01
Needle holder 5-mm	1	Self-retaining palm handle	Storz	26173 SK
5-mm self-retained endograsper:	1	Used to hold the catheter	Storz	
Inner part				33310 G
Shaft				33300
Handle				33123

Trocar Placement

We use a W-shaped arrangement of the trocars with insertion of the first trocar (12 mm) periumbilical minilaparotomy (Hasson technique). This port is used for the laparoscope and later for retrieving of the specimen. The other four trocars (2 × 10 and 2 × 5 mm) are placed under endoscopic control after establishing the pneumoperitoneum (maximum pressure 15 mmHg, maximum flow 30 mL). The abdomen is inspected for trocar injury, bleeding, and adhesions. Anatomic landmarks to observe are the Foley balloon in the bladder, obliterated urachus (median umbilical ligament) in the midline, the two obliterated umbilical ligaments (medial umbilical ligament), and the vasa deferentia.

Access to Retzius Space

Following the inspection of the abdomen, we divide the urachus and the both umbilical ligaments using monopolar endoscissor and bipolar endodissector, followed by incision of the peritoneum to the internal inguinal rings laterally. Traversing the light prepubic areolar tissue of the space of Retzius using sharp and blunt dissection exposing the pubic bone caudally as the first landmark and the external iliac vessels laterally, freeing the bladder from its anterior attachments. Then a sixth port (5-mm) is placed in the right lower abdomen through which a grasping forceps is used to pull the urachus and dome of the bladder cranially. After that, the pelvic lymphadenectomy is carried out depending on the prostate-specific antigen (>10 ng/mL) and Gleason score (>6).

Santorini Plexus Control and Transection

First, the bladder is retracted cranially with a forceps grasping at the urachus (VI trocar 5-mm, caudally to the right). The fatty tissue overlying the endopelvic fascia has to be resected or swept cephalad and lateral. An endo-peanut-sponge holder is used to push the prostate medially, exposing the endopelvic fascia. The point of incision is where the fascia is transparent, revealing the underlying levator ani musculature, lateral to the arcus tendineus fascia pelvis because the lateral branches of the dorsal venous complex are directly beneath it. The incision in the endopelvic fascia is then carefully extended in an anteromedial direction toward the puboprostatic (or pubovesical) ligaments (17). This incision, allowing access to the levator ani muscles arching lateral, is carried distally up to lateral most puboprostatic ligament. If necessary, the small veins around the puboprostatic ligaments may be safely cauterized with bipolar forceps. With the puboprostatic ligaments transected, the superficial branch of the dorsal vein is readily apparent in the midline over the bladder neck. The adherent levator ani muscle is gently detached from the prostate, followed by transection of the puboprostatic ligaments (pubovesical ligament). The Santorini plexus is adequately controlled by two stitches caudally and one at the base of prostate for the back flow, using endoscopic suturing technique (17-mm Vicryl MH 2/0). The needle is passed from the right to the left side and should be situated so that the curve of the needle follows the curves of the symphysis pubis. The dorsal vein complex is first coagulated with bipolar forceps then divided cranial to the two distal stitches due to the coagulation-induced shrinkage of the tissue. With slight cranial traction on the prostate, the coagulated veins and the surrounding fibromuscular fatty tissue retract on both sides.

Tips and Tricks

The angle between the needle and the needle holder should be 100 degrees. The dorsal vein complex is transected proximal to the caudal stitches. The optimal retraction of the prostatic apex is accomplished by the use of 120-degree endodissector (10-mm), with the blunt tips up to avoid injuries in the bladder. Minor bleeding (i.e., back bleeding from the prostate, lateral branches of deep dorsal vein complex) can be controlled by bipolar coagulations.

Apical Dissection

Following division of the Santorini plexus, both neurovascular bundles are exposed lateral to the rectum by blunt dissection.

The approach to the apex of the prostate is determined by a decision to proceed with nerve-sparing or with the nonnerve-sparing technique.

The criteria for carrying out nerve-sparing technique are listed in Table 3.

Nonnerve-Sparing Technique

After transection of the dorsal vein complex, the anterior striated sphincteric urethral complex is demonstrated. The fibers of this complex at the apex are horseshoe shaped and

The approach to the apex of the prostate is determined by the decision of proceeding with nerve-sparing or nonnerve-sparing technique.

TABLE 3 ■ Criteria for Carrying Out Nerve Sparing

Clinical stage	Role in nerve-sparing
T1	When prostate-specific antigen is relatively low and the number of positive biopsies or the extent of biopsy involvement is limited
T2a	A contralateral nerve-sparing procedure can be proposed
T2b	A nerve-sparing attempt can result in positive surgical margins and give rise to local failure

form a tubular, striated sphincter surrounding the membranous urethra (18). The urethral sphincter is incised using bipolar forceps and endoscissor exposing the smooth muscle of the urethra. Under the gentle cranial traction of the prostate, anterior rotation of the apex of the prostate occurs and the prostatourethral junction is illustrated where the anterior wall of urethra is incised sharply (no electrocoagulation). The anterior wall of urethra is incised at the level of the prostatic apex (i.e., veru montanum), trying to preserve a maximal length of the stump. After urethra transection the Foley catheter is ligated at the urethral meatus, cut and pulled inside the abdomen to achieve retraction of the gland cranially, using grasping forceps (VI Trocar). The 20-French bougie is inserted to facilitate the cutting of the urethral posterior wall. It is important not to divide the rectourethralis muscle, which fixates the urethral stump dorsally. The prostate apex is dissected gently from the rectum and the distal prostatic pedicles are clipped using 10-mm Hem-O-Lok clips.

Because, the verumontanum is considered as the beginning of the distal continence zone, the urethral transection should be performed at or just distal to the veru. Sometimes the apical prostate overlaps the urethra beyond the verumontanum with urethral transection at or beyond the apex, and the patient can expect a period of incontinence that exceeds what could be achieved if the transection had been made just distal to the verumontanum (17).

The dissection of the urethra should be performed as near as possible to the apex of the prostate before incision is carried out. The Foley catheter is ligated at the urethral meatus cut and pulled inside the abdomen to achieve retraction of the gland cranially, using a grasper (sixth port). The 20-French bougie is placed to assist in the division of the posterior urethral wall. This maneuver is facilitated by the use of 120-degree endodissector to retract the prostate (Fig. 6).

Because the apex of the prostate and rectal ampulla are in close proximity, rectal injuries during radical laparoscopic prostatectomy commonly occur at this location.

The apex of the prostate is dissected gently from the rectum using right angle forceps and suction device. The neurovascular bundle areas are clipped using 10-mm Hem-O-Lok clips and incised, releasing the posterolateral attachments of the prostate, while the midline is dissected bluntly.

Nerve-Sparing Technique

The nerves are microscopic in size; their anatomic location can be estimated by using the capsular vessels as a landmark. The neurovascular bundles are located in the posterolateral side of the prostate, inside a triangle formed by the lateral pelvic fascia (lateral wall), prostatic fascia (medial wall), and the anterior layer of the Denonvilliers' fascia (base) (19). Near the apex, the neurovascular bundle travels at 5 and 7 o'clock positions. The lateral pelvic fascia is incised prior to the incision of the urethra. Displacing the prostate on its side exposes the lateral surface of the prostate. A right angle clamp is inserted under the lateral pelvic fascia beginning at the bladder neck extending distal towards the apex of the prostate, detaching the area of neurovascular bundle from the posterolateral border of the prostate and dissecting gently from the apical part of the prostate. All the prostatic branches from the neurovascular bundle are controlled step by step using 5-mm titanium clips. We avoid the use of bipolar or monopolar coagulation in the bundles area.

The urethra is incised as in nonnerve-sparing technique but when the striated sphincter is divided closer to the apex of the prostate, there is risk that the neurovascular bundle may be damaged. As the neurovascular bundle approaches the apex of the prostate, it is often fixed medially beneath the striated sphincter by an apical vessel. For this reason, the lateral edges of the sphincter should be divided only down to the lateral edge of the smooth muscle of the urethra and not any further posteriorly (not close to the apex of the prostate) (18).

The dissection of the urethra should be performed as near as possible to the apex of the prostate before incision is carried out.

Because the apex of the prostate and rectal ampulla are in close proximity, rectal injuries during radical laparoscopic prostatectomy commonly occur at this location.

We avoid the use of bipolar or monopolar coagulation in the bundles area.

Bladder Neck Incision

After detaching the prostate from the rectum, the gland is gently pulled ventrally by applying traction on the intra-abdominal Foley catheter. The balloon helps to identify the vesicoprostatic commissure.

Non-Bladder Neck-Sparing Technique

Starting at the prostate-vesical junction, the anterior wall of the bladder neck is incised using bipolar coagulation and endoscissors, with the balloon becoming visible. Now the balloon is deflated by cutting the suture at the end of the catheter so that it can be now used as a loop-like retractor. The posterior bladder neck wall is incised, and via retrovesicle access both vasa deferentia and seminal vesicles are dissected following by the incision of the overlying Denonvilliers' fascia.

Bladder Neck-Sparing Technique

Before the division of the bladder neck, the attachments between the bladder and the prostate are incised anteriorly and laterally, thus opening the retrovesicle space and exposing the cranial pedicles, vasa deferentia, and seminal vesicles. Following transaction of these structures between clips, the only part attaching the bladder with the prostate is the bladder neck that is finally divided.

Division of Cranial Pedicles and Seminal Vesicle Dissection

Both lateral pedicles are divided stepwise starting to divide the superficial portions of pedicle and then the deeper portions using two or three lockable 10-mm Hem-O-Lok clips to secure it. In case of a nonnerve-sparing technique, the clips are placed proximally, while in the nerve-sparing technique they are placed close to the base of the prostate. After division of both proximal pedicles each vas deferens is transected. Finally, the seminal vesicles are completely isolated and divided after clipping their vasculature. In the nerve-sparing technique, the dissection of the tips of the seminal vesicles is performed carefully to avoid injuries in the neurovascular bundles. The specimen is then entrapped in the self-opening extraction bag.

Urethrovesical Anastomosis

To perform the urethrovesical anastomosis, the right-medial port IV (for the needle holder) and the left lateral port I (for endo-dissector or second needle holder) are used to achieve an optimal angle between the instruments (30–35 degrees). During this part, we insert the bougie for optimal exposure of the urethra. If it is necessary, the bladder is retracted cranially by a grasper inserted via left medial port. We start with a 17-cm suture at 6 o'clock taking the posterior urethra together with the rectourethralis muscle (Fig. 12). The telescope is inserted deep in the pelvis with the 30-degree angle looking upward. Subsequently, two further stitches are made at 5 and 3 o'clock followed by two stitches at 7 and 9 o'clock starting with the bladder side and then the urethral side. All stitches are performed using intracorporeal knotting technique and tension-free stitches. Thus, all sutures are tied outside the urethral lumen. Choreographed sequence and hand positions are summarized in Table 4.

Reconstruction of the Bladder Neck

After insertion of a 20-French Foley catheter with Tiemann tip, the anterior reconstruction of the bladder neck is performed with two or three interrupted sutures (15-cm Vicryl 3/0, SH needle). Subsequently, the anterior part of the anastomosis is closed over the indwelling catheter. Next, the Santorini vascular complex is reapproximated to the bladder neck to reduce tension on the anastomosis. Posterior bladder neck reconstruction is necessary when the orifices are very close (less than 5 mm) to the resection line (i.e., in case of a large midlobe). In critical case, the 20-French bougie with working channel allows to insert of a guide wire (0.038 inch) into the bladder and a central perforated 20-French silicone Foley catheter can be placed safely over the guidewire.

Specimen Retrieval

After placing the drainage tube via the port IV under vision and affixing it to the skin, the prostate is extracted within the organ bag via the umbilical incision (site of trocar I). For this purpose, the rectus fascia is incised according to the size of the gland. The entire specimen then is sent to the pathologist for staging of the disease.

All steps are summarized in Table 5.

TABLE 4 ■ Choreographed Sequence and Planning of Interrupted Vesi-Courethral Anastomosis During the Heilbronn Technique

Stitch sequence	Location	Plan	Which hand
1	6 o'clock	Outside-in on the urethra Inside-out on the bladder neck	Right hand, forehand stitch Right hand, forehand stitch
2	5 o'clock	Outside-in on the bladder neck Inside-out on the urethra	Right hand, forehand stitch Left hand, forehand stitch
3	3 o'clock	Outside-in on the bladder neck Inside-out on the urethra	Right hand, forehand stitch Left hand, forehand stitch
4	7 o'clock	Outside-in on the bladder neck Inside-out on the urethra	Left hand, forehand stitch Right hand, forehand stitch
5	9 o'clock	Outside-in on the bladder neck Inside-out on the urethra	Left hand, forehand stitch Right hand, forehand stitch
6	12 o'clock (triangle suture)	Outside-in on the bladder neck (right side) Inside-out on the urethra Outside-in on the bladder neck (left side) Inside-out on the bladder neck (right side)	Right hand, forehand stitch Right hand, backhand stitch Left hand, forehand stitch Left hand, forehand stitch

LAPAROSCOPIC TRANSPERITONEAL DESCENDING RADICAL PROSTATECTOMY (THE MONTSOURIS TECHNIQUE)

Trocar Positioning

After a transverse infraumbilical incision of 1–2 cm, a Veress needle is introduced into the peritoneal cavity and insufflation started after the safety maneuvers, without exceeding a pressure of 12 mmHg. After establishing pneumoperitoneum, a 10-mm trocar is inserted into the umbilicus for passage of the laparoscope. Four other trocars are placed

TABLE 5 ■ Laparoscopic Radical Prostatectomy with the Heilbronn Technique—Technical Steps of the Procedure

1. Trocar placement	A “W”-shaped arrangement of the trocars with insertion of the first trocar following infraumbilical Hasson technique. A sixth 5-mm port was inserted in the right lower abdomen after creating Retzius’ space
2. Exposure of Retzius’ space	By high transection of the urachus and both lateral umbilical ligaments
3. Incision of endopelvic fascia and control of dorsal vein complex	Following incision of the endopelvic fascia, partial transection of puboprostatic ligaments and placement of back flow stitch, the dorsal vein complex is double-sutured with grasping of the needle at a 100-degree angle to the branches of the needle holder
4. Transection for urethra and nerve sparing (if required)	The urethra is incised at the level of apex, the periprostatic fascia is incised laterally, and the neurovascular bundles are exposed and dissected from the apical part of the prostate
5. Incision of bladder neck	The circumferential attachments between the bladder and the prostate are incised using bipolar and endoscissor after pulling ventrally of the apex
6. Division of cranial pedicles and dissection of seminal vesicles	Stepwise two or three lockable 10-mm polyurethane clips. After division of both vasa deferentia, finally the seminal vesicles are completely isolated and divided with clipping their vasculature
7. Urethrov vesical anastomosis	Using the right-medial port IV (for the needle holder) and the left lateral port I (for endodissector) for an angle between the instruments (30–35 degrees). The anastomosis is performed by consecutive six interrupted suturing
8. Retrieving the specimen	After placing of drainage tube via port IV under vision and fixed to the skin, now the prostate is extracted within the organ bag via peri the umbilical incision (site of trocar I)

into peritoneal cavity: a 5-mm trocar in the left iliac fossa midway between the left anterior-superior iliac spine and umbilicus, a midline 5-mm trocar between the umbilicus and symphysis pubis, a 5-mm trocar at the level of umbilicus localized at the lateral margin of the right rectus abdominis muscle, and for introduction of the needles and the entrapment sac a second 10-mm trocar in the right iliac fossa at McBurney's point. According to Guillonnet and Vallencien's standardized technique, the Montsouris technique is performed in seven steps (Table 6).

Posterior Approach

Step 1: Posterior Dissection of the Prostate

Dissection of the Seminal Vesicles

The retrovesical cul-de-sac is inspected and the first landmarks are the vas deferens behind the peritoneum and transverse semicircular peritoneal folds at the inferoposterior aspects of the bladder on both sides.

The more superior of these peritoneal folds represents the approximate location of the ureters and should be avoided. The more inferior fold, nearly at the depth of the peritoneal reflection, is created by the meeting of the vasa deferentia in the midline, with the seminal vesicles lying just lateral.

As described by Abbou et al. (6) and Gill et al. (20), the sigmoid colon can be retracted cephalad with a stitch passed through an appendix epiploicae and brought out directly through the anterior abdominal wall and skin. Using electrosurgical endoshears a transverse peritoneotomy along the inferior peritoneal fold is created at the level of the second inferior peritoneal fold to reach the vas deferens and seminal vesicles. The vas deferens is cauterized or clipped and transected. At this point, the surgeon must be aware of the deferential artery that runs posterior along to the ductus and close to the seminal vesicle. This artery should be selectively coagulated and divided. Dissection and cephalad traction of the vas allows access to the ipsilateral seminal vesicles, which is mobilized circumferentially. The tip of the seminal vesicle, supplied by the vesicular artery, is located in close proximity to the neurovascular bundle. Excessive electrocautery in this area should be avoided in case of nerve-sparing technique.

The more superior of these peritoneal folds represents the approximate location of the ureters and should be avoided. The more inferior fold, nearly at the depth of the peritoneal reflection, is created by the meeting of the vasa deferentia in the midline, with the seminal vesicles lying just lateral.

TABLE 6 ■ Laparoscopic Radical Prostatectomy with the Montsouris Technique—Technical Steps of the Procedure

1. <i>Posterior dissection of the prostate:</i>	
Vas deferens and seminal vesicle dissection	A transverse peritoneotomy along the inferior fold is created at the retrovesical cul-de-sac to reach the vas deferens and seminal vesicles, which are mobilized following their arteries selectively coagulated and divided.
Opening Denonvilliers' fascia	The Denonvilliers' fascia is horizontally incised to expose the prerectal fatty tissue and to allow rectoprostatic cleavage to be extended downward until the levator ani muscles are reached.
2. <i>Anterior approach:</i>	
Development of space of Retzius	After making an inverted U-shaped incision, the urachus was divided. An avascular plane is developed on either side of the bladder and dissection is continued anterior and caudal as far as pubic bone.
Incision of endopelvic fascia	After the prostate is retracted to the contralateral and placing the ipsilateral endopelvic fascia on stretch, the fascia is incised on its line of reflection.
Ligation of the dorsal venous complex of Santorini	After placement of back flow stitch, the dorsal vein complex is double-sutured with grasping of the needle in a 100-degree angle to the branches of the needle holder.
3. <i>Bladder neck transection</i>	After incising, the fibrous fascia dissection is continued by following the detrusor muscle fibers where there is an avascular plane between the prostate and bladder until exposing the balloon of Foley catheter.
4. <i>Dissection of the lateral surfaces of the prostate</i>	The lateral pedicle then is meticulously and slowly divided close to the lateral border of the prostate using clip application and cold cutting.
5. <i>Apical dissection of the prostate</i>	
Section of the venous complex	Incision of venous complex is performed by first coagulating with bipolar forceps and then incising tangentially to avoid incision of the anterior surface of the prostate.
Incision of the urethra	The anterolateral urethral wall is incised with a cold knife or scissors. After the tip of urethral metal bougie is delivered through the anterior urethrotomy for exposing the posterior wall, the posterior wall of the urethra is incised similarly.
Incision of the rectourethral muscle	With gentle traction to the prostate superior, rectourethral muscle appears as the final attachment of the prostate and is then incised.
6. Urethrovesical anastomosis	Four sutures are placed at 4,8,2, and 10 o'clock positions and tied outside the lumen.
7. Exit from the abdominal cavity	Incisions are left open and a Drain introduced into the pelvis.

Opening Denonvilliers' Fascia

An important part of the posterior dissection represents the incision of Denonvilliers' fascia, which facilitates the dissection of the prostatic pedicles by taking the rectum away from the pedicles after bladder neck incision. To make the exposure easier, the bilateral completely mobilized seminal vesicles and vas deferens are retracted anteriorly and rectum is retracted posteriorly, thereby placing Denonvilliers' fascia on tension. A shallow incision is made and visualization of yellow perirectal fat confirms to entry into the correct plane between prostate and the rectum.

Step 2: Anterior Approach: Bladder Dissection**Development of Space of Retzius**

Bladder dissection starts with an inverted U-shaped incision, lateral to the bladder contour but medial to medial umbilical ligament, which is extended inferior to the vas and superior to the abdominal wall. The horizontal part of the U-incision is located high on the undersurface of the anterior abdominal wall, cephalad to the dome of the bladder. An avascular plane is developed on either side of the bladder and dissection is continued anterior and caudal as far as pubic bone. At the end of this step, in the midline in the vicinity of the puboprostatic ligaments, a small pad of fat remains including superficial dorsal vein, which is thoroughly coagulated with bipolar electrocautery and transected.

After incision of endopelvic fascia, the dorsal venous complex of Santorini is ligated in the above-described way, similar to the Heilbronn technique following a back bleeding stitch placed across the anterior surface of the prostate using a similar needle. The tails of the back bleeding stitch are cut somewhat long because this suture is helpful during subsequent dissection at the bladder neck, as a locking grasping forceps can be fixed to the tags emanating from the suture knot that allows upward traction of the stitch later during the procedure.

Step 3: Bladder Neck Transection

The bladder is retracted cephalad holding from the long end of back flow stitch, thereby placing the anterior bladder neck on traction. To identify the bladder neck the anterior prevesical fat is retracted superior causing a faint outline of the prostatic vesical plane. After incising the fibrous fascia, dissection is continued by following the detrusor muscle fibers where there is an avascular plane between the prostate and bladder. The anterior wall is incised to expose the balloon of Foley catheter. The catheter balloon is deflated and catheter is pulled up into the abdomen to expose the lateral and posterior urethral walls, which are incised. The bladder neck is carefully preserved with the ureteral orifices far from region of dissection. The anterior layer of Denonvilliers' fascia is incised to enter the previously dissected retrovesical plane. The ductus deferens and seminal vesicles now are delivered through this opening and placed on anterior traction. The remainder of the attachments between the bladder and prostate are divided with electrocautery, maintaining hemostasis. The endpoint of the dissection bilaterally is the lateral pedicle of the prostate, which is anatomically identified by presence of yellowish perivesical fat.

Step 4: Dissection of the Lateral Surfaces of the Prostate

In the antegrade laparoscopic procedure the pedicles are exposed before being incised. A thin fat plane separates the prostatic vascular pedicles from the posterolateral neurovascular bundles. The pedicle is characterized by well-visualized arteries and veins.

At this stage of the technique, different strategies are performed depending on nonnerve-sparing versus nerve-sparing procedures.

Nonnerve Sparing

Bipolar coagulation, harmonic scalpel, or vascular clips (i.e., Hem-O-Lok clips) can be employed to transect the lateral pedicles widely. The ipsilateral seminal vesicle and ductus deferens are retracted anteriorly, placing the adjacent lateral pedicle on traction. Vascular clips or even an endo is consecutively placed across the lateral pedicle, away from and cephalad to the base of the prostate. After employing the clips or stapler, the lateral border of the prostate and neurovascular bundle from the perirectal fat is detached, thereby achieving a wide margin of excision. A similar maneuver is performed on the contralateral side, leaving the prostate attached only at the apex.

Nerve Sparing

Nerve sparing is performed in an antegrade fashion. The ipsilateral seminal vesicle and ductus deferens are retracted anteriorly, placing the lateral pedicle on traction. The lateral pedicle then is meticulously and slowly divided close to the lateral border of the prostate using clip application and cold cutting. To avoid thermal damage to the neurovascular bundle, the surgeon should avoid use of bipolar electrocautery. After division of the cranial pedicles dissection enters a pericapsular fatty space, that contains the neurovascular bundles, which must be preserved by lateral incision of a thin visceral fascia that covers the peribundle fat lateral and medial incision of the lateral edges of Denonvilliers' fascia. These incisions expose the neurovascular bundles and capsular arteries lateral, rising vertically into the prostate that must be clipped with 5-mm metal clips without coagulation to decrease the risk of thermal lesions. Dissection must be extended to the point where the bundles enter the pelvic muscular floor, which is posterolateral from the urethra.

An avascular plane of dissection separating the urethra from the venous complex must be found underneath the venous complex. This plane allows complete identification of the prostate limits and urethra.

Step 5: Apical Dissection of the Prostate***Division of the Venous Complex***

Incision of venous complex is performed following additional bipolar coagulation and then incising tangentially to avoid incision of the anterior surface of the prostate.

An avascular plane of dissection separating the urethra from the venous complex must be found underneath the venous complex. This plane allows complete identification of the prostate limits and urethra.

Some authors prefer introducing a metal bougie into the urethra to facilitate the apical dissection and improve tactile perception of the urethral wall.

Incision of the Urethra

The anterolateral urethral wall is incised with a cold knife or scissors and the tip of previously introduced urethral metal bougie is delivered through the anterior urethrotomy to open the urethral lumen and expose the posterior wall. The posterior wall of the urethra is incised similarly with the endoscissors under traction.

Incision of the Rectourethral Muscle

Rectourethral muscle appears relatively attenuated with this approach and represents the final attachment of the prostate. Division of the rectourethral muscle close to the prostate completely frees the specimen. The excised prostate is entrapped immediately in an endobag, which is temporarily positioned in the upper abdomen.

Step 6: Urethrovesical Anastomosis

According to the authors with expertise in this technique, the preferred length of suture should equal 1.5 lengths of a laparoscopic trocar, working with two needle holders. Anastomosis is performed with interrupted 3-0 or 2-0 Vicryl on a No. 26 or UR-6 needle and all sutures are tied intracorporeally. The metal bougie with a depressed tip helps guide the needle into the urethra and the metal bougie can also help by allowing the needle to slide along the catheter. The first suture is placed at the 5 o'clock position, running inside out on the urethra (right hand, forehand). The second suture is placed at the 7 o'clock position, running inside out on the urethra (right hand, forehand) and outside in on the bladder neck (right hand, forehand). The two sutures are tied inside the urethral lumen. Then four sutures are symmetrically placed at the 4, 8, 2, and 10 o'clock positions, and tied outside the lumen similar to the Heilbronn technique.

Step 7: Exiting the Abdominal Cavity

Peritoneal incisions are left open and a drain is introduced into the pelvis through the lowest left port. Abdominal pressure is lowered to 5 mmHg to check for venous bleeding and trocar sites. The previously entrapped specimen is extracted through McBurney's incision.

TECHNICAL VARIATIONS**Trocar Positioning**

In the Montsouris technique, the authors from Paris prefer the insertion of Veress needle to achieve pneumoperitoneum before placement of the first two 10-mm trocars.

In contrast, in the Heilbronn and Creteil experiences, the authors prefer to place the first trocar (12-mm) using an open Hasson technique at the infraumbilical location (6,21).

Position of the trocars is different in the Montsouris, Creteil, and Cleveland experience in spite of the same technique (7,20,22).

Montsouris Technique

After creating pneumoperitoneum with a Veress needle, a 10-mm trocar is inserted infraumbilically. The second 10-mm trocar is inserted at McBurney's point, to which the CO₂ line is connected. A 5-mm trocar is placed superomedial to the second trocar on the right pararectal line at the level of umbilicus. A 5-mm trocar is inserted in the left iliac fossa midway between the anterior-superior iliac spine and umbilicus. Finally, a midline 5-mm trocar is placed between the umbilicus and the symphysis pubis.

Creteil Modification

The Creteil technique comprises a 12-mm trocar at the infraumbilical location (open Hasson technique); a second 12-mm trocar, near to the lateral margin of the rectus sheath and just below the umbilicus on the surgeon's side; a 10-mm trocar, lateral to the rectus and just below the umbilicus on the assistant's side; and two 5-mm trocars on each side at the level of the anterior-superior iliac spine, just lateral to the epigastric vessels.

Cleveland Modification

The Cleveland variation includes a 12-mm trocar at the infraumbilical location; 10-mm trocars (as port 2 and 3) are on either side of the midline, positioned lateral to the rectus muscle bilaterally and approximately two fingers breadths inferior to the level of the umbilicus; and 5-mm trocars (as port 4 and 5) on either side in the left iliac fossa midway between the anterosuperior iliac spine and umbilicus.

Heilbronn Technique

The Heilbronn technique includes a 12-mm trocar at the infraumbilical location (open Hasson technique); 10-mm trocars (as port 3 and 4) on either side of the midline, positioned lateral to the rectus muscle bilaterally and approximately two fingers breadths inferior to the level of the umbilicus; 5-mm trocars (as port 2 and 5) on the either side of the anterior axillar line at the level of umbilicus; and a sixth 5-mm port in the right lower abdomen following access to the Retzius' space by high transection of the urachus and both lateral umbilical ligaments are employed.

Access in Laparoscopic Radical Prostatectomy

Laparoscopic radical prostatectomy represents a continuously evolving technique with no more than 6000 patients treated in Europe. As in the open retropubic approach different technical modifications have been introduced. Principally four different approaches can be distinguished: (i) transperitoneal descending prostatectomy with initial dissection of the seminal vesicles (Montsouris technique), (ii) transperitoneal ascending prostatectomy (Heilbronn technique), (iii) extraperitoneal descending technique (Brussels technique), and (iv) extraperitoneal ascending technique (modified Heilbronn technique).

Recently, comparable surgical results between extraperitoneal and transperitoneal laparoscopic radical prostatectomy have been published by experienced centers (23–25). However, there was no consensus: some authors (24,26) emphasized the advantages of the extraperitoneal approach (i.e., no bowel lesion, ileus, and peritonitis) and concluded that this technique is superior to the transperitoneal access. Other authors (25) could not find significant differences between both techniques and stated this as a “false debate.”

According to the authors' experience comparing transperitoneal and extraperitoneal laparoscopic radical prostatectomy, there was no significant difference between extraperitoneal and transperitoneal approaches using the Heilbronn technique regarding all important parameters (27). In addition to the preference and experience of the individual surgeon, previous abdominal surgery, gross obesity, and requirement of simultaneous inguinal hernia repair may be considered as selective indications for extraperitoneal laparoscopic radical prostatectomy (Table 7).

Control of Vascular Structures

Adequate hemostasis is one of the most important prerequisites of the procedure. For this purpose, several techniques have to be mastered. Minor bleeders are controlled by

use of the bipolar forceps/dissector. We prefer the use of a bipolar dissector because it offers all functions of a normal dissector (i.e., grasping and retraction of tissue). The generator power should not increase 50 W to avoid secondary thermal lesions that could lead to a rectourethral fistula.

Especially on the side of prostatic pedicle control, several different instruments are preferred in different centers of excellence as listed below (6,7,20,28,29):

- Heilbronn technique: Bipolar endodissector combined with Hemo-O-Lok vascular clips.
- Cleveland technique: Endo-GIA vascular staplers (white color, 3.5 mm and gray color, 2.5 mm) for nonnerve-sparing approach; Hemo-O-Lok clips for nerve-sparing approach.
- Montsorius and Creteil techniques: Bipolar endodissector combined with Hemo-O-Lok vascular clips.
- Berlin technique: Ultrasonic endoscissor.

Anastomosis

In the Creteil technique, main difference is that these authors use a single circumferential running suture for urethra-vesical anastomosis instead of interrupted sutures (30). A starting knot is performed at the 3 o'clock position outside-in fashion forehand with the right needle holder on the bladder neck and inside-out on the urethra. The short tail of the suture is not cut because it will serve to knot the running suture when it is completed. The posterior half of the running suture consists of 4 to 5 needle passages. After performing the anterior half of the running sutures, anastomosis is completed by knotting at the 3 o'clock.

Recently, van Velthoven et al. (31) described a technique for facilitating the urethrovesical anastomosis. Two 6-inch sutures (3-0 Vicryl with SH or UR-5 needle) are tied together at their tail ends and delivered into the operative field by way of a 12-mm port. The running sutures is initiated by placing both needles outside-in through the bladder neck and inside-out on the urethra, one needle at the 5:30 position and the other needle at the 6:30 position. A running suture is completed from the 6:30 to the 12:00 o'clock position and from the 5:30 to the 12:00 o'clock position, at the end of which a single intracorporeal tie is completed.

As described previously, in Heilbronn technique (Table 4), the authors are used to outside knotting for all stitches, whereas the Cleveland and Montsorius groups prefer inside knotting at 5 and 7 o'clock (7,20).

TABLE 7 ■ Advantages and Disadvantages of Both Approaches and Techniques

Extraperitoneal LRP	Transperitoneal LRP	Descending approach	Ascending approach
<i>Advantages</i>		<i>Advantages</i>	
No contact with bowel	Larger room	Less bleeding	Similarity of open counterpart
Previous abdominal surgery	Less tension on anastomosis		Familiar anatomical aspect for nerve sparing
Less problems with extravasation		<i>Disadvantages</i>	
		Two peritoneal incisions	Previous incision of bleeding part
		Unfamiliar to open counterpart	
		Different anatomic dissection	
<i>No advantages in:</i> Operation time Morbidity Complication rate Positive surgical margin Continence		<i>No advantages in:</i> Operation time Morbidity Complication rate Positive surgical margin Continence	

RESULTS

Perioperative Outcomes

Guillonnet and Vallancien used transperitoneal access to the seminal vesicles followed by a descending radical prostatectomy starting the dissection at the bladder neck (7). The Heilbronn technique was designed to copy the standardized technique of open anatomic radical prostatectomy starting with an ascending part controlling Santorini's plexus, dividing the urethra and the distal pedicles followed by a descending part with transection of the bladder neck and transvesical access to the seminal vesicles (29). Corresponding to the experience with open surgery, the descending technique initially offers the advantage of less blood loss because of the earlier control of the proximal prostatic pedicles and the late transection of the dorsal vein complex. However, we could demonstrate that with evolution of our technique and increasing experience, we were able to decrease significantly our transfusion rate (Tables 8 and 9). In our opinion, the ascending technique offers some advantages over the descending technique, such as early identification and detachment of the neurovascular bundle and optimal exposure of the bladder neck, the seminal vesicles, and prostatic pedicles.

As with other laparoscopic procedures (i.e., radical nephrectomy), initially the operating time was significantly longer ranging from 4 to 5.4 hours in the first series. If one renews all of our 1010 cases, the operating time continuously decreased, down to 3.5 hours (2.2–5.4 hours) in our last 100 cases. For the open radical prostatectomy, Scardino's group reported a mean operating time of three hours during the period 1990–1994 decreasing from 3.6 hours in the first to 2.8 hours in the last year of his study. This means that they could reduce their operating time during four years performing 472 cases by 47 minutes or 21.7% of the initial time. With our 1010 patients, we needed a five-year period (1999–2004) for a 100-minute reduction of the operating time including pelvic lymph node dissection from 5.2 to 3.5 hours corresponding to 32.1% of the initial time. This is similar to the experience of the French centers. Therefore, it can be anticipated that a further reduction of operating time will occur in all laparoscopic series of experienced centers, which will also increase the financial benefit of the operation (Table 9).

The most relevant advantages of laparoscopic radical prostatectomy should be documented in a decrease of associated morbidity and shorter convalescence compared to open surgery (Table 10).

There is no doubt that these questions can only be answered definitively by a prospective randomized study. However, the comparison of early results of

The most relevant advantages of laparoscopic radical prostatectomy should be documented in a decrease of associated morbidity and shorter convalescence compared to open surgery.

TABLE 8 ■ Patients and Operative Data of Heilbronn Laparoscopic Radical Prostatectomy Experience

	n: 500	n: 500
Patient data		
Recruitment time	03/99-02/06	03/99-08/02
Median follow-up (mo)	34 (3-87)	37 (20-62)
Patients age (range)	64 (40-82)	64 (43-81)
Prostate-specific antigen (ng/mL)	11.4 (0.1-285)	11.7 (0.2-148)
Median Gleason score	6 (3-10)	7 (3-10)
Prostate volume (cc)	35.2 (3-110)	32.3 (3-102)
Specimen weight (g)	43.7 (8-135)	42.9 (10-125)
Tumor volume (cc)	3.0 (0.2-40)	2.7 (0.2-40)
pT1/2	874 (58.6)	304 (60.8)
pT3/4	618 (41.4)	196 (39.2)
Operative data		
Mean operating (min)	228 (97-600)	246 (128-600)
Nerve-sparing technique (%)	540 (36.0)	109 (21.8)
Bilateral nerve sparing (%)	330	68
Unilateral nerve sparing (%)	210	41
Conversion rate (%)	11 (0.7)	9 (1.8)
Reintervention rate (%)	36 (2.4)	18 (3.6)
Catheter time (days)	7 (4-63)	7 (4-60)
Early complication (%)	87 (5.8)	50 (10.0)
Late complication (%)	41 (2.7)	22 (4.4)

TABLE 9 ■ Comparison of Transperitoneal Laparoscopic Radical Prostatectomy and Open Radical Prostatectomy—Review of the Literature: Peri- and Postoperative Courses

	No. of pts	Operating room time (min)	Transfusion rate (%)	% Early reintervention	% Early complication	Hospitalization (days)	Catheter time (days)
<i>Laparoscopic radical prostatectomy</i>							
Hoznek et al. (2001)	200	210	3.0	2.5	6.0	6.1	4.8
Türk et al. (2001)	125	210	2.0	3.2	10.4	6.5	5.5
Gill et al. (2001)	>40	336	2.5	2.5	NA	1.6	9
Guillonneau et al. (2002)	567	203	4.9	3.7			5.8
Rassweiler et al. (present series)	1500	226	7.7	2.4	5.8	9	7
<i>Open radical prostatectomy</i>							
Dillioglugil et al. (33)	427	182	26.6	1.6	14.2	6.2	14–21
Arai et al. (34)	638	263	19.1	2.0	20.2		
Lepore et al. (35)	1000	NA	9.7	1.0	3.3	2.3	NA
Augustin et al. (36)	1243	NA	29.1	2.6	19.9	NA	15.5
Rassweiler et al. (37)	219	196	26.9	6.8	15.9	16	12

Abbreviation: NA, not available.

laparoscopy to recent data of experienced centers already documents considerable differences with respect to the rates of early and late complications in favor of laparoscopic radical prostatectomy. These differences are caused mainly by the lower rate of anastomotic, thromboembolic, and wound-related complications after endoscopy. Additionally, if the initial development phase, and the learning curve of laparoscopic radical prostatectomy, are taken into consideration, these differences may become even more pronounced.

Pathological Assessment of Follow-Up

Cure of the treated localized prostate cancer represents the first goal of radical prostatectomy as mentioned in the first part of this chapter. Because of the limited follow-up, laparoscopic radical prostatectomy can only provide short-term results. All of the few published series report only on a three-year progression-free survival (Table 11). On the other hand, the evaluation of the oncologic outcome of recent technical modifications of open radical prostatectomy can only be based on a similar follow-up. Since the overall results of the different series mainly depend on the case selection (i.e., with or without adjuvant radiation or antiandrogen therapy), we have

TABLE 10 ■ Comparison of Transperitoneal Laparoscopic Radical Prostatectomy and Open Radical Prostatectomy—Review of the Literature: Peri- and Postoperative Complications

Laparoscopic	Rectal injury (%)	Extravasation (%)	Bleeding (%)	Epigastric injury (%)	Rectourethral fistula (%)	Ileus (%)	Overall complication rate (%)
Türk et al. (2001)	2.4	13.6	1.6	—	0.8	3.2	14.4
Hoznek et al. (2001)	1.5	3.0	1.2	—	0.7	2.4	8.9
Gill et al. (2001)	2.5	NA	5	NA	—	NA	10
Guillonneau et al. (2002)	1.4	8.1	5	0.5		1.0	18.5
Rassweiler (present series)	1.2	5.1	1.4	0.1	0.5	0.4	15.7 ^a
Open	Rectal injury (%)	Extravasation (%)	Bleeding (%)	Lymphocele (%)	Rectourethral fistula (%)	Ileus (%)	Overall complication rate (%)
Dillioglugil et al. (1997)	0.6	NA	1.1	1.1	NA	1.7	27.8
Lepor et al. (2001)	0.5		0.5	0.1	NA	0.2	6.6
Augustin et al. (2003)	0.2	12.9	0.3	2.3	NA	0.3	19.9
Rassweiler et al. (2003)	1.3	2.3	2.9	6.8	0.4	0.4	15.9

^a12.3% major complications, 3.4% minor complication.
Source: From Rassweiler et al., Eur Urol 2006.

TABLE 11 ■ Oncologic Results of Transperitoneal Laparoscopic Radical Prostatectomy in the Literature

Author (Year)	n	Overall positive margin (%)	Stage				Location		
			pT2		pT3		Apex	Bladder	Postero-lateral neck
			pT2a	pT2b	pT3a	pT3b			
Fromont et al. (2002)	139	13.7		10		23.1	61	10.5	26.3
Guilloneneau et al. (2003)	1000	18.8	6.9	18	30	32	50	20	30
El-Feel et al. (2003)	100	25	18	18	45	50	52	20	12
Salomon et al. (2003)	169	18.9		NA		NA	44.4	13.9	41.6
Rassweiler et al. (present series)	1500	22.5		5.9	34.2	50.8	58.7	16.0	9.6

analyzed the current literature with a stratification according to the pathologic stage (pT2 vs. pT3).

For an objective evaluation of the positive margins, the specimen should be inked with two different colors for each lobe and examined with gross sections according to the Stanford protocol (41). In our routine follow-up protocol, the prostate-specific antigen was determined on the 10th postoperative day, after three weeks, and then every three months. If not performed in our laboratory, the data were obtained by telephone contact or transmitted via fax from the referring urologist. In the studies of the literature, patients were usually followed every three months in the first year, and every six months until year 5 (42–45).

We could not detect a significant difference when comparing the rate of positive margins after open or laparoscopic radical prostatectomy, neither for pT2 stages (2.1–16.4% vs. 7.4–21.9%) nor for pT3 tumors (26.4–67.7% vs. 31.1–45.7%).

However, there is a remarkable range in the different series. A recent paper found a higher positive margin rate (34% vs. 19%) after laparoscopic radical prostatectomy among junior surgeons compared to experienced surgeons (39). In our recently published comparative study, the overall rate of positive margins (SM+) did not differ significantly (28.7% vs. 21.0% vs. 23.7%) in the open versus the early and late laparoscopic groups (37). Similarly, no significant difference in the rates of positive surgical margin with 16.9% and 20% has been reported between biopsy grade and clinical stage-matched laparoscopic and open radical prostatectomy (46). However, there was significant difference in location at apex with 5.1% vs. 11.7% ($p < 0.05$) and multiple positive margin locations with 0% versus 8.3%. On the other hand, Katz et al. (47) were able to reduce the rate of positive margins continuously after technical changes of laparoscopic radical prostatectomy.

Wide resection of the bladder neck and cutting the puboprostatic ligaments decreased bladder neck and apical positive margins (47). In accordance to our own observation, nerve preservation did not increase the incidence of positive margins.

Prostate specific antigen relapse, defined as increase of serum levels more than 0.2 ng/mL, was observed in 4.1–11.0% of pT2 stages and 12.0–43.2% of pT3 tumors three years after laparoscopic radical prostatectomy (Table 11). In our first 500 patients followed up for five years, the overall progression-free survival rate was 82.5%, while prostate specific antigen-relapse rates were 15.8%, 19.2%, and 45.5% for pT2, pT3a, and pT3c/4, respectively (Table 12). As mentioned before, only a few centers are able to provide such results. Oncologic studies after open prostatectomy usually present a longer follow-up ranging from five to 15 years. When we have analyzed the Kaplan–Meier curves of the respective studies to calculate three years' results, this revealed similar results for open radical prostatectomy (pT2: 3.7–15%; pT3: 14.7–33.1%) compared to the laparoscopic group (14). The data about clinical progression could not be compared because of the different follow-up and presentation.

Current data indicate that the oncologic outcome after laparoscopic radical prostatectomy will not differ from open surgery. Most importantly, recent studies could not detect any specific oncologic risk related to the laparoscopic technique, such as port site metastases (48).

In summary, we did not detect any significant differences with respect to positive margins and short-term PSA recurrence comparing laparoscopic versus open radical prostatectomy. Of course, we have to wait for the long-term results of laparoscopy. However, until now there are no results indicating specific risk factors or deterioration of the oncologic outcome in comparison with open surgery.

We could not detect a significant difference when comparing the rate of positive margins after open or laparoscopic radical prostatectomy, neither for pT2 stages (2.1–16.4% vs. 7.4–21.9%) nor for pT3 tumors (26.4–67.7% vs. 31.1–45.7%).

Wide resection of the bladder neck and cutting the puboprostatic ligaments decreased bladder neck and apical positive margins. In accordance to our own observation, nerve preservation did not increase the incidence of positive margins.

Current data indicate that the oncologic outcome after laparoscopic radical prostatectomy will not differ from open surgery. Most importantly, recent studies could not detect any specific oncologic risk related to the laparoscopic technique, such as port site metastases.

TABLE 12 ■ Positive Surgical Margins and Oncologic Results in Laparoscopic Radical Prostatectomy with the Heilbronn Technique

	Laparoscopic radical prostatectomy	
	<i>n</i> : 1	<i>n</i> : 500
Positive margins (%)	332/1495 (22.2)	99 (19.8)
pT2	51/859 (5.9)	26/296 (8.8)
pT3a	126/368 (34.2)	30/107 (28.0)
pT3b	91/179 (50.8)	28/69 (40.6)
	Laparoscopic radical prostatectomy (<i>n</i> : 700)	
	3-Yr follow-up	5-Yr follow-up
PSA recurrence (>0.2 ng/mL)	86/636 (13.5%)	63/246 (25.6%)
pT2	37/379 (9.8%)	19/134 (14.2%)
pT3a	26/153 (16.9%)	22/57 (38.6%)
pT3c/4	23/104 (22.1%)	22/55 (40.0%)
Overall survival	638/649 (98.3%)	246/252 (97.6%)
Progression-free survival	620/638 (97.2%)	234/246 (95.1%)
Adjuvant treatment	137/649 (21.1%)	36/252 (14.3%)
Secondary therapy (e.g. radiotherapy, antiandrogen therapy)	44/649 (6.8%)	23/252 (9.1%)

Functional Assessments and Outcomes

Urinary incontinence and erectile dysfunction are the two most frequent and most disabling functional sequelae.

Recovery of Continence

The quality of continence after any technique of radical prostatectomy (i.e., retropubic, perineal, laparoscopic) is difficult to assess, as reflected by the marked variability of incontinence rates reported in the literature. This is related to three main factors: definition of continence, modalities of evaluation, and follow-up.

The definition of continence varies considerably from one pad study to another: total absence of protection (i.e., no pad) or use of a maximum of one pad (i.e., safety pad). Others distinguish between diurnal and nocturnal continence. Geary et al. (49) reported that 80.1% of patients did not require any protection, while Eastham et al. (50), considering patients who required a maximum of one pad daily to be continent, reported a rate of 91%. It might not be extremely relevant for the quality of life of the patients to wear a safety pad (i.e., to be “socially dry”), and some patients may still use one despite having reached already complete continence.

In most laparoscopic and open studies (Table 13), full continence was defined as no need of any pads during normal daily activity (i.e., work, exercise, walking), no urine leak with cough or sneeze. Minimal stress incontinence was defined as occasional urine leak (i.e., when exercising, with cough or sneeze) necessitating no more than three pads per day and no urine leak during night. Moderate stress incontinence was defined as urine leak during the day under normal activity requiring more than three pads, and no urine leak during night. Severe stress incontinence was defined as urine leak during the day and night representing a serious problem for the patient.

The modalities of evaluation also differ considerably: clinical interview by the surgeon, interview by another doctor not involved in the surgery, self-administered questionnaire. The method of data collection is essential to obtain perfectly objective information. Again an increase by 10–15% of incontinence rates has to be calculated, when using a questionnaire (36,59,60). Evidently, the general application of a validated questionnaire (i.e., Interhand Continence Society-Male Questionnaire) would facilitate comparison of the various results reported in the literature (61). It has to be emphasized that in most of the laparoscopic studies a questionnaire was applied. In our center, all patients who do not return the questionnaire are interviewed by colleagues not involved in the surgery. Additionally, the time to full continence is documented for each patient.

Finally, the follow-up frequently differs from one series to another. Although about half of the patients can achieve full continence within the first three months and

The definition of continence varies considerably from one study to another. Such different definitions usually contribute to a difference of about 10% in continence rates.

TABLE 13 ■ Laparoscopic versus Open Radical Prostatectomy: Recovery of Continence

Author (Ref.)	N	Mean age (yr)	Evaluation	Follow-up (mos)	Continence (%)
<i>Laparoscopic radical prostatectomy</i>					
Türk et al. (28)	275	60.2	Physician	12	94.0
Eden (51)	100	62.2	Physician	12	90.0
Guillonneau et al. (12)	567	63.0	Questionnaire	12	79.0
Salomon et al. (40)	100	65.1	Questionnaire	12	90.0
Roumeguere (52)	77	62.5	Physician	12	80.7
Rassweiler et al. (14)	500	64.0	Questionnaire	12	83.6
Rassweiler et al. (14)	310	64.0	Questionnaire	24	97.7
<i>Total/mean</i>	1929	63.0		13.7	87.8
<i>Open radical prostatectomy</i>					
Catalona et al. (1999)	1325	63.0	Physician	50	92.0
Walsh et al. (2000)	64	57.0	Questionnaire	18	93.0
Steiner (2000)	593	34–76	Physician	22	94.5
Kao (2000)	1069	63.6	Questionnaire	>12	77.0
Sullivan (2000)	75	63.3	Questionnaire	12	87.0
Rassweiler et al. (2003)	219	65.0	Questionnaire	12	89.9
Roumeguere (2003)	77	63.9	Physician	12	83.9
Harris (2003)	439	65.8	Physician	12	96.0
<i>Total/mean</i>	3861	63.0		18.7	89.1

most are dry at one year, some patients can still recover for up to two years (Table 14) with significant impact on their quality of life. Thereafter, improvement of urinary function is unlikely to occur.

Furthermore, independently of the technique, the main predisposing factor for postoperative incontinence appears to be greater than 70 years (49,52,53,61). The respective roles of other factors, such as stage of disease, associated diseases (i.e. diabetes, polyneuropathia, smoking), postoperative extravasation, or anastomotic stricture are also discussed (49,50,63).

Apart from this, some authors, again independent from the approach, consider that certain technical modifications appear to facilitate preservation of continence: quality of apical dissection, preservation of puboprostatic ligaments, preservation of bladder neck or the neurovascular bundle (55,63–65). The impact of such surgical modifications on postoperative continence is evident but very difficult to evaluate.

There is no doubt that in this millennium every “radical prostatecomist”—be it an open surgeon or a laparoscopist—tries to perform a most delicate apical dissection with maximal preservation of the circumferential rhabdosphincter muscles and minimal damage to its surrounding structure. On the other hand, all further technical proposals, such as preservation of the bladder neck or puboprostatic ligaments, preservation of the intrapelvic branch of the pudendal nerve, reconstruction of the rectourethralis muscle or facial retrourethral structures are still under debate, mainly because the initially described quicker time to total continence turned out not to be constantly reproducible (55,63–65).

TABLE 14 ■ Laparoscopic Radical Prostatectomy: Development of Continence (Compared with Open Radical Prostatectomy)

Follow-up (%)	Laparoscopic			Open		
	Rassweiler et al.	Salomon et al.	Eden et al.	Eastham et al.	Henzer et al.	Harris
1 month	28	45	11	28	33	38
3 months	51	63	62	65	69	62
6 months	70	74	81	79	85	85
12 months	84	90	90	92	91	96
24 months	97	NA	92 ^a	95	NA	NA

^aFollow-up at 18 months.
Abbreviation: NA, not available.

In summary, there are no significant differences between the laparoscopic or open approach, neither with respect to overall 12 months continence (60–94% vs. 61–98%) nor regarding the three months continence (51–63% vs. 62–69%), as postulated by some authors.

Conclusively, it is not the approach but the experience of the surgeon that remains one of the most essential factors to improve the recovery of continence.

The most successful tool to evaluate erectile dysfunction proved to be the abridged, five-item version of the International Index of Erectile Function.

In summary, there are no significant differences between the laparoscopic or open approach, neither with respect to overall 12 months continence (60–94% vs. 61–98%) nor regarding the three months continence (51–63% vs. 62–69%), as postulated by some authors.

Based on the actual results, laparoscopic surgery enables the transformation of all technical variations proposed for open radical prostatectomy, but despite all efforts could not yet significantly improve early continence rates in comparison to open surgery (49,50,53–55,62–65).

Conclusively, it is not the approach but the experience of the surgeon that remains one of the most essential factors to improve the recovery of continence. The cases of later recovery of continence are mainly attributed to associated factors such as age or concomitant morbidity of the patient.

Recovery of Sexual Potency

As for continence, objective evaluation of postoperative erectile dysfunction encounters a number of difficulties:

- 1. Absence of a consensual definition of sexual potency in the studies
- 2. Various methods of evaluation
- 3. Difficulties of evaluation
- 4. Variable follow-up

The definition of sexual potency varies according to the adopted criteria, such as erection without intercourse (i.e., return of erection) or erection firm enough for intercourse. Moreover, the frequency as well as quality of sexual activity has been recorded (66).

The most successful tool to evaluate erectile dysfunction proved to be the abridged, five-item version of the International Index of Erectile Function (67).

Hara et al. were able to demonstrate its applicability when comparing the quality of life after open and laparoscopic radical prostatectomy. They found a significant impairment of sexual function by surgery with no difference between the laparoscopic or open approach (68). Additionally, the quality of erection should be classified according the international classification (E1-5) distinguishing between tumescence (E2-3) and rigidity (E4-5).

The methods of evaluation of sexual potency are also very heterogeneous including clinical interview by the surgeon, interview by another physician, or a self-administered questionnaire (Table 15). The additional use of oral, intraurethral, or intracorporeal therapy of erectile dysfunction, particularly in the early postoperative phase (i.e., intracorporeal injection therapy to expedite recovery of erection) makes it difficult to compare the various series. In laparoscopic radical prostatectomy with the

TABLE 15 ■ Laparoscopic versus Open Radical Prostatectomy—Recovery of Potency After Bilateral Preservation

Author (Ref.)	N	Mean age (yr)	Evaluation	Follow-up (mo)	Potency (%)
<i>Laparoscopic radical prostatectomy</i>					
Türk et al. (28)	58	60.2	Physician	12	38.5
Eden (57)	58	62.2	Physician	18	64.0
Salomon et al. (40)	17	63.8	Questionnaire	12	58.8
Roumeguere et al. (52)	26	62.5	Questionnaire	12	65.3
Artibani et al. (69)	9	64.3	Physician	6	55.5
Rassweiler (present series)	219	64.0	Questionnaire	12	61.0
<i>Open radical prostatectomy</i>					
Geary et al. (49)	69	64.1	Physician	18	31.2
Talcott et al. (59)	19	61.5	Questionnaire	12	79.0
Catalona et al. (59)	798	63.0	Physician	18	68.0
Huland et al. (62)	366	n.a.	Questionnaire	12	56.0
Stanford et al. (54)	1291	62.9	Questionnaire	18	44.0
Walsh 2000	64	57.0	Questionnaire	18	86.0
Roumeguere et al.	33	63.9	Questionnaire	12	54.5

Heilbronn technique, our results of erectile response during sexual intercourse with or without using intracavernosal injection in patients who underwent bilateral and unilateral nerve sparing are given in Table 16. Moreover, in contrast to urinary continence, spontaneous sexual potency is difficult to assess objectively (65). Rigiscan studies may provide insight into the organic basis of postradical prostatectomy erectile dysfunction, but are not yet a routine part of evaluation (71).

Follow-up again represents an important parameter in this evaluation. While a large number of series have demonstrated the possibility of late recovery, most studies are limited to a relatively short follow-up. There is a consensus that the assessment of recovery of sexual function requires a follow-up of at least 18 months (71). According to this, Litwin et al. (72) found little additional recovery in the sexual domains after 18–24 months. Although the nerves are optimally preserved during nerve-sparing surgery, they usually are damaged by direct trauma or by stretch injury during intraoperative retraction. This is reflected again by the study of Hara et al. (68), showing a significant impairment of sexual life by surgery without any difference between laparoscopy and open prostatectomy. These damaged nerves need time to heal. Restoration of the neuron occurs from the point of injury to the target organ at a rate of 1 mm per day.

Like for recovery of continence, several authors have published some technical steps that may improve the results of nerve-sparing surgery, such as the use of water-jet dissection, the early detachment of the neurovascular bundle before division of the urethra to avoid any traction on the neurovascular bundle or monopolar coagulation close to the bundles and the tip of the seminal vesicles, and the preservation of the accessory pudendal arteries (70,73–75).

Other factors influencing the operative results have also been considered: the quality of erections before surgery, patient's age, and the type of surgery. It is very important whether the surgeon is able to preserve both or only one neurovascular bundle. In our previously published review, we focused mainly on the results of bilateral nerve sparing (Table 15). The long-term outcome of sural nerve-grafting (which has also been realized laparoscopically) still remains an open question (70–73). All comparative analyses should also focus on the selection of patients (i.e., less than 65 years, potent, with sexual interest, low-stage, low-grade tumor) in the different series. Some authors postulate that nerve-sparing surgery should only be limited to patients aged less than 60 or even 55 years (76).

In summary, there are no significant differences between the laparoscopic or open approach concerning the recovery of potency (34–67% vs. 31–79%), if one excludes the selected series of Walsh with a mean age of 57 years (Table 15).

Again, laparoscopic surgery enables the transformation of all technical variations proposed for open radical prostatectomy, but despite all efforts could not yet significantly improve potency rates in comparison to open surgery. Conclusively, not the approach but the experience of the surgeon still remains one of the most essential factors to improve the recovery of potency. The cases of failed recovery of potency are mainly attributed to associated factors such as age or concomitant morbidity of the patient.

Early outcomes have indicated that once the learning curve is established, transperitoneal laparoscopic radical prostatectomy is at least equivalent to open radical prostatectomy in terms of early oncological outcomes continence and potency rates, and operation times.

In summary, there are no significant differences between the laparoscopic or open approach concerning the recovery of potency (34–67% vs. 31–79%), if one excludes the selected series of Walsh with a mean age of 57 years.

Early outcomes have indicated that once the learning curve is established, transperitoneal laparoscopic radical prostatectomy is at least equivalent to open radical prostatectomy in terms of early oncologic outcomes continence and potency rates, and operation times.

TABLE 16 ■ Erectile Response after Laparoscopic Radical Prostatectomy via the Heilbronn Technique

	Laparoscopic radical prostatectomy	
	Penetration +/- PDE5-inhibitor ^a	Penetration +/- CI ^b
Bilateral nerve-sparing (%)	27/41 (65.9)	33/41 (80.5)
Unilateral nerve-sparing (%)	19/43 (44.2)	25/43 (58.1)
No nerve-sparing (%)	14/135 (10.4)	53/135 (39.3)

^aPhosphodiesterase type V selective inhibitor.
^bIntracorporeal injection.

TRAINING

Training for Vascular Control and Reconstructive Parts of Laparoscopic Radical Prostatectomy

In spite of the increasing number of laparoscopic operations performed worldwide, the issue of how to teach and train laparoscopy has not been solved. In our opinion, today's residents should be exposed to standardized training programs in laparoscopy from the beginning of their residency so that they gain experience in laparoscopic surgery and open surgery both. Training by experienced laparoscopic surgeons will enable residents to deal with intraoperative complications laparoscopically without the need for conversion to open surgery. We believe that urologic surgeons who wish to practice laparoscopic surgery and who have not been exposed to laparoscopic surgery should get their training in a laparoscopic center. Because of the long learning curve, especially for reconstructive laparoscopy, this training period should be at least several months before being able to practice reconstructive laparoscopy. For this purpose, the standardized Heilbronn laparoscopic training program is described.

Training Program

In a closed pelvic trainer, six different models were used to simulate and exercise reconstructive procedures. In step I, we used a two-row construction of four pins. In each row the middle pins had ring heads, the lateral pins had L-shaped hooks. This model allowed to practice hand-eye coordination under two-dimensional vision. In steps II and III, suturing and knotting activities were performed using a chicken leg to imitate human tissue (the different incisions and positions of the chicken leg allowed practice in changing angles of the needle, as needed in intracorporeal suturing). A bone and soft tissue model (chicken leg) was used in step IV; the bone part made it necessary to pass the needle above the bone through the soft tissue in the fashion that the needle was used to perform the stitch ligating the Dorsal-vein complex. In step V, we used a tubular structure (20 Chr. silicone catheter) to exercise interrupted sutures at the edges in 3, 5, 6, 7, 9, and 11 o'clock positions. In step VI, a urethrovesical anastomosis was simulated in a porcine bladder model. The anastomosis was performed the same way as in our laparoscopic prostatectomy starting with the 6 o'clock stitch and continuing clockwise. The pelvic trainer was used in combination with a standard two-dimensional video technology. Suturing was performed with a needle holder and an endodissect using 3-0 Vicryl suture filaments (15 to 17 cm). Only curved needles were used (RB needles) in our operating room for performing the urethrovesical anastomosis.

We used a defined standard position of the instruments (distance between trocars 12 cm, intracorporeal instrument length 25 cm, angle between the instruments and the horizontal line 55 degrees, middle position of the object, middle camera position, diameter of 25 cm available for motion of the instruments, angle between the instruments <45 degrees) (77).

Definition of Task Goals

Expert laparoscopic surgeons in our hospital (defined as those who performed advanced laparoscopic procedures, i.e., pyeloplasty, radical prostatectomy, radical cystectomy, and retroperitoneal lymph node dissection), developed the various stages of the training program in order to define the expert level time for each stage. The average time of the results for each step were multiplied by the factor 2 and defined as task goals (double expert time) for the participants. Due to this, the time frames 3, 15, 15, 10, 20, and 30 minutes for step I, II, III, IV, V, and VI, respectively, have become the student's goal to reach before proceeding to the next stage.

Each training session time had to be recorded to calculate the needed time for reaching the expert level in each stage and for completing the entire program. As mentioned previously, the training program is planned to expose the participant gradually to more and more advanced tasks in laparoscopy. After reaching the expert skill level, which will be proved by a standardized test, they will be able to proceed to the next step until being able to participate in laparoscopic operations (Table 17).

Influence of the Program to Reconstructive Dexterity

A complete stitch contains two parts, the suturing part and the knotting part. Due to the two-dimension vision the inverted manipulation is the suturing part; especially the right positioning of the needle into the needle holder is a challenging procedure.

TABLE 17 ■ Model, Purpose of Each Step, and Required Time in Laparoscopic Training

	Model	Purpose	Time (min)
Step I	Two-row pin construction	Hand-eye coordination under two-dimensional vision passing a rubber band through the pins	3
Step II	Chicken leg: linear incision	Simple linear cutting, suturing, and knotting	15
Step III	Chicken leg: curved incision	Curved cutting, suturing (with changing angles of the needle) and knotting	15
Step IV	Chicken leg: dorsal-vein complex-simulation	Suturing with a pronation movement of the needle imitating the dorsal-vein complex stitch	10
Step V	Tubular structure	Circular suturing and knotting	20
Step VI	Porcine urethra	Urethrovesical anastomosis	30

Therefore, two parts of the program were examined more accurately concerning the influence of training to increase reconstructive capability.

Step IV (dorsal-vein complex simulation) and the 6 o'clock stitch (step V) were analyzed regarding the suturing and knotting parts. There was a significant decrease in total time required for a single stitch before and after the training. Training of reconstructive procedures decreased the total time by 55.7% for step IV (mean, 18 vs. 7.5 minutes) and by 52% for the 6 o'clock stitch (mean, 206 vs. 102.5 seconds). The mean time required for a single 6 o'clock stitch was 206 seconds before training and 102.5 seconds after training ($p \leq 0.05$). The same applied to the needed time to succeed step IV (before training 18 minutes and after finishing the program 7.5 minutes, $p \leq 0.05$).

The time for the suturing part (especially the ideal positioning of the needle) could be decreased in step IV by 72.2%, whereas the improvement of the knotting part was 34.3% (Fig. 1A and B). Accordingly, in the 6 o'clock stitch, the suturing part decreased by 66.3%, the knotting part only by 38.2% (78).


Our study (78) showed that, after passing the training program, all trainees decreased the time for succeeding each task compared to their baseline. Due to this, all participants were able to perform a safe urethrovesical anastomosis reproducible in less than 30 minutes at the end of the program. The mean time for reaching this level required 40 hours of practice. In this context, it might be interesting to note that the time for an urethrovesical anastomosis in the clinical setting (laparoscopic radical prostatectomy) ranges between 2 and 40 minutes.

Results of our study indicate that the especially challenging parts of reconstructive laparoscopy, such as intracorporeal suturing with the right angle of the needle in relation to the model and the needle holder, can be learned by using specially designed tasks.

This preclinical part of our training program is followed by clinical training in the operating rooms, including the first and second assistance and performing different parts of each laparoscopic procedure under supervision. This training runs at least three and up to 12 months.

Results of our study indicate that the especially challenging parts of reconstructive laparoscopy, such as intracorporeal suturing with the right angle of the needle in relation to the model and the needle holder, can be learned by using specially designed tasks.

FIGURE 1 ■ (A) Comparison of mean required time (separately for suturing and knotting) performing step IV (Dorsal-vein complex-simulation). Influence of training on suturing and knotting performance. (B) Comparison of mean required time (separately for suturing and knotting) performing the 6 o'clock stitch (step V). Influence of training on suturing and knotting performance.



SUMMARY

- The goals of laparoscopic radical prostatectomy, as in retropubic radical prostatectomy, are lifelong oncologic control of localized prostate carcinoma while minimizing operative morbidity, maintaining continence, and preserving potency.
- Laparoscopic radical prostatectomy has become a worldwide accepted alternative to open surgery.
- The indications for radical laparoscopic prostatectomy are the same as that for the open procedure including treatment of men with localized prostate carcinoma and life expectancy of 10 years or more.
- Compared to open surgery, the most relevant advantages of laparoscopic radical prostatectomy are decreased morbidity and shorter convalescence.
- The authors could not detect a significant difference when comparing the rate of positive margins after open or laparoscopic radical prostatectomy, either for pT2 or for pT3 stage tumors.
- Wide resection of the bladder neck and cutting the puboprostatic ligaments decreased bladder neck and apical positive margins (47). Nerve preservation does not increase the incidence of positive margins.
- Oncologic outcome after laparoscopic radical prostatectomy will not differ from open surgery. No specific oncologic risk such as port site metastases correlates to the laparoscopic technique.
- There are no significant differences between the laparoscopic and open approach either with respect to overall 12 months continence or regarding the three months continence.
- There are no significant differences between the laparoscopic and open approach as regards recovery of potency.
- Early outcomes have indicated that once the learning curve is established, transperitoneal laparoscopic radical prostatectomy is at least equivalent to open radical prostatectomy in terms of operation times, early oncologic outcomes, and continence and potency rates.

REFERENCES

1. Schuessler WW, Kavoussi LR, Clayman RV. Laparoscopic radical prostatectomy: initial case report [abstr 130]. *J Urol Suppl* 1992; 147:246A.
2. Schuessler WW, Schulam P, Clayman RV, Kavoussi LR. Laparoscopic radical prostatectomy: initial short-term experience. *Urology* 1997; 50:854.
3. Rabbay A, Ferzli G, Albert P. Initial experience with extraperitoneal endoscopic radical retropubic prostatectomy. *Urology* 1997; 50:849.
4. Kavoussi LR, Schuessler WW, Vancaille TG, Clayman RV. Laparoscopic approach to the seminal vesicle. *J Urol* 1993; 150:417.
5. Guillonnet B, Cathelineau X, Baret E, Rozet F, Vallancien G. Laparoscopic radical prostatectomy: technical and early oncological assessment of 40 operations. *Eur Urol* 1999; 36:14.
6. Abbou CC, Salomon L, Hoznek A, et al. Laparoscopic radical prostatectomy: preliminary results. *Urology* 2000; 55:630.
7. Guillonnet B, Vallancien G. Laparoscopic radical prostatectomy: the Montsouris experience. *J Urol* 2000; 163:418.
8. Rassweiler J, Sentker L, Seemann O, Hatzinger M, Stock C, Frede T. Heilbronn laparoscopic radical prostatectomy: technique and results after 100 cases. *Eur Urol* 2001; 40:54.
9. Bollens R, Vanden Bossche M, Rhoumeguere TH, et al. Extraperitoneal laparoscopic radical prostatectomy: results after 50 cases. *Eur Urol* 2001; 40:65.
10. Gaston: personnel communication.
11. De la Rosette JJ, Abbou CC, Rassweiler J, Laguna MP, Schulman CC. Laparoscopic radical prostatectomy: a European virus with global potentials. *Arch Esp Urol* 2002; 55:603.
12. Guillonnet B, Rozet F, Cathelineau X, et al. Perioperative complications of laparoscopic radical prostatectomy: the Montsouris 3-year experience. *J Urol* 2002; 167:51.
13. Guillonnet B, El-Fettouh H, Baumert H, et al. Laparoscopic radical prostatectomy: oncological evaluation after 1000 cases at Montsouris Institute. *J Urol* 2003; 169:1261.
14. Rassweiler J, Schulze M, Teber D, Seemann O, Frede T. Laparoscopic radical prostatectomy: functional and oncological outcomes. *Curr Opin Urol* 2004; 14:75.
15. See WA. Selection and preparation of the patients for laparoscopic surgery. In: Clayman RV, McDougall EM, eds. *Laparoscopic urology*. St. Louis: Quality Medical Publishing Inc., 1993:3.
16. Vallancien G, Gupta R, Cathelineau X, Baumert H, Rozet F. Initial results of salvage prostatectomy after radiation failure. *J Urol* 2003; 170:1838.
17. Myers RP. Practical surgical anatomy for radical prostatectomy. *Urol Clin North Am* 2001; 28:473.
18. Walsh PC. Anatomical radical retropubic prostatectomy. In: Walsh PC, Retik AB, Kavoussi LR, Wein AJ, eds. *Campbell's urology*. 8th ed. Philadelphia: W.B. Saunders, 2003.
19. Tewari A, Peabody JO, Fischer M, et al. An operative and anatomic study to help in nerve sparing during laparoscopic and robotic radical prostatectomy. *Eur Urol* 2003; 43:444.
20. Gill IS, Zippe CD. Laparoscopic radical prostatectomy: technique. *Urol Clin North Am* 2001; 28:423.
21. Rassweiler J, Sentker L, Seemann O, Hatzinger M, Rumpelt HJ. Laparoscopic radical prostatectomy with the Heilbronn technique: an analysis of the first 180 cases. *J Urol* 2001; 166:2101.

22. Jacob F, Salomon L, Hoznek A, et al. Laparoscopic radical prostatectomy: preliminary results. *Eur Urol* 2000; 37:615.
23. Abreu SC, Gill IS, Kaouk JH, et al. Laparoscopic radical prostatectomy: comparison of transperitoneal versus extraperitoneal approach [abstr 76]. *J Urol* 2002; 167:19.
24. Hoznek A, Antiphon P, Borkowski T, et al. Assessment of surgical technique and perioperative morbidity associated with extraperitoneal versus transperitoneal laparoscopic radical prostatectomy. *Urology* 2003; 61:617–662.
25. Cathelineau X, Cahill D, Widmer H, Rozet F, Baumert H, Vallacien G. Transperitoneal or extraperitoneal approach for laparoscopic radical prostatectomy: a false debate over a real challenge. *J Urol* 2004; 171:714.
26. Stolzenburg JU, Do M, Rabenalt R, et al. Endoscopic extraperitoneal radical prostatectomy: initial experience after 70 procedures. *J Urol* 2003; 169:2066.
27. Erdogru T, Teber D, Frede T, et al. Comparison of transperitoneal and extraperitoneal laparoscopic radical prostatectomy using match-pair analysis. *Eur Urol*, 2004. In press.
28. Türk I, Deger S, Winlelmann B, Schönberger B, Loening SA. Laparoscopic radical prostatectomy: technical aspects and experience with 125 cases. *Eur Urol* 2001; 40:46.
29. Rassweiler J, Seemann O, Hatziger M, Schulze M, Frede T. Technical evolution of laparoscopic radical prostatectomy after 450 cases. *J Endourol* 2003; 17:143.
30. Hoznek A, Salomon L, Rabii R, et al. Vesicourethral anastomosis during laparoscopic radical prostatectomy the running suture method. *J Endourol* 2000; 14:749.
31. Van Velthoven RF, Ahlering TE, Peltier A, Skarecky DW, Clayman RV. Technique for laparoscopic running urethrovesical anastomosis: the single knot method. *Urology* 2003; 61:699.
32. Hoznek A, Salomon L, Olsson LE, et al. Laparoscopic radical prostatectomy. The Cretiel experience. *Eur Urol* 2001; 40:38.
33. Dilliogluligil O, Leibman BD, Leibman NS, Kattan MW, Rosas AL, Scarno PT. Risk factors for complications and morbidity after radical retropubic prostatectomy. *J Urol* 1997; 157(5): 1760–1767.
34. Arai Y, Egawa S, Tobisu K, et al. Radical retropubic prostatectomy: time trends, morbidity and mortality in Japan. *BJU Int*. 2000;85(3):287–294.
35. Lepor H, Neder AM, Ferrandino MN. Intraoperative and postoperative complications of radical retropubic prostatectomy in a consecutive series of 1,000 cases. *J Urol* 2001;166(5):1729–1733.
36. Augustin H, Pummer K, Daghofer F, Habermann H, Primus G, Hubner G. Patient self-reporting questionnaire on urological morbidity and bother after radical prostatectomy. *Eur Urol* 2002; 42:112–117.
37. Rassweiler J, Seemann O, Schulze M, Teber D, Hatzinger M, Frede T. Laparoscopic versus open radical prostatectomy: a comparative study at a single institution. *J Urol* 2003; 169:1689.
38. Fromont G, Guillonneau B, Validire P, Vallancien G. Laparoscopic radical prostatectomy: preliminary pathologic evaluation. *Urology* 2002; 60:661.
39. El-Feel A, Davis JW, Deger S, et al. Positive margins after laparoscopic radical prostatectomy: a prospective study of 100 cases performed by 4 different surgeons. *Eur Urol* 2003; 43:622.
40. Salomon L, Anastasiadis AG, Levrel O, et al. Location of positive surgical margins after retropubic, perineal and laparoscopic radical prostatectomy for organ-confined prostate cancer. *Urology* 2003; 61:386.
41. Stamey TA, McNeal JE, Freiha FS, Redwine E. Morphometric and clinical studies in 68 consecutive radical prostatectomies. *J Urol* 1988; 139:1235.
42. Catalona WJ, Smith DS. Cancer recurrence and survival rates after anatomic radical retropubic prostatectomy for prostate cancer: intermediate-term results. *J Urol* 1998; 160:2428.
43. Marcovich R, Wojno KJ, Wie JT, Rubin MA, Montie JE, Sanda MG. Bladder neck-sparing modification of radical prostatectomy adversely affects surgical margins in pathologic T3a prostate cancer. *Urology* 2000; 55:904.
44. Han M, Partin AW, Pound CR, Epstein J, Walsh PC. Long-term biochemical disease-free and cancer specific survival following anatomic radical retropubic prostatectomy. *Urol Clin North Am* 2001; 28:555.
45. Hull GW, Rabbani F, Abbas F, Wheeler TM, Kattan MW, Scardino PT. Cancer control with radical prostatectomy alone in 1,000 consecutive patients. *J Urol* 2002; 167:528.
46. Brown JA, Gartlitz C, Gomella LG, et al. Pathologic comparison of laparoscopic versus open retropubic prostatectomy specimens. *Urology* 2003; 62:48.
47. Katz R, Salomon L, Hoznek A, de la Taille A, Antiphon P, Abbou CC. Positive surgical margins in laparoscopic radical prostatectomy: the impact of apical dissection, bladder neck remodeling and nerve preservation. *J Urol* 2003; 169:2049.
48. Rassweiler J, Tsivian A, Ravi Kumar AV, et al. Oncological safety of laparoscopic surgery for urological malignancies: experience with more than 1,000 operations. *J Urol* 2003; 169:2072.
49. Geary ES, Dendinger TE, Freiha FS, Stamey TA. Incontinence and vesical neck strictures following radical retropubic prostatectomy. *Urology* 1995; 45:1000.
50. Eastham JA, Kattan MW, Rogers E, et al. Risk factors for urinary incontinence after radical prostatectomy. *J Urol* 1996; 156:1707.
51. Eden CG, Cahill D, Vass JA, Adams TH, Dauleh MI. Laparoscopic radical prostatectomy: the initial UK series. *BJU Int* 2002;90(9):876–882.
52. Roumeguere T, Bollens R, Vanden Bossche M, Rochet D, Bialek D, Hoffman P, Quackels T, Damoun A, Wespes E, Schulman CC, Zlotta AR. Radical prostatectomy: a prospective comparison of oncological and functional results between open and laparoscopic approaches. *World J Urol* 2003; 20(6):360–366.
53. Catalona WJ, Carvalhal GF, Mager DE, Smith DS. Potency, continence and complication rates in 1,870 consecutive radical prostatectomies. *J Urol* 1999; 162:443.
54. Walsh PC, Marschke P, Ricker D, Burnett DM. Patient reported urinary continence and sexual function after anatomical radical prostatectomy. *Urology* 2000; 55:58–61.
55. Steiner MS. Continence-preserving anatomical radical retropubic prostatectomy. *Urology* 2000; 55:427.

56. Kao TC, Cruess DF, Garner D, Foley J, Seay T, Friendrichs P, Thrasher JB, Mooneyhan RD, McLeod DG, Moul JW. Multicenter patient self-reporting questionnaire on impotence, incontinence and stricture after radical prostatectomy. *J Urol* 2000;163(3):858-864.
58. Harris JL. Treatment of postprostatectomy urinary incontinence with behavioral methods. *Clin Nurse Spec*. 1997;11(4):159-466.
59. Talcott JA, Rieker P, Probert KJ, et al. Patient-reported impotence and incontinence after nerve-sparing radical prostatectomy. *J Natl Cancer Inst* 1997; 89:1117.
60. Wei JT, Montie JE. Comparison of patients' and physicians' rating of urinary incontinence following radical prostatectomy. *Semin Urol Oncol* 2000; 18:76.
61. Bates TS, Wright MJ, Gillatt DA. Prevalence and impact of incontinence and impotence following total prostatectomy assessed anonymously by the ICS-male questionnaire. *Eur Urol* 1998; 33:165-169.
62. Stanford JL, Feng Z, Hamilton AS, et al. Urinary and sexual function after radical prostatectomy for clinically localized prostate cancer: The prostate cancer outcome study. *JAMA* 2000; 283:354-360.
63. Heinzer H, Graefen M, Noldus J, Hammerer P, Huland H. Early complications of anatomical radical retropubic prostatectomy: lessons from a single-center experience. *Urol Int* 1997; 59:30.
64. Walsh PC. Radical prostatectomy for localized prostate cancer provides durable cancer control with excellent quality of life: a structured debate. *J Urol* 2000; 163:1802.
65. Vallancien G, Abbou CC, Ackermann R, et al. New surgical techniques in the treatment of prostate cancer. In: Denis L, Bartsch G, Khoury S, Murai M, Partin A, eds. *Prostate cancer, 3rd international consultation on prostate cancer*. Paris: Health Publications, 2003:127.
66. McCullough AR. Prevention and management of erectile dysfunction following radical prostatectomy. *Urol Clin North Am* 2001; 28:613.
67. Rosen RC, Cappelleri JC, Smith MD, Lipsky J, Pena BM. Development and evaluation of an abridged, 5-item version of the International Index of Erectile Function (IIEF-5) as a diagnostic tool for erectile dysfunction. *Int J Impotence Res* 1999; 11:319.
68. Hara I, Kawabata G, Miale H, et al. Comparison of quality of life following laparoscopic and open prostatectomy for prostate cancer. *J Urol* 2003; 169:2045.
69. Artibani W, Grosso G, Novara G, Pecoraro G, Sidoti O, Sarti A, Ficarra V. Is laparoscopic radical prostatectomy better than traditional retropubic radical prostatectomy? An analysis of peri-operative morbidity in two contemporary series in Italy. *Eur Urol* 2003; 44(4):401-406.
70. Huland H. Radical prostatectomy: options and issues. *Eur Urol* 2001; 39(suppl):1-3.
71. Sohn MH, Seeger U, Sikora R. Criteria for examiner-independent nocturnal penile tumescence and rigidity (NTPR): correlation to invasive diagnostic methods. *Int J Impotence Res* 1995; 5:59.
72. Litwin MS, Melmed GY, Nakazon T. Life after radical prostatectomy: a longitudinal study. *J Urol* 2001; 166:587.
73. Fernandez de la Maza S, Conrad S, Graefen M, Noldus J, Huland H. Early clinical experience with water-jet dissection (hydro-jet) during nerve-sparing radical retropubic prostatectomy. *Min Invas Ther Allied Technol* 2002; 11:257.
74. Katz R, Salomon L, Hoznek A, et al. Patient reported sexual function following laparoscopic radical prostatectomy. *J Urol* 2002; 168:2078.
75. Polascik T, Walsh PC. Radical retropubic prostatectomy: the influence of accessory pudendal arteries on the recovery of sexual function. *J Urol* 1995; 153:150.
76. Sokoloff MH, Brendler CB. Indications and contraindications for nerve-sparing radical prostatectomy. *Urol Clin North Am* 2001; 28:535.
77. Frede T, Stock C, Renner C, Budair Z, Abdel-Salam Y, Rassweiler J. Geometry of laparoscopic suturing and knotting techniques. *J Endourol* 1999; 13:191.
78. Teber D, Dekel Y, Frede T, Klein, Rassweiler Jens J. The Heilbronn laparoscopic training program for laparoscopic suturing: concept and validation. *J Endourol*, 2004. In press.

COMMENTARY

Guy Vallancien

Institut Montsouris, Université Pierre et Marie Curie, Paris, France

The paper presented by Jens Rassweiler and the group at Heilbronn is an excellent review on the state of the art of transperitoneal laparoscopic radical prostatectomy. The author gives accurate results of the different techniques for this procedure.

As Rassweiler highlights, it is difficult to provide an accurate measure of potency and successful sexual intercourse in this patient population. It is, indeed, impossible to compare results between academic groups. Accurate results of sexual function and urinary incontinence can only be obtained if an academic group evaluates another group's patient population by the International Continence Society questionnaire and the IIEF5 questionnaire. Furthermore, to help minimize any potential bias, only questionnaires filled in at the patient's home should be used to evaluate these outcomes. Nevertheless,

potency results are improving every year. These improvements are the result of both bilateral nerve sparing and oral phosphodiesterase-5 inhibitor therapy started a few days after surgery.

Laparoscopy, despite its technical difficulty, material investment, and longer operating times, provides patients with less pain and a rapid recovery. These are the reasons surgeons learn to be laparoscopists. In urology, we have no validated outcome measures to compare open versus laparoscopic prostatectomy. However, an excellent clinical observation can be made. With open surgery, our patients are unable to mobilize without a pillow on their abdomen and someone to help them. They cannot laugh or cough without pain. After laparoscopy, however, when you knock at the door, the patient gets up from his chair, and with a large smile comes to greet and congratulate you.

As for technical training, it is important that young surgeons understand that a laparoscopic prostatectomy should not be attempted after participating in a postgraduate course and watching the operation on video. Laparoscopic skills can only be acquired at a significant laparoscopic center where these procedures are performed on a daily basis. The young surgeon needs to practice for hours to master knot tying and suturing. These skills can be acquired on cadavers, animal models, or the pelvitrainer. Only then will he or she have the skills to operate successfully on patients. Furthermore, in my opinion, a successful laparoscopic prostatectomy requires only scissors, two graspers, two bipolars, and one aspirator. There is no need for additional instruments.

As for the future of urologic surgery, I expect within the next 10 years, most surgeries will be done laparoscopically. This movement will be driven by the next generation of urologists who have understood the benefits of laparoscopy and its future in urologic surgery and who are ready to make the commitment to excellent surgical training.

LAPAROSCOPIC RADICAL PROSTATECTOMY: EXTRAPERITONEAL TECHNIQUE

Clément-Claude Abbou, András Hoznek, Laurent Salomon,
Matthew T. Gettman, and Philippe Sebe

Service d'Urologie, Centre Hospitalier Universitaire Henri Mondor, Créteil, France

- INTRODUCTION
- OPERATIVE TECHNIQUE
 - Patient Positioning
- DISCUSSION
- CONCLUSION

- SUMMARY
- REFERENCES
- COMMENTARY: Renaud Bollens and Claude Schulman

INTRODUCTION

Following the pioneering work of Schuessler et al. (1), laparoscopic radical prostatectomy was propagated mainly using transperitoneal approach (2–4). Most laparoscopic centers, including ours, considered that primary access to the seminal vesicles was the key step of this technique (2–5). However, some concern has been voiced because this technique transformed a traditionally extraperitoneal procedure (open retropubic or perineal radical prostatectomy) into a transperitoneal one, with unique potential complications (6–8).

In 1997, Raboy et al., (9) described a modification of this procedure, the extraperitoneal approach, which was later developed by Bollens et al. (10,11).

Following Bollens et al.'s experience, we started performing laparoscopic radical prostatectomy in 1998 using the transperitoneal approach, and we switched to the extraperitoneal approach since 2002 (10,11). Other teams embarked in this approach since then (8,12).

Our preliminary results with extraperitoneal technique convinced us to further develop this approach, abandoning the transperitoneal technique (13). Between February 2002 and May 2004, we performed more than 300 laparoscopic radical prostatectomy via this extraperitoneal approach. Herein, we describe our standardized extraperitoneal laparoscopic radical prostatectomy step by step.

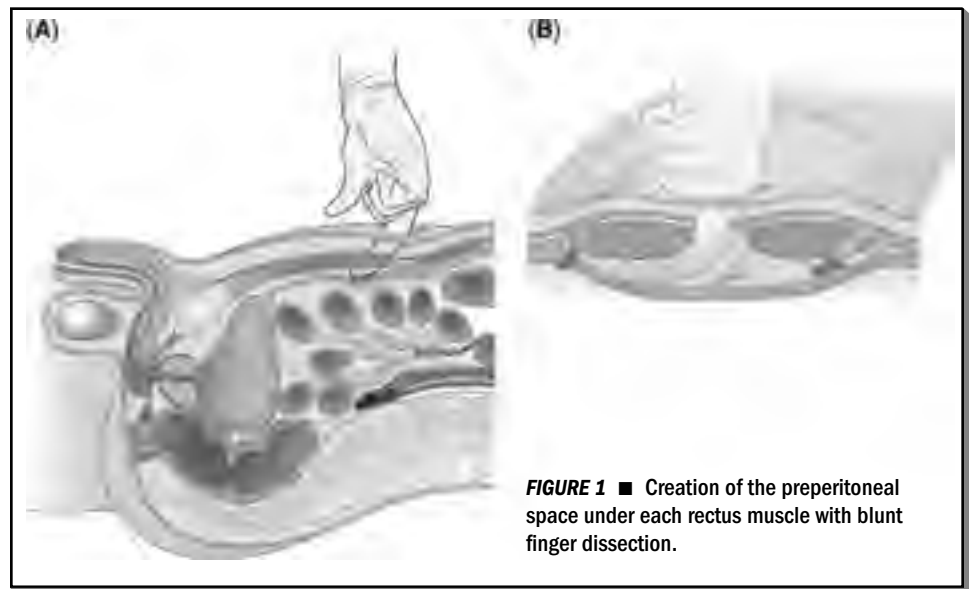
OPERATIVE TECHNIQUE

Patient Positioning

The patient is placed in dorsal decubitus with well-protected arms extended along the body. The legs are placed in a slight abduction to permit digital rectal examination during the procedure. After undergoing a standard iodine skin preparation, the patient is sterilely draped and a 20 French Foley catheter is inserted into the bladder. The surgeon stands on the left side of the patient and two assistants on the other side.

Step 1: Access to the Preperitoneal Space

A midline 3 cm incision is made transversally 1 cm inferior to the umbilicus. The subcutaneous tissue is divided down to the anterior rectus fascia. The anterior rectus fascia is then incised transversally to identify the inner borders of the rectus muscles separated by the linea alba. The index finger is introduced medially under the rectus muscle and along the posterior rectus sheath (Fig. 1). A blunt finger dissection is performed to create a space extending superiorly from the level of the skin incision to the lateral border of the rectus muscle. This space is limited caudally by the arcuate line of Douglas, posteriorly by the posterior rectus sheath, anteriorly by the posterior fibers of the rectus muscle and medially by the linea alba (Fig. 2). The same step is performed on the other side. At this stage, two spaces are created under each rectus muscle and separated by the linea alba.



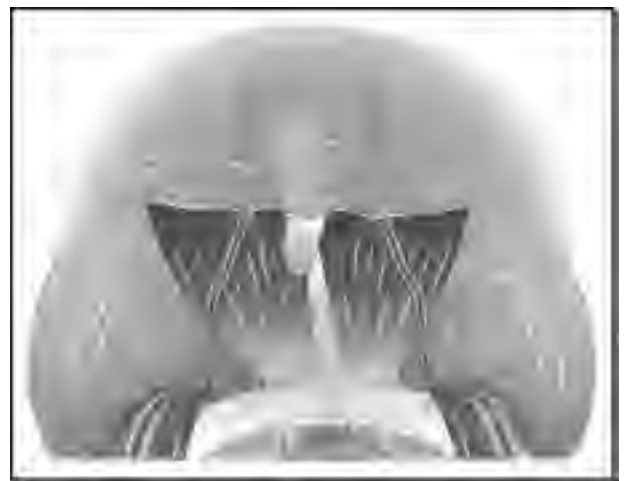The linea alba is then incised in contact with the anterior rectus fascia (Fig. 3). The disruption of linea alba is continued by the index finger as far as possible toward the symphysis pubis. At the end of the blunt finger dissection, a large preperitoneal space is created.

Step 2: Trocar Placement

Trocars No. 1 and No. 2 are inserted under digital guidance laterally to the rectus muscles (Fig. 4). A Hasson canula (Bluntport^{®a}) is inserted into the initial subumbilical incision and secured with stay sutures (trocar No. 3). Insufflation is initially performed at 18 mmHg. A conventional 0° laparoscope is placed in trocar No. 3.

Under laparoscopic vision, the incision of the linea alba is completed to the symphysis pubis. The Retzius space is opened and the prevesical space is developed laterally. The anterior aspect of the bladder, the pubic arch and the external iliac vessels are visualized. Development of the preperitoneal space is then performed laterally to the epigastric vessels, easily identified on the posterior aspect of the rectus muscles (Fig. 5). On both sides, the space is completed between the spermatic cord and the epigastric vessels in contact with the abdominal wall. The peritoneum is forced back. Under vision, trocars No. 4 and No. 5 are inserted in the iliac fossa 3 cm inside the anterior

FIGURE 2 ■ End of finger dissection: index finger can move in a large preperitoneal space.



^aU.S. Surgical Corp., Norwalk, CT.

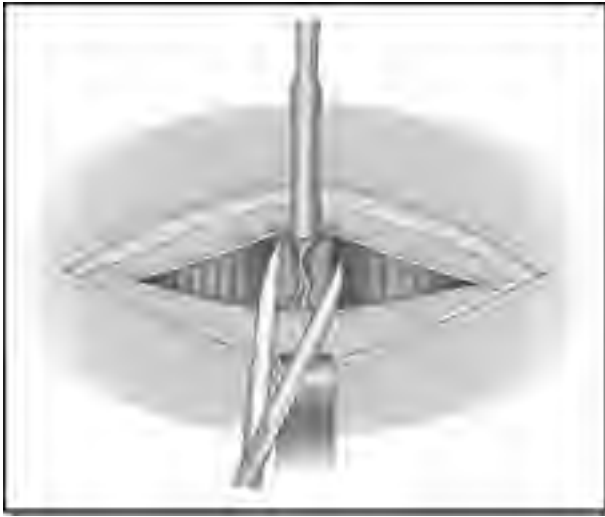


FIGURE 3 ■ Incision of linea alba in contact with the anterior rectus fascia.

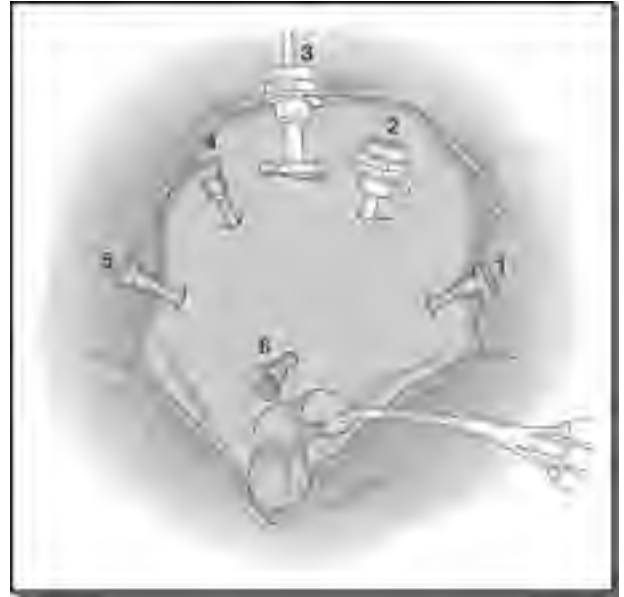
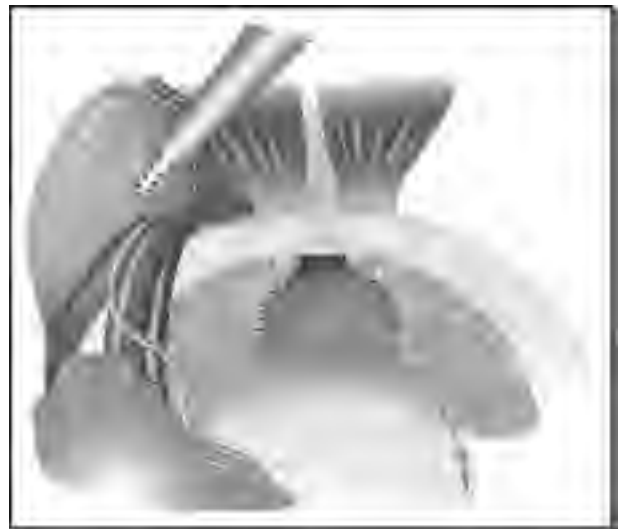

FIGURE 4 ■ Trocar positioning: No. 1, No. 4, No. 5, and No. 6: 5-mm trocars; No. 2: 12 mm (Versaport^{®b}); No. 3: 12-mm trocar (Bluntport).

superior iliac spine (Fig. 4). Insufflation pressure is lowered to 12 mmHg and table is set in a 20° Trendelenburg position.

The two previous steps, i.e., space creation and trocar insertion, can be performed more efficiently and quickly using the balloon-trocar. As such, the initial incision and the digital dissection between the rectus muscles and their posterior sheath are done the same way as described above. Then, the balloon-trocar is inserted on the left side; the tip of the trocar is directed toward the anterior superior iliac spine, and the balloon is inflated with approximately 3 L of air. Under laparoscopic control, the symphysis pubis, the epigastric vessels, and the spermatic cord are clearly seen. The same maneuver is repeated on the right side. Then, a 12-mm trocar is placed through the umbilical incision and the secondary trocars are inserted under laparoscopic control after insufflation.

FIGURE 5 ■ Development of the extraperitoneal space laterally to the epigastric vessels.



^bU.S. Surgical Corp., Norwalk, CT.

An accessory obturator vein is often found near the pubic arch, which may either be preserved or divided between hemostatic clips.

Step 3: Pelvic Lymph Node Dissection

Pelvic lymphadenectomy is performed if indicated. The technique is identical to pelvic lymphadenectomy performed during radical retropubic prostatectomy, with identical anatomical landmarks. The dissection of the inner border of the external iliac vein is bilaterally extended from the pubic arch to the vas deferens.

An accessory obturator vein is often found near the pubic arch, which may either be preserved or divided between hemostatic clips.

All tissues medial to the external iliac vein are dissected. The vein is then retracted laterally and dissection is completed to visualize the lateral wall of the pelvis. More posteriorly, the obturator nerve is exposed. The strip of lymph node tissue, starting distally with the lymph node of Cloquet is divided between clips in contact with the pubic arch. The lymphatic tissue with obturator nodes is then pulled upward with a locking grasper. The proximal dissection is performed as far as possible in order to include hypogastric nodes. An endoscopic bag is passed through trocar No. 2. The two specimens are placed in the bag and sent for frozen section analysis.

Step 4: Incision of the Endopelvic Fascia and Dissection of Santorini's Plexus

The fatty tissue is swept cephalad and lateral from the endopelvic fascia and from the anterior surface of the prostate. At this point, the superficial dorsal vein is coagulated and divided. On both sides, the endopelvic fascia is incised toward the puboprostatic ligaments laterally to its line of reflection. The levator muscle attachments are peeled off the prostate and the apical dissection is performed to identify Santorini's plexus. The puboprostatic ligaments are then divided in contact with pubic arch to facilitate dissection of the Santorini's plexus. The apical dissection is then started to identify the posterior limits of the plexus and the urethra.

Step 5: Transection and Preservation of the Bladder Neck

The bladder neck is identified by palpation of the supple bladder in comparison to the solid prostate. A second suture is passed and secured around the superficial tissue at the base of the prostate, and a long tail is left for retraction. A sixth trocar is inserted (Fig. 4) and a toothed grasper is placed on the stitch for upward traction of the bladder neck (Fig. 6). The anterior aspect of the bladder neck is incised at the limit between the muscular fibers of the detrusor and the prostatic capsule. When the bladder is opened, the catheter balloon is deflated, and the catheter pulled out through the opening. The grasper is now placed on the tip of the catheter. Counter traction is achieved by securing the catheter with a Kelly clamp placed just beyond the urethral meatus. In this manner, the assistant exposes the posterior edge of the prostate and the posterior bladder neck.

Transection of the bladder neck is completed. A locking grasper is placed on the posterior bladder neck, which is retracted cephalad, exposing the anterior layer of Denonvilliers' fascia (Fig. 7).

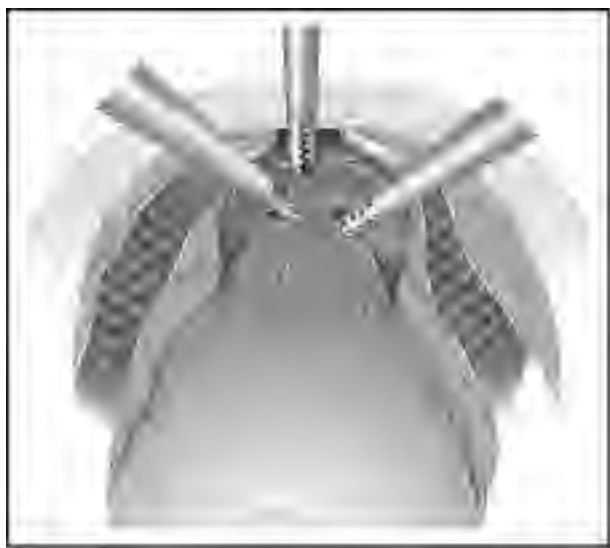


FIGURE 6 ■ Suspension of the base of the prostate and section of the anterior bladder neck.

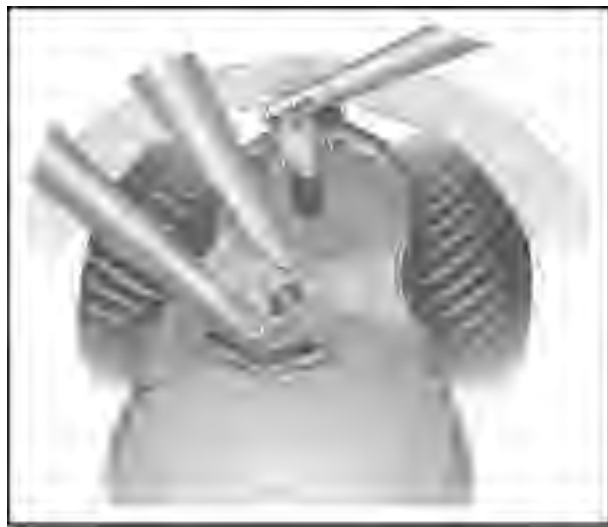

FIGURE 7 ■ Division of the posterior bladder neck from the anterior layer of Denonvilliers' fascia, which is incised transversally.

Step 6: Dissection of Seminal Vesicles

The anterior layer of the Denonvilliers' fascia is incised transversally to allow the visualization of the vasa deferentia (Fig. 7). The vasa deferentia are dissected, clipped, and divided. The vascular pedicle for each structure is selectively clipped and sectioned. After division of each vas deferens, upward traction on the distal portion of the vas allows exposure of the seminal vesicles. Two large arteries supplying each seminal vesicle from the lateral side are typically identified. These are clipped and divided in a position immediately adjacent to the seminal vesicles. As dissected, each seminal vesicle is grasped and pulled anteriorly (Fig. 8). With anterior traction on the seminal vesicles, the prostatic pedicles are exposed.

Step 7: Transection of Prostatic Pedicles and Preservation of Neurovascular Bundles

To optimize transection of prostatic pedicles and neurovascular bundle preservation, the visceral prostatic fascia and the lateral edge of the posterior Denonvilliers' fascia are incised in contact with prostatic capsule. Incision of the posterior layer of Denonvilliers' fascia reveals prerectal fat and provides a safe plane of dissection (Fig. 9). Hemostasis of prostatic pedicles is performed near the bundles with clips, and near the prostatic capsule with bipolar electrocautery. The plane between the neurovascular bundles and prostatic capsule is opened after transection of the pedicles. Small capsular arteries, which are divided in a position immediately adjacent to the prostatic capsule after being controlled with clips, are the last attachments of the bundles. Dissection is extended to the prostatic apex. The vasa deferentia and the seminal vesicles are grasped and retracted anteriorly. Incision of posterior Denonvilliers' fascia is completed medially and dissection of the prostatorectal plane is performed into the rectourethral muscle behind the prostate.

Step 8: Section of Santorini's Plexus and Section of Urethra

One assistant grasps and retracts the suture at the base of the prostate cephalad to put the apex on tension. The margin between the urethra and dorsal vein complex is identified and a figure-eight stitch is placed around the Santorini's plexus. The plexus is sectioned perpendicularly. The plane between the plexus and the urethra is then developed caudally in an oblique manner. The anterior urethral wall is incised and the Foley catheter is visualized (Fig. 10). The catheter is pushed through the anterior urethrotomy to open the urethral lumen and expose the posterior wall. The assistant retracts and rotates the prostate successively to each side and places the suction tip under the rectourethralis muscle and above the rectum. This maneuver allows a good exposure of the posterior lip of the prostatic apex, optimizing the section of posterior urethral wall and rectourethralis muscle and reducing the risk of positive posterior margins. After incising the urethra and the rectourethralis muscle, the freed prostate is placed in an endoscopic bag. The specimen is extracted through the slightly enlarged infraumbilical port site.

FIGURE 8 ■ Exposition of the prostatic pedicles.



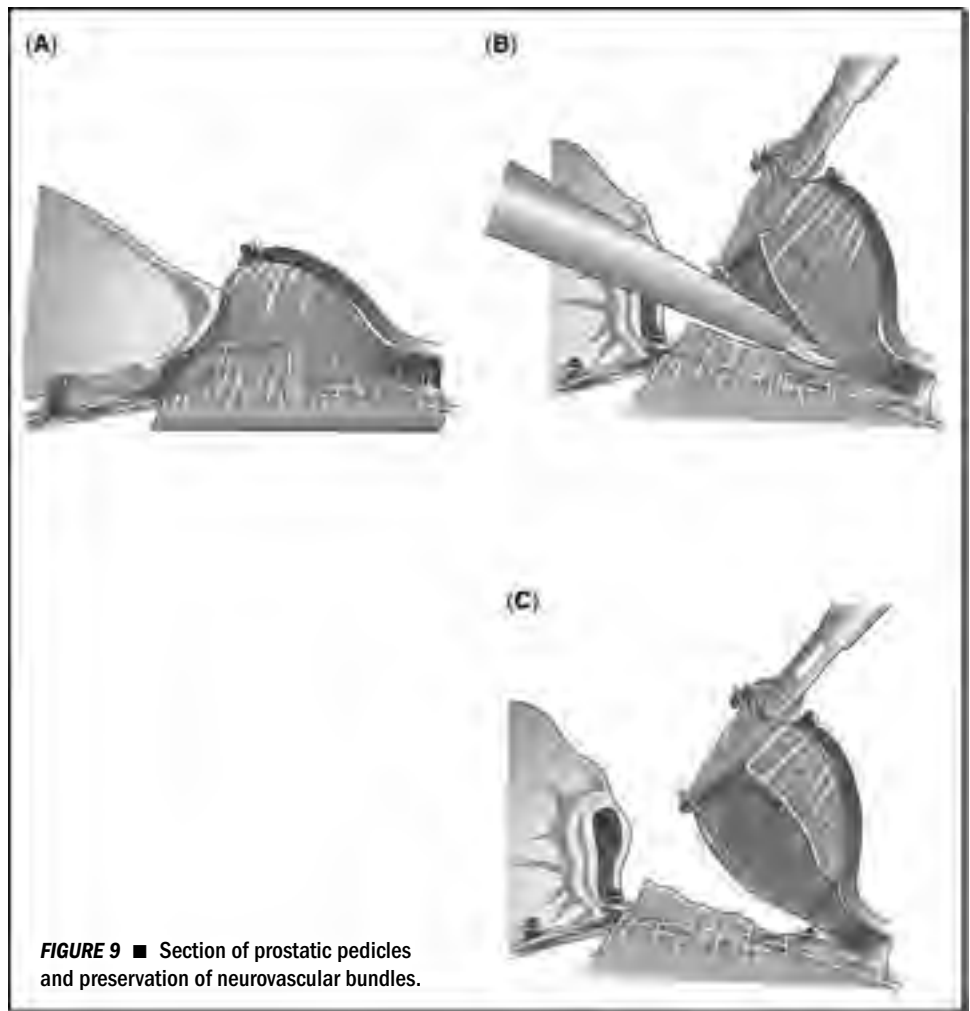


FIGURE 9 ■ Section of prostatic pedicles and preservation of neurovascular bundles.

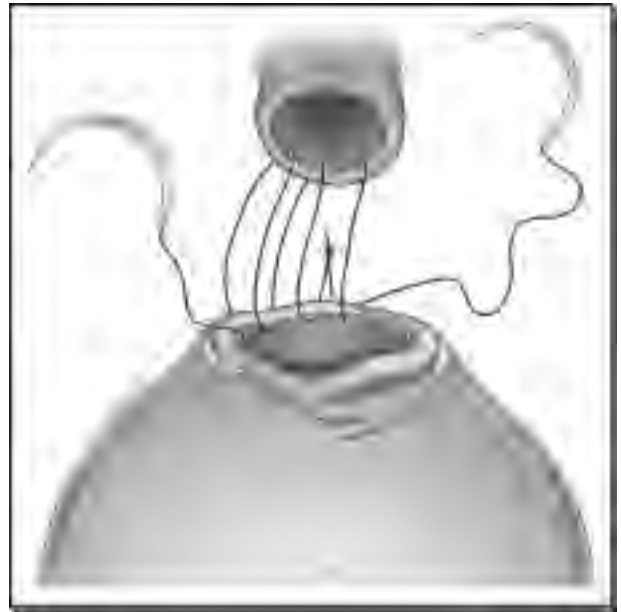
Step 9: Vesicourethral Reconstruction

The Hasson canula is replaced. A posterior tennis racket reconstruction may be necessary in case of associated large prostatic hyperplasia or previous transurethral resection of the prostate. The urethrovessical anastomosis is performed adopting the method originally described by Van Velthoven et al. (14). The running suture is prepared by knotting together two 3-0 Vicryl 5/8 sutures of a total length of 14 cm. The first running suture is initiated by placing a stitch outside in through the bladder neck and inside out on the urethra at the 4 o'clock position. Another needle is passed outside in through the bladder neck at the 3 o'clock position. The knot is blocked behind the bladder neck and the needle is

FIGURE 10 ■ Section of the urethra.



FIGURE 11 ■ Vesicourethral reconstruction: needle passages of the posterior anastomosis.



placed on the right side of the operative field. The other running suture is initiated by placing a stitch symmetrical to the first at the 5 o'clock position. The posterior lip of the bladder is left 2 cm apart from the urethral posterior wall. The posterior anastomosis is completed with four needle passages outside in on the bladder and inside out on the urethra, from the right to the left (Fig. 11). Upon completion of these passages, each suture is gently pulled on an alternating basis to approximate the bladder neck to the urethra. A Foley catheter is then placed into the bladder. The anterior anastomosis is then performed by placing the first suture outside in on the bladder and inside out on the urethra, from the right to the left. At the 10 o'clock position, the two running sutures are knotted on the outside of the bladder. Inadvertent inclusion of the Foley catheter into the anastomotic running suture should be ruled out prior to inflation of the balloon. Leakage from the urethrovesical anastomosis is ruled out by filling the bladder with 120 mL saline solution.

Step 10: Closure

A small suction drain is inserted through the left lateral port site and placed in the Retzius space near the anastomosis. The anterior rectus fascia is closed. Skin incisions are closed and sterile dressings are applied.

DISCUSSION

Development of laparoscopic radical prostatectomy started with the experience with transperitoneal laparoscopic access to the prostate and seminal vesicles employed by a few surgeons (2,5,15). In fact, transperitoneal laparoscopic radical prostatectomy was successfully introduced in routine clinical practice in France following the pioneering work of Gaston and Piéchaud in 1998 (unpublished series). This approach became predominant worldwide and is currently considered the gold standard of laparoscopic prostatectomy. However, other teams have shown that primary transperitoneal incision of the Douglas pouch is not essential for the dissection of seminal vesicles. Rassweiler et al. (4) proposed a technical alternative by approaching the Retzius space directly through a transperitoneal access and reproducing the retrograde technique described by Walsh. Raboy et al. performed the seminal dissection after transection of the bladder neck using a purely preperitoneal approach (9).

Creation of a preperitoneal working space was initially described to perform laparoscopic inguinal hernia repair (16). Later, access to the preperitoneal space has been used for many other laparoscopic procedures including pelvic lymph node dissection, bladder neck suspension, varicocelectomy, and more recently, radical prostatectomy (9,16).

The creation of a preperitoneal space is standardized and represents a minimally invasive approach to the prostate.

We developed a technique with initial blunt finger dissection, which is a fast, safe, and a less costly alternative to the balloon technique (16). Performing this dissection anterior to the posterior rectus sheath minimize the risk of inadvertent entry into the peritoneal cavity.

The creation of a preperitoneal space is standardized and represents a minimally invasive approach to the prostate.

Trocar geometry is similar to that previously described in transperitoneal laparoscopic radical prostatectomy but a sixth trocar can be introduced during initial space creation.

Prostate dissection is performed in a traditional anterograde fashion and allows preservation of the neurovascular bundles.

All crucial elements of our previously described transperitoneal technique of laparoscopic radical prostatectomy (17) are reproduced and only a few technical points have been modified since we switched to the extraperitoneal approach.

Trocar geometry is similar to that previously described in transperitoneal laparoscopic radical prostatectomy but a sixth trocar can be introduced during initial space creation. This 5-mm suprapubic trocar does not result in any additional morbidity but we have found it useful when mobilizing the prostate (Fig. 4).

Prostate dissection is performed in a traditional anterograde fashion and allows preservation of the neurovascular bundles. During this step, we prefer to use clips rather than any kind of thermal energy to achieve hemostasis.

Based on our favorable experience with vesicourethral reconstruction performed using two hemicircumferential running sutures (18), we recently adopted the technical modification proposed by Van Velthoven et al. (14). Such latter technique requires only one intracorporeal knot instead of three, and simplifies the control of the posterior half of the anastomosis since all the posterior stitches are placed prior to approximating the bladder neck to the urethra.

PURELY EXTRAPERITONEAL APPROACH

PROS

- Reduces risk of intraperitoneal injuries during laparoscopic access.
- Laparoscopic preperitoneal access renders bowel adhesions due to previous abdominal surgery a technical nonissues.
- Potentially decreased incidence of postoperative ileus and pain.

CONS

- Previous inguinal herniorrhaphy with mesh increase the complexity of prevesical space development. Pelvic lymphadenectomy is often impossible in these cases.
- Smaller working space.

Attempts to decrease operative time and perioperative morbidity should not outrival the oncologic principles.

In a comparison between extraperitoneal and transperitoneal laparoscopic radical prostatectomy at our center, measures of perioperative morbidity (postoperative pain, time to full diet) were more favorable when using the extraperitoneal technique (13). During transperitoneal laparoscopic radical prostatectomy, some urine and blood inevitably enter the peritoneal cavity, potentially causing at least some degree of chemical peritonitis. Persistent urine in the suction drain can be present for more than six days due to anastomotic leakage in 10% to 17.2% of patients (19–21). In transperitoneal laparoscopic series, prolonged ileus attributed to anastomotic leak was reported in 2.8% to 8.6% of cases (6,21). In another large series of transperitoneal laparoscopic radical prostatectomy, secondary anastomotic leakage in combination with acute pain, acute urinary retention, and peritoneal irritation syndrome occurred after catheter removal in 2% of patients (19). Ileus, anastomotic leak, and hemoperitoneum are all classified as group II by Clavien for laparoscopic surgery (19,22). Grade II complications are defined as “potentially life threatening but without residual disability.”

Establishing the complexity and technical difficulty of a surgical intervention is mostly a subjective exercise. However, indirect data suggest that, in certain institutions, the extraperitoneal approach may provide a simplification of laparoscopic prostatectomy. Currently, only a few studies comparing transperitoneal versus extraperitoneal laparoscopic radical prostatectomy are available in the literature (13,23).

The initial results of extraperitoneal laparoscopic radical prostatectomy in terms of oncologic cure and preservation of continence and potency are similar to those of transperitoneal laparoscopic radical prostatectomy (10,13,24). Extraperitoneal laparoscopic radical prostatectomy seems to be reproducible, with possibly a shorter operative time by 10 to 54 minutes (13,23,25). These advantages gain importance in an academic center like ours, especially because teaching laparoscopic radical prostatectomy is a complex process requiring a large number of cases (>50) to reach the plateau of learning curve (26). Nevertheless, attempts to decrease operative time and perioperative morbidity should not outrival the oncologic principles. To objectively determine the relative benefits of the transperitoneal and extraperitoneal approaches, a prospective comparison is awaited.

CONCLUSION

Laparoscopic radical prostatectomy is undergoing a continuous technical development. We consider the extraperitoneal approach the logical evolution of laparoscopic radical

prostatectomy because it combines the advantages of laparoscopic surgery and retropubic access and reduces operative time. We also believe that the extraperitoneal technique may shorten the learning curve of laparoscopic radical prostatectomy. Although well standardized, further evaluation of long-term results of this technique is necessary.

SUMMARY

- The creation of a preperitoneal space is standardized and represents a minimally invasive approach to prostate.
- Prostate dissection is performed in a traditional anterograde fashion and allows preservation of the neurovascular bundles.
- The extraperitoneal approach reduces risk of intraperitoneal injuries during laparoscopic access. It may also decrease incidence of postoperative ileus and pain.
- Previous inguinal herniorrhaphy with mesh increases the complexity of prevesical space development. Pelvic lymphadenectomy is often impossible in these cases.
- Attempts to decrease operative time and perioperative morbidity should not outrival the oncologic principles.
- Further evaluation of long-term results of this technique is necessary.

REFERENCES

1. Schuessler WW, Schulam PG, Clayman RV, et al. Laparoscopic radical prostatectomy: initial short-term experience. *Urology* 1997; 50:854.
2. Guillonnet B, Vallancien G. Laparoscopic radical prostatectomy: the Montsouris technique. *J Urol* 2000; 163:1643.
3. Abbou CC, Salomon L, Hoznek A, et al. Laparoscopic radical prostatectomy: preliminary results. *Urology* 2000; 55:630.
4. Rassweiler J, Sentker L, Seemann O, et al. Heilbronn laparoscopic radical prostatectomy: technique and results after 100 cases. *Eur Urol* 2001; 40:54.
5. Kavoussi LR, Schuessler WW, Vancailie TG, et al. Laparoscopic approach to the seminal vesicles. *J Urol* 1993; 150:417.
6. Dahl DM, L'esperance JO, Trainer AF, et al. Laparoscopic radical prostatectomy: initial 70 cases at a U.S. university medical center. *Urology* 2002; 60:859.
7. Dubernard P, Benchetrit S, Chaffange P, et al. Prostatectomie extra-péritonéale rétrograde laparoscopique (P.E.R.L.) avec dissection première des bandelettes vasculo-nerveuses érectiles. Technique simplifiée—à propos de 100 cas. *Prog Urol* 2003; 13:163.
8. Stolzenburg JU, Do M, Pfeiffer H, et al. The endoscopic extraperitoneal radical prostatectomy (EERPE): technique and initial experience. *World J Urol* 2002; 20:48.
9. Raboy A, Albert P, Ferzli G. Early experience with extraperitoneal endoscopic radical retropubic prostatectomy. *Surg Endosc* 1998; 12:1264.
10. Bollens R, Vanden Bossche M, Roumeguere T, et al. Extraperitoneal laparoscopic radical prostatectomy: results after 50 cases. *Eur Urol* 2001; 40:65.
11. Bollens R, Roumeguere T, Quackels T, Vanden Bossche M, Zlotta AR, Schulman CC. Extraperitoneal laparoscopic radical prostatectomy: Brussels technique. *Contemp Urol*. In press.
12. Cathelineau X, Cahill D, Widmer H, et al. Transperitoneal or extraperitoneal approach for laparoscopic radical prostatectomy: a false debate over a real challenge. *J Urol* 2004; 171:714.
13. Hoznek A, Antiphon P, Borkowski T, et al. Assessment of surgical technique and perioperative morbidity associated with extraperitoneal versus transperitoneal laparoscopic radical prostatectomy. *Urology* 2003; 61:617.
14. Van Velthoven RF, Ahlering TE, Peltier A, et al. Technique for laparoscopic running urethrovesical anastomosis: the single knot method. *Urology* 2003; 61:699.
15. Schuessler WW, Vancailie TG, Reich H, et al. Transperitoneal endoscopic lymphadenectomy in patients with localized prostate cancer. *J Urol* 1991; 145:988.
16. Sayad P, Ferzli G. The extraperitoneal approach and its utility. *Surg Endosc* 1999; 13:1168.
17. Hoznek A, Salomon L, Olsson LE, et al. Laparoscopic radical prostatectomy. The Creteil experience. *Eur Urol* 2001; 40:38.
18. Hoznek A, Salomon L, Rabii R, et al. Vesicourethral anastomosis during laparoscopic radical prostatectomy: the running suture method. *J Endourol* 2000; 14:749.
19. Guillonnet B, Rozet F, Cathelineau X, et al. Perioperative complications of laparoscopic radical prostatectomy: the Montsouris 3-year experience. *J Urol* 2002; 167:51.
20. Nadu A, Salomon L, Hoznek A, et al. Early removal of the catheter after laparoscopic radical prostatectomy. *J Urol* 2001; 166:1662.
21. Rassweiler J, Sentker L, Seemann O, et al. Laparoscopic radical prostatectomy with the heilbronn technique: an analysis of the first 180 cases. *J Urol* 2001; 166:2101.
22. Clavien PA, Sanabria JR, Strasberg SM. Proposed classification of complications of surgery with examples of utility in cholecystectomy. *Surgery* 1992; 111:518.
23. Abreu SC, Gill IS, Kaouk JH, et al. Laparoscopic radical prostatectomy: comparison of transperitoneal versus extraperitoneal approach. *J Urol* 2002; 167:19.

24. Stolzenburg JU, Truss MC, Do M, et al. Evolution of endoscopic extraperitoneal radical prostatectomy (EERPE)—technical improvements and development of a nerve-sparing, potency-preserving approach. *World J Urol* 2003; 21:147.
25. Bollens R, Roumeguere T, Vanden Bossche M, et al. Comparison of laparoscopic radical prostatectomy techniques. *Curr Urol Rep* 2002; 3:148.
26. Schulam PG, Link RE. Laparoscopic radical prostatectomy. *World J Urol* 2000; 18:278.

COMMENTARY

Renaud Bollens and Claude Schulman

Department of Urology, University Clinics of Brussels, Erasme Hospital, Brussels, Belgium

Laparoscopic radical prostatectomy is now an accepted management option for localized carcinoma of the prostate. Laparoscopic access to the prostate gland can be obtained by two distinct techniques. Historically, the transperitoneal approach was based on early identification and dissection of the vas deferens and then the seminal vesicles. This approach was widely adopted and led to the initial resurgence of interest in laparoscopic radical prostatectomy. Some surgeons had even claimed to replicate the open technique of Walsh by using the transperitoneal approach. However, the transperitoneal approach does not adhere to the basic laparoscopic principle of repeating the open procedure and so, respecting this, the extraperitoneal procedure has been developed. The first series to demonstrate this originated from our institution (1).

A number of different blind techniques have been reported to create the extraperitoneal space. We, however, prefer to develop the space of Retzius under laparoscopic vision; this minimizes the risk of peritoneal or vascular injury. To develop the working environment under visual control one needs to be familiar with the anatomy of the abdominal wall and, in particular, the areas where the peritoneum is least adherent to it. We have developed a number of maneuvers to aid in the safe development of the extraperitoneal working space under continuous vision.

Laparoscopic radical prostatectomy is still evolving, and this evolution, we hope, is leading to an improvement in outcome for the patient. The improvement of vision obtained through the use of a laparoscope should be directly translated into enhanced dissection and reconstruction, and so lead to better results. To this end, a number of groups have developed different reproducible techniques. In a manner analogous to Walsh's, we advocate the avoidance of energy sources whilst dissecting the neurovascular bundles, whether this is monopolar diathermy, bipolar diathermy, heat, or ultrasound. In addition to this, we believe it is also important to avoid traction on the neurovascular bundles and, in our experience, this leads to an improvement in the early return of potency.

Continence is mainly related to the technique of apical dissection. The preservation of a long urethral stump improves the immediate and early continence rate. To aid in this, we dissect the apex in two distinct stages: we first dissect the superficial periurethral tissue; this frees and aids in identification of the prostatic apex, and we then divide the urethra.

A number of methods have been described for the vesicourethral anastomosis; these include separate or running sutures, mucosal eversion or no mucosal eversion, preservation of the bladder neck, or reconstruction of the bladder neck. Each technique has its respective advantages and disadvantages, but no one technique has led to an improvement in the outcome.

Finally, we return to the initial question: which is the optimal technique for laparoscopic radical prostatectomy?

By limiting the surgical field to the extraperitoneum, one decreases the risk of bowel injury and prevents intraperitoneal hemorrhage without tamponade, and urine leakage, which may in turn lead to ileus, intraperitoneal adhesions, and even small bowel obstruction. As long as one creates the extraperitoneal space correctly, the volume of the working space is similar for both techniques. The published series do not prove the oncological or functional superiority of

either approach. Anecdotally, reduced Tredelenburg in the extraperitoneal approach may be an advantage for the anesthesiologist (decrease pressure of ventilation) but there is no literature to support this. The only outstanding concern is, does exposure of the peritoneal contents to a malignant prostate gland equate to peritoneal spillage? What will be the outcome of such patients if they relapse and develop hormone refractory disease in the future? By opening up a new body compartment we may potentially see a novel complication, e.g., peritoneal prostatic carcinomatosis. At present, the follow-up is too short to be certain that opening the peritoneum is safe.

Whatever the approach—open or laparoscopic, extraperitoneal or intraperitoneal—all of the technical refinements are striving for a common goal: to optimize the oncological and the functional outcomes of radical prostatectomy and so improve cancer-free survival, as well as aid in the early recovery of continence and potency.

REFERENCE

1. Bollens R, et al. *Eur Urol* 2001; 40:65.

ROBOTIC RADICAL PROSTATECTOMY: TECHNIQUE AND RESULTS

Melissa C. Fischer, James O. Peabody, and Mani Menon

Vattikuti Urology Institute, Henry Ford Health System, Detroit, Michigan, U.S.A.

Ashok K. Hemal

Department of Urology, All India Institute of Medical Sciences, New Delhi, India and Vattikuti Urology Institute, Henry Ford Health System, Detroit, Michigan, U.S.A.

<ul style="list-style-type: none"> ■ INTRODUCTION AND BACKGROUND ■ PATIENT SELECTION: INDICATIONS AND CONTRAINDICATIONS ■ PREOPERATIVE PREPARATION ■ DETAILED ROBOTIC PROSTATECTOMY TECHNIQUE <ul style="list-style-type: none"> Room Setup Surgical Team Equipment Positioning Port Placement Development of Extraperitoneal Space Apical Dissection and Control of Dorsal Venous Complex Bladder Neck Transection Dissection of Vasa Deferentia and Seminal Vesicles 	<ul style="list-style-type: none"> Control of Lateral Pedicles and Preservation of the Neurovascular Bundles Apical Dissection and Urethral Transection Pelvic Lymph Node Dissection Anastomosis Closing Postoperative Course ■ EXTRAPERITONEAL APPROACH FOR ROBOTIC RADICAL PROSTATECTOMY ■ SPECIFIC MEASURES TAKEN TO AVOID COMPLICATIONS ■ RESULTS ■ SUMMARY ■ REFERENCES ■ COMMENTARY: Guy Vallancien
--	---

INTRODUCTION AND BACKGROUND

In October 2000, the Vattikuti Urology Institute committed to apply minimal invasive surgical approaches toward radical prostatectomy. Initially, we performed laparoscopic prostatectomies based on the anatomic radical prostatectomy described by Walsh (1) and the Montsouris laparoscopic radical prostatectomy technique (2). Subsequently, we modified the operative approach to incorporate robotic technology using the da Vinci[®] surgical system^a starting in March 2001 (3) (Table 1). Robotic technology provides the surgeon with an unparalleled surgical tool, which offers three-dimensional, magnified visualization, wristed instrumentation and scaling of movement. As of July 2004, we have performed over 1200 robotic prostatectomies. Currently, many urology programs have established robotic programs and are routinely performing robotic prostatectomies (4–7). The initial technique has undergone numerous modifications (8,9).

PATIENT SELECTION: INDICATIONS AND CONTRAINDICATIONS

Any patient with clinically organ confined prostate cancer, who is a candidate for definitive therapy, should be considered for a robotic radical prostatectomy.

The only contraindications are; if the patient has certain medical problems that would preclude an elective laparoscopic procedure such as a bleeding disorder or severe chronic obstructive pulmonary disease. Furthermore, a history of stroke or cerebral aneurysm is a contraindication because of the prolonged, steep Trendelenburg position. Previous intra-abdominal surgery, including hernia repair with mesh, is not

Any patient with clinically organ-confined prostate cancer, who is a candidate for definitive therapy, should be considered for a robotic radical prostatectomy.

^aIntuitive Surgical, Sunnyvale, CA.

TABLE 1 ■ Vattikuti Institute of Prostatectomy Key Steps

Port placement
Development of the extraperitoneal space
Apical dissection and control of the dorsal venous complex
Bladder neck transection
Dissection of the vasa and seminal vesicles
Control of the lateral pedicles and preservation of the neurovascular pedicles
Apical dissection and urethral transection
Lymph node dissection
Anastomosis
Closing

a contraindication, but rather may be a good reason to consider the robotic approach. At our institution, approximately 30% of patients have had major intra-abdominal surgery, including a Whipple procedure and hemicolectomy, and none have required conversion to an open procedure. Also, a Vattikuti Institute of Prostatectomy has been performed on patients with previous abdominal radiation, as well as, salvage prostatectomies after external beam radiation therapy or radioactive seed implantation. Often patients require lysis of adhesions to varying degrees, either during or after port placement. An alternative surgical approach, such as an open or perineal prostatectomy, may be more appropriate for patients with multiple or extensive abdominal or pelvic surgeries.

While patient habitus is a consideration, morbid obesity is not a contraindication, but can make the dissection more challenging. We have performed the operation in patients with body mass indexes up to 39, but prefer patients with body mass indexes below 30. Furthermore, excessively large prostates are not prohibitive. Ideal prostate size ranges from 30 to 80 g; however, the Vattikuti Institute of Prostatectomy procedure has been successfully performed on glands greater than 200 g. A prominent median lobe or significantly enlarged lateral lobes will impact the bladder neck dissection but is not a contraindication. More importantly, if pelvic dimensions are small relative to the size of the prostate, then the dissection may be more difficult. It is exactly in these circumstances the robot provides excellent visualization in a narrow space and facilitates a more precise dissection.

PREOPERATIVE PREPARATION

Standard preoperative instructions are followed. Discontinuation of aspirin or other anticoagulants prior to surgery is mandatory. Patients are on a clear liquid diet for two days prior to surgery and perform a gentle bowel preparation with magnesium citrate the night before surgery. Preoperative medications include antibiotic prophylaxis (first generation cephalosporin) and deep venous thrombosis prophylaxis (subcutaneous heparin 5000 U). Sequential compression devices are placed on the lower extremities. An orogastric tube that is placed is removed prior to extubation. Also, anesthesia is instructed to avoid certain inhalants as with any laparoscopic procedure and to limit fluids to less than 600 cc until the anastomosis is performed to minimize urine in the field.

DETAILED ROBOTIC PROSTATECTOMY TECHNIQUE

Room Setup

In our operating purpose-designed room, there are two 5-by-6 foot screens, which project a three-dimensional image for the right-sided surgeon and left-sided assistant. The large screens also facilitate instruction for residents and visitors. The console surgeon may also easily view the screens during the operation.

In our experience, when the entire team has the benefit of viewing the same three-dimensional image, the precision of the assistants' movements is greatly increased, which ultimately improves the efficiency of the entire operation.

Surgical Team

The team consists of a primary surgeon who operates at the console and two additional personnel who are sterile at the patient's side. The right-sided surgeon should be a physician who is skilled in laparoscopy and facile in port placement and docking of the robot. The left-sided assistant may be a physician, nurse, or surgical assistant. Each assistant is responsible for exchanging the robotic instruments on his/her respective side. The operation can be performed with a single assistant who has moderate advanced laparoscopic skills and with a strong understanding of the operation (10). It has been our experience that observation and second assistance is crucial to a surgeon's understanding of the operation and greatly reduces the time needed to master the roles of first assistant and console surgeon. This training philosophy works especially well in the setting of a residency program and the development of a robotic program. Furthermore, as the level of experience of the entire team increases, so does the ease and efficiency of the operation.

In our experience, when the entire team has the benefit of viewing the same three-dimensional image, the precision of the assistants' movements is greatly increased, which ultimately improves the efficiency of the entire operation.

The *da Vinci* Surgical System is a master–slave robot system, which provides a magnified, three-dimensional image with wristed instrumentation.

Equipment

The *da Vinci*^b Surgical System is a master–slave robot system, which provides a magnified, three-dimensional image with wristed instrumentation.

The current system has four arms, one for the binocular endoscope and the other three for the articulated instruments.

For this procedure the following EndoWrist[®] robotic instruments are required:

- Long tip forceps
- Permanent cautery hook
- Bipolar cautery
- Round tip scissors
- Two needle drivers

More recently, the operation has been performed with just three robotic instruments:

- Bipolar Maryland tip graspers
- One needle driver
- Cautery scissors

Essentially, the bipolar Maryland tip grasper replaces the long tip forceps, bipolar cautery, and one needle driver, and the cautery scissors replaces the round tip scissors and the cautery hook. This will decrease the cost of disposables, but the anastomosis is slightly more cumbersome. Conventional laparoscopic instruments are used by the two assistants. The left-sided assistant uses an atraumatic grasper and manipulates the Foley when necessary. The right-sided surgeon uses an atraumatic grasper, scissors, a Surgiflex[®] WAVE XPTMc suction-irrigation system and a needle driver.

Positioning

The patient is placed in dorsal lithotomy position with his arms tucked to his side (Fig. 1). Care is taken to pad bony prominences. The shoulders are secured with foam pads, wide cloth tape and then Velcro[®] straps crisscrossed over the upper body. The table is placed in maximum Trendelenburg position and fully lowered. The legs are then lowered until the thighs are parallel to the floor. The patient is prepped from the subcostal margin to the groin, draped, and then an 18 French Foley catheter attached to a drainage bag is placed.

Port Placement

Pneumoperitoneum is established with a 120 mm Endopath[®]d pneumoneedle through a left lateral umbilical incision. The Carbob dioxide₂ insufflator is set to a maximal pressure of 15 mmHg. After adequate pneumoperitoneum is established, a 10/12 mm Endopath bladeless trocar is placed and the camera with the 30 degrees upward-looking lens is introduced. To optimize visualization, the lens should be warmed with hot water prior to insertion. Next, the right-sided 8 mm robotic port is typically placed approximately 1 to 2 cm below the umbilicus and equidistant from the anterior superior iliac spine and the midpoint of the inguinal ligament. A second 10/12 mm Endopath bladeless trocar is placed at least two finger breadths above the iliac crest and as far lateral as possible. Next, the left-sided 8 mm robotic port is placed in a symmetric position to the right. The left-sided 5 mm Endopath bladeless trocar is placed at least two finger breadths above the iliac crest and as far lateral as possible. The right-sided 5 mm assistant port is placed midway between the 12 mm camera port and the 8 mm robotic port and slightly inferior to allow the assistant's instruments to reach the pelvis.

A total of six ports are placed—a 10/12 mm camera port, 2 to 8 mm robotic ports, a 10/12 mm assistant port and 2 to 5 mm assistant ports (Fig. 2).

After port placement, the robot is docked.

Port placement can vary depending upon patient habitus and pelvic anatomy. The camera port may be placed infraumbilical or supraumbilical if the patient is greater than or less than 68 inches tall, respectively. If the patient has a narrow pelvis, the robotic ports can be placed more medially to minimize interference with the bony pelvis. Also,



FIGURE 1 ■ Patient positioning. Patient is in a modified dorsal lithotomy position in steep Trendelenburg.

A total of six ports are placed—a 10/12 mm camera port, 2 to 8 mm robotic ports, a 10/12 mm assistant port and 2 to 5 mm assistant ports.

^bIntuitive Surgical, Sunnyvale, CA.

^cACMI Corp., Southborough, MA.

^dEthicon, Cincinnati, OH.

if adhesions are present, the order of port placement may be varied to allow for laparoscopic release of adhesions.

Development of Extraperitoneal Space

Initially, the 30° upward-looking lens is used along with the cautery hook on the right and the long tip forceps on the left. First, the peritoneal cavity is inspected and any necessary lysis of adhesions is performed. Next, the dissection is started just lateral to the medial umbilical ligament over the vas deferens (Fig. 3). The vas deferens is isolated and divided, care is taken to cauterize the deferential vessel, which courses along the vas. The dissection is continued anteriorly; lateral to the medial umbilical ligament and just above the bladder dome, and inferiorly until the pubic arch and external iliac vein are visualized. The majority of this dissection can be performed bluntly in an avascular plane. Care should be taken to identify the iliac vessels that are just lateral to the plane of dissection. This step is repeated on the contralateral side. Next, the medial umbilical ligaments are divided with electrocautery and the dissection is continued medially from either side until the urachus is divided. The bladder is then reflected posteriorly. Overlying fat is dissected off the pubic arch, endopelvic fascia, puboprostatic ligaments, and the prostatic apex. Care is taken to cauterize the soft tissue in the midline between the puboprostatic ligaments that invariably contain the superficial dorsal vein.

Apical Dissection and Control of Dorsal Venous Complex

The lens is changed to 0°. The endopelvic fascia is scored and the space between the prostate and the levator ani is developed with blunt dissection. Cauterization should be minimized to avoid inadvertent injury to the neurovascular structures. The dissection is carried proximally until fat is seen at the junction of the prostate and bladder (Fig. 4). Distally, the dissection is carried just lateral to the puboprostatic ligaments that are left intact and just beyond the prostatic apex. Often the puboperinealis muscle is visible as a sling of muscle around the urethra just distal to the prostatic apex and care is taken to preserve this muscle (11). Next, the robotic instruments are changed to two needle drivers. A 6 to 9 0-Vicryl (polyglactin 910) suture on a CT-1 needle is used for a vertical mattress dorsal venous suture. The remainder of the suture is used for a prostatic traction suture placed just distal to the bladder neck.

Bladder Neck Transection

The lens is changed to 30° down and the cautery hook is on the right and long tip forceps on the left.

Determining the junction between the prostate and the bladder requires experience and is probably one of the most challenging aspects of this technique.

An assistant provides traction on the prostatic suture. Laterally, an area of fat is often seen at the junction between the prostate and the bladder. The dissection can be started laterally on either side and continued medially. The direction of the

Determining the junction between the prostate and the bladder requires experience and is probably one of the most challenging aspects of this technique.

FIGURE 2 ■ Port placement. Six ports are placed; 2 to 10/12 mm ports (A), the periumbilical port is for the camera, 2 to 8 mm robotic ports (B), and 2 to 5 mm assistant ports (C).

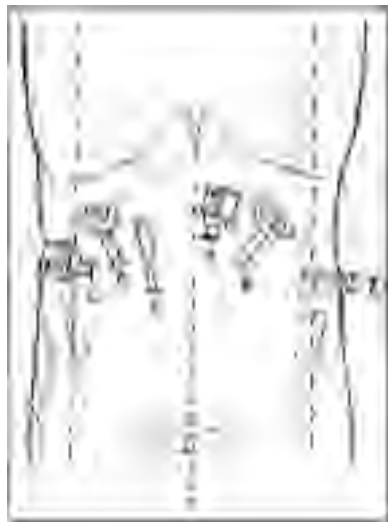



FIGURE 3 ■ Transperitoneal view. The bladder is reflected by incising the peritoneum just lateral to the medial umbilical ligament, dividing the vas deferens (arrowhead) and continuing the dissection across the midline and dividing the urachus (incision marked by dotted line). Care is taken not to injure the spermatic (arrow) or external iliac vessels.



dissection is angled slightly inferiorly and joined at the midline. If the surgeon is in the proper plane, the bleeding should be minimal. Once the anterior bladder is entered, the catheter balloon is deflated, and the second assistant uses the catheter to provide anterior traction. After the bladder is entered, the surgeon should visualize the ureteral orifices and assess for prominent prostatic lobes. If a prominent prostatic lobe is present, the mucosa over the adenoma is incised and dissected off the underlying adenoma.

The posterior bladder neck is divided, and the plane between the prostate and bladder is developed inferiorly and laterally. After the bladder neck dissection is performed, the bladder neck should be examined. If the bladder neck is excessively large, then bladder neck reconstruction may be performed. We have employed two techniques for bladder neck reconstruction. A figure of eight suture, usually a 2-0 Vicryl (polyglactin), RB-1 needle, may be placed at the lateral aspect of the bladder neck on either side prior to the anastomosis. Alternatively, if after the anastomosis is performed there is a gap anteriorly, a tennis racquet handle may be created.

Dissection of Vasa Deferentia and Seminal Vesicles

A plane is identified between the layers of Denonvillier's fascia, and the dissection is continued inferiorly in the midline. Often the vasa is easily visualized in the midline, but may be widely separated, especially with a significantly enlarged prostate (Fig. 5). The second assistant removes the catheter and grasps the posterior prostate and the edge of Denonvillier's fascia for traction facilitating dissection of the vasa. Each vas is dissected free from surrounding tissue then divided. The second assistant grasps the prostatic end and the first assistant grasps the proximal end. Adequate exposure allows the ipsilateral seminal vesicle to be dissected free from the surrounding tissue. After the vasa and seminal vesicles are isolated, the second assistant grasps both vasa and seminal vesicles and provides anterior and superior traction on the prostate. The dissection is then continued posteriorly in the midline between the layers of Denonvilliers' fascia as far distal as possible, usually to the level of the prostatic apex (Fig. 6). This step greatly facilitates the subsequent dissection of the neurovascular bundles and the apex.

Control of Lateral Pedicles and Preservation of the Neurovascular Bundles

This portion of the operation is typically performed with the bipolar cautery on the left and the scissors on the right, but the cautery hook and forceps can be used. An assistant provides contralateral traction by grasping either the ipsilateral seminal vesicle or the edge of the prostate (Fig. 7). The proximal pedicles are sharply dissected free from



FIGURE 4 ■ Endopelvic fascia dissection. After the endopelvic fascia is incised (*arrow indicating edge of fascia*), a space is developed lateral to the prostate until the prostatovesical junction and corresponding fat pad is identified (*double arrow*). Distally, the puboprostatic ligaments and superficial dorsal vein (*arrowhead*) are seen. After the dorsal vein suture is placed, a traction suture is placed on the prostate (*double arrowhead*).

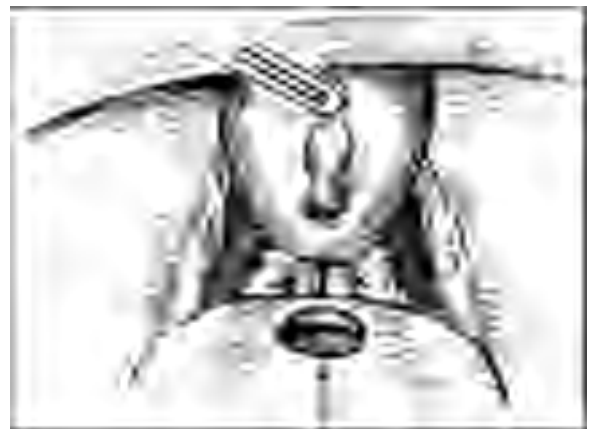

FIGURE 5 ■ Division of bladder neck. After dividing the bladder neck (*arrow*), the dissection is carried inferiorly, posterior to the prostate, until the vasa and seminal vesicles are identified.

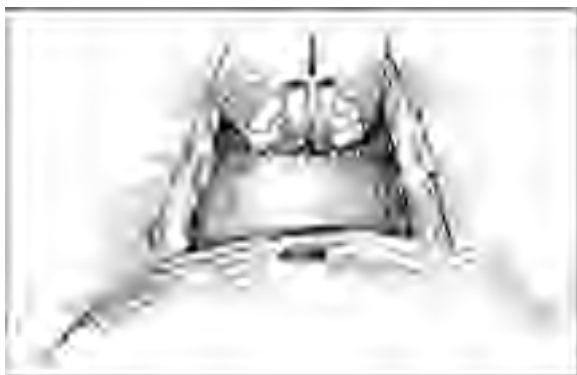

FIGURE 6 ■ Development of the plane posterior to the prostate toward the apex. The left-side assistant provides upward traction on the divided vasa and seminal vesicles (arrow).



FIGURE 7 ■ Lateral pedicle dissection. Contralateral traction is provided by an assistant. The pedicle may be divided with clips and scissors as shown. The plane of dissection varies depending on whether a standard nerve-sparing procedure or “veil” is performed.

surrounding tissue. Hem-O-Lok® MLK clips^e may be used for hemostasis. The majority of the dissection is performed sharply and bipolar is used for discrete bleeding.

For a standard nerve-sparing dissection, a plane is developed posterior and parallel to the prostate. At our institution, an additional accessory nerve preservation procedure is performed in which the main neurovascular bundle as well as perforating micropedicles are preserved. Patients who have excellent preoperative sexual function and minimal volume of Gleason less than seven disease are offered this procedure. A plane of dissection is developed posterolaterally between the layers of periprostatic fascia and is continued distally toward the puboprostatic ligament. A veil of tissue remains, the “veil of Aphrodite,” and encompasses the main neurovascular bundles and the perforating branches within the periprostatic fascia and is continuous with the puboprostatic ligament distally (Fig. 8) (12). Furthermore, in a given patient, a standard nerve sparing may be performed on one side and a veil performed on the other.

A meticulous apical dissection is crucial to excellent cancer control and maintenance of continence.

Apical Dissection and Urethral Transection

A meticulous apical dissection is crucial to excellent cancer control and maintenance of continence.

We have previously reported exclusively on this portion of the operation to highlight the advantages of robotic technology (13). The 0° lens is used for the apical dissection and the remainder of the operation. The bipolar cautery and scissors are used for the apical dissection. The Foley catheter is introduced. An assistant provides gentle traction by pulling the prostatic stay suture superiorly. The periurethral tissue is sharply separated from the urethra and the prostatic apex is defined. The urethra is divided sharply with scissors. Any remaining prostatic attachments are freed and the prostate is placed in an Endopouch™ Retriever^f to be removed later.

In our experience, and as reported by others, the most common location for a positive margin is the apex (14,15). Therefore, we routinely excise periapical soft tissue for frozen section analysis. If indicated, biopsies from other areas may be obtained at this time. If a biopsy contains carcinoma, then additional tissue is resected until a negative margin is obtained. Analysis of our results has shown that this procedure did not alter the already low (2–4%) positive apical margin rate in patients with organ confined prostate cancer, but did lower the positive margin rate in patients with pT3 disease from 30% to 11%. This may seem like “cheating” to the open surgeon or the traditional laparoscopist, but robotic surgeons realize that three-dimensional visualization and wristed instruments do allow them to remove a generous soft tissue margin around the urethra without sacrificing sphincteric length or compromising continence.

The technique of pelvic lymph node dissection is similar to laparoscopic pelvic lymph node dissection; however, the robotic instrumentation allows for a very precise anatomic dissection.

Pelvic Lymph Node Dissection

Pelvic lymph node dissection is usually performed at this time, if indicated. The instruments are unchanged from the previous step; 0° lens, bipolar cautery on the left and scissors on the right.

^eWeck Closure Systems, Research Triangle Park, NC.

^fEthicon, Cincinnati, OH.

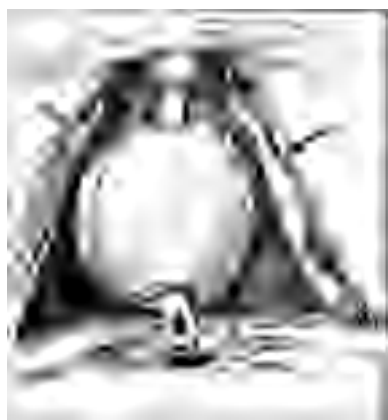

FIGURE 8 ■ Appearance of the prostate after the apex has been divided. Bilateral “veils of Aphrodite” (arrows) are preserved and are continuous with the puboprostatic ligaments.



FIGURE 9 ■ Anastomosis. A running anastomosis is performed with the initial pass outside in on the bladder neck and then inside out on the urethra (A). The posterior portion of the anastomosis is completed in a clockwise direction (B) then the anastomosis is completed by running the other end of the suture in a counterclockwise direction and tying an intracorporeal knot (C).

The technique of pelvic lymph node dissection is similar to laparoscopic pelvic lymph node dissection; however, the robotic instrumentation allows for a very precise anatomic dissection.

If necessary, an extended pelvic lymph node dissection is performed in the area of the obturator fossa, the internal and external iliac vessels, as well as, removal of the node of Cloquet. When a lymph node dissection is performed, the prostate and lymph nodes are placed in the same Endopouch Retriever.

Anastomosis

To begin the anastomosis, a needle driver is on the right and the long tip forceps on the left or two needle drivers may be used. In the beginning of our experience, the anastomosis was performed with eight or more interrupted sutures. A running anastomotic suture had been described for laparoscopic prostatectomy and was integrated into the Vattikuti Institute of Prostatectomy technique early in the evolution of the procedure (Fig. 9) (8,16,17). A running suture was found to be more efficient with excellent functional results. Presently, the anastomotic suture is made from two 7–8 cm 3-0 Monocryl (poligle-caprone 25) sutures on an RB-1 needle, dyed and undyed, tied together extracorporeally with the knot in the middle and a needle on either end. The running anastomosis is started with the dyed end, inside out on the bladder at the 4 o'clock position and continues in a clockwise direction. After two to three passes, the suture is cinched down with gentle downward traction on the bladder. After the bladder is brought down to the urethra, a needle driver is used on the left for the remainder of the anastomosis. The suture may be periodically locked to maintain tension or the right-sided surgeon may hold the suture on mild tension. At approximately the 9 o'clock position, the suture is reversed; inside to out on the bladder, outside to in on the urethra for two to three passes, then the second assistant holds the dyed needle on mild tension. Next, the undyed monocryl is passed outside in on the urethra at the 4 o'clock position and continued in a counterclockwise direction until the anastomosis is completed. The needles are removed and a single intracorporeal knot completes the anastomosis. A 20 French Foley catheter is placed, the bladder is distended to assess for anastomotic leaks, and 20 cc of saline is placed in the balloon.

Closing

The robotic instruments and camera are removed from the ports and the robot is dedocked. The first assistant places the camera through the lateral 12 mm port and grasps the endocatch string through the 12 mm umbilical port. Once the string is secured with a clamp, a 15 French Jackson-Pratt drain¹ is placed through the left-sided 5 mm port under visualization. Next, the ports are removed under direct vision to assess for bleeding and the umbilical port site is enlarged to allow removal of the specimen. The fascia is closed with 1-0 Ethibond™ on a CTX needle. The skin is closed with 4-0 Vicryl subcuticular sutures.

Postoperative Course

Patients are admitted for overnight observation and discharged within less than 23 or 24 hours after surgery.

Pain management includes ketorolac and acetaminophen with codeine. The pelvic drain is typically removed before discharge. A cystogram is usually performed on postoperative day 4–6, and if no leak is present, then the catheter is removed. Out-of-state

Patients are admitted for overnight observation and discharged within less than 23 or 24 hours after surgery.

patients may fly home within 48 hours and have their local urologist remove the catheter 10 to 14 days postoperatively.

EXTRAPERITONEAL APPROACH FOR ROBOTIC RADICAL PROSTATECTOMY

An extraperitoneal approach has been described for both laparoscopic and robotic prostatectomy (18–20). We have successfully performed 15 Vattikuti Institute of Prostatectomy's with an extraperitoneal approach. The extraperitoneal space is developed with a balloon dilator in the standard fashion. The ports are placed closer to the pelvic bones than with the transperitoneal approach, otherwise, the remainder of the procedure is identical to the previously described transperitoneal approach. An advantage of this approach is that some of the complications, which are seen with a transperitoneal approach, such as ileus from an anastomotic leak or postoperative bowel obstruction do not occur. The drawbacks are increased operating time (averaging 40 minutes additional per case) because of difficulty in creating the extraperitoneal working space and an increased incidence of lymphocele formation and deep venous thrombosis. For this reason, our preferred approach is transperitoneal for the vast majority of our patients.

SPECIFIC MEASURES TAKEN TO AVOID COMPLICATIONS

General laparoscopic principles should be adhered to regarding port placement and closure. This topic is covered elsewhere in this text. Excessive bleeding is a bothersome complication, not because of the amount of blood lost with regard to hemodynamic stability, but because even a small amount of bleeding obscures vision. Bleeding may be encountered at different steps of this procedure. Occasionally, when the endopelvic fascia is opened there is bleeding which can make the apical dissection more difficult. In such cases, a "cottonoid" Codman surgical strip may be placed on either side of the prostate. After the prostate has been removed, if there is bleeding in the area of the neurovascular bundles or prostatic fossa, a hemostatic sealant, such as, FloSeal® Matrix may be used prior to the anastomosis. Furthermore, additional dorsal venous complex sutures [2-0 Vicryl (polyglactin), RB-1 needle] may be placed after urethral transection, if necessary.

If there is concern regarding the integrity of the anastomosis, additional interrupted sutures [2-0 Monocryl (poliglecaprone) on an SH needle] may be placed to minimize anastomotic leaks. Furthermore, the bladder can be tacked to the pelvic sidewall to prevent tension on the anastomosis in the event of significant ileus or pelvic hematoma. Also, the peritoneum over the bladder can be sutured to the pubic arch in a running fashion to essentially extraperitonealize the retropubic space. We have tried all of these maneuvers and have concluded that they are not necessary in the vast majority of patients.

Postoperatively, if a patient has a significant ileus or abdominal pain, consider computerized tomography scan of the abdomen early in the evaluation. The vast majority of patients have minimal abdominal pain and a rapid recovery. If there is a deviation from the usual postoperative course, then an aggressive evaluation should be performed to exclude a hernia, urinary ascites, significant ileus, or pelvic hematoma.

RESULTS

Our institution has published prospective data regarding patient characteristics, preoperative parameters, and oncological and functional outcomes at various points during the development of our program (Table 2) (3,12,15,21–23). Our initial experience with robotic prostatectomy was reviewed after the first 40 cases were performed (3). The mean patient age was 60.7 and mean body mass index was 27.7. The mean operating time (incision to closure) was 4.6 hours, mean estimated blood loss 256 cc, and 80% of patients discharged within 24 hours after surgery.

Our robotic prostatectomy results and our laparoscopic prostatectomy results with experienced surgeons were comparable. However, estimated blood loss was significantly less in the robotic group.

Furthermore, Ahlering et al. has demonstrated that a laparoscopically naive, experienced open surgeon can successfully and efficiently perform a robotic prostatectomy after only 8 to 12 cases (24).

An interim evaluation of our technique prospectively compared our experience with 200 Vattikuti Institute of Prostatectomies to 100 radical retropubic prostatectomies (23).

Our robotic prostatectomy results and our laparoscopic prostatectomy results with experienced surgeons were comparable. However, estimated blood loss was significantly less in the robotic group.

TABLE 2 ■ Development of the Vattikuti Institute Prostatectomy: a Review of Experience Commensurate with the Evolution of the Technique

Number of patients	40 ^a (Ref. 3)	100 (Ref. 15)	First 200 (Ref. 21)	Last 200
Age (yrs)	61	60	60	57
BMI	28	28	28	28
Operating time (min)	274	195	160	150
Estimated blood loss (cc)	256	149	153	<100
Intraoperative transfusions (%)	0	0	0	0
Conversion (%)	0	0	0	0
Discharged in 23 hrs (%)	80	92	93	92
Complications (%)	5	6	5	3
Positive margin rate (%) (T2a-T3a)	18	12	6	9
Continence (% at 6 mos)	N/A	92	90	99 (at 4 wks)
Potency (% at 6 mos)	N/A	59	50	N/A ^b

^aThe Montsouris approach was performed on 33/40 patients.
^bPotency results are not available, as the follow-up is only 3 mos.
Abbreviation: BMI, body mass index.

In a review of 565 patients undergoing a Vattikuti Institute of Prostatectomy, there was no intraoperative mortality, no intraoperative blood transfusion and no conversion to open.

There was no difference between the two groups with regards to preoperative parameters. Our average Vattikuti Institute of Prostatectomy patient age was 60 years, mean body mass index was 27.7, mean preoperative prostate specific antigen level was 6.4 ng/mL, the two most common clinical stages were T1c and T2b (49% and 39%, respectively), and the most common Gleason scores were 6 and 7 (67% and 28%, respectively). The average operative time was 2.7 hours, similar to radical retropubic prostatectomies, and the mean estimated blood loss was 153 cc, which was significantly less than 910 cc with radical retropubic prostatectomies. Furthermore, there were no intraoperative transfusions with the Vattikuti Institute of Prostatectomy group and the mean postoperative pain score was significantly less (3/10 for Vattikuti Institute of prostatectomies and 7/10 for radical retropubic prostatectomies). Postoperatively, the average hospital stay was 1.2 days compared to 3.5 days with a radical retropubic prostatectomies. Ninety-three percent of Vattikuti Institute of Prostatectomy patients were discharged within 23 hours after surgery.

In a review of 565 patients undergoing a Vattikuti Institute of Prostatectomy, there was no intraoperative mortality, no intraoperative blood transfusion and no conversion to open (12).

Postoperative anemia requiring transfusion occurred in four patients, two for port site hematoma and two for pelvic hematoma. There were 21 unanticipated postoperative office visits after catheter removal for transient urinary retention (15), dysuria (4) or hematuria (2). At 12 months follow-up, nine bladder neck contractures and one meatal stenosis were identified. Prolonged ileus is a bothersome complication of the transperitoneal approach; five patients had an ileus lasting for greater than 24 hours. Deep vein thrombosis was noted in one patient and two patients incurred a bowel injury during lysis of adhesions.

The Vattikuti Institute of Prostatectomy technique allows for early catheter removal with excellent results. A cystogram is routinely performed on postoperative day 4–7, and if the study is negative for urinary extravasation, then the catheter is removed. Our review demonstrated that average duration of catheterization is seven days (23). Total continence was achieved in 96% of patients at six months follow-up with a mean time to continence of 42 days (12).

Postoperative sexual function has been assessed with third-party-validated questionnaires in 565 Vattikuti Institute of Prostatectomy patients (12). A total of 82% of preoperatively potent patients younger than 60 years old had return of some sexual activity and 64% had successful intercourse at six months follow-up. Of patients over the age of 60, 75% had some sexual activity and 38% had intercourse at six months follow-up. Preservation of the lateral prostatic fascia along with the posterolateral neurovascular bundle might preserve additional accessory nerves and better preserve the vascular supply to the nerves. This maneuver (the veil of Aphrodite) is difficult to perform with open or conventional laparoscopic surgery, but is relatively straightforward with robotic surgery. A follow-up was conducted by an independent third-party of 33 patients one year after surgery with a preoperative sexual function (sexual health inventory for men) score of 20 or higher. Twenty-two patients had undergone standard

nerve preservation and 11 patients had preservation of the lateral periprostatic fascia (veil of Aphrodite). Seven (32%) patients who underwent standard bilateral nerve sparing and nine (82%) in whom the veil of Aphrodite was preserved bilaterally reported one year sexual health inventory for men scores of 20 or greater ($p < 0.05$). While the sample size is notably small, we are encouraged that the return of potency and the quality of erections were superior in the cohort of patients undergoing the veil of Aphrodite modification of the Vattikuti Institute of Prostatectomy. We continue to perform a veil on appropriate patients and will continue to monitor and report our results.

With regard to oncological outcomes in an interim review of 200 patients, the margin positivity in organ-confined cancers (T2a–T3a) was 6% of whom 5% had focal positive margins and 1% had nonfocal extension (23). A total of 92% of patients had an undetectable prostate specific antigen with an average follow-up of 556 days. As there is variation in pathologists' assessment of positive margins, an independent pathologist, Jonathan Epstein, reviewed the pathologic specimens of 102 patients undergoing Vattikuti Institute of Prostatectomy by a single surgeon (MM). In this series, 60% of the patients had Gleason greater than six tumors and 40% had T3 disease. The positive margin rate was 5% in patients with T2 disease and 11% in patients with T3 disease. Two patients had a detectable prostate specific antigen of less than 0.2 at 12 months, one of whom had a preoperative prostate specific antigen of 25 and probable undetected metastasis preoperatively.

Over 1200 Vattikuti Institute prostatectomies have been performed to date and the procedure continues to be in evolution as minor modifications are introduced in an attempt to improve results and reduce complications. With experience, the average operating time is currently 2.3 hours, demonstrating a marked reduction from our initial experience. We continue to meticulously collect and analyze data to understand the impact of such modifications and to share our experience with fellow urologists.

SUMMARY

- Robotic technology provides the urologist with an unparalleled surgical tool, which can be applied to urologic oncology.
- The three-dimensional visualization and wristed instrumentation facilitates a more precise anatomic dissection of the prostate from surrounding tissues.
- Robotic-assisted radical prostatectomy, as described herein, is an efficient and reproducible technique with minimal morbidity and excellent results.

REFERENCES

1. Walsh PC. Anatomic radical prostatectomy: evolution of the surgical technique. *J Urol* 1998; 160 (6 Pt 2):2418.
2. Guillonnet B, Vallancien G. Laparoscopic radical prostatectomy: the Montsouris technique. *J Urol* 2000; 163:1643.
3. Menon M, Shrivastava A, Tewari A, et al. Laparoscopic and robot assisted radical prostatectomy: establishment of a structured program and preliminary results. *J Urol* 2002; 168:945.
4. Abbou C, Hoznek A, Salomon L, et al. Laparoscopic radical prostatectomy with a remote controlled robot. *J Urol* 2001; 165:1964.
5. Bents W, Wolfram M, Jones J, Brautigam R, Kramer W, Binder J. Robotic technology and the translation of open radical prostatectomy to laparoscopy: the early Frankfurt experience with robotic radical prostatectomy and one year follow-up. *Eur Urol* 2003; 44:175.
6. Binder J, Kramer W. Robotically-assisted laparoscopic radical prostatectomy. *BJU Int* 2001; 87:408.
7. Webster T, Herrell S III, Baumgartner R, Anderson L, Smith J. Robotic assisted laparoscopic prostatectomy versus radical retropubic prostatectomy: assessment of perioperative pain. *J Urol* 2004; 171(4 suppl):44.
8. Tewari A, Peabody J, Sarle R, et al. Technique of da Vinci robot-assisted anatomic radical prostatectomy. *Urology* 2002; 60:569.
9. Menon M, Tewari A, Peabody J, Members of the VIP team. Vattikuti Institute of Prostatectomy: technique. *J Urol* 2003; 169:2289.
10. Lee D, Eichler L, Skarecky D, Ahlering T. Robotic laparoscopic radical prostatectomy with a single assistant. *Urology* 2004; 63:1172.
11. Myers R, Cahill D, Kay P, et al. Puboperinealis: muscular boundaries of the male urogenital hiatus in 3D from magnetic resonance imaging. *J Urol* 2000; 164:1412.
12. Menon M, Tewari A, Peabody JO, Shrivastava A, Kaul S, Bhandari AK. Vattikuti Institute of Prostatectomy (VIP): a technique of robotic radical prostatectomy for management of localized carcinoma of the prostate. Experience of over 1100 cases. *Urol Clin North Am* 2004; 31:701.
13. Menon M, Hemal A, Tewari A, Shrivastava A, Bhandari A. The technique of apical dissection of the prostate and urethrovaginal anastomosis in robotic radical prostatectomy. *BJU Int* 2004; 93:715.
14. Epstein J. Incidence and significance of positive margins in radical prostatectomy specimens. *Urol Clin North Am* 1996; 23:651.

15. Menon M, Shrivastava A, Sarle R, Hemal A, Tewari A. Vattikuti Institute of Prostatectomy: a single-team experience of 100 cases. *J Endourol* 2003; 17(9):785.
16. Van Velthoven R, Ahlering T, Peltier A, Skarecky D, Clayman R. Technique for laparoscopic running urethrovesical anastomosis: the single knot method. *Urology* 2003; 61(4):699.
17. Nadu A, Salomon L, Hoznek A, et al. Early removal of the catheter after laparoscopic radical prostatectomy. *J Urol* 2001; 166:1662.
18. Hoznek A, Antiphon P, Borkowski T, et al. Assessment of surgical technique and perioperative morbidity associated with extraperitoneal versus transperitoneal laparoscopic radical prostatectomy. *Urology* 2003; 61(3):617.
19. Gettman M, Hoznek A, Salomon L, et al. Laparoscopic radical prostatectomy: description of the extraperitoneal approach using the da Vinci robotic system. *J Urol* 2003; 170(2 Pt 1):416.
20. Wolfram M, Brautigam R, Engl T, et al. Robotic-assisted laparoscopic radical prostatectomy: the Frankfurt technique. *World J Urol* 2003; 21(3):128.
21. Menon M, Tewari A, Members of the Vattikuti Institute of Prostatectomy team: Robotic radical prostatectomy and the Vattikuti Urology Institute technique: an interim analysis of results and technical points. *Urology* 2003; 61(suppl 4A):15.
22. Menon M, Tewari A, Baize B, Guillonneau B, Vallancien G. Prospective comparison of radical retropubic prostatectomy and robot-assisted anatomic prostatectomy: the Vattikuti Urology Institute experience. *Urology* 2002; 60(5):864.
23. Tewari A, Shrivastava A, Menon M, Members of the VIP team. A prospective comparison of radical retropubic and robot-assisted prostatectomy: experience in one institution. *BJU Int* 2003; 92:205.
24. Ahlering T, Skarecky D, Lee D, Clayman R. Successful transfer of open surgical skills to a laparoscopic environment using a robotic interface: initial experience with laparoscopic radical prostatectomy. *J Urol* 2003; 170:1738.

COMMENTARY

Guy Vallancien

Institut Montsouris, Université Pierre et Marie Curie, Paris, France

The positive experience in robotic laparoscopy, presented by the Detroit group, demonstrates the evolution of surgical telemanipulation systems to benefit the surgeon. For instance, during laparoscopic radical prostatectomy, the reanastomosis of the bladder neck to the urethra occurs at the end of the surgery. At this point, the surgeon is often tired, and it becomes more challenging to execute intracorporeal sutures. The execution of these sutures, however, is facilitated by the telemanipulation arms of the robot. The robotic arms provide six degrees of freedom, which allows an enormous flexibility in the "wristed arms." This flexibility allows the surgeon to place his needle in virtually any position, without the usual attention required in needle placement in the needle driver. Laparoscopic surgery, furthermore, can be physically exhausting when the surgeon stands next to the operating table for long periods of time. With the robot sitting at the control console, comfort is increased. One can extend this thought by stating that a more comfortable surgeon may execute a better operation. Nevertheless, robot-assisted laparoscopic prostatectomy does not provide any additional benefit to the patient. When comparing traditional laparoscopic prostatectomy to robot-assisted laparoscopic prostatectomy, a tour center, the only significant difference is a greater blood loss with robotic assistance.

What is the future of telemanipulation? I do not believe that teletransmission will be viable in a center where there is not a large volume of cases. Clearly, to acquire such equipment, the center must already be an important referral center with resources available to acquire current technology. Nevertheless, there is a growing interest in robot-assisted surgery, and this interest is attributable to two main reasons:

1. To train young surgeons in surgery and to expose them to difficult cases. As an analogy, the cockpit simulator of an Airbus A320 is extremely realistic. The most dangerous situations are programmed into the computer; and young pilots are trained through simulated events. Similarly, young surgeons will soon be able to learn operations and practise them multiple times, without operating on living patients.
2. The concept of the industrial revolution in medicine. In the future, laparoscopic prostatectomies can be performed in a large operating room of 250 m², equipped with four robots. At the Institut Mutualiste Montsouris, we have a

laparoscopic prostatectomy training program for scrub nurses. Currently, we do laparoscopic prostatectomies with only a scrub nurse at the operating table. This nurse prepares the patient, handles the robotic instruments, and assists the surgeon with the suction and forceps. At Montsouris, our resident controls the robot and the staff surgeon observes the operation. Our vision is to have four trained laparoscopic nurses and four residents, in this specialized setting, performing laparoscopic prostatectomies simultaneously. One staff surgeon would visit each console or, even with a fifth console, help the residents when required, for instance, in the dissection of the neurovascular bundles or the prostatic apex or in completing a difficult anastomosis. Such an evolution may also minimize long-term costs, because only one anesthetist and circulating nurse would be required for all four operations. Thus, technology has shifted the era of the surgeon as artist to the era of industrial surgery.

LAPAROSCOPIC RADICAL PROSTATECTOMY: CURRENT STATUS

**Karim A. Touijer, Edouard Trabulsi, and
Bertrand Guillonnet**

*Department of Urology, Sidney Kimmel Center for Prostate and Urologic Cancers,
Memorial Sloan-Kettering Cancer Center, New York, New York, U.S.A.*

- | | |
|---|--|
| <ul style="list-style-type: none"> ■ INTRODUCTION <ul style="list-style-type: none"> History Theoretical Advantages ■ TECHNIQUE <ul style="list-style-type: none"> Evolution of Techniques ■ PERIOPERATIVE PARAMETERS <ul style="list-style-type: none"> Operative Time Estimated Blood Loss Hospital Stay and Duration of Catheterization Convalescence Complications ■ CANCER CONTROL ■ FUNCTIONAL RESULTS <ul style="list-style-type: none"> Continence Potency | <ul style="list-style-type: none"> ■ NEW INNOVATIONS IN LAPAROSCOPIC PROSTATE SURGERY ■ PERSONAL EXPERIENCE OF THE SENIOR AUTHOR (B. G.): THE LESSONS LEARNED <ul style="list-style-type: none"> The Laparoscopic Approach in General Steps in Neurovascular Bundle Preservation Accessory Pudendal Arteries Control of the Dorsal Vascular Complex Dissection of the Apex Analyzing the Specimen ■ SUMMARY ■ REFERENCES ■ COMMENTARY: Robert P. Myers |
|---|--|

Since its first description 12 years ago, laparoscopic radical prostatectomy has gained increasing importance in the laparoscopic urologic oncology field and became an established treatment for organ-confined prostate cancer.

INTRODUCTION

History

Since its first description 12 years ago (1), laparoscopic radical prostatectomy has gained increasing importance in the laparoscopic urologic oncology field and became an established treatment for organ-confined prostate cancer.

With their pioneering efforts, the French teams from Paris refined the technique of laparoscopic radical prostatectomy and reduced it to an efficient and reproducible treatment (2–4). More recently, large series of laparoscopic radical prostatectomy from Germany, Belgium, Japan, United Kingdom, United States, and Italy have been published (5–12). The cumulative worldwide-published experience exceeds 2000 procedures and includes some surgical technique variations.

Theoretical Advantages

The major impetus driving the development of minimally invasive techniques for prostate cancer has been patient satisfaction and quality of life: shorter convalescence with quicker return to normal activity and shorter use of a Foley catheter are attractive goals to be achieved by laparoscopic radical prostatectomy.

Additional potential benefits of laparoscopic radical prostatectomy include a relatively decreased intraoperative blood loss and risk of transfusion, allowed by the tamponade effect of the pneumoperitoneum and the versatile visualization. The 12 to 15 times magnification afforded by laparoscopy allows a precise visualization of intraoperative anatomic details, which could be valuable in all the steps of the surgery. However, the lack of tactile sensation advocated as a useful aid in the assessment of induration, palpable nodules, and delineation of the proximity or involvement of the neurovascular bundles by cancer is an area of concern with laparoscopic radical prostatectomy.

TECHNIQUE

Evolution of Techniques

The initial report of laparoscopic radical prostatectomy by Schuessler et al. (1) was of nine cases performed through an intraperitoneal approach in an antegrade fashion. Shortly, thereafter, a single case of a laparoscopic radical prostatectomy through an extraperitoneal approach was reported (13). The largest initial series, however, originated in France, led first by Guillonnet and Vallancien at the Montsouris Institute in Paris, and then by Abbou in Créteil (2–4,14–18). More recently, the use of robotic devices to assist with the laparoscopic radical prostatectomy has been described (19,20).

Intraperitoneal Approach

Schuessler's initial report described an intraperitoneal approach, with the surgeon first dissecting the vasa deferentia and seminal vesicles through the pouch of Douglas, and proceeding in an antegrade fashion (1). After Schuessler's description, the Montsouris technique, also using an intraperitoneal approach, was initially described in 1998 (14). The vesicular complex is dissected first, and then the bladder is dissected off the anterior abdominal wall allowing access to the Retzius space. The endopelvic fascia is opened and the dorsal venous complex is ligated. The bladder neck is then incised at the prostatovesical junction and the previously dissected seminal vesicles are exposed. After control of the lateral pedicle of the prostate, the neurovascular bundle preservation is performed from the base towards the apex. Finally, the urethra is transected and an interrupted urethrovesical anastomosis using 8–12 sutures is performed.

Extraperitoneal Approach

Concerns of potential intraperitoneal complications (bowel injury, uroperitonitis, and ileus) led investigators to develop extraperitoneal approaches to laparoscopic radical prostatectomy (7). The initial report, by Raboy et al. (13), described a single extraperitoneal laparoscopic radical prostatectomy that duplicated the open retropubic radical prostatectomy as described by Walsh and Donker (21). Subsequent reports from Belgium and Germany have demonstrated the feasibility of the antegrade extraperitoneal approach (7,22–24). First the bladder neck is incised, the vasa deferentia and seminal vesicles are dissected through the bladder, and dissection is taken distally toward the apex of the prostate.

The theoretical advantages are the absence of peritoneotomy and therefore lesser risk of bowel injury, peritoneal irritation, and a quicker development of the Retzius' space. However, the drawbacks are a reduced and less ergonomic working space and a potential for increased tension at the urethrovesical anastomosis due to the limited bladder mobilization. Additionally, the extraperitoneal approach does not provide an accurate dissection of the seminal vesicles, which given the proximity of the neurovascular bundles and inferior hypogastric plexus may be relevant if a nerve sparing approach is planned.

Comparison of Approaches

Transperitoneal and extraperitoneal laparoscopic radical prostatectomy were compared by Hoznek et al. (25). In this retrospective study, the last 20 patients receiving transperitoneal laparoscopic radical prostatectomy were compared with the first 20 patients undergoing extraperitoneal laparoscopic radical prostatectomy. The operative time for extraperitoneal laparoscopic radical prostatectomy was significantly shorter (2.9 vs. 3.8 hours, $P < 0.001$), and resumption of a regular diet was significantly quicker (mean 1.6 vs. 2.6 days, $P = 0.002$). The duration of catheterization (4.2 vs. 5.3 days) and positive margin rates (25% vs. 15%) were similar between the two groups. Because of the preliminary nature of this paper, long-term cancer control rates and quality of life measures (potency, urinary continence) were not available. The authors concluded that the shorter operative time and the equivalent or superior morbidity and convalescence results indicated a significant advantage of the extraperitoneal technique over the transperitoneal technique.

A recent, retrospective study analyzing 100 consecutive extraperitoneal laparoscopic radical prostatectomy and 100 consecutive transperitoneal laparoscopic radical prostatectomy at the Montsouris Institute showed no significant differences in operative time (2.8 vs. 2.9 hours), transfusion rate (3% vs. 4%), or positive surgical margin rate (21% vs. 15%) between the two groups. The authors highlighted the importance of the individual surgeon's training and experience in determining the optimal technique to use (26).

A recent, retrospective study analyzing 100 consecutive extraperitoneal laparoscopic radical prostatectomy and 100 consecutive transperitoneal laparoscopic radical prostatectomy at the Montsouris Institute showed no significant differences in operative time (2.8 vs. 2.9 hours), transfusion rate (3% vs. 4%), or positive surgical margin rate (21% vs. 15%) between the two groups. The authors highlighted the importance of the individual surgeon's training and experience in determining the optimal technique to use.

Robotic Assistance

Use of robotics in laparoscopy has been spurred by the commercial availability of master–slave robotic devices such as the *da Vinci*^{®a} surgical robot. These devices have articulating instruments, which afford extra planes of motion that is particularly attractive for urologists with limited laparoscopic surgical skills (20,27–30). Additional reported benefits include improved ergonomics for the operating surgeon, who sits at a computer console separate from the operative field (31). It has been postulated that robotic assistance reduces the technical difficulty and potentially allows novice laparoscopists to complete these procedures (32). Use of the *da Vinci* robotic system has been reported with both transperitoneal and extraperitoneal approaches, with similar results (31,33).

One of the major limitations to the use of robotic devices in prostate surgery is the cost (34). The *da Vinci* surgical robot requires a tremendous capital investment, and the laparoscopic instruments used by the master–slave robot have preprogrammed senescence so that they can be used for only a finite number of procedures before they must be replaced. Additionally, the annual maintenance and per-case disposable instruments costs limit the widespread implementation of such device.

Other criticisms include the inadequacy of the available surgical instruments used in robotic-assisted laparoscopic radical prostatectomy, the loss of the sense of touch or tissue resistance feedback available with conventional laparoscopy, and finally the time-consuming set-up process.

Learning Curve

Laparoscopic radical prostatectomy is generally thought of as a technically demanding laparoscopic procedure, with an extended learning curve. Laparoscopic radical prostatectomy can be learned during residency or fellowship training, and other formats have been explored for the practicing urologist. Training laboratories, with laparoscopic skills trainers and ex vivo models of the urethrovesical anastomosis, have enabled urologists to improve their skills in a short time period (35). On-site mentoring by experienced laparoscopists has created successful laparoscopic radical prostatectomy programs in the United States (31,36). Proficiency and/or “learning curve” cannot be assessed by parameters such as number of cases or operating time. One does not become a skilled laparoscopic surgeon by completing case number 49 nor by performing a laparoscopic radical prostatectomy under 120 minutes, but a dedicated teaching program including laboratory training time, intraoperative video review, and operative participation, is essential to develop laparoscopic skills (depth perception, visual three-dimensional reconstruction of a two-dimensional image, etc.) and most importantly to master laparoscopic anatomy and apply the oncological principles of surgery.

PERIOPERATIVE PARAMETERS

Operative Time

As shown in Table 1, the average operative time has declined substantially with increased experience.

The average operative time from Montsouris, the center with the largest reported experience of laparoscopic radical prostatectomy, declined from more than four hours for the first 100 cases to 2.9 hours for the last 350 cases (17). Similarly, Hoznek et al. (18) reported that the operative time averaged over eight hours for their first 20 cases and declined to four hours for the next 114 cases. Other reports worldwide describe similar declines in operating times after the initial experience. Pelvic lymphadenectomy, which at most centers is performed only in selected, high-risk patients, appears to add 30–60 minutes to the operative times in most series. In our contemporary series from Memorial Sloan-Kettering Cancer Center, the average operative time is 3.3 hours with bilateral pelvic lymph node dissection in performed in 45% of the patients.

Estimated Blood Loss

The average estimated blood loss for the reported series of laparoscopic radical prostatectomy varies widely, as shown in Table 1. The average estimated blood loss in the series from Montsouris was 380 mL for all 550 patients, declining to 290 mL for the last 350 patients (17). The overall transfusion rate was 5.3% in this series, declining to 2.6%

One of the major limitations to the use of robotic devices in prostate surgery is the cost. The *da Vinci*[®] surgical robot requires a tremendous capital investment, and the laparoscopic instruments used by the master–slave robot have preprogrammed senescence so that they can be used for only a finite number of procedures before they must be replaced. Additionally, the annual maintenance and per-case disposable instruments costs limit the widespread implementation of such device.

As shown in Table 1, the average operative time has declined substantially with increased experience.

^a Intuitive, Sunnyvale, CA.

TABLE 1 ■ Summary of Surgical Parameters of Laparoscopic Radical Prostatectomy Experiences Worldwide

Center (Ref.)	No. of patients	Year	Surgical approach	Mean OR time (min)	EBL (mL)	Transfusion rate	Conversion rate	Hospital stay (days)	Catheter duration (days)	Rectal injury	Overall complication rate
San Antonio (1)	9	1997	TP	564 (all)	583	Not reported	0%	7.3	Not reported	0%	33%
New York (13)	1	1997	EP	345	600	0%	0%	2.5	14	0%	0%
Créteil (18)	134	2001	TP	Last 114:240	Not reported	3%	0%	Last 124:6.1	Last 124:4.8	1.5%	9%
Berlin (5)	125	2001	TP	265	185	2%	0%	8	12	2.4%	14%
Brussels (7)	50	2001	42 EP, 8 TP	317	First 10:1350; last 10:492	13%	2%	Last 10: 7.5	Last 10: 5.5	0%	34%
Montsouris (17)	550	2002	TP	200	380	5.3%	2.4%	After catheter removal	Last 350:4.2	1.45%	3.6%
Boston (10)	70	2002	TP	274	449	10%	1.40%	Not reported	Not reported	1.40%	23%
United Kingdom (9)	100	2002	TP	245	313	3%	1%	4.2	Not reported	1%	8%
Kobe (37,38)	26	2002	TP	453	850	3.80%	0%	Not reported	9	3.8%	19%
Leipzig (23)	70	2003	EP	155	350	1.40%	0%	Not reported	8.2	None reported	21%
Detroit (11)	250	2003	Robotic	Last 100:165 (with node dissection), 135 (without node dissection)	Last 100:150	Not reported	Not reported	Not reported	4.2	Not reported	Not reported
Heilbronn (39)	438	2003	TP	First 219:288; second 219:218	First 219:1100; second 219:800	First 219:30.1%; second 219:9.6%	First 219:3.7%; second 219:0.5%	First 219:12; second 219:11	7	First 219:1.4%; second 219:0%	10%
Milan (12)	80	2003	TP	218	376	53% autologous; 6% heterologous	0%	4.5	11	None reported	23%
MSKCC	250	2004	TP	200	300	5%	0%	1.9	7	0.4%	15%

Abbreviations: TP, transperitoneal; EP, extraperitoneal; OR, operating room; EBL, estimated blood loss; MSKCC, Memorial Sloan-Kettering Cancer Center.

for the last 350 cases (17). As shown in Table 1, average estimated blood loss at other centers worldwide is similar to that reported from Montsouris; at Memorial Sloan-Kettering Cancer Center the average estimated blood loss is 300 mL and the transfusion rate is 2.5%. The estimated blood loss data from Heilbronn were noticeably higher, with an average estimated blood loss of 1100 mL and a transfusion rate of 30% for their initial 219 patients, and 800 mL with a 9.6% transfusion rate for the last 219 patients (39). The reason for this discrepancy is unclear but could be technical since the Heilbronn approach is mainly retrograde. Because lower estimated blood loss represents an advantage of laparoscopic radical prostatectomy over open RP, this parameter requires careful examination.

Hospital Stay and Duration of Catheterization

The hospital stay after laparoscopic radical prostatectomy is dependent on cultural and societal factors unique to each center. In Europe, patients are much more reluctant to leave the hospital with a catheter than in the United States, making this parameter meaningless as an indicator of convalescence; it more correctly represents a measure of the duration of urethral catheterization.

As shown in Table 1, the average duration of catheterization has declined in all series, averaging approximately 4–6 days, which is shorter than historical controls of open retropubic radical prostatectomy.

Early removal of the urinary catheter was examined with cystography by Nadu et al. (40) in 113 patients, and no increase in incontinence rates, anastomotic stricture, or urinary extravasation was noted.

The average duration of catheterization has declined in all series, averaging approximately 4–6 days, which is shorter than historical controls of open retropubic radical prostatectomy.

Convalescence

Most series reported thus far lack detailed data on convalescence and return to normal activities. In addition, few reports have described the degree and duration of postoperative pain and use of analgesics using validated questionnaires. In a small series from Johns Hopkins, postoperative analgesic requirements and time to complete convalescence after laparoscopic radical prostatectomy were significantly improved compared to open retropubic radical prostatectomy (41). In a prospective study comparing open retropubic radical prostatectomy and laparoscopic radical prostatectomy from Kobe, Japan, quality of life questionnaires were used to measure quality of life differences before and after surgery (8,37). Using the EORTC prostate cancer quality of life questionnaire for general health-related quality of life, the investigators found no significant differences between open retropubic radical prostatectomy and laparoscopic radical prostatectomy (8). Patients receiving laparoscopic radical prostatectomy did, however, express a more favorable attitude towards surgery compared to those receiving open retropubic radical prostatectomy, and significantly more patients undergoing laparoscopic radical prostatectomy would have chosen that therapy again compared to those having open retropubic radical prostatectomy.

Complications

Complication rates after laparoscopic radical prostatectomy have varied significantly, as shown in Table 1, ranging from 3.6% to 34%. Unclear and nonstandardized reporting makes interpretation of the reported complication rates difficult.

Not surprisingly, the difficult learning curve of laparoscopic radical prostatectomy skews the results strongly. In the series from Créteil and Heillbronn, the complication rate dropped significantly as experience increased, falling from 23% to 3.2% and from 13.7% to 6.4%, respectively (18,39).

In a large series from Paris, Guillonnet et al. (42) reported on the perioperative complications of laparoscopic radical prostatectomy in 567 patients. In this series, there were 21 major complications (3.7%) and 83 minor complications (14.6%) for an overall complication rate of 17.1%. Perioperative complications requiring reoperation occurred in 21 patients (3.7%), including 13 for a major complication (2.3%), and eight for a minor complication (1.4%). Major complications requiring reoperation included bowel or rectal injury (five patients), hemorrhage (five patients), and ureteral injuries (two patients). There were eight rectal injuries (1.4%), seven of which were noticed immediately and closed laparoscopically in two layers. Two patients with rectal injury required reoperation and temporary colostomy: one patient whose rectal injury was not immediately recognized and one whose injury was repaired but who developed an abscess. Minor complications requiring intervention included epigastric artery injury (0.5%), wound dehiscence (0.7%), and persistent lymphatic drainage (0.2%). Other minor complications included deep vein thrombosis (0.3%), paralytic ileus (1%), vesicourethral anastomotic leakage (0.2%), upper extremity neuropathy (0.4%), and obturator nerve neuropraxia (0.2%). Conversion from laparoscopic radical prostatectomy to open retropubic radical prostatectomy occurred in seven patients (1.2%), all of whom were among the first 70 patients; there were no conversions among the last 500 patients.

In a subsequent report from Montsouris with 1000 patients, rectal injury occurred in 13 patients (1.3%) (43). In 11 patients, the injury was noted intraoperatively and closed primarily in two layers without colostomy or conversion to open retropubic radical prostatectomy. Two patients had delayed rectal injury noted due to development of peritonitis on postoperative day 2 and 4, respectively. These two patients, as well as two patients with immediately recognized and repaired rectal injury who developed peritonitis, required reoperation, and three required temporary colostomy (0.3%). One patient (0.1%) developed a rectourethral fistula despite rectal injury closure in two layers and diverting colostomy, requiring repair through a perineal approach. Of the 13 rectal injuries, 12 occurred during non-nerve sparing procedures, and one occurred during a unilateral nerve sparing procedure. Among the 11 injuries recognized intraoperatively, the injury occurred in 10 patients during dissection of the prostate posteriorly at the apex, and in one patient during wide excision of a neurovascular bundle.

Although rectal injury is a major complication when not recognized, the rate of rectal injuries was similar to that of open radical prostatectomy, and the vast majority was recognized immediately, allowing primary closure and no adverse sequelae (43,44).

Not surprisingly, the difficult learning curve of laparoscopic radical prostatectomy skews the results strongly. In the series from Créteil and Heillbronn, the complication rate dropped significantly as experience increased, falling from 23% to 3.2% and from 13.7% to 6.4%, respectively.

Although rectal injury is a major complication when not recognized, the rate of rectal injuries was similar to that of open radical prostatectomy, and the vast majority was recognized immediately, allowing primary closure and no adverse sequelae.

TABLE 2 ■ Oncologic and Functional Data After Laparoscopic Radical Prostatectomy in Series Worldwide

	No. of patients	Positive surgical margin rate	PSA nonrecurrence	Urinary continence (length of follow-up)	Potency (in previously potent patients undergoing nerve sparing surgery)
Créteil (18)	134	25%	89.6% (11 months)	86.2% (1 year)	BNS: 46% ^a
Créteil (50)	235	N/A	N/A	90% no pad (1 year)	BNS: 58.8% ^b
Berlin (5)	125	26.4%	100% (6 months)	92% 1 pad or less (9 months)	UNS or BNS: 59% (with or without sildenafil)
Brussels (7)	50	22%	94% (3 months)	85% (6 months)	BNS: 83% (with sildenafil)
Heidelberg (39)	438	Table 3	Table 3	90.3% (12 months) 95.8% (18 months)	Not reported
Montsouris (17)	550	16.7%	pT2a: 92.3% (36 months); pT2b: 86.3% (31 months)	82.3% no pad (12 months)	BNS: 85% spontaneous erections, 66% intercourse
Montsouris (51)	1000	19.2%	90.5% (3 years)	N/A	N/A
Boston (10)	70	11.4%	Not reported	85% 1 or less pad at 3 months	Not reported
United Kingdom (9)	100	16%	100% (3 months)	90% no pad (1 year)	BNS: 62% spontaneous erections
Kobe (38)	26	Not reported	100% (1 month)	100% no pad (6 months)	BNS: 71% spontaneous erections, 14% intercourse
Leipzig (23)	70	21%	Not reported	90% no pad (6 months)	BNS: 33% intercourse with sildenafil

^aDefined as intercourse without sildenafil.
^bSpontaneous erections.
Abbreviations: UNS, unilateral nerve sparing; BNS, bilateral nerve sparing.

CANCER CONTROL

The major underlying goal of laparoscopic radical prostatectomy is achieving the best cancer control with the least morbidity.

The major underlying goal of laparoscopic radical prostatectomy is achieving the best cancer control with the least morbidity.

Since the introduction of the modern anatomic open retropubic radical prostatectomy by Walsh and Donker in 1982 (21), the reported five- and 10-year prostate specific antigen nonprogression rates have been 77–80% at five years after open retropubic radical prostatectomy and 54–75% at 10 years (45–49). Because laparoscopic radical prostatectomy has been performed only within the past six years, long-term data on prostate specific antigen nonprogression after laparoscopic radical prostatectomy are unavailable. The short-term oncologic data after laparoscopic radical prostatectomy, however, are encouraging, as shown in Table 2.

The Montsouris experience of about 1000 cases of laparoscopic radical prostatectomy with a median follow-up of 12 months has been published (51). The final pathologic stage was pT2N0/Nx in 775 patients (77.5%), pT2a in 203 patients (20.3%) and pT2b in 573 patients (57.3%), pT3aN0/Nx in 142 patients (14.2%), pT3bN0/Nx in 77 patients (7.7%), and pT1-3N1 in six patients (0.6%). The positive surgical margin rates for each clinical and pathologic stage and each Gleason score are shown in Table 2. The positive surgical margin rate was 19.2% overall, and it varied with pathologic stage from 6.9% for pT2a patients up to 32% for pT3b patients.

In a recent series of laparoscopic radical prostatectomy at Memorial Sloan-Kettering Cancer Center, 77% of the patients had pT2 disease, 19% had pT3, and 4% had pT4 cancers. The positive surgical margin rate by pathological stage was after laparoscopic radical prostatectomy was 3.8% for pT2, 26% for pT3, and 100% for pT4 tumors; the total tumor volume in this series was 2.02 (+2.6) cm³.

In a retrospective study from Germany, Rassweiler et al. (39) compared three consecutive patient cohorts as Rassweiler's institution made a transition from open retropubic radical prostatectomy to laparoscopic radical prostatectomy. The cohorts consisted of 219 patients receiving open retropubic radical prostatectomy before routine laparoscopic radical prostatectomy was performed, the initial 219 patients who received laparoscopic radical prostatectomy during the "learning curve" (early), and the next 219 patients undergoing laparoscopic radical prostatectomy (late). To maintain the accuracy of comparison, the cohorts included only patients who had concurrent pelvic lymphadenectomy, and 83 patients who had laparoscopic radical prostatectomy without lymphadenectomy were excluded. These patient cohorts were consecutive rather than concurrent, with the open retropubic radical prostatectomy patients having surgery between 1994 and 1999 and the laparoscopic radical prostatectomy patients having surgery from 1999 to 2002. Understandably, the median follow-up was different

for each group: 67 months for the open retropubic radical prostatectomy group versus 30 months for the early laparoscopic radical prostatectomy group and eight months for the late laparoscopic radical prostatectomy group. Probably because of stage migration, the percentage of patients with organ-confined (pT1/T2) tumors was lowest in the retropubic radical prostatectomy group (45.7% vs. 55.3% vs. 65.3% in open retropubic radical prostatectomy, early laparoscopic radical prostatectomy, and late laparoscopic radical prostatectomy, respectively), but not significantly different. The positive surgical margin rate also did not differ significantly in these three groups, as shown in Table 2. With the relatively short median follow-up of 30 months, the PSA nonprogression rate in the early laparoscopic radical prostatectomy cohort was 86.8%.

In a similar, earlier study from Montsouris, Fromont et al. (52) compared a matched cohort of 139 open retropubic radical prostatectomy and 139 laparoscopic radical prostatectomy patients with procedures done by two senior surgeons. The laparoscopic radical prostatectomy patients were matched by preoperative serum PSA level with patients who received open retropubic radical prostatectomy performed by the same two surgeons during an earlier period (1994–1997). There was no significant difference between the open retropubic radical prostatectomy and laparoscopic radical prostatectomy groups in PSA (10.6 vs. 10.4), age (64.3 vs. 63.5 years), biopsy Gleason score (5.7 vs. 5.8), or number of positive biopsy cores (2.3 vs. 2.3). The proportion of T1 tumors was higher in the laparoscopic radical prostatectomy group (46% vs. 69%, $P < 0.01$), likely representing stage migration. In the final pathologic analysis, there were no significant differences between open retropubic radical prostatectomy and laparoscopic radical prostatectomy in the rate of positive lymph nodes (1.4% vs. 1.7%), prostate weight (53.4 vs. 55.5 g), or pathologic stage (pT2a: 20% vs. 18%, pT2b: 80% vs. 82%, pT3: 25% vs. 28%). Additionally, there was no significant difference in the final Gleason score, although there was a trend towards a higher percentage of high-grade cancers (Gleason 8–9) in the open retropubic radical prostatectomy group (8.6% vs. 4.3%). The overall rate of positive surgical margins was significantly lower in the laparoscopic radical prostatectomy group compared to the matched open retropubic radical prostatectomy group (13.7% vs. 25.9%, $P < 0.02$). When examining organ-confined cancers, the positive surgical margin rate for pT2 patients was also significantly lower for laparoscopic radical prostatectomy (10% vs. 20.9%, $P < 0.05$). Apical positive surgical margins appeared to account for the differences. Positive apical surgical margins occurred in laparoscopic radical prostatectomy and open retropubic radical prostatectomy in 7.2% versus 15.5% of patients overall, and in 7% versus 18% of patients with pT2 tumors ($P < 0.05$), with no significant difference in positive surgical margins occurring at other sites (posterolateral, base, bladder neck, or multiple sites). From this study, the authors concluded that laparoscopic radical prostatectomy does not lead to higher positive surgical margin rates compared to open retropubic radical prostatectomy.

Other studies have attempted to delineate anatomic differences between open and laparoscopic approaches, to better understand how positive surgical margins occur. A study by Salomon et al. (53) examined 371 patients with organ-confined prostate cancer (pT2) treated by retropubic prostatectomy (116 patients), radical perineal prostatectomy (PRP, 86 patients), or laparoscopic radical prostatectomy (169 patients). There was no significant difference between each group for age, Gleason grade, or clinical stage, but the serum prostate specific antigen level was significantly lower for laparoscopic radical prostatectomy versus retropubic radical prostatectomy and PRP patients (8.9 ng/mL vs. 11.1 and 11.1, respectively). The overall rate of positive surgical margins did not differ significantly for the three groups. The location of positive surgical margins, however, appeared different among the groups. The apical positive margin rate was lower in PRP compared to retropubic radical prostatectomy or laparoscopic radical prostatectomy; the bladder neck positive margin rate was lower for laparoscopic radical prostatectomy than for retropubic radical prostatectomy or PRP; and the posterolateral positive margin rate was higher for laparoscopic radical prostatectomy than retropubic radical prostatectomy or PRP (8.8%, 4.3%, and 3.4%, respectively). These differences, however, did not reach statistical significance. In a follow-up study from the same institution, changes in laparoscopic radical prostatectomy technique reduced the positive surgical margin rate (54). After switching from a bladder neck sparing approach to wide resection of the bladder neck, the rate of positive margins at the bladder neck decreased. Similarly, after changing technique to avoid preservation of the puboprostatic ligaments by incising them each time, the rate of positive margins at the apex decreased. Attempts at neurovascular bundle preservation in selected patients did not result in more positive surgical margins. These studies demonstrate that differences in technique

directly relate to the chance of having a positive surgical margin, but neurovascular bundle preservation does not appear to affect the rate of positive surgical margins significantly. In another retrospective case-control study by Brown et al. (57), 60 laparoscopic radical prostatectomy patients were analyzed for pathologic efficacy and compared with 60 concurrent open retropubic radical prostatectomy patients, and with 60 patients undergoing open retropubic radical prostatectomy matched with the laparoscopic radical prostatectomy patients by clinical stage and biopsy Gleason grade. In this study, the positive surgical margin rate in laparoscopic radical prostatectomy was not significantly different from that in either of the open retropubic radical prostatectomy groups, and the incidence of isolated apical positive margins and multiple-site positive margins was lower in the laparoscopic radical prostatectomy group.

Because of concerns of positive surgical margins in laparoscopic radical prostatectomy during nerve sparing procedures, surgeons at the Montsouris Institute prospectively sent all laparoscopic radical prostatectomy specimens for frozen section analysis in 100 patients undergoing bilateral nerve sparing laparoscopic radical prostatectomy (58). On each side of the prostate specimen, a wedge of tissue from the posterolateral margin in the vicinity of the neurovascular bundle was excised and immediately analyzed. In patients whose frozen section analysis demonstrated a positive surgical margin, the ipsilateral neurovascular bundle was excised. The frozen section analysis revealed positive surgical margins in 24%, and the complementary resection of the ipsilateral neurovascular bundle revealed residual tumor in one-third of these. Intraoperative frozen section analysis decreased the overall positive surgical margin rate from 33% to 12% and from 26% to 8% in organ-confined (pT2) tumors.

FUNCTIONAL RESULTS

The lack of uniformity in defining, assessing, and reporting functional results after radical prostatectomy leads to a disparity of results between different series. The definition used the methodology by which data are gathered and analyzed, and the time of assessment need to be taken into consideration while interpreting the results of potency and continence.

The lack of uniformity in defining, assessing, and reporting functional results after radical prostatectomy leads to a disparity of results between different series. The definition used the methodology by which data are gathered and analyzed, and the time of assessment need to be taken into consideration while interpreting the results of potency and continence.

Continence

Guillonneau et al. reported an 82.3% continence rate at 12 months including only pad-free patients as continent and using a validated questionnaire as a measurement tool. Using the same definition, Rassweiler et al. and Eden et al. reported a 91% and 90% continence rate at 12 months, respectively. In the Creteil's experience, the reported rates of urinary continence defined as no pad required at one year, improved from 78% to 90% in subsequent reports (50,59).

In an evaluation of short-term functional results at Memorial Sloan-Kettering Cancer Center, at three months after laparoscopic radical prostatectomy 49% of the patients had regained urinary continence and did not require the use of any pads, while 22% had mild SUI (leaked only with heavy physical activity) and wore one pad a day as a precaution.

Potency

Most series of laparoscopic radical prostatectomy include potency data only on a small subset of patients, usually treated after the technique of laparoscopic radical prostatectomy and neurovascular bundle preservation was mastered.

The measurement of potency after surgery appears somewhat convoluted, with some centers reporting only the rate of spontaneous erections and others including use of sildenafil as satisfactory for potency. The length of follow-up is another important facet in analysis of sexual function after prostate surgery, since potency can return months or years after surgery.

Potency depends significantly on preoperative sexual function, patient age, and the degree of neurovascular bundle preservation achieved during surgery: bilateral nerve sparing, unilateral nerve sparing, or no nerve sparing. Of their initial 550 patients, Guillonneau et al. reported in a subset of 47 consecutive patients less than 70 years of age. Of those patients who were preoperatively potent, and underwent bilateral nerve sparing, 31 patients (66%) were able to have intercourse with or without sildenafil.

In a contemporary cohort of 110 patients treated at Memorial Sloan-Kettering Cancer Center, 58% of the preoperatively fully potent patients were able to have intercourse (with or without sildenafil) when bilateral neurovascular bundle preservation

The measurement of potency after surgery appears somewhat convoluted, with some centers reporting only the rate of spontaneous erections and others including use of sildenafil as satisfactory for potency. The length of follow-up is another important facet in analysis of sexual function after prostate surgery, since potency can return months or years after surgery.

was performed versus 25% after unilateral preservation ($P = 0.013$; odds ratio, 4.1; 95% CI, 1.3–12.6) at three months after laparoscopic radical prostatectomy. Among patients with bilateral nerve sparing, the outcome was different depending on the quality of preservation. Seventy-one percent of patients with complete bilateral preservation were able to have intercourse versus 57% of the patients who had one nerve completely preserved and possible damage on the other ($P = 0.003$; odds ratio, 12.2; 95% CI, 2.3–65.3) and 16% in patients who had bilateral possible damage ($P = 0.03$; odds ratio, 6.8; 95% CI, 1.2–40.3). On multivariate analysis, the quality of neurovascular bundle preservation was predictive of potency at three months after laparoscopic radical prostatectomy.

NEW INNOVATIONS IN LAPAROSCOPIC PROSTATE SURGERY

As the technique of laparoscopic radical prostatectomy has become standardized and widespread, several centers have begun to use these techniques for salvage laparoscopic radical prostatectomy, and to perform sural nerve grafting during laparoscopic radical prostatectomy.

As the technique of laparoscopic radical prostatectomy has become standardized and widespread, several centers have begun to use these techniques for salvage laparoscopic radical prostatectomy, and to perform sural nerve grafting during laparoscopic radical prostatectomy.

In an early experience from France, Vallancien et al. (58) reported on laparoscopic radical prostatectomy performed as salvage therapy for seven patients. All had previously undergone radiotherapy (external beam radiation in five and brachytherapy in two) and had a rising PSA level with no evidence of clinical metastasis. The operative parameters were similar to those of standard laparoscopic radical prostatectomy; the urethral catheter was left longer (an average of 13 days) because of concerns with healing in a previously radiated field. There were no intraoperative complications or conversions to open surgery. Five of seven patients are continent (71%), and the postoperative PSA at mean follow-up of 11 months was <0.1 ng/mL in five patients.

Building on the experience of sural nerve grafts during open RP reported by Scardino et al. (59,60), Tuerk et al. (61) demonstrated the technical feasibility of performing nerve grafting during laparoscopic radical prostatectomy. The use of the daVinci robotic system for nerve grafting has also been reported by Kaouk et al. (62). All procedures were performed successfully, demonstrating the feasibility of this procedure. Long-term follow-up with greater numbers is necessary to determine efficacy.

PERSONAL EXPERIENCE OF THE SENIOR AUTHOR (B. G.): THE LESSONS LEARNED

In the last 6.5 years, I have performed laparoscopic radical prostatectomy in approximately 1000 patients. Although the concept of this procedure did not change, the operative strategy has evolved dramatically with experience.

The Laparoscopic Approach in General

Much of the debate at the present time is about the value of the intraperitoneal versus the extraperitoneal approach, and also about the timing of the dissection of the seminal vesicles. It is clear that the extraperitoneal approach is quicker. The Retzius space is developed with either a balloon or finger dissection, thus eliminating the anterior dissection of the intraperitoneal approach. Furthermore, the surgeon senses that the operation starts directly on the prostate.

It is my personal belief that for preoperatively potent patients for whom preservation of potency is intended, the dissection of the seminal vesicles first is paramount in laparoscopy.

The reason is anatomical: the seminal vesicles are superficially located behind the peritoneal fold of the pouch of Douglas; their dissection is definitely easier and controlled through this approach. The importance of this step vis-à-vis the functional outcome resides in the close anatomical relationship between the lateral aspects and the tips of the seminal vesicles and the inferior hypogastric plexus (pelvic plexus) and the cavernous nerves. It is essential to avoid any injury to these structures by an accurate dissection of the seminal vesicles in a bloodless surgical field and with a precise control of all the vessels feeding the seminal vesicles. To achieve this goal, it is obvious that dissection is better accomplished through the posterior transperitoneal approach. In the extraperitoneal approach, the seminal vesicles are approached anteriorly through the bladder neck, which most often requires a larger incision laterally towards the pedicles to compensate for an indirect axis of vision, more traction on the seminal vesicles, and

It is my personal belief that for preoperatively potent patients for whom preservation of potency is intended, the dissection of the seminal vesicles first is paramount in laparoscopy.

The argument that the extraperitoneal approach avoids the potential complications of the peritoneotomy is a false one.

Intraperitoneal dissection provides increased mobility of the bladder allowing a real tension-free anastomosis as compared to the extraperitoneal approach where the anastomosis is often performed under tension. This tension-free anastomosis is, to my knowledge, a better explanation for the very low bladder stricture rate, less than 0.5% in this experience.

These nerves are very fragile and any trauma of any nature can definitively damage them and compromise erectile function. The goal is to dissect the nerves in as delicate a way as possible and with the least manipulation. Developing the appropriate plane of dissection close to the prostate is ideal; however, oncological safety must not be compromised.

The impact of these apical arteries on potency and continence is unclear and for that reason they should all be preserved through a delicate dissection.

It is always possible to control the bleeding from the dorsal vascular complex, and raising the pressure of the pneumoperitoneum up to 20 mmHg during the stitching is definitively helpful.

a dissection in an often bloody area. Hence, there is a severe risk of damage to the neurovascular bundles.

However, in patients with preoperative erectile dysfunction, or in case of planned neurovascular bundle resection, or even difficult posterior access secondary to either obesity and/or deep pouch of Douglas, the seminal vesicles are approached anteriorly rather than posteriorly, but the above scenarios are sources of technical difficulties leading to a less accurate seminal vesicle dissection.

The argument that the extraperitoneal approach avoids the potential complications of the peritoneotomy is a false one.

Besides the points listed above, there are no complications solely related to the peritoneotomy. On the other hand, the transperitoneal approach provides a larger working space, with clearly better instrument manipulation and an easier use of the suction without prompt loss of the pneumoperitoneum. But more important is the quality of the anastomosis achieved with the intraperitoneal dissection.

Intraperitoneal dissection provides increased mobility of the bladder allowing a real tension-free anastomosis as compared to the extraperitoneal approach where the anastomosis is often performed under tension. This tension-free anastomosis is, to my knowledge, a better explanation for the very low bladder stricture rate, less than 0.5% in this experience.

Steps in Neurovascular Bundle Preservation

This step impacts greatly on the functional outcome and is the main reason why the operative time has not shortened with experience; any time saved on other steps of the dissection is allocated to the preservation of the nerves.

These nerves are very fragile and any trauma of any nature can definitively damage them and compromise erectile function. The goal is to dissect the nerves in as delicate a way as possible and with the least manipulation. Developing the appropriate plane of dissection close to the prostate is ideal; however, oncological safety must not be compromised.

Only an extended preoperative work-up and a complete comprehension of the anatomy will help in achieving this task. The use of hemostatic tools (clips, bipolar coagulation, and suture) for ligation of the pedicles is of no consequence—as long as this is performed close to the prostate, and is not performed “en bloc.” The dissection of the neurovascular bundle itself should be done without any hemostatic means, as long as an intrafascial plane is developed. Bleeding during this step most likely means that the dissection is taken in the neurovascular bundle itself (i.e., interfascial plane): the intracapsular vessels arising from the neurovascular bundle and entering the prostate, usually found at the base and apex, are the source of easily controlled bleeding.

Accessory Pudendal Arteries

Accessory pudendal arteries are frequent; their role and importance however are debatable. An accessory pudendal artery coming in laterally from the inferior vesical arteries is easily recognized laparoscopically. It is certain that in some patients they represent the only arterial supply to the corpora cavernosa and therefore every effort at sparing them should be taken.

But other accessory pudendal arteries encountered at the apex may be branches of the obturator arteries.

The impact of these apical arteries on potency and continence is unclear and for that reason they should all be preserved through a delicate dissection.

Control of the Dorsal Vascular Complex

At the apex, the incision of the dorsal vascular complex should be tangential in order to avoid a positive surgical margin anteriorly. In cases with high suspicion of anterior tumor, the dorsal vascular complex is directly transected as distal as possible, leaving a sufficient amount of vascular structures on the anterior aspect of the prostatic apex and without placing a hemostatic suture prior to incision.

It is always possible to control the bleeding from the dorsal vascular complex, and raising the pressure of the pneumoperitoneum up to 20 mmHg during the stitching is definitively helpful.

Dissection of the Apex

The apex is the principal location of positive margins in pT2 tumors, indicating that particular attention should be paid during this step.

At the present time, the urethra is kept intact during all of the apical dissection and used as a landmark: laterally, it helps to identify the junction between the prostate, the urethra, and the neurovascular bundle, and the contours of the prostate are then followed until the neurovascular bundle is totally freed. The urethra is therefore the last structure transected. This modification has certainly contributed to a reduction of the positive margin rate to about 3% in pT2 tumors.

At the present time, the urethra is kept intact during all of the apical dissection and used as a landmark: laterally, it helps to identify the junction between the prostate, the urethra, and the neurovascular bundle, and the contours of the prostate are then followed until the neurovascular bundle is totally freed. The urethra is therefore the last structure transected. This modification has certainly contributed to a reduction of the positive margin rate to about 3% in pT2 tumors.

Analyzing the Specimen

Once the prostate is freed, the specimen is extracted immediately for macroscopic examination. The purpose of this step is to adjust for the lack of intraoperative tactile feeling of laparoscopy and to ascertain oncological safety by giving the surgeon a chance to resect additional tissue based on the gross examination and/or frozen section results.

SUMMARY

- Laparoscopic radical prostatectomy is a relatively new approach to the surgical treatment of localized prostate cancer.
- Since its inception, the technique, however challenging, is undergoing continuous refinements, which made it today a feasible, reproducible, and teachable operation practiced by urologists worldwide.
- The advantages of the laparoscopic approach are a magnified view of the anatomic structures, and a decreased venous bleeding in the surgical field allowing an accurate dissection of the prostate and neurovascular bundles. These advantages translate to a low positive surgical margin rate, low morbidity profile, and favorable postoperative quality of life outcomes.
- Performed only in the last six years, long-term cancer control and functional results data following laparoscopic radical prostatectomy are not available.
- For a successful laparoscopic prostatectomy program, advanced laparoscopic skills, knowledge of the prostatic anatomy, and expertise in surgical oncology are required.

REFERENCES

1. Schuessler WW, Schulam PG, Clayman RV, Kavoussi LR. Laparoscopic radical prostatectomy: initial short-term experience. *Urology* 1997; 50:854.
2. Guillonnet B, Vallancien G. Laparoscopic radical prostatectomy: initial experience and preliminary assessment after 65 operations. *Prostate* 1999; 39:71.
3. Guillonnet B, Cathelineau X, Barret E, Rozet F, Vallancien G. Laparoscopic radical prostatectomy: technical and early oncological assessment of 40 operations. *Eur Urol* 1999; 36:14.
4. Abbou CC, Salomon L, Hoznek A, et al. Laparoscopic radical prostatectomy: preliminary results. *Urology* 2000; 55:630.
5. Tuerk I, Deger S, Winkelmann B, Schonberger B, Loening SA. Laparoscopic radical prostatectomy. Technical aspects and experience with 125 cases. *Eur Urol* 2001; 40:46.
6. Rassweiler J, Sentker L, Seemann O, Hatzinger M, Rumpelt HJ. Laparoscopic radical prostatectomy with the Heilbronn technique: an analysis of the first 180 cases. *J Urol* 2001; 166:2101.
7. Bollens R, Vanden Bossche M, Roumeguere T, et al. Extraperitoneal laparoscopic radical prostatectomy. Results after 50 cases. *Eur Urol* 2001; 40:65.
8. Hara I, Kawabata G, Miyake H, et al. Comparison of quality of life following laparoscopic and open prostatectomy for prostate cancer. *J Urol* 2003; 169:2045.
9. Eden CG, Cahill D, Vass JA, Adams TH, Dauleh MI. Laparoscopic radical prostatectomy: the initial UK series. *BJU Int* 2002; 90:876.
10. Dahl DM, L'Esperance JO, Trainer AF, et al. Laparoscopic radical prostatectomy: initial 70 cases at a U.S. university medical center. *Urology* 2002; 60:859.
11. Menon M, Tewari A. Vattikuti Institute prostatectomy, T.: robotic radical prostatectomy and the Vattikuti Urology Institute technique: an interim analysis of results and technical points. *Urology* 2003; 61:15.
12. Gregori A, Simonato A, Lissiani A, Bozzola A, Galli S, Gaboardi F. Laparoscopic radical prostatectomy: perioperative complications in an initial and consecutive series of 80 cases. *Eur Urol* 2003; 44:190.
13. Raboy A, Ferzli G, Albert P. Initial experience with extraperitoneal endoscopic radical retropubic prostatectomy. *Urology* 1997; 50:849.
14. Guillonnet B, Vallancien G. Laparoscopic radical prostatectomy: the Montsouris technique. *J Urol* 2000; 163:1643.
15. Guillonnet B, Vallancien G. Laparoscopic radical prostatectomy: the Montsouris experience. *J Urol* 2000; 163:418.
16. Guillonnet B, Rozet F, Barret E, Cathelineau X, Vallancien G. Laparoscopic radical prostatectomy: assessment after 240 procedures. *Urol Clin North Am* 2001; 28:189.

17. Guillonnet B, Cathelineau X, Doublet JD, Baumert H, Vallancien G. Laparoscopic radical prostatectomy: assessment after 550 procedures. *Crit Rev Oncol Hematol* 2002; 43:123.
18. Hoznek A, Salomon L, Olsson LE, et al. Laparoscopic radical prostatectomy. The Creteil experience. *Eur Urol* 2001; 40:38.
19. Menon M, Tewari A, Peabody J. The V. I. P. T.: Vattikuti Institute prostatectomy: technique. *J Urol* 2003; 169:2289.
20. Rassweiler J, Frede T, Seemann O, Stock C, Sentker L. Telesurgical laparoscopic radical prostatectomy. Initial experience. *Eur Urol* 2001; 40:75.
21. Walsh PC, Donker PJ. Impotence following radical prostatectomy: insight into etiology and prevention. *J Urol* 1982; 128:492.
22. Stolzenburg JU, Do M, Pfeiffer H, Konig F, Aedtner B, Dorschner W. The endoscopic extraperitoneal radical prostatectomy (EERPE): technique and initial experience. *World J Urol* 2002; 20:48.
23. Stolzenburg JU, Do M, Rabenalt R, et al. Endoscopic extraperitoneal radical prostatectomy: initial experience after 70 procedures. *J Urol* 2003; 169:2066.
24. Stolzenburg JU, Truss MC. Technique of laparoscopic (endoscopic) radical prostatectomy. *BJU Int* 2003; 91:749.
25. Hoznek A, Antiphon P, Borkowski T, et al. Assessment of surgical technique and perioperative morbidity associated with extraperitoneal versus transperitoneal laparoscopic radical prostatectomy. *Urology* 2003; 61:617.
26. Cathelineau X, Cahill D, Widmer H, Rozet F, Baumert H, Vallancien G. Transperitoneal or extraperitoneal approach for laparoscopic radical prostatectomy: a false debate over a real challenge. *J Urol* 2004; 171:714.
27. Binder J, Kramer W. Robotically-assisted laparoscopic radical prostatectomy. *BJU Int* 2001; 87:408.
28. Gettman MT, Blute ML, Peschel R, Bartsch G. Current status of robotics in urologic laparoscopy. *Eur Urol* 2003; 43:106.
29. Pasticier G, Rietbergen JB, Guillonnet B, Fromont G, Menon M, Vallancien G. Robotically assisted laparoscopic radical prostatectomy: feasibility study in men. *Eur Urol* 2001; 40:70.
30. Abbou CC, Hoznek A, Salomon L, et al. Laparoscopic radical prostatectomy with a remote controlled robot. *J Urol* 2001; 165:1964.
31. Tewari A, Peabody J, Sarle R, et al. Technique of da Vinci robot-assisted anatomic radical prostatectomy. *Urology* 2002; 60:569.
32. Ahlering TE, Skarecky D, Lee D, Clayman RV. Successful transfer of open surgical skills to a laparoscopic environment using a robotic interface: initial experience with laparoscopic radical prostatectomy. *J Urol* 2003; 170:1738.
33. Gettman MT, Hoznek A, Salomon L, et al. Laparoscopic radical prostatectomy: description of the extraperitoneal approach using the da Vinci robotic system. *J Urol* 2003; 170:416.
34. Guillonnet B. What robotics in urology? A current point of view. *Eur Urol* 2003; 43:103.
35. Katz R, Nadu A, Olsson LE, et al. A simplified 5-step model for training laparoscopic urethrovesical anastomosis. *J Urol* 2003; 169:2041.
36. Fabrizio MD, Tuerk I, Schellhammer PF. Laparoscopic radical prostatectomy: decreasing the learning curve using a mentor initiated approach. *J Urol* 2003; 169:2063.
37. Hara I, Kawabata G. Japanese experience with radical prostatectomy. *Curr Urol Rep* 2002; 3:159.
38. Hara I, Kawabata G, Miyake H, et al. Feasibility and usefulness of laparoscopic radical prostatectomy: Kobe University experience. *Int J Urol* 2002; 9:635.
39. Rassweiler J, Seemann O, Schulze M, Teber D, Hatzinger M, Frede T. Laparoscopic versus open radical prostatectomy: a comparative study at a single institution. *J Urol* 2003; 169:1689.
40. Nadu A, Salomon L, Hoznek A, et al. Early removal of the catheter after laparoscopic radical prostatectomy. *J Urol* 2001; 166:1662.
41. Bhayani SB, Pavlovich CP, Hsu TS, Sullivan W, Su LM. Prospective comparison of short-term convalescence: laparoscopic radical prostatectomy versus open radical retropubic prostatectomy. *Urology* 2003; 61:612.
42. Guillonnet B, Rozet F, Cathelineau X, et al. Perioperative complications of laparoscopic radical prostatectomy: the Montsouris 3-year experience. *J Urol* 2002; 167:51.
43. Guillonnet B, Gupta R, El Fettouh H, Cathelineau X, Baumert H, Vallancien G. Laparoscopic management of rectal injury during laparoscopic radical prostatectomy. *J Urol* 2003; 169:1694.
44. Katz R, Borkowski T, Hoznek A, Salomon L, de la Taille A, Abbou CC. Operative management of rectal injuries during laparoscopic radical prostatectomy. *Urology* 2003; 62:310.
45. Pound CR, Partin AW, Epstein JI, Walsh PC. Prostate-specific antigen after anatomic radical retropubic prostatectomy. Patterns of recurrence and cancer control. *Urol Clin North Am* 1997; 24:395.
46. Trapasso JG, deKernion JB, Smith RB, Dorey F. The incidence and significance of detectable levels of serum prostate specific antigen after radical prostatectomy. *J Urol* 1994; 152:1821.
47. Zincke H, Oesterling JE, Blute ML, Bergstralh EJ, Myers RP, Barrett DM. Long-term (15 years) results after radical prostatectomy for clinically localized (stage T2c or lower) prostate cancer [see comments]. *J Urol* 1994; 152:1850.
48. Catalona WJ, Smith DS. 5-year tumor recurrence rates after anatomical radical retropubic prostatectomy for prostate cancer [see comments]. *J Urol* 1994; 152:1837.
49. Hull GW, Rabbani F, Abbas F, Wheeler TM, Kattan MW, Scardino PT. Cancer control with radical prostatectomy alone in 1,000 consecutive patients. *J Urol* 2002; 167:528.
50. Salomon L, Anastasiadis AG, Katz R, et al. Urinary continence and erectile function: a prospective evaluation of functional results after radical laparoscopic prostatectomy. *Eur Urol* 2002; 42:338.
51. Guillonnet B, el-Fettouh H, Baumert H, et al. Laparoscopic radical prostatectomy: oncological evaluation after 1,000 cases at Montsouris Institute. *J Urol* 2003; 169:1261.
52. Fromont G, Guillonnet B, Validire P, Vallancien G. Laparoscopic radical prostatectomy. Preliminary pathologic evaluation. *Urology* 2002; 60:661.
53. Salomon L, Levrel O, de la Taille A, et al. Radical prostatectomy by the retropubic, perineal and laparoscopic approach: 12 years of experience in one center. *Eur Urol* 2002; 42:104.

54. Katz R, Salomon L, Hoznek A, de la Taille A, Antiphon P, Abbou CC. Positive surgical margins in laparoscopic radical prostatectomy: the impact of apical dissection, bladder neck remodeling and nerve preservation. *J Urol* 2003; 169:2049.
55. Brown JA, Garlitz C, Gomella LG, et al. Pathologic comparison of laparoscopic versus open radical retropubic prostatectomy specimens. *Urology* 2003; 62:481.
56. Fromont G, Baumert H, Cathelineau X, Rozet F, Validire P, Vallancien G. Intraoperative frozen section analysis during nerve sparing laparoscopic radical prostatectomy: feasibility study. *J Urol* 2003; 170:1843.
57. Olsson LE, Salomon L, Nadu A, et al. Prospective patient-reported continence after laparoscopic radical prostatectomy. *Urology* 2001; 58:570.
58. Vallancien G, Gupta R, Cathelineau X, Baumert H, Rozet F. Initial results of salvage laparoscopic radical prostatectomy after radiation failure [see comment]. *J Urol* 2003; 170:1838.
59. Scardino PTKE. Rationale for and results of nerve grafting during radical prostatectomy. *Urology* 2001; 57:1016.
60. Kim ED, Scardino PT, Hampel O, Mills NL, Wheeler TM, Nath RK. Interposition of sural nerve restores function of cavernous nerves resected during radical prostatectomy. *J Urol* 1999; 161:188.
61. Tuerk IA, Deger S, Morgan WR, Davis JW, Schellhammer PF, Loening SA. Sural nerve graft during laparoscopic radical prostatectomy. Initial experience. *Urol Oncol* 2002; 7:191.
62. Kaouk JH, Desai MM, Abreu SC, Papay F, Gill IS. Robotic assisted laparoscopic sural nerve grafting during radical prostatectomy: initial experience. *J Urol* 2003; 170:909.

COMMENTARY

Robert P. Myers

Department of Urology, Mayo Clinic, Mayo Clinic College of Medicine,
Rochester, Minnesota, U.S.A.

Minimally invasive therapy has as its basic premise the reduction of iatrogenic trauma. This approach must imply that the therapeutic procedure succeeds in a manner no less effective than is currently achievable by established methods of treatment.—*J.E.A. Wickham, 1993 (1).*

The surge of interest in laparoscopic radical prostatectomy (LRP) is certainly an offshoot of the concept of minimally invasive surgery, for which due credit must be extended to John Wickham, who has had so much influence (1). Open radical perineal prostatectomy has been accomplished for more than 100 years (2) and open radical retropubic prostatectomy for more than 50 years (3). Much is known about the long-term results of these open operations in terms of cancer control and functional outcome. The laparoscopic approach is so new, relatively speaking, that long-term outcomes are not at all clear at this time.

There are three distinct arguments for laparoscopic radical prostatectomy over the open retropubic operation. The first argument is reduced blood loss with, on average, likely a higher hemoglobin level at dismissal. This is associated with increased strength, quicker recovery, and more rapid return to work. This argument does not hold for the perineal operation, in which blood loss is minimal and same-day dismissal conceivable. The perineal route is the most direct access to the prostate, and the non-nerve-sparing operation can be completed skin to skin in 40 minutes, as the late Ormond Culp did when I first assisted him as a resident-in-training.

The second argument is the tremendously magnified ($\times 10$ to $\times 15$) and detailed view of the relevant anatomy with laparoscopic radical prostatectomy. However, this advantage can be attained in open surgery by wearing magnifying optical loupes of $\times 2$ to $\times 4.5$. I use $\times 2.5$ and have excellent three-dimensional depth of field. In laparoscopic radical prostatectomy, the two-dimensional field must be learned, and the Da Vinci robotic device with three-dimensional imaging makes the two-dimensional learning curve unnecessary.

The third argument for laparoscopic radical prostatectomy is the improved cosmetic result from using multiple tiny ports rather than a mid-line incision. But this can be achieved for the insistent patient by using either the transverse Langer line Pfannenstiel (in thin patients) or Cherney incisions, the latter providing wide pelvic access even in the deepest pelvis (4). The Cherney incision with its disarticulation of the rectus abdominis tendons



FIGURE 1 ■ Postoperative scar of transverse Cherney incision extended from previous left lower quadrant scar of incision used for placement of kidney transplant.

does necessitate careful reconstruction and convalescence to avoid subsequent hernia and is particularly useful for patients who have had a kidney transplantation to an abdominal lower quadrant (Fig. 1).

Laparoscopic radical prostatectomy provides no obvious advantage in terms of duration of hospitalization. The introduction of preemptive analgesia has made the open retropubic operation virtually pain free and patients are up and about, eating, and able to be dismissed in 24 to 48 hours. (Patients undergoing the perineal operation have very little pain). With careful hemostasis during the open retropubic operation, a hemoglobin value at dismissal of 10 to 12 g/dL, without having a transfusion, is possible; patients, thus, have a sense of strength and well-being at dismissal. If blood bank guidelines allowed transfusion for patients whose hemoglobin value was less than the ideal dismissal range of 10 to 12 g/dL, laparoscopic radical prostatectomy would not have an advantage in this regard.

Cost is not an insignificant issue. If patients who have the open techniques can be dismissed the same day as, or within 24 to 48 hours of, operation, these approaches will be more cost effective not only in operating room time for most surgeons but also certainly in the cost of material and “disposables.” In the United States, Medicare reimbursement for radical prostatectomy is so fine-tuned that it is an extraordinary challenge to come in under reimbursement. The *da Vinci*® robotic system, which has an initial cost of \$1.2 million, yearly maintenance cost of about \$100,000, and a cost for “disposables” of more than \$2000 per case, is economically impractical for most institutions. Furthermore, the number of candidates for radical prostatectomy exceeds the number of qualified practitioners of laparoscopic radical prostatectomy, both traditional and robotic.

The ability to succeed in the goals of cancer control, urinary control, and maintenance of erectile function depends on the skill of the surgeon to extract the prostate, seminal vesicles, and portions of the vasa deferentia with the least disturbance possible to the structures that need preservation. Structures that need preservation include the striated urethral sphincter and the “distal sphincter mechanism,” to credit Richard Turner Warwick’s terminology (5), and the “neurovascular bundles,” to credit Patrick Walsh’s terminology (6). For successful outcome, it may help to preserve the bladder neck longitudinal smooth muscle, the so-called Bundle of Heiss (7), which can be usefully incorporated for initial passive continence in the bladder neck plication during open surgery (8). Currently, it is not at all clear that laparoscopic radical prostatectomy can achieve minimal disturbance of these structures critical to functional outcome in the same way afforded by open surgery, particularly the open retropubic approach. “Below the abdominal wall level, laparoscopic radical prostatectomy is clearly no less invasive than an open approach.” To date, video demonstrations of laparoscopic radical prostatectomy that I have witnessed exhibit remarkable traction on the nerve bundles, and the extensive cautery used must generate considerable heat in the region of the pedicles and nerve bundles. In laparoscopic radical prostatectomy, discrimination and separation of the vascular pedicles from the nerve bundle appear challenging, as does accurate antegrade apical dissection of the prostate. As recently suggested, real-time transrectal ultrasonography can assist in the apical dissection during laparoscopic radical prostatectomy (9). Also, this latter difficulty of apical dissection has been overcome to some degree by takedown of the puboprostatic (pubovesical) ligaments close to their pubic insertion points. This then allows better direct access to the anterior prostatourethral junction for the purpose of optimal urethral transection. If the takedown of the puboprostatic ligaments is not done carefully, the immediately and laterally adjacent tendinous insertions of the puborectalis (puboanalis) sling could be disrupted and postoperative fecal control compromised. With the hands-on control and tactile feedback of open surgery, all of the above issues can be avoided.

Critical appraisal of laparoscopic radical prostatectomy and the open operations will be forthcoming only with prospective studies using internationally recognized, validated questionnaires under third-party control to probe general quality of life, functional outcomes and bother, and cancer control in suitable numbers of patients. Time to functional recovery of pad-free urinary

control and erectile function suitable for satisfactory intercourse is another matter. How quickly do patients recover those functions? For laparoscopic radical prostatectomy to be fully acceptable, the best results of laparoscopic radical prostatectomy must be shown to match, unequivocally, the best results of an open operation.

Finally, how do we improve training opportunities? How many patients are hurt in anybody's learning curve for any type of approach, and how can needless injury be avoided, for example, the 12-hour procedure with ultimate urinary and fecal diversion? This is not a criticism directed at laparoscopic radical prostatectomy. The open retropubic and perineal operations can become instant disasters in the hands of the unknowing when patients become victims of reckless behavior. Importantly, the bottom line is always going to be proper training and judgment in whatever approach is used.

REFERENCES

1. Wickham JEA. An introduction to minimally invasive therapy. *Health Policy* 1993; 23:7–15.
2. Young HH. The early diagnosis and radical cure of carcinoma of the prostate: being a study of 40 cases and presentation of a radical operation which was carried out in four cases. *Bull Johns Hopkins Hosp* 1905; 16:315–321.
3. Millin T. Radical retropubic surgery of the prostate. In: Maingot R, ed. *Techniques in British Surgery*. Philadelphia: WB Saunders Company, 1950:464–474.
4. Culp OS, DeWeerd JH. Advantages of the Cherney incision for urologic operations. *J Urol* 1953; 69:445–453.
5. Turner Warwick R. The sphincter mechanisms: their relation to prostatic enlargement and its treatment. In: Hinman F Jr, ed. *Benign Prostatic Hypertrophy*. New York: Springer-Verlag, 1983:809–828.
6. Walsh PC, Lepor H, Eggleston JC. Radical prostatectomy with preservation of sexual function: anatomical and pathological considerations. *Prostate* 1983; 4:473–485.
7. Woodburne RT. Anatomy of the bladder and bladder outlet. *J Urol* 1968; 100:474–487.
8. Myers RP, Villers A. Anatomic considerations in radical prostatectomy. In: Kirby R, Partin A, Feneley M, Parsons JK, eds. *Prostate Cancer: Principles and Practice. Treatment of Early Stage Prostate Cancer*. London: T&F Informa. In press.
9. Ukimura O, Gill IS, Desai MM, et al. Real-time transrectal ultrasonography during laparoscopic radical prostatectomy. *J Urol* 2004; 172:112–118.

PORT SITE METASTASIS IN UROLOGIC LAPAROSCOPY

Steven M. Baughman and Jay T. Bishoff

Urology Flight, Wilford Hall Medical Center, Lackland AFB, Texas, U.S.A.

- INTRODUCTION
- HISTORY: GYNECOLOGIC AND GENERAL SURGERY LITERATURE
- UROLOGIC EXPERIENCE
- BASIC SCIENCE AND PREDISPOSING FACTORS
 - Technical Factors
 - Local Wound Factors
 - Immune Response
 - Tumor Behavior
- PORT SITE RECURRENCE PREVENTION
- PERCUTANEOUS ABLATION
- SUMMARY
- REFERENCES

INTRODUCTION

The use of laparoscopy in the treatment of malignant disease has generated a great deal of controversy, in part, due to the fear of inadequate cancer control. The early laparoscopic experience cited in the surgical and gynecological literature initially elevated concerns regarding the risk of port site recurrence. Indeterminate surgical margins and loss of precise pathological staging information due to morcellation historically increased these concerns. In urologic surgery, minimally invasive procedures for malignant disease have shown equivalent cancer control when compared to traditional open approaches.

HISTORY: GYNECOLOGIC AND GENERAL SURGERY LITERATURE

Recurrence of malignancy at trocar or port sites following laparoscopy has been described in the general surgical, gynecologic, and urologic literature.

Port site recurrence can be defined as subcutaneous tissue or abdominal wall malignant tumor reappearance following laparoscopy for malignancy, not associated with carcinomatosis at the time of the initial procedure.

To date, however, the majority of port site recurrences have been reported in the general and gynecologic surgical literature. From the early experience with laparoscopic cholecystectomy came reports of unrecognized gall bladder and gastrointestinal tumors recurring at the port sites following laparoscopy (1–6), which caused concern and criticisms of laparoscopy applied to oncologic surgery. As a result, some surgeons expressed the need for more formal prospective randomized studies to further understand this dilemma (7).

In an effort to retrospectively refute these criticisms, an initial broad survey of over 1050 European general surgery programs demonstrated port site recurrence in 17% of laparoscopic cholecystectomies where there was an incidental finding of gall-bladder carcinoma and 4.6% of laparoscopic cases for colorectal cancer (8). The authors implicate laparoscopy as an independent factor leading to port site recurrence, without taking into account the incidental discovery of gastrointestinal cancer or unprotected organ removal from the abdomen, violating established cancer surgical principles. A six-year review of 533 procedures (mean follow-up of 13.2 months) from the University of Texas M.D. Anderson Cancer Center identified only four port site recurrences for nongynecologic laparoscopic cancer surgery. Three of the four patients had demonstrable intra-abdominal disease at the time of laparoscopy, with the final patient having the port site as the only site of recurrence. This group concluded that port site recurrence is not only rare, but also indeed more rare in those patients with no evidence of advanced intra-abdominal disease (9). The rarity of port site recurrence is further demonstrated in other contemporary series of laparoscopic oncologic procedures compared to open surgical experiences, with no statistically significant comparative wound recurrence rates (10–12).

Port site recurrence can be defined as subcutaneous tissue or abdominal wall malignant tumor reappearance following laparoscopy for malignancy, not associated with carcinomatosis at the time of the initial procedure.

Vertical midline laparotomy is argued as the gold standard for ovarian malignancy, because large prospective randomized clinical trials comparing laparoscopy are absent from the contemporary gynecologic literature (13). Despite this argument, the ubiquity and benefits of laparoscopy has driven minimally invasive management for many gynecologic malignancies (14). Using laparoscopy for the treatment of uterine carcinoma with bulky adenopathy appears to have a higher gynecologic risk of port site recurrence when compared to open surgery (15–18). Additional citations also reflect that nearly every gynecologic malignancy has reported port site recurrences (19–21).

In evaluating the cases reported regarding port site seeding, several common elements emerge. Many cases are associated with circumstances where malignancy was unexpected or was being determined with diagnostic laparoscopy or biopsy (10,22). As such, basic principles of cancer surgery may have been violated and in many cases metastatic disease (i.e., carcinomatosis) or malignant ascites was already present (23). In addition, the majority of cases involved removal of tissue either directly through a trocar site or through a small incision without entrapment sac protection.

UROLOGIC EXPERIENCE

A careful search of the urologic literature demonstrates a relatively low incidence of laparoscopic port site seeding from adrenal, renal, urothelial, testicular, or prostate carcinomas (Table 1).

Dunn et al. demonstrated no port site recurrence or peritoneal seeding in their initial nine-year experience of 61 laparoscopic radical nephrectomies removed through both intact delivery and morcellation (38). As in other series (39), it is noteworthy that Clayman's group morcellated all specimens within a specially designed, impermeable sac, with the port site redraped in an effort to prevent wound contamination. Their institution's efforts are also successful in obviating port site recurrence following laparoscopic nephroureterectomy (40).

Rassweiler et al. reported a decade's experience of 1098 laparoscopic procedures for urologic malignancies (36). Local recurrence was observed in eight patients following nephroureterectomy for ureteral transitional cell carcinoma, one radical nephrectomy for renal cell carcinoma, one patient with teratoma following retroperitoneal lymph node dissection, three instances of prostate cancer, and one case following adrenalectomy for metastatic melanoma. port site recurrences, however, were observed following metastatic laparoscopic adrenalectomy for small cell carcinoma of the lung (Fig. 1) and following one postchemotherapy retroperitoneal lymph node dissection. Unfortunately descriptions of tissue manipulation, entrapment techniques, and specimen delivery are not discussed with these reports (36).

The inherent aggressive biologic behavior of metastatic disease to the adrenal gland is a likely mechanism for port site recurrence following laparoscopic adrenalectomy. To date, there are no identified primary adrenal malignancy port site recurrence reports. Conversely, there are two reports of port site recurrence following laparoscopic adrenalectomy for metastatic small cell carcinoma (36,37). Chen et al. describe wide en bloc dissection in an attempt to avoid manipulation of the adrenal gland and entrapment in an impermeable extraction device was noted in their report. However, at five months, the patient presented with a palpable port site mass (Fig. 2) and bowel obstruction. Palliative external beam radiotherapy management was attempted, but the patient expired as a result of metastatic disease 10 months postadrenalectomy (37).

To date, there have been four reports of port site seeding following laparoscopic radical nephrectomy for renal cell carcinoma. In a series of 57 laparoscopic radical nephrectomies, with specimen morcellation, one patient with T3N0M0 (Fuhrman IV/IV) disease suffered a solitary recurrence at one trocar site, 25 months after radical nephrectomy (24). Castilho et al. report multiple-site port site recurrences in a 72-year-old-male with a T1N0M0 renal cell carcinoma after laparoscopic radical nephrectomy. In this patient, ascites, relative immunosuppression from cirrhosis, or morcellation within a "plastic" nonimpermeable sac may have each contributed to this port site recurrence (25). Finally, one hand-assisted laparoscopic radical nephrectomy port site recurrence has also been reported (26). A patient with a 10 cm T2N0M0, Fuhrman grade III, renal cell carcinoma was without initial tumor violation, and negative surgical margins, but had the specimen delivered intact through the hand port without entrapment. Specific delivery through the hand port orifice or wound (without port) was not discriminated in this report. At nine months postnephrectomy, however, a 6 × 5 cm hand port site mass was seen (Fig. 3). The patient was treated with wide

A careful search of the urologic literature demonstrates a relatively low incidence of laparoscopic port site seeding from adrenal, renal, urothelial, testicular, or prostate carcinomas.

TABLE 1 ■ Reported PSR Following Minimally Invasive Management of Urologic Malignancy

References	Pathology (primary TNM stage, grade)	Primary laparoscopic approach	Recurrence identification	Management
<i>Renal cell carcinoma</i>				
24	Renal cell carcinoma (T3N0M0, Fuhrman IV/IV)	Transperitoneal	Port site discomfort with solid mass. CT confirmation at 25 mo	Surgical excision, every 3-mo clinical and radiographic (chest X ray, CT) follow-up. No evidence of disease at 35 mo postnephrectomy
25	Renal cell carcinoma (morcellated specimen, stage not reported, Fuhrman IV/IV)	Transperitoneal	Abdominal masses identified on CT	Alpha-interferon immunotherapy. Patient died 8 mo postnephrectomy
26	Renal cell carcinoma (T2N0M0, Fuhrman III/IV)	Hand-assisted, transperitoneal	Clinically palpable with CT confirmation at 9 mo	Operative excision, biopsy, and immunotherapy referral
27	Renal cell carcinoma PT3a, II/IV	Retropertitoneal	Left lumbar pain 39 wk postnephrectomy with CT confirmation	External beam radiation with no further follow-up reported
<i>TCC</i>				
28	Ureteral TCC (T1NxMx, "high-grade")	Extraperitoneal	Clinically palpable with CT confirmation at 12 mo	Operative excision with negative pathologic margins and 18-mo follow-up
29	TCC (TNM not reported, "high grade" TCCa invasive into renal parenchyma with one positive hilar lymph node)	Extraperitoneal	Painful mass at trocar site, with CT confirmation at 3 mo	Ultrasound biopsy for confirmation. No other management reported
30	TCC T4bNxM0, grade II	Transperitoneal laparoscopic staging and biopsy	Palpable nodule "shortly after" biopsy	Open exploration with positive biopsy. Tumor involvement of urachus, anterior abdominal wall, and preaortic lymph nodes
31	TCC (stage not reported, "high-grade" TCCa invasion with small vascular focus of invasion)	"Laparoscopic" nephrectomy	Painful umbilical port site 8 mo postnephrectomy	Open positive biopsy with CT follow-up demonstrating residual local recurrence at renal fossa, along psoas muscle, and hepatic metastases. Patient referred for chemotherapy. No follow-up reported
<i>Pelvic lymph node dissection</i>				
32	LPLND for CaP (T3N1M0, grade II)	Transperitoneal	Clinically palpable at 6 mo	Aspiration cytologic confirmation with no other diagnostic or therapeutic maneuvers. Patient died 8 mo postlymphadenectomy
33	LPLND for TCC (T3N1M0, grade II)	Transperitoneal	Clinically palpable subcutaneous masses at multiple port sites, with CT confirmation	Observation secondary to previous post-LPLND failure of M-VAC, chemotherapy and external beam radiotherapy. Hepatic mass identified on CT. Patient died one mo after PSR recognition
34	TCC (T2NxM0, grade II (at time of LPLND) (T3N0M0, grade III) after open cystectomy and ureterosigmoidostomy	Transperitoneal	Right lower extremity edema 3 mo post cystectomy, with positive CT for right pelvic lymphadenopathy and 3 cm right superior port site mass	Open biopsy positive for TCCa. Patient refused chemotherapy and died three mo later
<i>Miscellaneous</i>				
35	Squamous cell carcinoma of the renal pelvis (T3N0M0)	Retropertitoneoscopic nephroureterectomy	Clinically palpable with CT confirmation at 6 mo	Surgical excision with mesh repair of aponeurotic defect. Disease free at 6-mo follow-up from excision
36	1. Metastatic small cell carcinoma to adrenal (TNM not reported) 2. Nonseminomatous germ cell tumor to the retroperitoneum. (TNM not reported)	Not reported	CT (adrenal lesion). Month not reported	Not reported. Each patient died within 6 mo after identification of PSR
37	Metastatic small cell carcinoma to adrenal (stage IIb small cell carcinoma of lung)	Transperitoneal	Clinically palpable with CT confirmation at 5 mo	Palliative external beam radiotherapy. Patient died 10 mo postadrenalectomy

Abbreviations: PSR, port site recurrence; TCC, transitional cell carcinoma; CT, computed tomography; LPLND, laparoscopic lymph node dissection; CaP, carcinoma of the prostate; TNM, tumor nodal metastatic; M-VAC, methotrexin vinblastin adriamycin cisplatin.



FIGURE 1 ■ Port site recurrence (white arrow) following retroperitoneal adrenalectomy for metastatic small cell carcinoma of the lung. Source: From Ref. 36.

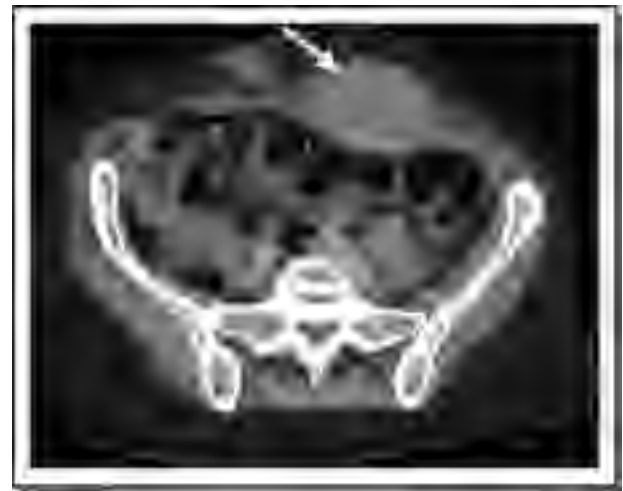

FIGURE 2 ■ Computed tomography image of port site recurrence (white arrow) following transperitoneal adrenalectomy for metastatic small cell carcinoma of the lung. Source: From Ref. 37.

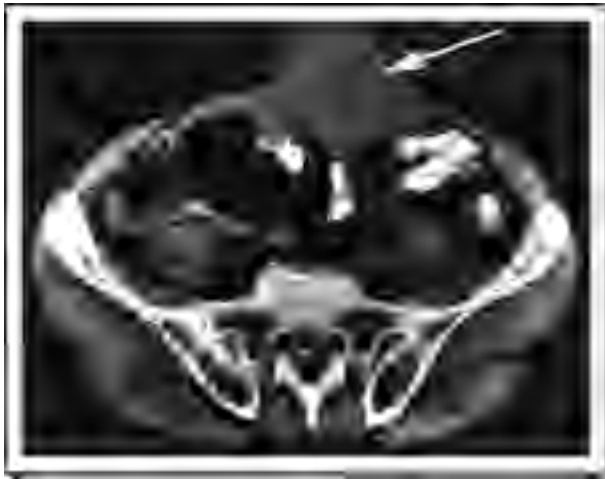

FIGURE 3 ■ Computed tomography image of port site recurrence at hand-port site following hand-assisted laparoscopic nephrectomy for renal cell carcinoma. Source: From Ref. 26.

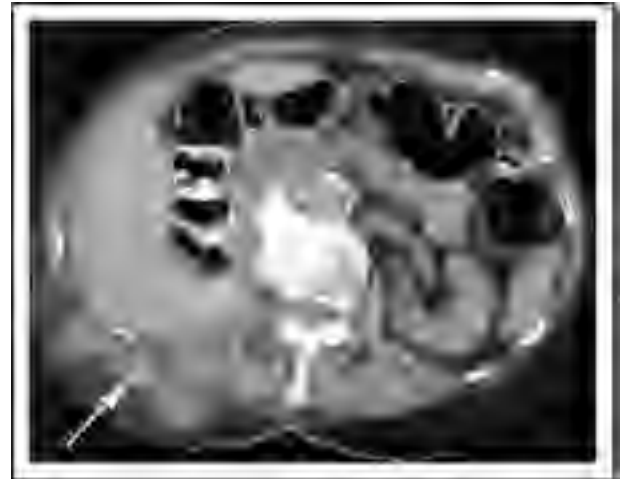

FIGURE 4 ■ Subcutaneous port site masses following extraperitoneal nephroureterectomy for ureteral transitional cell carcinoma. Source: From Ref. 28.

Long-term open versus laparoscopic nephrectomy comparison by Portis et al. demonstrates no significant differences in local or distant metastatic recurrence rates, with no wound or port site recurrence.

local excision and immunotherapy therapy (26). Finally, at 39 weeks post left retroperitoneoscopic radical nephrectomy, Iwamura et al. report the most recent abdominal wall recurrence in a patient with a primary T3a, Fuhrman grade II clear cell renal cell carcinoma. Importantly, tissue entrapment was not used in this case (27).

The exact incidence of laparoscopic port site recurrence following laparoscopic radical nephrectomy is not known. However, wound metastases following open radical nephrectomy for renal cell carcinoma are reported in approximately 0.4% (2 of 518) of cases (41). In open colon surgery for known cancer there is a 1.5% wound recurrence rate reported in the literature (42). In a retrospective multicenter study, with a mean follow-up of 19.2 months (range, 1–72; 51 with greater than two years follow-up), Cadeddu et al. reported no port site recurrence from laparoscopic nephrectomy for renal cell carcinoma in 157 cases (43).

Long-term open versus laparoscopic nephrectomy comparison by Portis et al. demonstrates no significant differences in local or distant metastatic recurrence rates, with no wound or port site recurrence (44).

Transitional cell carcinoma appears to be more biologically susceptible to soft tissue metastatic implantation (45) and port site recurrence (46). In the laparoscopic staging and treatment of transitional cell carcinoma there have been several reports of port site seeding (28–31,33,47). In three instances, port site recurrence developed after laparoscopic staging with a biopsy or laparoscopic pelvic lymph node dissection of a primary bladder tumor. In one of three cases related to nephrectomy, seeding developed in a patient with a tuberculous atrophic kidney containing unsuspected transitional cell carcinoma (29). Loss of entrapment sac integrity was cited as a possible predisposing confounding factor in this case. Another case of port site recurrence was reported after laparoscopic extraperitoneal nephroureterectomy was performed one week following ureteroscopy and ureteral stent placement (Fig. 4). At the time of laparoscopic nephroureterectomy, the ureteral stent was seen protruding outside of the collecting system, possibly seeding the perirenal tissues (28). The uncommon squamous cell carcinoma from urothelial origin has also demonstrated abdominal wall recurrence following retroperitoneoscopic nephroureterectomy (35).

Bangma et al. reported on the first patient with port site seeding after laparoscopic pelvic lymph node dissection for prostate cancer (32). Since their initial report, several additional cases have been reported, each after nonentrapped, piecemeal extraction of lymphatic tissues (31,33,34,48). In contrast, Cadeddu et al. found no cases of port site seeding after 372 cases of laparoscopic pelvic lymph node dissection. A review of a subset of 40 patients with positive pelvic lymph nodes for prostate cancer (at the time of laparoscopic pelvic lymph node dissection) revealed no port site seeding up to three years after surgery. Furthermore, there was no acceleration in the natural history of the disease after laparoscopic pelvic lymph node procedures (49,50). Although pelvic lymph node extractions for urothelial and prostatic carcinomas demonstrate port site recurrence, no laparoscopic prostatectomy procedures have demonstrated port site recurrence.

BASIC SCIENCE AND PREDISPOSING FACTORS

Port site recurrence appears to be multifactorial, influenced by four possible mechanisms: (i) technical factors; (ii) local wound factors; (iii) immune status; and (iv) biologic tumor behavior.

Technical Factors

The technical aspects of laparoscopy have received the most attention in the understanding of port site recurrence. Investigators have demonstrated that tumor cells may be deposited at the port site during laparoscopy either directly from contaminated instruments or indirectly via aerosolization of tumor cells in the insufflation gas (51–54). However, “gasless” laparoscopic models also demonstrate variable tumor cell dissemination or port site recurrences when compared to insufflated cases (55–58), potentially further implicating the peritoneal dissemination of malignant cells via the development of a pneumoperitoneum (59). Studies using a CO₂-pneumoperitoneum reflect a higher incidence of port site recurrence compared to gasless, or other non-CO₂ gas-induced working spaces (60–62). Thomas et al. demonstrated that expelled filtered port site carbon dioxide gas was free from aerosolized malignant cells, but found that every single laparoscopic instrument and trocar themselves had malignant cell contamination, suggesting that direct instrument contamination and not gas dispersion may be the mechanism for port site recurrence (63).

Indeed, contemporary data reflect that direct contamination and seeding are the likely mechanisms (64), as hematogenous and other models (including one renal cell carcinoma model) fail to reflect port site recurrences from pneumoperitoneum creation (65–68).

Tissue manipulation itself may have a significant impact on the rates of port site recurrence. Increased tissue manipulation from laparoscopic-assisted techniques, such as hand-assisted laparoscopic surgery, may also potentiate tumor seeding. The implications on port site recurrence that hand-assisted laparoscopic may demonstrate have been shown in a murine model, where laparoscopic-assisted subcostal splenectomy had a significantly higher port site recurrence rate versus open splenectomy (69). The authors cite increased tissue manipulation as a potential catalyst for wound recurrence. Although not significantly reported in the current literature, one recent renal cell carcinoma port site recurrence was reported at a hand-assisted laparoscopic site (26). Additionally, increased tissue manipulations in concert with “leaking” port sites have promoted implantation and growth of port site recurrences in another murine model (70).

Indeed, contemporary data reflect that direct contamination and seeding are the likely mechanisms, as hematogenous and other models (including one renal cell carcinoma model) fail to reflect port site recurrences from pneumoperitoneum creation.

Currently, if a patient with clinically localized renal cell carcinoma is found to have microscopically advanced disease, there is no effective adjunct therapy. As such, morcellation does not alter subsequent follow-up or treatment.

Inherent with tissue manipulation are entrapment and morcellation. All potentially cancerous tissue should be entrapped in an impermeable sack and the field well draped prior to morcellation or extraction (39,71). Morcellation of specimens for extraction has raised concerns about both accurate pathological staging and its contribution toward port site recurrence. Computed tomography has been proven to be an effective tool for planning surgery and reliably predicting pathological findings. The overall accuracy of computed tomography in staging renal cell carcinoma ranges from 72% to 90% (72–75). In a review of 172 renal tumors treated with open radical nephrectomy, Shalhav et al. correlated the preoperative computed tomography-based clinical stage with the final pathological tumor stage. They found one patient (0.6%) to be understaged and seven (4%) overstaged by preoperative computed tomography. They concluded that clinical computed tomography staging of low-stage renal tumors is reliable and tends to over stage rather than under stage renal tumors (76).

Currently, if a patient with clinically localized renal cell carcinoma is found to have microscopically advanced disease, there is no effective adjunct therapy. As such, morcellation does not alter subsequent follow-up or treatment.

The long-term follow-up in laparoscopic series where kidneys are morcellated compared to open radical nephrectomy shows equivalent cancer free survival (77,78). When pathological staging is required, the specimen may be removed intact through a small, low midline, or Pfannenstiel incision.

Local Wound Factors

Local trocar-induced tissue trauma may itself pose an inherent risk to port site recurrence. Formal excision of laparoscopic port sites has demonstrated an actual increase in wound metastases in one model (79). Notwithstanding, the intact peritoneum seems to provide a barrier to tumor cell implantation. Peritoneal trauma has demonstrated tumor ingrowth at damaged surfaces compared to nontraumatized peritoneal sites (80).

When controlling for anesthesia alone, prolonged (30 minutes), low-pressure (6 mmHg) pneumoperitoneal studies demonstrate not only peritoneal damage (81,82), but also adhesion of cancer cells to the peritoneal basal layer (81). Mathew et al. demonstrated a possible synergistic effect of both peritoneal injury (with port site placement) in concert with pneumoperitoneum (83). Rats undergoing isolated laparotomy after purposeful abdominal malignant cellular dissemination had a statistically less histologic wound recurrence when compared to the same model undergoing laparoscopy. These observations may then suggest that obvious peritoneal disruption coupled with creation of a pneumoperitoneum, predispose the potential adhesion and ingrowth of tumor cells.

Immune Response

Various peritoneal immune responses are noted with both open laparotomy and laparoscopic techniques. Authors have suggested that CO₂-pneumoperitoneum diminishes macrophage-secreted tumor necrosis factor (84,85), depressing peritoneal cell-mediated immunity and increasing tumor implantation (84). Despite these findings, Lee et al. demonstrated that a full laparotomy performed in a sealed CO₂ chamber had similar lymphocyte proliferation suppression when compared to room-air-exposed incisions (86). These findings suggest that the incisional size, and not the CO₂ environment, depress peritoneal immunity.

Further work on the importance of peritoneal immunity is demonstrated by Neuhaus et al., where intraperitoneal injection of endotoxin 18 hours prior to laparoscopy decreased tumor growth and port site recurrence. This was challenged against the null effects of systemically injected cyclosporin (87).

To date, the effects of local wound and peritoneal immunity are poorly understood, but may be a significant variable toward port site recurrence.

To date, the effects of local wound and peritoneal immunity are poorly understood, but may be a significant variable toward port site recurrence.

The biology of the primary lesion, along with the inoculum size of malignant cells deposited to the trocar site, are also possible sources of port site recurrence.

Tumor Behavior

The biology of the primary lesion, along with the inoculum size of malignant cells deposited to the trocar site, are also possible sources of port site recurrence (88,89).

Cases that support this theory are noted previously in this manuscript. For example, the biologic susceptibility of transitional cell carcinoma to local and ectopic recurrence likely predisposes these tumors to port site recurrence. Squamous cell carcinoma arising from the urothelium is also known to hold aggressive biologic characteristics

TABLE 2 ■ Port Site Recurrence Prevention

Avoid resection and excision of tissue in face of carcinomatosis
 Ascitic fluid sent for cytology should be isolated from all wounds
 Minimize direct tumor handling to prevent iatrogenic tumor violation
 Ensure wide en bloc dissection of tumor and surrounding tissues
 All tissues should be placed within an impermeable laparoscopic sac prior to morcellation or tissue extraction
 Redrape port sites at the time of tissue removal
 All possible contaminated instrumentation should be removed from the newly towel-draped operative field
 Change the surgeons' and technicians' gloves prior to formal peritoneal closure

(35). Metastatic disease, regardless of etiology, likely demonstrates biologic activity that is more aggressive. For example, chemoresistant cancers, which have metastasized, may carry a biologic predilection for tissue implantation and growth (36). This argument is also demonstrated with metastatic lesions to the adrenal, where the only port site recurrence cases from this organ are subsequent to metastatic adrenal lesion excision (36,37).

PORT SITE RECURRENCE PREVENTION

Several steps should be taken in order to prevent port site seeding and tumor spillage (Table 2):

- The historical developments of basic cancer surgery principles must be followed; experience with laparoscopic oncology is paramount—as port site recurrence has been shown to fall with experience (86).
- Ascitic fluid suspicious for malignancy should be sent for cytology with exhaustive efforts to keep this fluid away from fresh surgical wounds.
- Direct handling of the tissue must be minimized and attempts made to prevent violation of the tumor.
- Wide en bloc dissection should be performed to avoid tumor spillage and to obtain appropriate surgical margins.
- All potentially cancerous tissue should be entrapped in an impermeable sack (examined for perforations prior to abdominal placement) and the field draped prior to laparoscopically monitored morcellation or extraction (24,40,71).
- During tissue delivery, all possible contaminated instrumentation should be removed from the newly towel-draped operative field, the surgeon's gloves exchanged for new, and formal peritoneal closure performed (90).
- Potential intraperitoneal immune or adhesion modifiers such as endotoxin (87), heparin (91,92) or helium pneumoperitoneum (93), povidine iodine or taurolidine (92,94–96) may prove beneficial in the prevention of port site recurrence in future.

PERCUTANEOUS ABLATION

With the advent of newer minimally invasive techniques such as percutaneous ablative mechanisms, recurrence at needle tract sites may occur.

Although local recurrence of renal cell carcinoma has been reported following percutaneous radio frequency ablation (97), no radio frequency-, cryo-, or microwave-probe tract recurrences have been reported in the urologic literature to date.

In addition, hepatocellular carcinoma seeding has been reported following radio frequency ablation and subcutaneous needle-tract recurrence at a paracentesis site in a patient with ovarian carcinoma (98–100). While the incidence of access site seeding with needle ablative technologies, in the treatment of malignancy, appears to be low these case reports support the theoretical possible for access site contamination and should factor into the surgeons decision to use minimally invasive techniques.

Although local recurrence of renal cell carcinoma has been reported following percutaneous radio frequency ablation, no radio frequency-, cryo-, or microwave-probe tract recurrences have been reported in the urologic literature to date.

SUMMARY

- Port site recurrence of malignancy is a recognized entity that carries a poor prognosis.
- Work on basic science, prevention, and technique refinement has been performed and is ongoing.
- Implantation of malignant cells into the port site wound are likely secondary to primary tumor characteristics, traumatic tissue handling, slipping or leaking trocars, unrecognized metastases or contaminated ascites, and poor tissue retrieval or extraction techniques.
- Preventive techniques including radiographic staging, surgical expertise, trocar fixation, careful tissue handling, minimization of abdominal wall or peritoneal trauma, tissue isolation and extraction, and peritoneal closure are paramount.
- Future peritoneal or trocar-site cytotoxic or immunomodulating irrigants may prove beneficial and are under investigation.

REFERENCES

1. Lane TM, Cook AJ. Port-site metastasis after laparoscopic cholecystectomy for benign disease. *J Laparoendosc Adv Surg Tech A* 1999; 9(3):283–284.
2. Z'graggen K, Birrer S, Maurer CA, Wehrli H, Klaiber C, Baer HU. Incidence of port site recurrence after laparoscopic cholecystectomy for preoperatively unsuspected gallbladder carcinoma. *Surgery* 1998; 124(5):831–838.
3. Iuppa A, Petralia GA, Sciuto A, Romeo G. Abdominal wall metastasis of pancreatic adenocarcinoma following laparoscopy. (Italian/Abstract). *Annali Italiani di Chirurgia* 1996; 67(2):265–269.
4. Barsoum GH, Windsor CW. Parietal seeding of carcinoma of the gallbladder after laparoscopic cholecystectomy. *Br J Surg* 1992; 79(8):846.
5. Drouard F, Delamarre J, Capron JP. Cutaneous seeding of gallbladder cancer after laparoscopic cholecystectomy. *N Engl J Med* 1991; 325(18):1316.
6. Carlson NL, Krivak TC, Winter WE, Macri CI. Port site metastasis of ovarian carcinoma remote from laparoscopic surgery for benign disease. *Gynecol Oncol* 2002; 85(3):529–531.
7. Stocchi L, Nelson H. Wound recurrences following laparoscopic-assisted colectomy for cancer. *Arch Surg* 2000; 135(8):948–958.
8. Paolucci V, Schaeff B, Schneider M, Gutt C. Tumor seeding following laparoscopy: international survey. *World J Surg* 1999; 23:989–995.
9. Pearlstone DB, Mansfield PF, Curley SA, Kumparatana M, Cook P, Feig BW. Laparoscopy in 533 patients with abdominal malignancy. *Surgery* 1999; 125(1):67–72.
10. Shoup M, Brennan MF, Martin K, Gillern S, McMahon R, Conlon K. Port site metastasis after diagnostic laparoscopy for upper gastrointestinal tract malignancies: an uncommon entity. *Ann Surg Oncol* 2002; 9(7):632–636.
11. Feliciotti F, Paganini AM, Guerrieri M, Sanctis A, Campagnacci R, Lezoche E. Results of laparoscopic vs. open resections for colon cancer in patients with a minimum follow-up of 3 years. *Surg Endosc* 2002; 16(8):1158–1161.
12. Pearlstone DB, Deig BW, Mansfield PF. Port site recurrences after laparoscopy for malignant disease. *Semin Surg Oncol* 1999; 16(4):307–312.
13. Canis M, Rabischong B, Botchorishvili R, et al. Risk of spread of ovarian cancer after laparoscopic surgery. *Curr Opin Obstet Gynecol* 2001; 13(1):9–14.
14. Canis M, Rabischong B, Houille C, et al. Laparoscopic management of adnexal masses: a gold standard? *Curr Opin Obstet Gynecol* 2002; 14(4):423–428.
15. Morice P, Viala J, Pautier P, Lhomme C, Duvillard P, Castaigne D. Port-site metastasis after laparoscopic surgery for gynecologic cancer. A report of six cases. *J Reprod Med* 2000; 45(10):837–840.
16. Tjalma WA, Winter-Roach BA, Rowlands P, De Barros LA. Port-site recurrence following laparoscopic surgery in cervical cancer. *Int J Gynecol Cancer* 2001; 11(5):409–412.
17. Gregor H, Sam CE, Reinhaller A, Joura EA. Port site metastasis after laparoscopic lymph node staging of cervical carcinoma. *J Am Assoc Gynecol Laparosc* 2001; 8(4):591–593.
18. Lane G, Tay J. Port-site metastasis following laparoscopic lymphadenectomy for adenosquamous carcinoma of the cervix. *Gynecol Oncol* 1999; 74(1):130–133.
19. Picone O, Aucouturier JS, Louboutin A, Coscas Y, Camus E. Abdominal wall metastasis of a cervical adenocarcinoma at the laparoscopic trocar insertion site after ovarian transposition: case report and review of the literature. *Gynecol Oncol* 2003; 90(2):446–449.
20. Kohlberger PD, Edwards L, Collins C, Milross C, Hacker NF. Laparoscopic port-site recurrence following surgery for a stage IB squamous cell carcinoma of the cervix with negative lymph nodes. *Gynecol Oncol* 2000; 79(2):324–326.
21. Muntz HG, Goff BA, Madsen BL, Yon JL. Port-site recurrence after laparoscopic surgery for endometrial carcinoma. *Obstet Gynecol* 1999; 93(5 Pt 2):807–809.
22. Jorgensen JO, McCall JL, Morris DL. Port site seeding after laparoscopic ultrasonographic staging of pancreatic carcinoma. *Surgery* 1995; 117(1):118–119.
23. Ikramuddin S, Lucas J, Ellison EC, Schirmer WJ, Melvin WS. Detection of aerosolized cells during carbon dioxide laparoscopy. *J Gastrointest Surg* 1998; 2(6):580–583.
24. Fentie DD, Barrett PH, Taranger LA. Metastatic renal cell cancer after laparoscopic radical nephrectomy: long-term follow up. *J Endourol* 2000; 14:407–411.
25. Castilho LN, Fugita OEH, Mitre AI, Arap S. Port site tumor recurrences of renal cell carcinoma after videolaparoscopic radical nephrectomy. *J Urol* 2001; 165(2):519.
26. Chen YT, Yang SSD, Hsieh CH, Wang CC. Hand port-site metastasis of renal-cell carcinoma following hand-assisted laparoscopic radical nephrectomy: case report. *J Endourol* 2003; 17(9):771–773.
27. Iwamura M, Tsumura H, Matsuda D, Kurosaka S, Yoshida K, Baba S. Port site recurrence of renal cell carcinoma following retroperitoneoscopic radical nephrectomy with manual extraction without using entrapment sac or wound protector. *J Urol* 2004; 171:1234–1235.
28. Ong AM, Bhayani SB, Pavlovich CP. Trocar site recurrence after laparoscopic nephroureterectomy. *J Urol* 2003; 170(4):1301.
29. Otani M, Schinichiro I, Tsuji Y. Port site metastasis after laparoscopic nephrectomy: unsuspected transitional cell carcinoma within a tuberculous atrophic kidney. *J Urol* 1999; 162:486–487.
30. Anderson JR, Steven K. Implantation metastasis after laparoscopic biopsy of the bladder cancer. *J Urol* 1995; 153:1047.
31. Ahmed I, Shaikh NA, Kapadia CR. Track recurrence of renal pelvic transitional cell carcinoma after laparoscopic nephrectomy. *Br J Urol* 1998; 81:319.
32. Bangma CH, Kirkels WJ, Chadha S, Schroder FH. Cutaneous metastasis following laparoscopic pelvic lymphadenectomy for prostate cancer. *J Urol* 1995; 153:1635.
33. Stolla V, Rossi D, Bladou F, et al. Subcutaneous metastasis after coelioscopic lymphadenectomy for vesical urothelial carcinoma. *Eur Urol* 1994; 26:342.
34. Altieri V, D'Armiento M, DeSio M, Ucciero G, Lotti T, Graziotti PP. Can laparoscopic lymphadenectomy disseminate bladder cancer? *Acta Urologica Italica* 1998; 12(4):231–233.

35. Matsui Y, Ohara H, Ichioka K, Terada N, Yoshimura K, Terai A. Abdominal wall metastasis after retroperitoneoscopic assisted total nephroureterectomy for renal pelvic cancer. *J Urol* 2004; 171:793.
36. Rassweiler J, Tsivian A, Kumar AV, et al. Oncologic safety of laparoscopic surgery for urologic malignancy: experience with more than 1,000 operations. *J Urol* 2003; 169(6):2072–2075.
37. Chen B, Zhou M, Cappelli MC, Wolf JS. Port site, retroperitoneal, and intra-abdominal recurrence after laparoscopic adrenalectomy for apparently isolated metastasis. *J Urol* 2002; 168(6):2528–2529.
38. Dunn MD, Portis AJ, Shalhav AL, et al. Laparoscopic versus open radical nephrectomy: a 9-year experience. *J Urol* 2000; 164:1153–1159.
39. Barrett PH, Fentie DD, Taranger LA. Laparoscopic radical nephrectomy with morcellation for renal cell carcinoma: the Saskatoon experience. *Urology* 1998; 52:23–28.
40. Shalhav AL, Dunn MD, Portis AJ, Elbahnasy AM, McDougall EM, Clayman RV. Laparoscopic nephroureterectomy for upper tract transitional cell cancer: the Washington University Experience. *J Urol* 2000; 163(4):1100–1104.
41. Uson AC. Tumor recurrence in the renal fossa and/or abdominal wall after radical nephrectomy for renal cell carcinoma. *Prog Clin Biol Res* 1982; 100:549.
42. Reilly WT, Nelson H, Schroeder G, Weiland HS, Bolton J, O'Connell MJ. Wound recurrence following conventional treatment for colorectal cancer. A rare but perhaps underestimated problem. *Dis Colon Rectum* 1996; 39:200.
43. Cadeddu JA, Yoshinari O, Clayman RV, et al. Laparoscopic nephrectomy for renal cell cancer: evaluation of efficacy and safety: a multicenter experience. *Urology* 1998; 52:773–777.
44. Portis AJ, Yan Y, Landman J, et al. Long-term follow-up after laparoscopic radical nephrectomy. *J Urol* 2002; 167(3):1257–1262.
45. Hita Rosino E, Lopez Cubillana P, Nieto Olivares A, Torroba Caron M, Gomez Gomez G. Bladder tumor. Presentation of 2 patients with soft tissue involvement (Spanish/ Abstract). *Arch Exp Urol* 1997; 50(5):532–534.
46. Elbahnasy AM, Hoenig DM, Shalhav A, McDougall EM, Clayman RV. Laparoscopic staging of bladder tumor: concerns about port site metastases. *J Endourol* 1998; 12(1):55–59.
47. Elbahnasy AM, Hoenig DM, Shalhav A, et al. Laparoscopic staging of bladder tumor: concerns about port site seeding. *J Endourol* 1998; 12:55–57.
48. Dorrance HR, O'Dwyer PJ. Cutaneous metastasis following laparoscopic pelvic lymphadenopathy for prostatic carcinoma. *J Urol* 1996; 156(2):484–485.
49. Kavoussi LR, Sosa E, Chandoke P, et al. Complications of laparoscopic pelvic lymph node dissection. *J Urol* 1993; 149:322–328.
50. Cadeddu J, Schulam P, Moore RG, et al. Effects of laparoscopic pelvic lymphadenectomy on the natural history of D1 prostate cancer (abstract). *J Endourol* 1996; 10:585.
51. Neuhaus SJ, Texler M, Hewett PJ, Watson DI. Port-site metastasis following laparoscopic surgery. *Br J Surg* 1998; 85:735–741.
52. Schaeff B, Paolucci V, Thomopoulos J. Port site recurrences after laparoscopic surgery. A review. *Digest Surg* 1998; 15:124–134.
53. Whelan RL, Lee SW. Review of investigations regarding the etiology of port site tumor recurrence. *J Laparoendosc Adv Surg Tech* 1999; 9:1–6.
54. Wittich P, Marquet RL, Kazemier G, Bonjer HJ. Port-site metastases after CO(2) laparoscopy. Is aerosolization of tumor cells a pivotal factor? *Surg Endosc* 2000; 14(2):189–192.
55. Mathew G, Watson DI, Ellis T, De Young N, Rofo AM, Jamieson GG. The effect of laparoscopy on the movement of tumor cells and metastasis to surgical wounds. *Surg Endosc* 1997; 11(12):1163–1166.
56. Moreira H, Yamaguchi T, Wexner S, et al. Effect of pneumoperitoneal pressure on tumor dissemination and tumor recurrence at port-site and midline incisions. *Am Surgeon* 2001; 67(4):369–373.
57. Gutt CN, Riemer V, Kim ZG, Erceg J, Lorenz M. Impact of laparoscopic surgery on experimental hepatic metastases. *Br J Surg* 2001; 88(3):371–375.
58. Agostini A, Robin F, Aggerbeck M, Jais JP, Blanc B, Lecuru F. Influence of peritoneal factors on port-site metastases in a xenograft ovarian cancer model. *BJOG* 2001; 108(8):809–812.
59. Koster S, Melchert F, Volz J. Effect of CO2 pneumoperitoneum on intraperitoneal tumor growth in the animal model (abstract.) *Geburtshilfe und Frauenheilkunde* 1996; 56(9):458–461.
60. Jacobi CA, Wenger FA, Ordemann J, Gutt C, Sabat R, Muller JM. Experimental study of the effect of intra-abdominal pressure during laparoscopy on tumor growth and port site metastasis. *Br J Surg* 1998; 85(10):1419–1422.
61. Hopkins MP, Dulai RM, Occhino A, Holda S. The effects of carbon dioxide pneumoperitoneum on seeding of tumor in port sites in a rat model. *Am J Obstet Gynecol* 1999; 181(6):1329–1333.
62. Mathew G, Watson DI, Rofo AM, Ellis T, Jamieson GG. Adverse impact of pneumoperitoneum on intraperitoneal implantation and growth of tumor cell suspension in an experimental model. *Aust NZ J Surg* 1997; 67(5):289–292.
63. Thomas WM, Eaton MC, Hewett PJ. A proposed model for the movement of cells within the abdominal cavity during CO2 insufflation and laparoscopy. *Aust NZ J Surg* 1996; 66(2):105–106.
64. Wilkinson NW, Shapiro AJ, Harvey SB, Stack RS, Cornum RL. Port-site recurrence reproduced in the VX-2 rabbit carcinoma model: an in vivo model comparing laparoscopic port sites and open incisions. *J Soc Laparoendosc Surg* 2001; 5(3):221–226.
65. Iwanaka T, Arya G, Ziegler MM. Mechanism and prevention of port-site tumor recurrence after laparoscopy in a murine model. *J Pediatr Surg* 1998; 33(3):457–461.
66. Brundell S, Ellis T, Dodd T, Watson DI, Hewett PJ. Hematogenous spread as a mechanism for the generation of abdominal wound metastases following laparoscopy. *Surg Endosc* 2002; 16(2):292–295.
67. Tsivian A, Shtabsky A, Issakov J, Gutman M, Sidi AA, Szold A. The effect of pneumoperitoneum on dissemination and scar implantation of intra-abdominal tumor cells. *J Urol* 2000; 164(6):2096–2098.
68. Lecuru F, Agostini A, Camatte S, et al. Impact of pneumoperitoneum on tumor growth. *Surg Endosc* 2002; 16(8):1170–1174.

69. Lee SW, Whelan RL, Southall JC, Bessler M. Abdominal wound tumor recurrence after open and laparoscopic-assisted splenectomy in a murine model. *Dis Colon Rectum* 1998; 41(7):824–831.
70. Tseng LN, Berends FJ, Wittich P, et al. Port-site metastases. Impact of local tissue trauma and gas leakage. *Surg Endosc* 1998; 12(12):1377–1380.
71. Urban DA, Kerbl K, McDougall EM, et al. Organ entrapment and renal morcellation: permeability studies. *J Urol* 1993; 150:1792.
72. London NM, Messios N, Kinder RB, et al. A prospective study of the value of conventional computed tomography, dynamic computed tomography, ultrasonography and arteriography for staging renal cell carcinoma. *Br J Urol* 1989; 64:209–217.
73. Johnson CD, Dunnick NR, Choan RC, Illescas FF. Renal adenocarcinoma. Computed tomography staging of 100 tumors. *Am J Roentgenol* 1987; 148:59–63.
74. Zagoria RJ, Bechtold RE, Dyer RB. Staging of renal adenocarcinoma: role of various imaging procedures. *Am J Roentgenol* 1995; 164:363–370.
75. Parks CM, Kelley MJ. Staging renal cell carcinoma. *Clin Radiol* 1994; 49:223–230.
76. Shalhav AL, Leibovitch I, Lev R, et al. Is laparoscopic radical nephrectomy with specimen morcellation acceptable cancer surgery? *J Endourol* 1998; 12:225–257.
77. Ono Y, Kinukawa T, Hattori R, et al. Long-term outcome of laparoscopic radical nephrectomy for renal cell carcinoma (abstract). *J Urol* 2000; 163:81.
78. Chan DY, Cadeddu JA, Jarrett TW, et al. Laparoscopic radical nephrectomy: cancer control in renal carcinoma. *J Urol* 2001; 166:2095.
79. Watson DI, Ellis T, Leeder PC, Neuhaus SJ, Dodd T, Jamieson GG. Excision of laparoscopic port sites increases the likelihood of wound metastases in an experimental model. *Surg Endosc* 2003; 17(1):83–5.
80. Van den Tol PM, Rossen EE, Eijck CH, et al. Reduction of peritoneal trauma by using non-surgical gauze leads to less implantation metastasis of spilled tumour cells. *Ann Surg* 1998; 227:242–248.
81. Volz J, Koster S, Spacek Z, Paweletz N. The influence of pneumoperitoneum used in laparoscopic surgery on an intraabdominal tumor growth. *Cancer* 1999; 86:770–774.
82. Volz J, Koster S, Spacek Z, Paweletz N. Characteristic alterations of the peritoneum after carbon dioxide pneumoperitoneum. *Surg Endosc* 2000; 13:611–614.
83. Mathew G, Watson DI, Rofo AM, Baigrie CF, Ellis T, Jamieson GG. Wound metastases following laparoscopic and open surgery for abdominal cancer in a rat model. *Br J Surg* 1996; 83(3):1087–1090.
84. Matthew G, Watson DI, Ellis TS, et al. The role of peritoneal immunity and the tumor-bearing state on the development of wound and peritoneal metastases after laparoscopy. *Aust NZ J Surg* 1999; 69:14–18.
85. Chekan EG, Nataraj C, Clary EM, et al. Intraperitoneal immunity and pneumoperitoneum. *J Surg Endosc* 1999; 13:1135–1138.
86. Lee SW, Southall JC, Gleason NR, et al. Time course of differences in lymphocyte proliferation rates after laparotomy vs. CO₂ insufflation. *Surg Endosc* 2000; 14:145–148.
87. Neuhaus SJ, Watson DI, Ellis T, et al. The effect of immune enhancement and suppression on the development of laparoscopic port site metastases. *Surg Endosc* 2000; 14:439–43.
88. Kavic SM, Basson MD. Environmental factors of temperature, humidity, serum accumulation, and cell seeding increase colon cancer cell in vitro, with partial characterization of the serum component responsible for pressure-stimulated adhesion. *J Surg Res* 2001; 98(2):89–96.
89. Steinert R, Lippert H, Reymond MA. Tumor cell dissemination during laparoscopy: prevention and therapeutic opportunities. *Digest Surg* 2002; 19(6):464–472.
90. Agostini A, Robin F, Jais JP, et al. Peritoneal closure reduces port site metastases: results of an experiment in a rat ovarian cancer model. *Surg Endosc* 2002; 16(2):289–291.
91. Jacobi CA, Ordemann J, Bohm B, Zieren HU, Sabat R, Muller JM. Inhibition of peritoneal tumor cell growth and implantation in laparoscopic surgery in a rat model. *Am J Surg* 1997; 174(3):359–363.
92. Jacobi CA, Peter FJ, Wenger FA, Ordemann J, Muller JM. New therapeutic strategies to avoid intra- and extraperitoneal metastases during laparoscopy: results of a tumor model in the rat. *Digest Surg* 1999; 16(5):393–399.
93. Gupta A, Watson DI, Ellis T, Jamieson GG. Tumor implantation following laparoscopy using different insufflation gases. *Aust NZ J Surg* 2002; 72:254–257.
94. Wenger FA, Kilian M, Braumann C, et al. Effects of taurolidine and octreotide on port site and liver metastasis after laparoscopy in an animal model of pancreatic cancer. *Clin Exp Metastasis* 2002; 19(2):169–173.
95. Lee SW, Gleason NR, Bessler M, Whelan RL. Peritoneal irrigation with povidone-iodine solution after laparoscopic-assisted splenectomy significantly decreases port-tumor recurrence in a murine model. *Dis Colon Rectum* 1999; 42(3):319–326.
96. Jacobi CA, Wildbrett P, Volk T, Muller JM. Influence of different gasses and intraperitoneal instillation of antiadherent or cytotoxic agents on peritoneal tumor cell growth and implantation with laparoscopic surgery in a rat model. *Surg Endosc* 1999; 13(10):1021–1025.
97. McLaughlin CA, Chen MY, Torti FM, Hall MC, Zagoria RJ. Radiofrequency ablation of isolated local recurrence of renal cell carcinoma after radical nephrectomy. *Am J Roentgenol* 2003; 181(1):93–94.
98. Decker GA, Gores GJ, Roberts LR. Tumor seeding complicating radiofrequency ablation of hepatocellular carcinoma. *J Hepatol* 2003; 38(5):692.
99. Llovet JM, Vilana R, Bru C, et al. Increased risk of tumor seeding after percutaneous radio frequency ablation for single hepatocellular carcinoma. *Hepatology* 2001; 33(5):1124–1129.
100. Kruitwagen RF, Swinkels BM, Keyser KG, Doesburg WH, Schijf CP. Incidence and effect on survival of abdominal wall metastases at trocar or puncture sites following laparoscopy or paracentesis in women with ovarian cancer. *Gynecol Oncol* 1996; 60(2):322–324.

SECTION

VI

PEDIATRIC LAPAROSCOPY

LAPAROSCOPY IN THE CHILD: SPECIFIC ISSUES

Craig A. Peters

Department of Urology, Children's Hospital, Harvard Medical School, Boston, Massachusetts, U.S.A.

- | | |
|--|--|
| <ul style="list-style-type: none"> ■ INDICATIONS ■ ONCOLOGY ■ PATIENT PREPARATION ■ PORT POSITIONING AND SETUP ■ CANNULAE ■ HAND INSTRUMENTS ■ ACCESS <ul style="list-style-type: none"> Veress Access Open Access Port Site Handling | <ul style="list-style-type: none"> ■ MANIPULATION PRINCIPLES ■ RETROPERITONEAL ACCESS ■ PHYSIOLOGY AND ANESTHETIC CONSIDERATIONS ■ COMPLICATIONS <ul style="list-style-type: none"> Ventriculoperitoneal Shunts ■ SURGICAL COMPLICATIONS ■ POSTOPERATIVE COURSE ■ SUMMARY ■ REFERENCES |
|--|--|

The distinction between adult and pediatric urologic laparoscopy begins with divergent indications, reflecting the different patterns of urologic disease between adults and children. The need for laparoscopic procedures in pediatric urologic practice is different from adults, with some elements of overlap.

As the potential for reconstructive pediatric laparoscopy has emerged, it has been evident that the dispersion of laparoscopic skills into complex reconstruction by pediatric urologists has been limited.

The ability to gain sufficient case numbers to become expert at complex laparoscopy in a reasonable period of time will be difficult and the collaboration of adult and pediatric surgeons will be important to permit development of these skills in the pediatric realm.

INDICATIONS

The distinction between adult and pediatric urologic laparoscopy begins with divergent indications, reflecting the different patterns of urologic disease between adults and children. The need for laparoscopic procedures in pediatric urologic practice is different from adults, with some elements of overlap.

Most of the procedures being performed are based on an integration of diagnostic and operative laparoscopy for the undescended testis. Procedures involving extirpative surgery are almost always for benign disease of congenital origin. Overlap is emerging, mostly in areas of reconstructive urology. While these differences may discourage sharing of experience, the basic principles are similar and the adult urologist with significant laparoscopic experience can facilitate the development of their pediatric colleagues' laparoscopic expertise. Similarly, the pediatric urologist can bring experience with delicate reconstruction to the adult arena.

As the potential for reconstructive pediatric laparoscopy has emerged, it has been evident that the dispersion of laparoscopic skills into complex reconstruction by pediatric urologists has been limited.

The reasons for this are multiple but may largely stem from different practice patterns among adult and pediatric urologists that have limited the number of surgeons willing and able to climb the learning curve for reconstructive work.

The pediatric urologist's practice patterns pose a challenge to the development of laparoscopic skills and experience in that even with a busy practice the fraction of cases that may ever be performed laparoscopically will remain limited. In academic departments, there might be surgeons performing only one or two operations in adult practice, while in pediatric groups nearly all will routinely perform up to 20 different types of procedures from hypospadias to pyeloplasty.

The ability to gain sufficient case numbers to become expert at complex laparoscopy in a reasonable period of time will be difficult and the collaboration of adult and pediatric surgeons will be important to permit development of these skills in the pediatric realm.

ONCOLOGY

Very little laparoscopic work has been performed in any pediatric oncologic applications, yet there should be the potential for such application in the future. For the common neoplasms, however, there will likely be substantial limitations due to the frequent large size of pediatric tumors, particularly Wilms' and neuroblastoma. Adrenal tumors have

been resected laparoscopically with good results in children, usually neuroblastoma (1–3). Genital tumors such as gonadoblastoma have been resected laparoscopically, although often when occult in dysgenetic gonads (4). There is likely a role for laparoscopy as more screening programs directed toward at-risk populations for neuroblastoma or Wilms' tumor in which small volume tumors may be more often detected. Diagnostic or staging applications may also see some development as well. This might be particularly suitable for contralateral exploration of the kidney in Wilms' tumor or in prechemotherapy biopsy to permit more accurate diagnosis and staging.

The evolution of pediatric urologic laparoscopy will continue at perhaps a slower pace than that in adult urology, but it should continue to do so. Much of the current work is being carried out by pediatric surgeons who also perform a variety of intra-abdominal laparoscopic procedures and thereby can develop their skills and experience more rapidly. This may limit the role the pediatric urologists play in the overall development of this field and active participation should be encouraged.

PATIENT PREPARATION

There is little specific preparation needed for children to undergo laparoscopy, although recognition of the smaller operative spaces and the occasional physiological limitations of some children are important.

Children to undergo any possible pelvic surgery laparoscopically, including orchiopexy, antireflux surgery or vesical procedures, should have a limited bowel preparation aimed at debulking the rectosigmoid. This can be efficiently performed using a liquid diet the day before and a bisacodyl suppository or oral tablet the night before the procedure.

While laparoscopy is well tolerated by most children and infants, there is the potential for respiratory compromise due to the elevated intra-abdominal pressures.

Children with limited respiratory reserve such as former premature infants with a history of bronchopulmonary dysplasia, those with restrictive thoracic conditions, and very young infants may show sensitivity to the pneumoperitoneum. They have a very limited ability to maintain adequate oxygenation when intra-abdominal pressure is increased and may show desaturation with increased pressures. These risks may be anticipated and often are adequately controlled by limiting pneumoperitoneum pressures, but if there is concern, preoperative evaluation should be obtained to assess the degree of limitation. Similarly, in children with congenital cardiac anomalies, preoperative evaluation is useful, although we have rarely seen any clinically apparent compromise.

While laparoscopy is well tolerated by most children and infants, there is the potential for respiratory compromise due to the elevated intra-abdominal pressures.

PORT POSITIONING AND SETUP

Port placement is critical for efficient performance of all procedures and in children this is perhaps even more critical as there is less room for maneuvering. Port positions depend upon the procedure and the anatomy of the patient. Location should be in proportion to the size of the patient rather than determined by any arbitrary set distances between ports.

While each type of surgery requires a distinctive port setup, the general principle of a symmetrical array of working ports around the camera-operative site line should be adhered to as much as possible. For example, port placement for transperitoneal pyeloplasty would involve an umbilical port for the camera and working ports in the midline between xyphoid and umbilicus and in the ipsilateral lower quadrant in the mid-clavicular line (Fig. 1). This offers a symmetric alignment toward the ureteropelvic junction to permit the most efficient working arrangement. In the smaller spaces in children, the effect of one port that is asymmetric may be significant and very troublesome in the performance of the procedure. When the operative field is wide, as it might be for a total ureterectomy, some compromise is needed. In those cases, one would give preference to the orientation for the most difficult aspect of the procedure. In the case of total nephroureterectomy, the exposure and access to the renal hilum is the most important part of the procedure, so the port alignment should favor that area, rather than the distal ureter, which may often be mobilized up to an accessible position. Occasionally a fourth port may be needed to complete the operation.

The arrangement of patient, surgeon, and surgical team follows similar principles as with adult surgery, although the small patient size offers some potential advantages.

Port placement is critical for efficient performance of all procedures. In children this is perhaps even more critical as there is less room for maneuvering. Port positions depend upon the procedure and the anatomy of the patient. Location should be in proportion to the size of the patient rather than determined by any arbitrary set distances between ports.

The arrangement of patient, surgeon, and surgical team follows similar principles as with adult surgery, although the small patient size offers some potential advantages.



FIGURE 1 ■ Port placement for transperitoneal laparoscopic pyeloplasty. The camera port is in the umbilicus while the working ports are in the midline between the umbilicus and xyphoid and in the mid-clavicular line in the ipsilateral lower quadrant.

For upper abdominal procedures, as with the kidney, it may be preferable in the small child to position the surgeon at the feet of the child, reaching over the legs and pelvis to be in comfortable line with the upper abdomen. This arrangement is shown in Figure 2. In larger children, the lower legs may be flexed to permit a similar arrangement. For still larger patients, the surgeon is best positioned at the opposite side, aiming toward the ipsilateral shoulder (Fig. 3).

When the surgical field is the pelvis, the surgeon may be best positioned at the head of the patient (Fig. 4) to be in line with the endoscope and operative area. There is a significant advantage to be gained when working in a linear arrangement, both for orientation, equal efficiency of both working ports and comfort. Surgeon discomfort will detract from surgical efficiency and its emphasis is not to make life easier for the surgeon, but for the patient (5).

CANNULAE

Cannula size is often short for pediatric cases to make the instruments seem more age appropriate, yet this may be a drawback in some cases. If the instruments are of normal length, the shorter cannulae offer no advantage at all. For all situations in which the cannulae are fairly close together, shorter lengths are detrimental as the heads will bump into each other more often. In smaller children with retroperitoneal exposures, the short cannulae are a particular problem, specifically if they have larger heads. If there is a problem with the port being too short to reach the area of surgery, the port should be fixed so as to permit further entry into the working space, but being limited on withdrawal to prevent accidental removal.

HAND INSTRUMENTS

When using pediatric instruments, one should avoid using instruments of differing lengths, as this creates further asymmetry of the surgeon's arm position, one arm being close, the other distant from the patient.

Similar issues are applicable to the working instruments, in which case, short instruments may put the hands too close together for comfortable work. It may be very challenging to perform suturing. Of course, too long an instrument, with the ports at a larger working angle, will put the handles at a wide spread, also limiting the efficiency of the operator.

When using pediatric instruments, one should avoid using instruments of differing lengths, as this creates further asymmetry of the surgeon's arm position, one arm being close, the other distant from the patient.

ACCESS

Veress Access

Access using the Veress method is applicable to children as long as the operator recognizes several issues.




FIGURE 2 ■ Diagram of surgical setup with the surgeon at the patient's feet for an upper abdominal procedure in a small child. The surgeon is orientated in a straight line with the operative area. *Abbreviations:* S, surgeon; SN, scrub nurse; SA, surgical assistant; A, anesthesiologist; M, monitor.



FIGURE 3 ■ Diagram showing the surgical setup in a larger child for a renal procedure with the surgeon at the side of the patient, similar to that for adult patients. *Abbreviations:* S, surgeon; SN, scrub nurse; SA, surgical assistant; A, anesthesiologist; M, monitor.



FIGURE 4 ■ Diagram showing the surgical setup for a pelvic procedure such as an antireflux operation with the surgeon at the patient's head to permit alignment with the operative field. *Abbreviations:* S, surgeon; SN, scrub nurse; SA, surgical assistant; A, anesthesiologist; M, monitor.

In the child it is very easy to tent the peritoneum upward at the umbilical attachments and slide the Veress needle along the preperitoneal space.

In the child tissue resistance may not be great and the shield can snap back blunting the needle before the peritoneum is pierced. It is also important to recognize the danger of past-pointing when passing the needle or subsequent trocars in children. It is much closer to the back wall of the body and associated vascular structures.

In general the open access approach is used in our routine pediatric laparoscopic cases. It is likely the lowest risk and most efficient system.

Port fixation is critical in children as it is very easy to dislodge the cannula.

Skin stitches in children may not be as useful as the skin can pull away from the abdominal wall much more easily. Fixation sutures should include some external fascia as well for security.

The author prefers to close all ports of 3 mm and larger.

In the child it is very easy to tent the peritoneum upward at the umbilical attachments and slide the Veress needle along the preperitoneal space.

This space is insufflated, which may make subsequent laparoscopy difficult. There is a tendency of the pediatric peritoneum to pull away from the abdominal wall more readily than in adults, so this problem is more of an issue. Similarly, as the Veress needle advances, the safety shield is pushed back by the resistance of the tissues.

In the child this resistance may not be great and the shield can snap back blunting the needle before the peritoneum is pierced. It is also important to recognize the danger of past-pointing when passing the needle or subsequent trocars in children. It is much closer to the back wall of the body and associated vascular structures.

When using the Veress system it is preferable to utilize a single-pass system that allows positioning of the endoscope through the Veress needle (using a miniature 2 mm endoscope), or to use the sheath placed with the Veress needle to permit placement of the larger cannula, as in the Step[®] system^a. This eliminates the need for a second port placement after the insufflation and reduces the risk of inadvertent injury. The Visiport[®] system has not been of much use in pediatric applications due to its size.

Open Access

In general the open access approach is used in our routine pediatric laparoscopic cases. It is likely the lowest risk and most efficient system.

It is important to be able to create an adequate air-seal after port placement, however. It is not totally free of complications and caution is needed to avoid bowel injury (6). Several simple maneuvers may be performed to facilitate efficient use of the open access system.

There is no formal Hasson cannula in smaller sizes and most are fairly bulky for pediatric use (7). One can modify a conventional cannula by wrapping it with a cuff of rubber tubing and using this to suture to as well as to press into the skin and fascia to improve an air seal. Vaseline gauze may be used if a leak persists.

The most useful tool has been the placement of a purse string suture in the fascia after the peritoneum (or retroperitoneum) has been entered, but before the cannula is placed (8). The purse string is of 3-0 or 2-0 absorbable suture and the loop side is kept loose. The cannula is placed and if there is a gas-leak, the two ends are pulled taut and held in place with a Rummel tourniquet. If the seal is good, the loop is wrapped twice around the gas input stem and pulled snugly at the point where the cannula is in the appropriate amount. This prevents the cannula from being dislodged. The stitch may be used as the fascial closure stitch at the end of the case.

Port fixation is critical in children as it is very easy to dislodge the cannula. Ports cannot be placed too far in to the abdomen or retroperitoneum as they will interfere with the operative field, but with little inside the body, they are more easily prone to inadvertent removal. The abdominal wall is much thinner and there is less to pass through and less resistance. Any method used to secure the cannula must limit the risk of dislodgement. With the Step system, the cannula is unlikely to be dislodged due to the radially expanding design, but this is not guaranteed and fixation is recommended.

When possible, the fascial purse-string stitch is used to keep the cannulae in the body, and makes later port site closure efficient. A simple fixation stitch to the fascia is just as effective.

Skin stitches in children may not be as useful as the skin can pull away from the abdominal wall much more easily. Fixation sutures should include some external fascia as well for security.

Port Site Handling

The author prefers to close all ports of 3 mm and larger. The risk of port site hernia is low in children, but certainly real, and there are anecdotal reports of hernias through the smaller port sites (9,10). The preplaced fascial holding stitches are, therefore, an efficient way to provide closure; alternatively, a simple stitch through the fascia is adequate closure.

MANIPULATION PRINCIPLES

During laparoscopic manipulation in children, the basic principles are the same as in adults with a few extra considerations. The operative area created by the pneumoperitoneum (or retroperitoneum) is smaller, often markedly so. This limits the movement potential,

^a U.S. Surgical Corp., Norwalk, CT.

particularly when handling sutures or retracting. This is not necessarily a direct problem, but requires a different pattern of movements than in adults. The amount of external movement needed to create a particular internal movement can be much less. The pneumoperitoneum is much more sensitive to loss of insufflating gas and small leaks during instrument changes, for example, can produce significant field of view losses. Increased gas flow can compensate for this but may produce excess pressures due to the lag time in pressure sensing. The best approach is to be aware of the problem and limit leakage.

The intraperitoneal space of the child looks different from that of the adult. In many ways it is much clearer to distinguish the anatomy, largely due to lack of fat. This may be disorienting to the experienced adult laparoscopist looking for different visual clues.

It is helpful to take time at the beginning of a case to orient to the anatomy and the proximity of associated structures, all of which are much closer than in the adult. Working in the small spaces of the child requires adjustments of movement and operative planning. While the anatomy may be more plainly visible, the proximity of structures demands a more meticulous and methodical pace to any procedure. Cautery injury is more readily possible and settings should be set lower for children. The amount of force needed to move tissues and organs is less and a degree of delicacy is called for.

The risk of cautery injury from direct contact is higher due to the small spaces, but also from the phenomenon of capacitive coupling (11–13). This is more likely in the smaller instruments due to increased current density at the level of the abdominal wall. There is also less abdominal wall tissue to diffuse the induced current. While this has not been a clinical problem with modern laparoscopic instruments and judicious use of cautery at relatively low power settings, all surgeons should be aware of its causes and potential.

It is helpful to take time at the beginning of a case to orient to the anatomy and the proximity of associated structures, all of which are much closer than in the adult.

RETROPERITONEAL ACCESS

Retroperitoneal access for renal surgery in the child increases the challenges of smaller spaces for surgical manipulation, even though it is considered advantageous over transperitoneal methods.

Retroperitoneal access for renal surgery in the child increases the challenges of smaller spaces for surgical manipulation, even though it is considered advantageous over transperitoneal methods (14–16).

Those advantages are more direct access to the kidney and hilum, less risk of inadvertent injury to adjacent structures, and less chance of postoperative intestinal adhesions. The relative advantage is difficult to define, but the direct access to the renal hilum is a reality that is worth the limitations in space. When space is limited in retroperitoneal access, it is even more important to position ports appropriately and to recognize the limitations in size when working in the smaller space. Maintaining orientation of the camera and the surgical anatomy is essential. A minor rotation in the endoscope may convey a marked apparent difference in the anatomic orientation of some structures including the renal vessels and vena cava. Regular orientation checks are useful, particularly before placing clips on vessels.

During any retroperitoneal procedure it is essential to recognize the location of the peritoneum and its reflections. In children this may be difficult as the peritoneum is very delicate and may be difficult to see. Tearing the peritoneum will allow insufflation, which reduces the working space in the retroperitoneum. Often this is only noted as a gradual diminishment in the working space.

Typical areas of peritoneal violation are the lateral aspect during development of the retroperitoneal space, particularly if performed with the endoscope, and at the superior pole of the kidney where it is immediately adjacent to the peritoneum.

If the peritoneum is violated and insufflation limits the operative field, there are several options for correction. The peritoneal space may be vented using an angiocatheter placed near the lateral margin, the tear may be repaired directly and the peritoneal space evacuated, or a small tear may be opened widely to limit gas trapping in the peritoneum and permit a wider operative field.

In essence the latter turns the case into a retro- and transperitoneal procedure. There is seldom a reason to convert to an open procedure if the peritoneum is violated.

Although the transperitoneal approach is considered more risky and potentially related to small bowel adhesions, this has not yet been reported in children. It has been shown that even after direct laparoscopic intraperitoneal surgery in children, there are very few adhesions produced (17). This was shown in a study of relook procedures for contralateral intra-abdominal orchiopexy in which much of the peritoneal

Tearing the peritoneum will allow insufflation, which reduces the working space in the retroperitoneum. Often this is only noted as a gradual diminishment in the working space.

If the peritoneum is violated and insufflation limits the operative field, there are several options for correction. The peritoneal space may be vented using an angiocatheter placed near the lateral margin, the tear may be repaired directly and the peritoneal space evacuated, or a small tear may be opened widely to limit gas trapping in the peritoneum and permit a wider operative field.

surface surrounding the testis was stripped; yet no substantial adhesions were produced. In most of these cases, as with most transperitoneal renal surgeries, the small and large bowel are manipulated to a minimal degree. It may be that this limited manipulation reduces the degree of adhesive changes. When placed in the context of the facility of renal access, particularly of the ureteropelvic junction, a transperitoneal approach may be preferable.

There is early evidence suggesting that the patterns of tissue healing are different with laparoscopic procedures (18) and these may be distinct between adults and children. The mediators of inflammatory changes seem different in degree and timing of activation after laparoscopic surgery than open surgery (19,20). Whether this plays any role in intestinal adhesions remains to be determined.

PHYSIOLOGY AND ANESTHETIC CONSIDERATIONS

Although there was initial concern regarding the impact of pneumoperitoneum on pediatric cardiorespiratory physiology, the clinical effects appear to be limited. It is rare that any child has significant adverse response to the pneumoperitoneum. Several studies of the anesthetic response of children to laparoscopic procedures have been published demonstrating detectable differences, which do not have major clinical significance (21–25). They do serve to alert the surgeon and anesthesiologist to the potential for problems in the compromised child. Due to the effects of a pneumoperitoneum, it can be anticipated that children with a smaller than normal functional reserve of pulmonary function may have difficulty maintaining oxygenation with increased intra-abdominal pressures. Neonates have relatively less reserve and may have more significant alterations in cardiorespiratory function with a pneumoperitoneum, as well as greater CO₂ absorption (26). We have seen this in a few patients with restrictive pulmonary conditions. In general these alterations may be corrected with reduced intra-abdominal pressures. Cardiac function has not been markedly altered and in some cases this has been examined with transesophageal echocardiography for follow-up of congenital cardiac disease.

It should be anticipated that certain children would have reduced oxygenation with increased intra-abdominal pressures, including those with restrictive pulmonary conditions, smaller infants or premature infants.

It should be anticipated that certain children would have reduced oxygenation with increased intra-abdominal pressures, including those with restrictive pulmonary conditions, smaller infants or premature infants.

To some degree these children can be managed with increased minute ventilation, but that alone may not be sufficient and reduced intra-abdominal pressures are probably the best initial measure. We have never had to convert a laparoscopic case due to anesthetic conditions.

There was much concern about the effect of laparoscopy on the child's temperature, yet for renal and bladder surgery this has not been a concern (27). Indeed, in infants, we have noted a small but measurable degree of hyperthermia during nephrectomy. The etiology of this is uncertain, but the anticipated hypothermia has not been seen. Anesthesiologists should be informed not to expect significant reductions in body temperature. It is prudent to be prepared to warm the child with the various warming devices available, however, in case the procedure is prolonged or complex and there is loss of body temperature.

Reduced urine output during pneumoperitoneum is well recognized and occurs in children.

Reduced urine output during pneumoperitoneum is well recognized (28) and occurs in children. The actual physiology remains incompletely defined and while direct pressure effects have been postulated (29), there is evidence of a more complex mechanism as well (30). The effect is rapidly reversible and we have not seen adverse clinical outcomes. The anesthesia team needs to be informed so as to anticipate this occurrence and not respond by overhydrating the child. As more complex patients are undergoing laparoscopic procedures, the question of the effect of pneumoperitoneum-induced oliguria on already reduced renal function was raised. In experimental studies this did not appear to further injure renal function (30) and we have not identified this in clinical practice.

COMPLICATIONS

Ventriculoperitoneal Shunts

Many pediatric patients will have ventriculoperitoneal shunts for hydrocephalus, and one report suggested that these children would require exteriorization of the shunt during laparoscopy to prevent acute rise in intracranial pressure (31). The theory behind this was logical but it has not appeared to be the case clinically and several patients with

There is no evidence that the presence of a ventriculoperitoneal shunt should pose any risk to laparoscopic procedures.

ventriculoperitoneal shunts have undergone laparoscopic procedures with no apparent problems (32).

There is no evidence that the presence of a ventriculoperitoneal shunt should pose any risk to laparoscopic procedures. Indeed we have used laparoscopy for intra-abdominal shunt revision.

Complications in children are the same as in adults, although their clinical presentation may be less distinct and a higher index of suspicion should be established.

SURGICAL COMPLICATIONS

Complications in children are the same as in adults, although their clinical presentation may be less distinct and a higher index of suspicion should be established.

The potential for major complications exists due to the smaller size of the surgical field and less sturdy tissues, although the higher visibility in general should limit this risk. Early in the development of pediatric urologic laparoscopy, a survey reported an incidence of 2% with the need for surgical intervention in 0.4%. In a large review of pediatric laparoscopic complications, with the majority including diagnostic procedures, a complication rate of 2.7% was reported, with no mortality. Conversions were required in one-third of these. The most significant complications were bleeding, while others included bladder perforation during orchiopexy (Esposito, 2003 p. 310). The major risks of acute injury are obvious and rarely missed, including bleeding and injury to adjacent structures.

Occult injury to the bowel is a recognized possibility and as with adults, it seems that the clinical presentation is subtler than in bowel injury with open procedures (33). Reported cases suggest that there is less of a febrile response, more subtle clinical signs of peritonitis and a lower leukocytosis. The reasons for this remain unclear, but some authors have focused on altered immune responses following laparoscopy (34). Use of C-reactive protein as an indicator of bowel injury after laparoscopy has been reported in adults (35). None of these issues have been studied in children,

When dealing with children, following any surgical procedure, it is important to recognize their ability to maintain a well-compensated state for long periods but then to rapidly decline in their ability to remain compensated.

When dealing with children, following any surgical procedure, it is important to recognize their ability to maintain a well-compensated state for long periods but then to rapidly decline in their ability to remain compensated.

They will deteriorate rapidly after appearing to be stable and healthy. Early, subtle signs of that compensation should be recognized in the appropriate context, including persistent tachycardia, increased respiratory rate, and poor feeding. Of course, these patterns may simply represent postoperative effects that will resolve, but one must be cognizant of the potential for subsequent rapid deterioration. In the situation of a difficult procedure that may not have progressed as well as usual, it may be prudent to delay discharge if the child is not making a rapid recovery, just to be able to identify warning signs of either peritonitis or hemorrhage. While routine blood tests are seldom performed, these might be the situations to consider doing so.

POSTOPERATIVE COURSE

There is little difference in recovery patterns among children of different ages and it is difficult to determine what might predict the rapidity of recovery in particular cases. There does seem to be a tendency among children to be very quiet and sluggish in recovery for 6 to 18 hours following complex laparoscopic procedures, and then very rapidly return to their baseline level of comfort and activity. This is in contrast to the pattern seen after open surgery, which shows a steady, but usually more prolonged recovery phase. The basis for this is unclear. Most children under the age of five are ready to return home, on oral analgesics (often no more than acetaminophen), taking liquids and some solids and moving comfortably within 36 hours of the procedure, some within 24 hours. Older children usually require two or three days to achieve a similar level of comfort. Some infants have been ready for discharge on the same day following partial nephrectomy or pyeloplasty. There seems to be a general sense of malaise in the recovery period for children, although they do not usually seem to localize their pain. Even older children do not complain specifically of focal discomfort.

Rarely do children complain of shoulder pain, as is often noted in adults. A few teenagers have done so, but this is unusual. It may simply reflect the general tendency of children to be unable to localize abdominal pain.

SUMMARY

- Laparoscopic procedures in children are well tolerated and have an excellent potential for improving surgical outcomes with reduced morbidity in a variety of urological procedures.
- It is important to recognize the unique characteristics of laparoscopic surgery in children. While many of the principles of laparoscopy in adults are completely applicable to children, the smaller size, distinct tissue textures and strengths, and their lack of physiological reserve offer special challenges to performing these procedures in the young patient.
- With attention to detail, recognition of a child's unique physiology, and their patterns of healing, more complex laparoscopic procedures are being more commonly performed and should continue to evolve.

REFERENCES

1. Castilho LN, Castillo OA, Denes FT, Mitre AI, Arap S. Laparoscopic adrenal surgery in children. *J Urol* 2002; 168(1):221–224.
2. El-Ghoneimi A. Paediatric laparoscopic surgery. *Curr Opin Urol* 2003; 13(4):329–335.
3. Iwanaka T, Arai M, Yamamoto H, et al. No incidence of port-site recurrence after endosurgical procedure for pediatric malignancies. *Pediatric Surg Int* 2003; 19(3):200–203.
4. Wilson EE, Vuitch F, Carr BR. Laparoscopic removal of dysgenetic gonads containing gonadoblastoma in a patient with Swyer syndrome. *Obstet Gynecol* 1992; 79:842–844.
5. Vereczkel A, Bubbs H, Feussner H. Laparoscopic surgery and ergonomics: it's time to think of ourselves as well. *Surg Endosc* 2003; 17(10):1680–1682.
6. Sadeghi-Nejad H, Kavoussi LR, Peters CA. Bowel injury in open technique laparoscopic cannula placement. *Urology* 1994; 43(4):559–560.
7. Humphrey GM, Najmaldin A. Modification of the Hasson technique in paediatric laparoscopy. *Br J Surg* 1994; 81(9):1319.
8. Poppas DP, Bleustein CB, Peters CA. Box stitch modification of Hasson technique for pediatric laparoscopy. *J Endourol* 1999; 13(6):447–450.
9. Bloom DA, Ehrlich RM. Omental evisceration through small laparoscopy port sites. *J Endourol* 1993; 7(1):31–32.
10. Waldhausen JH. Incisional hernia in a 5-mm trocar site following pediatric laparoscopy. *J Laparoendosc Surg* 1996; 6(suppl 1):S89–S90.
11. Grosskinsky CM, Ryder RM, Pendergrass HM, Hulka JF. Laparoscopic capacitance: a mystery measured. Experiments in pigs with confirmation in the engineering laboratory. *Am J Obstet Gynecol* 1993; 169(6):1632–1635.
12. Tucker RD, Voyles CR, Silvis SE. Capacitive coupled stray currents during laparoscopic and endoscopic electrosurgical procedures. *Biomed Instrum Technol* 1992; 26(4):303–311.
13. Willson PD, van der Walt JD, Moxon D, Rogers J. Port site electrosurgical (diathermy) burns during surgical laparoscopy. *Surg Endosc* 1997; 11(6):653–654.
14. Borer JG, Peters CA. Pediatric retroperitoneoscopic nephrectomy. *J Endourol* 2000; 14(5):413–416; discussion 417.
15. El-Ghoneimi A, Farhat W, Bolduc S, Bagli D, McLorie G, Khoury A. Retroperitoneal laparoscopic vs open partial nephroureterectomy in children. *BJU Int* 2003; 91(6):532–535.
16. Yeung CK, Tam YH, Sihoe JD, Lee KH, Liu KW. Retroperitoneoscopic dismembered pyeloplasty for pelvi-ureteric junction obstruction in infants and children. *BJU Int* 2001; 87(6):509–513.
17. Moore RG, Kavoussi LR, Bloom DA, et al. Postoperative adhesion formation after urological laparoscopy in the pediatric population. *J Urol* 1995; 153(3 Pt 1):792–795.
18. Walker CB, Bruce DM, Heys SD, Gough DB, Binnie NR, Eremin O. Minimal modulation of lymphocyte and natural killer cell subsets following minimal access surgery. *Am J Surg* 1999; 177(1):48–54.
19. Mendoza-Sagaon M, Gitzelmann CA, Herreman-Suquet K, Pegoli W Jr., Talamini MA, Paidas CN. Immune response: effects of operative stress in a pediatric model. *J Pediatr Surg* 1998; 33(2):388–393.
20. Gitzelmann CA, Mendoza-Sagaon M, Talamini MA, Ahmad SA, Pegoli W Jr., Paidas CN. Cell-mediated immune response is better preserved by laparoscopy than laparotomy. *Surgery* 2000; 127(1):65–71.
21. Gentili A, Iannettone CM, Pigna A, Landuzzi V, Lima M, Baroncini S. Cardiocirculatory changes during videolaparoscopy in children: an echocardiographic study. *Paediatr Anaesth* 2000; 10(4):399–406.
22. Bergesio R, Habre W, Lanteri C, Sly P. Changes in respiratory mechanics during abdominal laparoscopic surgery in children. *Anaesth Intensive Care* 1999; 27(3):245–248.
23. Halachmi S, El-Ghoneimi A, Bissonnette B, et al. Hemodynamic and respiratory effect of pediatric urological laparoscopic surgery: a retrospective study. *J Urol* 2003; 170(4 Pt 2):1651–1654; discussion 1654.
24. Gueugniaud PY, Abisseron M, Moussa M, et al. The hemodynamic effects of pneumoperitoneum during laparoscopic surgery in healthy infants: assessment by continuous esophageal aortic blood flow echo-Doppler [see comments]. *Anesth Analg* 1998; 86(2):290–293.
25. Rubin SZ, Davis GM, Sehgal Y, Kaminski MJ. Does laparoscopy adversely affect gas exchange and pulmonary mechanics in the newborn? An experimental study. *J Laparoendosc Surg* 1996; 6(suppl 1):S69–S73.

26. McHoney M, Corizia L, Eaton S, et al. Carbon dioxide elimination during laparoscopy in children is age dependent. *J Pediatr Surg* 2003; 38(1):105–110; discussion 105–110.
27. Kaynan AM, Winfield HN. Thermostasis during laparoscopic urologic surgery. *J Endourol* 2002; 16(7):465–470.
28. Chang DT, Kirsch AJ, Sawczuk IS. Oliguria during laparoscopic surgery. *J Endourol* 1994; 8(5):349–352.
29. Razvi HA, Fields D, Vargas JC, Vaughan EJ, Vukasin A, Sosa RE. Oliguria during laparoscopic surgery: evidence for direct renal parenchymal compression as an etiologic factor. *J Endourol* 1996; 10(1):1–4.
30. Cisek LJ, Gobet RM, Peters CA. Pneumoperitoneum produces reversible renal dysfunction in animals with normal and chronically reduced renal function. *J Endourol* 1998; 12(2):95–100.
31. Uzzo RG, Bilsky M, Mininberg DT, Poppas DP. Laparoscopic surgery in children with ventriculoperitoneal shunts: effect of pneumoperitoneum on intracranial pressure—preliminary experience. *Urology* 1997; 49(5):753–757.
32. Jackman SV, Weingart JD, Kinsman SL, Docimo SG. Laparoscopic surgery in patients with ventriculoperitoneal shunts: safety and monitoring. *J Urol* 2000; 164(4):1352–1354.
33. Bishoff JT, Allaf ME, Kirkels W, Moore RG, Kavoussi LR, Schroder F. Laparoscopic bowel injury: incidence and clinical presentation. *J Urol* 1999; 161(3):887–890.
34. Aldana JP, Marcovich R, Singhal P, et al. Immune response to laparoscopic bowel injury. *J Endourol* 2003; 17(5):317–322.
35. Rongieres C, Gomel V, Garbin O, Fernandez H, Frydman R. C-reactive protein should accelerate the diagnosis of bowel injury after gynecologic surgery. *J Am Assoc Gynecol Laparosc* 2002; 9(4):488–492.

LAPAROSCOPIC MANAGEMENT OF THE UNDESCENDED NONPALPABLE TESTICLE

Gerald H. Jordan

Department of Urology, Eastern Virginia Medical School, Norfolk, Virginia, U.S.A.

Linda Baker

Department of Urology, University of Texas Southwestern Medical Center, Dallas, Texas, U.S.A.

- INTRODUCTION
- CONSIDERATIONS FOR ORCHIDOPEXY
 - Laparoscopic Evaluation
- THERAPEUTIC LAPAROSCOPY
 - Laparoscopic Surgery for Unilateral Nonpalpable Testicles

Complications of Laparoscopic Orchidopexy
Two-Stage Fowler—Stephens Laparoscopic Orchidopexy

- SUMMARY
- REFERENCES

INTRODUCTION

Cryptorchidism is the absence of a testicle in the scrotum. In most cryptorchid boys, the testicle is palpable in the groin. In only about 20%, is the testicle nonpalpable (1). A nonpalpable testicle can be absent, can be intraabdominal, or within the inguinal canal. Intraabdominal testicles can be found along the normal path of descent or can be ectopic. Likewise, “inguinal” undescended testicles can either be undescended along the normal path of descent, i.e., canalicular or can descend to an ectopic location (such as the perineum) (2,3).

Orchidopexy is recommended (i) for easier examination of the testicle, (ii) to correct any associated inguinal hernia, (iii) to prevent testicular torsion, and (iv) to alleviate possible psychologic trauma resulting from the young child or man having an empty hemiscrotum. Additionally, the concepts of improving fertility or diminishing the potential for malignant transformation have been offered as indications (4). With regards to fertility, it has been shown that fertility is impaired in approximately 50% to 70% of boys born with one undescended testicle and as many as 75% with bilateral undescended testicles, even after orchidopexy (5). Histologic deterioration is believed to be worse for higher testicles; fertility was thus felt to vary in association with location. Likewise, histologic abnormality has been proposed as an indicator of the possibility for malignant transformation (6).

- Laparoscopy has been useful as a diagnostic modality as well as a therapeutic modality.
- There are many who feel that laparoscopy is the gold standard for localization of the undescended gonad.
- Increasing evidence has developed that laparoscopic orchidopexy may be the best of the surgical modalities.

Prior to 1976, the nonpalpable testicle was located by inguinal exploration. If the gonad, an atrophic nubbin, or blind-ending vessels were not found in the groin, then the inguinal exploration could be and was extended allowing exploration of the retroperitoneum. It was rare for the surgeon to be unable to locate the gonad, or residua thereof.

In 1976, Cortesi et al. first described laparoscopy as a modality that could reveal the location of the nonpalpable testicle (7). It was not long after that, that laparoscopy was used therapeutically. Bloom in 1991 described a procedure for staged pelvioscopic orchidopexy. At the first stage, the vessels were ligated with a Hulka clip (8). The second stage was, as described by Bloom, then accomplished via an open technique.

Jordan et al. described the first laparoscopic orchidopexy (9). In that procedure, the testicle was located laparoscopically and was brought down to the scrotum using pure laparoscopic techniques. In 1993, Bogaert et al. also described a series of laparoscopic

In 1976, Cortesi et al. first described laparoscopy as a modality that could reveal the location of the nonpalpable testicle.

orchidopexy. Initially, the utility of laparoscopy for diagnostic purposes and especially laparoscopic orchidopexy caused a great deal of debate among pediatric urologists (10–13). As mentioned, however, diagnostic laparoscopy and therapeutic laparoscopy for the undescended testicle now have found good acceptance and have been incorporated into the practice of many pediatric urologists.

CONSIDERATIONS FOR ORCHIDOPEXY

It has been shown that undescended testicles at birth and throughout the first year of life have normal histology, and that includes a normal population of germ cells.

Huff et al. showed that beyond age of 18 months, both light microscopy and electron microscopy showed the development of abnormal histologic changes (15).

This was one factor that dictated timing of orchidopexy. Anesthesia risks also dictated timing of orchidopexy; however, infants aged four to six months have been shown now, with modern pediatric anesthesia techniques, to have risks similar to the healthy adult.

Recent studies would suggest that orchidopexy at six months is optimal as it capitalizes on the anatomic advantages conferred by the child's small size, while exhausting the real chances for spontaneous descent (16).

The role for orchidopexy in the older child, adolescent, and young adult is less well defined. Clearly, the undescended testicle will almost certainly have poor fertility potential; however, its usefulness for androgen production must be considered. There is then also the risk of malignant change, and as mentioned, relocation to the scrotum may not alter that risk at all. A recent analysis comparing anesthetic risks of orchiectomy versus the lifetime-adjusted risk of germ cell cancer was performed by Kibel and coworkers (17).

Kibel and coworkers recommend that healthy males with undescended testicles undergo orchiectomy until the age of 50 years. For patients with comorbid conditions [American Society of Anesthesiologists (> 2)] the risks of surgery might contraindicate orchiectomy even before the age of 50 years (17).

The preoperative diagnostic modalities used in the evaluation of the patient with a nonpalpable testicle include radiological tests and hormonal challenge. Medical management will not be discussed in this manuscript. However, radiologic evaluation will be discussed as many feel that a real alternative to laparoscopic localization. Virtually, all imaging modalities have been used. These would include ultrasound, venography, magnetic resonance imaging, and computed tomography. None of these modalities have been found to be sufficiently sensitive to answer the questions: (i) is there a testicle present, and (ii) where is that testicle (18–22)?

Radiographic imaging can be useful in some instances. One such instance is in the overweight boy with a nonpalpable testicle, which can be proven to be inguinal. Likewise, there is utility in adolescents for follow-up who are not surgical candidates because of comorbid conditions. One should not forget the examination under anesthesia at the time of orchidopexy or laparoscopic localization, because that oftentimes will reveal the location of the testicle (3).

Laparoscopic Evaluation

As mentioned, laparoscopy has proven itself to be an excellent localization and diagnostic tool (23–26). It is useful in patients with bilateral undescended testicles as well as in cases of unilateral undescended testicles. It also has been helpful in allowing the surgeon to plan subsequent therapy (i.e., to decide whether orchidopexy or testicular removal is indicated). Motility of the testis and its vas deferens as well as the vascular supply can be assessed on laparoscopic diagnosis.

Diagnostic laparoscopy requires general anesthesia and the patient should be secured to the operating table to allow the bed to be manipulated to all extremes. Patient preparation and draping must be suitable for an open exploration should it be required. A Foley catheter and an oral gastric tube are placed. A supra- or infra-umbilical skin incision is made and the peritoneum is accessed via an open technique. In children, the use of Veress needle insufflation has been abandoned at most centers. Likewise, true Hasson access is cumbersome.

In the young child, the peritoneum can be controlled and a trocar easily dilated into place under direct vision. Holding sutures placed in the fascia are helpful in elevating the fascia and peritoneum prior to peritoneotomy.

Huff et al. showed that beyond age of 18 months, both light microscopy and electron microscopy showed the development of abnormal histologic changes.

Recent studies suggest that orchidopexy at six months is optimal as it capitalizes on the anatomic advantages conferred by the child's small size, while exhausting the real chances for spontaneous descent.

Kibel and coworkers recommend that healthy males with undescended testicles undergo orchiectomy until the age of 50 years. For patients with comorbid conditions the risks of surgery might contraindicate orchiectomy even before the age of 50 years.

In the young child, the peritoneum can be controlled and a trocar easily dilated into place under direct vision. Holding sutures placed in the fascia are helpful in elevating the fascia and peritoneum prior to peritoneotomy.

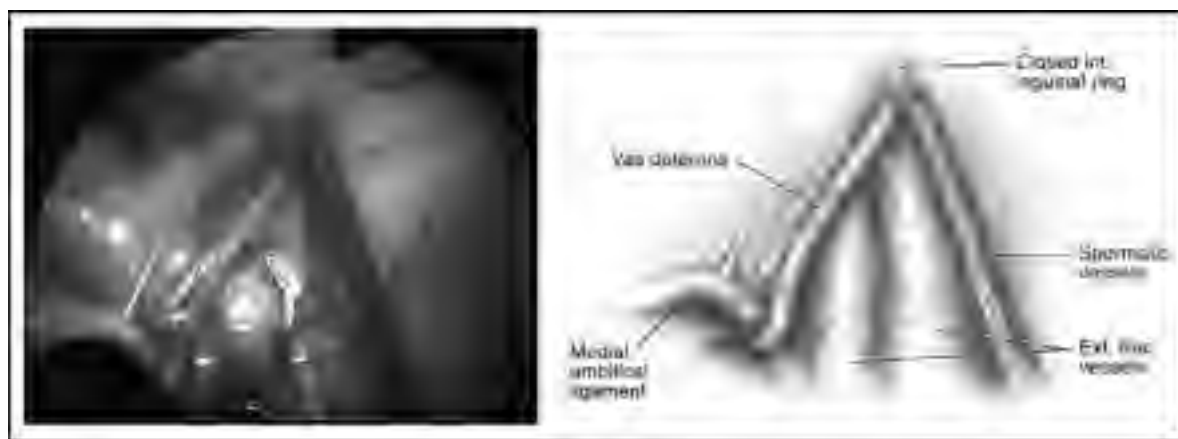
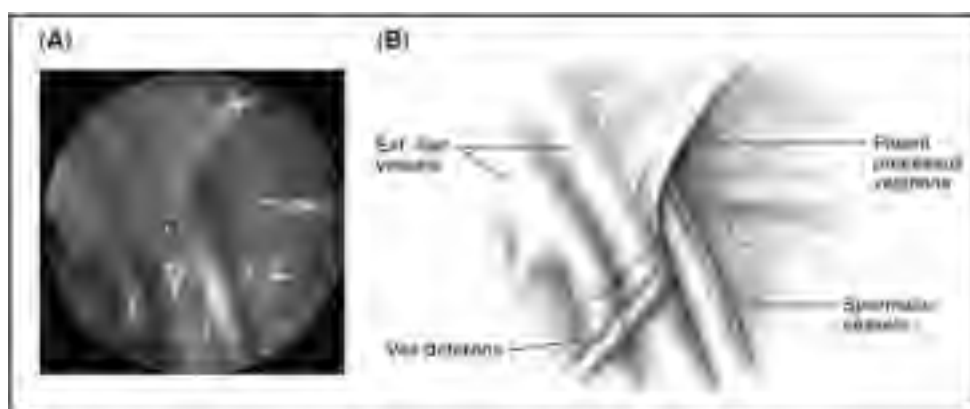


FIGURE 1 ■ Left: Laparoscopic photograph. Right: Diagram of the normal right internal ring.

FIGURE 2 ■ (A) Laparoscopic photograph. (B) Diagram of the right internal ring with a patent processus vaginalis.



The InnerDyne[®] Radial Dilating Step^a introducer system is helpful but not mandatory (27,28). In most cases, 5 mm access is more than adequate. Alternatively, 2 or 3 mm needlescopic ports and access can be used (27,29,30). The abdomen is insufflated to 14–15 millimeters of mercury pressure, the peritoneum is inspected to ensure proper positioning at which point the working cannulas can be placed as needed. The patient should already be in Trendelenburg position; however, if further exposure is needed in the pelvis further Trendelenburg positioning is helpful along with some lateral tilt. This will expose each internal ring, which can then be inspected. If the rings are difficult to visualize, and there is a descended testicle, traction on that descended testicle will very easily make the spermatic vessels more prominent at which point the opposite groin can be examined in a similar location. A number of findings are possible (see box).

- The vas and testicular vessels appear normal and exit a closed internal ring (Fig. 1). The groin can be explored for a descended remnant. Alternatively, an open inguinal approach can be used. These nubbins do need to be removed as approximately 10% contain viable germ cells and ostensibly could be at risk for undergoing malignant change (31–33).
- The vas and testicular vessels appear normal and exit an open internal ring (Fig. 2). Oftentimes, gentle pressure over the groin pushes a canalicular (peeping) testicle or nubbin into the abdomen (Fig. 3). If the gonad is not pushed back into the abdomen, the groin must be explored and again this can be done by either open or laparoscopic techniques (34).
- The blind-ending vessels are clearly identified and have a “horsetail” appearance. A blind-ending vessel is often in direct proximity to a blind-ending vas. These findings are pathognomonic for the vanished testicle and the procedure can be terminated. Most would agree that only in the case of a prominent nubbin being noticed would intervening tissue have to be removed (Fig. 4).

^aTyco International, Inc., Princeton, NJ.

FIGURE 3 ■ (A) Laparoscopic photograph of the right internal ring in a patient with a peeping testicle. (B) With external pressure on the inguinal canal, the peeping testicle can be visualized.

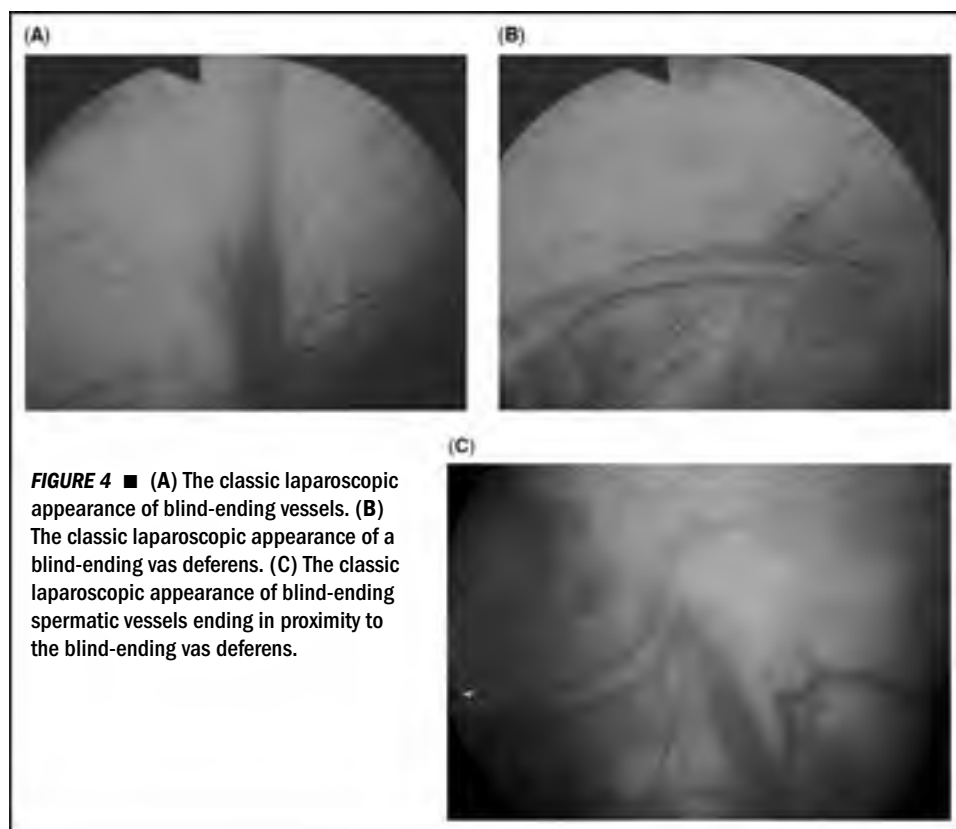
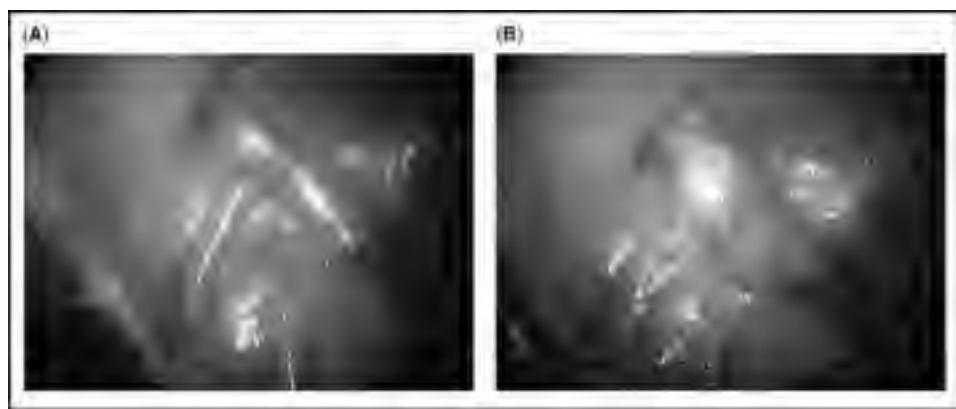


FIGURE 4 ■ (A) The classic laparoscopic appearance of blind-ending vessels. (B) The classic laparoscopic appearance of a blind-ending vas deferens. (C) The classic laparoscopic appearance of blind-ending spermatic vessels ending in proximity to the blind-ending vas deferens.

- The blind-ending vas is seen without blind-ending vessels in vicinity. The testicular nubbin is always in proximity to the blind-ending vessels; and hence, the laparoscopic exploration must be carried rostrally seeking those findings.
- An intra-abdominal testicle is located (Fig. 5).

Analyzing the existing data, 50% to 60% of all cases of nonpalpable testicles are identified as an intra-abdominal testicle or peeping testicle, 30% as an atrophic nubbin, and 20% as an absent or vanished testicle. A testicle located within 2 cm of the internal ring or is proven to be peeping in about 38% of cases and those testicles are usually normal in size with a normal vessel leash, vas, and epididymis. Testicles located higher in the abdomen are either along the normal path of descent, 44.8%, or are in an ectopic site in 7.1% (35).

When the testicle is not clearly identified just with placement of the camera alone, either small probes or working instruments are ideal to improve exposure. Because therapeutic maneuvers will be required in about 90% of cases, moving on to cannula

FIGURE 5 ■ (A) Laparoscopic photograph of the right groin in a child with a low abdominal undescended testicle. (B) Diagram of the right groin in a child with low abdominal undescended testicle.

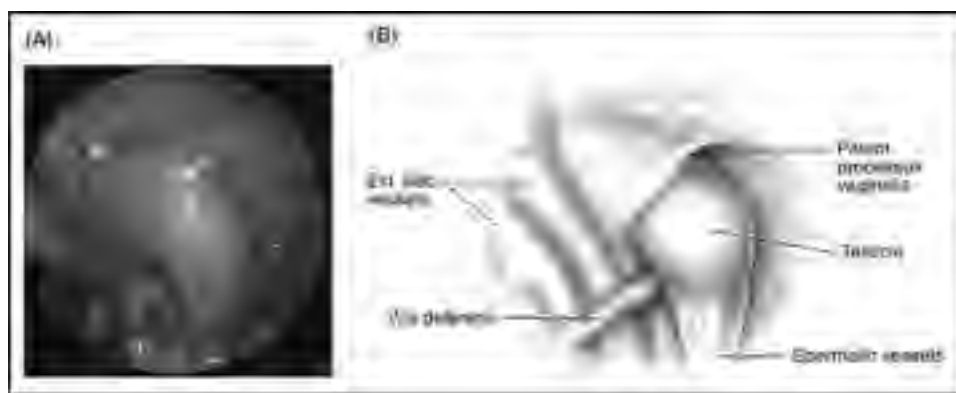


FIGURE 6 ■ Diagram of the cannula placement for a right laparoscopic orchidopexy.



For primary laparoscopic orchidopexy, maximal exposure of the inguinal and groin area is obtained by placing the table in steep Trendelenburg with the bed tilted contralateral to the undescended testicle.

Cautery is used for this maneuver, as there can be rather prominent vasculature in the gubernaculum. Care must be taken to identify a long looping vas, which unusually can be encountered.

If the testicle can be placed across the abdomen to the opposite groin, then usually there is sufficient ability for the testicle to be placed in the ipsilateral hemiscrotum.

placement and placement of working instruments is probably most expedient. Correct placement of the working cannula is shown in Figure 6. During working cannula placement, insufflation is increased to 20 mmHg pressure, which can then be decreased to 10–15 mmHg.

THERAPEUTIC LAPAROSCOPY

Laparoscopic Surgery for Unilateral Nonpalpable Testicles

The goal of therapeutic laparoscopy for a unilateral undescended testicle is either permanent fixation of the testicle in the scrotum or removal of a grossly abnormal testicle. The choice of surgical procedure is determined and our usual approach is summarized in the algorithm shown in Figure 7.

For primary laparoscopic orchidopexy, maximal exposure of the inguinal and groin area is obtained by placing the table in steep Trendelenburg with the bed tilted contralateral to the undescended testicle.

The open inguinal ring or the testicle is located and a peritoneotomy is made to either completely surround the open inguinal ring or to expose the gubernacular structures (Fig. 8). The authors prefer to leave the peritoneum between the vas and the vessels undissected and hence the peritoneotomy is extended along the spermatic vessel leash allowing for dissection rostral on the vascular cord structures. A peritoneotomy is likewise made over the vas deferens. To achieve sufficient mobility on the vas and vessels, eventually those two peritoneotomies need to be connected leaving a triangle of peritoneum in the area between the juncture of vas with vessels (Fig. 9). Ostensibly, this leaves the collateral circulation in that area undisturbed; and if one needed to proceed to single-stage Fowler–Stephens orchidopexy, then the results would be optimized by not having disturbed this area.

The testicular vessels, testicle, and vas are elevated on the “peritoneal pedicle.” The testicle is then rostrally retracted inverting the processus vaginalis and the gubernaculum, and the gubernaculum is thinned and then cut across.

Cautery is used for this maneuver, as there can be rather prominent vasculature in the gubernaculum (Fig. 10). Care must be taken to identify a long looping vas, which unusually can be encountered (Fig. 11).

Current hemostatic modalities include Ligasure^{TMb} or Harmonic Scalpel^{TMc}. However, because cautery is minimally employed throughout the entire orchidopexy procedure, the expense of these additional instruments, we feel, is not justified.

The testicle is further freed, maximizing the length of vessels and vas.

If the testicle can be placed across the abdomen to the opposite groin, then usually there is sufficient ability for the testicle to be placed in the ipsilateral hemiscrotum (Fig. 12).

Elder has shown that vigorous dissection of the vas may be more related to testicular atrophy than vigorous mobilization of the spermatic cord. If length is inadequate

^bValleylab, Tyco Healthcare, Norwalk, CT.

^cEthicon, Cincinnati, OH.

FIGURE 7 ■ Algorithm outlining management of the impalpable undescended testicle.

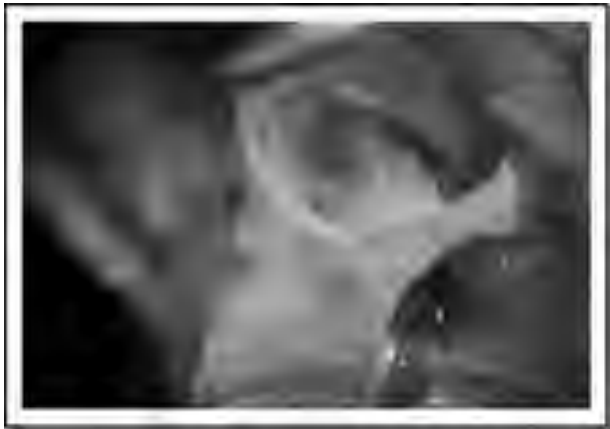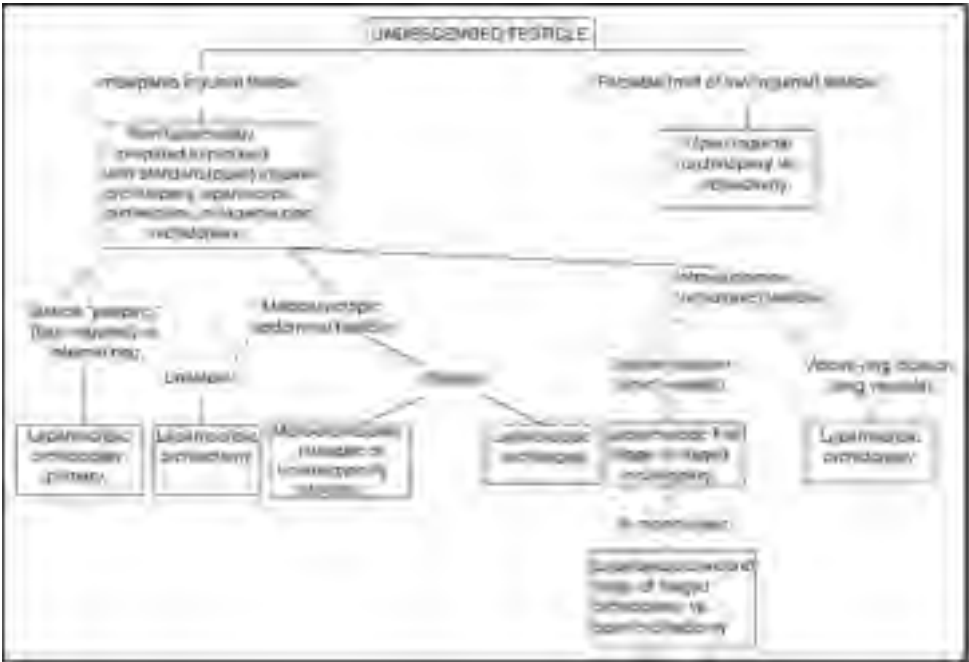


FIGURE 8 ■ Laparoscopic photograph of a child with a peeping testicle; the appearance of the right groin as the peritoneum is opened around the patent processes vaginalis.

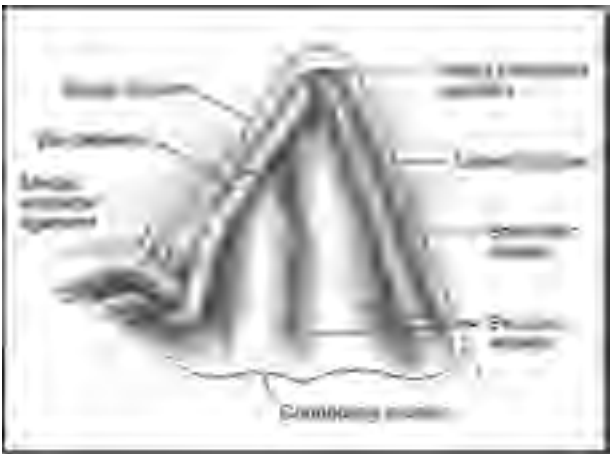


FIGURE 9 ■ Diagram of the peritoneal incisions.

The path that the testicle will take is medial to the inferior epigastric vessels and medial to the ipsilateral medial umbilical ligament but lateral to the bladder. The vessels are placed just over the top of the pubic ramus and down the inguinal canal.

after connecting the peritoneotomies and maximally dissecting vas and vessels, then the spermatic vessels can be divided. It is the authors' opinion that this scenario is best avoided; and hence, we make every effort to be sure that length will be adequate prior to proceeding this far with the dissection.

A number of techniques have been described for passing the testicle into the ipsilateral hemiscrotum, including the retrograde passage of a hemostat. A laparoscopic port can be primarily placed from below using a dilating trocar system or the path can be developed from within by passing a grasper into the hemiscrotum and then a dilating trocar system or step cannula used for the transfer. Lucent cannulas can be very helpful and prototype reusable lucent cannulas are in development.

The path that the testicle will take is medial to the inferior epigastric vessels and medial to the ipsilateral medial umbilical ligament but lateral to the bladder. The vessels are placed just over the top of the pubic ramus and down the inguinal canal.

A scrotal skin incision is made in the ipsilateral hemiscrotum and we prefer a subdartos pouch for fixation. In passing the testicle, a laparoscopic grasper is passed through the cannula into the abdomen grasping either the testicle or the gubernaculum



FIGURE 10 ■ Laparoscopic photograph of the testicle freed; the gubernaculum is exposed and is divided with cautery (same child as in Fig. 8).



FIGURE 11 ■ Laparoscopic photograph of the appearance of a long looping vas deferens; the testicle is being retracted into the abdomen and the vas is noted coursing along the path of the gubernaculum.

(Fig. 13). There are graspers which atraumatically grasp the testicle. The testis is then delivered through the port (Fig. 14). Should the vessels come under tension, then with the additional retraction, further dissection of vas and vessels can be accomplished above. Once the testicle is adequately mobilized to the level of the hemiscrotum, the pneumoperitoneum is immediately reduced and the internal surgical field is assessed for bleeding. The peritoneum in the area of dissection of the groin is not closed. In children, all port sites, 5 mm or greater, must be closed. The skin wounds can be injected with a long acting local anesthetic, adjuvant caudal anesthesia may also be beneficial.

The children are recovered from anesthesia and are discharged. In most cases, activity is somewhat diminished in the first 12 to 24 hours following surgery, but parents report that children very rapidly get back to normal activities.

No limit to activities is necessary other than asking parents to prohibit the child from straddle activities for at least six weeks.

In most cases, diet can be rapidly advanced.

No limit to activities is necessary other than asking parents to prohibit the child from straddle activities for at least six weeks.

Complications of Laparoscopic Orchidopexy

- Complications of laparoscopic orchidopexy can include the following:
- Bleeding
- Infection
- Anesthesia risks
- Injury to intra-abdominal or retroperitoneal organs necessitating emergent laparotomy
- Acute atrophy of the testicle
- Mechanical injury to the vas, epididymis, testis, or testicular vessels
- Poor testicular position
- Unrecognized need for a staged operation

As mentioned, if vessel length after significant dissection is found to continue to be inadequate, then the testicular vessels are clipped and transected, allowing further mobility and easier placement in the hemiscrotum. However, single-stage transfer in this fashion is clearly associated with higher atrophy rates than with single-stage primary orchidopexy and in most cases should and can be avoided.

Two-Stage Fowler–Stephens Laparoscopic Orchidopexy

A two-stage Fowler–Stephens orchidopexy can be performed when diagnostic laparoscopy reveals a testicle high in the abdomen and the surgeon deems the placement of the testicle in the ipsilateral hemiscrotum not feasible despite significant dissection. In stage I, a 5-mm port is placed and a clip applier is used to control the testicular vessels. The clips should be placed relatively proximal to avoid interference with collaterals between the junction of the vas and the testicular vessels, if present. Although

FIGURE 12 ■ Laparoscopic photograph of the appearance of the testicle, with the spermatic vessels and the vas dissected.

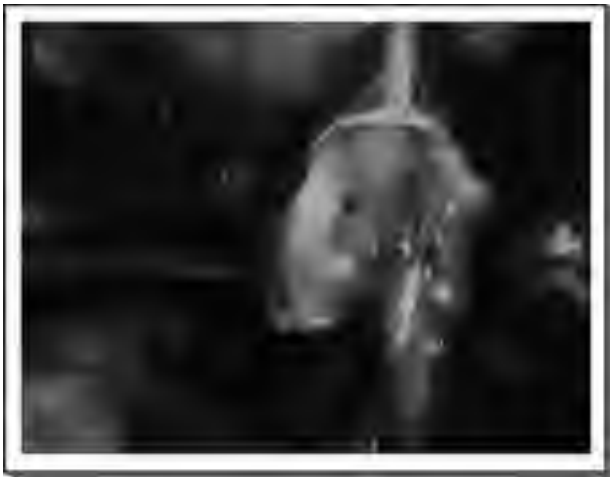
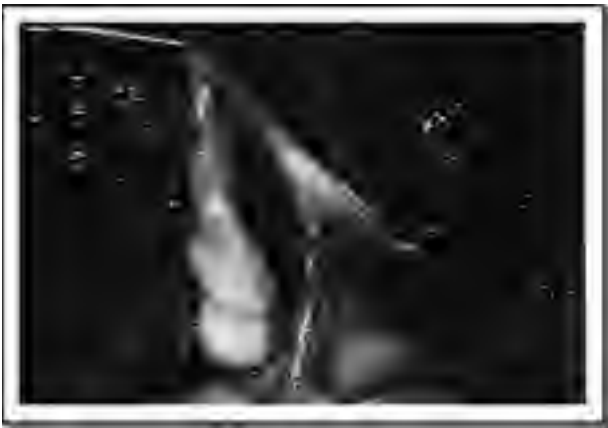

FIGURE 13 ■ Laparoscopic photograph showing the testicle drawn into the cannula.



FIGURE 14 ■ Photograph showing the appearance of the testicle as it is brought down into the scrotum within the cannula.

the vessels may be transected, in most cases mere placement of clips is adequate. After a six-month interval, a collateral blood supply via the enhanced paravasal arteries develops (Fig. 15). At stage II, cannula placement is identical for primary orchidopexy. If the vessels were not previously transected, they are transected and the testicle is mobilized on the vas (Fig. 16). Great care is taken with the triangle of peritoneum between the juncture of the vas and the distal spermatic vessels. Placement in the scrotum is identical to that already described (Fig. 17).

TABLE 1 ■ Comparison of Open vs. Laparoscopic Orchiopexy Success Rates from Two Large Published Series^a

	Primary orchiopexy		Single-stage Fowler-Stephens		Two-stage Fowler-Stephens	
	<i>n</i>	%	<i>n</i>	%	<i>n</i>	%
Open orchiopexy (43)	80	81.3	321	66.7	56	76.8
Laparoscopic orchiopexy (35)	178	97.2	27	74.1	58	87.9

n, number of testes.
^aSuccess was defined as scrotal position and lack of atrophy.

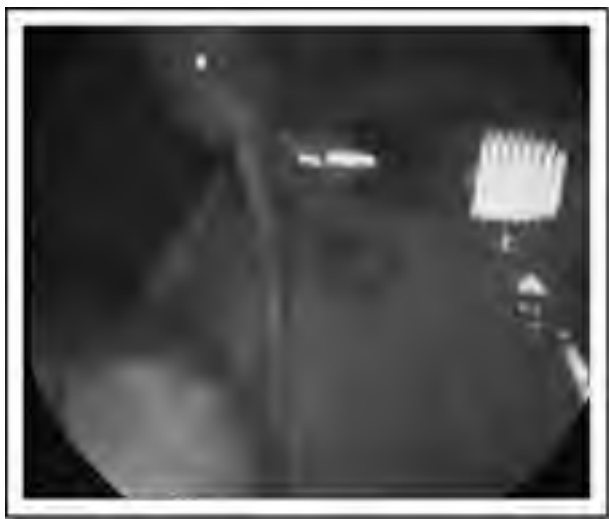

FIGURE 15 ■ Laparoscopic photograph of the appearance of the right groin in a child, who had a clip placed across the spermatic vessels six months earlier, and now is back for second-stage Fowler–Stephens orchidopexy.

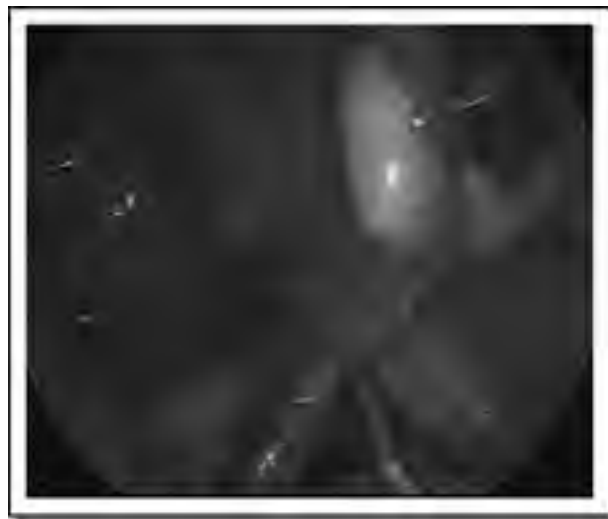


FIGURE 16 ■ Laparoscopic photograph—additional clips are placed and the spermatic vessels are divided.

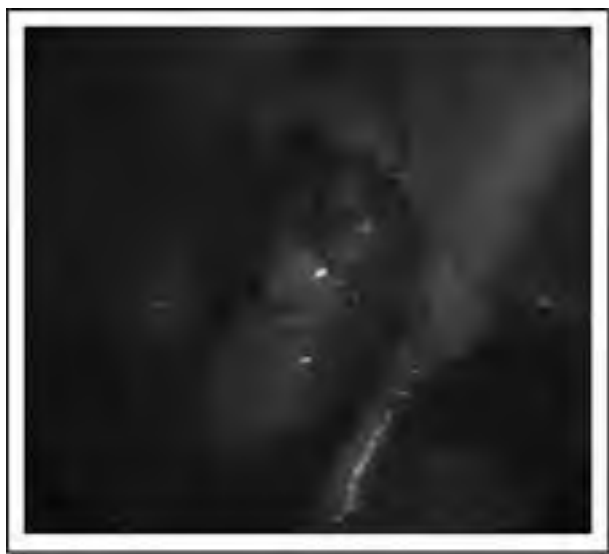


FIGURE 17 ■ Laparoscopic photograph—after dissection to free the testicle on the enhanced vassal vasculature of the vas deferens, the testicle is brought to the ipsilateral hemiscrotum.



FIGURE 18 ■ Laparoscopic photograph of the left groin in a child with an abdominal medial ectopic testicle.

Testicles having a horizontal lie in the abdomen and often appearing to be “ovarian” on laparoscopy can be quite difficult to deal with. Although no studies examining the histology of these testicles have been conducted, orchiectomy is probably indicated if unilateral. Micro-orchidopexy might be considered for bilateral cases.

In the case of normal vessels and vas entering a closed ring, most would agree that some form of inguinal exploration is required and that can be done in most cases from above with a laparoscopic approach. Occasionally, the testicle will migrate intra-abdominally to a medial ectopic position. These abdominal medial ectopic testes are quite difficult to manage because they have short spermatic vessel leashes and also a short vas deferens (Fig. 18). Thus, the advantages of the Prentiss maneuver are obviated.

Testicles having a horizontal lie in the abdomen and often appearing to be “ovarian” on laparoscopy can be quite difficult to deal with. Although no studies examining the histology of these testicles have been conducted, orchiectomy is probably indicated if unilateral. Micro-orchidopexy might be considered for bilateral cases.

“Micro-orchidopexy” is the term applied to the procedure in which an abdominal undescended testicle is autotransplanted to the scrotum by microvascular techniques. Originally described by Silber and Kelly (36), the procedure was modified by Wacksman et al. (37). Wacksman et al., who have accumulated the greatest experience,

recently described the use of laparoscopy to elevate and move the testicle. Then through an open incision, the microcoaptation to the recipient vessels is performed (38). In a small series of what clearly are difficult situations, they report excellent results.

SUMMARY

- Laparoscopies for the nonpalpable testicle have become the standard approach in many U.S. and European centers.
- The advantages of laparoscopic diagnosis, localization, and orchidopexy are felt to outweigh the disadvantages.
- The alternative to laparoscopic localization and diagnosis and laparoscopic orchidopexy is open inguinal exploration and open orchidopexy. However, some investigators have raised serious concerns regarding the reliability of open inguinal exploration to rule out an intra-abdominal testis. In fact, a number of series have reported abdominal testicles identified via laparoscopy after "negative open explorations" (25,35,39–42).
- A critical assessment of the surgical outcomes of open orchidopexy for the intra-abdominal testicle has shown less than optimal success rates with regards to acute atrophy (43,44).
- A multicenter review by Baker et al. suggests that therapeutic laparoscopy offers the highest success rate for orchidopexy for the management of the intra-abdominal testicle (Table 1) (35).
- Laparoscopic orchidopexy like all other surgeries can be associated with complications (35).
- Many of the complications were due to the practice of blind cannula placement and Veress needle insufflation. Most pediatric surgeons have now abandoned such approach in children.
- Reported complications include (i) acute testicular atrophy; (ii) bowel perforation (45); (iii) cecal volvulus; (iv) bladder perforation (13); (v) ileus, vas injury, bowel incarceration at the site of the parietal peritoneal closure of the internal ring, spermatic vessel avulsion necessitating an unplanned single-stage Fowler-Stephens orchidopexy (35).

REFERENCES

1. Levitt SB, Kogan SJ, Engel RM, Weiss RM, Martin DC, Ehrlich RM. The impalpable testis: a rational approach to management. *J Urol* 1978; 120:515–520.
2. Jordan GH, Winslow BH. Laparoscopic single stage and staged orchiopexy. *J Urol* 1994; 152:1249–1252.
3. Cisek LJ, Peters CA, Atala A, Bauer SB, Diamond DA, Retik AB. Current findings in diagnostic laparoscopic evaluation of the nonpalpable testis. *J Urol* 1998; 160:1145–1149; discussion 1150.
4. Bell AI. Psychologic implications of scrotal sac and testes for the male child. *Clin Pediatr* 1974; 13:838–843, 846–847.
5. Cendron M, Keating MA, Huff DS, Keep CE, Snyder HM III, Duckett JW. Cryptorchidism, orchiopexy and infertility: a critical long-term retrospective analysis. *J Urol* 1989; 142:559–562; discussion 572.
6. Tomboc M, Lee PA, Mitwally MF, Schneck FX, Bellinger M, Witchel SF. Insulin-like 3/relaxin-like factor gene mutations are associated with cryptorchidism. *J Clin Endocrinol Metab* 2000; 85: 4013–4018.
7. Cortesi N, Ferrari P, Zambarda E, Manenti A, Baldini A, Morano FP. Diagnosis of bilateral abdominal cryptorchidism by laparoscopy. *Endoscopy* 1976; 8:33–34.
8. Bloom DA. Two-step orchiopexy with pelviscopic clip ligation of the spermatic vessels. *J Urol* 1991; 145:1303–1033.
9. Jordan GH, Winslow BH, Robey EL. Laparoendoscopic surgical management of the abdominal/transinguinal undescended testicle. *J Endourol* 1992; 6:157.
10. Duckett JW. Pediatric laparoscopy: prudence, please [editorial]. *J Urol* 1994; 151:742–743.
11. Jordan GH. Children's genitourinary laparoscopic surgery: the pro side [editorial]. *Urology* 1994; 44:812–814.
12. Molenaar JC, Hazebroek FW. Diagnostic laparoscopy should not be routinely done in non palpable testes. *Neder Tijdschr Geneesk* 1993; 137:582.
13. Bogaert GA, Kogan BA, Mevorach RA. Therapeutic laparoscopy for intra-abdominal testes. *Urology* 1993; 42:182–188.
14. Huff DS, Hadziselimovic F, Duckett JW, Elder JS, Snyder HM. Germ cell counts in semithin sections of biopsies of 115 unilaterally cryptorchid testes. The experience from the Children's Hospital of Philadelphia. *Eur J Pediatr* 1987; 146(suppl 2):S25–S27.
15. Huff DS, Hadziselimovic F, Snyder HM III, Blythe B, Duckett JW. Histologic maldevelopment of unilaterally cryptorchid testes and their descended partners. *Eur J Pediatr* 1993; 152(suppl 2): S11–S14.
16. Elder JS. Management of the Abdominal Undescended Testicle. Presented at the American Association of Genitourinary Surgeons, Amelia Island FL, April 2004.
17. Oh J, Landman J, Evers A, Yan Y, Kibel AS. Management of the postpubertal patient with cryptorchidism: an updated analysis. *J Urol* 2002; 167:1329–1333.

18. Rajfer J. Congenital anomalies of the testis and scrotum. In: Walsh et al., eds. *Campbell's Urology*. Philadelphia: WB Saunders Company, 1998:2172–2192.
19. Hrebinko RL, Bellinger MF. The limited role of imaging techniques in managing children with undescended testes. *J Urol* 1993; 150:458–460.
20. Wolverson MK, Houttuin E, Heiberg E, Sundaram M, Shields JB. Comparison of computed tomography with high-resolution real-time ultrasound in the localization of the impalpable undescended testis. *Radiology* 1983; 146:133–136.
21. Cain MP, Garra B, Gibbons MD. Scrotal-inguinal ultrasonography: a technique for identifying the nonpalpable inguinal testis without laparoscopy. *J Urol* 1996; 156:791–794.
22. Maghnie M, Vanzulli A, Paesano P, et al. The accuracy of magnetic resonance imaging and ultrasonography compared with surgical findings in the localization of the undescended testis. *Arch Pediatr Adolesc Med* 1994; 148:699–703.
23. Castilho LN, Ferreira U. Laparoscopy in adults and children with nonpalpable testes. *Andrologia* 1987; 19:539–543.
24. Froeling FM, Sorber MJ, de la Rosette JJ, de Vries JD. The nonpalpable testis and the changing role of laparoscopy. *Urology* 1994; 43:222–227.
25. Perovic S, Janic N. Laparoscopy in the diagnosis of non palpable testes. *Br J Urol* 1994; 73:310–313.
26. Milad MF, Haddad MJ, Zein TA, et al. Laparoscopy for the impalpable testes. Initial experience of one center. *Int Surg* 1994; 79:163–165.
27. Ferrer FA, Cadeddu JA, Schulam P, Mathews R, Docimo SG. Orchiopexy using 2 mm. laparoscopic instruments: 2 techniques for delivering the testis into the scrotum. *J Urol* 2000; 164:160–161.
28. Schulam PG, Hedican SP, Docimo SG. Radially dilating trocar system for open laparoscopic access. *Urology* 1999; 54:727–729.
29. Gill IS, Ross JH, Sung GT, Kay R. Needlescopic surgery for cryptorchidism: the initial series. *J Pediatr Surg* 2000; 35:1426–1430.
30. Ross JH, Gill IS, Kay R. Needlescopic surgery for cryptorchidism. *Dialogues. Pediatr Urol* 1999; 22.
31. Rozanski TA, Wojno KJ, Bloom DA. The remnant orchiectomy. *J Urol* 1996; 155:712–713; discussion 714.
32. Merry C, Sweeney B, Puri P. The vanishing testis: anatomical and histological findings. *Eur Urol* 1997; 31:65–67.
33. Grady RW, Mitchell ME, Carr MC. Laparoscopic and histologic evaluation of the inguinal vanishing testis. *Urology* 1998; 52:866–869.
34. Elder JS. Laparoscopy for impalpable testes: significance of the patent processus vaginalis. *J Urol* 1994; 152:776–778.
35. Baker LA, Docimo SG, Surer I, et al. A multi-institutional analysis of laparoscopic orchidopexy. *BJU Int* 2001; 87:484–489.
36. Silber SJ, Kelly J. Successful autotransplantation of an intra-abdominal testis to the scrotum by microvascular technique. *J Urol* 1976; 115:452–454.
37. Wacksman J, Dinner M, Handler M. Results of testicular autotransplantation using the microvascular technique: experience with 8 intra-abdominal testes. *J Urol* 1982; 128:1319–1321.
38. Wacksman J, Billmire DA, Lewis AG, Sheldon CA. Laparoscopically assisted testicular autotransplantation for management of the intra-abdominal undescended testis. *J Urol* 1996; 156:772–774.
39. Lakhoo K, Thomas DF, Najmaldin AS. Is inguinal exploration for the impalpable testis an outdated operation? *Br J Urol* 1996; 77:452–454.
40. Boddy SA, Corkery JJ, Gornall P. The place of laparoscopy in the management of the impalpable testis. *Br J Surg* 1985; 72:918–919.
41. Koyle MA, et al. The role of laparoscopy in the patient with previous negative inguinal exploration for impalpable testis. *J Urol* 1994; 151:236 (abstract 35).
42. Koyle MA, Rajfer J, Ehrlich RM. The undescended testis. *Pediatr Ann* 1988; 17:39, 42–46.
43. Docimo SG. The results of surgical therapy for cryptorchidism: a literature review and analysis. *J Urol* 1995; 154:1148–1152.
44. Gibbons MD, Cromie WJ, Duckett JW Jr. Management of the abdominal undescended testicle. *J Urol* 1979; 122:76–79.
45. Caldamone AA, Amaral JF. Laparoscopic stage 2 Fowler-Stephens orchiopexy. *J Urol* 1994; 152:1253–1256.

Jonathan H. Ross and Richard Sutherland*Glickman Urological Institute, Cleveland Clinic Foundation,
Cleveland, Ohio, U.S.A.*

■ INTRODUCTION

■ VESICoureTERAL REFLUX: MANAGEMENT

■ TRANSVESICAL CROSS-TRIGONAL
APPROACH

■ LAPAROSCOPIC EXTRAVESICAL APPROACH

■ SUMMARY

■ REFERENCES

INTRODUCTION

Vesicoureteral reflux refers to the retrograde flow of urine from the bladder into the ureter(s) with filling or voiding. Reflux in itself is benign, but the reflux of infected urine can lead to pyelonephritis and subsequent renal scarring. High-pressure reflux in patients with neurogenic bladder can also lead to renal injury. Because most cases of reflux resolve spontaneously over several years, the initial management of reflux is usually medical—preventing infections with antibiotic prophylaxis and treating underlying conditions such as constipation and voiding dysfunction that may predispose to urinary tract infections or propagate reflux. Surgical intervention is generally considered for children with breakthrough infections despite prophylaxis, children with high-grade reflux (which is unlikely to resolve spontaneously), or for children who cannot tolerate or comply with medical treatment and periodic testing.

VESICoureTERAL REFLUX: MANAGEMENT

The standard surgical treatment for vesicoureteral reflux is ureteral reimplantation. Historically, this has been accomplished by transvesical approaches with either a cross-trigonal (Cohen) or orthotopic (Glenn–Anderson or Leadbetter–Politano) creation of the new intramural tunnel. Ureteral reimplantation is a well-established technique with a high success rate of greater than 95%. Failures usually have persistent reflux or, less frequently, ureteral obstruction requiring reoperation. To minimize the morbidity of the operation, an extravesical approach has been developed which allows ureteral mobilization and reimplantation without opening the bladder. In theory, this decreases the irritative voiding symptoms and hematuria that accompany a transvesical approach. However, there have been occasional patients with prolonged urinary retention following the extravesical approach. Both intravesical and extravesical open procedures have evolved to the point where many patients may be discharged the following day without a catheter or drain. However, there is still significant postoperative pain, and school-age children usually require recovery at home for one week before returning to school.

In an effort to minimize the morbidity of surgical intervention, minimally invasive techniques have been developed for the management of reflux. Subureteric injection is a minimally invasive technique that has been available for nearly 20 years, but has recently been popularized because of the Food and Drug Administration approval of dextranomer/hyaluronic acid copolymer (Deflux). Subureteric injections are performed with a needle through a cystoscope under a brief general anesthetic. There is virtually no morbidity or significant recovery associated with the procedure. Injection of a bulking agent under the ureteral orifice adds support to the intramural tunnel of the ureter, discouraging reflux. In Europe, Teflon[®] has been used successfully for this approach. Teflon injection was abandoned years ago in the United States because of reports of migration of the Teflon particles throughout the body—including to the brain. When injectable collagen became available, it was employed with reasonable

As with other laparoscopic operations, the strategy for obtaining a high degree of success is to reproduce the open operation and simply change the approach from an incision to the percutaneous placement of instruments. Both percutaneous cross-trigonal and laparoscopic extravesical reimplantations have been described.

success—approximately 75%. However, concerns regarding the use of an agent obtained from cows—the possibility of transmitting infectious agents and allergic reactions—along with the tendency of collagen to be absorbed over time have limited its use. Deflux is a synthetic material which is easy to inject and appears in initial reports to be durable. Success rates of 72% and 86% following a single injection have been reported (1–3). Success is related to the grade of reflux ranging from 90% for grade 1 reflux to 65% for grade 4 reflux. Most failures can be salvaged with a second injection. Ureteral obstruction occurs in only about 1 in 1000 injections. The introduction of this less invasive procedure to treat reflux has lowered the threshold for surgical intervention. Many parents will prefer an outpatient procedure to years of antibiotic prophylaxis and repeated radiographic studies. Indeed at some centers nearly all patients are treated initially with an injection, while other centers still use injection therapy only in those patients that fulfill the traditional criteria for surgical intervention.

Laparoscopic/percutaneous approaches to ureteral reimplantation have been developed in an attempt to achieve the high success of open reimplantation with the decreased morbidity associated a minimally invasive approach (4–7).

As with other laparoscopic operations, the strategy for obtaining a high degree of success is to reproduce the open operation and simply change the approach from an incision to the percutaneous placement of instruments. Both percutaneous cross-trigonal and laparoscopic extravesical reimplantations have been described.

TRANSVESICAL CROSS-TRIGONAL APPROACH

Under general anesthesia, cystoscopy is performed with the patient in the modified lithotomy position. A double-pigtail ureteral catheter is placed in the ureter. Two 5-mm balloon tip ports are inserted suprapubically into the distended bladder under cystoscopic visualization. These are passed one fingerbreadth superior to the pubic symphysis on either side of the midline. The balloons are inflated and the cuffs cinched down and secured to prevent extravasation of irrigation during the procedure. Both ports are placed to light wall suction to maintain a partially distended bladder throughout the procedure. Suction is adjusted to allow adequate distension for exposure, but to prevent overdistension and resulting extravasation. The cystoscope is exchanged for a resectoscope with Collins knife. Visualization for the entire procedure is maintained through the resectoscope.

Patients are kept in the hospital for 24 to 48 hours postoperatively and require minimal analgesia. Patients have been sent home with a Foley catheter for one week, though a shorter duration may be adequate. No drain is necessary, and the double-J stent may be removed at the end of the procedure or left in place at the surgeon's discretion.

LAPAROSCOPIC EXTRAVESICAL APPROACH

To begin a laparoscopic extravesical reimplantation, trocars are placed at the umbilicus and the right and left midclavicular lines. Trocars at the umbilicus and contralateral midclavicular line are working ports and the ipsilateral port is the camera access with a 30° lens. In the older child with a larger pelvis the contralateral working port may be placed slightly lower than the umbilicus on the midclavicular line to increase the working angle of the instruments. This helps with eventual suturing and knot placement. A final working port is placed midline in the suprapubic region to manipulate the ureter during suturing of the extravesical tunnel.

Postoperative care includes antibiotics and analgesics. A Foley catheter is not left in place unless a hole is made in the mucosa during creation of the tunnel. In that case, overnight drainage should be adequate with the Foley removed the next morning. In an uncomplicated case, the child can be expected to go home the same day as surgery.

SUMMARY

- A minimally invasive approach may be used both for transvesical and extravesical ureteral reimplantation. In both cases, postoperative pain and duration of recovery seem to be reduced compared to open approaches.
- The extravesical approach offers a technically easier ureteral dissection and reimplantation and avoids the need for postoperative catheter drainage. However, the risk of temporary urinary retention after bilateral extravesical reimplants is well documented. While retention is uncommon,

even a short course of intermittent straight catheterization would seem to defeat the goal of minimal morbidity, and so one might limit this extravesical approach to patients with unilateral reflux.

- The transvesical approach avoids the risks of a transperitoneal approach and dissection at the bladder base, but is technically more challenging and currently utilizes postoperative catheter drainage. To date, this approach has also only been employed in unilateral cases.
- The availability of injection therapy for reflux—an even less invasive approach—will limit the utilization of laparoscopic/percutaneous approaches, particularly because they are technically more challenging.
- Laparoscopic/percutaneous approaches do not have the long track record of success seen with standard open techniques, and the morbidity of the open approach is relatively mild because it is an extraperitoneal operation with a relatively quick recovery. Nonetheless, the laparoscopic/percutaneous approaches offer some marginal advantage in postoperative morbidity compared with open techniques while holding out the promise of greater success than injection therapy.

REFERENCES

1. Capozza N, Caione P. Dextranomer/hyaluronic acid copolymer implantation for vesico-ureteral reflux: a randomized comparison with antibiotic prophylaxis. *J Pediatr* 2002; 140:230–234.
2. Kirsch AJ, Perez-Brayfield MR, Scherz HC. Minimally invasive treatment of vesicoureteral reflux with endoscopic injection of dextranomer/hyaluronic acid copolymer: the children's hospitals of Atlanta experience. *J Urol* 2003; 170:211–215.
3. Puri P, Chertin B, Velayudham M, et al. Treatment of vesicoureteral reflux by endoscopic injection of dextranomer/hyaluronic acid copolymer: preliminary results. *J Urol* 2003; 170:1541–1544.
4. Ehrlich RM, Gershman A, Fuchs G. Laparoscopic vesicoureteroplasty in children: initial case reports. *Urology* 1994; 43:255.
5. Reddy PK, Evans RM. Laparoscopic ureteroneocystostomy. *J Urol* 1994; 152:2057.
6. Lakshmanan Y, Fung LC. Laparoscopic extravesicular ureteral reimplantation for vesicoureteral reflux: recent technical advances. *J Endourol* 2000; 14:589.
7. Gill IS, Ponsky LE, Desai M, et al. Laparoscopic cross-trigonal Cohen ureteroneocystostomy: novel technique. *J Urol* 2001; 166:1811–1814.

SECTION

VII

HAND-ASSISTED LAPAROSCOPY

HAND-ASSISTED LAPAROSCOPIC NEPHRECTOMY

Steven J. Shichman

Division of Urology, Department of Surgery, University of Wisconsin Medical School, Madison, Wisconsin, U.S.A.

Joseph R. Wagner

Department of Urology, Beth Israel Medical Center, Albert Einstein College of Medicine, New York, New York, U.S.A.

- | | |
|--|---|
| <ul style="list-style-type: none"> ■ INTRODUCTION ■ PATIENT SELECTION: INDICATIONS AND CONTRAINDICATIONS ■ PREOPERATIVE PREPARATION ■ DETAILED LAPAROSCOPIC TECHNIQUE <ul style="list-style-type: none"> Equipment and Hand-Assist Devices Trocar and Hand-Port Configuration | <ul style="list-style-type: none"> Stepwise Dissection Technique ■ PROS AND CONS OF DIFFERENT TECHNIQUES ■ TECHNICAL CAVEATS/TIPS ■ SPECIFIC MEASURES TAKEN TO AVOID COMPLICATIONS ■ SUMMARY ■ REFERENCES |
|--|---|

INTRODUCTION

Over the last decade, the use of laparoscopy by urologists has grown exponentially. From its initial use in pelvic lymph node dissections to contemporary use in radical prostatectomies, laparoscopy is quickly becoming a staple in the armament of modern urologic surgery. Because of its technical challenge and steep learning curve, however, laparoscopy tends to be limited to younger, fellowship-trained surgeons. In addition, standard laparoscopic techniques even in the most skilled hands are not routinely used for removal of kidneys with large tumors.

Hand-assisted laparoscopic nephrectomy was introduced in 1996 when Bannenberg et al. (1) performed the first nephrectomy in the pig. They reported that the hand-assisted laparoscopic nephrectomy technique was quick and easy to perform, and compared with conventional laparoscopic nephrectomy, operative times were shorter (30–45 vs. 90–120 minutes). In 1997, Nakada and colleagues (2) reported the first hand-assisted laparoscopic nephrectomy in a human for removal of a chronically infected kidney from stone disease. Since 1997, numerous publications have reported the use of hand-assisted techniques for radical nephrectomies, nephroureterectomies, donor nephrectomies, partial nephrectomies, and dismembered pyeloplasties (3–7). Since 1998, we have performed over 500 hand-assisted laparoscopic renal procedures using hand-assisted techniques.

Hand-assisted laparoscopic offers a minimally invasive technique, which is easy to learn even for the nonlaparoscopic surgeon. This technique has given hundreds of community-based urologists the ability to offer their patients a minimally invasive alternative to standard extirpative techniques.

Hand-assisted techniques utilize all the principles of standard laparoscopy but offer the surgeons the advantage of using their most versatile instrument available: their hand. The hand aids in dissection, exposure, retraction, and maintaining hemostasis. The hand may also assist in more advanced techniques such as intracorporeal suturing and knot tying. Furthermore, by maintaining tactile sensation, the surgeon is able to palpate vessels and organs that may not be discerned by visualization alone, thereby potentially minimizing the risk of injury to vital structures, particularly during difficult dissections. In essence, hand-assisted laparoscopic combines the advantages of laparoscopic and open surgery (8).

Pure laparoscopic nephrectomy has inherent limitations. When operating on large, bulky tumors, it may be difficult to adhere to principles of oncologic surgery using standard laparoscopic techniques. In addition, removal of an intact specimen

Hand-assisted laparoscopic offers a minimally invasive technique, which is easy to learn even for the nonlaparoscopic surgeon. This technique has given hundreds of community-based urologists the ability to offer their patients a minimally invasive alternative to standard extirpative techniques.

requires an incision usually as large, or larger, than a “hand-access” incision. Hand assistance helps the urologist maintain standard principles of oncologic surgery while employing a minimally invasive approach. In addition, the operative time can usually be shortened as compared to pure laparoscopic surgical techniques. Finally, if an incision is going to be utilized to remove the intact kidney, there is a clear benefit in making this incision early on in the procedure and using the hand to facilitate the entire procedure.

PATIENT SELECTION: INDICATIONS AND CONTRAINDICATIONS

Indications for hand-assisted laparoscopic nephrectomy can include almost any scenario in which an open nephrectomy is warranted. The most common indications include nephrectomy for functional renal masses (renal cell carcinoma being the most common pathology), nonfunctioning kidneys, and renovascular hypertension. Hand-assisted techniques can also be applied to nephroureterectomy hand-assisted laparoscopic nephrectomy for live donor renal transplants and upper tract transitional cell carcinoma.

The most favorable patients, especially during the initial learning phase, include those who are relatively thin, have unviolated abdominal cavities, and have small lower pole tumors located away from the renal hilum.

Care must be taken in evaluating whether a patient is appropriate for hand-assisted laparoscopic nephrectomy. The most favorable patients, especially during the initial learning phase, include those who are relatively thin, have unviolated abdominal cavities, and have small lower pole tumors located away from the renal hilum.

Several conditions make a patient less than ideal for initial attempts at hand-assisted cases. Obese patients can be a significant challenge since excessive adipose tissue can make dissection tedious and difficult. Multiple prior abdominal surgeries predispose to intraperitoneal adhesions, which are time consuming to lyse and increase the risk of visceral injury. Patients with extremely muscular abdominal walls have reduced abdominal wall compliance that reduces the working space, restricting the use of the hand. Relative contraindications to hand-assisted techniques also include extremely large tumors, extensive renal vein or inferior vena cava thrombus, history of severe perirenal and/or intra-abdominal inflammatory conditions, ipsilateral abdominal wall stomas, and pregnancy. As the surgeon's experience grows, patients with relative contraindications become more amenable to the hand-assisted technique. Absolute contraindications include caval thrombus extending above the hepatic veins, large tumors with direct extension into the body wall or adjacent viscera, and uncorrectable bleeding disorders.

PREOPERATIVE PREPARATION

Patients should be appropriately informed of the surgeon's experience and the risks and benefits of hand-assisted techniques versus standard laparoscopy and open surgical techniques. Preoperative discussions should always include the caveat that conversion to an open nephrectomy is possible. Consent must include permission for open nephrectomy. A type and screen should be obtained. Patients are instructed to take a clear liquid diet starting the day prior to surgery. Since an empty bowel helps maximize working space and allows for more comfortable dissection, a mechanical bowel prep is suggested. We use an 8 oz bottle of magnesium citrate the afternoon before surgery followed by a Fleets™ enema in the evening. The patient should have nothing to eat or drink by mouth after midnight except for a sip of water with medications the morning of surgery.

Prior to induction of general anesthesia and endotracheal intubation, pneumatic antiembolic stockings are applied. After induction of anesthesia, a nasogastric/orogastric tube and a Foley catheter are used in order to keep the stomach and bladder decompressed. Prophylactic antibiotics are administered. The patient is then positioned in semilateral decubitus position at a 45° angle, using gel pads to support the side of the pathology (Fig. 1). A padded neuro-armrest is used to support the upper arm. An axillary roll is not required using the semilateral position. The lower leg is flexed and the upper leg extended with pillows placed in between. The table is left flat and not flexed. In order to allow the patient to be rolled intraoperatively from a near supine position to the full flank position, three inch cloth tape is wrapped over the patient and passed under the operating room table several times to secure the patient's head, shoulders, chest, hips, and legs. Upper and lower body warming blankets are used to maintain core body temperature throughout the case. The surgical field from nipples to pubis and laterally to the mid axillary line should be shaved. After the patient is positioned, it is

FIGURE 1 ■ Patient positioning.

important to widely prep and drape in order to accommodate placement of the hand-assist device and trocars.

DETAILED LAPAROSCOPIC TECHNIQUE

Equipment and Hand-Assist Devices

The operating room is assembled in a similar manner as for any laparoscopic procedure. Equipment used in hand-assisted cases versus pure laparoscopic cases is similar as well.

Two important instruments exclusive to hand-assisted surgery include a ringless laparotomy pad and the hand-assist device.

A clean, rolled up laparotomy pad with the ring removed is placed into the abdomen through the hand incision. The laparotomy pad is used to help retract and dry tissues. Drier tissues are easier to grasp and dissect, and tissue planes are easier to identify. It also saves time not having to stop and insert a suction/irrigating instrument. If the laparotomy pad becomes excessively bloody it can absorb a significant amount of light, which can darken the video image. Replacing a bloody laparotomy pad with a clean one can dramatically brighten the video image.

The purpose of the hand-access device is to enable the surgeon to comfortably insert the nondominant hand into the abdominal cavity through a small incision without the loss of the pneumoperitoneum. There is no perfect hand-access device.

Each device has its advantages and disadvantages. Factors determining the ideal choice of a hand-access device for a specific case include the patient's body habitus and pathology, and the surgeon's experience and preference using each individual device. All devices require similar-size incisions (3–4 in) in the abdominal wall, but vary widely on how these maintain a seal around the surgeon's arm and wrist. Unlike the first-generation devices, none of the new products adhere to the body wall using adhesive seals. These adhesives seals were tedious and difficult to apply and were very prone to leakage.

Devices that are currently on the market include Gelport^a, Lapdisc^b, and Omniport^c. All of these devices secure to the body wall using two concentric rings that are attached together with vinyl or rubber. One ring is inserted on the undersurface of the abdominal wall and the other ring rests on the outside surface of the body wall. The material holding the two rings together is placed on stretch, maintaining the seal at the body wall and acting as a wound protector. These second-generation devices can be directly inserted into the abdominal cavity without first insufflating, which is a definite time saver.

Advantages of the Gelport (Fig. 2) device include an excellent seal, flexibility, and comfort offered by the gel. The unique gel-like polymer through which the

Two important instruments exclusive to hand-assisted surgery include a ringless laparotomy pad and the hand-assist device.

The purpose of the hand-access device is to enable the surgeon to comfortably insert the nondominant hand into the abdominal cavity through a small incision without the loss of the pneumoperitoneum. There is no perfect hand-access device.

^aApplied Medical, Rancho Santa Margarita, CA.

^bEthicon, Cincinnati, OH.

^cIntermed, Selling, NV.



FIGURE 2 ■ Gelport device. *Source:* Courtesy of applied medical.

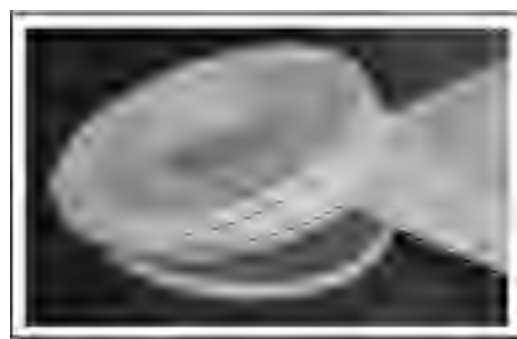

FIGURE 3 ■ Lapdisc device. *Source:* Courtesy of Ethicon.

surgeon's hand is inserted is flexible and soft around the wrist. Additionally, this polymer can be temporarily pierced by an instrument or trocar and maintain a seal at the puncture site. Instruments can even be inserted through the gel while the hand is inserted in the device. Other advantages include the fact that removal of the surgeon's hand from the abdominal cavity does not cause loss of pneumoperitoneum and rarely causes the device to become dislodged. The Gelport device has the largest template or footprint, requiring a large area for application. This is not a problem in most cases, but in small-framed patients the device may be too large to use in a right lower quadrant incision that is commonly used for a right-sided nephrectomy. In these cases, the anterior iliac spine may prevent the device from sitting evenly against the body wall, thereby jeopardizing the seal. A smaller version of this device has recently become available to obviate these problems. Gelport is the most expensive hand-access device on the market.

The Lapdisc (Fig. 3) is the least expensive device on the market and is the easiest to use. There are no pieces that need to be assembled, and insertion of the device is quick and easy. This device has the smallest footprint, fitting almost anywhere on most abdominal walls and rarely interferes with adjacent trocars. An oversized device is available for patients with thicker than normal abdominal walls. The iris that tightens around the surgeon's wrist, to develop the seal, can alternatively be tightened around a trocar or completely closed on its self to maintain the pneumoperitoneum. This iris requires meticulous adjustment around the wrist. If it is too tight the hand will quickly tire and become painful, if too loose, the device will leak. When removing the hand from the abdomen the iris must be adequately loosened or the Lapdisc will inadvertently be removed. Pneumoperitoneum is lost when the hand is removed but can easily be re-established by quickly closing the iris.

The Omniport (Fig. 4) is an inflatable device, which maintains an excellent seal and rarely becomes dislodged once it is inserted. As with the Gelport and Lapdisc, the surgeon's hand can rapidly be removed and reinserted, which is a major advantage for resident teaching programs when the teaching surgeon must quickly take over the case to avert or manage a potential complication. The device can be insufflated to maintain pneumoperitoneum without the hand being inserted, but an accessory trocar or instrument cannot be inserted through the device. Unfortunately, the device can be difficult to insert. Additionally, care must be taken to assure that bowel or omentum is not caught under the rigid inner ring, which is unforgiving and can easily damage soft tissue.

As with all forms of minimally invasive surgery, products will continue to change and improve. It is not practical or cost effective for any one operating room to have all products available. Surgeons performing hand-assisted laparoscopic should periodically evaluate the hand-access devices available and select the one or two devices they feel are best suited for their needs.

Trocar and Hand-Port Configuration

We have used the following hand incision and trocar configurations successfully in over 500 cases with little modification. Numerous factors must be considered when determining the optimal positioning of trocars and the hand incision. These factors include



FIGURE 4 ■ Omniport device. *Source:* Courtesy of intermed.

the specific operation being performed, the patient's anatomy, the surgeon's experience and the surgeon's hand and forearm size.

At the start of the case the table is rolled so that the patient is in a near supine position. The midline should always be marked, which aids in trocar placement as well as provides a quick and accurate guide if emergent laparotomy is necessary. Placement of the hand incision is made with the patient in this position as this allows for easier access to the peritoneal cavity and ensures better cosmetic results, especially in obese patients.

The length of the hand incision in centimeters is usually equal to the surgeon's glove size. Once the incision is made and the peritoneal cavity is entered, test the size and length of the incision for comfort. If the incision is too small, parasthesias and cramping of the surgeon's hand can result, which will make the operation more difficult. Too large of an incision may result in the hand device coming dislodged and loss of the pneumoperitoneum.

The renal hilum is approximately 8–12 cm cephalad to the umbilicus, but this distance can vary widely based on patient body habitus and vascular anatomy. Examine the patient's computed tomography scan and calculate this distance by counting the number of tomographic images between the renal hilum and the umbilicus. If the distance is greater than 12 cm, the surgeon has short arms, the patient is obese, or the girth of the abdominal cavity is larger than normal consider moving the hand incision cephalad and/or lateral, which allows improved access to the renal hilum.

The hand incision should be far enough from the operative target to allow insertion of the entire hand and wrist into the peritoneal cavity.

The surgeon's wrist should have free range of motion and the fingertips should comfortably reach the renal hilum (the most important part of the dissection).

If the hand incision is placed too close to the kidney, the hand will not be able to be completely inserted into the abdominal cavity, losing maneuverability of the wrist and fingers. The hand will act more as a retractor and less optimally as a dissector.

Attempt to place the hand incision as low as possible on the abdominal cavity, as this will result in decreased postoperative discomfort and respiratory compromise. Additionally, always try to avoid cutting muscle fibers, as this will reduce postoperative morbidity and reduce the risk of incisional hernias. We use a low midline or peri-umbilical hand incision for a left nephrectomy and a muscle splitting right lower quadrant incision for a right nephrectomy.

For a right-sided nephrectomy (Fig. 5), the hand incision is placed in the right lower quadrant lateral to the rectus muscle, just below the level of the umbilicus. The skin is incised in line with the external oblique fascial fibers and the abdominal wall musculature is split. In a small percentage of right-sided cases, the incision is made in line with the internal oblique fibers and shifted more cephalad. This alteration gives the surgeon the option to extend the incision cephalad and medially, creating a low lateral subcostal incision if the case cannot be completed laparoscopically.

If emergent conversion is required, an incision should be made in a location that will allow most efficient and safe management of the situation at hand. Trying to manage a complication or difficult case through an extended hand incision if it will not offer optimal exposure is not recommended.

After insertion of the hand-assist device, the working instrument port is placed just below or above the umbilicus and the camera port is placed in the supraumbilical midline approximately 8 cm cephalad to the working trocar. The camera and working instruments may be switched at any time to facilitate the dissection. A third port is placed in the right mid-clavicular line at the costal margin that allows placement of a liver retractor. Placement of this port more medially will result in the liver retractor leaning against the gallbladder, potentially causing injury.

For a left nephrectomy (Fig. 6), the hand port is placed midline in the infraumbilical or periumbilical region. The camera port is placed in the anterior axillary line at the level of the umbilicus while the working instrument port is placed in the midclavicular line, just below the level of the umbilicus. For very large upper pole tumors, an additional superior midclavicular working port may be used for the most cephalad part of the dissection. Adequate mobilization of the spleen obviates the need for a splenic retraction port.

In morbidly obese patients or patients with very rotund and protuberant abdominal walls, the hand and trocar template is shifted lateral and cephalad. In a left-sided nephrectomy, the hand incision is placed lateral to the rectus muscle belly and the two trocar sites are moved approximately equidistance lateral to their standard locations. In a right-sided nephrectomy, the hand-access incision and trocar sites can

The surgeon's wrist should have free range of motion and the fingertips should comfortably reach the renal hilum (the most important part of the dissection).

If emergent conversion is required, an incision should be made in a location that will allow most efficient and safe management of the situation at hand. Trying to manage a complication or difficult case through an extended hand incision if it will not offer optimal exposure is not recommended.

be moved lateral any distance, as the hand-access incision is already lateral to the rectus muscle belly.

In almost all cases, we start out by making the hand incision and inserting the hand-access device and working trocar prior to establishing a pneumoperitoneum. In cases where there is a high index of suspicion for significant adhesions, the hand incision allows direct visualization of the abdominal cavity and open surgical lysis of adhesions. Lysis of extensive intra-abdominal adhesions through the hand incision can save a significant amount of time as compared to using a purely laparoscopic technique.

Another option is to initially establish the pneumoperitoneum using a Hasson trocar or Veress needle and inspect the peritoneal cavity using the laparoscope. This allows the surgeon to identify adhesions and appreciate variations of anatomy that may alter the positioning of the hand-assist device and/or trocars. We stopped using this technique after our first 100 cases, as we found that the placement of our hand incision and trocar placement was rarely, if ever, modified.

Once the pneumoperitoneum is established, it is maintained at a pressure of 12–15 mmHg as per standard laparoscopy.

Stepwise Dissection Technique

Left Radical Nephrectomy

The colon is released from the lateral sidewall by incising the white line of Toldt. Dissection is carried out from the splenic flexure to the iliac vessels. The colon is reflected medially using the back of the hand, while the fingertips help dissect the mesocolon off of the anterior aspect of Gerota's fascia. Dissection is continued in the cephalad direction, freeing the splenic flexure and releasing the splenorenal ligaments. The lateral attachments from the body sidewall to the spleen are now released up to the level of the gastric fundus, which allows the entire spleen and splenic flexure to fall medially.

Lateral attachments of the kidney to the body sidewall should be preserved, as these attachments are used for counter traction, which aids in the medial dissection of the renal hilum.

The plane between the tail of the pancreas and the anterior aspect of Gerota's fascia is then developed, which allows the tail of the pancreas to rotate medially with the spleen. The back of the hand is used as an atraumatic retractor on the spleen and the pancreas while the fingertips aid in dissection. Care is taken to leave the entire anterior aspect of Gerota's fascia intact. The colon and mesocolon are mobilized medially to allow identification of the aorta and renal hilum. Investing tissue overlying the hilar vessels is grasped with the fingertips, retracted anteriorly and a plane between these tissues and renal vein is developed using the harmonic scalpel or scissors. Once the anterior wall of the renal vein is exposed, meticulous dissection allows identification of both the gonadal vein and left adrenal vein entering the renal vein. These veins are dissected free of their surrounding tissues and doubly clipped both proximally and distally.

In some cases, we choose not to clip and divide the gonadal and adrenal vessels at this point in the procedure, as we do not want to have clips potentially interfere with the subsequent firing of the linear stapling device across the renal vein later in

Lateral attachments of the kidney to the body sidewall should be preserved, as these attachments are used for counter traction, which aids in the medial dissection of the renal hilum.

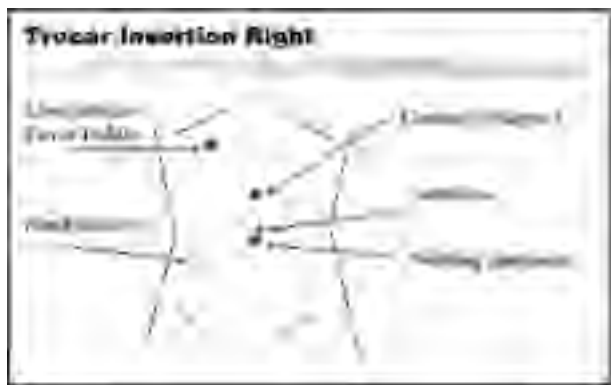


FIGURE 5 ■ Right-sided nephrectomy.

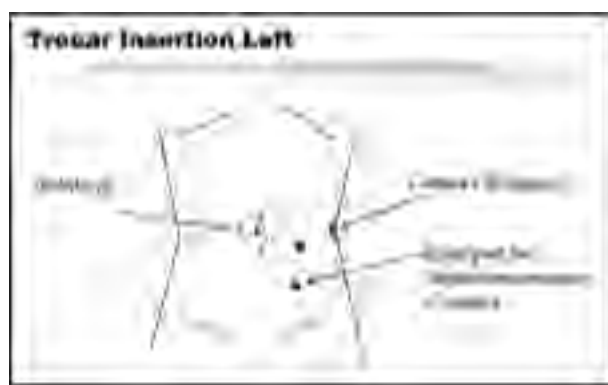


FIGURE 6 ■ Left-sided nephrectomy.

At this point, the surgeon must not be tempted to continue dissection of the renal vasculature from this anterior approach. The key to success of the hand-assisted laparoscopic nephrectomy technique is obtaining the vascular control from a posterior approach, which allows the fingertips to surround the renal hilum, helping with palpation, dissection, and control of the renal artery and vein.

the case. In other cases, the anatomy may be favorable for dividing the renal vein proximal to the adrenal vein, obviating the need for division of the adrenal and gonadal veins as long as the surgeon plans on removal of the adrenal gland with the kidney.

At this point, the surgeon must not be tempted to continue dissection of the renal vasculature from this anterior approach. The key to success of the hand-assisted laparoscopic nephrectomy technique is obtaining the vascular control from a posterior approach, which allows the fingertips to surround the renal hilum, helping with palpation, dissection, and control of the renal artery and vein.

In a very rare case, the main renal artery will be easily accessible anteriorly and should obviously be ligated and divided at this point in the procedure.

Dissection now continues at the most inferior lateral portion of Gerota's fascia, identifying the body sidewall and psoas muscle. The fingertips and the dissecting instrument of choice, either electrocautery scissors or harmonic scalpel, are used to reflect the perinephric fat in a medial and anterior direction off the psoas muscle. The surgeon works from a lateral to medial direction, coming across the gonadal vein, which is doubly clipped proximally and distally with hemoclips and divided. If a radical nephrectomy is performed, the ureter is also identified, clipped, and transected. Obviously, during a nephroureterectomy, the ureter is left intact. If a donor nephrectomy is being performed, the periureteral tissue is left adjacent to the ureter as well as leaving the ureter intact, and dissection of the ureter with all of its surrounding tissue is continued into the true pelvis below the iliac vessels.

The surgeon continues reflecting the inferior pole of the kidney, adjacent perinephric fat and overlying Gerota's fascia anteriorly and medially, releasing the posterior and lateral attachments to the body sidewall and posterior wall. All lateral attachments are now released up to the level of the adrenal gland, as the kidney is reflected anteriorly and medially with the back of the hand. Care must be taken not to enter Gerota's fascia. As the lateral attachments to the inferior aspect of the diaphragm are encountered, the surgeon must be careful not to perforate through the diaphragm. If perforation occurs, rapid loss of pneumoperitoneum will occur resulting in a tension pneumothorax. Perforations can be closed using hand-assisted laparoscopic suturing techniques; conversion to open nephrectomy may be necessary.

After releasing all lateral and posterior attachments, the kidney can be rolled anteriorly and medially, exposing the posterior aspect of the renal pedicle. The kidney should then be rolled back to its normal position and the tips of the second and third finger are placed just above the exposed anterior aspect of the renal vein. Using the thumb and dissecting instrument, the kidney is now rolled anteriorly and medially and the thumb is placed on the posterior aspect of the renal vessels. This maneuver helps identify the renal artery by direct palpation and allows for presentation of the artery to the dissecting instruments. Additionally, if bleeding is encountered the fingers can compress the pedicle achieving rapid hemostasis. Using curved electrocautery shears, a Maryland dissector or a harmonic scalpel to dissect the surrounding lymphatic tissue, the posterior and inferior aspects of the renal artery are exposed. Oftentimes, a lumbar vein is seen coursing across the posterior aspect of the proximal renal artery. This lumbar vein can complicate exposure and dissection of the renal hilum, as it may tether the renal vein or obscure the renal artery. In these situations, the lumbar vein must be clipped and divided. Following this, a right angle dissector is passed around the renal artery, completely freeing the vessel from all remaining attachments. The artery can be controlled using either three locking clips, two proximally and one distally, or by using an endoscopic linear stapling device.

After the renal artery is divided, the renal vein is freed of all surrounding lymphatic and connective tissues, and controlled using an endoscopic linear stapling device or large hemoclips. When the endoscopic stapler is used, great care must be taken not to engage any previously placed clips in between the jaws of the stapler. Both visual inspection and palpation with the hand assures that the stapler has not engaged any extraneous tissue or clips. Engaging clips in the jaws of the stapler will cause the device to misfire, resulting in a disruption of the staple line and significant bleeding.

If the adrenal gland needs to be removed with the left kidney, attention is now directed to the most superior phrenic attachments. With the spleen completely mobilized medially, diaphragmatic attachments are identified and controlled using hemoclips or the harmonic scalpel. There is usually a single artery originating from the diaphragmatic attachment, which must be adequately controlled with the harmonic scalpel or clips. The remaining vessels can usually be divided using the harmonic

scalpel. Care must be taken to identify any accessory phrenic veins that may exist, coursing from the diaphragm along the medial aspect of the adrenal gland toward the renal vein. These structures can be easily mistaken for the adrenal vein when dissecting in the region of the superior aspect of the renal vein. The superolateral attachments from the adrenal gland to the body sidewall are left intact and the medial attachments to the aorta are divided using the harmonic scalpel and clips when necessary. The remaining superolateral attachments and posterior attachments are now divided using the harmonic scalpel or electrocautery scissors and the specimen is completely freed.

If the adrenal gland is to be left intact, use visual inspection and palpation with the fingertips to locate the groove separating the adrenal gland from the kidney. The attachments between the adrenal gland and the superior aspect of the kidney are divided using the harmonic scalpel. If the adrenal vein has not already been divided, it should be doubly clipped proximally and distally, and sharply transected. Usually, a single large arterial branch originating from the renal artery feeds the most inferior lateral aspect of the adrenal gland. Hemoclips can be used on this vessel for adequate hemostasis.

Once dissection is complete, the kidney is removed through the hand incision. Oncologic principles are no different in the hand-assisted technique from that of open surgery. The specimen is delivered intact, without the need for morcellation, preserving the pathologic integrity of the specimen. The hand is placed back into the abdomen and pneumoperitoneum is re-established. Adequate hemostasis should be assessed at lower insufflation pressures (5–8 mmHg) confirming vascular control of all arterial and venous structures. Renal hilar vascular stumps are re-examined and any bleeding staple lines or vascular stumps can be controlled with laparoscopic suture ligation.

Left Donor Nephrectomy

The operative technique is a modification of the above description. After the anterior wall of the renal vein is identified, Gerota's fascia is entered along the medial inferior aspect of the kidney. The entire inferior aspect of the renal capsule is identified. Perinephric fat is released from the capsule using either electrocautery shears or the harmonic scalpel. The entire anterior aspect of the renal capsule is now exposed and the inferior and lateral perinephric fat is also cleared away. The adrenal gland is now released from the medial superior aspect of the renal capsule using the harmonic scalpel. The adrenal vein is identified, doubly clipped proximally and distally and sharply divided. Usually, there is one large arterial branch coming off the renal artery, feeding the lower aspect of the adrenal gland, which requires control with hemoclips. The gonadal vein is now clipped and divided. Ureteral dissection is now accomplished, leaving as much periureteral tissue with the ureter as possible, hopefully preventing subsequent ischemia of the transplant ureter. Ureteral dissection is continued into the true pelvis, distal to the common iliac vessels. The ureter is not divided until later in the procedure, just before division of the renal vasculature, thereby preventing leakage of large amounts of urine into the wound, which will compromise exposure and visualization. The posterior and remaining lateral attachments are now divided and the kidney is rolled anteromedially using a similar maneuver as described in the above left-sided operative technique. Great care must be taken not to place the renal artery on stretch, as this can cause both spasms of the renal artery and potential intimal disruption. Lumbar veins are now identified originating from the renal vein and usually coursing over the proximal aspect of the renal artery. Using Maryland and right angle dissectors, the veins are isolated, controlled using hemoclips, and sharply divided. The renal artery should now be completely freed from surrounding tissue and ready for division. The remaining posterior and inferior attachments to the renal vein are now divided and the renal vein should be completely freed proximally to the level of the vena cava. The renal artery is divided using the linear stapling device with a vascular load or secured with locking Weck clips and divided distal to the clips. The linear stapling device with vascular load is used to divide the renal vein at the level of the vena cava. The kidney is promptly removed and placed in iced preservation solution.

Right Radical Nephrectomy

After insertion of the hand device and trocars as previously described, the liver retractor is inserted and the liver is retracted medially. The right lobe of the liver is released from the body sidewall by incising the triangular ligament and, if necessary, the

anterior and posterior divisions of the coronary ligaments. There may also be significant attachments between the undersurface of the right lobe of the liver to the anterior/superior aspect of Gerota's fascia that must be released using the harmonic scalpel.

With the liver adequately mobilized medially, the attachments of the hepatic flexure to the overlying Gerota's fascia are released using the fingertips to develop pedicles, which are transected using the harmonic scalpel. The duodenum is now identified. If the vena cava is covered by the duodenum at the level of the renal hilum, a standard Kocher maneuver is performed using sharp dissection, mobilizing the duodenum medially off of the underlying renal hilum and vena cava. Investing tissue over the vena cava and renal vein is released and the anterior wall of the renal vein is skeletonized. The tendency would be to continue dissection on the renal hilum and vasculature at this time, but the surgeon should remember that it is imperative to obtain vascular control from the posterior approach.

Posterior exposure of the renal hilum is obtained by releasing all attachments of Gerota's fascia and perinephric fat to the body wall and rotating the kidney anteriorly and medially. We start this part of the dissection by directing our attention to the perinephric fat inferior to the lower pole of the kidney. Using fingertip dissection, the psoas muscle is identified and the fingers are passed lateral to medial raising the most caudal attachments of the perinephric fat off the psoas muscle. This large pedicle of tissue may include the right gonadal vein and ureter. The entire pedicle can be divided using an endoscopic linear stapling device. Alternatively, individual pedicles of fat can be divided using the harmonic scalpel, while the gonadal vein and ureter are individually clipped and sharply divided. In some cases, the gonadal vein can be gently retracted medially and division of the vein is unnecessary. Attachments of Gerota's fascia and perinephric fat to the lateral and posterior body sidewall are released using the harmonic scalpel or electrocautery shears.

With the hand placed posterior to the kidney, the kidney is elevated. Any remaining inferior medial attachments to the vena cava or lower pole accessory veins are identified and secured using clips or the harmonic scalpel. The second and third fingers are now curled behind the renal pedicle, allowing identification of the renal artery. Using gentle traction with the index finger, the artery can be pulled inferiorly and dissected free of surrounding lymphatic tissue using the harmonic scalpel, Maryland dissector, or right angle dissector. The artery can be controlled using locking clips or an endoscopic stapling device with a vascular cartridge. The renal vein is dissected free from surrounding lymphatic and investing tissues and transected using the endoscopic stapling device.

If the adrenal gland needs to be removed with the kidney, the liver must be aggressively mobilized medially. The most superior phrenic attachments and vessels feeding the adrenal gland should now be controlled and ligated with clips or the harmonic scalpel. The superolateral attachments should be left intact and dissection should continue along the vena cava, releasing medial attachments. The adrenal vein will now be easily identified and should be ligated using large hemoclips and sharply divided. The remaining posterior and lateral attachments can easily be transected using the harmonic scalpel.

If the adrenal gland does not need to be removed, use visual inspection and palpation with the fingertips to locate the groove separating the adrenal gland from the kidney. The attachments are divided using the harmonic scalpel.

PROS AND CONS OF DIFFERENT TECHNIQUES

Since the first laparoscopic nephrectomy was reported in 1991, the urologic community has increasingly accepted laparoscopic approaches for many urologic conditions (9). This acceptance has been fostered by numerous articles demonstrating certain advantages to laparoscopic surgery, particularly decreased postoperative pain and a quicker recovery time to normal activity. In examining whether a new surgical technique is appropriate, one must address the technique's outcomes, morbidities, and costs. Many factors may affect more than one of these criteria, e.g., operative times may affect both morbidity and cost. If outcome, morbidity, and cost results are acceptable, one must then determine whether the new technique is transferable to other surgeons and institutions. While such comparisons of different procedures are often difficult to interpret, certain trends are apparent when one examines open laparoscopy, and hand-assisted laparoscopic renal surgery.

For a purely ablative procedure, results demonstrate that laparoscopic and hand-assisted laparoscopic approaches are as efficacious as open surgery.

For a purely ablative procedure, results demonstrate that laparoscopic and hand-assisted laparoscopic approaches are as efficacious as open surgery.

With five-year follow-up, Portis et al. (10) demonstrated equal oncologic effectiveness for open and laparoscopic radical nephrectomy. This had also been similarly demonstrated by Ono et al. (11) in 2001 for renal masses less than 5 cm. Two-year follow-up data for laparoscopic and hand-assisted laparoscopic nephroureterectomy are also encouraging (4,12).

Laparoscopic partial nephrectomy can be daunting because of the potential for large blood loss and the need for reconstruction, which can be difficult. However, the laparoscopic procedure has been shown to have good pathologic outcomes (13,14).

Numerous studies have demonstrated equivalent graft function for open, laparoscopic, and hand-assisted laparoscopic donor nephrectomy (15,16). A randomized trial of hand-assisted laparoscopic versus open donor nephrectomy clearly demonstrated less analgesic use, shorter hospital stay, and quicker return to normal activity in the hand-assisted laparoscopic group (17). Similarly, shorter hospital stays and quicker returns to normal activity were seen when hand-assisted laparoscopic radical nephrectomy is compared to open radical nephrectomy (18). Postoperative complications were similar across all groups in each of these studies. Numerous other studies have similarly shown quicker recoveries for hand-assisted laparoscopic compared to open surgery. The biggest area of controversy is currently whether laparoscopic nephrectomy, particularly with morcellation, offers improved convalescence compared to hand-assisted laparoscopic. Several studies suggest this is not the case.

Despite larger tumors in the hand-assisted laparoscopic group, a nonrandomized study by Nelson and Wolf (19) demonstrated equal recovery and morbidity in the hand-assisted laparoscopic and morcellated laparoscopic groups.

A comparison of open, laparoscopic, and hand-assisted laparoscopic donor nephrectomy showed equally shorter recovery times with laparoscopic and hand-assisted laparoscopic nephrectomy (16).

During laparoscopic nephrectomy, no differences are seen in postoperative pain or hospital stay whether a specimen is morcellated or removed intact (20). Thus, hand-assisted laparoscopic and laparoscopic renal surgery appear to be equivalent when examining postoperative recovery.

Cost analysis, while important, is a very difficult issue to address. Some studies have demonstrated increased costs associated with laparoscopic procedures due to instrument costs, while other studies have shown decreased costs due to decreased hospital stays (21,22). The issue becomes even more confusing once physician time, patient work hours lost/gained, etc. are entered into the equation. Each element in the process (patient, surgeon, institution, etc.) will have a different cost/benefit ratio that should be considered though absolute values will always be lacking.

While hand-assisted laparoscopic and laparoscopic renal surgery show similar benefits, hand-assisted laparoscopic is a more easily mastered technique and can be utilized in situations where laparoscopy alone may not be sufficient. Overcoming the lack of three-dimensional viewing is very difficult for the novice laparoscopist; hand-assisted laparoscopic allows the surgeon's hand to be in the operative field and can compensate for the two-dimensional view. Open surgeons are not accustomed to operating with the long instruments and fulcrum points needed for laparoscopy; surgeons are comfortable dissecting and retracting with their open hand. Hand-assisted laparoscopic can also be helpful for large renal tumors that might not be as easily removed with straight laparoscopy. We have removed tumors up to 22 cm with hand-assisted laparoscopic and feel that nephrectomy under these conditions is more easily performed with hand-assisted laparoscopic than laparoscopy. Together, these factors describe a technique that is more easily learned and can be more widely applied than standard laparoscopy.

A comparison of open, laparoscopic, and hand-assisted laparoscopic donor nephrectomy showed equally shorter recovery times with laparoscopic and hand-assisted laparoscopic nephrectomy.

TECHNICAL CAVEATS/TIPS

- Trocar and hand incisions noted in the operative technique section are for right-handed surgeons. Use mirror image placement for left-handed surgeons.
- The nondominant hand should be in the operative field and the dominant hand performs fine dissection using laparoscopic instruments.
- Hand incisions are positioned to allow the back of the hand to be used as a retractor while using the fingers to grasp and dissect.

- If you are using your hand just as a retractor, your incision was not properly placed or you are not using your hand correctly.
- If you are using your hand as a retractor and not for dissection, think about locations where you can insert a 5 mm trocar for a laparoscopic retractor, freeing up your hand to be used as an instrument.
- Experienced laparoscopists initially may not use their hand properly. Do not use your hand as a passive instrument and perform standard laparoscopic surgery. You will be surprised how fast you can progress with your hand compared to standard laparoscopy.
- The surgeon with the hand in the operative field should be using the dissecting instruments. The surgeon has the proprioception, depth perception, and control of the tissues and should control the instruments.
- Insert a rolled-up lap pad into the abdominal cavity with your hand. It can help retract and dry tissues. Drier tissues are easier to grasp and dissect, and tissue planes are easier to identify. It also saves time not having to stop and insert a suction/irrigating instrument.
- Uses of your hand include: determining optimum position of trocars and insertion of trocars; locating laparoscopic instruments as they are inserted into the abdominal cavity; palpation; depth perception; proprioception; counter traction; and vascular control.
- Exposure! Do not work in a hole. Obtain wide exposure. Work in layers. If you get into bleeding while working in a hole, it is hard to get control of the bleeding vessel. If you have good exposure you will more likely be able to get control of the bleeder.
- Do not use monopolar cautery near veins, especially large veins such as the renal vein or vena cava. The large volume of fluid in these vessels acts as a great conductor and may be the path of least resistance for the current to get back to the ground plate, resulting in a hole in the vein wall.
- The harmonic scalpel is much safer for dividing small vessels compared to monopolar electrocautery instruments, but takes longer to divide the tissues. If ever uncertain, be safe and patient; use the harmonic scalpel.

SPECIFIC MEASURES TAKEN TO AVOID COMPLICATIONS

Many complications can be prevented with thoughtful, preoperative planning and attention to detail during surgery. As usual, this process begins with a thorough history and physical examination. Comorbidities should be assessed preoperatively with the physiologic changes unique to laparoscopic surgery kept in mind. For instance, an obese patient with obstructive pulmonary disease and CO₂ retention may be difficult to ventilate with resultant hypercapnia during hand-assisted laparoscopic nephrectomy. Radiographic studies should be carefully examined for mass size and location, level of the renal hilum, renal vein, or caval involvement, duplicated renal vessels, retroaortic renal veins, etc. These factors will influence hand/port placement and allow the surgeon to anticipate minor anatomic anomalies. Occasionally, we will also perform preoperative renal artery embolization for tumors in which we feel that the ability to control and transect the renal vein before the artery will be beneficial. While intraoperative bowel complications are rare, we still conservatively have all our patients perform a bowel preparation with clear liquids and magnesium citrate the day before surgery (23).

While most anesthesiologists are comfortable with short laparoscopic procedures such as cholecystectomy, hernia repair, etc., they may be less versed in major, longer laparoscopic cases and inappropriately treat the patient as they would an open nephrectomy. Given the decreased blood loss, decreased insensible loss, and decreased urine output due to insufflation pressures, this can result in fluid overload. Avoid nitrous inhalants, as they can cause bowel distension with decreased exposure. Insufficient ventilation can result in hypercapnia with pulmonary arrest or fatal arrhythmias. A multi-institutional review by Gill et al. (24) revealed that 35% of complications were due to the physiologic changes that occur during laparoscopy. Open communication before and during the surgery with the anesthesia team will avoid many of these complications.

When positioning the patient, be sure that all pressure points are well padded and the arms are positioned to avoid neurologic injuries. Initial access and trocar placement during laparoscopic surgery can be the cause of significant morbidity. As previously mentioned, we therefore make the hand incision first and place all subsequent trocars with hand guidance and/or direct visualization. Transilluminate the abdomen to avoid major vessels, particularly the epigastric. Having the patient secured to the table allows the surgeon to rotate the table for optimal exposure; exposure is obviously crucial in avoiding intraoperative injuries.

During right nephrectomy, incision of the triangular ligament with adequate liver mobilization will help avoid hepatic injuries. Similarly, the spleen and pancreas must be

Bleeding is not an uncommon complication of hand-assisted laparoscopic nephrectomy. Bleeding can be due to renal or adjacent organ injury as well as vascular injuries. These injuries can occur due to thermal injury, blunt trauma, or stapler/clip misadventure. Depending on the situation, pressure, endoclips or staplers, fibrin sealants, Surgicel, temporarily raising the insufflation pressure, or free suturing techniques can generally salvage the situation. However, one should not hesitate to obtain adequate assistance when necessary or to convert to an open procedure.

adequately mobilized during left nephrectomy. Care should be taken to avoid diaphragmatic injuries during splenic or hepatic mobilization as well as during the mobilization of large, upper pole tumors. In our experience, the most common indication of a diaphragm laceration is loss of space around the upper pole as the diaphragm is pushed inferiorly by the insufflation pressure. At times, this can be accompanied by hemodynamic or ventilatory changes. As long as there is no lung laceration and the patient is stable, the injury can be repaired and the CO₂ will be rapidly reabsorbed. If the pneumothorax is preventing adequate exposure or the patient is hemodynamically unstable, a small Heimlich valve tube can be placed to evacuate the pneumothorax and complete the procedure.

Bleeding is not an uncommon complication of hand-assisted laparoscopic nephrectomy. Bleeding can be due to renal or adjacent organ injury as well as vascular injuries. These injuries can occur due to thermal injury, blunt trauma, or stapler/clip misadventure. Depending on the situation, pressure, endoclips or staplers, fibrin sealants, Surgicel, temporarily raising the insufflation pressure, or free suturing techniques can generally salvage the situation. However, one should not hesitate to obtain adequate assistance when necessary or to convert to an open procedure.

Large tumors should be placed in a retrieval bag to prevent tumor breakage, spillage, or port seeding. All trocars should be removed under laparoscopic visualization to assess for bleeding. Significant bleeding can be controlled with fulguration or endoscopic suturing with a Carter Thomason needle. Care should be taken to completely close all indicated port sites as well as the hand incision to prevent postoperative herniations.

At the end of the procedure, the patient should be examined for signs of significant subcutaneous emphysema. The presence of diffuse crepitus is associated with mucosal absorption and resultant laryngeal obstruction in a patient in whom hyperventilation may be required to expel excess CO₂. Therefore, extubation in this setting must be controlled: Lack of cuff leak around endotracheal tube with a deflated balloon, chest X-ray evidence of pneumomediastinum, direct visualization of laryngeal coaptation, or baseline pulmonary insufficiency are all indications for delayed extubation.

In any surgery, diligent preoperative assessment and preparation, thoughtful operative planning and attention to detail during surgery, and open communication with the operative team will avoid most perioperative complications. The majority of complications during hand-assisted laparoscopic nephrectomy can be addressed laparoscopically, particularly with increased surgeon experience and skills. However, one should not hesitate to enlist the aid of a more experienced laparoscopic surgeon or convert to open surgery when the situation warrants.

SUMMARY

- Pure laparoscopy tends to be performed by younger, fellowship-trained surgeons.
- Hand-assisted laparoscopic offers a minimally invasive technique, which is easy to learn even for the nonlaparoscopic surgeon. This technique has given hundreds of community-based urologists the ability to offer their patients a minimally invasive alternative to standard extirpative techniques.
- For a purely ablative procedure, results demonstrate that laparoscopic and hand-assisted laparoscopic approaches are as efficacious as open surgery.
- Numerous studies have demonstrated equivalent graft function for open, laparoscopic, and hand-assisted laparoscopic donor nephrectomy.
- Numerous other studies have similarly shown quicker recoveries for hand-assisted laparoscopic compared to open surgery.
- While hand-assisted laparoscopic and laparoscopic renal surgery show similar benefits, hand-assisted laparoscopic is a more easily mastered technique and can be utilized in situations where pure laparoscopy alone may not be sufficient. hand-assisted laparoscopic can also be helpful for large renal tumors that might not be as easily removed with pure laparoscopy.

REFERENCES

1. Bannenberg JJ, Meijer DW, Bannenberg JH, Hodde KC. Hand-assisted laparoscopic nephrectomy in the pig: initial report. *Min Invasive Ther Allied Technol* 1996; 5:483-487.
2. Nakada SY, Moon TD, Gist M, Mahivi D. Use of the pneumo sleeve as an adjunct in laparoscopic nephrectomy. *Urology* 1997; 49(4):612-613.
3. Slakey DP, Wood JC, Hender D, et al. Laparoscopic living donor nephrectomy: advantages of the hand-assisted method. *Transplantation* 1999; 68:581.

4. Stifelman MD, Sosa RE, Andrade A, et al. Hand-assisted laparoscopic nephroureterectomy for the treatment of transitional cell carcinoma of the upper urinary tract. *Urology* 2000; 56:741.
5. Wolf JS, Seifman BD, Montie JE. Nephron sparing surgery for suspected malignancy: open surgery compared to laparoscopy with selective use of hand assistance. *J Urol* 2000; 163:1659–1664.
6. Wolf JS Jr., Moon TD, Nakada SY. Hand-assisted laparoscopic nephrectomy: comparison to standard laparoscopic nephrectomy. *J Urol* 1998; 160:22.
7. Wolf JS Jr., Tchetgen MB, Merion RM. Hand-assisted laparoscopic live donor nephrectomy. *Urology* 1998; 52:885.
8. Clayman RV. Ramon Guiteras lecture. American Urologic Association Convention, 2000.
9. Clayman RV, Kavoussi LR, Soper NJ, et al. Laparoscopic nephrectomy: initial case report. *J Urol* 1991; 146:278.
10. Portis AJ, Yan Y, Landman J, et al. Long-term followup after laparoscopic radical nephrectomy. *J Urol* 2002; 167:1257.
11. Ono Y, Kinukawa T, Hattori R, et al. The long-term outcome of laparoscopic radical nephrectomy for small renal cell carcinoma. *J Urol* 2001; 165:1867.
12. ElFettouh HA, Rassweiler JJ, Schulze M, et al. Laparoscopic radical nephroureterectomy: results of an international multicenter study. *Eur Urol* 2002; 42:447.
13. Gill IS, Matin SF, Desai MM, et al. Comparative analysis of laparoscopic versus open partial nephrectomy for renal tumors in 200 patients. *J Urol* 2003; 170:64.
14. Stifelman MD, Sosa RE, Nakada SY, et al. Hand-assisted laparoscopic partial nephrectomy. *J Endourol* 2001; 15:161.
15. Ratner LE, Montgomery RA, Kavoussi LR. Laparoscopic live donor nephrectomy. A review of the first 5 years. *Urol Clin North Am* 2001; 28:709.
16. Ruiz-Deya G, Cheng S, Palmer E, et al. Open donor, laparoscopic donor and hand-assisted laparoscopic donor nephrectomy: a comparison of outcomes. *J Urol* 2001; 166:1270.
17. Wolf JS Jr., Merion RM, Leichtman AB, et al. Randomized controlled trial of hand-assisted laparoscopic versus open surgical live donor nephrectomy. *Transplantation* 2001; 72:284.
18. Nakada SY, Fadden P, Jarrard DF, et al. Hand-assisted laparoscopic radical nephrectomy: comparison to open radical nephrectomy. *Urology* 2001; 58:517.
19. Nelson CP, Wolf JS Jr. Comparison of hand-assisted versus standard laparoscopic radical nephrectomy for suspected renal cell carcinoma. *J Urol* 2002; 167:1989.
20. Hernandez F, Rha KH, Pinto PA, et al. Laparoscopic nephrectomy: assessment of morcellation versus intact specimen extraction on postoperative status. *J Urol* 2003; 170:412.
21. Meraney AM, Gill IS. Financial analysis of open versus laparoscopic radical nephrectomy and nephroureterectomy. *J Urol* 2002; 167:1757.
22. Velidedeoglu E, Williams N, Brayman KL, et al. Comparison of open, laparoscopic, and hand-assisted approaches to live-donor nephrectomy. *Transplantation* 2002; 74:169.
23. Bishoff JT, Allaf ME, Kirkels W, et al. Laparoscopic bowel injury: incidence and clinical presentation. *J Urol* 1999; 161:887.
24. Gill IS, Kavoussi LR, Clayman RV, et al. Complications of laparoscopic nephrectomy in 185 patients: a multi-institutional review. *J Urol* 1995; 154:479.

HAND-ASSISTED LAPAROSCOPY: CURRENT STATUS

J. Stuart Wolf, Jr.

Division of Minimally Invasive Urology, Department of Urology, University of Michigan, Ann Arbor, Michigan, U.S.A.

Stephen Y. Nakada

Division of Urology, Department of Surgery, University of Wisconsin School of Medicine and Public Health, Madison, Wisconsin, U.S.A.

<ul style="list-style-type: none"> ■ INTRODUCTION ■ HISTORY ■ EXPERIENCE WITH HAND-ASSISTED LAPAROSCOPY <ul style="list-style-type: none"> Simple Nephrectomy Radical Nephrectomy Partial Nephrectomy Nephroureterectomy Donor Nephrectomy Cystectomy ■ COMPLICATIONS OF HAND-ASSISTED LAPAROSCOPY <ul style="list-style-type: none"> Specific Complications Controversial Circumstances Conclusion 	<ul style="list-style-type: none"> ■ COMPARISON OF HAND-ASSISTED LAPAROSCOPY TO OTHER LAPAROSCOPIC TECHNIQUES <ul style="list-style-type: none"> Radical Nephrectomy Partial Nephrectomy Nephroureterectomy Donor Nephrectomy Learning Curve Overall Comparison ■ SELECTION OF PATIENTS FOR HAND-ASSISTED LAPAROSCOPY <ul style="list-style-type: none"> Unique Factors Preferences by Procedure ■ SUMMARY ■ REFERENCES
--	---

Whatever role hand-assisted laparoscopy has in a given urologist's practice, there is no doubt that it has played a major role in the integration of laparoscopy into the mainstream of urologic practice.

INTRODUCTION

As with any surgical tool, hand-assisted laparoscopy is used differently by different practitioners. Some urologists perform only standard laparoscopic surgery, without ever using hand-assisted laparoscopy. Others use hand-assisted laparoscopy either selectively or as stepping stone to more difficult standard laparoscopic procedures. Still others use hand-assisted laparoscopy as virtually the only laparoscopic technique that they offer.

Whatever role hand-assisted laparoscopy has in a given urologist's practice, there is no doubt that hand-assisted laparoscopy has played a major role in the integration of laparoscopy into the mainstream of urologic practice.

HISTORY

It is difficult to attribute the concept of hand-assisted laparoscopy to any single person or report, but rather it may be described as a concept that evolved into a reality due to the rapid insurgence of standard laparoscopy in urology (1). In response to the difficulty of standard laparoscopy, particularly in complex cases, several physicians reported hand-assisted procedures, including nephrectomies, in the mid-1990s (2–4). What was most significant is that these reports revealed shorter operating room times and the removal of larger specimens.

As more urologists began performing hand-assisted laparoscopy, it soon became clear that improvements in the technology were necessary (5). Various approaches were described to troubleshoot hand access devices (6). The essence of an effective hand access device is the ability to maintain the pneumoperitoneum while a hand is inserted in the abdomen. Since the initial report using the Pneumo Sleeve, several companies and iterations of hand access devices have emerged (4,7,8). What is of clinical interest to most urologists is the evolution of hand access devices, from "sleeveless," to "glueless" and finally to "one-piece, multifunctionality" (Table 1).

EXPERIENCE WITH HAND-ASSISTED LAPAROSCOPY

There are logical benefits of performing inflammatory nephrectomies using hand-assisted laparoscopy because the normal anatomic planes are not often present.

Another procedure that can be improved by using hand-assisted laparoscopy is laparoscopic nephrectomy for autosomal dominant polycystic kidney disease.

Hand-assisted laparoscopy radical nephrectomy has proven to be an excellent approach to remove even larger specimens with reasonable operative times and convalescence similar to that of other minimally invasive nephrectomies.

In many ways, the strongest benefit of hand-assisted laparoscopy is the ability to manage large renal specimens intraoperatively, because these can be challenging using the standard approach. While many laparoscopists morcellate cancer specimens, those that select intact removal should consider using hand-assisted laparoscopy as an incision is necessary regardless.

Simple Nephrectomy

There are logical benefits of performing inflammatory nephrectomies using hand-assisted laparoscopy because the normal anatomic planes are not often present. Simple nephrectomy is often not so simple.

The initial report of hand-assisted laparoscopy nephrectomy included a patient with a severely inflamed kidney and obstructed ureter and a chronic indwelling nephrostomy tube (4). The benefits of hand-assisted dissection are useful when tissues are firm, and cannot be easily dissected without tactile feedback (9). There have been formal reports of hand-assisted laparoscopy simple nephrectomy and the technique, highlighting these concepts (10,11).

Another procedure that can be improved by using hand-assisted laparoscopy is laparoscopic nephrectomy for autosomal dominant polycystic kidney disease.

Initially reported using standard laparoscopy by Elashry et al., this series offered the first alternative to open surgery, which had higher complication rates and prolonged convalescence compared to its laparoscopic counterpart (12). The main concerns with standard laparoscopy for these patients include the management of large specimens and lesion extraction. In addition, access to the abdomen can be complex because the abdomen is filled by cystic disease. Making the hand incision to start the case can be beneficial when performing these cases as closed entry risks injuring cysts and other structures.

Similarly, bilateral nephrectomies are well suited to hand-assisted laparoscopy. Bilateral nephrectomy for autosomal dominant polycystic kidney disease has been reported using a single midline incision (13,14). These rather complex operations could be performed in four to five hours. Typically, repositioning the patient is not necessary.

Radical Nephrectomy

Radical nephrectomy was first reported using hand-assisted laparoscopy in 1996 (4). Including only the most recent updates of series, nine retrospective series have been published to date (Table 2) (15–23).

Hand-assisted laparoscopy radical nephrectomy has proven to be an excellent approach to remove even larger specimens with reasonable operative times and convalescence similar to that of other minimally invasive nephrectomies (17).

In many ways, the strongest benefit of hand-assisted laparoscopy is the ability to manage large renal specimens intraoperatively, because these can be challenging using the standard approach. While many laparoscopists morcellate cancer specimens, those that select intact removal should consider using hand-assisted laparoscopy as an incision is necessary regardless.

The use of early posterior artery control is effective in laparoscopic radical nephrectomy, a maneuver particularly suited to hand-assisted laparoscopy (9). Although a much newer approach than standard laparoscopic nephrectomy, series have accumulated quickly. The latest report by one of the authors (SYN) showed sustained convalescence, as well as cancer control similar to open nephrectomy at up to five years (23).

In addition, the urologist should consider using an entrapment sack for larger tumors, to minimize the risk of local recurrence at the extraction site.

TABLE 1 ■ Hand-Assisted Laparoscopy Devices: Evolution of Options

	Requires a sleeve	Requires adhesive	One piece construction	Requires inflation	Allows trocar passage through device	Can use instrument simultaneously	Hand exchanges without loss of pneumoperitoneum
PneumoSleeve ^a	Yes	Yes	No	No	No	No	No
Intromit Device ^b	No	Yes	No	No	No	No	No
Handport Device ^c	No	No	No	Yes	No	No	No
Omniport Device ^d	No	No	Yes	Yes	Yes	No	No
Lapdisc Device ^e	No	No	Yes	No	Yes	No	No
Gelpport Device ^f	No	No	No	No	Yes	Yes	Yes

^aDexterity Surgical, San Antonio, TX; ^bApplied Medical, Rancho Santa Margarita, CA; ^cSmith and Nephew, Port Charles, NY;

^dWeck Surgical, Research Triangle Park, NC; ^eEthicon Endosurgery, Cincinnati, OH; ^fApplied Medical, Rancho Santa Margarita, CA.

TABLE 2 ■ Published Hand-Assisted Laparoscopy Radical Nephrectomy Series

	No. of patients (HALS only)	Mean OR time (min)	Mean EBL (mL)	No. of conversion to open surgery	Mean MSO4 equivalents (mg)	No. of pts with minor/major complications	Mean hospital stay (days)
Batler et al. (15) ^a	12	238	294	0 ^b	35.7	0/1	4.4
Nelson and Wolf (16)	22	205	191	0	31	10/5	2.7
Stifelman et al. (17)	95	158	128	3	34	7/4	3.7
Baldwin et al. (18)	8	168	410	0	42.1	2/0	2.6
Busby et al. (19)	22	265	186	0	11.3	2/1	3.4
Lee et al. (20)	54	195	183	0	—	3/0	6.8
Patel et al. (21)	60	189	119	4	—	2/3	3.1
Hayakawa et al. (22)	14	261	204	1	—	0/1	15.4
Lowry and Nakada (23)	50	233	170	0	—	4/2	4.0
Total	337	198 ^c	165 ^c	2.4% ^d	31.2 ^c	8.9%/5.0% ^d	4.5 ^c

^aOne case in this series was a simple nephrectomy.
^bOne case was converted from retroperitoneoscopic to HALS.
^cWeighted mean.
^dPercentage occurrence of summed totals.
Abbreviations: HALS, hand-assisted laparoscopy; OR, operating room; EBL, estimated blood loss.

Partial Nephrectomy

Partial nephrectomy is a technically difficult operation, and is probably the most challenging laparoscopic renal procedure. Hand-assisted laparoscopic and standard laparoscopic (both transperitoneal and retroperitoneal) approaches have performed with success, with an even wider variety of maneuvers for collecting system closure and hemostasis. There have been four published series of hand-assisted laparoscopy partial nephrectomy for renal masses suspicious for malignancy (Table 3) (24–27). In none of the series were any final margins positive, although in the experience of Brown and associates additional resection was required in five patients based upon intraoperative frozen sections. All procedures were completed laparoscopically except for one conversion to open surgery in the series of Stifelman and associates. In the series of Wolf and associates, two of procedures were performed with standard laparoscopy and one was converted to hand-assisted laparoscopy from standard laparoscopy.

Nephroureterectomy

Following the first report of hand-assisted laparoscopy for nephroureterectomy, a single case among a series of 22 laparoscopic nephroureterectomies reported by Keeley and Tolley (28), there have been 10 series reported, totaling 196 cases (Table 4) (29–38). Resection of the distal ureter was performed in a variety of manners, including open resection of a bladder cuff, laparoscopic resection of a bladder cuff with either sutured or stapled closure, and transurethral resection of the bladder cuff. The mean operating time, including repositioning and removal of the distal ureter, was 315 minutes, not

TABLE 3 ■ Published Hand-Assisted Laparoscopy Partial Nephrectomy Series

	No. of pts.	Mean mass size (cm)	Mean OR time (min)	Mean EBL (mL)	No. of pts with postoperative hemorrhage	No. of pts with urine leak	No. of pts with other minor/major complications ^a	Mean hospital stay (days)
Wolf et al. (24) ^b	10	2.4	199	460	0	0	2/1	2
Stifelman et al. (25)	11	1.9	274	319	0	0	2/0	3.3
Brown et al. (26)	30	2.6	218	415	2	6	1/0	4
Pruthi et al. (27)	15	2.7	129	173	0	0	1/0	2.7
Total	66	2.5 ^c	204 ^c	351 ^c	3.0% ^d	9.1% ^d	9.1%/1.5% ^d	3.3 ^c

^aIncludes blood transfusions not accounted for in delayed hemorrhage column.
^bOf the 10 cases, two were standard laparoscopy.
^cWeighted mean.
^dPercentage occurrence of summed totals.
Abbreviations: OR, operating room; EBL, estimated blood loss.

TABLE 4 ■ Published Hand-Assisted Laparoscopy Nephroureterectomy Series

	No. of pts.	Method for distal ureter	Mean OR time (min)	No. of pts with minor/major complications	No. conversion to open surgery	Mean hospital stay (days)	Mean follow up (mo)	No. nonvesical recurrence
Chen et al. (29)	7	Open	224	—	0	7.3	7.8	0
Seifman et al. (30)	16	TUR	320	3/3	1	3.9	18	0
McGinnis et al. (31)	32	Laparoscopic, sutured	372	5/3	0	5.5	13	0
Li et al. (32)	10	Various	267	—	1	7.6	—	—
Chueh et al. (33)	7	Open	294	—	—	8.8	—	—
Landman et al. (34)	16	Laparoscopic, stapled	294	2/2	1	4.5	9.6	3
Wong and Leveillee (35)	14	Endoscopic cuff	—	—	0	2	8	0
Uozumi et al. (36)	10		456	4/1	0	0	—	—
Munver et al. (37)	30	Various	289	1/2	0	4.6	33	2
Kawauchi et al. (38)	54	Various	296	4/4	2	—	17	4
Total	196		315 ^a	12%/9.5% ^b	2.6% ^b	5.0 ^a	17.6 ^a	5.5% ^b

^aWeighted mean.
^bPercentage occurrence of summed totals.
Abbreviations: OR, operating room; TUR, transurethral resection.

including the 2.6% of patients in whom the procedure was converted to open surgery. The overall minor and major complication rates were 12% and 9.5%, respectively. With a mean follow-up of 17.6 months, the nonvesical recurrence rate has been 5.5%.

Donor Nephrectomy

Many of the series of donor nephrectomy reported by surgeons who did not start performing the procedure until the advent of hand-assisted laparoscopy have been performed using hand-assisted laparoscopy (Table 5) (39–51). Among these 13 series reporting 454 patients in total, the mean operative time was 224 minutes and the mean warm ischemia time of the harvested kidney was two minutes and 36 seconds. Aside from conversion to open surgery in 2.0% of patients, the minor and major complication rates were 13.2% and 2.7%, respectively. Of the studies, four detailed donor convalescence, reporting a mean return to nonstrenuous activity levels in 8.7 days.

TABLE 5 ■ Published Hand-Assisted Laparoscopy Donor Nephrectomy Series

	No. of pts.	Mean OR time (min)	Mean warm ischemia time (min)	No. of pts with minor/major complications	No. conversion to open surgery	Mean hospital stay (day)	Mean graft follow-up (mo)	No. graft ureteral complications	No. loss of graft
Wolf et al. (39)	10	215	2.9	3/0	0	1.8	5	0	0
Kercher et al. (40)	30	275	1.2	7/0	1	3.4	11.5	0	0
Buell et al. (41)	30	246	2.2	—	2	2.9	—	—	1
Wolf et al. (42)	23	206	3.1	4/0	0	1.7	3	2	3
Stifelman et al. (43)	60	240	2	3/3	0	3.5	—	1	0
Ruiz-Deya et al. (44)	23	165	1.6	2/0	1	2	12	0	0
Velidedeoglu et al. (45)	60	260	—	—	1	2.6	—	—	—
Lindstrom et al. (46)	11	197	3.6	0/0	0	6.2	—	—	—
Gershbein et al. (47)	29	205	2.4	2/0	1	2.3	—	0	0
Wadstrom et al. (48)	10	155	3.0	1/0	0	6.3	—	—	—
Buell et al. (49)	100	234	3.1	16/6	2	2.2	—	—	—
Mateo et al. (50)	18	269	3.4	2/1	1	4.1	—	0	—
Maartense et al. (51)	50	153	3	8/0	0	5	—	2	3
Total	454	224 ^a	2.6 ^a	13.2%/2.7% ^b	2.0% ^b	3.0 ^a	8.6 ^a	2.2% ^b	2.7% ^b

^aWeighted mean.
^bPercentage occurrence of summed totals.
Abbreviation: OR, operating room.

The results of the graft after hand-assisted laparoscopic donor nephrectomy have been excellent, with 97% functioning at a mean follow-up of 8.6 months.

The results of the graft after hand-assisted laparoscopic donor nephrectomy have been excellent, with 97% functioning at a mean follow-up of 8.6 months.

Ureteral complications occurred in 1.7% of recipients. Among the first 200 hand-assisted laparoscopy donor nephrectomies performed by one of the authors (JSW) at the University of Michigan, the one month, one year, and three year actuarial graft survival rates have been 97%, 96%, and 91%, respectively. The ureteral complication rate has been 6% overall, with a 16% ureteral complication rate prior to modifications in ureteral dissection (first 24 cases) and 4.5% in the 176 cases since then.

Cystectomy

Hand-assisted laparoscopy in urology was initially (4) and has been most frequently applied to renal disease. Concurrent with the more recent interest in laparoscopic prostatectomy and cystectomy, hand-assisted laparoscopy has been applied as well. A pure hand-assisted laparoscopy radical prostatectomy has not been reported, although authors have described open surgical prostatectomy through the lower midline incision used to place the hand-assisted laparoscopy device for concomitant radical nephrectomy (52,53), but hand-assisted laparoscopy cystectomy has been described. In their series of multiple-organ removal using hand-assisted laparoscopy, Troxel and Das reported a case of simple cystectomy for pyocystitis performed at the same time as simple nephrectomy for pyonephrosis. The first published description of hand-assisted laparoscopy radical cystectomy for urothelial carcinoma of the bladder was from Peterson et al. in 2002 (54). The ileal conduit urinary diversion was created with open surgical techniques through the incision for the hand-assisted laparoscopy device. The operative time was seven hours, there were no complications, the patient was discharged from the hospital seven days postoperatively, and he was back to work four weeks postoperatively. One of the authors (JSW) performed a similar (unreported) case in 2000, although the patient remained in the hospital for eight days postoperatively and suffered a small bowel obstruction requiring adhesiolysis six weeks postoperatively. The only series of hand-assisted laparoscopy radical cystectomy has been described by McGinnis et al. (55). In all seven patients, the hand-assisted laparoscopy device was placed through an infraumbilical midline incision. The cystoprostatectomies (all patients were men) were performed with hand-assisted laparoscopy and four laparoscopic ports, followed by open surgical ileal conduit urinary diversion through the hand-assisted laparoscopy incision. Of the seven procedures, one was converted to open surgery following cystoprostatectomy for failure to progress with the dissection of lymph node encircling the right external iliac vein. For the six cases completed with hand-assisted laparoscopy, the average operative time was 7.6 hours and the estimated blood loss was 420 mL. After a use of an average of 28.8 mg morphine equivalents, the patients were discharged from the hospital three to six days postoperatively (mean, 4.6 days). Aside from the one conversion to open surgery and two patients requiring transfusion of one and two units of blood, there were no other postoperative complications. All margins were negative except for one right ureteral margin positive for carcinoma-in-situ on final reading. Of the patients, two had positive pelvic lymphadenectomy specimens and received chemotherapy; one had progression of metastatic disease and died. Of the remaining five patients, all with negative pelvic lymphadenectomy specimens, one died of unrelated causes eight months postoperatively, two have no evidence of disease, and two developed local recurrences. The latter two are particularly concerning; a 29% pelvic recurrence rate is higher than expected. Although this may be simply an artifact of a small case series, it deserves further consideration.

COMPLICATIONS OF HAND-ASSISTED LAPAROSCOPY

Specific Complications

Hedican et al. reported a multi-institutional complications report including 196 patients undergoing various hand-assisted laparoscopy renal procedures (56). Procedures included 57 radical nephrectomies, 50 donor nephrectomies, 38 nephroureterectomies, 24 partial nephrectomies, 2 simple nephrectomies, and 2 other renal procedures. The data showed that 28 patients (14%) had minor complications, including urinary retention in 11 and prolonged ileus in four. Of the patients, 9.2% suffered major complications, including small bowel injury (3), hemorrhage requiring conversion (3) and reintubation (3). There were 12 (6.2%) intraoperative complications. Multiple complications occurred in 11 patients, accounting for 46% of all the complications. There were only two delayed complications, including one port site hernia and one small bowel

Conceptually, hand assistance should reduce complication rates, particularly intraoperative complications. More rapid dissection, better hemostasis, and more rapid identification of structures are publicized benefits of hand-assisted laparoscopy. In contrast, potential added risks include incisional complications, namely wound infection or hernias, and inadvertent bowel or adjacent organ injury due to the presence of the intra-abdominal hand, which sometimes is not always in view laparoscopically. Similarly, concerns of increased abdominal pain, and higher risks of ileus as compared to standard laparoscopy may be part of the postoperative expectations of patients undergoing hand-assisted laparoscopy procedures.

The morbidly obese are a controversial subgroup in laparoscopy. Hedican et al. reported that hand-assisted laparoscopy was not only safe but in fact beneficial in the obese subgroup.

It is the authors' belief that hand-assisted laparoscopy is particularly useful in the obese population, because the hand incision may be less significant in this patient subgroup. Moreover, these patients have capacious abdomens, which also favor the use of hand-assisted laparoscopy.

obstruction (57). It is important to emphasize that these institutions were pioneers of the approach, and many of the procedures were on the learning curve.

Conceptually, hand assistance should reduce complication rates, particularly intraoperative complications. More rapid dissection, better hemostasis, and more rapid identification of structures are all well publicized benefits of hand-assisted laparoscopy. In contrast, potential added risks of hand-assisted laparoscopy include incisional complications, namely wound infection or hernias (see below), and inadvertent bowel or adjacent organ injury due to the presence of the intra-abdominal hand, which sometimes is not always in view laparoscopically. Similarly, concerns of increased abdominal pain, and higher risks of ileus as compared to standard laparoscopy may be part of the postoperative expectations of patients undergoing hand-assisted laparoscopy procedures.

The morbidly obese are a controversial subgroup in laparoscopy. Hedican et al. (58) reported that hand-assisted laparoscopy was not only safe but also in fact beneficial in the obese subgroup.

They also assessed the profoundly obese (body mass index > 40) and found those patients doing similarly well. This finding is in contrast to the report of Mendoza et al. (59), which showed a greater risk of complications in the morbidly obese with standard laparoscopy. However, this study was a multicenter trial published in 1996, and thus may reflect technology and the global status of laparoscopy at that time. More recent data in standard laparoscopy have shown a similar complication rate in the morbidly obese (60).

It is the authors' belief that hand-assisted laparoscopy is particularly useful in the obese population, because the hand incision may be less significant in this patient subgroup. Moreover, these patients have capacious abdomens, which also favor the use of hand-assisted laparoscopy.

Finally, neuromuscular complications are worthy of note. Wolf et al. (61) reported a 2.7% risk of neuromuscular complications during laparoscopy, and although some cases in this series were hand-assisted laparoscopy procedures, the shortened operating room time for hand-assisted laparoscopy should decrease the risk of neuromuscular injury. Additionally, positioning for hand-assisted laparoscopy does not require as aggressive a flank position as standard renal surgery. Conversely, hand-assisted laparoscopy appears to produce more physical pain in some body parts of the surgeon than does standard laparoscopy (62).

Controversial Circumstances

There is some evidence that there is an increased risk of paralytic ileus using hand-assisted laparoscopy (44). However, this has not been borne out by other large series of hand-assisted laparoscopy. Nevertheless, the amount of bowel manipulation during the procedure, more pronounced early in a surgeon's experience, may lead to increased ileus and pain at the incision site postoperatively. Similarly, urologists must be careful closing the hand access incision, as with aggressive manipulation, the fascial incision may become torn. Similarly, the incision should be copiously irrigated once the hand device is removed, as often a midline hand access incision can be close to the edge of the sterile drape.

Conclusion

Many of the complications of standard laparoscopy are understated in the literature. Despite this, hand-assisted laparoscopy complications have been fairly well described. In general, we counsel our patients undergoing hand-assisted laparoscopy in a similar manner to those undergoing standard laparoscopy. Over time, every urologist will reach his or her comfort level with hand-assisted laparoscopy and risk of complications when using hand-assisted laparoscopy. It is likely that the amount of hand dissection plays some role in the convalescence of these patients.

COMPARISON OF HAND-ASSISTED LAPAROSCOPY TO OTHER LAPAROSCOPIC TECHNIQUES

The first comparison of hand-assisted laparoscopy and standard laparoscopy in urology was reported by the two authors in 1998, describing the first 13 hand-assisted and eight standard transperitoneal laparoscopic nephrectomies performed at the University of Michigan and the University of Wisconsin (5). The mean operative time for hand-assisted laparoscopy was 1.5 hour less than that for of standard laparoscopy, and there were fewer major complications in the hand-assisted laparoscopy group. These advantages were incurred without impact on convalescence. In 2003, Kercher et al. (63)

TABLE 6 ■ Published Series Comparing Standard Laparoscopic to Hand-Assisted Laparoscopy Radical Nephrectomy

	No. of patients and route	Mean OR time (min)	Mean estimated blood loss (mL)	No. conversion to open surgery	Mean MSO4 equivalents (mg)	No. of pts with minor/major complications	Mean hospital stay (days)
Batler et al. (15) ^a	12 standard RP	256	142	0 ^b	24.5	1/0	3.6
	12 HALS	238	294	0	35.7	0/1	4.4
Nelson and Wolf (16)	16 standard TP	270	289	0	30	4/2	2.4
	22 HALS	205	191	0	31	10/5	2.7
Baldwin et al. (18)	13 standard TP	168	125	0	22.9	0/0	1.3
	8 HALS	168	410	0	42.1	2/0	2.6
Hayakawa et al. (22)	16 standard TP	266	83	0	—	1/0	12.9
	14 HALS	261	204	1	—	0/1	15.4

^aOne case in this series was a simple nephrectomy.
^bOne case was converted from retroperitoneoscopic to HALS.
Abbreviations: HALS, hand-assisted laparoscopy; OR, operating room; RP, retroperitoneoscopic; TP, transperitoneal laparoscopic.

reported a larger comparison with their analysis of 39 patients undergoing standard laparoscopic nephrectomy and 80 patients undergoing hand-assisted laparoscopy nephrectomy. Importantly, the operations occurred over generally the same time period and there were no differences in preoperative characteristics of the patients and lesions. Differences in these factors have flawed other comparisons of these two techniques (see below). Similar to the findings of the earlier study (5), the hand-assisted approach reduced mean operative time by almost an hour and was associated with a lower complication rate. Hospital charges and length of stay were similar between the two groups. Noteworthy, wound complications tended to be less in the hand-assisted group. Both of these studies suggest that, at least early in a surgeon's experience, hand-assisted laparoscopy "shortens the learning curve" for transperitoneal nephrectomy. With regard to the wound complications, however, the data of Okeke et al. (64), who compared 13 hand-assisted laparoscopy nephrectomies with 16 standard laparoscopic ones, revealed a 23% incidence of major wound complications at the hand-assisted laparoscopy incision site compared to none in the standard group (two severe wound infections requiring readmission, and one incisional hernia).

In the personal series of 424 hand-assisted laparoscopy nephrectomies by one of the authors (JSW), infections and incisional hernias at the hand-assisted laparoscopy incision site have occurred in 6.8% and 3.5% of patients, respectively, compared to rates of 0.5% and 0.2% at the laparoscopic ports in the same patients. This increased rate of wound complications is an important consideration for hand-assisted laparoscopy.

Radical Nephrectomy

There have been four retrospective series comparing hand-assisted laparoscopy and standard laparoscopic radical nephrectomy (Table 6) (15,16,18,22). An additional small series reported by Okeke et al. (64) is described below in the section on nephroureterectomy. Of 38 laparoscopic radical nephrectomies in the study of Nelson and Wolf (16), 16 were performed with standard transperitoneal laparoscopy and 22 with transperitoneal hand-assisted laparoscopy. Cases were performed during the same time period, with those selected for hand-assisted laparoscopy being based primarily upon greater tumor size, specimen weight, and body mass index. Despite this, hand-assisted laparoscopy was 1.5 hours faster than standard laparoscopy during the first half of the series and 30 minutes faster in the second half (overall 65 minutes faster). The intensity and duration of convalescence was similar between the two groups, although there was a trend toward more abdominal pain with hand assistance. The other three series all found that hand-assisted laparoscopy improved operative time only minimally, and that there was a trend (not statistically significant) toward greater estimated blood loss, more analgesic use, and/or longer hospital stay in the hand-assisted laparoscopy group. Unfortunately, all four studies had factors that confound the comparisons. In that of Batler et al. (15), the comparison was with retroperitoneoscopic nephrectomy rather than standard transperitoneal laparoscopic nephrectomy as in the others. The greater tumor size, specimen weight, and body mass index in the hand-assisted laparoscopy group in the study of Nelson and Wolf would tend to make the hand-assisted laparoscopy results less favorable in comparison to standard laparoscopy. The responsible surgeon in the series of Baldwin et al. (18) had more than five years prior experience with standard laparoscopic

In the personal series of 424 hand-assisted laparoscopy nephrectomies by one of the authors (JSW), infections and incisional hernias at the hand-assisted laparoscopy incision site have occurred in 6.8% and 3.5% of patients, respectively, compared to rates of 0.5% and 0.2% at the laparoscopic ports in the same patients. This increased rate of wound complications is an important consideration for hand-assisted laparoscopy.

nephrectomy. Finally, Hayakawa et al. (22) performed the hand-assisted laparoscopy radical nephrectomies before the standard laparoscopic radical nephrectomies, rather than concurrently. Although these factors preclude an unbiased comparison between standard laparoscopy and hand-assisted laparoscopy for radical nephrectomy, important information can nonetheless be gleaned.

Partial Nephrectomy

With increasing experience with pure laparoscopy, the advantage of hand-assisted laparoscopy in terms of operative time diminishes, and is also less when the comparison is to retroperitoneoscopic radical nephrectomy, which is an inherently faster technique in properly selected patients.

There have been no published series directly comparing hand-assisted laparoscopy and standard laparoscopic partial nephrectomy. Some relative assessment can be made nonetheless. Of the hand-assisted laparoscopy partial nephrectomy series listed in Table 3, none included the use of renal hilar clamping. An advantage of hand-assisted laparoscopy for partial nephrectomy is direct parenchymal compression with the hand for hemostasis. That the estimated blood loss in these hand-assisted laparoscopy series tended to be greater than that reported in series that employed renal hilar clamping (65,66) likely owes to the lack of renal hilar clamping. If renal hilar clamping is used during hand-assisted laparoscopy partial nephrectomy, and hand-assisted laparoscopy does allow the use of large open surgical bulldog clamps that are helpful, then estimated blood loss should be similar. The other important aspect of partial nephrectomy to consider is final hemostasis and closure of the collecting system. Among the hand-assisted laparoscopy partial nephrectomy series listed in Table 3, laparoscopic suturing was used sparingly. Final hemostasis and collecting system closure were obtained primarily with coagulation devices and biologic sealants. A technique of closure that may be the best among the nonsutured techniques, that being a "patch" of fibrin glue and gelatin sponge (24,26), is best applied using hand-assisted laparoscopy.

Hand-assisted laparoscopy may be better suited to a nonsutured technique of hemostasis and collecting system closure, as some aspects of laparoscopic suturing are awkward with hand-assisted laparoscopy.

Although delayed hemorrhage or urinary leak occurred in only two and six patients, respectively, among the combined 66 patients in Table 3, as larger and deeper renal masses are approached in order to expand the pool of patients benefiting from laparoscopy, the nonsutured methods may prove to be unreliable. In the series of one of the authors (JSW), the hemorrhage/urine leak rate was 41% in 17 cases in which the collecting system and/or renal sinus were entered during laparoscopic partial nephrectomy (compared to 3.4% rate without such entry) when closure was performed

With increasing experience with pure laparoscopy, the advantage of hand-assisted laparoscopy in terms of operative time diminishes, and is also less when the comparison is to retroperitoneoscopic radical nephrectomy, which is an inherently faster technique in properly selected patients.

Hand-assisted laparoscopy may be better suited to a nonsutured technique of hemostasis and collecting system closure, as some aspects of laparoscopic suturing are awkward with hand-assisted laparoscopy.

TABLE 7 ■ Published Series Comparing Standard Transperitoneal Laparoscopic to Hand-Assisted Laparoscopy Donor Nephrectomy

	No. of patients and route	OR time (min)	Warm ischemia (min)	Minor/major complications (no.)	Conversion (no.)	Hospital stay (days)
Ruiz-Deya et al. (44)	11 standard	215	3.9	1/1	0	1.6
	23 HALS	165	1.6	2/0	1	2.0
Lindstrom et al. (46)	11 standard	270	5.0	3/0	0	6.5
	11 HALS	197	3.6	0/0	0	6.2
Velidedeoglu et al. (45)	40 standard	255	—	—	3	3.2
	60 HALS	260	—	—	1	2.6
Gershbein and Fuchs (47)	15 standard	276	3.8	1/0	0	2.0
	29 HALS	205	2.4	2/0	1	2.3
Mateo et al. (50)	29 standard	311	3.7	5/2	4	4.1
	18 HALS	269	3.4	2/1	1	4.1
El-Galley et al. (67)	28 standard	306	3.0	0/0	0	2.0
	17 HALS	249	2.0	1/0	0	2.0
Total	134 standard	278 ^a	3.7 ^a	11%/3.2% ^b	5.2% ^b	3.1 ^a
	158 HALS	232 ^a	2.5 ^a	7.1%/1.0% ^b	2.5% ^b	2.8 ^a

^aWeighted mean.

^bPercentage occurrence of summed totals.

Abbreviations: HALS, hand-assisted laparoscopy; OR, operating room.

In select cases, depending on the anatomical relationship of the mass to the rest of the kidney, the direct manual control of the operative site provided by hand-assisted laparoscopy is of great advantage.

In a report by Okeke and associates, although the operative time for laparoscopic radical nephrectomy was not improved by hand-assisted laparoscopy, the operative time for nephroureterectomy was reduced by 66 minutes compared to standard laparoscopy.

Hand-assisted laparoscopy tends to be faster and associated with shorter warm ischemia time. While there is also a small trend to fewer complications, less frequent conversion to open surgery, and shorter hospital stay, the differences are not clinically significant.

The decline in hand-assisted laparoscopy operative time with experience is more rapid than has been reported in series of standard laparoscopic nephrectomy.

with only fibrin-glue-based products. In 18 subsequent cases in which suture of the collecting system and sutured bolsters of the parenchymal defect were used, the postoperative hemorrhage rate fell to 11%, with no urine leaks. Inasmuch as laparoscopic suturing appears to be useful when resecting larger and deeper masses, and some find hand-assisted laparoscopy suturing of the renal defect awkward, the standard laparoscopic approach may be more attractive in some cases.

In select cases, depending on the anatomical relationship of the mass to the rest of the kidney, the direct manual control of the operative site provided by hand-assisted laparoscopy is of great advantage.

Nephroureterectomy

Landman et al. (34) compared 11 standard transperitoneal laparoscopic and 16 hand-assisted laparoscopy nephroureterectomies. The authors already had extensive prior experience with standard transperitoneal laparoscopic nephroureterectomy. Nonetheless, they found that hand-assisted laparoscopy reduced mean operative time by 72 minutes but did not alter significantly any measure of the intensity and duration of convalescence. The length of hospital stay did tend to be longer in the hand-assisted group, but the difference was not statistically significant (3.3 days vs. 4.5 days).

In a report by Okeke and associates, although the operative time for laparoscopic radical nephrectomy was not improved by hand-assisted laparoscopy, the operative time for nephroureterectomy was reduced by 66 minutes compared to standard laparoscopy.

Donor Nephrectomy

Standard transperitoneal laparoscopic and hand-assisted laparoscopy donor nephrectomy have been compared in six nonrandomized, retrospective series (Table 7) (44–47,50,67). The comparison of standard laparoscopy and hand-assisted laparoscopy is cleanest for this procedure, because candidates for donor nephrectomy are fairly a homogenous group. The results of all six studies have been remarkably similar.

Although recovery parameters were not assessed in a similar fashion, in three of the studies (44,47,67) there tended to be more postoperative narcotic use and/or slightly longer duration of convalescence in the hand-assisted laparoscopy group.

Hand-assisted laparoscopy tends to be faster and associated with shorter warm ischemia time. While there is also a small trend to fewer complications, less frequent conversion to open surgery, and shorter hospital stay, the differences are not clinically significant.

Learning Curve

The first few standard transperitoneal laparoscopic nephrectomies can be very challenging for the novice laparoscopist; operative times and complications are greatest in the first 20 cases (68). Ponsky et al. (69) reported use of one of the hand-assisted laparoscopy devices that can accept a laparoscopic port to simplify the adoption of standard laparoscopic nephrectomy for those already facile in hand-assisted laparoscopy nephrectomy. After insertion of a laparoscopic port within the hand-assisted laparoscopy device, the laparoscope is placed there and the usual working ports are inserted. At any time during the procedure, the laparoscope can be moved to another port to allow use of the surgeon's hand through the hand-assisted laparoscopy device. In this way, a surgeon can perform standard laparoscopy in those first few cases confident in the ability to rapidly convert to hand-assisted laparoscopy when necessary. Series have also documented that the "learning curve" of hand-assisted laparoscopy is shorter than the 20 or so cases that is estimated for standard transperitoneal laparoscopic nephrectomy. Gaston et al. (70), in a prospective survey of senior urology residents trained in open surgical nephrectomy but new to laparoscopy, found that by the fourth procedure residents reported a difficulty level less than that of open surgical nephrectomy. Operating time also decreased with each case, falling to half the duration of the first case by the time of the sixth procedure. Similarly, Wolf et al. (39), in their first 10 hand-assisted laparoscopy donor nephrectomies, found that the mean operative time was reduced from 4.2 hours in the first five patients to 2.9 hours in the second five patients. In a subsequent study, Hollenbeck et al. (71) determined that residents in training performing hand-assisted laparoscopy donor nephrectomy had a statistically and clinically significant reduction in operating time by the sixth case as primary surgeon.

The decline in hand-assisted laparoscopy operative time with experience is more rapid than has been reported in series of standard laparoscopic nephrectomy.

The benefit of hand-assisted laparoscopy is greater in the setting of more complex procedures (such as nephroureterectomy and donor nephrectomy), but is less when there is extensive prior experience or when compared to retroperitoneoscopy.

Patients with prior peritonitis, or abdominal surgery with postoperative complications that would be expected to worsen abdominal scarring, are the only subgroups in which we distinctly avoid a transperitoneal laparoscopic approach. Interestingly, patients with smaller abdomens, or prior abdominoplasty procedures, tend to be more challenging for hand assistance, because there is less room to work once the surgeon's hand is in the abdomen. These patients may benefit more from standard laparoscopy.

Hand-assisted laparoscopy allows shortened operating time, reduced need for conversion, enhanced teaching capability, and ease of control of hemorrhage, all of which benefit the busy clinician.

Overall Comparison

Overall, the published data suggest that hand-assisted laparoscopy is generally faster than standard transperitoneal laparoscopy, but that several factors alter the impact of hand-assisted laparoscopy with regard to operative time.

The intensity and duration of postsurgical recovery appears to be slightly increased by hand-assisted laparoscopy, but the magnitude of the difference between hand-assisted laparoscopy and standard laparoscopy is much less than that between hand-assisted laparoscopy and open surgery. For advanced procedures such as donor nephrectomy, hand-assisted laparoscopy appears to reduce the likelihood of conversion to open surgery.

The benefit of hand-assisted laparoscopy is greater in the setting of more complex procedures (such as nephroureterectomy and donor nephrectomy), but is less when there is extensive prior experience or when compared to retroperitoneoscopy.

SELECTION OF PATIENTS FOR HAND-ASSISTED LAPAROSCOPY

Ultimately, it is the surgeon's decision whether patients should undergo open, standard laparoscopic, or hand-assisted laparoscopic approaches. Generally, hand-assist techniques are favored anytime intact removal of the kidney is indicated, such as nephroureterectomy, donor nephrectomy, and certain large radical nephrectomies (72). Some believe that hand assistance is an approach that is more straightforward for more urologists, making hand-assisted laparoscopy an option whenever a minimally invasive nephrectomy or procedure is feasible.

Unique Factors

Patients with prior peritonitis, or abdominal surgery with postoperative complications that would be expected to worsen abdominal scarring, are the only subgroups in which we distinctly avoid a transperitoneal laparoscopic approach. Interestingly, patients with smaller abdomens, or prior abdominoplasty procedures, tend to be more challenging for hand assistance, because there is less room to work once the surgeon's hand is in the abdomen. These patients may benefit more from standard laparoscopy.

When selecting patients for hand-assisted laparoscopy, several factors play a role. While prior abdominal surgery poses an increased risk in standard laparoscopy, we have found making the hand incision first, gaining safe abdominal access, and then inspecting the insufflated abdomen with the laparoscope and placing ports under endoscopic control to be quite efficient.

In contrast, morbidly obese patients do very well with hand-assisted laparoscopy, as their abdomens are usually capacious, and the significance of the hand incision is much less over an over significant surface area. Finally, cosmesis plays a role in the decision-making. While standard laparoscopy avoids any incision, often more trocar sites are utilized. The hand incision in many patients can be Pfannestiel, and thus cosmetically preferable as there are fewer port sites. However, generally we utilize a midline or lower abdominal location, and thus create an abdominal scar.

In general, the overriding benefit of hand-assisted laparoscopy is the surgeon's confidence in the approach. Many times, a surgeon may opt for a hand-assisted laparoscopy procedure over a standard laparoscopic approach, and visa versa based on technical preference.

Hand-assisted laparoscopy allows shortened operating time, reduced need for conversion, enhanced teaching capability, and ease of control of hemorrhage, all of which benefit the busy clinician.

Preferences by Procedure

For extirpative renal surgery, we generally favor hand-assisted laparoscopy for procedures that require intact specimen extraction (nephroureterectomy and donor nephrectomy) as well as for large radical nephrectomies. Approaches to partial nephrectomy are in flux. For procedures with smaller specimens (adrenalectomy, prostatectomy, and lymph node dissection) and most reconstructive procedures, we prefer either the standard or robotic approaches. Other novel procedures, such as cystectomy and diversion, simultaneous bilateral nephrectomies and nephrectomy for polycystic kidneys, also favor hand-assisted laparoscopy. Regardless, guiding principles of selection for hand-assisted laparoscopy focus on approach (morcellation vs. intact removal), prior history (abdominoplasty and prior operations), body habitus, and surgeon's competence.

SUMMARY

- Hand-assisted laparoscopy has played a major role in the integration of laparoscopy into the mainstream of urologic practice.
- Overall, the published data suggest that hand-assisted laparoscopy is generally faster than standard transperitoneal laparoscopy.
- The benefit of hand-assisted laparoscopy is greater in the setting of more complex procedures (such as nephroureterectomy and donor nephrectomy), but is less when there is extensive prior experience or when compared to retroperitoneoscopy.
- The intensity and duration of postsurgical recovery appears to be slightly increased by hand-assisted laparoscopy, but the magnitude of the difference between hand-assisted laparoscopy and standard laparoscopy is much less than that between hand-assisted laparoscopy and open surgery.

REFERENCES

1. Nakada SY, Wolf JS Jr. hand-assisted laparoscopy in urology: a 5-year critical update – introduction. *J Endourol* 2004; 18:311.
2. Tierney JP, Oliver SR, Kusminsky RE, Tiley EH, Boland JP. Laparoscopic radical nephrectomy with intra-abdominal manipulation. *Min Inv Ther* 1994; 3:303.
3. Bannenberg JJG, Meijer DW, Bannenberg JH, Hodde KC. Hand-assisted laparoscopic nephrectomy in the pig: initial report. *Min Invas Ther Allied Technol* 1996; 5:483.
4. Nakada SY, Moon TD, Gist M, Mahvi D. Use of the Pneumo Sleeve as an adjunct in laparoscopic nephrectomy. *Urology* 1997; 49:612.
5. Wolf JS Jr, Moon TD, Nakada SY. Hand-assisted laparoscopic nephrectomy: comparison to standard laparoscopic nephrectomy. *J Urol* 1998; 160:22.
6. Purohit S, Slakey D, Conerly V, et al. Making hand-assisted laparoscopy easier: preventing CO₂ leak. *J Endourol* 2001; 15:943.
7. Rane A, Dasgupta P. Prospective experience with a second-generation hand-assisted laparoscopic device and comparison with first-generation devices. *J Endourol* 2003; 17:895.
8. Stifelman M, Patel R. hand-assisted laparoscopy devices and operating room set-up: pearls and pitfalls. *J Endourol* 2004; 18:315.
9. Nakada SY. Hand-assisted laparoscopic nephrectomy. *J Endourol* 1999; 13:9.
10. Stifelman M, Andrade A, Sosa RE, Shichman S. Simple nephrectomy: hand-assisted technique. *J Endourol* 2000; 14:793.
11. Anderson KR. Simple nephrectomy: managing the difficult case: xanthogranulomatous pyelonephritis and autosomal dominant polycystic kidney disease. *J Endourol* 2000; 14:799.
12. Elashry OM, Nakada SY, Wolf JS Jr, McDougall EM, Clayman RV. Laparoscopy for adult polycystic kidney disease: a promising alternative. *Am J Kidney Dis* 1996; 27:224.
13. Rehman J, Landman J, Andreoni C, McDougall EM, Clayman RV. Laparoscopic bilateral hand assisted nephrectomy for autosomal dominant polycystic kidney disease: initial experience. *J Urol* 2001; 166:42.
14. Jenkins MA, Crane JJ, Munch LC. Bilateral hand-assisted laparoscopic nephrectomy for autosomal dominant polycystic kidney disease using a single midline HandPort incision. *Urology* 2002; 59:32.
15. Batler RA, Campbell SC, Funk JT, Gonzalez CM, Nadler RB. Hand-assisted vs. retroperitoneal laparoscopic nephrectomy. *J Endourol* 2001; 15:899.
16. Nelson CP, Wolf JS Jr. Comparison of hand-assisted versus standard laparoscopic radical nephrectomy for suspected renal cell carcinoma. *J Urol* 2002; 167:1989.
17. Stifelman MD, Handler T, Nieder AM, et al. Hand-assisted laparoscopy for large renal specimens: a multiinstitutional study. *Urology* 2003; 61:78.
18. Baldwin DD, Dunbar JA, Parekh DJ, et al. Single-center comparison of purely laparoscopic, hand-assisted laparoscopic, and open radical nephrectomy in patients at high anesthetic risk. *J Endourol* 2003; 17:161.
19. Busby E, Das S, Rao Tunuguntla HSG, Evans CP. Hand-assisted laparoscopic vs the open (flank incision) approach to radical nephrectomy. *BJU Int* 2003; 91:341.
20. Lee SE, Ku JH, Kwak C, Kim HH, Paick SH. Hand assisted laparoscopic radical nephrectomy: comparison with open radical nephrectomy. *J. Urol* 2003; 170:756.
21. Patel VR, Leveillee RJ. Hand-assisted laparoscopic nephrectomy for stage T1 and large stage T2 renal tumors. *J Endourol* 2003; 17:379.
22. Hayakawa K, Aoyagi T, Ohashi M, Hata M. Comparison of gas-less laparoscopy-assisted surgery, hand-assisted laparoscopic surgery and pure laparoscopic surgery for radical nephrectomy. *Int J Urol* 2004; 11:142.
23. Lowry PS, Nakada SY. Hand-assisted laparoscopic radical nephrectomy. *J Endourol* 2004; 18:337.
24. Wolf JS Jr, Seifman BD, Montie JE. Nephron-sparing surgery for suspected malignancy: open surgery compared to laparoscopy with selective use of hand-assistance. *J Urol* 2000; 163:1659.
25. Stifelman MD, Sosa RE, Nakada SY, Schichman S. Hand-assisted laparoscopic partial nephrectomy. *J Endourol* 2001; 15:161.
26. Brown JA, Hubosky SG, Gomella LG, Strup SE. Hand assisted laparoscopic partial nephrectomy for peripheral and central lesions: a review of 30 consecutive cases. *J Urol* 2004; 171:1443.
27. Pruthi RS, Chun J, Richman M. The use of fibrin sealant during laparoscopic partial nephrectomy. *BJU Int* 2004; 93:813.

28. Keeley JFX, Tolley DA. Laparoscopic nephroureterectomy: making management of upper-tract transitional-cell carcinoma entirely minimally invasive. *J Endourol* 1998; 12:139.
29. Chen J, Chueh S-C, Hsu W-T, Lai M-K, Chen S-C. Modified approach of hand-assisted laparoscopic nephroureterectomy for transitional cell carcinoma of the upper urinary tract. *Urology* 2001; 58:930.
30. Seifman BD, Montie JE, Wolf JJS. Prospective comparison between hand-assisted laparoscopic and open surgical nephroureterectomy for urothelial carcinoma. *Urology* 2001; 57:133.
31. McGinnis DE, Trabulsi EJ, Gomella LG, Strup SE. Hand-assisted laparoscopic nephroureterectomy: description of technique. *Tech Urol* 2001; 7:7.
32. Li C-C, Chou Y-H, Shen J-T, et al. Comparison of hand-assisted laparoscopic nephroureterectomy with open surgery for upper urinary tract tumor. *Kaohsiung J Med Sci* 2001; 17:615.
33. Chueh S-C, Chen J, Hsu W-T, Hsieh M-H, Lai M-K. Hand assisted laparoscopic bilateral nephroureterectomy in 1 session without repositioning patients is facilitated by alternating inflation cuffs. *J Urol* 2002; 167:44.
34. Landman J, Lev R, Bhayani S, et al. Comparison of hand assisted and standard laparoscopic radical nephroureterectomy for the management of localized transitional cell carcinoma. *J Urol* 2002; 167:2387.
35. Wong C, Leveillee RJ. Hand-assisted laparoscopic nephroureterectomy with cystoscopic en bloc excision of the distal ureter and bladder cuff. *J Endourol* 2002; 16:329.
36. Uozumi J, Fujiyama C, KMeiri H, et al. Hand-assisted retroperitoneoscopic nephroureterectomy for upper urinary-tract urothelial tumors. *J Endourol* 2002; 16:743.
37. Munver R, Del Pizzo JJ, Sosa RE. Hand-assisted laparoscopic nephroureterectomy for upper urinary-tract transitional-cell carcinoma. *J Endourol* 2004; 18:351.
38. Kawauchi A, Fujito A, Soh J, Ukimura O, Mizutani Y, Miki T. Hand-assisted retroperitoneoscopic radical nephrectomy and nephroureterectomy. *J Endourol* 2004; 18:365.
39. Wolf JS Jr, Marcovich R, Merion RM, Konnak JW. Prospective, case-matched comparison of hand-assisted laparoscopic and open surgical live donor nephrectomy. *J Urol* 2000; 163:1650.
40. Kercher K, Dahl D, Harland R, Blute R, Gallagher K, Litwin D. Hand-assisted laparoscopic donor nephrectomy minimizes warm ischemia. *Urology* 2001; 58:152.
41. Buell JF, Alverdy J, Newell K, et al. Hand-assisted laparoscopic live-donor nephrectomy. *J Am Coll Surg* 2001; 192:132.
42. Wolf JS Jr, Merion RM, Leichtman AB, et al. Randomized controlled trial of hand-assisted laparoscopic versus open surgical live donor nephrectomy. *Transplantation* 2001; 72:284.
43. Stifelman MD, Hull D, Sosa RE, et al. Hand assisted laparoscopic donor nephrectomy: a comparison with the open approach. *J Urol* 2001; 166:444.
44. Ruiz-Deya G, Cheng S, Palmer E, Thomas R, Slakey D. Open donor, laparoscopic donor and hand assisted laparoscopic donor nephrectomy: a comparison of outcomes. *J Urol* 2001; 166:1270.
45. Velidedeoglu E, Williams N, Brayman KL, et al. Comparison of open, laparoscopic, and hand-assisted approaches to live-donor nephrectomy. *Transplantation* 2002; 174:169.
46. Lindstrom P, Haggman M, Wadstrom J. Hand-assisted laparoscopic surgery (HALS) for live donor nephrectomy is more time- and cost-effective than standard laparoscopic nephrectomy. *Surg Endosc* 2002; 16:422.
47. Gershbein AB, Fuchs GJ. Hand-assisted and conventional laparoscopic live donor nephrectomy: a comparison of two contemporary techniques. *J Endourol* 2002; 16:509.
48. Wadstrom J, Lindstrom P. Hand-assisted retroperitoneoscopic living-donor nephrectomy: initial 10 cases. *Transplantation* 2002; 73:1839.
49. Buell JF, Hanaway MJ, Potter SR, et al. Hand-assisted laparoscopic living-donor nephrectomy as an alternative to traditional laparoscopic living-donor nephrectomy. *Am J Transplant* 2002; 2:983.
50. Mateo RB, Sher L, Jabbour N, et al. Comparison of outcomes in noncomplicated and in higher-risk donors after standard versus hand-assisted laparoscopic nephrectomy. *Am Surg* 2003; 69:771.
51. Maartense S, Idu M, Bemelman FJ, Balm S, Surachno S, Bemelman WA. Hand-assisted laparoscopic live donor nephrectomy. *Br J Surg* 2004; 91:344.
52. Oda J, Landman J, Bhayani S, Figenshau RS. Concomitant laparoscopic hand-assisted radical nephrectomy and open radical prostatectomy using a single lower midline incision. *Urology* 2000; 56:1056vi.
53. Landman J, Figenshau RS, Bhayani S, et al. Dual-organ ablative surgery using a hand-assisted laparoscopic technique. A report of four cases. *J Urol* 2002; 16:215.
54. Peterson AC, Lance RS, Ahuja SK. Laparoscopic hand assisted radical cystectomy with ileal conduit urinary diversion. *J Urol* 2002; 168:2103.
55. McGinnis DE, Hubosky SG, Bergmann LS. Hand-assisted laparoscopic cytoprostatectomy and urinary diversion. *J Endourol* 2004; 18:383.
56. Hedican SP, Wolf JS Jr, Moon TD, Rayhill SC, Seifman BD, Nakada SY. Complications of hand-assisted laparoscopy in urologic surgery [abstract 91]. *J Urol* 2002; 167(suppl):22.
57. Hedican SP. Complications of hand-assisted laparoscopic urologic surgery. *J Endourol* 2004; 18:387.
58. Hedican SP, Moon TD, Lowry PS, Nakada SY. Hand-assisted laparoscopic renal surgery in the morbidly and profoundly obese. *J Endourol* 2004; 18:241.
59. Mendoza D, Newman RC, Albala D, et al. Laparoscopic complications in markedly obese urologic patients (a multi-institutional review). *Urology* 1996; 48:562.
60. Fugita OE, Chan DY, Roberts WW, Kavoussi LR, Jarrett TW. Laparoscopic radical nephrectomy in obese patients: outcomes and technical considerations. *Urology* 2004; 63:247.
61. Wolf JS Jr, Marcovich R, Gill IS, et al. Survey of neuromuscular injuries to the patient and surgeon during urologic laparoscopic surgery. *Urology* 2000; 55:831.
62. Johnston WK III, Hollenbeck BK, Wolf JS Jr. Comparison of neuromuscular injuries to the surgeon during hand-assisted versus standard laparoscopic urologic surgery. *J Urol* 2004; 171(suppl):396.
63. Kercher KW, Joels CS, Matthews BD, Lincourt AE, Smith TL, Heniford BT. Hand-assisted surgery improves outcomes for laparoscopic nephrectomy. *Am Surg* 2003; 69:1061.

64. Okeke AA, Timoney AG, Keeley FX. Hand-assisted laparoscopic nephrectomy: complications related to the hand-port site. *BJU Int* 2002; 90:364.
65. Gill IS, Matin SF, Desai MM, et al. Comparative analysis of laparoscopic versus open partial nephrectomy for renal tumors in 200 patients. *J Urol* 2003; 170:64.
66. Kim FJ, Rha KH, Hernandez F, Jarrett TW, Pinto PA, Kavoussi LR. Laparoscopic radical versus partial nephrectomy: assessment of complications. *J Urol* 2003; 170:408.
67. El-Galley R, Hood N, Young CJ, Deierhoi M, Urban DA. Donor nephrectomy: a comparison of techniques and results of open, hand assisted and full laparoscopic nephrectomy. *J Urol* 2004; 171:40.
68. Gill IS, Kavoussi LR, Clayman RV, et al. Complications of laparoscopic nephrectomy in 185 patients: a multi-institutional review. *J Urol* 1995; 154:479.
69. Ponsky LE, Cherullo EE, Banks KLW, et al. Laparoscopic radical nephrectomy: incorporating the advantages of hand assisted and standard laparoscopy. *J Urol* 2003; 169:2053.
70. Gaston KE, Moore DT, Pruthi RS. Hand-assisted laparoscopic nephrectomy: prospective evaluation of the learning curve. *J Urol* 2004; 171:63.
71. Hollenbeck BK, Seifman BD, Wolf JS Jr. Clinical skills acquisition for hand-assisted laparoscopic donor nephrectomy. *J Urology* 2004; 171:35.
72. Wolf JS Jr. Selection of patients for hand-assisted laparoscopic surgery. *J Endourol* 2004; 18:327.

Kazuo Suzuki

Department of Urology, Shintoshin Clinic, Iwata, Shizuoka, Japan

- INTRODUCTION
- HISTORY
 - Cholecystectomy and Gastrointestinal Surgery
 - Neck Surgery
 - Gynecology
 - Urology
- EQUIPMENT AND TECHNIQUE
- GASLESS VS. PNEUMOPERITONEUM
 - Basic Research
 - Clinical Studies
- SUMMARY
- REFERENCES

Gasless laparoscopic surgery means performance of operative procedures under video monitoring or direct vision in the abdominal cavity by lifting the abdominal wall.

In 1991, Nagai et al. first performed gasless laparoscopic cholecystectomy by the subcutaneous wire lifting method, a technique for lifting the abdominal wall by using both ends of a Kirschner wire that was inserted subcutaneously.

When combined with minilaparotomy, gasless laparoscopic surgery allows surgeons to perform an operation via a small incision under direct vision and still insert a hand easily.

INTRODUCTION

Gasless laparoscopic surgery means performance of operative procedures under video monitoring or direct vision in the abdominal cavity by lifting the abdominal wall.

Gasless laparoscopy is different from minilaparotomy, in which all procedures are performed with ordinary surgical instruments under direct vision by illumination of the operating field with headlights through a small skin incision.

HISTORY

Cholecystectomy and Gastrointestinal Surgery

In 1991, Gazayerli introduced laparoscopic surgery by the peritoneal planar lifting method with a simple T-shaped retractor for herniorrhaphy and cholecystectomy (1). Strictly speaking, it was not pure gasless surgery because the abdominal wall was lifted as an adjunct to carbon dioxide pneumoperitoneum.

In 1991, Nagai et al. first performed gasless laparoscopic cholecystectomy by the subcutaneous wire lifting method, a technique for lifting the abdominal wall by using both ends of a Kirschner wire that was inserted subcutaneously (2).

Abdominal wall lifting methods that employed various wires were subsequently developed in Japan (3,4). In the United States, laparoscopic surgery by the peritoneal planar lifting method (LaparoliftTM^a) was performed from around 1993 (5–7). In 1999, Sampietro developed a unique method for lifting the whole abdominal wall and used it to perform gasless laparoscopic surgery in Italy (8).

Subsequently, carbon dioxide pneumoperitoneum has become the mainstream mode of laparoscopic surgery because of its technical simplicity and ability to provide a wide operating space. Previously, gasless laparoscopic surgery was routinely used in restricted hospitals and was used for patients with serious cardiopulmonary complications at most medical institutions. However, hand-assisted laparoscopic surgery has recently been used for technically demanding procedures such as distal gastrectomy and colorectal surgery.

When combined with minilaparotomy, gasless laparoscopic surgery allows surgeons to perform an operation via a small incision under direct vision and still insert a hand easily.

Recent studies have demonstrated the utility of minilaparotomy or hand-assisted gasless laparoscopic surgery for distal gastrectomy with D2 lymph node dissection (9,10), as well as gasless laparoscopic surgery combined with minilaparotomy or transanal excision for colorectal cancer (11–15).

^aOrigin Medsystems, Inc., San Francisco, CA, currently unavailable.

The clinical practice guidelines on pneumoperitoneum for laparoscopic surgery released by the European Association for Endoscopic Surgery also recommend that abdominal wall lifting should be combined with low-pressure pneumoperitoneum in patients who have cardiopulmonary dysfunction.

Etwaru et al. reported pelvic lymph node dissection by the peritoneal planar lifting method using the Laparolift® in 1994.

In the author's experience, gasless laparoscopic surgery combined with the small skin incision was advantageous because there was no need for carbon dioxide pneumoperitoneum, the renal arteries and veins could be safely dissected under direct vision, and the patient could be immediately switched to open surgery if serious complications occurred such as massive bleeding.

It has also been reported that low-pressure laparoscopic surgery with abdominal wall lifting is useful for patients with cardiopulmonary dysfunction, advanced obesity, and pregnant women (16–19). Alijani and Cuschieri reported that such surgery was useful for high-risk patients because the addition of abdominal wall lifting gave surgeons a sufficient operating space at a pneumoperitoneum pressure as low as 3 to 4 mmHg and minimized the adverse effects of carbon dioxide pneumoperitoneum (17).

The clinical practice guidelines on pneumoperitoneum for laparoscopic surgery released by the European Association for Endoscopic Surgery also recommend that abdominal wall lifting should be combined with low-pressure pneumoperitoneum in patients who have cardiopulmonary dysfunction (20).

Neck Surgery

Laparoscopic surgery for thyroid and parathyroid diseases involves subcutaneous insufflation of carbon dioxide gas, which causes a problem with gas absorption. Shimizu et al. developed video-assisted thyroid lobectomy with subcutaneous wire lifting in 1998 (21). Subsequently, gasless video-assisted neck surgery has become popular for thyroid adenoma, thyroid cancer, and parathyroid adenoma because it is a less invasive, aesthetically excellent technique without the adverse effects of carbon dioxide (22–24).

Gynecology

Since about 1994, gasless laparoscopic surgery has been applied in the field of gynecology to treat ovarian tumors and uterine myoma (25,26). Gasless laparoscopic methods have also been used for gynecologic surgery via a transvaginal approach because the abdominal wall lifting extends the surgical field and it is therefore unnecessary to care about the leakage of carbon dioxide (27,28).

Urology

Etwaru et al. reported pelvic lymph node dissection by the peritoneal planar lifting method using the Laparolift®^b in 1994 (29).

Hirsch et al. performed gasless laparoscopic surgery for renal biopsy, varicocele, and pelvic lymph node dissection, reporting that it was useful for renal biopsy and varicocele via the retroperitoneal approach, but was not appropriate for pelvic lymph node dissection because of poor field of view (30). After reviewing additional patients, they reported that gasless laparoscopic surgery only provided a limited field of view, and that new abdominal wall lifting devices were needed (31).

In 1994, Suzuki et al. proposed gasless laparoscopy-assisted radical nephrectomy, in which a small skin incision was first created to remove the renal cancer en bloc and then a planar lifting retractor was inserted through the incision to lift the abdominal wall (32,33).

In the author's experience, gasless laparoscopic surgery combined with the small skin incision was advantageous because there was no need for carbon dioxide pneumoperitoneum, the renal arteries and veins could be safely dissected under direct vision, and the patient could be immediately switched to open surgery if serious complications occurred such as massive bleeding.

The concept of gasless laparoscopy-assisted radical nephrectomy was subsequently extended to gasless laparoscopy-assisted live donor nephrectomy.

Gasless laparoscopic surgery has also been used for Burch bladder neck suspension. Flax performed gasless extraperitoneal laparoscopic Burch bladder neck suspension in 47 patients with Type 2 stress incontinence, and reported that it was necessary to switch to open surgery in three patients (6%), but that previous multiple operations and obesity were not contraindications to the technique (34).

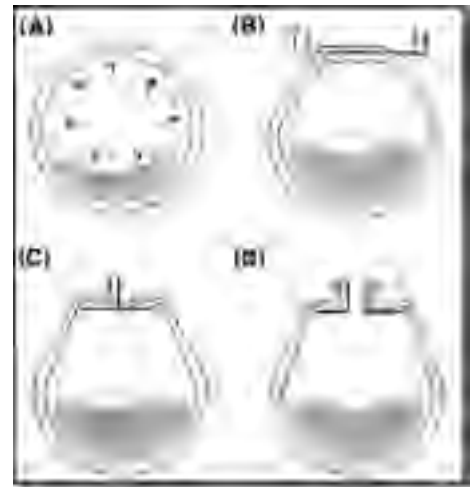
In addition, some Japanese reports have been published on gasless laparoscopic adrenalectomy and partial nephrectomy (35–38).

Live Donor Nephrectomy

Gasless laparoscopic surgery has also been applied to live donor nephrectomy to avoid the effect of carbon dioxide pneumoperitoneum on the kidneys. Yang et al. reported on the performance of minilaparotomy-assisted laparoscopic nephrectomy via the retroperitoneal approach, although they did not state any details of the technique, such as blood loss (39,40). Subsequently, they performed laparoscopy-assisted live donor nephrectomy

^bOrigin Medsystems, Inc., San Francisco, CA.

FIGURE 1 ■ Extension of the working space by carbon dioxide pneumoperitoneum and various lifting techniques. (A) Carbon dioxide pneumoperitoneum. (B) Subcutaneous wire lifting. (C) Peritoneal planar lifting. (D) Peritoneal planar lifting with minilaparotomy.



in 103 patients with improved retractors and techniques, and reported satisfactory results, with a mean operating time of 130 minutes and blood loss of 100 mL (41).

Suzuki et al. also reported on retroperitoneal laparoscopy-assisted live donor nephrectomy using the abdominal wall lifting method in 1997 (42). Subsequently, they introduced various improvements to reduce the operating time, and concluded that gasless retroperitoneoscopy-assisted live donor nephrectomy was an effective procedure (43).

Advantages of Gasless Retroperitoneoscopic Live Donor Nephrectomy

- It does not have any adverse effects on cardiopulmonary function and renal blood flow because there is no carbon dioxide pneumoperitoneum.
- The extraperitoneal approach may be employed.
- Surgeons can safely dissect the renal vessels under direct vision.
- The patient can be quickly switched to open surgery by extending the small incision.

Disadvantages of Gasless Retroperitoneoscopic Live Donor Nephrectomy

- A relatively limited visualization of the operative field.
- The lifting device may interfere with the use of forceps.
- Strong traction on the small incision may increase postoperative wound pain (44).

EQUIPMENT AND TECHNIQUE

Gasless laparoscopy creates a working space in the abdominal cavity by lifting the abdominal wall instead of using carbon dioxide. To lift the abdominal wall, the following three methods are available; subcutaneous wire lifting in which a thin steel wire is passed subcutaneously to lift the abdominal wall; peritoneal planar lifting in which by a retractor is inserted into the abdominal cavity to lift the whole abdominal wall; and abdominal wall lifting in which the abdominal wall is lifted by a retractor inserted through a small skin incision (Fig. 1A–D).

Further, gasless laparoscopic surgery can be performed by the following techniques: a pure laparoscopic procedure in which several ports are placed after the abdominal wall is lifted and all surgical procedures are done under video monitoring; gasless laparoscopic minilaparotomy in which abdominal wall lifting is combined with a small skin incision to allow surgery under direct vision; hand-assisted surgery in which one hand of the surgeon is inserted through a small skin incision; and a combination of minilaparotomy and hand-assisted surgery.

Lifting devices for subcutaneous wire lifting that were developed by Nagai et al. and Hashimoto et al. are commercially available in Japan^c (Fig. 2A and B). The abdominal wall is lifted with a subcutaneous steel wire to create a working space in the peritoneal cavity. Because the space created is relatively small, this method requires some skill when it is used in obese patients or for technically difficult operations.

^cMizuho Medical Co., Ltd., <http://www.pnet.mizuho.co.jp>; Takasago Medical Industry Co., Ltd., <http://www.takasagoika.co.jp>.

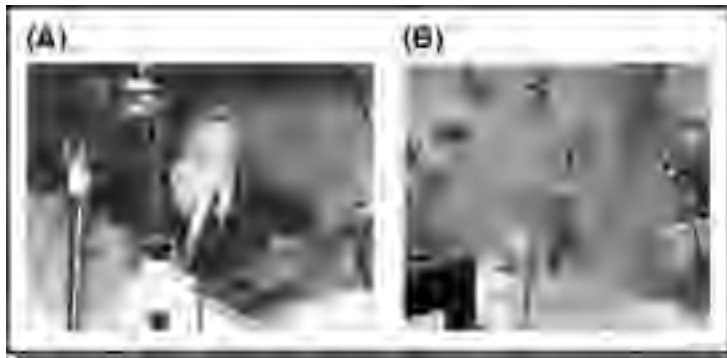


FIGURE 2 ■ (A) Subcutaneous wire lifting methods was developed by Nagai et al. (2). (B) Subcutaneous wire lifting methods was developed by Hashimoto et al. (4).



FIGURE 3 ■ Peritoneal planar lifting device: VarioLift.

However, technically easier operations such as cholecystectomy can be performed as a pure laparoscopic procedure without minilaparotomy.

A device for lifting the whole abdominal wall (Laparofan, Laparolift) was used in Western countries since around 1993, but is no longer being manufactured. The currently available device for peritoneal planar lifting is known as the VarioLift^{TMd} (Fig. 3).

Peritoneal planar lifting provides a slightly larger working space than the subcutaneous wire method because it raises the whole abdominal wall. However, a Japanese multicenter clinical study compared the peritoneal planar lifting with subcutaneous wire lifting and found that C-reactive protein was significantly increased in the peritoneal planar group postoperatively. This indicates that the peritoneal planar lifting may have a stronger effect on the peritoneum and abdominal wall muscles (45).

Yang et al. developed a mechanical retractor for video-assisted minilaparotomy live donor nephrectomy^e (Fig. 4). This device requires the insertion of several retractors into the retroperitoneum and a working space created by pulling on the retractors. This technique is generally used under direct vision in live donor nephrectomy. Suzuki et al. have performed hand-assisted, live donor nephrectomy by lifting the abdominal wall with retractors inserted into the retroperitoneum^f to allow insertion of the



FIGURE 4 ■ Minilaparotomy and planar lifting devices developed by Yang et al.

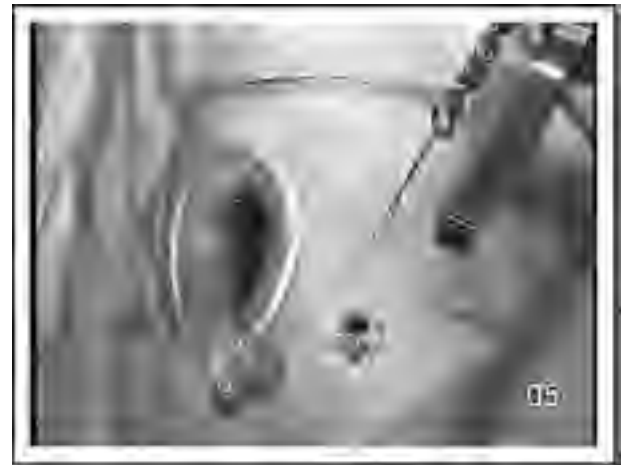

FIGURE 5 ■ Minilaparotomy and hand-assisted technique developed by Suzuki et al.

^dAESCLAP Inc.; Center Valley, PA.

^eThompson Surgical Instruments, Inc. Traverse City, MI.

^fMinilaparotomy Retractor; Mizuho Medical Co., Ltd. <http://www.pnet.mizuho.co.jp>.

surgeon's hand (Fig. 5). The kidney and ureter are dissected with a hand-assisted technique under video monitoring, while the renal pedicle is managed under direct vision for safety.

GASLESS VS. PNEUMOPERITONEUM

Basic Research

Many basic studies have compared gasless laparoscopic surgery and laparoscopic surgery using pneumoperitoneum in terms of invasiveness and effects on the patient.

Gasless surgery without carbon dioxide pneumoperitoneum is not associated with compression of the inferior vena cava and intestinal vessels, elevation of the diaphragm, and absorption of carbon dioxide gas into the blood. Therefore, the gasless laparoscopic surgery is superior with regard to the effects on hemodynamics and respiratory function (46–48).

The results with respect to several points other than cardiopulmonary effects are described here.

Tumor Seeding, Abdominal Wall and Port Metastases

In 1996, Bouvy et al. reported striking experimental results on tumor seeding and abdominal wall metastases in the *Annals of Surgery* (49). Using rats divided into three experimental groups (carbon dioxide pneumoperitoneum, gasless laparoscopy, and conventional laparotomy groups), they obtained the following results: (i) direct contact between a solid tumor and the port led to an increase of local tumor seeding, (ii) laparoscopy is associated with less intraperitoneal tumor seeding than laparotomy, and (iii) insufflation of carbon dioxide promotes peritoneal tumor seeding and is associated with more abdominal wall metastases than gasless laparoscopy. In response to their results, many other authors have reported data on the relationship between carbon dioxide pneumoperitoneum and tumor cell growth or port metastasis.

It has often been reported that the spread of tumor cells in the abdominal cavity and port metastasis is not due to carbon dioxide gas per se, but arises from widespread tumor cell dissemination and implantation caused by the aspiration or insufflation of gas into the abdominal cavity (50–56). However, port site metastases are considered to result from direct contact between the tumor and port when removing the lesion because these metastases have also been frequently reported after thoracoscopic surgery without carbon dioxide gas insufflation (57,58). In any case, it seems true that insufflating gas at a high pressure and desufflating it increases the risk of tumor cell dissemination to the peritoneum and intraabdominal organs.

Bouvy et al. also reported that carbon dioxide pneumoperitoneum stimulates tumor growth (49). Many subsequent studies have investigated the mechanism of tumor growth associated with pneumoperitoneum. Previously, it was considered that carbon dioxide pneumoperitoneum itself might play a role as a carbon dioxide incubator.

Tumor growth may be attributable not to carbon dioxide gas, but to reduced blood flow in the peritoneum, liver, and renal cortex secondary to high-pressure pneumoperitoneum (59–64).

Immune Response

Several studies have compared immune response between pneumoperitoneum and gasless laparoscopic surgery. Animal experiments have shown the following results: (i) carbon dioxide pneumoperitoneum reduces the activity of T lymphocytes (65); (ii) it reduces the intraperitoneal pH, which decreases macrophage activity and lowers the production of interferon- α (66); and (iii) it reduces splenic and hepatic natural killer cell activity (67). However, clinical data remain controversial: one study showed that carbon dioxide pneumoperitoneum reduced immunocompetence compared with gasless laparoscopic surgery (68), while another found no difference in immunocompetence between the two techniques (69). Buunen et al. (70) reviewed the effect of carbon dioxide pneumoperitoneum on immunocompetence and stated that local (i.e., peritoneal) immune function was affected, but the production of tumor necrosis factor and the phagocytotic capacity of peritoneal macrophages were less impaired. In addition, the systemic stress response, as determined from the delayed-type hypersensitivity response and leukocyte antigen expression by lymphocytes, is preserved after laparoscopic surgery, but is weaker than after conventional surgery. The authors concluded

Gasless surgery without carbon dioxide pneumoperitoneum is not associated with compression of the inferior vena cava and intestinal vessels, elevation of the diaphragm, and absorption of carbon dioxide gas into the blood. Therefore, the gasless laparoscopic surgery is superior with regard to the effects on hemodynamics and respiratory function.

Tumor growth may be attributable not to carbon dioxide gas, but to reduced blood flow in the peritoneum, liver, and renal cortex secondary to high-pressure pneumoperitoneum.

that intraperitoneal carbon dioxide insufflation attenuates peritoneal immunity, but laparoscopic surgery is associated with less systemic stress than open surgery.

Renal Function

In 1996, Chiu et al. reported that carbon dioxide pneumoperitoneum reduced the urine output and induced electrolyte abnormalities (71). Subsequent investigations showed that the urine output was reduced because pneumoperitoneum compressed the kidneys, thereby reducing blood flow in the renal cortex (72,73).

Reduction of pneumoperitoneum pressure, should be applied in patients with renal dysfunction or those receiving treatment with angiotensin II receptor 1 blockers or angiotensin converting enzyme inhibitors (74,75).

The effect on renal function of live donor nephrectomy with carbon dioxide pneumoperitoneum has been often reported as well. From the results of animal studies, Hazebroek et al. reported that pneumoperitoneum caused transient renal dysfunction, but had little effect on the kidney after transplantation (76–78). Abreu et al. reviewed 100 consecutive cases of laparoscopic live donor nephrectomy and concluded that carbon dioxide pneumoperitoneum had no effect on post-transplant kidney function (79).

Miscellaneous Effects

Other studies have revealed the following results: gasless laparoscopic surgery had less effect on respiratory function and causes fewer postoperative adhesions because of lower peritoneal oxidative stress than carbon dioxide pneumoperitoneum (80,81); gasless laparoscopic surgery does not stimulate bacterial growth (82); and gasless laparoscopic surgery is more appropriate for patients with head injury because it does not increase intracranial pressure (83,84).

Clinical Studies

Since 1996, a number of randomized controlled trials have been performed to compare abdominal wall lifting with carbon dioxide pneumoperitoneum. Gasless laparoscopic surgery had less effect on cardiopulmonary function than pneumoperitoneum.

Major studies on laparoscopic cholecystectomy are listed in Table 1 (45,85–90). Most investigators have reported that gasless laparoscopic surgery provides a small working space and is more technically difficult and time consuming. However, some investigators have found that the difference in operating time compared with pneumoperitoneum becomes negligible as surgeons increase their familiarity with the technique.

Several studies have revealed that gasless laparoscopic surgery is comparable to or better than pneumoperitoneum with respect to postoperative recovery. Some randomized trials have indicated that gasless laparoscopic surgery has less effect on neuroendocrine or hepatic function (91,92).

The randomized controlled trials performed in obstetrics and gynecology patients provided slightly different results from those on cholecystectomy patients (93–97). Many authors have concluded that gasless laparoscopic surgery was most appropriate for patients with serious cardiopulmonary dysfunction because it had little effect on cardiopulmonary function, but that it would be necessary to improve the lifting devices before gasless surgery became popular because it only provided a small working space, was more technically difficult, and often had to be switched to carbon dioxide pneumoperitoneum.

TABLE 1 ■ Comparison of Gasless Laparoscopic Cholecystectomy with Pneumoperitoneum

Author	No. of pts.	Adverse effects (cardiopulmonary)	Surgical procedure	Operative time	Convalescence
Nagai H (85) ^a	144	–	–	Same	Same
Koivusalo AM	26	Low	–	–	Fast
Vezakis (86) ^b	36	Same	Difficult	Long	Same
Larsen JF (87)	50	Low	Difficult	Same	Same
Ortiz-Oshiro E (88)	34	–	Same	Same	–
Uen YH (89)	95	Low	Difficult	Long	Fast
Alijani (90)	40	Low	Difficult	–	Fast

^aA prospective nonrandomized multicenter study in Japan.
^bGasless versus low pressure pneumoperitoneum.

Reduction of pneumoperitoneum pressure, should be applied in patients with renal dysfunction or those receiving treatment with angiotensin II receptor 1 blockers or angiotensin converting enzyme inhibitors.

Gasless laparoscopic surgery had less effect on cardiopulmonary function than pneumoperitoneum.

Several studies have revealed that gasless laparoscopic surgery is comparable to or better than pneumoperitoneum with respect to postoperative recovery. Some randomized trials have indicated that gasless laparoscopic surgery has less effect on neuroendocrine or hepatic function.

SUMMARY

- Deaths that are not directly associated with laparoscopic surgery, but are caused by carbon dioxide pneumoperitoneum (gas embolism or splanchnic vessel thrombosis) have been reported (98–100).
- Sternberg et al. stated that gasless or low-pressure laparoscopic surgery should be considered for patients with preoperative impairment of splanchnic blood flow and/or a hypercoagulable state (98). Gasless laparoscopic surgery is valuable as a less invasive technique for patients with serious cardiopulmonary dysfunction.
- We have performed laparoscopic surgery in about 720 patients at our institution. Gasless minilaparotomy (three radical nephrectomies and one adrenalectomy) was necessary in four patients with serious cardiopulmonary dysfunction contraindicating.
- Gasless laparoscopic surgery has the major merit of little influence on cardiopulmonary function, but has the demerit that it only provides a small working space, particularly when the access site is blocked by the intestines or not.
- Gasless laparoscopic surgery is considered to be more appropriate for surgery at sites that are not severely obstructed by the intestines, such as cholecystectomy, partial hepatectomy, oophorectomy, and adrenalectomy.
- Gasless laparoscopy-assisted minilaparotomy may be useful for technically demanding operations on malignant tumors. Surgeons who aim to be an expert at laparoscopic surgery should master various techniques and approaches, and then select the most appropriate method for each tumor and patient. Abdominal wall lifting may be an option for laparoscopic surgery.

REFERENCES

1. Gazayerli MM. The Gazayerli endoscopic retractor model 1. *Surg Laparosc Endosc* 1991; 1:98–100.
2. Nagai H, Inaba T, Kamiya, et al. A new method of laparoscopic cholecystectomy: an abdominal wall lifting technique without pneumoperitoneum [abstr]. *Surg Laparosc Endosc* 1991; 1:126.
3. Kitano S, Tomikawa M, Iso Y, et al. A safe and simple method to maintain a clear field of vision during laparoscopic cholecystectomy. *Surg Endosc* 1992; 6:197–198.
4. Hashimoto D, Nayeem SA, Kajiwara S, Hoshino T. Laparoscopic cholecystectomy: an approach without pneumoperitoneum. *Surg Endosc* 1993; 7:54–56.
5. Smith RS, Fry WR, Tsoi EK, et al. Gasless laparoscopy and conventional instruments. The next phase of minimally invasive surgery. *Arch Surg* 1993; 128:1102–1107.
6. Newman L III, Luke JP, Ruben DM, Eubanks S. Laparoscopic herniorrhaphy without pneumoperitoneum. *Surg Laparosc Endosc* 1993; 3:213–215.
7. Brams DM, Cardoza M, Smith RS. Laparoscopic repair of traumatic gastric perforation using a gasless technique. *J Laparoendosc Surg* 1993; 3:587–591.
8. Sampietro R. Correct use of the gasless LaparoTenser system. *Surg Endosc* 1999; 13:316.
9. Ohki J, Nagai H, Hyodo M, Nagashima T. Hand-assisted laparoscopic distal gastrectomy with abdominal wall-lift method. *Surg Endosc* 1999; 13:1148–1150.
10. Hyodo M, Hosoya Y, Yokoyama T, et al. Gasless laparoscopy-assisted distal gastrectomy for early cancer via mini-laparotomy using an abdominal wall lift. *Hepatogastroenterology* 2003; 50:2279–2281.
11. Miura Y, Mitsuta H, Yoshihara T, et al. Gasless hand-assisted laparoscopic surgery for colorectal cancer: an option for poor cardiopulmonary reserve. *Dis Colon Rectum* 2001; 44:896–898.
12. Kawamura YJ, Sawada T, Sunami E, et al. Gasless laparoscopically assisted colonic surgery. *Am J Surg* 1999; 177:515–517.
13. Jiang JK, Chen WS, Yang SH, et al. Gasless laparoscopy-assisted colorectal surgery. *Surg Endosc* 2001; 15:1093–1097.
14. Nakagoe T, Ishikawa H, Sawai T, et al. Gasless, video endoscopic transanal excision for carcinoid and laterally spreading tumors of the rectum. *Surg Endosc* 2003; 17:1298–1304.
15. Araki Y, Isomoto H, Shirouzu K. Video-assisted gasless transanal endoscopic microsurgery: a review of 217 cases of rectal tumors over the past 10 years. *Dig Surg* 2003; 20:48–52.
16. Banting S, Shimi S, Vander Velpen G, et al. Abdominal wall lift. Low-pressure pneumoperitoneum laparoscopic surgery. *Surg Endosc* 1993; 7:57–59.
17. Alijani A, Cuschieri A. Abdominal wall lift systems in laparoscopic surgery: gasless and low-pressure systems. *Semin Laparosc Surg* 2001; 8:53–62.
18. Stany MP, Winter WE III, Dainty L, et al. Laparoscopic exposure in obese high-risk patients with mechanical displacement of the abdominal wall. *Obstet Gynecol* 2004; 103:383–386.
19. Edelman DS. Alternative laparoscopic technique for cholecystectomy during pregnancy. *Surg Endosc* 1994; 8:794–796.
20. Neudecker J, Sauerland S, Neugebauer E, et al. The European Association for Endoscopic Surgery clinical practice guideline on the pneumoperitoneum for laparoscopic surgery. *Surg Endosc* 2002; 16:1121–1143.
21. Shimizu K, Akira S, Tanaka S. Video-assisted neck surgery: endoscopic resection of benign thyroid tumor aiming at scarless surgery on the neck. *J Surg Oncol* 1998; 69:178–180.

22. Bellantone R, Lombardi CP, Raffaelli M, et al. Minimally invasive, totally gasless video-assisted thyroid lobectomy. *Am J Surg* 1999; 177:342–343.
23. Kitano H, Fujimura M, Kinoshita T, et al. Endoscopic thyroid resection using cutaneous elevation in lieu of insufflation. *Surg Endosc* 2002; 16:88–91.
24. Shimizu K, Tanaka S. Asian perspective on endoscopic thyroidectomy—a review of 193 cases. *Asian J Surg* 2003; 26:92–100.
25. Hill D, Maher P, Wood C, Barnetson W. Gasless laparoscopy. *Aust NZ J Obstet Gynaecol* 1994; 34:79–80.
26. Chang FH, Soong YK, Cheng PJ, et al. Laparoscopic myomectomy of large symptomatic leiomyoma using airlift gasless laparoscopy: a preliminary report. *Hum Reprod* 1996; 11:1427–1432.
27. D'Ercole C, Cravello L, Guyon F, et al. Gasless laparoscopic gynecologic surgery. *Eur J Obstet Gynecol Reprod Biol* 1996; 66:137–139.
28. Imperato F, Basili R, Luele T. Laparoscopically assisted vaginal hysterectomy gasless. Retrospective study in patients with uterine fibroids. *Clin Ther* 2003; 154:163–165.
29. Etwaru D, Raboy A, Ferzli G, Albert P. Extraperitoneal endoscopic gasless pelvic lymph node dissection. *J Laparoendosc Surg* 1994; 4:113–116.
30. Hirsch IH, Moreno JG, Lotfi MA, Gomella LG. Noninsufflative laparoscopic access. *J Endourol* 1995; 9:483–486.
31. Hirsch IH, Abdel-Meguid TA, Gomella LG. Gasless laparoscopic varicocele ligation: experience with new instrumentation and technique for retroperitoneal and intraperitoneal approaches. *J Laparoendosc Adv Surg Tech A* 1997; 7:221–226.
32. Suzuki K, Ihara H, Kurita Y, et al. Laparoscopy-assisted radical nephrectomy without pneumoperitoneum. *Eur Urol* 1994; 25:237–241.
33. Suzuki K, Masuda H, Ushiyama T, et al. Gasless laparoscopy-assisted nephrectomy without tissue morcellation for renal carcinoma. *J Urol* 1995; 154:1685–1387.
34. Flax S. The gasless laparoscopic Burch bladder neck suspension: early experience. *J Urol* 1996; 156:1105–1107.
35. Moriya K, Sakakibara N, Hirakawa K, et al. Clinical study of gasless laparoscopic adrenalectomy in 17 cases — comparison between laparoscopic adrenalectomy with and without pneumoperitoneum. *Jpn J Urol* 1997; 88:1021–1027.
36. Nishio S, Takeda H, Yokoyama M. Changes in urinary output during laparoscopic adrenalectomy. *BJU Int* 1999; 83:944–947.
37. Kageyama S, Suzuki K, Un-No T, et al. Gasless laparoscopy-assisted partial nephrectomy for a complicated cystic lesion: case report. *J Endourol* 1997; 11:41–44.
38. Sakakibara N, Shinojima H, Matugase Y, et al. Gasless retroperitoneoscopic partial nephrectomy for a case with renal cell carcinoma. *Int J Urol* 2000; 7:112–114.
39. Yang SC, Lee DH, Rha KH, et al. Retroperitoneoscopic living donor nephrectomy: two cases. *Transplant Proc* 1994; 26:2409.
40. Yang SC, Park DS, Lee DH, et al. Retroperitoneal endoscopic live donor nephrectomy: report of 3 cases. *J Urol* 1995; 153:1884–1886.
41. Yang SC, Ko WJ, Byun YJ, et al. Retroperitoneoscopy assisted live donor nephrectomy: the Yonsei experience. *J Urol* 2001; 165:1099–102.
42. Suzuki K, Ushiyama T, Ishikawa, et al. Retroperitoneoscopy assisted live donor nephrectomy: the initial 2 cases. *J Urol* 1997; 158:1353–1356.
43. Suzuki K, Ishikawa A, Ushiyama T, et al. Retroperitoneoscopic live donor nephrectomy without gas insufflation: the five-year Hamamatsu University experience. *Transplant Proc* 2002; 34:720–721.
44. Suzuki K. Hand-assisted endoscopic living donor nephrectomy. In: Higashihara E, eds. *Recent Advances in Endourology*. Vol. 5. New Challenge in Laparoscopic Urologic Surgery. Tokyo: Springer-Verlag, 2003:69–80.
45. The Japanese Association of Abdominal Wall Lifting for Laparoscopic Surgery. Comparison between CO₂ insufflation and abdominal wall lift in laparoscopic cholecystectomy. A prospective multiinstitutional study in Japan. *Surg Endosc* 1999; 13:705–709.
46. Woolley DS, Puglisi RN, Bilgrami S, et al. Comparison of the hemodynamic effects of gasless abdominal distention and CO₂ pneumoperitoneum during incremental positive end-expiratory pressure. *J Surg Res* 1995; 58:75–80.
47. McDermott JP, Regan MC, Page R, et al. Cardiorespiratory effects of laparoscopy with and without gas insufflation. *Arch Surg* 1995; 130:984–988.
48. Takagi S. Hepatic and portal vein blood flow during carbon dioxide pneumoperitoneum for laparoscopic hepatectomy. *Surg Endosc* 1998; 12:427–431.
49. Bouvy ND, Marquet RL, Jeekel H, et al. Impact of gas(less) laparoscopy and laparotomy on peritoneal tumor growth and abdominal wall metastases. *Ann Surg* 1996; 224:694–700.
50. Watson DI, Mathew G, Ellis T, et al. Gasless laparoscopy may reduce the risk of port-site metastases following laparoscopic tumor surgery. *Arch Surg* 1997; 132:166–168.
51. Mathew G, Watson DI, Ellis T, et al. The effect of laparoscopy on the movement of tumor cells and metastasis to surgical wounds. *Surg Endosc* 1997; 11:1163–1166.
52. Mathew G, Watson DI, Rofo AM, et al. Adverse impact of pneumoperitoneum on intraperitoneal implantation and growth of tumour cell suspension in an experimental model. *Aust NZ J Surg* 1997; 67:289–292.
53. Iwanaka T, Arya G, Ziegler MM. Mechanism and prevention of port-site tumor recurrence after laparoscopy in a murine model. *J Pediatr Surg* 1998; 33:457–461.
54. Cavina E, Goletti O, Molea N, et al. Trocar site tumor recurrences. May pneumoperitoneum be responsible? *Surg Endosc* 1998; 12:1294–1296.

55. Dorrance HR, Oien K, O'Dwyer PJ. Effects of laparoscopy on intraperitoneal tumor growth and distant metastases in an animal model. *Surgery* 1999; 126:35–40.
56. Moreira H Jr, Yamaguchi T, Wexner S, et al. Effect of pneumoperitoneal pressure on tumor dissemination and tumor recurrence at port-site and midline incisions. *Am Surg* 2001; 67:369–373.
57. Reymond MA, Schneider C, Kastl S, et al. The pathogenesis of port-site recurrences. *J Gastrointest Surg* 1998; 2:406–414.
58. Zayyan KS, Christie-Brown JS, Van Noorden S, et al. Rapid flow carbon dioxide laparoscopy disperses cancer cells into the peritoneal cavity but not the port sites in a new rat model. *Surg Endosc* 2003; 17:273–277.
59. Gutt CN, Kim ZG, Schmandra T, et al. Carbon dioxide pneumoperitoneum is associated with increased liver metastases in a rat model. *Surgery* 2000; 127:566–570.
60. Gutt CN, Kim ZG, Schemmer P, et al. Impact of laparoscopic and conventional surgery on Kupffer cells, tumor-associated CD44 expression, and intrahepatic tumor spread. *Arch Surg* 2002; 137:1408–1412.
61. Gutt CN, Gessmann T, Schemmer P, et al. The impact of carbon dioxide and helium insufflation on experimental liver metastases, macrophages, and cell adhesion molecules. *Surg Endosc* 2003; 17:1628–1631.
62. Bouvy ND, Giuffrida MC, Tseng LN, et al. Effects of carbon dioxide pneumoperitoneum, air pneumoperitoneum, and gasless laparoscopy on body weight and tumor growth. *Arch Surg* 1998; 133:652–656.
63. Leister I, Manegold S, Schuler P, et al. Effect of laparotomy and CO₂ pneumoperitoneum on tumor growth of human colon carcinoma and expression pattern of tumor-associated proteins in the SCID mouse. *Int J Colorectal Dis* 2003; 18:508–513.
64. Lundberg O, Kristoffersson A. Pneumoperitoneum impairs blood flow and augments tumor growth in the abdominal wall. *Surg Endosc* 2004; 18:293–296.
65. Gutt CN, Hollander D, Brier CH, et al. Influence of laparoscopy and laparotomy on systemic and peritoneal T lymphocytes in a rat model. *Int J Colorectal Dis* 2001; 16:216–220.
66. Neuhaus SJ, Watson DI, Ellis T, et al. Influence of gases on intraperitoneal immunity during laparoscopy in tumor-bearing rats. *World J Surg* 2000; 24:1227–1231.
67. Takeuchi I, Ishida H, Mori T, et al. Comparison of the effects of gasless procedure, CO₂-pneumoperitoneum, and laparotomy on splenic and hepatic natural killer activity in a rat model. *Surg Endosc* 2004; 18:255–260.
68. Sietses C, von Blomberg ME, Eijssbouts QA, et al. The influence of CO₂ versus helium insufflation on the abdominal wall lifting technique on the systemic immune response. *Surg Endosc* 2002; 16:525–528.
69. Kim WW, Jeon HM, Park SC, et al. Comparison of immune preservation between CO₂ pneumoperitoneum and gasless abdominal lift laparoscopy. *JSL* 2002; 6:11–15.
70. Buunen M, Gholghesaei M, Veldkamp R, et al. Stress response to laparoscopic surgery: a review. *Surg Endosc* 2004; 18:1022–1028.
71. Chiu AW, Chang LS, Birkett DH, et al. Changes in urinary output and electrolytes during gaseous and gasless laparoscopy. *Urol Res* 1996; 24:361–36.
72. Dunn MD, McDougall EM. Renal physiology. Laparoscopic considerations. *Urol Clin North Am* 2000; 27:609–614.
73. Lindberg F, Bergqvist D, Bjorck M, et al. Renal hemodynamics during carbon dioxide pneumoperitoneum: an experimental study in pigs. *Surg Endosc* 2003; 17:480–484.
74. de Cleva R, Silva FP, Zilberstein B, et al. Acute renal failure due to abdominal compartment syndrome: report on four cases and literature review. *Rev Hosp Clin Fac Med Sao Paulo* 2001; 56:123–130.
75. Lindstrom P, Wadstrom J, Ollerstam A, et al. Effects of increased intra-abdominal pressure and volume expansion on renal function in the rat. *Nephrol Dial Transplant* 2003; 18:2269–2277.
76. Hazebroek EJ, de Bruin RW, Bouvy ND, et al. Short-term impact of carbon dioxide, helium, and gasless laparoscopic donor nephrectomy on renal function and histomorphology in donor and recipient. *Surg Endosc* 2002; 16:245–251.
77. Hazebroek EJ, Gommers D, Schreve MA, et al. Impact of intraoperative donor management on short-term renal function after laparoscopic donor nephrectomy. *Ann Surg* 2002; 236:127–132.
78. Hazebroek EJ, de Bruin RW, Bouvy ND, et al. Long-term impact of pneumoperitoneum used for laparoscopic donor nephrectomy on renal function and histomorphology in donor and recipient rats. *Ann Surg* 2003; 237:351–357.
79. Abreu SC, Goldfarb DA, Derweesh I, et al. Factors related to delayed graft function after laparoscopic live donor nephrectomy. *J Urol* 2004; 171:52–57.
80. Pross M, Schulz HU, Flechsig A, et al. Oxidative stress in lung tissue induced by CO₂ pneumoperitoneum in the rat. *Surg Endosc* 2000; 14:1180–1184.
81. de Souza AM, Wang CC, Chu CY, et al. The effect of intra-abdominal pressure on the generation of 8-iso prostaglandin F₂alpha during laparoscopy in rabbits. *Hum Reprod* 2003; 18:2181–2188.
82. Sare M, Demirkiran AE, Alibey E, et al. Effect of abdominal insufflation on bacterial growth in experimental peritonitis. *J Laparoendosc Adv Surg Tech A* 2001; 11:285–289.
83. Moncure M, Salem R, Moncure K, et al. Central nervous system metabolic and physiologic effects of laparoscopy. *Am Surg* 1999; 65:168–172.
84. Rosin D, Brasesco O, Varela J, et al. w-pressure laparoscopy may ameliorate intracranial hypertension and renal hypoperfusion. *J Laparoendosc Adv Surg Tech A* 2002; 12:15–19.
85. Koivusalo AM, Kellokumpu I, Lindgren L. Gasless laparoscopic cholecystectomy: comparison of postoperative recovery with conventional technique. *Br J Anaesth* 1996; 77:576–580.
86. Vezakis A, Davides D, Gibson JS, et al. Randomized comparison between low-pressure laparoscopic cholecystectomy and gasless laparoscopic cholecystectomy. *Surg Endosc* 1999; 13:890–893.

87. Larsen JF, Ejstrup P, Kristensen JU, et al. Randomized comparison of conventional and gasless laparoscopic cholecystectomy: operative technique, postoperative course, and recovery. *J Gastrointest Surg* 2001; 5:330–335.
88. Ortiz-Oshiro E, Mayol J, Aparicio Medrano JC, et al. Gasless laparoscopic cholecystectomy is not more time-consuming. *Surg Endosc* 2001; 15:1448–1451.
89. Uen YH, Liang AI, Lee HH. Randomized comparison of conventional carbon dioxide insufflation and abdominal wall lifting for laparoscopic cholecystectomy. *J Laparoendosc Adv Surg Tech A* 2002; 12:7–14.
90. Alijani A, Hanna GB, Cuschieri A. Abdominal wall lift versus positive-pressure capnoperitoneum for laparoscopic cholecystectomy: randomized controlled trial. *Ann Surg* 2004; 239:388–394.
91. Koivusalo AM, Kellokumpu I, Scheinin M, et al. Randomized comparison of the neuroendocrine response to laparoscopic cholecystectomy using either conventional or abdominal wall lift techniques. *Br J Surg* 1996; 83:1532–1536.
92. Giraudo G, Brachet Contul R, Caccetta M, et al. Gasless laparoscopy could avoid alterations in hepatic function. *Surg Endosc* 2001; 15:741–746.
93. Johnson PL, Sibert KS. Laparoscopy. Gasless versus CO₂ pneumoperitoneum. *J Reprod Med* 1997; 42:255–259.
94. Goldberg JM, Maurer WG. A randomized comparison of gasless laparoscopy and CO₂ pneumoperitoneum. *Obstet Gynecol* 1997; 90:416–420.
95. Cravello L, D'Ercole C, Roger V, et al. Laparoscopic surgery in gynecology: randomized prospective study comparing pneumoperitoneum and abdominal wall suspension. *Eur J Obstet Gynecol Reprod Biol* 1999; 83:9–14.
96. Ogihara Y, Isshiki A, Kindscher JD, et al. Abdominal wall lift versus carbon dioxide insufflation for laparoscopic resection of ovarian tumors. *J Clin Anesth* 1999; 11:406–412.
97. Lukban JC, Jaeger J, Hammond KC, et al. Gasless versus conventional laparoscopy. *N J Med* 2000; 97:29–34.
98. Sternberg A, Alfici R, Bronek S, et al. Laparoscopic surgery and splanchnic vessel thrombosis. *J Laparoendosc Adv Surg Tech A* 1998; 8:65–68.
99. Cottin V, Delafosse B, Viale JP. Gas embolism during laparoscopy: a report of seven cases in patients with previous abdominal surgical history. *Surg Endosc* 1996; 10:166–169.
100. Popesco D, Le Miere E, Maitre B, et al. Coronary gas embolism after laparoscopic surgery. *Ann Fr Anesth Reanim* 1997; 16:381–385.

SECTION

VIII

LAPAROSCOPY: DEVELOPING TECHNIQUES

THORACOSCOPIC TRANSDIAPHRAGMATIC ADRENALECTOMY

Massimiliano Spaliviero and Anoop M. Meraney

Section of Laparoscopic and Robotic Surgery, Glickman Urological Institute, Cleveland Clinic Foundation, Cleveland, Ohio, U.S.A.

- INTRODUCTION
- CURRENT INDICATIONS AND CONTRAINDICATIONS OF LAPAROSCOPIC ADRENALECTOMY
- TRANSTHORACIC LAPAROSCOPY: EXPERIMENTAL AND CLINICAL DATA
 - Experimental Data
 - Clinical Data
- THORACOSCOPIC TRANSDIAPHRAGMATIC ADRENALECTOMY: PATIENT SELECTION
- SURGICAL TECHNIQUE
 - Patient Preparation and Positioning
 - Step 1: Laparoscopic Entry
 - Step 2: Placement of Secondary Ports
 - Step 3: Intraoperative Ultrasound
 - Step 4: Incision of the Diaphragm
 - Step 5: Access to Retroperitoneum
 - Step 6: Adrenalectomy
 - Step 7: Closure of the Diaphragmatic Incision
 - Step 8: Laparoscopic Exit
- RESULTS
- TECHNICAL CAVEATS
- TECHNICAL LIMITATIONS
- SUMMARY
- REFERENCES

Laparoscopic adrenalectomy has achieved established status and is increasingly performed at many institutions worldwide in the majority of patients with benign surgical adrenal disease.

INTRODUCTION

Many endocrine disorders of the adrenal gland, including primary aldosteronism, Cushing's syndrome, and pheochromocytoma and malignant adrenal disease may be treated surgically with adrenalectomy (1). The large abdominal skin incision employed in past decades to achieve the large open surgical exposure—mandatory to perform adrenal surgery—was dictated by the anatomic characteristics of the adrenal, namely its retroperitoneal high location, small size, friability, and abundant delicate vascularity. For the same very anatomic reasons, minimally invasive approaches, including laparoscopic adrenalectomy, have found rather dramatic application in the field of adrenal surgery since their first description in the early 1990s by Gagner et al. (2)

Laparoscopic adrenalectomy has achieved established status and is increasingly performed at many institutions worldwide in the majority of patients with benign surgical adrenal disease (3).

Although open surgery remains the technique of choice in patients with primary adrenal cancer, the laparoscopic radical dissection of a small, organ confined, solitary adrenal metastasis or primary adrenal carcinoma is associated with acceptable oncological outcomes (4).

Laparoscopic adrenalectomy can be performed either transperitoneally (5) or retroperitoneally (6), and 2 mm needlescopic instruments and optics may be utilized to further minimize the morbidity of conventional laparoscopic adrenalectomy (5).

CURRENT INDICATIONS AND CONTRAINDICATIONS OF LAPAROSCOPIC ADRENALECTOMY

Laparoscopic adrenalectomy has become the gold standard approach for the treatment of select patients with aldosteroma, pheochromocytoma, Cushing's disease, nonfunctioning adenoma, and rarely, adrenal cyst or myelolipoma. Laparoscopic radical adrenalectomy for primary or metastatic malignancy, has been reported (4).

Unacceptable cardiopulmonary risk, uncorrected coagulopathy, abdominal sepsis, and bowel obstruction represent general contraindications for laparoscopy. Laparoscopic adrenalectomy is currently contraindicated for the treatment of a large adrenocortical carcinoma with local periadrenal invasion or venous thrombus. Morbid obesity is no longer a contraindication to laparoscopic adrenalectomy (7,8).

The first thoracoscopic transdiaphragmatic incisional biopsy of the left adrenal gland was performed by Mack et al. in 1992.

TRANSTHORACIC LAPAROSCOPY: EXPERIMENTAL AND CLINICAL DATA

After its first description in the 1920s, thoracoscopy was initially employed as a purely diagnostic tool and, subsequently, as a complex therapeutic procedure for the treatment of pulmonary, mediastinal, spinal, esophageal, and cardiac diseases (9–11).

The first thoracoscopic transdiaphragmatic incisional biopsy of the left adrenal gland was performed by Mack et al. in 1992 (12).

Experimental Data

The porcine model was used by Pompeo et al. to describe transthoracic (TT) left adrenalectomy in 1997 (13). After inserting four 10-mm laparoscopic trocars into the left pleural cavity, left pneumothorax was created insufflating CO₂ at a mean pressure of 10 mmHg. A 6-cm phrenotomy was performed starting from the lateral side of the aorta and retroperitoneal space entry was achieved. Carbon dioxide–induced positive intrapleural pressure facilitated this maneuver. After Gerota's fascia opening and gentle spleen retraction, the adrenal gland was identified and dissected downward. Endoscopic clips were used to control small tributary vessels, which were subsequently divided. Blunt dissection was used to free the inferior pole of the adrenal gland from the renal vein until the main adrenal vein was identified, clipped, and divided. The specimen was retrieved through one of the trocars. Adequate hemostasis was secured and phrenotomy repaired with running nonabsorbable suture placed with endosuture technique. Laparoscopic exit was performed after reexpansion of the ipsilateral lung. Mean operative time was 2.75 hours, mean blood loss was 76 cc. Complications included splenic injury in one pig and difficult diaphragmatic repair in another. However, all the procedures ($n = 5$) were successfully completed. Endoscopic suturing or staples were used to perform thoracoscopic repair of the diaphragmatic incision (13,14).

In 2000, Meraney et al. performed the first thoracoscopic transdiaphragmatic bilateral nephrectomy in an acute porcine model (15). In their study, three ports were used to gain thoracic access and the retroperitoneum was accessed through a diaphragmatic incision. Feasibility of individual control of the renal artery and vein, and circumferential mobilization of the kidney was assessed. Acceptable intraoperative arterial blood gas parameters were maintained in all procedures. The spleen during left-sided nephrectomy, and the liver during right-sided nephrectomy, respectively, were adequately retracted using a TT 10 mm fan retractor. Mean diaphragmatic incision was 7.2 cm. Diaphragm repair was performed placing continuous sutures. Perioperative results showed mean surgical time of 69.3 minutes for left nephrectomy ($n = 4$) and 74.3 minutes for right nephrectomy ($n = 4$), and a mean blood loss of 18.7 cc.

Based on the encouraging results of the porcine study (10), Gill et al. developed and refined the technique for thoracoscopic nephrectomy and extrapolated the approach to adrenal surgery in human cadavers (16). Four human cadavers underwent bilateral thoracoscopic transdiaphragmatic nephrectomy (Table 1).

After access and development of the retroperitoneal space, individual control of the renal artery and vein was feasible in all eight procedures. However, the necessary exposure was achieved only after performing considerable TT retraction of the liver or spleen despite the lateral position in which all the cadavers were placed. Left nephrectomy and right nephrectomy required a mean surgical time of 64.3 minutes and of 82.5 minutes,

Based on the encouraging results of the porcine study, Gill et al. developed and refined the technique for thoracoscopic nephrectomy and extrapolated the approach to adrenal surgery in human cadavers.

TABLE 1 ■ Thoracoscopic Transdiaphragmatic Nephrectomy: Human Cadaver Study

Variables	Left nephrectomy (range)	Right nephrectomy (range)
No. subjects	4	4
Mean surgical time (min)	64.3 (54–76)	82.5 (72–90)
Individual steps (min):		
Diaphragmatic incision	11 (10–13)	11.5 (10–13)
Hilar dissection	26.2 (24–31)	31 (29–36)
Renal vessel control	10.2 (9–11)	13 (11–15)
Diaphragmatic repair	19.2 (16–23)	22.2 (20–25)
Diaphragmatic incision length (cm)	10 (8–12)	9.5 (8–12)
No. inadvertent celiotomy	1	1
Ureteral length (cm)	5.6 (3.5–8)	3.9 (3–4.5)

Source: From Ref. 16.

respectively. Approximately half an hour was necessary to perform hilar dissection on either side, with no injury occurring to the renal vessels. Specimen mobilization resulted in inadvertent peritoneotomy in two instances. However, intraoperative exposure was not compromised by such events. No inadvertent injury to adjacent organs occurred. Suture repair of a mean diaphragmatic incision of 10 cm could be performed adequately.

Clinical Data

The best approach to esophagectomy for benign or malignant disease is still controversial. However, TT and blunt transhiatal esophagectomy remain the two most frequently performed procedures. Safety and feasibility of laparoscopic transhiatal total esophagectomy, and combined thoracoscopic and laparoscopic total esophagectomy assessed by many authors have been confirmed by Nguyen et al. who compared these two procedures with conventional esophagectomy (17,18). In the authors' opinion, the main advantages of thoracoscopy, used for mobilization of the intrathoracic esophagus, included better visualization for nodal clearance, prevention of injury to mediastinal structures during esophageal dissection, and lesser intraoperative blood loss.

The TT approach may be favorable also for the repair of bilateral Morgagni hernia, and for lysis of pericardial adhesions and avoiding complications due to uncontrolled transabdominal dissection of pericardial adhesions. This technique results in shorter hospital stay, lesser postoperative pain, and better cosmetic result (19).

Video-assisted thoracoscopy may be employed to perform radical esophagectomy with three-field lymphadenectomy. In fact, pulmonary function may be better preserved and quality of life improved while achieving equivalent long-term survival (20).

THORACOSCOPIC TRANSDIAPHRAGMATIC ADRENALECTOMY: PATIENT SELECTION

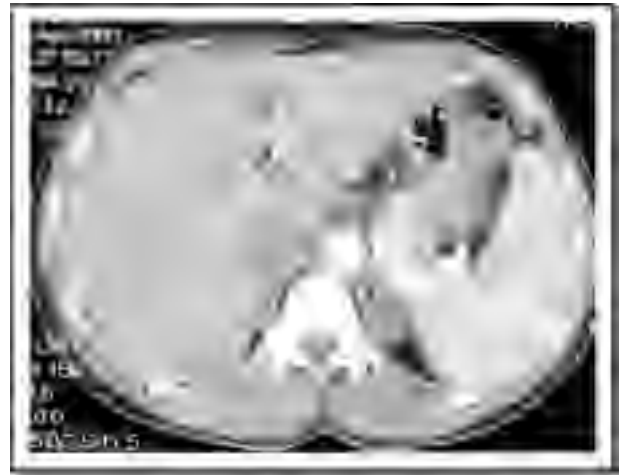Although a history of major open abdominal surgery is no longer a contraindication to transabdominal laparoscopic adrenalectomy, significant technical difficulty may be encountered in patients with such a history. In fact, the presence of extensive adhesions might preclude transperitoneal laparoscopy in these patients. In these cases, the virgin retroperitoneal space may be directly and successfully accessed using retroperitoneal laparoscopy (6,21). Nevertheless, neither the transperitoneal nor the retroperitoneal laparoscopic approach may be confidently employed in the occasional patient who has had both the transperitoneal and the retroperitoneal spaces already violated by open surgery. An ipsilateral radical, total or partial nephrectomy through an extraperitoneal 11th rib incision, followed by a subsequent staged contralateral renal or adrenal procedure through a transperitoneal Chevron incision for bilateral renal carcinoma or benign end-stage disease, may result in the clinical situation described above in the occasional patient presenting with a metachronous solitary adrenal lesion. The adrenal gland is located high in the retroperitoneum in close juxtaposition to the undersurface of the diaphragm. Thus, TT transdiaphragmatic laparoscopy performed through the virgin thoracic cavity may represent an attractive minimally invasive approach to reach the adrenal gland in such select circumstances.

Gill et al. performed the first thoracoscopic transdiaphragmatic adrenalectomy in three patients (right side two, left side one) (16).

Thoracoscopic transdiaphragmatic right adrenalectomy was performed in a 62-year-old male with a new 3.5 cm irregular, heterogeneous right adrenal mass suspicious for metachronous adrenal metastasis. Prior dense transperitoneal and retroperitoneal postoperative adhesions precluded use of transabdominal laparoscopy. The mass was revealed by abdominal computerized tomography obtained during follow-up after open right radical nephrectomy for cancer performed through an extraperitoneal 11th rib incision and followed by staged open left adrenalectomy through a Chevron incision for adrenal metastasis. In another patient, a 64-year-old male, a 2.4 cm, right adrenal mass suggestive of solitary metachronous adrenal metastasis was identified during follow-up of right partial nephrectomy for cancer through an extraperitoneal 11th rib incision, left radical nephrectomy for cancer through a Chevron incision, open cholecystectomy, and appendectomy. This patient underwent thoracoscopic transdiaphragmatic right adrenalectomy. Finally, a 20-year-old female on hemodialysis who had previously undergone bilateral open nephrectomy for renal failure due to end-stage hypertensive nephropathy, presented with persistent intractable hypertension (resistant to 4 antihypertensive medications) for two years after nephrectomy. Biochemical evaluation of the patient revealed moderately increased dopamine (level = 61 mg/mL; normal, 0–20), and normal plasma

Gill et al. performed the first thoracoscopic transdiaphragmatic adrenalectomy in three patients (right side two, left side one).

FIGURE 1 ■ Abdominal computed tomography scan showing left adrenal mass. Source: From Ref. 16.



epinephrine, norepinephrine, and aldosterone, and normal urinary metanephrine, normetanephrine, and vanillylmandelic acid levels. A left adrenal mass increasing in size (from 2.8 to 3 cm) was noted on serial abdominal computed tomography (Fig. 1). The patient underwent thoracoscopic transdiaphragmatic left adrenalectomy.

SURGICAL TECHNIQUE

Patient Preparation and Positioning

Trocar placement can be preoperatively planned with the useful aid of 3-dimensional computed tomography reconstruction of the adrenal gland with vector projection.

Double lumen endotracheal intubation is performed to obtain general anesthesia. The ipsilateral lung is not inflated and absence of breath sounds in the ipsilateral hemithorax is confirmed by auscultation. After positioning the patient prone on a radiolucent spinal frame table, respiratory excursions of the anterior abdominal wall should be left unrestricted (Fig. 2). Patient's arms are adducted. Preparation and draping of the back should be wide and extending beyond the anterior axillary line on both sides.

Step 1: Laparoscopic Entry

TT approach is performed using four valveless, 12 mm ports (Fig. 3). A 1.5 cm transverse incision is made directly over the underlying seventh rib and the initial port is inserted in the intercostal space at the junction of the posterior axillary line and seventh rib. The incision is bluntly deepened using a Kelly clamp until the rib surface is reached. In the same blunt manner, dissection is then continued immediately along the superior edge of the rib, and blunt entry into the pleural cavity is gained. Careful blunt dissection prevents iatrogenic injury to the intercostal neurovascular bundle or lung. A 10 mm 30° laparoscope inserted through the 10 to 12 mm blunt tipped port is used to inspect the thoracic cavity. Ample working space in the ipsilateral hemithorax is achieved using the double lumen endotracheal tube, which allows the collapse of the ipsilateral lung (Fig. 4A). Active

Trocar placement can be preoperatively planned with the useful aid of 3-dimensional computed tomography reconstruction of the adrenal gland with vector projection.

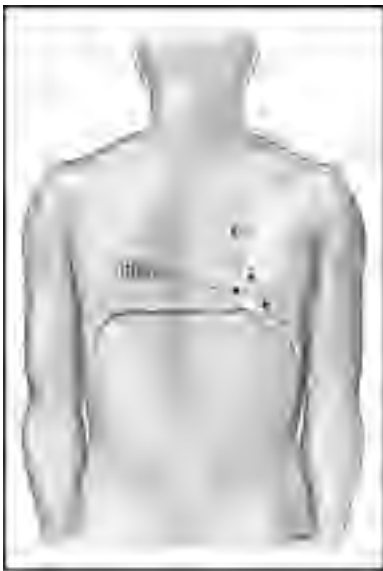


FIGURE 3 ■ Port placement. Source: From Ref. 16.



FIGURE 2 ■ Patient positioning. Source: From Ref. 16.

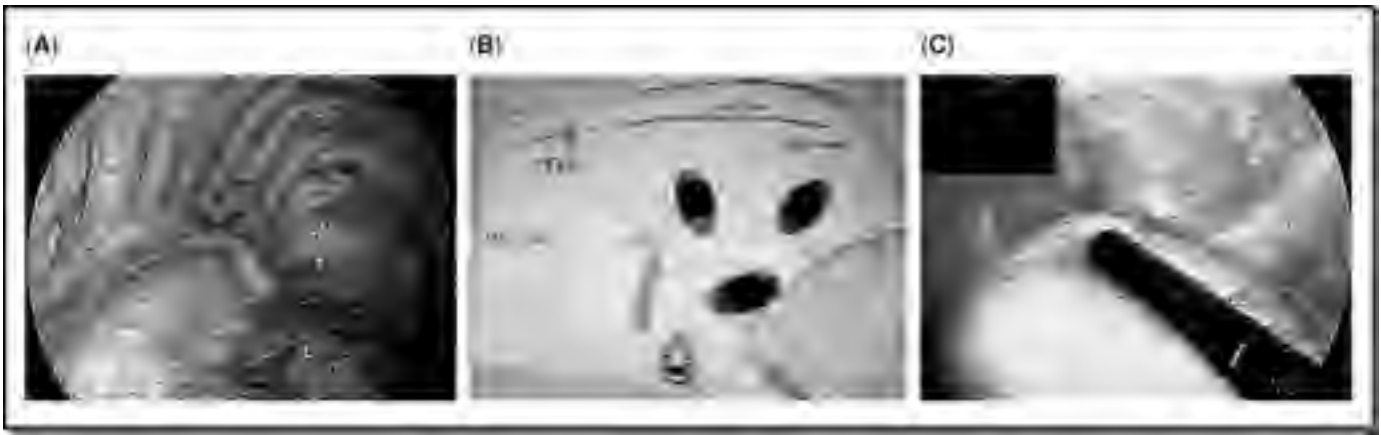


FIGURE 4 ■ Laparoscopic entry and secondary port placement. (See text for details.) Source: From Ref. 16.

retraction, creation of pneumothorax, or CO₂ insufflation is not necessary because the ipsilateral lung falls out of view spontaneously due to lung deflation and the prone position of the patient.

Step 2: Placement of Secondary Ports

Secondary ports are inserted under laparoscopic guidance and include one 10 mm port in the fifth intercostal space along the anterior axillary line, one 5 mm trocar in the eighth intercostal space along the mid axillary line, and one 5 mm port in the eighth intercostal space approximately 5 cm behind the posterior axillary line.

Step 3: Intraoperative Ultrasound

After securing three secondary ports (Fig. 4B), real-time ultrasound is performed using a flexible, steerable color Doppler ultrasound probe inserted through a lateral port and positioned directly on the pleural surface of the hemidiaphragm. Intraoperative ultrasound allows the precise localization of the adrenal mass on the abdominal side of the diaphragm (Fig. 4C) and its location relative to the adjacent anatomical structures, including the edge of the liver and inferior vena cava on the right side (Fig. 5A), or the edge of the spleen and aorta on the left side. The proposed incision site is radially scored on the thoracic surface of the diaphragm with electrocautery (Fig. 5B). Confirmation of accuracy of the location of the proposed line of diaphragmatic incision directly over the adrenal mass is obtained by repeat ultrasonography (Fig. 5C).

Step 4: Incision of the Diaphragm

Using the ultrasound, the supradiaphragmatic inferior vena cava and aorta are clearly identified and avoided. A 6- to 7 cm, full thickness incision is made through the diaphragm muscular wall using an electrosurgical J-hook to maintain complete hemostasis. The diaphragmatic incision, performed posteriorly in a curvilinear fashion, may be extended as necessary to better expose the adrenal gland. However, a distance of at least 2 cm from the chest wall should be maintained.

Step 5: Access to Retroperitoneum

The full thickness incision of the diaphragm exposes the retroperitoneal fat surrounding the adrenal gland, along with the surface of the liver or spleen on the right or left side, respectively (Fig. 5D). The retroperitoneal fat and fibers of the psoas muscle are visualized along the posterior aspect of the operative field.

Step 6: Adrenalectomy

The superomedial and superolateral aspects of the adrenal gland are mobilized slowly and in a deliberate manner using an electrosurgical J-hook to ensure meticulous hemostasis, which is critical at all times (Fig. 6A). The inferior phrenic vessels are controlled. During right adrenalectomy, the main right adrenal vein is visualized when performing the dissection between the adrenal gland and inferior vena cava. The main right adrenal vein is secured and precisely transected with an articulating 30 mm cartridge Endo-GIA stapler (vascular). The adrenal gland is completely freed

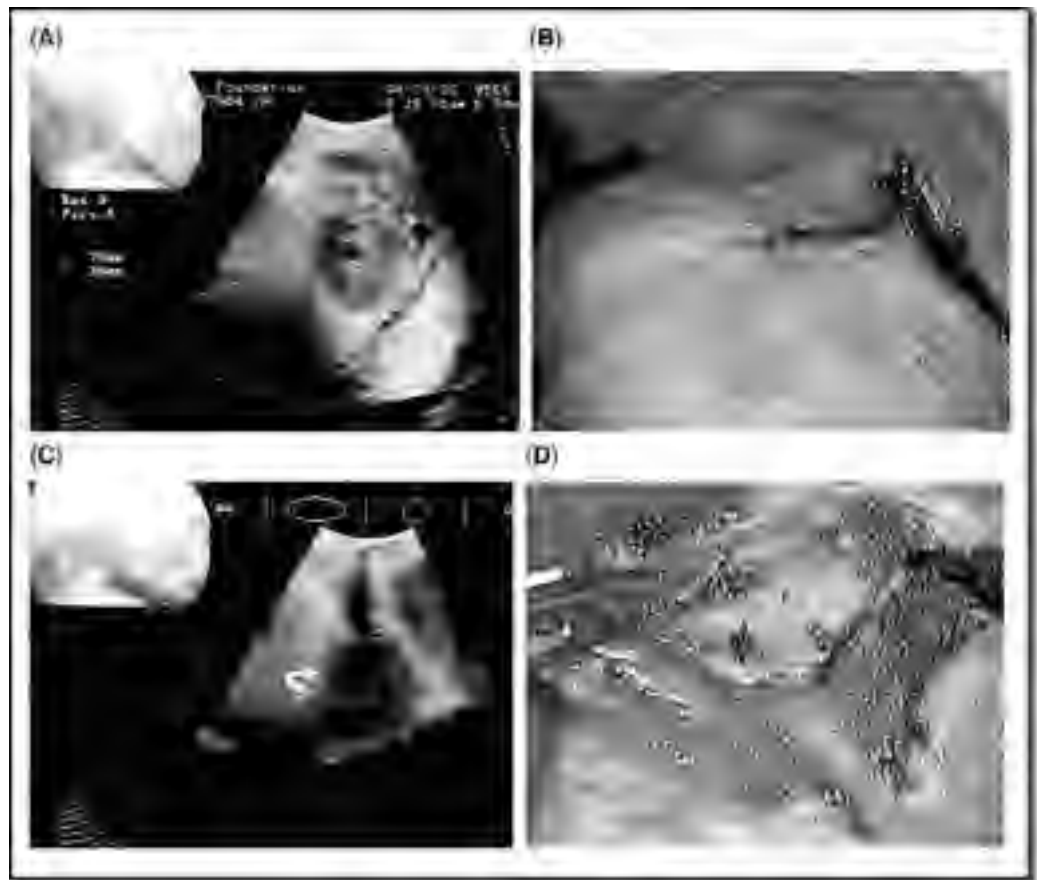


FIGURE 5 ■ Intraoperative ultrasound. (See text for details.) Source: From Ref. 16.

by continuing the dissection caudal, and clipping and dividing multiple adrenal branches arising from the renal hilum. On the left side, the longer, obliquely oriented left main adrenal vein is identified along the inferior-medial aspect of the adrenal gland. After the left main adrenal vein is secured with an Endo-GIA stapler, the adrenal gland is completely freed and is retrieved into the thoracic cavity. The specimen is then entrapped in an Endo Catch bag, and extracted intact through a port site. After confirming hemostasis, the adrenal bed may be filled with a thrombin soaked absorbable hemostatic agent.

Step 7: Closure of the Diaphragmatic Incision

The diaphragm is suture repaired in an airtight manner with a running locking 2-0 polyglactin suture on a computed tomography-1 needle with freehand laparoscopic suturing and intracorporeal knot tying techniques (Fig. 6B).

The diaphragm is suture repaired in an airtight manner with a running locking 2-0 polyglactin suture on a computed tomography-1 needle with freehand laparoscopic suturing and intracorporeal knot tying techniques.

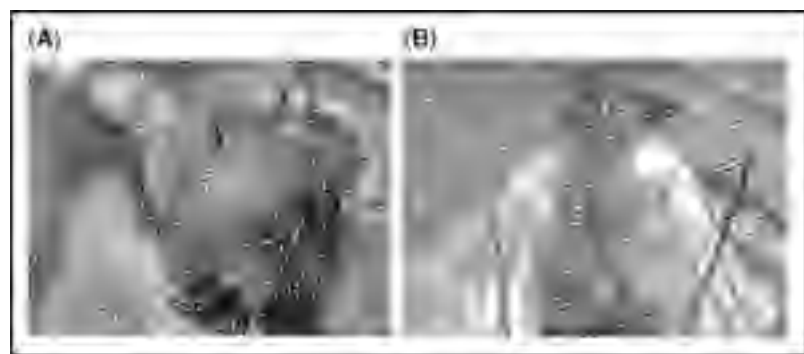


FIGURE 6 ■ The adrenalectomy. (See text for details.) Source: From Ref. 16.

Hemostasis is confirmed, and the pleural cavity is thoroughly irrigated and cleansed.

Step 8: Laparoscopic Exit

Port removal is performed under thoracoscopic visualization. A 34-French chest tube may be inserted through a lateral port and attached to water seal suction. A figure-of-8 2-0 polyglactin suture in the intercostal muscles is used to close the port sites. After unclamping the double lumen endotracheal tube and maintaining the ipsilateral lung fully inhaled and expanded, each knot is tied down. Skin closure is achieved using 4-0 polyglactin subcuticular sutures.

RESULTS

TT approach for adrenalectomy may represent a unique minimally invasive option for the rare patient with adrenal pathology and concomitant scarring of the intraperitoneal and retroperitoneal spaces due to prior transperitoneal and retroperitoneal

TABLE 2 ■ Thoracoscopic Transdiaphragmatic Adrenalectomy: Clinical Experience

	Case 1	Case 2	Case 3
Operation date	12/9/99	4/13/00	6/8/00
Sex/age (yr)	Male/62	Male/64	Female/20
Body mass index	21.4	40	20
American Society of Anesthesiologists class	3	3	3
Prior abdominal surgery	R radical nephrectomy, L Adrenalectomy	L radical nephrectomy, R partial nephrectomy, cholecystectomy, appendectomy	Bilateral nephrectomy
Adrenal side	R	R	L
Adrenal size (cm)	3.5	2.4	2.8
Patient position	Prone	Prone	Prone
No. of ports	4	4	4
Blood loss (cc)	150	500	50
Total surgical time (hr)	4.5	6.5	2.5
Diaphragm suturing time (min)	25	28	18
Inadvertent celiotomy	None	None	None
Intraop. intravenous fluids (cc)	3300	4000	1500
Pulse rate/min			
Maximum	120	136	112
Minimum	76	70	54
Blood pressure			
Maximum	180/90	180/100	190/100
Minimum	120/60	108/64	90/50
End tidal carbon dioxide (mmHg)			
Maximum	36	40	39
Minimum	25	33	28
Chest tube	Yes, overnight	Yes, overnight	No
Resume ambulation (days)	1	1	1
Resume oral intake (days)	1	1	1
Morphine sulfate analgesia (mg)	18	24	38
Hospital stay (days)	2	2	2
Convalescence (wk)	4	4	8
Postop. diaphragm mobility	N/A	Normal	Normal
Adrenal wt. (g)	12	17	12
Pathologic diagnosis	Metastatic renal cell carcinoma	Metastatic renal cell carcinoma	Myelolipoma
Complications	None	None	None
Followup (mo)	8	4	2

^aMovement of the postoperative hemidiaphragm was evaluated by fluoroscopic examination of the chest.

Abbreviations: R, right; L, left.

Source: From Ref. 16.

Freehand laparoscopic suturing and intracorporeal knot tying techniques allowed satisfactory airtight suture repair of the diaphragmatic incision in all three cases.

open surgery. In such cases, transabdominal laparoscopic adrenalectomy may be a technically difficult undertaking, and the virgin thoracic cavity may represent a reasonable access route to the pathological adrenal gland.

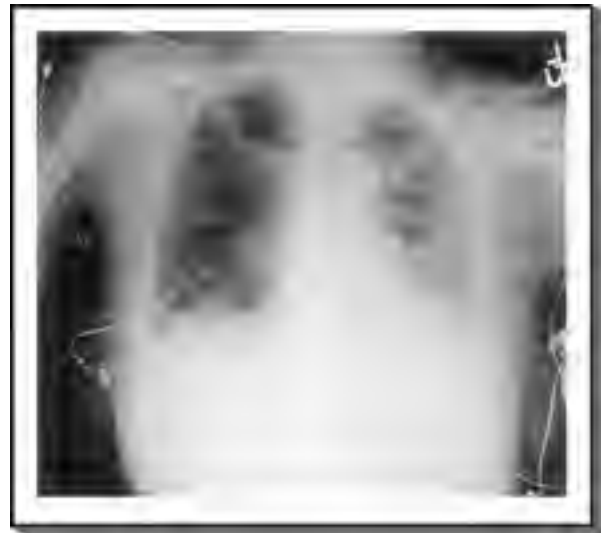Table 2 shows demographic, intraoperative and postoperative data of the three clinical cases performed at the author's institution (16).

A considerable history of prior transperitoneal and retroperitoneal open surgery was present in all three patients. The initial two cases required a long operating time of 4.5 and 6.5 hours, respectively. However, the third case was completed in 2.5 hours. Blood loss of 150 and 500 cc in the first two cases, respectively decreased to 50 cc in the third case due to increasing confidence with the novel approach. Histology revealed solitary adrenal metastasis in the initial two cases and adrenal myelolipoma in the third case. Malignant adrenal disease and its periadrenal reaction and neovascularity may explain the high intraoperative blood loss in the first two cases.

Freehand laparoscopic suturing and intracorporeal knot tying techniques allowed satisfactory airtight suture repair of the diaphragmatic incision in all three cases.

As a result, the authors deemed a chest tube not necessary in the third case (Fig. 7). No clinically significant changes of hemodynamic and capnometric parameters occurred in any case. Postoperatively, the patients were offered fluoroscopic examination of the chest and in the two patients who consented to undergo the test, normal respiratory excursions of the ipsilateral hemidiaphragm were documented. No late complications occurred at a mean follow-up of seven months, and follow-up computerized tomography showed no local recurrence in the adrenal bed in the two patients with adrenal malignancy. A total of five patients have undergone transthoracic transdiaphragmatic adrenalectomy at the Cleveland Clinic from December 1999 to date.

FIGURE 7 ■ Postoperative X-ray of case 3. (See Table 2 and text for details.) *Source:* From Ref. 16.



TECHNICAL CAVEATS

- Mastering of thoracic and retroperitoneal anatomy, and considerable prior experience with major laparoscopy and open surgery are prerequisites to perform thoracoscopic transdiaphragmatic procedures (10,22).
- Thorough familiarity of the anesthesia team with double lumen endotracheal intubation techniques is mandatory for single-lung ventilation.
- Confirmation of adequate deflation of the appropriate lung on clamping the double lumen tube by auscultation at intubation, after prone positioning, and prior to skin incision is necessary (22). Inadequate functioning of the double lumen tube should be detected immediately by continuous monitoring and promptly addressed intraoperatively by bronchoscopy.
- Rigid valveless ports (Fig. 4B) allowing free passage of various instruments are employed given no CO₂ pneumo-insufflation is necessary.
- The need for active retraction of the liver or spleen is minimal due to prone position of the patient, which also allows a direct approach to the adrenal gland, and the related gravity induced anterior displacement of the liver or spleen.

- Diaphragmatic incision directly over the adrenal gland should be precisely planned under real-time ultrasonographic guidance.
- Main adrenal vein control is safely and rapidly performed using an articulating vascular stapler.
- Needle puncture of the lung should be avoided at all times during diaphragmatic repair to prevent inadvertent creation of a bronchopleural fistula.
- Adequate experience and skills with thoracoscopic techniques and team work with an expert minimally invasive thoracic or spine surgeon are strongly recommended.

TECHNICAL LIMITATIONS

Transthoracic transdiaphragmatic surgery is not free of limitations (9,23,24). Preexisting cardiopulmonary disease precluding single-lung ventilation, postoperative pulmonary adhesions due to prior thoracic surgery are contraindications to this technique.

SUMMARY

- Thoracoscopic transdiaphragmatic technique is a novel minimally invasive procedure.
- In patients with a surgically virgin abdomen, laparoscopic adrenalectomy done with the technically simpler transperitoneal or retroperitoneal approaches is recommended and preferred.
- A thoracoscopic transdiaphragmatic approach through the virgin thoracic cavity may be reasonable in the rare patient with surgical adrenal pathology and prior major abdominal surgery precluding transperitoneal and retroperitoneal laparoscopy.
- Necessary requirements for thoracoscopic transdiaphragmatic surgery include anatomical familiarity and considerable experience with thoracoscopic and transabdominal laparoscopy.
- In the future, thoracoscopic and transabdominal laparoscopy could be combined to provide a minimally invasive alternative to open surgical thoracoabdominal incision in patients with larger adrenal (25) or upper pole renal masses.

REFERENCES

1. McCallum RW, Connel JMC. Laparoscopic adrenalectomy. *Clin Endocrinol* 2001; 55:435–436.
2. Gagner M, Lacroix A, Bolte E. Laparoscopic adrenalectomy in Cushing's syndrome and pheochromocytoma. *New Engl J Med* 1992; 327:1033.
3. Gill IS. The case for laparoscopic adrenalectomy. *J Urol* 2001; 166:429–436.
4. Moinzadeh A, Gill IS. Laparoscopic radical adrenalectomy for malignancy in 31 patients. *J Urol* 2005; 173:519–525.
5. Gill IS, Soble JJ, Sung GT, et al. Needlescopic adrenalectomy: the initial series: comparison with conventional laparoscopic adrenalectomy. *Urology* 1998; 52:180.
6. Takeda M, Go H, Watanabe R, et al. Retroperitoneal laparoscopic adrenalectomy for functioning adrenal tumors: comparison with conventional transperitoneal laparoscopic adrenalectomy. *J Urol* 1997; 157:19.
7. Fazeli-Matin S, Gill IS, Hsu TH, et al. Laparoscopic renal and adrenal surgery in obese patients: comparison to open surgery. *J Urol* 1999; 162:665–669.
8. Lal G, Duh Q-Y. Laparoscopic adrenalectomy—indications and technique. *Surg Oncol* 2003; 12:105–123.
9. Dieter RA Jr, Kuzycz GB. Complications and contraindications of thoracoscopy. *Int Surg* 1997; 82:232.
10. Landreneau RJ, Mack MJ, Hazelrigg SR, et al. Videoassisted thoracic surgery: basic technical concepts and intercostals approach strategies. *Ann Thorac Surg* 1992; 54:800.
11. Dexter SP, Martin IG, McMahon MJ. Radical thoracoscopic esophagectomy for cancer. *Surg Endosc* 1996; 10:147.
12. Mack MJ, Arnoff RJ, Acuff, TE, et al. Thoracoscopic transdiaphragmatic approach for adrenal biopsy. *Ann Thorac Surg* 1993; 55:772.
13. Pompeo E, Coosemans W, De Leyn P. Thoracoscopic transdiaphragmatic left adrenalectomy: an experimental study. *Surg Endosc* 1997; 11:390.
14. Fredman B, Olsfanger, D, Jedeikin R. Thoracoscopic sympathectomy in the treatment of palmar hyperhidrosis: anaesthetic implications. *Br J Anaesth* 1997; 79:113.
15. Meraney AM, Gill IS, Hsu TH, et al. Thoracoscopic transdiaphragmatic nephrectomy: feasibility study. *Urology* 2000; 55:443.
16. Gill IS, Meraney AM, Thomas JC, et al. Thoracoscopic transdiaphragmatic adrenalectomy: the initial experience. *J Urol* 2001; 165:1875–1881.
17. Nguyen NT, Follette DM, Wolfe BM, et al. Comparison of minimally invasive esophagectomy with transthoracic and transhiatal esophagectomy. *Arch Surg* 2000; 135:920–925.
18. Nguyen NT, Roberts P, Follette DM, et al. Thoracoscopic and laparoscopic esophagectomy for benign and malignant disease: Lesson learned from 46 consecutive procedures. *J Am Coll Surg* 2003; 197:902–913.

19. Tarim A, Nursal TZ, Yildirim S, et al.: Laparoscopic repair of bilateral morgagni hernia. *Surg Laparosc Endosc Percutan Tech* 2004; 14:96–97.
20. Osugi H, Takemura M, Higashino M, et al. A comparison of video-assisted thoracoscopic oesophagectomy and radical lymph node dissection for squamous cell cancer of the oesophagus with open operation. *Br J Surg* 2003; 90:108–113.
21. Sung GT, Hsu TH, Gill IS. Retroperitoneoscopic adrenalectomy: lateral approach. *J Endourol* 2001; 15:505–511.
22. Lieberman I.H, Salo PT, Orr RD, et al. Prone position endoscopic transthoracic release with simultaneous posterior instrumentation for spinal deformity: a description of the technique. *Spine* 2000; 25:2251.
23. Yim AP, Liu HP. Complications and failures of videoassisted thoracic surgery: experience from two centers in Asia. *Ann Thorac Surg* 1996; 61:538.
24. Jancovici R, Lang-Lazdunski L, Pons F, et al.: Complications of video-assisted thoracic surgery: a five year experience. *Ann Thorac Surg* 1996; 61:533.
25. Hobart MG, Gill IS, Schweizer D, et al. Laparoscopic adrenalectomy for large-volume (or 55 cm) adrenal masses. *J Endourol* 2000; 14:149.

Anup P. Ramani

Section of Laparoscopy, Department of Urological Surgery, University of Minnesota, Minneapolis, Minnesota, U.S.A.

- INTRODUCTION
- PHYSIOLOGY OF RENAL HYPOTHERMIA
- TECHNIQUES OF LAPAROSCOPIC RENAL HYPOTHERMIA
- LAPAROSCOPIC ICE SLUSH RENAL HYPOTHERMIA
- ENDOSCOPIC RETROGRADE COLD SALINE INFUSION
- TRANSARTERIAL RENAL HYPOTHERMIA
- THE LAPAROSCOPIC COOLING SHEATH
- ANCILLARY TECHNIQUES FOR ISCHEMIC RENOPROTECTION
- SUMMARY
- REFERENCES

INTRODUCTION

Laparoscopic partial nephrectomy is emerging as a viable treatment option for select patients who are deemed candidates for nephron-sparing surgery. The laparoscopic option was initially reserved for patients with small, superficial and exophytic tumors. However, with increasing skill and experience, certain centers in the world are now applying laparoscopy to the management of larger and deeper renal tumors.

A clear bloodless field during laparoscopic partial nephrectomy is a pre-requisite for a successful procedure. This allows for optimal visualization of tumor margins as well as tumor depth during resections, which are critical in achieving a negative margin. Although transient hilar control achieves this goal admirably, the attendant warm ischemia may be detrimental to the aerobic metabolism of the kidney. Certainly, the effect is deemed to be more permanent if the warm ischemia period exceeds 30 minutes. Hypothermia induces short-term suspension of renal metabolism, which is necessary for cellular protection and for minimizing post-ischemic renal injury. Thus renal hypothermia is necessary in patients in whom the warm ischemia period is estimated to exceed 30 minutes.

PHYSIOLOGY OF RENAL HYPOTHERMIA

Renal metabolic activities are predominantly aerobic and hence the kidney is susceptible to damage from warm ischemia. Almost immediately after renal arterial occlusion, adenosine triphosphates in the kidney cells break down to monophosphate nucleotides to provide energy for cellular integrity. With increasing duration of ischemia, there is influx of salt and water into the cell resulting in cellular edema and eventually cell death.

Canine studies have shown that warm ischemic intervals of up to 30 minutes can be tolerated by the kidney, with eventual full recovery of function. With greater periods of warm ischemia, there is significant immediate functional loss with either incomplete or absent delayed recovery of renal function. The proximal tubular cells are the most susceptible and show varying degrees of necrosis, while the glomeruli and blood vessels are generally spared. In humans, 30 minutes is the maximum tolerable period of warm ischemia, before permanent damage may ensue (1). Anecdotally, a solitary kidney has been shown to be more resilient to ischemic damage as compared to bilaterally normal kidneys. The exact mechanism remains uncertain.

A variety of techniques have been described to minimize warm ischemic damage due to hilar occlusion. These include preoperative and intraoperative hydration, minimize

traction on the renal artery and intraoperative administration of mannitol. Hypothermia is the most commonly employed technique for protecting the kidneys from ischemic damage (2). Lowering renal temperature reduces energy-dependent metabolic activity of the cortical cells which leads to decreased consumption of oxygen and reduced breakdown of ATP. A negative effect of hypothermia is inactivation of the sodium-potassium pump at the cellular level, which ultimately allows salt and water to enter the cell. These effects are completely reversible at temperatures above 4°C. With further fall in temperature, formation of ice crystals and irreversible cell damage occurs. For practical purposes, a uniform temperature of 20°C to 25°C has been found adequate to maintain renal function even after three hours of arterial occlusion.

TECHNIQUES OF LAPAROSCOPIC RENAL HYPOTHERMIA

Laparoscopic partial nephrectomy is now being performed at a variety of centers in the United States and in the world. Duplicating open surgical principles is a key aim of any laparoscopic procedure. Thus various authors have reported their techniques of achieving laparoscopic renal hypothermia, which are modifications of the technique used during open surgery. The critical issue in achieving laparoscopic hypothermia is to ensure that the hypothermia is uniform throughout the kidney surface, cortex and the medulla.

LAPAROSCOPIC ICE SLUSH RENAL HYPOTHERMIA

Based on prevailing open surgical principles, the technique of laparoscopic ice slush for renal hypothermia was first described by Gill et al. (3) from the Cleveland Clinic Foundation. They reported their technique in 12 patients, with a mean tumor size of 3.2 cm (range, 1.5–5). Mean depth of invasion into the parenchyma was 1.5 cm (range, 0.7–2.5). Of these, two patients had a solitary kidney.

A transperitoneal approach was used. A 5 French open ended ureteral catheter was inserted cystoscopically and positioned in the renal pelvis. The renal artery and vein were circumferentially mobilized en bloc, without any attempt to individually dissect the vessels. The kidney was completely mobilized within Gerota's fascia, maintaining the perirenal fat over the tumor. Laparoscopic ultrasonography was now performed to delineate the tumor and circumferentially score the proposed line of resection around the tumor, including an adequate margin of healthy tissue. Mannitol (12.5 g) was administered intravenously and a Satinsky clamp was positioned around the intact, en bloc renal hilum without closing its jaws.

Sterile ice slush was created in an ice slush machine and constantly stirred manually to reduce it to a fine consistency. Five 30 cc syringes were modified by cutting off the nozzle end of the barrel. They were prefilled with ice slush in preparation for rapid injection.

The 12 mm inferior pararectal port was removed and a 15 mm Endocatch II bag inserted through the same skin incision. The bag was opened and carefully positioned around the kidney. The drawstring was pulled, thus, detaching the bag and deploying it around the kidney. The disengaged metal ring of the bag was removed from the abdomen and the inferior pararectal port was reinserted. The drawstring was further cinched with extreme care taken to avoid any trauma to the renal vein and artery. Typically, the drawstring cannot be synched completely, requiring placement of hem-o-lock clips to snug the mouth of the bag gently around the intact renal hilum. Thus, the kidney is completely enclosed by the bag. The jaws of the Satinsky clamp were then securely closed around the renal vessels taking care not to include any part of the bag in the jaws.

The bottom end of the bag was grasped with locking Allis forceps inserted through the inferior pararectal port. This port was removed, delivering the end of the bag outside the abdomen, where it was secured with a hemostat. The port site skin incision was extended by only 2–3 mm and the peritoneal fascia was similarly incised.

Pneumoperitoneum was desufflated and the exteriorized end of the bag was cut open. Using the previously loaded syringes, 600–750 cc of ice slush were rapidly inserted into the bag, thus, completely surrounding the kidney with ice. The opened end of the bag was closed with a tie, the bag reinserted into the abdomen, a 10 mm balloon cuffed blunt tip cannula secured at this port site and pneumoperitoneum was restored. Laparoscopic visualization confirmed that the kidney was properly surrounded by ice slush within the bag. A laparoscopic sponge (4 × 18 inches) was positioned around the bag to prevent bowel from coming in direct contact with the ice filled

bag. After approximately 10 minutes the bag was incised and the ice slush removed from around the tumor site only, leaving the ice in contact with the remainder of the kidney surface. Laparoscopic partial nephrectomy was then completed in the standard fashion.

In the Cleveland clinic series, the median time to deploy the bag was seven minutes (range, 5–20). A nadir renal parenchymal temperature of 5°C to 19.1°C was achieved in the five patients in whom renal parenchymal temperatures were measured using thermocouples. Concomitantly, median systemic esophageal temperature decreased by only 0.6°C.

Median total ischemia time was 43.5 minutes and total operative time was 4.3 hours (range, 3–5.5). Median hospital stay was three days (range, 2–7).

Intraoperative complications occurred in two patients.⁰ In one, the kidney was not fully mobilized, and the ice slush filled bag partially slipped off the kidney. In the other, part of the bag was caught in the jaws of the Satinsky clamp resulting in inadequate occlusion of the renal pedicle and a 500 cc blood loss during resection of tumor.

Postoperative radionuclide scanning confirmed function in the operated kidney in each instance, although with various degrees of resolving acute tubular necrosis. For the whole group, mean preoperative serum creatinine was 1.1 mg/dL. Mean peak serum creatinine was 1.5 mg/dL an average of 1.2 days after surgery and nadir serum creatinine was 1.2 mg/dL an average of 2.8 days after surgery.

Potential shortcomings of this technique include space limitations to deploy and engage the bag in the retroperitoneal approach, significant perinephric adhesions that may preclude complete mobilization of the kidney, and the theoretical possibility of systemic hypothermia.

The authors concluded that adequate renal cooling can be achieved by purely laparoscopic techniques and the additional studies are required to develop a more efficient ice delivery system.

Wakabayashi et al. (4) recently described a technique for renal hypothermia using ice slush during retroperitoneal laparoscopic partial nephrectomy. They reported their experience in two cases. The renal tumor size was 1.3 cm and 9 mm, respectively.

A 6 French pigtail catheter was inserted into the renal pelvis cystoscopically. A standard retroperitoneal approach was then achieved using a balloon dilator and four trocars. The renal artery was mobilized and vascular tape placed around the renal artery. The kidney was completely mobilized. The primary port site incision was then extended and a cylindrical cannula was then inserted into the retroperitoneum. Ice slush was then introduced through the cylindrical cannula into the retroperitoneum. The device was removed and the skin incision narrowed with a suture. The balloon port was then secured into the retroperitoneum. The ice slush was then evenly distributed over the kidney using an Endo Retractor^a, and Mannitol administered intravenously. A laparoscopic bulldog clamp was placed on the renal artery. Pneumoperitoneum was restored after 15 minutes of cooling. Laparoscopic partial nephrectomy was then completed.

In these two cases, the total operative times were 214 and 233 minutes, respectively. Cold ischemia times were 81 and 47 minutes. Nadir renal temperature was 18.4°C and 25.8°C. The systemic temperature decreased by 0.8°C and 0.6°C, respectively. A total of 1500 cc and 1200 cc ice slush was introduced, respectively, mean time of 10.5 minutes to insert the ice slush. Postoperative isotope renal scans showed good function in the renal remnants. There were no complications. The concern with this technique is the potential for uneven cooling of the kidney due to uneven application of the slush over the entire surface of the kidney. Also any inadvertent peritoneal entry may compromise bowel integrity.

ENDOSCOPIC RETROGRADE COLD SALINE INFUSION

Historically, Jones and Politano initially reported the concept of renal parenchymal cooling using cold saline irrigation of the renal collecting system. However, due to limitations in technology at that time, a ureterotomy was required to gain access to the collecting system.

More recently, Landman et al. (5) described renal cooling using ice cold saline solution for retrograde injection through a pre placed ureteral access sheath. They reported their technique in the porcine model and subsequently in one patient who underwent open radical nephrectomy for renal tumor.

^aU.S. Surgical Corp., Norwalk, CT.

A 12/14 ureteral access sheath was advanced cystoscopically over an Amplatz superstiff guidewire up to the renal pelvis, under fluoroscopic guidance. A side adaptor was twisted into the distal end of the access sheath. A 7.1 French pigtail catheter was passed through the access sheath into the renal pelvis. The access sheath was then secured to the Foley catheter to prevent dislodgement during patient positioning. The kidney was approached and completely mobilized through a flank incision. The renal artery and the vein were individually dissected and then clamped. Ice cold (-1.7°C) 0.9% saline from a 3 L bag suspended 120 cm above the kidney was irrigated through the access sheath into the renal pelvis for 35 minutes. The efflux returning from the pigtail catheter in the pelvis was collected. The radical nephrectomy was then completed in standard fashion.

The above technique resulted in the circulation of 85 mL/min of ice-cold saline through the collecting system. The renal cortical and medullary temperatures were measured with thermocouples to be 24°C and 21°C , respectively. The patient's core temperature remained at 37°C throughout the procedure. In this one patient who underwent radical nephrectomy, the cold ischemia was maintained for 35 minutes. As this patient underwent a radical nephrectomy, no follow-up on renal function was available.

A potential concern with this technique is that during laparoscopic partial nephrectomy for an infiltrating tumor, entry into the collecting system occurs early within one to two minutes of initiating resection. This would lead to leakage of the perfusate with potential compromise of renal cooling.

In both their studies, Landman et al. (5) did not perform a partial nephrectomy to evaluate the effect of leakage of the perfusate. Thus additional studies are required to evaluate this technique with radiological follow up of the renal remnant to evaluate residual function.

TRANSARTERIAL RENAL HYPOTHERMIA

Percutaneous transarterial renal hypothermia offers another option of for achieving laparoscopic renal hypothermia. A variety of studies in literature report on the efficacy of this technique. Marberger and Eisenberger (6) in the early 1970s, initially reported that renal artery perfusion cools the kidney three times as rapidly as does surface cooling. They also reported that surface cooling leads to heterogeneous cooling of the kidney, although this has now been shown to be erroneous and that uniform cooling is possible with surface hypothermia with ice slush. They reported on 63 patients who underwent hypothermic nephrolithotomy for extensive stone disease. Percutaneous renal artery access was achieved with a catheter. The renal artery was occluded with either a tourniquet or with a double lumen balloon tipped catheter in the artery. The kidneys were perfused with Ringer lactate or 5% Dextrane solution at 4°C . Rectal temperature was measured simultaneously. A control group of 39 kidneys undergoing the same procedure were cooled with surface ice slush.

The average cold ischemia was 61.3 minutes in the arterial catheter group and 59.8 minutes in the ice slush group. Renal parenchymal temperature was not measured during the procedure. Follow-up consisted of obtaining hippuran clearance. They showed a statistically significant decrease in postoperative renal clearance in the surface cooled kidneys compared to the arterially perfused kidneys. They also reported that poorly functioning kidneys recovered better from the ischemic insult if the hypothermia was arterial as compared to surface cooling.

More recently, Munver et al. (7) reported on a novel technique involving cannulation of the renal artery and infusion of cold lactated ringer's solution in nine patients undergoing open partial nephrectomy.

Following occlusion of the renal artery and vein with vascular clamps, the vessels were cannulated with 14 gauge angiographic catheters. The ice cold perfusate was then run through the arterial catheter and the effluent cleared through the venous catheter.

This led to a rapid (one to two minutes) drop in renal temperature that was uniform throughout the kidney. There were no complications reported in this series. Serial postoperative isotope scans revealed good function in the renal remnants.

Janetschek et al. have reported on their technique of renal artery perfusion for laparoscopic partial nephrectomy. A total of 15 patients underwent laparoscopic partial nephrectomy under cold ischemia induced by renal arterial perfusion. The mean tumor size was 2.7 cm (range 1.5–4). Four of the tumors were completely intra-renal.

An open tipped ureteral catheter was placed in the renal pelvis under fluoroscopic guidance. An angiocatheter was then passed into the main renal artery through a femoral puncture in the operating room by a radiologist. The kidney was approached laparoscopically. The renal artery can be occluded either with the intra-arterial balloon or by

arterial occlusion with a vascular clamp or a tourniquet. In the above series, the intra-arterial balloon was used in two patients and the tourniquet in 13 patients. The balloon was unable to occlude the entire lumen that led to bleeding during resection. Intravenous mannitol was administered 15 minutes before arterial occlusion. Hypothermia was achieved by occluding the renal artery and infusing 1000 mL of iced Ringer lactate at 4°C at a rate of 50 mL per minute. Surgery was started immediately following the infusion. Renal temperature was monitored with a thermocouple probe in the parenchyma. When parenchymal temperature of 25°C was attained, perfusion was decreased to maintain steady temperature. Patient was warmed with a warm air blanket and rectal temperature continuously monitored.

The mean time for renal parenchymal temperature to reach 25°C was 10 minutes following initiation of perfusion. Mean operative time was 185 minutes (range, 135–220). The angiocatheter placement required a mean of 16 minutes (range, 10–20). Mean total ischemia time was 40 minutes (range, 27–101). Mean amount of perfusate was 1580 mL (range, 1150–2800). Mean decrease in body temperature was 0.64°C (0.5–1.1). Inadequate occlusion of the artery by the balloon in the initial two patients led to significant blood loss, following which the authors modified their technique to include hilar clamping. One patient required a second look laparoscopy for persistent hemorrhagic drainage from the drain. The cause was found to be a parenchymal suture that had cut through. Hemostasis was achieved with strips of Tachocomb^b. Of the 15 patients, postoperative renal function was evaluated in eight patients, which revealed decrease of function on isotope scans proportionate to the parenchyma excised.

Although an attractive option, this technique has the potential for injury to the femoral artery as well as the renal artery. This can range from an intimal tear to complete avulsion of the artery. Also this requires an additional procedure with the presence of a radiologist. Thus significant experience with renal artery catheterization is mandatory before this can be attempted.

THE LAPAROSCOPIC COOLING SHEATH

Herrell et al. described the use of a cooling sheath for achieving surface renal hypothermia during laparoscopic surgery. This consisted of a plastic double jacket with inlet and outlet tubings. In a porcine model, 12 animals were divided into three groups. In group I, the kidney was mobilized by open surgery and surface cooling achieved with ice slush after arterial occlusion. In group II, the kidney was mobilized laparoscopically and the renal hilum was clamped for 60 minutes without any hypothermia. In group III, the kidney was mobilized laparoscopically. In three of the four animals in this group, a 4 cm open incision was made to apply the cooling jacket around the kidney. In the last animal the jacket was placed around the kidney through an 18 mm trocar. Mannitol was given intravenously and the renal artery clamped using a bulldog clamp. A tubing pump was then used to initiate flow of cold sterile saline from a chilled bath (3–5°C) through sterile tubing into the sheath. Outflow to the bath through similar sterile tubing created a sterile circuit. Renal and body temperatures were recorded. After 60 minutes, the clamp and the sheath were removed.

The kidney was harvested at seven days after ischemia. The renal temperature in groups I and II dropped to the optimal hypothermic range (5–25°C) within five minutes. Overall surface ice slush cooling resulted in lower temperatures than the sheath, but this was not statistically significant. In one animal, leakage from the sheath, with continued irrigation led to transient drop of body temperature to 34°C with no adverse events. Histology revealed no differences in kidneys from groups I and III (hypothermia) whereas kidneys from group II (no hypothermia) showed expected tubular epithelial necrosis and vacuolization.

ANCILLARY TECHNIQUES FOR ISCHEMIC RENOPROTECTION

The cornerstones of minimizing renal ischemic damage are to achieve copious diuresis before and after hilar clamping, reduce oxidative damage due to free radicals and minimize ischemia time during surgery. Intravenous mannitol given 10–15 minutes prior to and immediately after arterial occlusion ensures adequate diuresis after unclamping.

Protection of renal function by injection of the nucleotide inosine has been well documented in literature. Wickham et al. in 1979 reported the use of inosine in seven

^bNycomed, Linz, Austria.

patients. Six of these had a staghorn calculus and one had a renal tumor. Ten minutes prior to clamping, 2 g of inosine in 80 mL of diluent Trophycardyl^c were administered intravenously. The renal artery was then occluded and surgery performed. On differential renography postoperatively patients showed evidence of diminished function, but by one month all had regained preoperative function. Inosine is thought to act by replenishing the adenylic nucleotide pool.

Oxygen free radicals generated as a result of anaerobic metabolism are known to have a toxic effect on cellular architecture. Scavengers of oxygen free radicals may have a renoprotective effect in patients requiring extensive ischemic periods for complicated reconstructive surgeries.

SUMMARY

- Renal hypothermia is infrequently required during the performance of laparoscopic renal procedures today
- Of the variety of techniques available to achieve laparoscopic renal hypothermia, the surface hypothermia achieved with ice slush duplicates open surgical, time-tested principles and represents the preferred option currently.
- Better delivery systems for hypothermic solutions are needed to optimally achieve uniform cooling of the kidney.

REFERENCES

1. Ward JP. Determination of the optimum temperature hypothermia during temporary renal ischemia. *Br J Urol* 1975; 47:17–24.
2. Novick AC. Renal hypothermia: In vivo and ex vivo. *Urol Clin North Am* 1983; 10:637–644.
3. Gill IS, Abreu SC, Desai MM, et al. Laparoscopic ice slush renal hypothermia for nephrectomy: the initial experience. *J Urology* 2003; 170:52–56.
4. Wakabayashi Y, Narita M, Kim C, Kawakami T, Yoshiki T, Okada Y. Renal hypothermia using ice slush for retro laparoscopic partial nephrectomy. *Urology* 2004; 63(4):773–775.
5. Landman J, Venkatesh R, Lee D, Vanlangendonck R, Andriole G, et al. Renal hypothermia achieved by retro cold saline perfusion: technique and initial clinical application. *Urology* 2003; 61:1023–1025.
6. Marberger M, Eisenberger F. Regional hypothermia of the kidney; surface or transarterial perfusion cooling? A functional study. *J Urol* 1980; 124:179–183.

^cLaboratories Innothera, France.

Thomas H. S. Hsu

Department of Urology, Stanford University Medical Center, Stanford University School of Medicine, Stanford, California, U.S.A.

■ INTRODUCTION
 ■ LAPAROSCOPIC AORTORENAL BYPASS
 ■ LAPAROSCOPIC RENAL AUTOTRANSPLANTATION

■ LAPAROSCOPIC REPAIR OF RENAL ARTERY ANEURYSM
 ■ SUMMARY
 ■ REFERENCES

To date, three different types of laparoscopic renovascular surgical procedures have been reported in the literature. These include laparoscopic aortorenal bypass, laparoscopic renal autotransplantation, and laparoscopic repair of renal artery aneurysm.

INTRODUCTION

Laparoscopic surgery has been shown to reduce postoperative patient morbidity and recovery based on the extensive worldwide clinical experience in the urologic surgical literature. However, the sweeping changes seen in most aspects of urologic laparoscopy have not been paralleled in the area of renovascular surgery. The lack of development in its application to renovascular surgery is primarily due to the high level of technical difficulty in performing meticulous and expeditious vascular reconstruction, in which the intracorporeal suturing and knot-tying skills that are associated with steep learning curve are essential to success.

To date, three different types of laparoscopic renovascular surgical procedures have been reported in the literature. These include (i) laparoscopic aortorenal bypass, (ii) laparoscopic renal autotransplantation, and (iii) laparoscopic repair of renal artery aneurysm.

LAPAROSCOPIC AORTORENAL BYPASS

Physiologically significant renal artery stenosis, mostly due to atherosclerosis, has been known to cause hypertension and deterioration of renal function (1–3). Percutaneous transluminal balloon angioplasty and intravascular stenting have evolved as the first-line therapy in recent years; however, they have provided inferior long-term patency (4).

Surgical revascularization remains the gold-standard definitive treatment of renal artery stenosis as well as the salvage treatment of failed endovascular intervention. However, the conventional open revascularization surgery is typically associated with significant patient morbidity and recovery. Laparoscopy was thought to have the potential to reduce the postrevascularization patient morbidity.

Hsu et al. from the Cleveland Clinic investigated the feasibility and the physiologic and pathologic outcomes of laparoscopic aortorenal bypass in the laboratory setting (5,6). Their reports also represented the first attempt to study laparoscopic renovascular surgery in the surgical community.

In the initial report on laparoscopic renovascular surgery, the authors performed an aorta-to-left renal artery bypass using an interposition polyethylene graft in five large farm pigs, following extensive experience with laparoscopic vascular suturing from arduous practice in the in vitro setting as well as in approximately 20 animals (5). In the procedure, five to six trocars were used for transperitoneal access, and intracorporeal free-hand suturing and knot-tying techniques were used exclusively for vascular reconstruction. In this feasibility study, the mean surgical time was 5.4 hours, and the mean renal ischemia time was 61 minutes. The mean end-to-side graft-to-aorta and end-to-end graft-to-renal artery anastomosis times were 34 and 40 minutes, respectively. The average estimated blood loss was 66 mL. Upon revascularization, there was prompt reperfusion of the kidney and Doppler-confirmed pulsation of the renal artery. On autopsy following the surgical procedure, there was anastomotic patency was present in all five cases.

Surgical revascularization remains the gold-standard definitive treatment of renal artery stenosis as well as the salvage treatment of failed endovascular intervention. However, the conventional open revascularization surgery is typically associated with significant patient morbidity and recovery. Laparoscopy was thought to have the potential to reduce the postrevascularization patient morbidity.

Following the successful feasibility study above, the same authors proceeded to investigate the long-term clinical and pathologic outcomes of laparoscopic aortorenal bypass in a survival animal study, in which a total of eight large farm pigs underwent the laparoscopic procedure (6). Again, the aorta-to-left renal artery bypass without graft was performed, involving transection of left renal artery and end-to-side aorta-to-renal artery anastomosis. Again, all steps were performed using totally intracorporeal laparoscopic surgical techniques. Furthermore, a novel method of in situ renal hypothermia was used to achieve intracorporeal renoprotective effects by infusion of ice-cold saline into the renal artery through a balloon catheter. In the study, all eight animals underwent the bypass procedure successfully. The median surgical time and total anastomotic time were 110 and 40 minutes, respectively. The median renal warm ischemic time was nine minutes. The median estimated blood loss was 30 mL. Postoperatively, one animal died of pneumonia, and the remaining seven experienced no postoperative complication and were euthanized at different time points from day 0 to week 6. Physiologically, there was no significant difference between preoperative and postoperative (at euthanasia) serum creatinine values (1.15 mg/dL vs. 1.2 mg/dL; $p = 0.39$). Peripheral renin activity was found to have a transient rise in the immediate postoperative period but normalize by one week postoperatively. On autopsy, a grossly normal left kidney with Doppler confirmation of blood flow in the repaired renal artery was identified in all seven animals. Radiographically, ex vivo angiography confirmed a patent anastomosis in all cases. Histologically, there was gradual resolution of mild acute tubular necrosis in the left kidney within six weeks, and there was gradual endothelialization of the aorto-left renal artery anastomotic site, which was found to be complete by six weeks. In short, durable success with physiologic, radiographic, and pathologic confirmation can be achieved in laparoscopic aortorenal bypass.

Subsequent to these two reports of successful laparoscopic aortorenal bypass, the Cleveland Clinic investigators studied another variation of laparoscopic surgical management of renal artery stenosis—laparoscopic splenorenal bypass (7). In the survival animal study, six dogs underwent the transperitoneal laparoscopic splenorenal bypass successfully, in which end-to-end splenic artery-to-left renal artery anastomosis was performed intracorporeally. Mean total operative time and renal ischemia time were 297 and 71 minutes, respectively. Five of six animals were kept alive from one to two months, and patent anastomoses were found in all animals on autopsy. This chronic canine study further supports that laparoscopic vascular bypass involving the renal artery can provide durable results in the laboratory setting.

LAPAROSCOPIC RENAL AUTOTRANSPLANTATION

Renal autotransplantation has been performed for aortorenal vascular disease, upper ureteral tumors and strictures, ureteral loss, loin pain-hematuria syndrome, and idiopathic retroperitoneal fibrosis (8–13). Renal autotransplantation involving two separate procedures, live donor nephrectomy and autotransplantation, is known to be a morbid open surgical procedure requiring two large skin incisions. Laparoscopy was thought to have the potential to minimize the morbidity of this renovascular surgical procedure.

Meraney et al. from the Cleveland Clinic investigated the feasibility and outcome of laparoscopic renal autotransplantation in the laboratory setting (14). This study represents the initial and only report of a completely laparoscopically performed renal autotransplantation.

In their survival study, six farm pigs underwent the laparoscopic renal autotransplantation procedure (14). Laparoscopic left donor nephrectomy was first performed, following which intracorporeal renal hypothermia was achieved via intra-arterial infusion of ice-cold saline solution through a balloon catheter, the same method described earlier by the same Cleveland Clinic group (6). The renal vessels were then anastomosed to the ipsilateral common iliac vessels in the end-to-side manner using laparoscopic intracorporeal free-hand suturing and knot-tying techniques. All animals underwent the procedure successfully, with return of pink color to the autotransplanted kidney and Doppler-confirmed renal arterial pulsation following revascularization. The mean operative time was 6.2 hours. The mean venous anastomosis time was 33 minutes, and the arterial anastomosis time was 31 minutes. The mean iliac clamping time was 77 minutes. The total renal ischemia time was 68.7 minutes, including warm ischemia of 5.1 minutes, cold ischemia of 33 minutes, and rewarming of 31 minutes. Postoperatively,

Meraney et al. from the Cleveland Clinic investigated the feasibility and outcome of laparoscopic renal autotransplantation in the laboratory setting. This study represents the initial and only report of a completely laparoscopically performed renal autotransplantation.

one animal was found to have atrophic, thrombosed autograft. The remaining five animals had stable serum creatinine levels (mean of 1.6 mg/dL) following staged contralateral nephrectomy after autotransplantation. Just before euthanasia, which was done at various times postoperatively (from one to four months), intravenous pyelography and aortography demonstrated prompt contrast uptake and excretion by the autotransplanted kidneys and patent arterial anastomoses in all five animals, respectively. Following euthanasia, histopathologic examination of the autograft showed normal renal architecture without evidence of ischemia or acute tubular necrosis.

LAPAROSCOPIC REPAIR OF RENAL ARTERY ANEURYSM

Renal artery aneurysms may cause renal function deterioration and renovascular hypertension. Furthermore, large aneurysms (>2 cm) have the increased risk of rupture. When indications for intervention are present, the conventional open surgical renal revascularization is the gold-standard treatment, which is known to be associated with significant postoperative morbidity.

Gill et al. from the Cleveland Clinic reported their initial experience with repair of renal artery aneurysm performed laparoscopically to minimize the patient morbidity associated with renal revascularization (15). This report represented the initial laparoscopic renovascular surgery in the clinical setting.

The initial clinical laparoscopic renovascular surgery was performed in a 57-year-old woman with 3-cm saccular aneurysm of the distal left main renal artery that was confirmed by selective left renal arteriography. A transperitoneal four-port approach was used. Meticulous dissection led to the identification of the renal artery aneurysm, which was mostly covered by the main renal vein. Following proximal and distal control of the renal artery with respect to the aneurysm using laparoscopic bulldog clamps, the aneurysm was bivalved, and the excess aneurysm sac was meticulously excised. The edges of the excision site were then trimmed and reconstructed using intracorporeal laparoscopic suturing techniques. Following the removal of the vascular clamps, there was prompt return of pink coloration to the kidney and excellent pulsation in the distal main renal and segmental arteries, with no bleeding from the anastomotic suture line or compromise of the caliber of the reconstructed renal artery segment. Total operative time was 4.2 hours, and total blood loss was 100 mL. Total renal artery clamping time was 31 minutes. There was no perioperative complication. Hospital stay was two days. Renal scan on postoperative day 1 showed good perfusion to the left kidney without evidence of acute tubular necrosis, and there was improved relative left renal function (from 37% before the surgery to 43% after the surgery). Postoperative angiography showed normal caliber of the reconstructed artery at one month.

Gill et al. from the Cleveland Clinic reported their initial experience with repair of renal artery aneurysm performed laparoscopically to minimize the patient morbidity associated with renal revascularization. This report represented the initial laparoscopic renovascular surgery in the clinical setting.

SUMMARY

- Laparoscopic renovascular surgery is feasible, and its short-term and intermediate-term efficacy has been shown in the laboratory and clinical settings to a limited degree.
- Laparoscopic renal revascularization is technically challenging, especially the free-hand intracorporeal suturing and knot-tying steps, and there is clearly a need for further refinement in surgical instrumentation to minimize the steep learning curve associated with laparoscopic vascular suturing and reconstruction.
- Prior to embarking on laparoscopic renovascular surgery, adequate skills in laparoscopic reconstructive techniques are mandatory for success.
- Atraumatic control and handling of the vascular tissues and precise laparoscopic vascular suturing in a meticulous and time sensitive manner are necessary to achieve successful outcome.

REFERENCES

1. Schreiber MJ, Pohl MA, Novick AC. The natural history of atherosclerotic and fibrous renal artery disease. *Urol Clin North Am* 1984; 11:383–392.
2. Dean RH, Tribble RW, Hansen KJ. Evolution of renal insufficiency in ischemic nephropathy. *Ann Surg* 1991; 213:446–455.
3. Derkx FHM, Schalekamp MADH. Renal artery stenosis and hypertension. *Lancet* 1994; 344:237–239.

4. Blum U, Krumme B, Flugel P. Treatment of ostial renal artery stenoses with vascular endoprostheses after unsuccessful balloon angioplasty. *N Engl J Med* 1997; 336:459–465.
5. Hsu THS, Gill IS, Sung GT. Laparoscopic aortorenal bypass: a feasibility study. *J Laparoendosc Adv Surg Tech A* 2000; 1:55–58.
6. Hsu THS, Gill IS, Sung GT, Meraney A, McMahon JT, Novick AC. Laparoscopic aortorenal bypass. *J Endourol* 2000; 14:123–131.
7. Abreu S, Sung GK, Gill IS, et al. Laparoscopic splenorenal bypass in canine model [abstr]. *J Endourol* 2002; 16:S1.
8. Mestres CA, Campistol JM, Botey A, et al. Improvement of renal function in azotemic hypertensive patients after surgical revascularization. *Br J Surg* 1998; 75:578–580.
9. Dubernard JM, Martin X, Gelet A, Mongin D, Canton F, Tabib A. Renal autotransplantation versus bypass techniques for renovascular hypertension. *Surgery* 1985; 97:529–534.
10. Deweerd JH, Paulk SC, Tomera FM, Smith LH. Renal autotransplantation for upper ureteral stenosis. *J Urol* 1976; 116:23–25.
11. Bodie B, Novick AC, Rose M, Straffon RA. Long-term results with renal autotransplantation for ureteral replacement. *J Urol* 1986; 136:1187–1189.
12. Chin J, Kloth D, Pautler S, Mulligan M. Renal autotransplantation for the loin pain-hematuria syndrome: long-term follow-up of 26 cases. *J Urol* 1998; 160:1232.
13. Oesterwitz H, Lenk S, Hengst E, Althaus P. Renal autotransplantation for idiopathic retroperitoneal fibrosis. *Int Urol Nephrol* 1994; 26:167–171.
14. Meraney AM, Gill IS, Kaouk J, Skacel M, Sung GT. Laparoscopic renal autotransplantation. *J Endourol* 2001; 15:143–149.
15. Gill IS, Murphy DP, Hsu THS, Fergany A, El Fattough H, Meraney A. Laparoscopic repair of renal artery aneurysm. *J Urol* 2001; 166:202–205.

LAPAROSCOPIC SURGERY FOR THE HORSESHOE KIDNEY

Hyung L. Kim

Department of Urology, Roswell Park Cancer Institute, Buffalo, New York, U.S.A.

Peter Schulam

Department of Urology, UCLA School of Medicine, Los Angeles, California, U.S.A.

- INTRODUCTION
- PYELOPLASTY
Technique
- HEMINEPHRECTOMY
Technique

- SUMMARY
- REFERENCES

Horseshoe kidney is the most common renal fusion anomaly, occurring in approximately 1 in 400 births. In most cases, there are multiple arteries and veins that supply each kidney.

Although most horseshoe kidneys do not cause symptoms, nephrolithiasis, ureteropelvic junction obstructions, and renal masses are the most frequent findings that require surgery.

In the horseshoe kidney, several factors are thought to contribute to the ureteropelvic junction obstruction, including high ureteral insertion, abnormal course of the ureter ventral to the isthmus, and anomalous blood supply to the kidney.

INTRODUCTION

Horseshoe kidney is the most common renal fusion anomaly, occurring in approximately 1 in 400 births (1).

The right and left kidneys are fused in the midline by a parenchymal or fibrous isthmus. During gestation, the metanephric blastema abnormally migrates toward the midline, leading to contact and fusion of the lower poles. The normal ascent of the kidney is arrested by the inferior mesenteric artery at the level of the L3 or L4 vertebra, and the kidney fails to normally rotate. Consequently, the renal pelvis is ventrally placed and the ureters often course over the isthmus.

The vascular supply to the horseshoe kidney may be complex. The isthmus usually has a separate blood supply. The blood supply to the isthmus may arise from the main renal arteries or it may branch from the inferior mesenteric, iliac, or sacral arteries (2,3). In most cases, there are multiple arteries and veins that supply each kidney.

Horseshoe kidneys are frequently associated with other congenital anomalies. Anomalies involving the skeletal, cardiovascular, and central nervous systems are common. The most frequently associated genitourinary anomalies are hypospadias, cryptorchidism, bicornuate uterus, septate vagina, polycystic renal disease, ureteral duplication, and vesicoureteral reflux (4). Horseshoe kidneys are found in 20% of patients with trisomy 18 and 60% of patients with Turner's syndrome (5,6).

Although most horseshoe kidneys do not cause symptoms, nephrolithiasis, ureteropelvic junction obstructions, and renal masses are the most frequent findings that require surgery (7).

The location of the kidney and the isthmus make laparoscopy challenging. However, laparoscopy is becoming the standard for surgical management of many renal diseases, and laparoscopic pyeloplasties and heminephrectomies can be successfully performed in patients with a horseshoe kidney.

PYELOPLASTY

Ureteropelvic junction obstructions occur in approximately 15% to 33% of horseshoe kidneys (8–10).

In the horseshoe kidney, several factors are thought to contribute to the ureteropelvic junction obstruction, including high ureteral insertion, abnormal course of the ureter ventral to the isthmus, and anomalous blood supply to the kidney.

The conventional surgical treatment for a ureteropelvic junction obstruction in a horseshoe kidney is an open dismembered pyeloplasty, isthmectomy, and nephropexy of the involved renal moiety. The success rate for open pyeloplasty in this patient population ranges from 55% to 80% (11,12). Schuessler et al. described the first laparoscopic

pyeloplasty (13). Laparoscopic pyeloplasty offers the advantages of a minimally invasive surgical approach and high success rates associated with open surgery. The reported success rates for laparoscopic pyeloplasty range from 94% to 98% (14,15).

Several authors have reported successfully performing laparoscopic pyeloplasties in horseshoe kidneys (16–20). Bove et al. reported the results of laparoscopic pyeloplasty in 11 patients with upper urinary tract anomalies, including five patients with horseshoe kidneys (16). One of the patients with a horseshoe kidney had previously failed an endopyelotomy. The mean operative time was 3.2 hours and the mean estimated blood loss was 122 mL. No patients required transfusions and there were no operative complications. With a median radiologic follow-up of eight months, all five patients had improvement in renal function on excretory urogram or renal scan.

The medial and ventral location of the ureters in a horseshoe kidney is preferred when performing laparoscopy pyeloplasty.

Although several centers have successfully applied a retroperitoneal approach for horseshoe kidneys when performing extirpative surgery (20–22), the transperitoneal approach provides greater working space for reconstructing the collecting system, which may be dilated and enlarged. However, in select cases a retroperitoneal approach may be feasible. Hsu and Presti reported performing an extraperitoneal laparoscopic pyeloplasty in a horseshoe kidney (19). They used a balloon dilator to extraperitoneally develop 500-mL spaces in multiple directions. The peritoneal sac was bluntly mobilized en bloc to fully expose a dilated left renal pelvis. The surgery time was approximately 6.7 hours. Postoperatively, an excretory urogram was used to document prompt drainage. In both reports, the isthmus was not divided.

Although an isthmectomy is part of the conventional surgery for a ureteropelvic junction obstruction in a horseshoe kidney, these initial reports suggest that the isthmus may be left intact during laparoscopic pyeloplasty.

However, in select cases it may be necessary to divide the isthmus if it contributes to the obstruction at the ureteropelvic junction. Nadler et al. reported performing a hand-assisted laparoscopic pyeloplasty and isthmectomy in a horseshoe kidney (17). Electrocautery was used to score the capsule of the isthmus and the isthmus was divided using an ultrasonic shear. Hemostasis was achieved using manual compression, argon-beam coagulation, thrombin, and fibrin glue. The affected moiety was moved several centimeters laterally before performing the pyeloplasty.

Technique

For patients with horseshoe kidneys, the criteria for diagnosing a ureteropelvic junction obstruction and the indication for surgical intervention are no different than for patients with normally positioned kidneys.

Given the anomalies of the blood supply to the horseshoe kidney, a preoperative angiogram or computed tomography angiogram with three-dimensional volume rendering should be obtained.

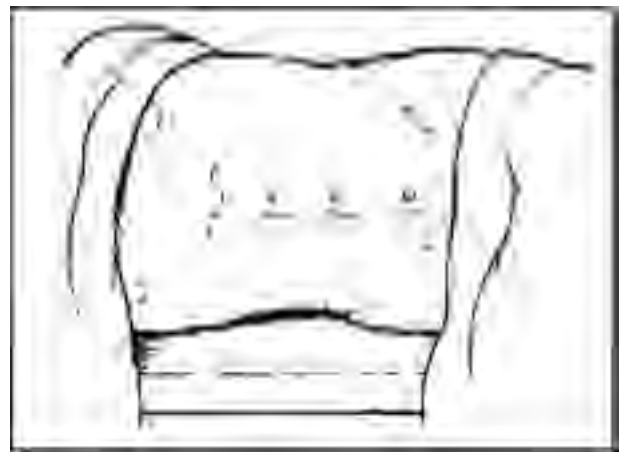
An understanding of the vascular supply is important when mobilizing the horseshoe kidney and dividing the isthmus. Any crossing vessels should be identified and avoided while mobilizing the proximal ureter.

The medial and ventral location of the ureters in a horseshoe kidney is preferred when performing laparoscopy pyeloplasty.

Although an isthmectomy is part of the conventional surgery for a ureteropelvic junction obstruction in a horseshoe kidney, these initial reports suggest that the isthmus may be left intact during laparoscopic pyeloplasty.

Given the anomalies of the blood supply to the horseshoe kidney, a preoperative angiogram or computed tomography angiogram with three-dimensional volume rendering should be obtained.

FIGURE 1 ■ Transperitoneal laparoscopy can be performed using two 12-mm ports and one 5-mm port. The camera is placed through the center port.



Prior to starting the laparoscopic portion of the surgery, flexible cystoscopy is used to place a standard guidewire past the ureteropelvic junction. The guidewire is secured to the Foley catheter in a sterile manner to allow manipulation of the wire by the surgeons during the laparoscopic repair. We prefer to perform the surgery with the patient in a modified flank position using a transperitoneal approach. The surgery can be performed using three midline ports, which include two 12-mm ports and one 5-mm port (Fig. 1). The 5-mm port is the superior-most port and the middle port, used for the camera, is placed through the umbilicus. Depending on the location of the kidney, the three port sites can be adjusted while maintaining the relative position of the three ports.

The colon is reflected medially to expose the kidney and the isthmus.

If a prominent isthmus contributes to the obstruction of the ureteropelvic junction, an isthmectomy should be performed.

To perform the isthmectomy, the isthmus should be separated from the aorta. The involved renal moiety may need to be mobilized to allow the isthmus and aorta to be separated. The isthmus can be divided using electrocautery, ultrasonic shears, or endoscopic staplers. Hemostasis can be achieved at the cut surface using a combination of argon-beam coagulation, fibrin glue, thrombin, cellulose sheet, and intracorporeal sutures.

The involved renal moiety can then be moved several centimeters laterally before performing the ureteropelvic junction repair. However, nephropexy is not necessary (12,23).

A Heineke–Mickulicz repair is well suited for short intrinsic segments of stenosis; a Y–V plasty is well suited in patients with high ureteral insertions. An Anderson–Hynes dismembered pyeloplasty is ideal for patients with a redundant renal pelvis. The ureter and renal pelvis should be transposed over any crossing vessels that may be present. If a renal stone is present, the stone can be removed through the endopyelotomy using a flexible cystoscope and a basket.

The collecting system can be reconstructed using 4-0 Vicryl sutures placed in an interrupted fashion. After performing the posterior half of the ureteropelvic anastomosis, a double-J stent is passed over the previously placed guidewire. The placement of the stent is visually confirmed before completing the anterior portion of the ureteropelvic anastomosis. A surgical drain is placed in the retroperitoneum before repositioning the colon. The drain can be removed on postoperative day one if the drain output remains low following Foley catheter removal. The ureteral stent should be left in place for approximately six weeks.

HEMINEPHRECTOMY

The most common indications for performing a heminephrectomy in a horseshoe kidney are a renal mass and a nonfunctioning moiety, which is usually secondary to a ureteropelvic junction obstruction.

If a prominent isthmus contributes to the obstruction of the ureteropelvic junction, an isthmectomy should be performed.

The involved renal moiety can then be moved several centimeters laterally before performing the ureteropelvic junction repair. However, nephropexy is not necessary.

The most common indications for performing a heminephrectomy in a horseshoe kidney are a renal mass and a nonfunctioning moiety, which is usually secondary to a ureteropelvic junction obstruction.

TABLE 1 ■ Summary of Selected Reports of Extirpative Surgery in Patients with Horseshoe Kidney

	<i>n</i>	Indication for surgery	Division of isthmus or parenchyma	Approach	Angiogram or CTA	Intraoperative ureter guide
Riedl et al. (24)	1	Nonfunction	Endostapler	Transperitoneal	No	Yes
Ao et al. (25)	1	Nonfunction	Electrocautery ^a	Transperitoneal	No	No
Donovan et al. (26)	1	Nonfunction	Endostapler	Transperitoneal	Yes	Yes
Hayakawa et al. (27)	1	Nonfunction	Microwave coagulator	Transperitoneal	No	No
Hemal et al. (20) ^b	2	Nonfunction	Suture ligature ^a	Retroperitoneal	No	No
Yao and Poppas (28) ^b	1	Nonfunction	Ultrasonic shear	Transperitoneal	No	No
Kitamura et al. (22)	1	3.5-cm renal cell carcinoma	Ultrasonic shear and argon coagulator	Retroperitoneal	No	No
Molina and Gill (21)	1	2-cm cystic renal mass	Intracorporeal suturing	Retroperitoneal partial nephrectomy	Yes	Yes

^aThe isthmus divided extracorporeally.
^bIncludes additional patients with anomalous kidneys undergoing laparoscopic nephrectomy.
 Abbreviation: CTA, computed tomography angiogram.

Most reports of laparoscopic heminephrectomy in horseshoe kidneys have been for a nonfunctioning and hydronephrotic renal moiety (Table 1) (20,24–28). There is one report of a heminephrectomy for a 3.5-cm renal cell carcinoma (22) and another report of a partial nephrectomy for a patient with a 2-cm cystic renal mass (21).

When performing an extirpative surgery on a horseshoe kidney, there is no consensus on whether a preoperative angiogram is required or if a ureteral stent should be placed to help identify the ureter during the laparoscopic dissection. Several authors argue that for nonfunctioning kidneys an angiogram is not necessary (20,24,25,27,28). The renal parenchyma is atrophic and the blood supply is minimal. They argue that the magnification provided by laparoscopy makes identification of the vascular supply straightforward.

Laparoscopic heminephrectomy can be performed using a transperitoneal or a retroperitoneal approach, depending on the preference of the surgeon.

When the surgery is being performed for suspected renal cell carcinoma, we feel that the specimen should be extracted intact, using an entrapment bag. A small midline or Pfannenstiel incision can be made. The colon should be repositioned after specimen removal.

If the surgery is performed retroperitoneally, care should be taken to avoid inadvertently opening the thin parietal peritoneum covering the ventral surface of the kidney. Molina and Gill state that when performing a partial nephrectomy in a horseshoe kidney, they prefer a retroperitoneal approach for posterior tumors and a transperitoneal approach for anterior tumors (21). The reported operative times for both retroperitoneal and transperitoneal approaches are approximately 200 to 300 minutes (21,22,25,28).

A variety of techniques have been described for dividing the isthmus (Table 1).

When performing a heminephrectomy for a hydronephrotic, nonfunctioning moiety, the isthmus can be divided extracorporeally (20,25).

A port is placed at the level of the umbilicus, contralateral to the affected side and just off the midline. After the ureter is clipped and the collecting system is decompressed, the port site is extended to approximately 4 cm. The collecting system is then pulled out of the abdomen through the 4-cm incision. Traction is applied extracorporeally as the kidney is mobilized laparoscopically and the blood supply is ligated. The kidney is mobilized to allow the isthmus to be pulled out of the abdomen and be divided extracorporeally.

Molina and Gill make the point that when planning for a partial nephrectomy, a computed tomography scan with three-dimensional volume rendering or an angiogram is crucial (21). A complete understanding of the arterial and venous supply is necessary to achieve vascular control. Molina and Gill report placing an open ended ureteral catheter and injecting dilute methylene blue dye to help identify entry into the collecting system. After repairing the collecting system with 2-0 Vicryl, hemostasis was achieved using a surgical bolster and 0 Vicryl sutures on a CTX needle. The warm ischemia time was 31 minute. The estimated blood loss was 100 mL and the total operative time was 3.3 hours.

Technique

A heminephrectomy may be performed for a nonfunctioning kidney or for a renal mass. We will briefly describe an approach for laparoscopically managing a nonfunctioning moiety of a horseshoe kidney. We feel that for an atrophic kidney with minimal renal parenchyma, a planning angiogram is unnecessary. We prefer to decompress the collecting system at the time of the operation after the kidney is exposed. This avoids the possibility of adhesions resulting from percutaneous drain placement, and the distension of the collecting system facilitates the initial dissection.

For a transperitoneal approach, the port placements are the same as for a laparoscopic pyeloplasty in a horseshoe kidney (Fig. 1). The colon is mobilized medially to expose the kidney. The ureter is identified and ligated between clips. The kidney and isthmus are mobilized and separated from the aorta. The hydronephrotic collecting system is decompressed under direct vision using a percutaneously placed spinal needle. The isthmus can be separated using electrocautery, ultrasonic shears, or an endoscopic stapler. Hemostasis can be achieved at the cut surface using a combination of argon-beam coagulation, manual compression, fibrin glue, thrombin, cellulose sheet, and intracorporeal sutures. Alternatively, the isthmus can be divided using an extracorporeal approach as described above.

Once the affected renal moiety is completely freed, it is placed in an entrapment bag and manually morcellated to allow removal through a 12-mm trocar site.

When the surgery is being performed for suspected renal cell carcinoma, we feel that the specimen should be extracted intact, using an entrapment bag. A small midline or Pfannenstiel incision can be made. The colon should be repositioned after specimen removal.

Laparoscopic heminephrectomy can be performed using a transperitoneal or a retroperitoneal approach, depending on the preference of the surgeon.

When performing a heminephrectomy for a hydronephrotic, nonfunctioning moiety, the isthmus can be divided extracorporeally.

When the surgery is being performed for suspected renal cell carcinoma, we feel that the specimen should be extracted intact, using an entrapment bag. A small midline or Pfannenstiel incision can be made. The colon should be repositioned after specimen removal.

SUMMARY

- Horseshoe kidneys represent the most common renal fusion anomaly.
- Nephrolithiasis, ureteropelvic junction obstructions, and renal masses are the most common indications for surgical intervention in patients with horseshoe kidneys.
- Ureteropelvic junction obstructions and concurrent stones can be treated by laparoscopic pyeloplasty.
- Nonfunctioning renal moiety and renal masses can be managed by laparoscopic heminephrectomy or a laparoscopic partial nephrectomy.

REFERENCES

1. Walsh PC, Retik AB, Vaughan ED, Wein AJ, eds. *Campbell's Urology*. 8th ed. Philadelphia: W.B. Saunders, 2002:1725–1728.
2. Boatman DL, Cornell SH, Kolln CP. The arterial supply of horseshoe kidneys. *Am J Roentgenol Radium Ther Nucl Med* 1971; 113:447.
3. Kolln CP, Boatman DL, Schmidt JD, Flocks RH. Horseshoe kidney: a review of 105 patients. *J Urol* 1972; 107:203.
4. Boatman DL, Kolln CP, Flocks RH. Congenital anomalies associated with horseshoe kidney. *J Urol* 1972; 107:205.
5. Lippe B, Geffner ME, Dietrich RB, Boechat MI, Kangaroo H. Renal malformations in patients with Turner syndrome: imaging in 141 patients. *Pediatrics* 1988; 82:852.
6. Smith DW. Recognizable patterns of human malformation; genetic embryologic and clinical aspects. In: *Major Problems in Clinical Pediatrics*. Vol. 7. Philadelphia: W.B. Saunders, 1970:50.
7. Yohannes P, Smith AD. The endourological management of complications associated with horseshoe kidney. *J Urol* 2002; 168:5.
8. Keeley FX Jr, Bagley DH, Kulp-Hugues D, Gomella LG. Laparoscopic division of crossing vessels at the ureteropelvic junction. *J Endourol* 1996; 10:163.
9. Bellman GC, Yamaguchi R. Special considerations in endopyelotomy in a horseshoe kidney. *Urology* 1996; 47:582.
10. Jabbour ME, Goldfischer ER, Stravodimos KG, Klima WJ, Smith AD. Endopyelotomy for horseshoe and ectopic kidneys. *J Urol* 1998; 160:694.
11. Pitts WR Jr, Muecke EC. Horseshoe kidneys: a 40-year experience. *J Urol* 1975; 113:743.
12. Das S, Amar AD. Ureteropelvic junction obstruction with associated renal anomalies. *J Urol* 1984; 131:872.
13. Schuessler WW, Grune MT, Tecuanhuey LV, Preminger GM. Laparoscopic dismembered pyeloplasty. *J Urol* 1993; 150:1795.
14. Soulie M, Salomon L, Patard JJ, et al. Extraperitoneal laparoscopic pyeloplasty: a multicenter study of 55 procedures. *J Urol* 2001; 166:48.
15. Ben Slama MR, Salomon L, Hoznek A, et al. Extraperitoneal laparoscopic repair of ureteropelvic junction obstruction: initial experience in 15 cases. *Urology* 2000; 56:45.
16. Bove P, Ong AM, Rha KH, Pinto P, Jarrett TW, Kavoussi LR. Laparoscopic management of ureteropelvic junction obstruction in patients with upper urinary tract anomalies. *J Urol* 2004; 171:77.
17. Nadler RB, Thaxton CS, Kim SC. Hand-assisted laparoscopic pyeloplasty and isthmectomy in a patient with a horseshoe kidney. *J Endourol* 2003; 17:909.
18. Janetschek G, Peschel R, Altarac S, Bartsch G. Laparoscopic and retroperitoneoscopic repair of ureteropelvic junction obstruction. *Urology* 1996; 47:311.
19. Hsu TH, Presti JC Jr. Anterior extraperitoneal approach to laparoscopic pyeloplasty in horseshoe kidney: a novel technique. *Urology* 2003; 62:1114.
20. Hemal AK, Aron M, Gupta NP, Seth A, Wadhwa SN. The role of retroperitoneoscopy in the management of renal and adrenal pathology. *BJU Int* 1999; 83:929.
21. Molina WR, Gill IS. Laparoscopic partial nephrectomy in a horseshoe kidney. *J Endourol* 2003; 17:905.
22. Kitamura H, Tanaka T, Miyamoto D, Inomata H, Hatakeyama J. Retroperitoneoscopic nephrectomy of a horseshoe kidney with renal-cell carcinoma. *J Endourol* 2003; 17:907.
23. Culp OS, Winterringer JR. Surgical treatment of horseshoe kidney: comparison of results after various types of operations. *J Urol* 1955; 73:747.
24. Riedl CR, Huebner WA, Schramek P, Pflueger H. Laparoscopic hemi-nephrectomy in a horseshoe kidney. *Br J Urol* 1995; 76:140.
25. Ao T, Uchida T, Egawa S, Iwamura M, Ohori M, Koshiba K. Laparoscopically assisted heminephrectomy of a horseshoe kidney: a case report. *J Urol* 1996; 155:1382.
26. Donovan JF, Cooper CS, Lund GO, Winfield HN. Laparoscopic nephrectomy of a horseshoe kidney. *J Endourol* 1997; 11:181.
27. Hayakawa K, Baba S, Aoyagi T, Ohashi M, Ishikawa H, Hata M. Laparoscopic heminephrectomy of a horseshoe kidney using microwave coagulator. *J Urol* 1999; 161:1559.
28. Yao D, Poppas DP. A clinical series of laparoscopic nephrectomy, nephroureterectomy and heminephroureterectomy in the pediatric population. *J Urol* 2000; 163:1531.

LAPAROSCOPIC BOARI FLAP URETERONEOCYSTOSTOMY AND ILEAL URETER REPLACEMENT

Amr F. Fergany

Section of Oncology, Laparoscopy and Minimally Invasive Surgery, Glickman Urological Institute, Cleveland Clinic Foundation, Cleveland, Ohio, U.S.A.

- LAPAROSCOPIC BOARI FLAP
URETERONEOCYSTOSTOMY
- Introduction and Indications
- Contraindications
- Preparation
- Technique
- Laparoscopic Experience

- LAPAROSCOPIC ILEAL URETER
REPLACEMENT
- Introduction and Indications
- Contraindications
- Preparation
- Technique
- REFERENCES

LAPAROSCOPIC BOARI FLAP URETERONEOCYSTOSTOMY

Introduction and Indications

Bladder flap (Boari flap) reimplantation is a versatile procedure first described experimentally by Boari in 1894 (1), and clinically by Ockerblad in 1947 (2). This is a useful procedure that can be used to bridge lower and middle ureteric defects when the ureter is of inadequate length to reach the urinary bladder but complete ureteric replacement is not required (3). With shorter ureteric defects of the lower ureter, this procedure can be used interchangeably with the psoas hitch procedure. Properly fashioned bladder flaps can easily extend to the middle portion of the ureter and have been reported to reach as high as the renal pelvis (4). The principles of the technique are simple and reliable, and have been readily incorporated into the wide array of laparoscopic procedures currently performed by urologists.

Contraindications

The presence of malignancy within the urinary bladder is a contraindication to bladder flap reimplantation. Neurogenic bladder dysfunction as well as urinary tract infection should be managed preoperatively. Cases of diminished bladder capacity are unsuitable for this procedure because a healthy flap of adequate length cannot be made.

Preoperative cystogram is advisable in all cases to confirm adequate bladder capacity. Adequate studies of the upper tract to localize the site of ureteric obstruction are also essential to allow accurate operative planning prior to the procedure.

Preparation

A clear liquid diet the day before surgery and a light mechanical bowel preparation (such as oral magnesium citrate) are advisable to avoid bowel distention, which can increase the difficulty of the laparoscopic procedure as well as increase the chances of laparoscopic bowel injury.

Technique

The supine or low lithotomy positions both can be used. Intraoperative sterile access to the genitalia is preferred to allow filling of the bladder or exchange of catheters as needed.

The Trendelenburg position is essential to displace the bowel out of the pelvis, and a contralateral lateral tilt to improve access to the surgical side of the pelvis helps as well.

The patient should be adequately padded and secured to allow positioning in this manner for the duration of the procedure without neuromuscular injury. Although the procedure can be performed through an extraperitoneal or transperitoneal approach

The Trendelenburg position is essential to displace the bowel out of the pelvis, and a contralateral lateral tilt to improve access to the surgical side of the pelvis helps as well.

using open surgical technique, laparoscopic Boari flap reimplantation has been performed only transperitoneally so far. The principles of the procedure described in the following section apply to the laparoscopic procedure as much as they do the open surgical procedure.

The procedure starts with identification and mobilization of the ureter preserving the periureteral blood supply. The site of obstruction is confirmed, and a final assessment of the length of ureteric defect is made. The ureter is spatulated and carefully inspected to ensure healthy appearance at the site of transection. Adequate mobilization of the urinary bladder is then performed. This is easiest done with the bladder partially filled to help identify the proper tissue planes. Mobilization should be as complete as possible to allow complete mobility in cases requiring longer flaps.

It is critical to avoid dividing the bladder pedicle on the ipsilateral side of the flap because the vascularity of the flap will depend on that pedicle.

This can complicate cases where a full distal ureterectomy is needed as in lower ureteric tumors. In cases requiring a long flap the contralateral bladder pedicle can be divided, allowing added bladder mobility to the side of the flap.

The flap is oriented obliquely based on the superior vesical artery on the ipsilateral side, with the base of the flap being wider than the tip to ensure good vascularity. In cases requiring very long flaps, a spiral flap encompassing most of the anterior bladder wall can be fashioned. The ureter can be anastomosed to the flap in a direct or in an antirefluxing manner depending on the clinical circumstance, and the flap is rolled upon itself to form a tube of bladder, and the suture line is usually continued over the anterior wall of the bladder, closing the cystotomy. Added security can be obtained by suturing the adventitia of the ureter to the distal flap, and suturing the back of the flap to the psoas fascia.

The bladder flap should be outlined on the anterior surface of the filled bladder before incision into the bladder lumen is started to avoid disorientation after the bladder is emptied. This also allows proper judgment of stretched length of the flap.

Laparoscopic Experience

The bladder flap technique of ureteral reimplantation is a fairly simple technique that was readily applied to the laparoscopic field applying all the previously mentioned principles from open surgery. Fergany et al. (5) described the laparoscopic procedure experimentally in a porcine model, performing direct as well as nonrefluxing anastomoses in six animals. No complications were encountered and anastomoses were all patent at the time of sacrifice. In the clinical arena, Boari flap reimplant was first reported by Fugita et al. in 2001 (6). In this report of three patients with various causes of lower ureteric obstruction, laparoscopic Boari flap reimplant was performed without complication and follow up extending to six months confirmed a successful result. All three reimplantations were performed directly without antireflux techniques, and operative time ranged from 120 to 330 minutes. No surgical complications were reported.

Laparoscopic Boari flap ureteric reimplantation is a procedure that has moved from the experimental into the realm of laparoscopic urologic practice. The principles of open surgery can be duplicated with consistent results with a reasonable amount of laparoscopic suturing experience.

In all reported cases, a three or four port transperitoneal technique was used, and the principles learned from the open surgical procedure were applied. Suturing the bladder flap and bladder closure can be performed using freehand suturing, which is probably easiest, or a suturing device. In our experience freehand suturing in this situation is usually straightforward because of the anterior longitudinal orientation of the suture line facilitating exposure and handling.

LAPAROSCOPIC ILEAL URETER REPLACEMENT

Introduction and Indications

Ileal ureter replacement was first described by Shoemaker in 1906, and has proved to be a reliable procedure for urinary reconstruction (7). Replacement of the ureter with ileum is performed in certain clinical indications where a long segment or the entire length of the ureter needs to be replaced. The only other alternative in these cases is the more complicated renal autotransplantation (8,9).

Indications for ileal ureter replacement include long or multiple ureteric strictures (inflammatory, iatrogenic, radiation, retroperitoneal scarring), multifocal tumors, and repeated episodes of stone passage with pain and obstruction.

It is critical to avoid dividing the bladder pedicle on the ipsilateral side of the flap because the vascularity of the flap will depend on that pedicle.

The bladder flap should be outlined on the anterior surface of the filled bladder before incision into the bladder lumen is started to avoid disorientation after the bladder is emptied. This also allows proper judgment of stretched length of the flap.

Laparoscopic Boari flap ureteric reimplantation is a procedure that has moved from the experimental into the realm of laparoscopic urologic practice. The principles of open surgery can be duplicated with consistent results with a reasonable amount of laparoscopic suturing experience.

Indications for ileal ureter replacement include long or multiple ureteric strictures (inflammatory, iatrogenic, radiation, retroperitoneal scarring), multifocal tumors, and repeated episodes of stone passage with pain and obstruction.

The shortest possible length of ileum should be used to minimize absorption of urinary components and kinking of the ileum. If the proximal ureter is healthy, it can be spared and anastomosed to the proximal part of the ileal loop.

It is generally recommended that segments of bowel not be placed within the urinary tract if the serum creatinine is 2.0 mg/dL or higher. Metabolic complications will occur in more than half of these patients (10).

Ureterectomy is necessary only in cases where a ureteric tumor is diagnosed. A suitable portion of ileum is chosen of sufficient length to span the length of ureteric defect, and of adequate mobility to reach the renal pelvis as well as the urinary bladder.

No tapering of the ileum is needed before reimplantation into the bladder, and no antireflux is needed in most cases.

Ileal ureter replacement is most commonly performed unilaterally, however in cases with bilateral ureteric pathology, a bilateral replacement procedure can be performed with a single loop of small bowel reaching from both renal units to the bladder in an inverted L-fashion.

The shortest possible length of ileum should be used to minimize absorption of urinary components and kinking of the ileum. If the proximal ureter is healthy, it can be spared and anastomosed to the proximal part of the ileal loop.

Healthy distal ureter, however, cannot be used because the ileal peristalsis is not strong enough to pass the urine bolus into distal ureter, and a functional obstruction will result. In other words, the distal extent of the ileum has to be anastomosed to the urinary bladder.

Contraindications

Although ileal ureter replacement can be performed for almost any ureteric pathology, certain conditions of the bowel contraindicate this type of surgery. Among these are short bowel syndrome, inflammatory bowel disease, radiation damage to the bowel, and marked scarring of the mesentery (e.g., desmoid tumors).

Absorption of urinary metabolites occurs across the length of the ileal segment, and normal renal function is essential to avoid systemic metabolic derangement (hyperchloremic metabolic acidosis).

It is generally recommended that segments of bowel not be placed within the urinary tract if the serum creatinine is 2.0 mg/dL or higher. Metabolic complications will occur in more than half of these patients (10).

Even in patients with normal renal function, the shortest length of ileum should be used to minimize absorption. Normal bladder function is an important consideration, and patients with neurogenic bladder dysfunction or decreased bladder capacity or compliance should be managed appropriately before surgery or concomitantly with ileal replacement.

Preparation

A multiday mechanical and chemical bowel preparation for ileal surgery has largely been replaced today by a simplified prep consisting of clear liquids the day before surgery and a mechanical prep taken the night before surgery in the form of 4 L of GoLytely® or until the bowel motions are clear. Antibiotic use can generally be started immediately preoperatively.

Technique

Although the current laparoscopic experience is limited to one case, several important points are necessary during laparoscopic as well as open surgery. Reflection of the ipsilateral colon is the first step in the procedure. This allows exposure of the healthy proximal ureter or renal pelvis in order to estimate the required length of ileum.

Ureterectomy is necessary only in cases where a ureteric tumor is diagnosed. A suitable portion of ileum is chosen of sufficient length to span the length of ureteric defect, and of adequate mobility to reach the renal pelvis as well as the urinary bladder.

Bowel continuity is restored after isolating the ileal segment. The ileal segment is placed in an isoperistaltic direction to avoid functional obstruction. The open end of the ileal segment can be anastomosed to a dilated renal pelvis, to a small renal pelvis opened with an extended pyelotomy into the lower calyx, or even to a dilated lower pole calyx as an ileocalycostomy (11).

Laparoscopic Technique

No tapering of the ileum is needed before reimplantation into the bladder, and no antireflux is needed in most cases.

The urologic literature contains only one description of a laparoscopic ileal ureter replacement (12). The indication for surgery was an upper ureteric tumor in a solitary kidney. The basics of the technique described are the same as the open procedure with certain modifications necessary for the laparoscopic procedure.

In this single case report, the patient was placed in the modified lateral position. A transperitoneal technique was used, which is essential for working with the ileum. The ipsilateral colon was mobilized, and the healthy renal pelvis was identified. The ureter was excised with a bladder cuff, and an appropriate length of ileum was selected. Isolation of the ileal segment and restoration of bowel continuity was performed extracorporeally by

pulling the ileum to the skin surface through a port site. The bowel and the excluded loop were then returned into the abdominal cavity for the ureteroileal and ileovesical anastomosis. With increasing experience in laparoscopic bowel surgery, a completely intracorporeal ileal exclusion and anastomosis can be performed using the endoscopic GIA stapler with similar results. Freehand intracorporeal suturing was used for both ileal anastomoses in this case described in the literature.

As experience with a wide variety of laparoscopic procedures has shown, moving parts of the bowel or the urinary tract from one region of the abdomen to the other and through or underneath bowel mesentery can be particularly challenging. Ideally, an ileal ureter should pass through the sigmoid mesentery to lie retroperitoneally on the left side although on the right side it can be placed caudal to the cecum. In the previously mentioned case, the ileum was placed anterior to the colon (due to scarring from previous surgery) without any apparent ill effects; and with increased experience with this procedure, it will remain to be seen how the placement of the ileum will be performed and how that would affect the surgical outcome.

The operative time reported for this case was eight hours, which is longer than the expected time for open surgery, but the authors correctly point to several factors that could reduce operating time. In this particular case some time was lost mobilizing adhesions from previous surgery. Additional time was lost shortening the excluded ileal segment to the required length laparoscopically as well as placing a double-J stent cystoscopically. They recommend precise measurement of the ileal length and placement of the stent through the ileum before performing the proximal and distal anastomoses as a method to decrease operative time. Follow up in this case was three months at which time the patient was doing well with normal kidney function and without urinary obstruction.

REFERENCES

1. Casati E, Boari A. Contributo sperimentale alla plastica dell'uretere. *Comunicazione preventiva*. *Atti Acad Sci Med Nat* 1894; 14(3):149.
2. Ockerblad NF. Reimplantation of the ureter into the bladder by a flap method. *J Urol* 1947; 57:845.
3. Thompson IM, Ross G. Long term results of bladder flap repair of ureteral injuries. *J Urol* 1974; 111:483.
4. Motiwala HG, Shah SA, Patel SM. Ureteric substitution with Boari bladder flap. *Br J Urol* 1990; 66(4):369–371.
5. Fergany A, Gill IS, Abdel-Samee A, Kaouk J, Meraney A, Sung G. Laparoscopic bladder flap ureteral reimplantation: survival porcine study. *J Urol* 2001; 166(5):1920–1923.
6. Fugita OE, Dinlenc C, Kavoussi L. The laparoscopic Boari flap. *J Urol* 2001; 166(1):51–53.
7. Shoemaker. A critical study of the different principles of surgery that have been used in uretero-intestinal implantation. *Trans Am Assoc Genito-Urin Surg* 1936; 29:15.
8. Boxer RJ, Fritzsche P, Skinner DG, et al. Replacement of the ureter by small intestine: clinical application and results of the ileal ureter in 89 patients. *J Urol* 1979; 121(6):728–731.
9. Benson MC, Ring KS, Olsson CA. Ureteral reconstruction and bypass: experience with ileal interposition, the Boari flap-psoas hitch and renal autotransplantation. *J Urol* 1990; 143(1):20–23.
10. Koch MO, McDougal WS. The pathophysiology of hyperchloremic metabolic acidosis after urinary diversion through intestinal segments. *Surgery* 1985; 98(3):561–570.
11. Mesrobian HG, Kelalis PP. Ureterocalicostomy: indications and results in 21 patients. *J Urol* 1989; 142(5):1285–1287.
12. Gill IS, Savage SJ, Senagore AJ, Sung GT. *J Urol* 2000; 163(4):1199–1202.

TRANSVESICAL LAPAROSCOPIC BLADDER DIVERTICULECTOMY

Vito Pansadoro

Vincenzo Pansadoro Foundation, Rome, Italy

- INTRODUCTION
- HISTORY OF LAPAROSCOPIC DIVERTICULECTOMY
- INDICATIONS AND CONTRAINDICATIONS
- SURGICAL TECHNIQUE
- CURRENT DATA FROM THE LITERATURE
- COMPLICATIONS
- ADVANTAGES AND DISADVANTAGES
- SUMMARY
- REFERENCES

INTRODUCTION

Bladder diverticulum, a herniation of the bladder mucosa, occurs through a weak point of a hypertrophied muscular wall caused by bladder outlet obstruction. Bladder diverticula can be congenital but, more frequently, are acquired. The diverticulum wall includes an inner mucosal layer and an outer fibrous reactive layer. In 1922 Geraghty demonstrated that removing the mucosal layer was sufficient to obliterate the cavity delimited by the fibrous layer.

The surgical approach can be extraperitoneal, transperitoneal, or transvesical. The transvesical laparoscopic removal of the inner mucosal layer, followed by intracorporeal suturing of diverticulum neck represents a definite advantage, with a very limited trauma to the patient.

HISTORY OF LAPAROSCOPIC DIVERTICULECTOMY

The first report about laparoscopic bladder diverticulectomy dates back to 1992 when Raul Parra (3) reported the first case. The case was done transperitoneally and the opening in the bladder wall was closed with two successive firings of endostaplers under transurethral endoscopic control. In the following years a few other reports of anecdotal cases have been reported and the surgical technique was always transperitoneal.

In 1994 Nadler and Clayman (7) reported the first extraperitoneal laparoscopic diverticulectomy using a technique popularized years later for the extraperitoneal approach for laparoscopic radical prostatectomy.

Iselin (9) in 1996 and Porpiglia (12) in 2002 addressed the problem of the timing of transurethral resection of the prostate and transperitoneal diverticulectomy stating, although with a limited number of patients, that the two procedures could safely be performed in the same setting. The literature shows that laparoscopic bladder diverticulectomy can easily be performed, either through the transperitoneal or extraperitoneal approach, but the limited number of patients with this pathology does not allow to have significant data.

INDICATIONS AND CONTRAINDICATIONS

Indications are limited to diverticula over 4–5 cm in diameter because diverticula of smaller size can easily be treated through the urethra with a resectoscope. Other indications are persistent urinary infection, large postvoid residual, presence of calculi inside the diverticulum and interference with ureteral drainage. Bladder outlet obstruction should be treated before or at the same time of the diverticulectomy. Proximity to the ureteral meatus is not a limitation. In fact laparoscopy enables better view of these structures. Small bladder capacity can be a limiting factor and the indication in these

cases should be postponed after resolution of the outlet obstruction. Diverticula positioned on the dome and multiple diverticula are a contraindication as it is the presence of neoplasm and vesicoureteral reflux.

Preoperative computed tomography is recommended for posterior and trigonal diverticula and for evaluation of upper tract.

SURGICAL TECHNIQUE

With the patient in general anesthesia a cystoscope is introduced in the bladder, which is distended with saline at his/her maximum capacity. The diverticulum's ostium and its relationship with the ureters are evaluated. Under ultrasound and endoscopic control three spinal needles are introduced in the bladder and then substituted with three Entec^a 5 mm trocars, with a self-retaining balloon (Fig. 1). Combination of ultrasound and endoscopic control will ensure the appropriate placement of the three trocars avoiding perforation of the peritoneal cavity. The trocar, which will be used for the 0° 5 mm optic is introduced on the abdominal midline and the remaining two on the opposite side of the diverticulum with the axis forming a 90° angle. The use of the Entec trocars, with a self-retaining balloon, allows to fix the bladder dome to the abdominal wall thus avoiding the possibility of losing the bladder in case a deflation occurs (Fig. 2). Care must be taken during this delicate maneuver because if a hole in the bladder is accidentally caused the whole procedure cannot be performed. In fact the bladder cannot be distended anymore and the trocars cannot be introduced.

Water is then substituted with air, laparoscopic forceps and a hook are introduced in the trocars, and the diverticulum orifice is circumscribed. The cleavage plan between mucosa and the fibrous layer is easily developed using a monopolar hook (Fig. 2). Once completely released from the reactive capsule, the intact diverticulum is recovered from the bladder through a transurethral 24 Ch sheath of a resectoscope and a biopsy forceps.

A small 8 French Redon drainage is introduced in the bladder through one of the trocars. At the same time, through an extravesical separate stab wound, a Kelly clamp is introduced in the residual cavity. Using a forceps, introduced through the other trocar, the drainage is positioned in the residual cavity and extracted with the Kelly clamp.

The defect in the bladder wall is sutured with two running sutures, Vicryl 3-0 for the muscle and Vicryl 5-0 for the mucosa. Using a half sheath of a Korth cannula, introduced on a guidewire through the trocars these are substituted with three Foley catheters 14 Ch.

In case of a small prostate a transurethral resection of the prostate is performed in the same setting thanks to the drainage of the three Foley catheters. If the prostate is large the transurethral resection of the prostate is postponed for one week. The suprapubic

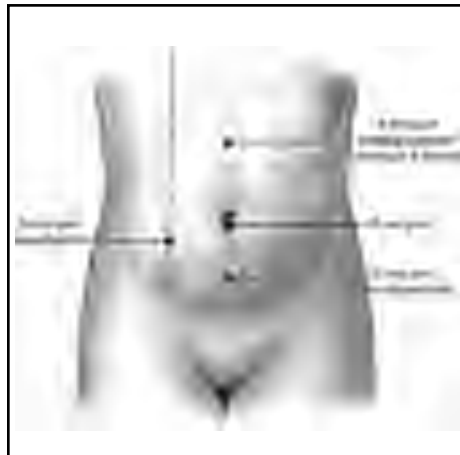


FIGURE 1 ■ Pointed trocar with a self-retaining balloon and stopper.

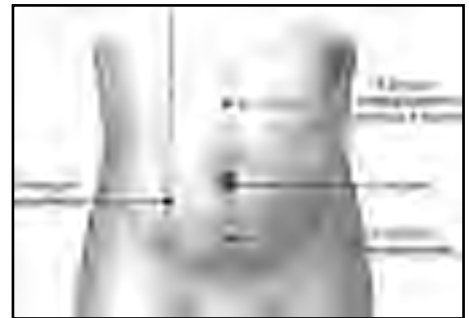

FIGURE 2 ■ Trocars in place fixing the bladder dome to the abdominal wall.

^aIncision Medical, Brisbane, Australia.

Foley catheters and drainage are removed after 48 hours and urethral catheter 24 hours later. Patients are dismissed the day after.

CURRENT DATA FROM THE LITERATURE

Altogether the number of cases reported in the literature is still very limited with a definite preference for the transperitoneal approach as opposed to the extraperitoneal approach (27 vs. 1). No reports are yet available on the transvesical approach.

COMPLICATIONS

Persistent leakage may occur due, most of the time, to a bladder outlet obstruction. In case of a urinary infection an abscess may occur in the residual cavity.

Ureteral involvement secondary to the suture of the diverticulum neck can be the cause of idronephrosis. Rectal injury is rare and might occur with trigonal and posterior diverticula.

ADVANTAGES AND DISADVANTAGES

The main advantage is the minimal trauma compared to sometimes difficult and complicated procedures for trigonal and posterior diverticula.

The disadvantage is the necessity of two operations if the outlet obstruction cannot be treated at the same time as the diverticulectomy.

SUMMARY

- Transvesical laparoscopic diverticulectomy is an anatomical procedure with a minimal trauma to patients eliminating the need of an open procedure either transperitoneal or extraperitoneal.
- The bladder outlet obstruction, if secondary to a large prostatic hypertrophy, requires a second operation that is a small price to pay, especially in complicated and large posterior diverticula which need a transperitoneal approach.

REFERENCES

1. Orandi A. Transurethral fulguration of bladder diverticulum: new procedure. *Urology* 1977; 10:30.
2. Vitale PJ, Woodside JR. Management of bladder diverticula by transurethral resection: re-evaluation of an old technique. *J Urol* 1979; 122:744.
3. Parra RO, Jones JP, Andrus CH, Hagoor PG. Laparoscopic diverticulectomy: preliminary report of a new approach for the treatment of bladder diverticulum. *J Urol* 1992; 148:869–871.
4. Das S. Laparoscopic removal of bladder diverticulum. *J Urol* 1992; 148:1837–1839.
5. Gill IS, Kerbl K, Clayman RV. Laparoscopic surgery in urology: current application. *Am J Roentgenol* 1993; 160(6):1167–1170.
6. Jarrett TW, Pardalidis NP, Sweetser P, Badlani GH, Smith AD. Laparoscopic trans peritoneal bladder diverticulectomy: surgical technique. *J Laparoendosc Surg* 1995; 5(2):105–111.
7. Nadler RB, Pearle MS, McDougall EM, Clayman RV. Laparoscopic extraperitoneal bladder diverticulectomy: initial experience. *Urology* 1995; 45:524–527.
8. Zanetti G, Trinchieri A, Montanari E, et al. Bladder laparoscopic surgery. *Ann Urol (Paris)* 1995; 29(2):97–100.
9. Iselin CE, Winfield HN, Rohner S, Graber P. Sequential laparoscopic bladder diverticulectomy and transurethral resection of the prostate. *J Endourol* 1996; 10(6):545–549.
10. Anderson KR, Clayman RV. Laparoscopic lower urinary tract reconstruction. *World J Urol* 2000; 18(5):349–354.
11. Fukatsu A, Okamura K, Nishimura T, Ono Y, Ohshima S. Laparoscopic extraperitoneal bladder diverticulectomy: an initial case report. *Nippon Hinyokika Gakkai Zasshi* 2001; 92(6):636–639.
12. Porpiglia F, Tarabuzzi R, Cossu M, et al. Sequential TurP and laparoscopic bladder diverticulectomy: comparison with open surgery. *Urology* 2002; 60(6):1045–1049.
13. Khonsari S, Lee DI, Basillote JB, McDougall EM, Clayman RV. Intraoperative catheter management during laparoscopic excision of a giant bladder diverticulum. *J Laparoendosc Adv Surg Tech A* 2004; 14(1):47–50.
14. Porpiglia F, Tarabuzzi R, Cossu M, et al. Is laparoscopic bladder diverticulectomy after transurethral resection of the prostate safe and effective? Comparison with open surgery. *J Endourol* 2004; 48(1):73–76.
15. Faramarzi-Roques R, Calvet C, Gateau T, Ballanger PH. Surgical treatment of bladder diverticula: laparoscopic approach. *J Endourol* 2004; 48(1):69–72.

LAPAROSCOPIC SIMPLE PROSTATECTOMY

Rene Sotelo Noguera and Alejandro Garcia-Segui

Section of Laparoscopic and Minimally Invasive Surgery, Department of Urology, "La Floresta" Medical Institute, Caracas, Venezuela

- INTRODUCTION
- PATIENT SELECTION
- PREOPERATIVE PREPARATION
- LAPAROSCOPIC TECHNIQUE

- Step 1: Patient Positioning
- Step 2: Creation of the Preperitoneal Space
- Step 3: Trocar Placement
- Step 4: Transverse Cystotomy
- Step 5: Retraction of the Median Lobe
- Step 6: Development of the Subcapsular Plane

Step 7: Prostatic Adenomectomy

Step 8: Trigonization of the Prostatic Fossa

Step 9: Suture Repair of the Cystotomy

- TECHNICAL MODIFICATIONS
- PROS AND CONS OF VARIOUS TECHNIQUES
- TECHNICAL CAVEATS AND TIPS
- SPECIFIC MEASURES TAKEN TO PREVENT COMPLICATIONS
- REFERENCES

Open surgery has traditionally been the treatment of choice for benign, symptomatic, large size prostatomegaly.

Size of the prostate gland is an important consideration to select the appropriate surgical approach for the individual patient with symptomatic benign prostatic hypertrophy.

- Transurethral incision of prostate is efficacious for glands up to 30 cc in size.
- Transurethral resection of the prostate is the long-established gold standard surgical procedure for the medium-sized adenomas.
- Glands larger than 80–100 g may be better managed with open simple retropubic prostatectomy, especially in the presence of coexisting pathology, such as large vesical diverticulum, large/multiple bladder calculi, or severe hip ankylosis contraindicating a lithotomy position.

INTRODUCTION

Open surgery has traditionally been the treatment of choice for benign, symptomatic, large size prostatomegaly (1).

First described in 1945 by Millin (2), retropubic simple prostatectomy achieves complete enucleation of the prostate adenoma through a transverse capsulotomy incision on the anterior surface of the prostate gland. Subsequently, transurethral endoscopic techniques have virtually replaced the open approach in the surgical management of benign prostatic hypertrophy (3–5). Recent modifications of the gold standard transurethral resection (transurethral resection of the prostate) include transurethral needle ablation, thermotherapy, and holmium or “green light” laser enucleation. In general, these techniques are applied for small to moderate sized benign prostatic hypertrophy. More recently, the holmium laser has been employed for “giant” prostatomegaly, even in excess of 100 g (6,7). Nevertheless, at many centers, open prostatectomy remains the technique of choice for the majority of patients with hugely enlarged benign prostatic hypertrophy (8,9).

The size of the prostate gland is an important consideration to select the appropriate surgical approach for the individual patient with symptomatic benign prostatic hypertrophy:

- Transurethral incision of prostate is efficacious for glands up to 30 cc in size (8).
- Transurethral resection of the prostate is the long-established gold standard surgical procedure for the medium-sized adenomas.
- Glands larger than 80–100 g may be better managed with open simple retropubic prostatectomy, especially in the presence of coexisting pathology, such as large vesical diverticulum, large/multiple bladder calculi, or severe hip ankylosis contraindicating a lithotomy position (9).

Operative morbidity of transurethral resection of the prostate increases when performed for prostatic adenoma larger than 45 g, in procedures lasting more than 90 minutes, or patients older than 80 years or with prior history of acute urinary retention (10,11).

A meta-analysis of the literature concluded that open prostatectomy is the most effective method for improving the symptoms of an obstruction caused by benign prostatic hyperplasia, despite being an invasive and expensive procedure. This obstruction is corrected by completely removing the adenoma and this is what guarantees the favorable results (11,12).

Considering that improvement of the obstructive symptoms is related to the amount of tissue that has been extracted and that transurethral resection of the prostate may be unable to extract large enough volumes in the case of large prostates (12), transvesical prostatectomy indeed improves obstructive symptoms efficiently. Newer transurethral techniques have been devised and developed to excise the largest possible amount of prostatic tissue. The use of the Holmium laser for this purpose has paved the way for the application of this principle (13,14). Using this technique, the adenoma is precisely dissected from the surgical capsule in the cleavage plane between the adenoma and the capsule in a retrograde direction. Hemostasis is achieved at the bleeding points with the wavelength of the laser beam. The resected fragments are deposited in the bladder, from where they are finally extracted with a transurethral morcellator (7,13–16).

The results of randomized prospective studies comparing transvesical prostate adenomectomy and transurethral prostate enucleation using Holmium laser evidenced a similarly significant improvement in the maximum urinary flow and in the volume of residual urine, as measured using the American Urology Association symptom score. Although surgical time was significantly longer in the Holmium group, blood loss, length of catheterization, and hospital stay were significantly shorter. The volume of extracted tissue was similar in both groups (6,7,15,16).

Persistence of the irritative symptoms due to the presence of residual, heat-damaged prostate tissue occurs more frequently after minimally invasive procedures (11). Chen et al. showed that the reduction of the prostate volume after transurethral resection of the prostate proportionally correlates to the rates of American Urology Association symptomatic score improvement (17). However, as shown by Roehrborn et al. in a cooperative study on the guidelines for the diagnosis and treatment of benign prostatic hypertrophy, the average resected tissue was only 22 g (1). Further, in a comparison between transurethral resection of the prostate and Holmium laser performed by Gilling et al., the estimated resected specimen weight was 15.5 and 21.7 g, respectively (14).

Indications for the laparoscopic surgery are constantly growing and expanding. Indeed, the benefits of this approach, including lower morbidity, limited pain, shorter hospital stay, and earlier return to normal working activities, have been largely proven. Thus, laparoscopic retropubic prostatectomy has the potential to combine the advantages of the minimally invasive techniques with the favorable results of open surgery.

Mariano et al. first reported laparoscopic simple prostatectomy performed in a patient with benign prostatic hypertrophy. A total of four hemostatic sutures were used for vascular control (18). Baumert et al. performed laparoscopic simple prostatectomy in 20 patients (19). van Velthoven et al. reported their initial experience with laparoscopic extraperitoneal Millin's prostatectomy in 18 patients (20). Nadler et al. recently reported preperitoneal laparoscopic approach for resection of a large prostatic adenoma in one patient (21). Sotelo et al. described their technique of laparoscopic simple retropubic prostatectomy in 17 patients with symptomatic significant prostatomegaly (≥ 60 g on transrectal ultrasonography, mean 93 g) (22).

PATIENT SELECTION

Indications for laparoscopic simple retropubic prostatectomy for benign prostatic hypertrophy are listed in Table 1 (9). Table 2 shows relative and absolute contraindications for laparoscopic simple retropubic prostatectomy.

PREOPERATIVE PREPARATION

The patient should always be informed on the potential for open conversion should technical difficulties or complications not readily manageable by laparoscopic occur. The patient should also be advised of alternatives (open or transurethral surgery). Informed consent must be obtained.

TABLE 1 ■ Indications

Patients with symptomatic BPH with TRUS estimated gland weight of 60 g or more
Patients with obstructive prostatomegaly and associated surgical pathology such as multiple or large bladder calculi, inguinal hernia, large diverticula, a severe ankylosis of the hip that impairs the position of the patient that is required for transurethral resection
<i>Abbreviations:</i> BPH, benign prostatic hypertrophy; TRUS, transrectal ultrasound.

TABLE 2 ■ Relative and Absolute Contraindications*Relative contraindications*

Gross obesity
 Significant previous intraperitoneal or preperitoneal surgery
 Abdominal wall infection
 Bowel obstruction

Absolute contraindications

Uncorrectable coagulopathy
 Cardiopulmonary contraindication
 Severe obstructive airway disease
 Morbid obesity

TABLE 3 ■ Preoperative Evaluation

History—physical examination
 Routine laboratory test
 PSA
 IPSS and QoL
 Uroflowmetry
 TRUS

Abbreviations: IPSS and QoL, International Prostate Symptom Score and Quality of Life questionnaires; TRUS, transrectal ultrasound; PSA, prostate specific antigen.

As part of the preoperative workup, all patients should have a complete history and physical examination. Preoperative evaluation includes digital rectal exam, routine laboratory tests including prostate specific antigen, International Prostate Symptom Score and Quality of Life questionnaires, Uroflowmetry, and transrectal ultrasonography with measurement of prostate volume. Blood typing and cross-match should be performed (Table 3). Preoperative preparation is listed in Table 4.

LAPAROSCOPIC TECHNIQUE

The laparoscopic technique comprises nine steps as listed in Table 5.

Step 1: Patient Positioning

In the operating room, the patient is placed in the supine and modified Trendelenburg position. Pneumatic boots are placed on the lower extremities to prevent deep vein thrombosis. The arms are padded and tucked in by the patient's sides. General anesthesia is administered, and an indwelling urethral catheter is placed for bladder decompression.

Step 2: Creation of the Preperitoneal Space

A 1.5 cm subumbilical vertical incision is made, and extended to reach the preperitoneal fat. The index finger of the right hand is inserted, and digital dissection of the preperitoneal space is performed until the pubis is reached. To complete the dissection, a balloon device may be inflated in the preperitoneal space (20–22).

Subsequently, a 10-mm Hassan trocar is inserted in this space, CO₂ is insufflated at a pressure of 15 mmHg, and then a 10 mm, 0° scope is inserted.

Step 3: Trocar Placement

The preperitoneal space is further expanded under direct visualization. After identification of the left anterior–superior iliac spine, a 5 mm port is placed 2 cm medial to this bony landmark. A 5 mm trocar is placed on the left pararectal line, 1–2 cm caudal to an imaginary line extending from the umbilicus to the left anterior–superior iliac spine. In a similar manner, two additional ports are inserted in the contra lateral side of the abdomen. Overall, the port placement duplicates laparoscopic entry during extraperitoneal laparoscopic radical prostatectomy (Fig. 1) (23).

TABLE 4 ■ Preoperative Preparation

Bowel preparation is not routinely performed; but a clear liquid diet is advised for the day prior to the surgery and a bisacodyl suppository the night before surgery
 Aspirin and other nonsteroidal analgesic or anticoagulants are discontinued one week before surgery
 Low dose subcutaneous heparin low molecular weight in patients at high risk for deep vein thrombosis
 Intravenous quinolones (Ciprofloxacin) is administered for antibiotic prophylaxis

TABLE 5 ■ Technical Steps for Laparoscopic Simple Prostatectomy

Patient positioning
 Creation of the preperitoneal space
 Placement of the tracers
 Transverse cystotomy
 Retraction of the medial lobe
 Development of subcapsular plane
 Prostatic adenomectomy
 Trigonization of the prostatic fossa
 Suture repair of the cystotomy

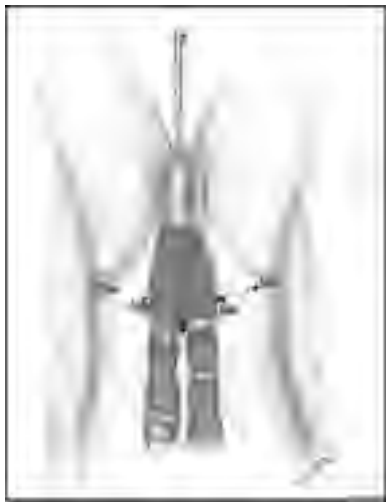

FIGURE 1 ■ Trocar placement in the preperitoneal space.

The space of Retzius is entered and the anterior surface of the prostate capsule is cleared of the overlying fatty tissue. The superficial dorsal vein on the anterior aspect of the prostate is carefully coagulated with the harmonic scalpel.

Step 4: Transverse Cystotomy

A transverse cystotomy is performed 1–2 cm proximal to the junction between the bladder and the prostate using harmonic scalpel or J-hook electrocautery. In this manner, the anterior bladder neck is incised and entry into the bladder lumen is gained. The bulging prostate, with or without median lobe, is now visualized.

Step 5: Retraction of the Median Lobe

If a large bulging median lobe is present, it can be efficaciously retracted anteriorly with a figure-of-eight stitch placed with either a Keith needle or a Carter–Thomason port-closure needle device. Both ends of the stitch are retrieved and anchored to outside the anterior abdominal wall (Fig. 2).

Step 6: Development of the Subcapsular Plane

A transverse (horizontal) incision is made on the bladder mucosa overlying the prostate lobes in the vicinity of the bladder neck area. This semicircular mucosal incision, extending from the 8 o'clock to the 6 o'clock and further extended to the 4 o'clock position, is deepened until the prostate adenoma is identified. Careful blunt and electrocautery dissection is performed to reach the proper subcapsular plane outside the prostate adenoma (Fig. 3).

Step 7: Prostatic Adenomectomy

Semicircular movements using the J-hook electrocautery, harmonic scissors, or the suction-irrigation cannula progressively free the adenoma from the internal surface of the prostate capsule. At this point, the initial mucosal incision is completed circumferentially. The left lateral lobe is dissected first, with the dissection proceeding distally in a largely avascular plane. Simultaneously, one assistant aspirates and countertracts this region with the suction cannula. This enables the surgeon to clearly visualize and further develop the cleavage plane between the adenoma and the capsule. Hemostasis is secured continuously with electrocautery or harmonic scalpel by controlling any perforating tethering blood vessels. Large volume prostate adenomas are divided and extracted piecemeal. Specific care is taken at the prostate apex at its point of transection from the urethra to avoid injury to the external sphincter and possible avulsion (Figs. 4–6).

Every attempt is made to maintain good hemostasis constantly during dissection, such that enucleation proceeds under clear visualization. Adequate control of the main prostatic vessels can be achieved with either the harmonic scalpel and/or hemostatic figure-of-eight sutures placed at 4 and 8 o'clock position at the bladder neck. The contralateral lobe of the prostate is enucleated in a similar manner.

Step 8: Trigonization of the Prostatic Fossa

Whenever there is a redundant or hypermobile incised edge of bladder neck mucosa, it is suture approximated to the floor of the prostatic fossa or to the posterior wall of the urethra in an attempt to trigonize the fossa (Fig. 7).

Step 9: Suture Repair of the Cystotomy

Once enucleation is completed and adequate hemostasis is obtained, a 22 to 24 French Foley catheter is inserted and its balloon inflated to 25–30 cc. The transverse cystotomy incision is closed in a watertight manner with a running 2-0 Vicryl stitch on a CT-1 needle. Bladder irrigation with saline solution is performed to assess watertightness of the incision. A Jackson–Pratt drain is inserted, the specimen is entrapped and extracted, and laparoscopic exit completed (Fig. 8).

TECHNICAL MODIFICATIONS

Mariano et al. performed an intraperitoneal technique in one patient (18). The prostatic capsule and the bladder neck were opened in the midline. Two hemostatic sutures of 2-0 polyglactin were used to control the dorsal vein complex and the puboprostatic liga-

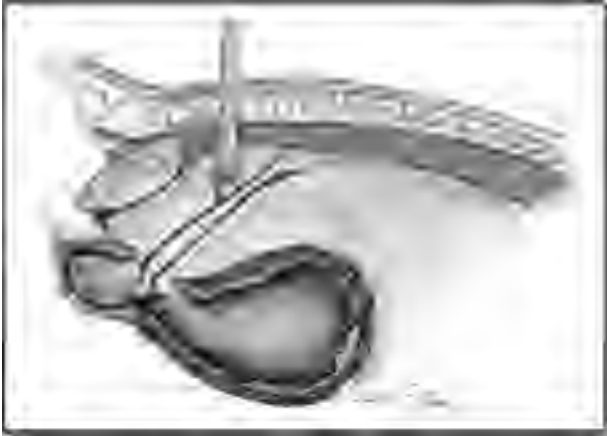

FIGURE 2 ■ Retraction of the medial lobe with the Carter-Thomason port-closure device. The stitch is retrieved and anchored outside the abdominal wall.

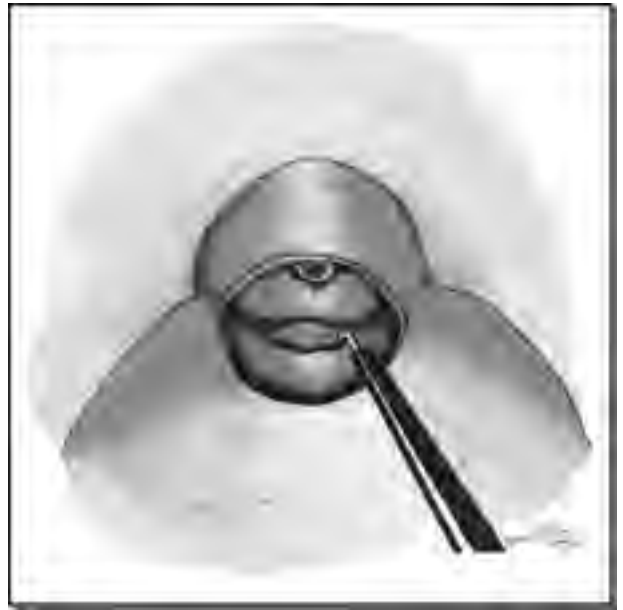

FIGURE 3 ■ Developing the subcapsular plane with a transverse incision made back on the bladder mucosa overlying the prostate lobes in the vicinity of the bladder neck.

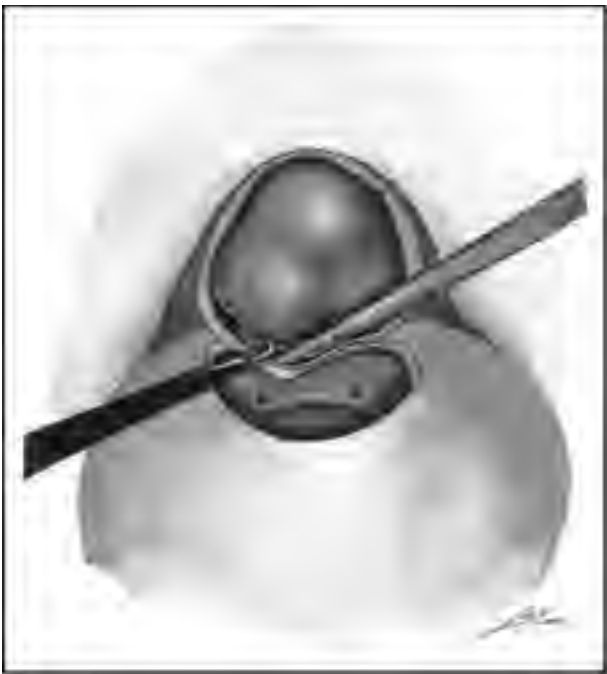

FIGURE 4 ■ The left lobe of the adenoma is being enucleated using a combination of J-hook electrocautery and blunt dissection with suction cannula.

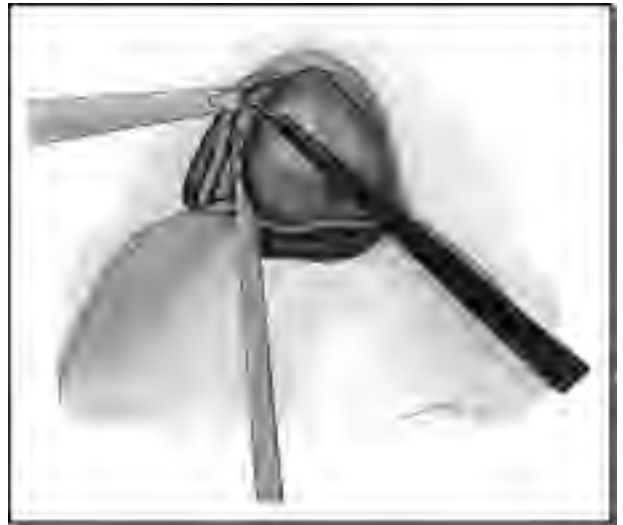
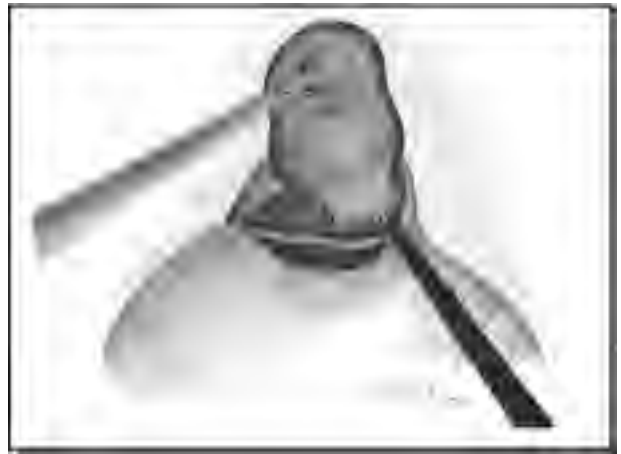
FIGURE 5 ■ The adenoma enucleation is continued.

ments, and two additional sutures were placed to secure the lateral pedicles of the prostate (near the bladder neck). Blood loss was 800 cc, and operative time was 3.8 hours.

van Velthoven et al. reported their initial experience with laparoscopic extraperitoneal Millin's prostatectomy in 18 patients (20). Their technique, which included hemostatic control of lateral venous vesicoprostatic pedicles, transverse

FIGURE 6 ■ The adenoma enucleation is completed.



anterior incision of the prostate capsule, adenoma enucleation, and reconstruction of the posterior bladder neck and prostate capsule, is similar to the original technique described by Millin (2). In their series, mean operative time was 2.4 hours, and mean blood loss 192 cc.

An important technical modification by the authors consists of a transverse cystotomy incision proximal to the junction between the bladder and the prostate, instead of incising the prostate capsule itself. This cystotomy is created by using a harmonic scalpel or J-hook electrocautery. In our early cases, we attempted various technical maneuvers to minimize intraoperative hemorrhage, such as suture ligation of the dorsal vein complex after incising the endopelvic fascia, and extravesical suture ligation of the lateral prostate pedicles bilaterally. Later, a transverse or longitudinal anterior capsulotomy of the prostate gland was attempted. In our experience, none of these maneuvers reliably provided a bloodless field. In fact, it is now our impression that performing a capsulotomy directly over the anterior surface of the prostate gland may transgress the subcapsular venous plexus, contributing to increased blood loss. Incising the bladder neck just proximal cephalad to the prostatovesical junction to gain entry into the urinary bladder, thereafter entering the subcapsular plane posteriorly and posterolaterally, and its subsequent circumferential development is effective in decreasing blood loss.

Several maneuvers had been described to facilitate the enucleation of the adenoma. Njinou Ngninkeu et al. described an extraperitoneal laparoscopic prostatic adenomectomy assisted by the index finger inserted through the abdominal wall for digital enucleation of the adenoma after the removal of the medial port and a 2-cm enlargement of the port (24). Nadler et al. used a fan retractor and laparoscopic shears to enucleate the adenoma (21). We perform the enucleation with the "Sotelo Prostatotome," a device designed by the senior author. It is similar to a curette or an osteotome and facilitates the enucleation of the adenoma during laparoscopic simple prostatectomy. Its metallic, curvilinear tip with a sharp cold-knife on the distal side of the forceps divides the adherence between the adenoma and its capsule during circumferential dissection of the gland (Fig. 9; Tables 6 and 7).

PROS AND CONS OF VARIOUS TECHNIQUES

Compared to open surgery, all laparoscopic techniques mentioned above have limitations, including a steep learning curve and the requirement of significant laparoscopic expertise. In all the reported series, operative time was significantly longer than the conventional open surgical adenomectomy. Compared to open surgery, laparoscopic techniques may result in decreased blood loss, shorter hospital stay, shorter postoperative length of catheterization (range 3–10 days), less postoperative pain, lower morbidity, and shorter convalescence. The ability to precisely transect the prostate adenoma at its apex under magnified laparoscopic visualization, while maintaining the integrity of the sphincteric zone of the membranous urethra, is superior compared to open surgery. Unlike open surgery, the surgeon does not insert the index finger in the open capsule nor are any intravesical retractors placed, thus decreasing the risk of capsular trauma and potential capsular avulsion (18–21).

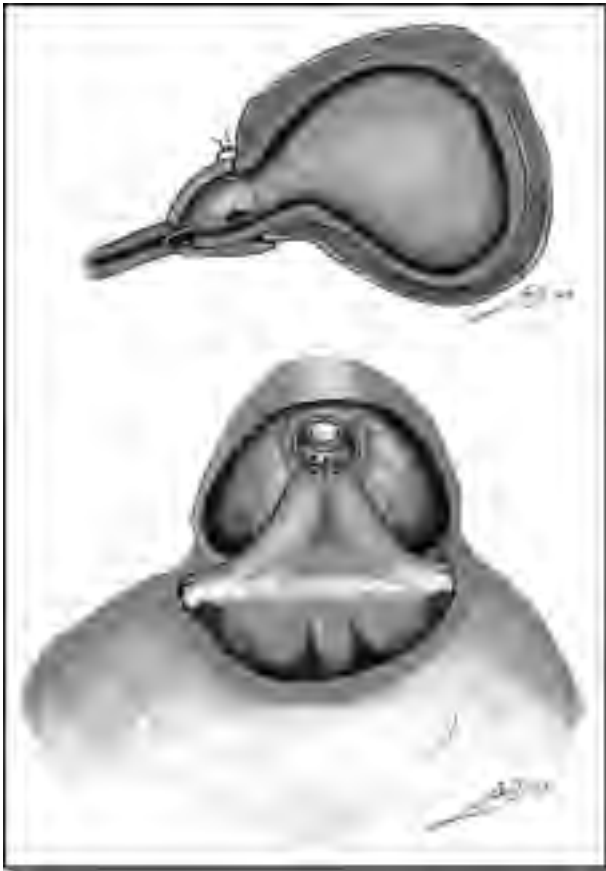


FIGURE 7 ■ Trigonization. The trigone is advanced into the floor of the prostate fossa or into the posterior wall of the urethra.

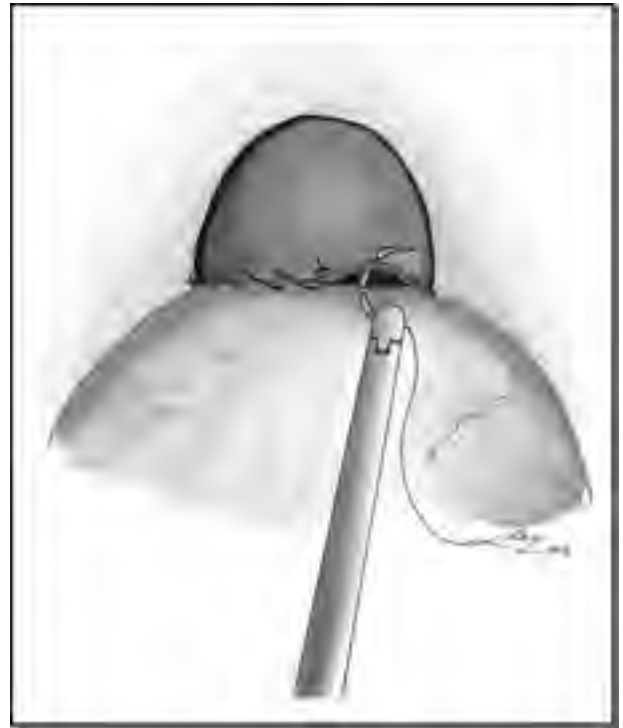


FIGURE 8 ■ The prostate capsule is suture approximated anteriorly.

Bladder entry also allows the concomitant management of any coexistent intravesical disease such as bladder calculi. A benefit of this technique, similar to open surgery, is the nearly complete removal of the entire adenoma thus achieving complete clearance of the obstructive symptoms. Complications of transurethral surgery, such as the transurethral resection syndrome, which occur due to prolonged resection times frequently noted with the larger glands do not occur during laparoscopic simple prostatectomy.

Advantages of the technique proposed by van Velthoven's include its preperitoneal nature, the relatively short operative time (2.4 hours), and limited blood loss (192 mL). However, it is our feeling that a direct capsulotomy over the anterior surface of the prostate gland potentially transgresses the subcapsular venous plexus and contributes to increased blood loss. In van Velthoven's series, the average specimen weight of the excised prostate was equal to only 50% of the gland weight estimated on preoperative transrectal ultrasonography (20).

We described an extraperitoneal technique for laparoscopic simple prostatectomy in 17 patients. Blood loss was 516 mL, operative time 156 minutes, and average specimen weight was 72 g, representing 77% of the preoperative transrectal ultrasonography estimated weight.

TECHNICAL CAVEATS AND TIPS

An important technical caveat is that subcapsular dissection should proceed in close contact with the whitish surface of the prostatic adenoma, with this plane being further developed bluntly with a combination of J-hook electrocautery, harmonic scalpel, Sotelo prostatome, or suction-irrigation cannula tip. Small vessels entering the adenoma can thus be precisely identified and electrocoagulated.



FIGURE 9 ■ The prostatotome. A metallic curvilinear-tip laparoscopic instrument with a sharp cold-knife in the distal side of the forceps to facilitate the enucleation of the adenoma.

TABLE 6 ■ Laparoscopic Simple Prostatectomy: Literature Review

Title	Author	Reference
Laparoscopic retropubic simple prostatectomy-	Sotelo et al.	(22)
Laparoscopic prostatectomy with vascular control for BPH	Mariano et al.	(18)
Laparoscopic extraperitoneal adenectomy (Millin) pilot study on feasibility	van Velthoven et al.	(20)
Preperitoneal laparoscopic simple prostatectomy	Nadler et al.	(21)
Laparoscopic simple prostatectomy	Baumert et al.	(19)
Novedosa técnica para la creación del espacio prevesical en el abordaje extraperitoneal durante la cirugía laparoscópica de próstata	Sotelo et al.	(23)
Retropubic prostatectomy	Millin	(2)

Abbreviation: BPH, benign prostatic hypertrophy.

TABLE 7 ■ Comparison of Series Results and Case Reports of Laparoscopic Simple Prostatectomy

Authors	No. of patients	Bloodloss (cc)	Operative time (min)	Hospital stay	Mean weight specimen (g)	Foley duration	AUA score preoperative	AUA score postoperative	Uroflow (Q_{max}) preoperative	Uroflow (Q_{max}) postoperative
Mariano et al.	1	800	225	4	120	NA	NA	NA	NA	NA
Baumert et al.	20	412	NA	4	NA	4	NA	NA	NA	NA
van Vethoven et al.	18	192	145	5.9	47.6	3	NA	NA	4.3	17.9
Nadler et al.	1	300	350	3	170	10	21	NA	NA	NA
Sotelo et al.	17	516	156	2	72	6.3	24.5	9.9	7	22.8

Abbreviation: AUA, American Urology Association; NA, data not available.

Maintaining a thick prostate capsule is important to minimize violation of the subcapsular venous plexus. Using this technique we have not encountered significant hemorrhage from the prostatic vessels entering the prostatic capsule at the 4 o'clock and 8 o'clock positions.

Attempting to extract the entire prostatic lobe intact may actually impair visualization, contributing to increased blood loss. Hence, piecemeal excision of the already mobilized part of the adenoma provides superior visualization of the remaining part of the adenoma, allowing better hemostasis.

SPECIFIC MEASURES TAKEN TO PREVENT COMPLICATIONS

The transverse cystotomy incision should not be extended onto the prostate capsule, but must remain limited to the bladder wall exclusively. The adequate plane for incision may be identified by laparoscopic sense of touch over the surface of the prostate and the bladder using a laparoscopic forceps to appreciate the different consistency of the two tissues; the edge of the prostate is easily recognized moving the catheter inside the lumen of the prostatic urethra and the bladder.

Special attention should be directed to avoid any comprise of the ureteral orifices. Any source of bleeding in the prostate bed should be definitively controlled with the J-hook, the harmonic scalpel, or a hemostatic stitch.

REFERENCES

1. Roehrborn CG, Bartsch G, Kirby R, et al. Guidelines for the diagnosis and treatment of benign prostatic hyperplasia: a comparative international overview. *Urology* 2001; 58:642-650.
2. Millin T. *Retropubic Urinary Surgery*. London: Livingstone, 1947.

3. Lu-Yao GL, Barry MJ, Chang CH, et al. Transurethral resection of the prostate among Medicare beneficiaries in the United States: time trends and outcomes. *Urology* 1994; 44:692–696.
4. McNicholas TA. Management of symptomatic BPH in the UK: who is treated and how? *Eur Urol* 1999; 36:33–39.
5. Gordon NS, Hadlow G, Knight E, Mohan P. Transurethral resection of the prostate: still the gold standard. *Aust NZ J Surg* 1997; 67:354–357.
6. Kuntz R, Lehrich K. Transurethral holmium laser enucleation versus transvesical open enucleation for prostate adenoma greater than 100 g. A randomized prospective trial of 120 patients. *J Urol* 2002; 168:1465–1469.
7. Moody JA, Lingeman JE. Holmium laser enucleation for prostate adenoma greater than 100 g: comparison to open prostatectomy. *J Urol* 2001; 165:459.
8. AUA Practice Guidelines Committee. AUA guideline on management of benign prostatic hyperplasia (2003). Chapter 1: Diagnosis and treatment recommendations. *J Urol* 2003; 170:530–547.
9. Han M, Alfert H, Partin A. Retropubic and suprapubic open prostatectomy. In: Walsh PC, Retik AB, Vaughan ED, Wein AJ, eds. *Campbell's Urology*. Vol. 2. 8th ed. Philadelphia: Saunders (Chapter 41).
10. Tubaro A, Vicentini R, Renzetti R, Miano L. Invasive and minimally invasive treatment modalities for lower urinary tract symptoms: what are the relevant differences in randomized controlled trials? *Eur Urol* 2000; 38:7–17.
11. McConnell JD, Barry MJ, Bruskewitz RC, et al. Benign Prostatic Hyperplasia: Diagnosis and Treatment. Clinical Practice Guideline AHCPR Publications No. 94-0582. Rockville: Agency for Health Care Policy and Research, Public Health Service, U.S. Department of Health and Human Services, 1994.
12. Tubaro A, Carter S, Hind A, Vicentini C, Miano L. A prospective study of the safety and efficacy of suprapubic transvesical prostatectomy in patients with benign prostatic hyperplasia. *J Urol* 2001; 166:172–176.
13. Gilling PJ, Cass CB, Cresswell MD, Fraundorfer MR. Holmium laser resection of the prostate: preliminary results of a new method for the treatment of the benign prostatic hyperplasia. *Urology* 1996; 47:48.
14. Gilling PJ, Mackey M, Cresswell M, Kennett K, Kabalin JN, Fraundorfer MR. Holmium laser versus transurethral resection of the prostate: a randomized prospective trial with 1-year followup. *J Urol* 1999; 162:1640–1644.
15. Kuo RL, Kim SC, Paterson RF, Ligeman JE, Munch LC. Holmium laser enucleation of the prostate (Holep): a minimally invasive alternative to open simple prostatectomy. *J Urol* 2003; suppl 169; 111 Abstract V430.
16. Kuo RL, Kim SC, Paterson RF, Watkins S, Steele RE, Lingerman JE. Holmium laser enucleation of the prostate (Holep): the methodist hospital experience with >75 gram enucleations. *J Urol* 2003; suppl 169; 389 Abstract 1452.
17. Chen SS, Hong JG, Hsiao YJ, et al. The correlation between clinical outcome and residual prostatic weight ratio alter transurethral resection of the prostate for benign prostatic hyperplasia. *BJU Int* 2000; 85:79.
18. Mariano MB, Graziottin TM, Tefilli MV. Laparoscopic prostatectomy with vascular control for benign prostatic hyperplasia. *J Urol* 2002; 167:2528–2529.
19. Baumert H, Gholami SS, Bermúdez H, et al. Laparoscopic simple prostatectomy. *J Urol* 2003; suppl 169; 109 Abstract V423.
20. van Velthoven R, Peltier A, Laguna MP, et al. Laparoscopic extraperitoneal adenomectomy (Millin): pilot study on feasibility. *Eur Urol* 2004; 45:103–109.
21. Nadler Robert B, Blunt Lynn W Jr., User Herbert M, Vallancien G. Preperitoneal laparoscopic simple prostatectomy. *Urology* 2004; 63:778.e9–778.e10.
22. Sotelo R, Spaliviero M, Garcia-Segui A, et al. Laparoscopic retropubic simple prostatectomy. *J Urol* 2005; 173:757–760.
23. Sotelo R, Garcia A, Hanssen A, et al. Prostatectomía Radical Laparoscópica: Reporte de los primeros 20 casos. *Urol Panam Ene-Mar* 2003; 15(1):42–46.
24. Njinou Ngninkeu B, Gaston R, Piechaud T, Lorge F. Laparoscopic prostatic adenomectomy assisted by index digital finger: a preliminary report. *J Endourol* 2003; 17(suppl 1); Abstract MP19.28.

TECHNIQUES FOR URETHROVESICAL ANASTOMOSIS IN LAPAROSCOPIC RADICAL PROSTATECTOMY

Roland F. P. van Velthoven

Department of Urology, Institut Jules Bordet and CHU Saint-Pierre, Université Libre de Bruxelles, Brussels, Belgium

- INTRODUCTION
- PATIENT POSITIONING
- SURGEON POSITIONING
- PREPARATION OF THE URETHRAL STUMP
- PREPARATION OF THE BLADDER NECK
- URETHROVESICAL ANASTOMOSIS IN THE MONTSOURIS TECHNIQUE
- RUNNING SUTURE TECHNIQUE FOR VESICourethRAL ANASTOMOSIS
- SINGLE KNOT METHOD FOR THE LAPAROSCOPIC RUNNING URETHROVESICAL ANASTOMOSIS
- DISCUSSION
- SUMMARY
- REFERENCES

INTRODUCTION

Laparoscopic radical prostatectomy represents a “minimally invasive approach” to conventional retropubic radical prostatectomy (1). The technique, however, requires a significant learning curve even for experienced laparoscopic surgeons (1–3). Indeed, it is estimated that the steep part of the learning curve extends over 40 to 50 cases (4). One area of difficulty is mastering laparoscopic suturing techniques in order to perform the urethrovesical anastomosis, which is one of the most demanding steps of the whole procedure. According to Schuessler et al., it represents the part of the procedure requiring the greatest time, taking twice as long as the removal of the prostate (1). However, this technique needs to be standardized at the very beginning of the laparoscopic experience in order to improve its ergonomics and accuracy.

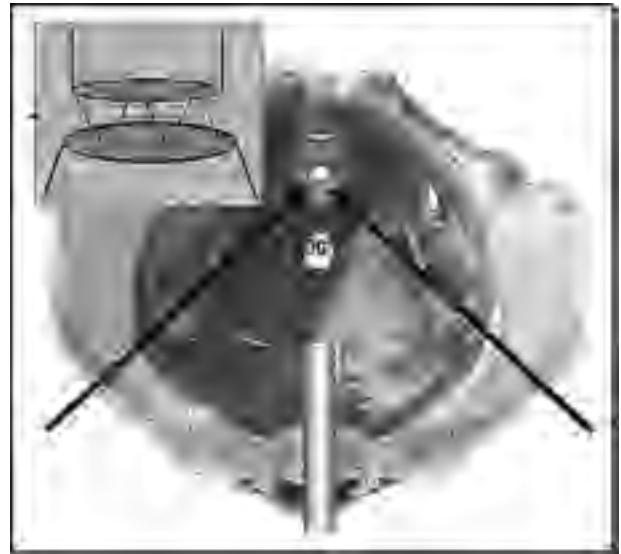
It is trivially obvious to say that urethrovesical anastomosis comes at the end of the radical prostatectomy itself. When the prostate is removed through a laparoscopic approach, the difficulty inherent to this maneuver may be increased by the variable length of the former technical steps, with a direct impact on the surgeon’s fatigue and hence on eventual shortcomings compromising the suture’s quality. Suturing in the deep pelvis is moreover submitted to anatomical variations able to disturb the suturing technique.

Laparoscopic technique offers optimal light conditions under the pubic symphysis and the 10- to 12-fold magnifications permits accurate placement of the sutures which was never approached with open techniques (5). Nevertheless, the reduction of the work space, the distance from the bladder neck to the urethral stump, the weight of a filled bladder in Trendelenburg position, the impaired axial vision in a two-dimensional space, all these usual conditions may lead urologists with limited laparoscopic experience to face severe problems at the end of a demanding procedure. Several technical prerequisites, which are inherent to the whole operative protocol, may yet improve this situation.

PATIENT POSITIONING

At the moment of the suture, steep Trendelenburg is less contributive than during the antegrade dissection of a transperitoneal approach. The reduction of this inclination may ease the ascension of the bladder.

FIGURE 1 ■ View of the pelvis, the working axes of the needle holders are represented with respect to the anatomical position of the urethrovesical anastomosis.



SURGEON POSITIONING

The urethrovesical anastomosis is generally carried out with preferably two needle holders, eventually with one needle holder in the dominant surgeon's hand, assisted by a straight or Maryland forceps. The choice of the trocars defines the spatial relationship between the needle holders and hence has also a direct impact on the suturing technique.

It has been described by Frede et al. (6) that the angles between the instruments and the suture line are of outmost importance. Acute angles between instruments of 25° and 45° maximize the efficiency of suturing and knotting. This statement is adopted by several teams, irrespectively of the trocar placement. In addition, angles inferior to 55° between needle holders and the horizontal plane simplify also these maneuvers. If the latter sentence seems quite obvious in order to reduce surgeon's fatigue and frustration, the former appears more questionable.

As the urethrovesical suture line is anatomically oriented in the horizontal plane, suturing maneuvers and appropriate needle direction may be eased by needles working as much as possible in a vertical plane, that is perpendicular to the suture plane (Fig. 1). Taking into account the respective orientations of the needle and of the needle holder tip, this is hardly feasible if the main needle holder works through a midline port. In this situation, the needle should work rather parallel to the suture line and this might compromise the achievement and the quality of some stitches with respect to the position of the urethral stump.

In the author's view, needle holders should work preferably with an angulation between 60° and 90°, through the lateral or the pararectal ports.

As a matter of fact, this favorable situation is reproduced when the suture is "robot-assisted." It is well known that the working arms of the "slave system" work through the lateral iliac ports, reproducing as such an ideal isosceles triangulation shape with "the eyes of the surgeon" materialized by the lens, located on the midline port.

PREPARATION OF THE URETHRAL STUMP

The preserved length of the urethra is essential to the quality of the urethrovesical anastomosis.

As the urethra is classically sharply cut in a stretched position, with the assistance of a cephalad traction on the prostate, a subsequent retraction of the urethra is expected after section (7). The presence of an 18-French catheter or of a urethral dilator facilitates the exposition of the stump with eventual assistance of a gentle push on the perineum at the level of the bulbar urethra.

In the author's view, needle holders should work preferably with an angulation between 60° and 90°, through the lateral or the pararectal ports.

The preserved length of the urethra is essential to the quality of the urethrovesical anastomosis.

Relative preservation of the bladder neck contributes to the feasibility of the anastomosis not only in terms of smooth muscle preservation but also by the saving of available centimeters of tissue to fill the prostate gap.

PREPARATION OF THE BLADDER NECK

Complete resection of the prostate unavoidably removes a significant length of urethra, according to the prostate's size.

Relative preservation of the bladder neck contributes to the feasibility of the anastomosis not only in terms of smooth muscle preservation but also by the saving of available centimeters of tissue to fill the prostate gap.

A wider opening of the bladder neck, in case of the presence of a large median prostatic lobe has only reduced impact on the anastomotic technique (8).

The posterior lip of the bladder neck is generally approximated first to the posterior urethra. In case of excessive discrepancy between the diameters of both organs, an anterior vesicoplasty will be carried out at the end of the anastomosis in most of the cases. A posterior vesicoplasty, performed prior to the anastomosis, is generally not necessary but must be achieved only when the ureteric orifices are at 5 mm or less from the bladder limit; this suture is carried out with either interrupted or running stitches; it allows for a larger safety distance between orifices and suture line but may also enable the anastomotic technique by reducing and tubulizing the diameter of the bladder neck. This latter artifice becomes mandatory in case of previous transurethral resection of the prostate or of Millin's adenomectomy; in these instances, both the ureters are at high risk of obstructive stretching if the bladder is simply pulled down toward the urethra.

Three main techniques are presented in the literature to achieve the vesicourethral anastomosis: the Montsouris technique (8) for interrupted sutures; the running suture, popularized by Gaston in Bordeaux and described in 2000 by the group of Creteil (France) (5); and the modified running suture, described by our group (9–11).

URETHROVESICAL ANASTOMOSIS IN THE MONTSOURIS TECHNIQUE

This protocol was described by Guillonnet and Vallancien (8) after a continuous cohort of 260 patients operated in 23 months. According to these authors, when compared to the technique described by Walsh (12), it is not necessary to evert the bladder mucosa or to narrow the bladder neck. Knots may be formed inside or outside of the anastomotic lumen. The surgeon works with two needle holders all along this step.

Anastomosis is performed with interrupted 3-0 resorbable 4/8 or 5/8 sutures on a No. 26 needle.

All sutures are tied intracorporeally, although the assistance of a knot pusher may ease the maneuver for beginners. For internally tied interrupted sutures a 6-in. length is sufficient. A metal Benique dilator with a depressed tip allows for the placement of the needle into the urethra and the metal sheet can also help by allowing the needle to slide along the dilator.

The first suture is placed at the 5 o'clock position, running inside-out on the urethra (right hand, forehand) and outside-in on the bladder neck (right hand, forehand). The knot is tied inside the urethral lumen (Fig. 2). Then four sutures are placed symmetrically at the 2, 4, 8, and 10 o'clock positions, the knots are tied outside the lumen.

For a right-handed surgeon, the right-sided sutures run outside-in on the bladder (right hand, forehand) and inside-out on the urethra (left hand, backhand). The left-sided stitches run outside-in on the urethra (right hand, forehand) and inside-out on the bladder neck (right hand, forehand). Finally two sutures are placed at the 11 and 1 o'clock positions, running outside-in on the urethra (right hand, forehand) and inside-out on the bladder neck (right hand, forehand, on the left; left hand forehand, on the right) (Fig. 3). These two last sutures are tied only when the Foley catheter has been correctly positioned in the bladder and checked. The knots are tied outside the lumen, without any risk of balloon injury. The balloon is inflated with 8–10 cc and the bladder is irrigated with 120–200 mL of saline to assess the watertightness of the anastomosis.

Türk et al. described a similar approach in 2001 (13) without major modifications; for these authors, the anastomosis requires 8 to 10 single stitches of 2-0 Vicryl. The same year, Gill and Zippe reported the same attitude; moreover, they described carefully the choreographed sequence of planning and placing the interrupted sutures (Table 1) (7).

Stitch placement is performed using both hands, because more than 50% of the sutures are passed with the left hand.

These authors also address the possible difficulties encountered when starting the sutures. Per Türk et al., to facilitate placement of the initial two stitches, a sponge stick can be employed to place perineal pressure, thereby presenting the urethral stump somewhat more clearly. Difficulties encountered with the placement of the Foley catheter may be

Anastomosis is performed with interrupted 3-0 resorbable 4/8 or 5/8 sutures on a No. 26 needle.

Stitch placement is performed using both hands, because more than 50% of the sutures are passed with the left hand.

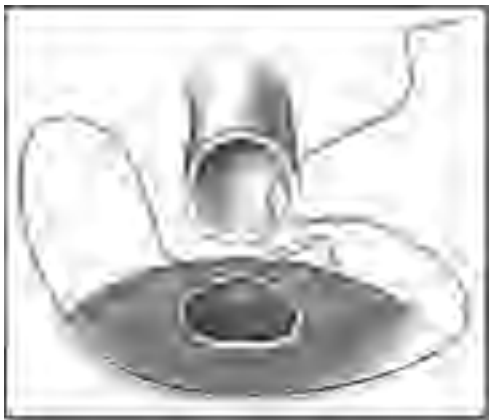

FIGURE 2 ■ Urethrovesical anastomosis in the Montsouris technique. The first suture is placed at the 5 o'clock position, running inside-out on the urethra (right hand, forehand) and outside-in on the bladder neck (right hand, forehand). The knot is tied inside the urethral lumen.



FIGURE 3 ■ Urethrovesical anastomosis in the Montsouris technique. Finally two sutures are placed at the 11 and 1 o'clock positions, running outside-in on the urethra (right hand, forehand) and inside-out on the bladder neck (right hand, forehand, on the left; left hand forehand, on the right).

If the posterior stitches are too distant to each other, a “fausse route” may develop during catheter insertion. This gap may also cause delayed healing of the anastomosis at the 6 o'clock level, which may require considerable additional catheter time.

solved by a finger placed into the rectum to lift the bulbar urethra anteriorly; alternatively a catheter insertion mandrin (Guyon) can be employed (7).
If the posterior stitches are too distant to each other, a “fausse route” may develop during catheter insertion. This gap may also cause delayed healing of the anastomosis at the 6 o'clock level, which may require considerable additional catheter time.

RUNNING SUTURE TECHNIQUE FOR VESICourethRAL ANASTOMOSIS

Hoznek et al. started their own laparoscopic experience with prostatectomy about six months later than the Montsouris group. One will notice that these authors moved very early to a running suture to deal with the urethrovesical anastomosis. This attitude aimed at sparing the time devoted to knots on interrupted stitches as well as to avoid any intraluminal knotting (5).
The patient is positioned in dorsal decubitus, with the legs slightly spread to allow intraoperative rectal examination. Five trocars are used; as already mentioned, trocar disposition has primary importance in the anastomotic technique, because they determine the axis of the needle holder, plane of the needle, and angle between the instruments. Once the prostate is excised, there is usually no need to perform a racket

TABLE 1 ■ Choreographed Sequence of Successive Stitches in Interrupted Vesicourethral Anastomosis

Stitch	Location (o'clock)	Start	Hand	End	Hand	Knot
1	5	UR-lo	Rh Fh	BN-Oi	Rh Fh	Inside
2	7	UR-lo	Lh Fh	BN-Oi	Lh Fh	Inside
3	8	BN-Oi	Lh Fh	UR-lo	Lh Fh	Outside
4	4	BN-Oi	Rh Fh	UR-lo	Lh Bh	Outside
5	9-10	BN-Oi	Lh Fh	UR-lo	Rh Bh	Outside
6	2-3	BN-Oi	Rh Fh	UR-lo	Lh Bh	Outside
7	11-12	UR-Oi	Lh Fh	BN-lo	Rh Fh	Outside
8	12-01	UR-Oi	Lh Fh	BN-lo	Lh Fh	Outside

Abbreviations: UR, urethra; BN, bladder neck; Rh, right hand; Lh, left hand; Bh, backhand; Fh, forehand; lo, inside-outside; Oi, outside-inside.
Source: From Refs.7 and 8.

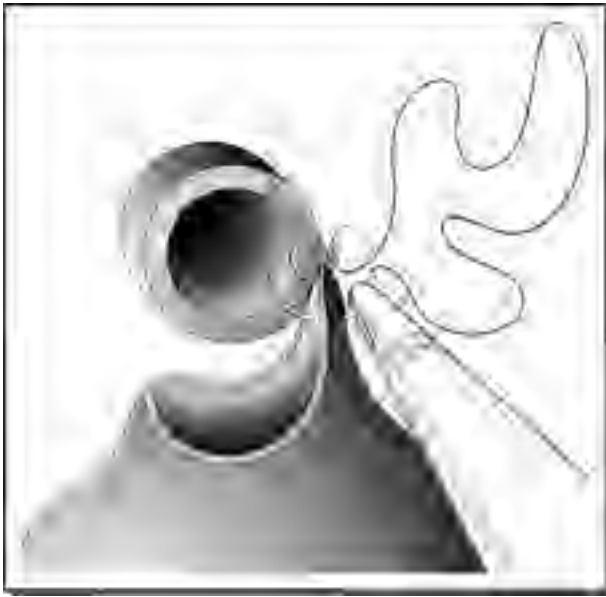

FIGURE 4 ■ The running suture technique. A starter knot is done at the 3 o'clock position, the suture is conducted from outside-in on the bladder, then from inside of the urethra to the outside. For both needle passages, we use the right needle holder. The suture is then tightened with intracorporeal technique.

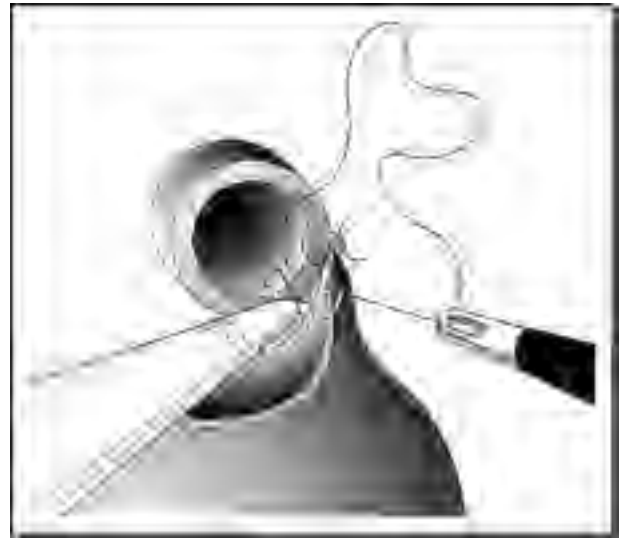

FIGURE 5 ■ The running suture technique. One or two sutures are then placed near the 6 o'clock position of the bladder and urethra. The sutures at the bladder side are easier to perform with the more horizontal left needle holder.

The vesicourethral anastomosis consists in a posterior and an anterior hemicircumferential running suture. Two needle holders are used simultaneously.

handle bladder neck reconstruction. Indeed, due to improved visibility and identification of anatomic landmarks during laparoscopy, the bladder neck is often sectioned in the optimal plane.

The vesicourethral anastomosis consists in a posterior and an anterior hemicircumferential running suture. Two needle holders are used simultaneously.

The right needle holder is inserted through the 12-mm disposable trocar situated at the right margin of the rectus sheath. This trocar allows also the passage of the suturing material: a 3-0 Vicryl suture with a 26-mm needle, where the optimal length of the suture is about 20 cm. The left needle holder is passed through the 5-mm port near the left anterior superior iliac spine. One will notice here again that this implies an angle of at least 60° between the needle holders axes. The surgeon manipulates these two needle holders. The first assistant holds the 0° lens which is passed through the 12-mm trocar at the umbilicus. In the other hand, he holds the suction-irrigation device, passed through the left 12-mm trocar. The suction-irrigation device allows exposing the bladder neck and removing the accumulated urine from the operating field. A second assistant or the instrumentalist uses a narrow forceps to hold the long tail of the running suture. On the urethral side, the long tail is maintained under traction in the direction of the symphysis, while on the bladder side it is pulled cephalad.

A starter knot is done at the 3 o'clock position. The suture is placed from outside in on the bladder, then from inside of the urethra to the outside. For both needle passages we use the right needle holder. The suture is then tightened with intracorporeal technique (Fig. 4). Next, the needle is passed from outside to inside of the bladder, below the starter knot, at the lower margin of the bladder neck in the 4 o'clock position. This is done with the right needle holder. One or two sutures are then placed near the 6 o'clock position of the bladder and urethra. The sutures at the bladder side are easier to perform with the more horizontal left needle holder (Fig. 5). For the left lateral zone of the bladder neck and urethra, we use the right needle holder (Fig. 6).

For the terminal knot of the posterior hemicircumferential suture, a closed loop is prepared at the 9 o'clock position. The needle is passed from inside to outside on the bladder, then from outside to inside on the urethra, thus forming a loop, and again from inside to outside on the bladder side. The suture line is thus ended extramurally with a three-legged. The Foley catheter is pushed without any difficulty into the bladder.

Then, a second running suture is realized on the anterior margin of the bladder and urethra, beginning at the 2 o'clock position on the bladder side, then in the urethra with the help of the right needle holder (Fig. 7). Two or three needle passages

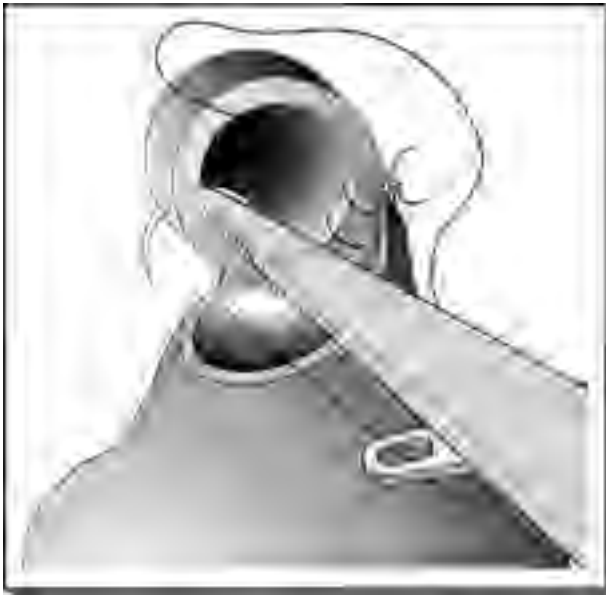

FIGURE 6 ■ The running suture technique. For the left lateral zone of the bladder neck and urethra, we use the right needle holder.



FIGURE 7 ■ The running suture technique. Then, a second running suture is realized on the anterior margin of the bladder and urethra, beginning at the 2 o'clock position on the bladder side, then in the urethra with the help of the right needle holder. Two or three needle passages are sufficient to close entirely the anterior aspect of the anastomosis.

are sufficient to close entirely the anterior aspect of the anastomosis. A loop is again formed at the 10 o'clock position and the knot is tied. These different sutures are performed with deliberate structured and error-free choreography, which has evolved progressively during the developmental phase of laparoscopic radical prostatectomies.

SINGLE KNOT METHOD FOR THE LAPAROSCOPIC RUNNING URETHROVESICAL ANASTOMOSIS

This protocol was developed in Brussels in December 2000, after a continuing cohort of 85 patients operated in 20 months, of whom 75 underwent an interrupted suture tied extracorporeally for the very first, then intracorporeally according to the Montsouris technique, and 10 patients had a running suture for the anastomosis.

Since 2000, about 265 consecutive patients have been treated with this modified running suture consisting of one single intracorporeal knot (9–11).

After laparoscopic removal of the prostate has been accomplished, the bladder neck is identified. The running suture is prepared by tying together the ends of two 5–7 in. sutures of 3-0 or 2-0 monolayer polyglycolic acid; when available one thread is dyed and the other is not dyed, for easy identification purposes. The running stitch is initiated by placing both needles (SH or UR-5) outside in through the bladder neck and inside out on the urethra, one at 5:30 position and the other needle at 6:30 (Fig. 8). The sutures are run from the 6:30 and 5:30 positions to the 9 o'clock and 3 o'clock positions, respectively, approximating the bladder and urethra at each pass. The posterior lip of the bladder neck is left apart from the posterior urethra as long as the two first runs on the urethra and the three first runs on the bladder are not completed (Fig. 9). When this is achieved, a gentle traction is exerted on each thread simultaneously or alternatively, and the system of loops acts as a “whinch” to bring the bladder in contact with the urethra without any excessive traction on the latter. For that purpose, the presence of the knot at 6 o'clock position allows to keep two equal suture branches when pulling and forces the bladder to move as the fixed point of the winch. At this point, the 16-French silastic catheter used during the whole procedure is placed into the bladder. Proceeding in this manner, both knots might reside on the bladder side of the anastomosis, this is

Since 2000, about 265 consecutive patients have been treated with this modified running suture consisting of one single intracorporeal knot.

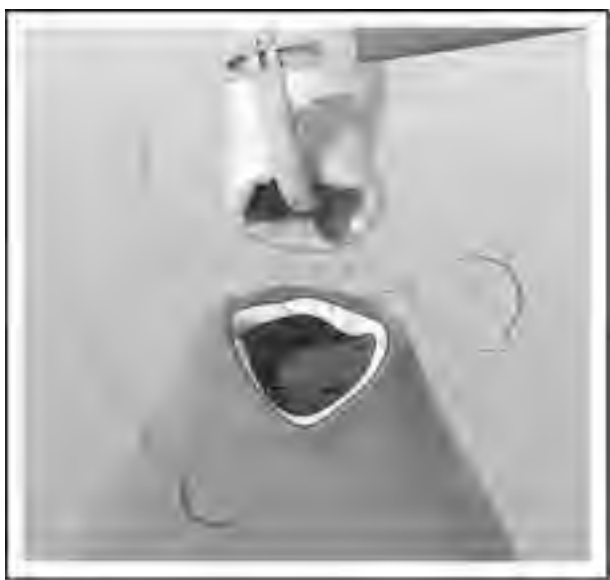

FIGURE 8 ■ The “single knot” running suture technique (all stitches are labeled according to Table 2). The running stitch is initiated by placing both needles (SH or UR-5) outside in through the bladder neck and inside out on the urethra, one at 5:30 position and the other needle at 6:30.



FIGURE 9 ■ The “single knot” running suture technique (all stitches are labeled according to Table 2). The sutures are run from the 6:30 and 5:30 positions to the 9 and 3 o'clock positions, respectively, approximating the bladder and urethra at each pass. The posterior lip of the bladder neck is left apart from the posterior urethra as long as the two first runs on the urethra and the three first runs on the bladder are not completed.

avoided between sutures 7 and 8 to end on the urethral side with the right thread and on the bladder side with the left one (Fig. 10). Carrying the suturing up to the 12 o'clock position on both sides, going outside in on the urethra and inside out on the bladder completes the remaining closure (Fig. 11). At 12 o'clock, the ends of the running sutures are tied to one another on the outside of the bladder (Fig. 12). The choreographed

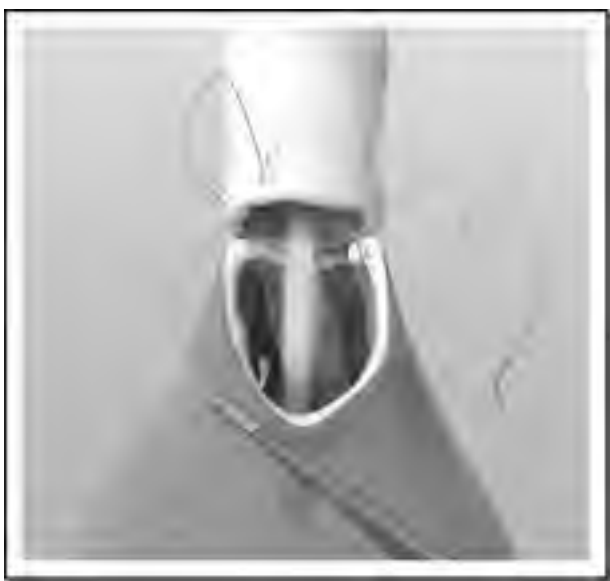

FIGURE 10 ■ The “single knot” running suture technique (all stitches are labeled according to Table 2). As such, going on this way, both knots might reside on the bladder side of the anastomosis, this is avoided between sutures 7 and 8 to end on the urethral side with the right thread and on the bladder side with the left one.

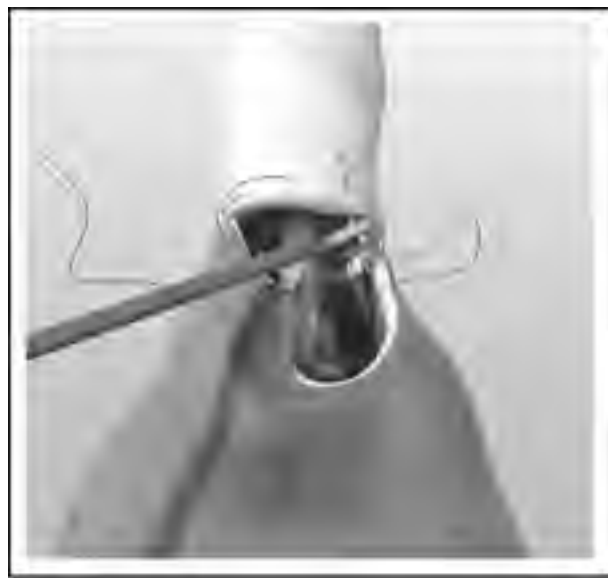

FIGURE 11 ■ The “single knot” running suture technique (all stitches are labeled according to Table 2). Carrying the suturing up to the 12 o'clock position on both sides, going outside in on the urethra and inside out on the bladder completes the remaining closure.

FIGURE 12 ■ The “single knot” running suture technique (all stitches are labeled according to Table 2). At 12 o'clock, the ends of the running sutures are tied to one another, intracorporeally, on the outside of the bladder.

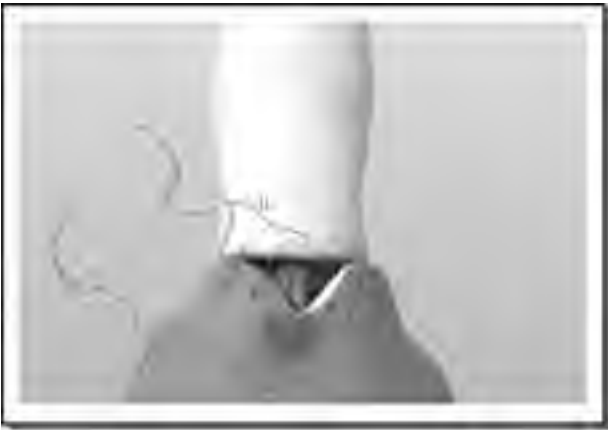

TABLE 2 ■ Choreographed Sequence of Successive Stitches in Running “Single Knot” Vesicourethral Anastomosis

Stitch	Position (o'clock)	Start	Hand	End	Hand
1	5–6	BL Oi	Rh Fh	UR Io	Rh Fh
2	6–7	BL Oi	Rh Fh	UR Io	Rh Fh
3	4	BL Oi	Rh Fh	UR Io	Rh Fh
4	3	BL Oi	Rh Fh	UR Io	Lh Bh
5	8	BL Oi	Lh Fh	UR Io	Lh Fh
6	9	BL Oi	Lh Fh	UR Io	Rh Bh
7	10	UR Oi	Rh Fh	BL Io	Rh Fh
8	11	UR Oi	Rh Fh	BL Io	Rh Fh
9	2	BL Oi	Rh Fh	UR Io	Lh Bh
10	1	BL Oi	Rh Fh	UR Io	Lh Bh
11	12	BL Oi	Rh Fh	UR Io	Rh Bh

Abbreviations: UR, urethra; BN, bladder neck; Rh, right hand; Lh, left hand; Bh, backhand; Fh, forehand.
Source: From Refs. 9–11.

sequence of all sutures are described in Table 2. This table also illustrates the reduced need to sew with the left or nondominant hand although ambidextrous skills remain useful to some extent.

If some discrepancy persists between the diameters of the urethra and of the bladder neck, some residual anterior opening of the bladder is closed at that moment in two layers with the same sutures; in that case, both lengths of threads are increased accordingly to about 20 cm. The balloon on the 20-French silastic catheter is filled with 10 cc of water; the bladder is irrigated until clear with approximately 60 cc of sterile water. A drain is placed and is usually removed on the first postoperative day. The catheter is normally left in place for five to six days, and removed after a retrograde cystogram.

One of the major advantages of laparoscopic radical prostatectomy is its potential to perform all the sutures under total visual control. However, knotting of the sutures is time consuming and contributes to prolonged operating time (1). In open surgery, in fact, a half-knot necessitates less than two seconds, whereas the same requires 15 to 20 seconds during laparoscopy.

DISCUSSION

As stated by Hoznek et al., in open retropubic radical prostatectomy, the pubic bone impairs the visibility and the access to the urethral stump making the placement of the sutures difficult. In addition, the surgeon must tie the knots in a blind field and must rely on tactile sensation only. Therefore, there is a risk of inadequate suture knot positioning. Moreover, if the knot is pulled too strongly it may tear out of the urethra, whereas if it is too loose, the vesical neck and the urethral stump will not be correctly aligned (5).

One of the major advantages of laparoscopic radical prostatectomy is its potential to perform all the sutures under total visual control. However, knotting of the sutures is time consuming and contributes to prolonged operating time (1). In open surgery, in

fact, a half-knot necessitates less than two seconds, whereas the same requires 15 to 20 seconds during laparoscopy (14).

The difficulties inherent to vesicourethral anastomosis are illustrated in conventional open retropubic prostatectomy where several authors developed maneuvers designated to ease the approximation of the bladder to the urethra or the suture technique itself, some of these tips might be transposed to laparoscopy.

The exposition of the urethra may be eased by a Benique dilator, held by the assistant at the edge of the cut urethra; the manipulation of its tip opens the urethral stump according to the various orientation of the needles requested for the four to seven stitches generally used for the anastomosis (8). Currently, the dilator may be replaced by a Foley catheter, put in tension by a traction on its tip combined by a counter-traction on a forceps placed at the urethral meatus. These artifices are used in open and in laparoscopic surgery.

For tying the knots after an open procedure, surgeons may temporarily "hire the assistance" of a laparoscopic instrument like a knot pusher, combined with a Reuder knot, to ease the maneuver when tactile control seems insufficient (15). Approximation of the bladder to the pelvic floor may be eased by additional sutures, sometimes placed through the perineum (16) in case of morbid obesity (17). Novicki et al. consider even the modified Vest suture as a valid alternative to direct anastomosis, providing similar results in terms of long-term continence (18). Anchoring the bladder to the pelvic wall near the urethra is also realized by modified sutures tying the surface of bladder neck to the base of the urethral stump (19). Beyond anecdotal reports, none of these artifices where ever described in laparoscopy where the visual advantage of a direct approach and the magnification factor seem to solve most of the technical problems, in conjunction with a relatively wider perivesical dissection allowing for a direct anastomosis.

Assistance to the open suturing procedure is brought either by a Foley catheter leading the needle to the urethral lumen (20) or by several suturing devices such as Maniceps[®] (21,22) or Endostitch[®] (23). It seems here again that skilled laparoscopic surgeon solved most of the suture technique problems with straight or slightly curved needle holders combined to 4/8 or 5/8 22–26 mm needles.

In laparoscopic vesicourethral anastomosis, the main difficulty may still reside in the tying of the first knot. In fact, this step must successfully achieve two main goals, as the approximation of the bladder as well as the adequate start point of an immediately watertight anastomosis.

Quality control problems with interrupted sutures are illustrated by the complication rates observed even on large cohorts; however, one must yet remain aware of the fact that these cumulative series also describe forever the discovery-learning curve of these protocols. Guillonneau and Rozet reported about 57 cases out of 567 (10%) with early urine leakage resulting in aspiration of urine by the suction drain (24). In 43 patients, the diagnosis occurred before the removal of the catheter and healing followed spontaneously with longer catheter drainage. Two patients requested percutaneous aspiration of urine, while one patient had to be reoperated laparoscopically. In 11 cases, catheter removal was followed by a status of acute pain, acute urinary retention, and peritoneal irritation syndrome, leading to the diagnosis of secondary anastomotic leakage requiring continuous bladder drainage for another week.

The reported difficulties encountered in vesicourethral reconstruction during laparoscopic prostatectomy prompted the group of Creteil to use two hemircumferential running sutures for the anastomosis instead of interrupted sutures, which so far, were used in all of the reported series (3,4,25). The authors also observed four cases of intraperitoneal urine extravasation in the beginning of their experience; these patients requested open or laparoscopic repair, for three and one of them, respectively. No reoperation was necessary for the second half of the experience in Creteil, although postoperative cystography, performed at postoperative days 4 to 5, demonstrates that about 15% of patients have at least some degree of anastomotic leak (26).

To ensure the quality of the direct anastomosis, Türk et al. emphasize the importance of an atraumatic and precise dissection of the bladder neck. They observed 13.6% anastomotic leakage in their series of 125 patients, almost all of them gathered during the learning curve; overzealous use of diathermy around the bladder neck was estimated responsible for these relatively poor results (13).

Beside the arguments in favor of running techniques to increase the watertightness of anastomoses, several experimental studies on small bowel demonstrate, that the time required is significantly shorter with running sutures compared to interrupted sutures. However, interrupted sutures are often preferred on small bowel, because running sutures may lead to anastomotic stenosis when the suture line is tightened (27). In

spite of this, stenosis almost never occurs on urethrovessical anastomosis with running sutures, because the Foley catheter prevents early narrowing of the anastomotic circumference and because reduced extravasation prevents subsequent fibrosis.

Increased surgical precision may reduce the risk of postoperative urethral strictures. Catalona et al. reported 4% urethral strictures in his series of 1870 open prostatectomies (28). Furthermore, as reported for the Medicare population, transurethral incision in 3.3%, transurethral resection in 2.9%, and urethral dilation in 7.3% were performed, respectively, after radical retropubic prostatectomy, for the relief of urethral or bladder neck strictures (29). Vesicourethral anastomosis stricture is reported as high as 0.48% to 32% in the literature; several comorbidity conditions may influence this outcome of surgery through the mechanism of microvascular disease having a direct impact on oxygenation and tissue healing (30,31).

Strictures after laparoscopic prostatectomy were reported in 2.8% only by Rassweiler et al. and in only 0.5% during the further experience of Abbou and coworkers.

Strictures after laparoscopic prostatectomy were reported in 2.8% only by Rassweiler et al. (32) and in only 0.5% during the further experience of Abbou and coworkers (33).

In the author's own experience, only 4/265 (1.5%) anastomotic or urethral strictures with a mean follow-up above 18 months (range, 1–43 months) were observed. This compares favorably with the 4/85 cases (4.7%) observed with our initial series of patients. The difficulties already mentioned with the first knot remain true with the technique of two hemirunning sutures, where the anastomosis is initiated by approximating the bladder neck to the urethra at the 3 o'clock position with one suture only.

Our technique described herein as the single knot method, offers further simplification of the running suture technique. The first knot is prepared extracorporeally by joining the two ends of the threads together. After both needles are passed through the posterior bladder neck and urethra, the bladder neck is easily moved into position at the 6 o'clock position where the knot sits. So, the entire bladder neck from the 5:30 to 6:30 position is moved as a unit toward the urethra, acting much as a mattress suture. After one suture is run from the 5:30 position to the 3 o'clock position, the other suture is run from the 6:30 to 9 o'clock position. We believe this latter method may decrease the chances of pulling through the initial suture. The catheter is then placed into the bladder. The transition suture allows the stitch to now exit the bladder on its outer surface. The sutures are continued to the 12 o'clock position and tied to each other. This solitary intracorporeal knot now, like the initial extracorporeal knot, rests on the bladder side of the anastomosis.

This simplification of the running suture technique has now been adopted by several teams. For example, Menon et al. moved from the two hemicircle running suture to the single knot technique during their experience with robot-assisted prostatectomy (34,35). This technique was also firstly adopted by Ahlering et al. during the development of his own robot-assisted protocol of laparoscopic prostatectomy (36,37).

The impact of the suturing technique on the days before catheter removal was nicely illustrated by Gill and coworkers (38); they showed that mean catheter time after interrupted, two hemirunning, and single knot running suture at one institution were 14.4 ± 8.4 , 9.0 ± 9.2 , and 7.6 ± 6.7 days, respectively.

Contrary to our initial concerns with an interrupted suture anastomosis, there have been few problems with bladder neck contractures that have come to our clinical attention. However, we have not been routinely performing cystoscopy on our patients to assess for this problem. Not surprisingly, symptomatic postoperative urinary extravasation has not occurred. Based on a retrograde cystogram, 17/265 patients operated at our center or during mentoring of coworking teams requested additional catheter time beyond days 5 to 7 postoperatively. We believe the initiating mattress-type stitch at the 5:30 to 6:30 position area effectively buttresses and seals this area while the running nature of the closure further results in a urine-tight anastomosis. Referring to our personal experience, we believe also that the avoidance of even minimal urine leak between the suture points may reduce the rate of anastomotic strictures observed by other authors with separated stitches.

It may seem meaningless to compare these running techniques whose results are rather comparable in skilled hands; reduction of operative time was certainly obtained through the development of a stepwise standardized protocol for the whole laparoscopic prostatectomy.

The choreographic sequence of technical steps is closely linked to a thorough reflexion about suturing ergonomics. The best and easiest anastomoses are obtained through an iterative sequence of maneuvers, ensuring an optimal management of the needle exchange between both needle holders.

The choreographic sequence of technical steps is closely linked to a thorough reflexion about suturing ergonomics. The best and easiest anastomoses are obtained through an iterative sequence of maneuvers, ensuring an optimal management of the needle exchange between both needle holders.

Not surprisingly are these maneuvers accomplished in an improved ergonomic environment when the prostatectomy is robot-assisted.

Currently, daily conventional laparoscopic practice may be enabled by the respect of a strict spatial organization of the needle holders in the working space. The axes of the instruments should work at an angle of 60° to 90°; through pararectal or lateral ports. In this position, when the needle is prepared for stitching, its curve is situated in a vertical plane, hence the jaws of the working needle holder belong to an horizontal plane, perpendicular to the needle plane. If the second needle holder is moved to place its jaws in the same plane as the needle, then when the latter will be pulled through the stitch, a slight rotation of the wrist will replace it immediately ready to be caught for another stitch. This rule works irrespectively of the right or left side of the working hand and with either forehand or backhand maneuvers and of course with interrupted or running sutures. This type of ergonomic rule may be reproduced for any type of suture such as for pyeloplasty or in case of robot-assisted procedures. In our experience, this technique brought our suturing time for urethrovessical anastomosis around 20 minutes during a whole prostatectomy lasting 2 to 2.5 hours.

Basic suturing principles should always be taught in dry boxes where these ergonomic rules are easily illustrated; thereafter, their application to tissues could be extended to still and live animal models such as simple chicken skin models (39,40), chicken breast models (41,42) or in surgery on the pig or on human cadavers (43,44). The chicken thoraco-abdominal cavity reproduces very nicely the human pelvis hollow cavity. The esophagus dissection starts at the joint with the glandular stomach releasing it basically, from the surrounding fat; the esophagus-gastric junction is then divided sharply.

In the chicken model, the “intrapelvic perspective” on the esophageal stump and on the gastric lumen will easily reproduce the vesicourethral picture. This model is easily adapted to learn interrupted or running suture techniques, and is undebatably cost-effective when compared to other sophisticated models available.

In the chicken model, the “intrapelvic perspective” on the esophageal stump and on the gastric lumen will easily reproduce the vesicourethral picture. This model is easily adapted to learn interrupted or running suture techniques, and is undebatably cost-effective when compared to other sophisticated models available.

SUMMARY

- Urethrovessical anastomosis is one of the most demanding steps of the whole laparoscopic prostatectomy.
- The pubic bone impairs the visibility and the access to the urethral stump making the placement of the sutures difficult.
- The preserved length of the urethra is essential to the quality of the urethrovessical anastomosis.
- Relative preservation of the bladder neck contributes to the feasibility of the anastomosis.
- The best and easiest anastomoses are obtained through an iterative sequence of maneuvers, ensuring an optimal management of the needle exchange between both needle holders.
- In laparoscopic vesicourethral anastomosis, the main difficulty may still reside in the tying of the first knot; this step must successfully achieve two main goals, as the approximation of the bladder as well as the adequate start point of an immediately watertight anastomosis. The use of two hemicircumferential running sutures instead of interrupted sutures greatly simplified a crucial part of laparoscopic radical prostatectomy. Such technical advances made laparoscopic prostatectomy coming closer to the operating times of open radical prostatectomy while reducing postoperative morbidity.
- The “single knot” running urethrovessical anastomosis described offers another simplifying step to the laparoscopic surgeon interested in performing laparoscopic radical prostatectomy. The method is easy to learn and perform, is watertight and appears to have a low risk of bladder neck contracture. This may enable surgeons with limited suturing experience to master this difficult technical step, unavoidably located at the end of a very challenging procedure.

REFERENCES

1. Schuessler WW, Schulam PG, Clayman RV, Kavoussi LR. Laparoscopic radical prostatectomy: initial short-term experience. *Urology* 1997; 50:854.
2. Vallancien G, Cathelineau X, Baumert H, Doublet JD, Guillonnet B. Complications of transperitoneal laparoscopic surgery in urology: review of 1,311 procedures at a single center. *J Urol* 2002; 168:23.
3. Abbou CC, Salomon L, Hoznek A, et al. Laparoscopic radical prostatectomy: preliminary results. *Urology* 2000; 55:630.

4. Guillonnet B, Vallancien G. Laparoscopic radical prostatectomy: initial experience and preliminary assessment after 65 operations. *Prostate* 1999; 39:71–75.
5. Hoznek A, Salomon L, Rabii R, et al. Vesicourethral anastomosis during laparoscopic radical prostatectomy: the running suture method. *J Endourol* 2000; 14:749.
6. Frede T, Stock C, Rassweiler JJ, Alken P. Retroperitoneoscopic and laparoscopic suturing: tips and strategies for improving efficiency. *J Endourol* 2000; 14(10):905–914.
7. Gill IS, Zippe C. Laparoscopic radical prostatectomy: technique. *Urol Clin N Am* 2001; 28(2):423–436.
8. Guillonnet B, Vallancien G. Laparoscopic radical prostatectomy: the Montsouris technique. *J Urol* 2000; 163:1643–1649.
9. van Velthoven RF, Ahlering TE, Peltier A, DW Sharecky, Clayman RV. Technique for laparoscopic running urethrovesical anastomosis: the single knot method. *Urology* 2003; 61:699–702.
10. van Velthoven RF, Peltier A. Prostatectomia radical laparoscopica en especie humana. In: *Prostatectomia Radical Laparoscopica*. Caceres, Spain: Centro de Cirugia de Minima Invasion, 2003:173–204.
11. van Velthoven RF, Peltier A, Laguna MP, Ahlering TE. Technique for laparoscopic running urethrovesical anastomosis: the single knot method [abstr]. *J Endourol* 2003; 17(suppl 1):MP15–MP21.
12. Walsh PC. Anatomic radical prostatectomy: evolution of the surgical technique. *J Urol* 1998; 160:2418.
13. Türk I, Deger S, Winkelmann B, Schönberger B, Loening S. Laparoscopic radical prostatectomy. *Eur Urol* 2001; 40:46–53.
14. Cuschieri A, Szabo Z. Laparoscopic hand-sutured and stapled anastomoses. In: *Tissue Approximation in Endoscopic Surgery*. Oxford: Isis Medical Media, 1995:113–139.
15. Cestari A, Guazzoni G, Riva M, Nava L, Rigatti P. Use of the laparoscopic knot introducer in urethrovesical anastomosis following radical prostatectomy. *Tech Urol*; 5(3):152–154.
16. Igel TC, Wehle MJ. Vesicourethral reconstruction in radical retropubic prostatectomy: an alternative technique. *J Urol* 1999; 161:844–846.
17. Kamerer A, Basler J, Thompson I. Novel technique of vest suture vesicourethral anastomosis in a morbidly obese patient undergoing radical retropubic prostatectomy. *J Urol* 2003; 170:174.
18. Novicki D, Larson T, Andrews P, Swanson S, Ferrigni R. Comparison of the modified vest and the direct anastomosis for radical retropubic prostatectomy. *Urology* 1997; 49:732–736.
19. Saito S. Modified reinforcement for vesicourethral anastomosis after radical prostatectomy. *Br J Urol* 1997; 80:147.
20. Mimata H, Kasagi Y, Sakamoto S, Nomura Y. A simple technique for vesicourethral anastomosis in retropubic radical prostatectomy. *Urol Int* 1998; 61:232–234.
21. Yamada Y, Honda N, Nakamura K, et al. New semiautomatic device (Maniceps) for precise vesicourethral anastomosis during radical retropubic prostatectomy. *Int J Urol* 2002; 9:71–72.
22. Yamada Y, Honda N, Nakamura K, et al. Vesicourethral anastomosis suture placement during radical prostatectomy using Maniceps. *Urol Int* 2003; 70:181–185.
23. Escandon AS, Garcia RG. Use of a laparoscopic instrument to improve urethrovesical anastomosis quality during retropubic radical prostatectomy. *Tech Urol* 2000; 6(1):39–41.
24. Guillonnet B, Rozet F, Cathelineau X, et al. Perioperative complications of laparoscopic radical prostatectomy: the Montsouris 3-year experience. *J Urol* 2002; 167:51–56.
25. Price DT, Chari RS, Neighbors JD Jr, Eubanks S, Schuessler WW, Preminger GM. Laparoscopic radical prostatectomy in the canine model. *J Laparoendosc Surg* 1996; 6:405–412.
26. Nadu A, Salomon L, Hoznek A, et al. Early removal of the catheter after laparoscopic radical prostatectomy. *J Urol* 2001; 166:1662.
27. Waninger J, Salm R, Imdahl A, et al. Comparison of laparoscopic handsewn suture techniques for experimental small-bowel anastomoses. *Surg Laparosc Endosc* 1996; 6:282–289.
28. Catalona WJ, Carvalhal G, Mager D, et al. Potency, continence and complication rates in 1870 consecutive radical prostatectomies. *J Urol* 1999; 162:433.
29. Popken G, Sommerkamp H, Schultze-Seeman W, et al. Anastomotic stricture after radical prostatectomy: incidence, findings and treatment. *Eur Urol* 1998; 33:382–386.
30. Borboroglu PD, Sands JP, Roberts JL, Amling CL. Risk factors for vesicourethral anastomosis stricture after radical prostatectomy. *Urology* 2000; 56:96–100.
31. Kostakopoulos A, Argiropoulos V, Protogerou V, et al. Vesicourethral anastomosis stricture after radical retropubic prostatectomy: the experience of a single institution. *Urol Int* 2004; 72:17–20.
32. Rassweiler J, Sentker L, Seemann O, Hatzinger M, Rumpelt HJ. Laparoscopic radical prostatectomy with the Heilbronn technique: an analysis of the first 180 cases. *J Urol* 2001; 166:2101–2108.
33. Hoznek A, Antiphon P, Borkowski T, et al. Assessment of surgical technique and perioperative morbidity associated with extraperitoneal versus transperitoneal laparoscopic radical prostatectomy. *Urology* 2003; 61.
34. Menon M, Tewari A, Peabody J, et al. Vattikuti institute prostatectomy: technique. *J Urol* 2003; 169:2289–2292.
35. Menon M, Hemal A, Tewari A, et al. The technique of apical dissection of the prostate and urethrovesical anastomosis in robotic radical prostatectomy. *BJU Int* 2004; 93:715–719.
36. Ahlering TE, Sharecky D, Lee D, Clayman RV. Successful transfer of open skills to a laparoscopic environment using a robotic interface: initial experience with laparoscopic radical prostatectomy. *J Urol* 2003; 170(5):1738–1741.
37. Ahlering TE, Woo D, Eichel L, Lee D, Edwards R, Sharecky D. Robot-assisted versus open radical prostatectomy: a comparison of one surgeon's outcomes. *Urology* 2004; 63(5):819–822.
38. Albani J, Steinberg A, Sharp D, et al. Laparoscopic radical prostatectomy: analysis of 3 urethrovesical anastomotic techniques [abstr]. *J Endourol* 2003; 17(suppl 1):MP15–MP22.
39. Katz R, Nadu A, Olsson LE, et al. A simplified 5-step model for training laparoscopic urethrovesical anastomosis. *J Urol* 2003; 169:2041–2044.

40. Nadu A, Olsson LE, Abbou CC. Simple model for training in the laparoscopic vesicourethral running anastomosis. *J Endourol* 2003; 17(7):481–484.
41. Sanchez C, Kibanov V. Chicken as the experimental model for practicing of the urethrovesical anastomosis during laparoscopic radical prostatectomy [abstr 329]. *Eur Urol* 2004; 3(2):85.
42. Laguna MP, Alcazar A, Mochtar CH, van Velthoven R, Peltier A, de la Rosette JJ. Chicken training model for laparoscopic radical prostatectomy suture: an internal validation. *J Enduro* 2006; 20(1):1969–1974.
43. Roca A, Passas J, Sanchez F, Tejonero M. Prostatectomia radical laparoscopica en el cerdo. In: *Prostatectomia Radical Laparoscopica*. Caceres, Spain: Centro de Cirugia de Minima Invasion, 2003:125–159.
44. Katz R, Antiphon P, Hoznek A, et al. Cadaveric versus porcine models in urological laparoscopic training. *Urol Int* 2003; 71(3):310–315.

Anoop M. Meraney

*Section of Laparoscopic and Robotic Surgery, Glickman Urological Institute,
Cleveland Clinic Foundation, Cleveland, Ohio, U.S.A.*

■ INTRODUCTION
■ MINILAPAROSCOPIC INSTRUMENTS
■ MINILAPAROSCOPIC UROLOGIC PROCEDURES
Needlescopic Urologic Procedures

■ BENEFITS AND LIMITATIONS
■ CURRENT STATUS AND FUTURE POTENTIAL
■ SUMMARY
■ REFERENCES

INTRODUCTION

Technologic innovations constantly influence current surgical practice. Minimally invasive surgery has been particularly influenced by the development of newer technology and refinement of existing technology. Development of sophisticated and miniaturized optical systems led to the beginnings of minilaparoscopic surgery. Initially, minilaparoscopy was used primarily as a diagnostic tool in gynecologic surgery. Amongst the initial minilaparoscopes was a system developed by Medical Dynamics^a in Englewood, Colorado. The system consisted of optical fibers, incorporated in fiber-optic bundles known as “optical catheters.” Utilizing this technology, Dorsey and Tabb reported their experience with minilaparoscopic myomectomy, adhesiolysis, and biopsy and laser coagulation of endometriosis tissue in 1991 (1). More recently, numerous therapeutic applications of minilaparoscopy have been described in general surgery, endocrine surgery, gynecology, thoracic surgery, and urology.

Various terms have been used in the literature to describe laparoscopic surgery that is performed utilizing small caliber laparoscopic instruments. These include microlaparoscopy, needlescopy, and minilaparoscopy. There appears to be a lack of clarity in the literature regarding the precise definition of these terms. Commonly, the terms have been used interchangeably to denote instruments that are of smaller caliber than conventional laparoscopic instruments. Within this chapter the term “needlescopic” is utilized to denote instruments with an outer diameter of 2 mm or lesser. As such, needlescopic ports have an outer diameter of 2 mm, which is similar to the diameter of a 14-gauge angio-catheter needle, hence the term “needlescopic.” The term “minilaparoscopic instruments” includes all devices that are smaller than conventional laparoscopic instrumentation, which have an outer diameter lesser than 5 mm. The term “minilaparoscopy” includes procedures performed employing needlescopic instruments.

In a pure sense, minilaparoscopic procedures are those that are performed exclusively utilizing minilaparoscopic instruments. However, more commonly, during procedures involving the use of minilaparoscopic instruments, conventional laparoscopic instruments, especially conventional 5 or 10 mm laparoscopes, are also utilized to effectively obtain the most optimal surgical result. This has resulted from deficiencies in minilaparoscopic instrumentation and optics.

In a pure sense, minilaparoscopic procedures are those that are performed exclusively utilizing minilaparoscopic instruments. However, more commonly, during procedures involving the use of minilaparoscopic instruments, conventional laparoscopic instruments, especially conventional 5 or 10 mm laparoscopes, are also utilized to effectively obtain the most optimal surgical result.

MINILAPAROSCOPIC INSTRUMENTS

Conventional laparoscopes typically incorporate the Hopkins rod lens image transmission systems. The image relay system occupies the center of the laparoscope, while the light illumination fibers are located peripherally. Image transfer is facilitated by a series of lenses and glass rods, which was invented by Harold Hopkins in 1960 (2). This

technology is also utilized in the manufacture of rigid minilaparoscopes. Further miniaturization of the minilaparoscopes has been facilitated by employing fiber-optic imaging technology. Each fiber-optic quartz fiber measures 6 μm in diameter. A needlescope typically contains 30,000 to 50,000 quartz fibers arranged in a bundle. The fiber-optic tele-scopes are flexible. Because image transfer occurs via individual optical fibers, the image obtained appears pixilated. Overall, images obtained through rod lens systems are of improved quality compared to images obtained from fiber-optic systems. Also, the fiber-optic laparoscopes are delicate and damage to individual fibers impacts image quality. Further, unlike the rod lens minilaparoscopes, the fiber-optic minilaparoscopes cannot be autoclaved and need to be gas sterilized.

Minilaparoscopes currently available include Storz microendoscope^a, diameter 1 mm; Medical Dynamics microendoscope^b, diameter 1.8 mm; Pixie microendoscope^c, diameter 1.9 mm; Minisite^d, diameter 2 mm; and Hopkins II^b, diameter 3.3 mm.

Both reusable and disposable trocars for 3 mm minilaparoscopic instruments are available. Disposable trocars utilized for needlescopic surgery have an outer diameter of 2 mm (Miniport^d), and are similar to Veress needles. The needle ports are valveless, although they have roughened outer surfaces, which minimizes leakage of gas.

Given the narrow port diameter, inflow of insufflation gas occurs at a low flow of approximately 1 L/min. This results in slow filling and evacuation of insufflation gas. Evacuation of smoke following the use of electrocautery is also slow, which may prolong the operative time.

Various reusable and disposable minilaparoscopic instruments are available for clinical use. Reusable instruments include scissors, hook scissors, single-action and double-action graspers, needle drivers, and suction-irrigation cannulas. Disposable insulated 2 mm shears (Minisite^d) designed for monopolar electrocautery are also available. The shears are equipped with only a thin layer of insulation, and the manufacturers recommend that electrosurgical power be limited to 30 W to prevent damage to the insulation and inadvertent thermal injury to adjacent tissues. Instruments of larger diameter (3 mm) are sturdier than needlescopic instruments (2 mm). Also, wider selections of instruments are available in the former category, including needle drivers and a selection of tissue graspers.

Given the narrow port diameter, inflow of insufflation gas occurs at a low flow of approximately 1 L/min. This results in slow filling and evacuation of insufflation gas. Evacuation of smoke following the use of electrocautery is also slow, which may prolong the operative time.

MINILAPAROSCOPIC UROLOGIC PROCEDURES

Needlescopic Urologic Procedures

Adrenalectomy

Technique

Left Adrenalectomy. The procedure is performed with the patient in the lateral position with a 45° tilt. A 2 mm Minisite port is utilized to gain initial peritoneal access. The 2 mm trocar serves as a Veress needle and is inserted lateral to the lateral border of rectus abdominus muscle (anterior axillary line) 3 fingerbreadths inferior to the costal margin. Initial peritoneal entry is confirmed utilizing the needlescope. Pneumoperitoneum is then established. Additional ports that are inserted subsequently include a 10 mm port at the umbilicus, a 5-mm port in the midclavicular line 2 fingerbreadths inferior to the costal margin, and a 2 mm port along the lateral border of the rectus at the costal margin. Except for the initial 2 mm port, all ports are placed under direct visual guidance. A 10 mm 45° laparoscope is inserted through the umbilical port. The surgeon operates through the medial 2 mm port and the 5 mm port. The lateral 2 mm port is utilized by the assistant to place traction on the kidney in an inferior and lateral direction, in order to facilitate tissue dissection. Initially, the line of Toldt is incised, and the left colon is reflected medially. The left renal vein is identified. Dissection along the superior margin of the left renal vein facilitates identification of the adrenal vein. The vein is controlled utilizing 5 mm hemoclips and divided. Next, adrenal vessels arising from the renal artery and aorta are individually controlled with hemoclips and divided. The gland is then circumferentially mobilized. A 10 mm endocatch bag is inserted through the umbilical port

^aKarl Storz, Culver City, CA.

^bMedical Dynamics, Englewood, CO.

^cOrigin MedSystems, Menlo Park, CA.

^dU.S. Surgical Corp., Norwalk, CT.

The steps of the procedure are similar to those of a transperitoneal laparoscopic adrenalectomy. The differences between conventional laparoscopic and needlescopic adrenalectomy include (i) the utilization of a 45° laparoscope at the umbilicus instead of a 30° laparoscope inserted through a more laterally placed port; (ii) the utilization of 2 mm instruments for dissection, and 5 mm hemoclips; and (iii) the need to switch to a needlescope during insertion of secondary ports, specimen extraction, and fascial closure of the umbilical port site.

for specimen entrapment. Insertion of the needlescope through the lateral 2 mm port facilitates this maneuver. Hemostasis is reconfirmed. The fascia underlying the 10 mm port site is closed with a 0 Vicryl suture utilizing a Carter–Thomason closure device.

The steps of the procedure are similar to those of a transperitoneal laparoscopic adrenalectomy. The differences between conventional laparoscopic and needlescopic adrenalectomy include (i) the utilization of a 45° laparoscope at the umbilicus instead of a 30° laparoscope inserted through a more laterally placed port; (ii) the utilization of 2 mm instruments for dissection, utilization of 5 mm hemoclips; and (iii) the need to switch to a needlescope during insertion of secondary ports, specimen extraction, and fascial closure of the umbilical port site.

Right Adrenalectomy. Initial peritoneal access is achieved with a 2 mm port placed in the anterior axillary line 3 fingerbreadths inferior to the costal margin. A 10-mm port is placed at the umbilicus, a 2-mm port is placed lateral to the xiphoid at the costal margin, and a 5-mm port is placed at the lateral border of the rectus 3 fingerbreadths inferior to the costal margin. The assistant retracts the liver superiorly with a 2 mm grasper inserted through the medial 2 mm port. The surgeon operates utilizing the lateral 2 mm port and the 5 mm port. Initially, the line of Toldt is incised and the right colon is reflected medially. Following this, the posterior parietal peritoneum inferior to the inferior margin of the liver is incised. The inferior vena cava is then identified. Dissection between the adrenal gland and the inferior vena cava facilitates identification of the adrenal vein, which is controlled with 5 mm hemoclips and divided. The specimen is then circumferentially mobilized, entrapped in an endocatch bag, and extracted through the umbilical port site.

Results

Gill et al. compared needlescopic adrenalectomy ($n = 15$) to conventional laparoscopic adrenalectomy ($n = 21$) (3). Within this retrospective review, patients in the needlescopic group were older than patients in the conventional laparoscopic group (60.4 ± 11.3 years vs. 52 ± 12.7 years; $p = 0.06$). The needlescopic group was associated with shorter operative time (2.8 hours vs. 3.7 hours; $p = 0.05$), lesser estimated blood loss (61.4 mL vs. 183.1 mL; $p = 0.002$), and shorter length of stay in the hospital (1.1 days vs. 2.7 days; $p < 0.001$). The average specimen weight for the needle-scopic group was 41.6 g (range, 6.8–108 g) and was 15.7 g (range, 6.6–55 g) for the laparoscopic group. Convalescence was shorter for the needlescopic group (2.1 ± 1.02 weeks vs. 3.1 ± 1.9 weeks; $p < 0.001$). Four of the needlescopic cases were converted to conventional laparoscopy for various reasons including: morbid obesity with a body mass index of 34.1 ($n = 1$); large tumor size (6 cm) ($n = 1$); and hemorrhage ($n = 2$). None of the cases required open conversion.

Orchiopexy

Technique

Initially, a 2 mm needle port is inserted at the umbilicus. The normal side is inspected first. The internal ring is identified lateral to the medial umbilical ligament. The vas and testicular vessels are identified entering the ring. Next, the internal ring of the affected side is identified. Blind ending testicular vessels are indicative of anorchia obviating the need for any further intervention. In the rare case with a blind ending vas, identification of the testicular vessels should still be performed as an undescended testis may still be present and may be identified at the termination of the testicular vessels. Alternatively, intra-abdominal testis peeping into the inguinal canal or inguinal testis may be identified. At times, identification of the abdominal testis may require medial reflection of the right colon. Two secondary 2 mm ports are inserted and the line of Toldt is incised, and the right colon is reflected medially. Following identification of intra-abdominal testis therapeutic options include orchiectomy, one-stage or two-stage orchiopexy. For inguinal testis, inguinal exploration may be performed needlescopically or open surgically. The testicular vessels are mobilized, and the gubernaculum is divided. A scrotal incision is then made and the testis is transferred into the scrotum where it is inserted into a subdartos pouch. A stay suture placed on the testis facilitates its transfer into the scrotum. A hemostat inserted through the scrotal incision grasps the stay suture and the testis is then delivered into the scrotum. Alternatively, a laparoscopic port may be introduced through the scrotal incision to facilitate transfer of the testis. During needlescopic dissection, the internal ring may be enlarged medially in order to achieve a more direct course to the scrotum. If needed, a Stephen Fowler orchiopexy or a two-staged orchiopexy may also be performed.

Results

Gill et al. reported their results following 12 needlescopic procedures for cryptorchidism with nonpalpable testis (4). Following 12 diagnostic needlescopic explorations therapeutic interventions were performed in select cases. These included bilateral orchiopexy ($n = 2$), orchiectomy ($n = 2$), and excision of testicular remnant ($n = 2$). The average operative time was 1.8 hours (range, one to two hours), and the estimated blood loss was 6 mL (range, 0–20 mL).

Bladder Cuff Excision During Laparoscopic Radical Nephroureterectomy**Technique**

To begin with, a thorough cystoscopic examination is performed to rule out the presence of any concomitant bladder tumors. Two needlescopic ports are then inserted into the bladder suprapubically. A 2 mm endoloop tie is inserted through one of the ports and is placed over the targeted ureteral orifice. Following this, a ureteric catheter is inserted through the cystoscope. The catheter is inserted through the endoloop tie, into the targeted ureteral orifice. Now, the cystoscope is exchanged for a resectoscope with a Collins knife, and the 2 mm ports are hooked to wall suction to minimize the possibility of extravasation. Glycine is used as the irrigant. A 2 mm grasper is inserted through one of the suprapubic ports in order to retract the ureteral orifice anteromedially. The resectoscope with the Collins knife is then utilized to detach a full thickness bladder cuff. Traction applied by the suprapubically inserted 2 mm grasper facilitates dissection of 3–4 cm of distal ureter in this fashion. The detached ureteral orifice is then occluded with the previously positioned endoloop tie. The bladder is emptied, the 2 mm ports are removed, and a Foley catheter is left indwelling in the bladder. Formal closure of the bladder is not performed. Following this, the patient is positioned in the flank position for a retroperitoneoscopic radical nephrectomy.

Results

The above technique was reported by Gill et al. (5). The procedure was performed in 20 patients undergoing laparoscopic nephroureterectomy. The operative time for this maneuver was 59 minutes (range, 35–120 minutes). In one patient, extravasical extravasation was noted during the case, and the endoscopic procedure was aborted. Postoperative cystograms were obtained by one week. Mild extravasation was noted in one of the 20 patients, which resolved following catheter drainage of the bladder for an additional week.

Lymphocele Drainage**Technique**

Pelvic lymphoceles that are symptomatic and recur following percutaneous drainage are best treated by marsupialization into the peritoneal cavity. Laparoscopic lymphocele drainage entails a three-port transperitoneal approach. Large lymphocele are easily identified laparoscopically and appear as a visible bulge. Surface or intra-abdominal intraoperative ultrasound may be employed to facilitate precise localization of lymphoceles. The lymphocele wall is excised to facilitate a wide communication between the lymphocele and peritoneum. Lymphoceles that are superficially located, and those that are not associated with significant adhesions can be easily treated utilizing needlescopic instruments.

Results

Gill and colleagues reported their results following needlescopic lymphocele drainage in three patients (6). The procedures were performed on an outpatient basis. Mean operative time was 118.3 minutes, and estimated blood loss ranged from 10–50 mL.

Renal Cyst Drainage**Technique**

Marsupialization of simple renal cysts may be offered to patients with symptomatic renal cysts. For cysts that are anteriorly located, needlescopic techniques may be employed. The procedure is performed through a three- or four-port transperitoneal approach. A 5 mm port is inserted at the umbilicus from the outset of the procedure and a 5 mm laparoscope is inserted through the umbilical port. The other ports are of needlescopic size. The colon is reflected medially, and the Gerota's fascia is incised to expose

the cyst. The cyst is drained and the cyst wall is excised. Occasionally, bleeding may be encountered from the residual cyst wall. A 5 mm argon beam coagulator inserted through the 5 mm port is utilized to achieve hemostasis. Next, a 2 mm needlescope is inserted through one of the lateral ports, and the excised cyst wall is extracted through the umbilical port.

Results

Gill and Colleagues reported their experience following three procedures (6). Average operative time was 1.7 hours, and mean estimated blood loss ranged from 10–200 mL. One case was converted to conventional laparoscopy to facilitate better hemostasis. Over a six-month period, one of the three patients developed a recurrent renal cyst, which was subsequently treated utilizing conventional laparoscopic techniques.

Minilaparoscopic Pyeloplasty

Minilaparoscopic pyeloplasty was reported by Tan (7). The procedure is performed utilizing 3 mm instruments inserted through 3.8 mm ports, and a 5 mm laparoscope. The procedure is performed utilizing a transperitoneal approach, and initial peritoneal access is obtained with a 6 mm Hasson cannula, which is inserted through the supraumbilical skin crease. An Anderson-Hynes dismembered pyeloplasty is performed utilizing a 6-0-polydioxane suture on a 3/8 circle round body needle. Initially, the posterior layer of the anastomosis is completed in a running fashion. Next, an antegrade ureteral stent is introduced and the suture is continued to complete the anterior layer of the anastomosis. In this manner, a running ureteropelvic anastomosis is performed. No drains are placed, and the fascia underlying the 5 mm port is closed. The bladder is drained with a catheter for a period of 24 hours. The procedure was performed in 18 patients. Average patient age was 17 months (range, 3 months to 15 years). Mean operative time was 1.5 hours. Complications included a trocar injury resulting in a hematoma, and a case of postoperative stent migration, which necessitated ureteroscopic extraction at six weeks. None of the cases were converted to open. During follow-up, 2 of the 18 patients needed to undergo repeat laparoscopic pyeloplasty for persistent ureteropelvic junction obstruction. Both these patients were less than three months of age at the time of the primary laparoscopic procedure.

BENEFITS AND LIMITATIONS

Minilaparoscopy is associated with a cosmetic advantage compared to conventional laparoscopy in which, port site incisions vary from 5–15 mm. A retrospective study comparing needlescopic and conventional laparoscopic adrenalectomy demonstrated lesser postoperative pain, decreased length of stay in the hospital, and a shorter convalescence associated with needlescopic surgery. Also, patients undergoing minilaparoscopic procedures can often be treated on an outpatient basis or in an office setting (8). Moreover, diagnostic minilaparoscopic procedures may be performed under local anesthesia, making this a versatile tool in the office or emergency/trauma room.

Minilaparoscopic instruments are ideally suited for handling finer structures and fine sutures, making them optimal for performance of delicate reconstructive laparoscopic procedures.

Compared to 5 and 10 mm laparoscopes utilized for conventional laparoscopy, image resolution with the minilaparoscopes is inferior. The minilaparoscopes have a short focal distance, and as a result need to be placed closer to the target object compared to conventional laparoscopes. This results in transmission of an image that is too bright. Minilaparoscopic instruments lack tensile strength and are not as sturdy as conventional laparoscopic instruments. As a result, this makes the performance of major ablative procedures rather cumbersome. Another limitation with minilaparoscopy is the limited selection of instruments presently available. These include the lack of some instruments that are essential to effectively performing any laparoscopic case including clip applicators, energy-based hemostatic devices, effective suction-irrigation systems, tissue retractors, and improved tissue-handling graspers.

CURRENT STATUS AND FUTURE POTENTIAL

Until date, numerous urologic procedures have been performed utilizing minilaparoscopic instruments. Minilaparoscopy is uniquely suited for the performance of procedures involving delicate tissue reconstruction, pediatric urologic procedures, and also

Minilaparoscopic instruments are ideally suited for handling finer structures and fine sutures, making them optimal for performance of delicate reconstructive laparoscopic procedures.

to obtain a superior cosmetic result. The size and tissue handling characteristics of mini-laparoscopic instruments make them ideal for handling delicate tissues and fine sutures. These instruments are akin to microsurgical instruments utilized during open surgery. It has been our observation from experience in the laboratory that complex urologic vascular reconstructive procedures can be successfully performed utilizing mini-laparoscopic instruments (9). With the aid of 3 mm instruments we demonstrated the feasibility of performing laparoscopic renal autotransplantation in a porcine survival model. Vascular anastomoses were performed utilizing 5-0 prolene sutures. In addition to facilitating manipulation of delicate vascular tissue, the 3 mm grasper and needle driver permit precise suture placement and suture handling. There is minimal suture fraying as often encountered with the use of conventional laparoscopic instruments.

SUMMARY

- The role of laparoscopy in pediatric urology is, at present, limited. The ability to perform major abdominal surgery through small-sized open surgical incisions has resulted in limited application of laparoscopy in pediatric urology. Incisions measuring 5–10 mm for each port site are rather large in the pediatric population. Utilization of minilaparoscopic instrumentation in this scenario would be cosmetically advantageous and also would afford appropriate handling of delicate pediatric tissues.
- Performance of fine reconstructive laparoscopic procedures will require the development of finer instruments, in the minilaparoscopic range.
- Continued development of minilaparoscopic technology and growing laparoscopic experience are likely to result in more widespread application of minilaparoscopy, either exclusively or in conjunction with conventional and robotic laparoscopic procedures to provide increased precision during laparoscopic tissue reconstruction and to improve cosmetic outcomes.

REFERENCES

1. Dorsey JH, Tabb CR. Mini-laparoscopy and fiber-optic lasers. *Obstet Gynecol Clin North Am* 1991; 18(3):613–617.
2. Gow JG. Harold Hopkins and optical systems for urology—an appreciation. *Urology* 1998; 52(1):152–157.
3. Gill IS, Soble JJ, Sung GT, Winfield HN, Bravo EL, Novick AC. Needlescopic adrenalectomy—the initial series: comparison with conventional laparoscopic adrenalectomy. *Urology* 1998; 52(2):180–186.
4. Gill IS, Ross JH, Sung GT, Kay R. Needlescopic surgery for cryptorchidism: the initial series. *J Pediatr Surg* 2000; 35(10):1426–1430.
5. Gill IS, Soble JJ, Miller SD, Sung GT. A novel technique for management of the en bloc bladder cuff and distal ureter during laparoscopic nephroureterectomy. *J Urol* 1999; 161(2):430–434.
6. Gill IS. Needlescopic urology: current status. *Urol Clin North Am* 2001; 28(1):71–83.
7. Tan HL. Laparoscopic Anderson-Hynes dismembered pyeloplasty in children using needlescopic instrumentation. *Urol Clin North Am* 2001; 28(1):43–51.
8. Mazdisnian F, Palmieri A, Hakakha B, Hakakha M, Cambridge C, Lauria B. Office microlaparoscopy for female sterilization under local anesthesia. A cost and clinical analysis. *J Reprod Med* 2002; 47(2):97–100.
9. Meraney AM, Gill IS, Kaouk JH, Skacel M, Sung GT. Laparoscopic renal autotransplantation. *J Endourol* 2001; 15(2):143–149.

Amy E. Krambeck and Matthew T. Gettman

Department of Urology, Mayo Clinic College of Medicine, Rochester, Minnesota, U.S.A.

- INTRODUCTION
- UPPER URINARY TRACT
 - Robotic Pyeloplasty
 - Robotic Adrenalectomy
 - Robotic Nephrectomy
 - Robotic Donor Nephrectomy

- LOWER URINARY TRACT
 - Robotic Radical Cystectomy and Urinary Diversion
 - Sacrocolpopexy
- CONCLUSION
- REFERENCES

INTRODUCTION

The development and increased acceptance of laparoscopic techniques for a variety of extirpative and reconstructive procedures have revolutionized the practice of urology. As highlighted in multiple chapters of this text, urologic laparoscopy has provided multiple patient-related benefits including decreased pain, shortened convalescence, earlier return to work, and improved cosmesis. Conventional laparoscopy can limit surgical performance secondary to visualization of three-dimensional images on a flat two-dimensional screen, limited instrument maneuverability, and reduced dexterity in comparison to open surgery. Furthermore, training opportunities to learn laparoscopic urology are relatively limited. In addition, laparoscopic techniques such as intracorporeal suturing can be more difficult to perform than corresponding tasks in open surgery. The increased difficulty of conventional laparoscopy has prompted a variety of technologic enhancements designed to address performance deficiencies of the standard techniques and possibly increase clinical applicability.

As previously discussed elsewhere in the text, surgical robots can address the performance limitations of standard laparoscopy. In addition, surgical robots may increasingly provide an opportunity for “untrained” urologists to perform complex urologic techniques. While telesurgical robots such as the *da Vinci*® Surgical System^a have been utilized predominantly for radical prostatectomy, other robotic applications have been described and increasingly performed for indications in the upper and lower urinary tract. Unfortunately, a common thread to essentially all of these other robotic techniques is limited clinical experience. This chapter will review the current status of robotics for other urologic applications in the upper and lower urinary tract.

UPPER URINARY TRACT

Robotic Pyeloplasty

There are a myriad of treatments for ureteropelvic junction obstruction. Open pyeloplasty is associated with the highest success rate, up to 95% (1). Unfortunately, it requires a sizeable muscle incision and is associated with considerable postoperative pain and convalescence. Since the 1980s, various techniques of antegrade and retrograde endopyelotomy were introduced as less invasive treatment options for primary and secondary ureteropelvic junction obstruction. While these techniques are faster and less morbid than open surgery, overall success rates for all endopyelotomy techniques remain lower than those for open pyeloplasty (2).

^aIntuitive Surgical, Sunnyvale, CA.

In an attempt to merge the high success rates of pyeloplasty with the advantages of minimally invasive surgery, the techniques of laparoscopic pyeloplasty were developed. These techniques report success rates comparable to open pyeloplasty without the morbidity of a large flank incision (3). Unfortunately, there is a steep learning curve associated with this approach and despite advancements in instrumentation, laparoscopic pyeloplasty remains one of the more difficult procedures performed by urologists. Robotics has been applied to pyeloplasty in an attempt to simplify the laparoscopic technique yet maintain the benefits of minimally invasive surgery.

Telerobotic laparoscopic pyeloplasty has been performed in the animal model and clinically. Sung et al. first evaluated efficacy and feasibility of robotic dismembered pyeloplasty in the animal model (4). In the study, five female farm pigs were prospectively randomized and laparoscopic pyeloplasty performed with or without the Zeus robotic system. When comparing robotic procedures to conventional laparoscopy, no significant differences in operative time, suturing time, or total number of suture bites per ureter were reported (4). Sung et al. concluded that the Zeus-assisted robotic approach was feasible and could be used for clinical application. In the experimental model, Sung and Gill subsequently compared laparoscopic pyeloplasty performed with either the Zeus robotic system or the *da Vinci* robotic system. They found that *da Vinci*-assisted pyeloplasties were associated with shorter overall operative times, shorter anastomotic times, and an increased number of suture bites per ureter (5). The conclusion was either system could be used for robotic pyeloplasty; however, the researchers thought that the *da Vinci* robotic system was more intuitive. These early experimental studies at Cleveland Clinic provided a foundation for clinic application of robotic pyeloplasty.

Robot-assisted laparoscopic pyeloplasty has been performed clinically using either the *da Vinci* robotic system or the Zeus robotic system (6–9). The only system currently supported for performance of robotic pyeloplasty is the *da Vinci* robotic system. The indications for robotic pyeloplasty are the same as those described for the conventional laparoscopic technique. Robotic pyeloplasty can be performed for patients with both primary and secondary ureteropelvic junction obstruction. In addition, robotic pyeloplasty can be safely performed in the presence of crossing vessels, a redundant renal pelvis, and intrinsic or extrinsic obstruction (6–9). Patients that have previously failed open pyeloplasty are not ideal candidates for this procedure. In addition, patients with poorly functioning obstructed kidney and those with a relatively small intrarenal pelvis are not ideal candidates.

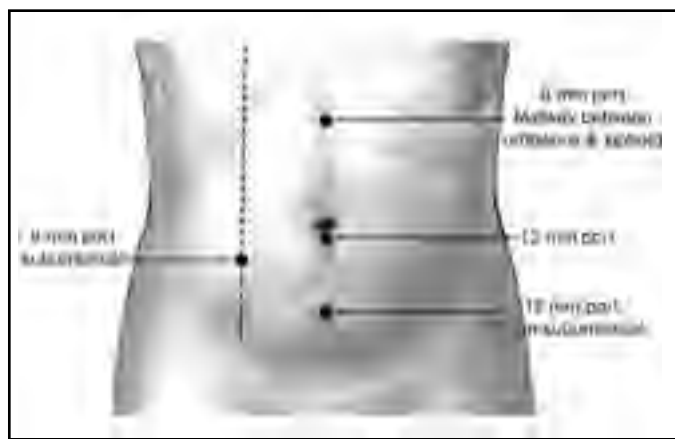
The most commonly performed technique for robotic pyeloplasty utilizes the *da Vinci* robotic system. The procedure is performed using four transperitoneal ports with the patient in a 45° lateral decubitus position (Fig. 1). A standard 12 mm port is inserted at the umbilicus for placement of the laparoscope. Two 8 mm robotic ports are then placed as well as another standard 12 mm laparoscopic port for the assistant surgeon. The robotic system is then installed, and all operative steps are performed solely using the *da Vinci* robotic system.

For renal exposure, the line of Toldt is incised and the large intestine is retracted medially. While mobilization of the descending colon is commonly preferred for exposure of the left ureteropelvic junction obstruction, a transmesenteric approach has also been described for thin patients. Exposure of the ureteropelvic junction obstruction is commonly performed using a Prograsp or Cadiere forceps on the left robotic arm and the hook electrode on the right robotic arm. Next, either a nondismembered Fenger-plasty or an Anderson–Hynes-dismembered pyeloplasty is performed based on the type of ureteropelvic junction obstruction encountered. Regardless of the technique utilized, the surgical indication and the operative steps of robotic pyeloplasty mirror the steps described for conventional laparoscopic pyeloplasty. During the pyeloplasty procedure, a 7 French double pigtail stent is placed in an antegrade fashion over a guidewire into the ureter via the 12 mm assistant port (6,7).

Once the ureteropelvic junction repair is completed, displaced bowel is then repositioned anatomically and secured using 4-0 vicryl suture. Placement of a surgical drain is recommended only in certain surgical situations and is up to the discretion of the individual surgeon. The ureteral stents are left in place for six weeks, at which time they are removed via a cystoscopic approach.

Clinical experience with robotic pyeloplasty is limited but encouraging. Based on an initial report of nine patients undergoing laparoscopic Anderson–Hynes pyeloplasty with the *da Vinci* system, Gettman et al. reported a mean operative time of 139 minutes, mean suturing time of 62 minutes, and a 100% success rate at short-term follow-up (6).

FIGURE 1 ■ Port placement for robotic-assisted pyeloplasty. The 12-mm port for the camera is placed at the umbilicus. The 8-mm robotic ports are placed midway between the umbilicus and xiphoid in the midline and pararectally just below the level of the umbilicus. The 12-mm assistant port is placed at least 5 cm below the umbilicus in the midline.



Robot-assisted procedures have also been reported as advantageous when compared to traditional laparoscopic pyeloplasty with regards to mean operative time and mean suturing time (7). When patients undergoing *da Vinci*-assisted laparoscopic Fenger-plasty or Anderson–Hynes pyeloplasty were compared to patients undergoing purely laparoscopic procedure, the *da Vinci*-assisted procedures were associated with shorter operative times and decreased suturing times. Furthermore, the magnitude of improvement was greatest for patients treated with the more difficult Anderson–Hynes repair (7). A report by Bentas et al. further supports the clinical applicability of robotic pyeloplasty. In this series, 11 patients underwent a *da Vinci*-assisted laparoscopic Anderson–Hynes pyeloplasty with no intraoperative complications or open conversions (8). At one-year follow-up, the group reported 100% success rate. Interestingly, the group from Frankfurt had no formal training in laparoscopic surgery before successfully embarking on these types of robotic procedures.

Robotic pyeloplasty appears to be gaining momentum as a definitive treatment of ureteropelvic junction obstruction. The use of robotics negates most of the technical disadvantages associated with the traditional laparoscopic procedure, yet still provides a successful, minimally invasive treatment. Additional clinical experience, however, is needed from investigators at multiple centers with varying degrees of laparoscopic experience to define the exact role of robotic pyeloplasty among other treatment options for ureteropelvic junction obstruction.

Robotic Adrenalectomy

Adrenalectomy has historically been a significantly morbid procedure due to the deep location of the adrenal glands in the retroperitoneum. Laparoscopy has significantly decreased the morbidity associated with this operation, and laparoscopic adrenalectomy is now the recommended gold standard for the majority of adrenal disorders requiring surgery. Despite this transition to minimally invasive surgery, the incidence of disease processes requiring laparoscopic adrenalectomy is quite low and can potentially limit acquisition of skills necessary to perform the procedure. Laparoscopic adrenalectomy requires a delicate dissection of the adrenal gland as well as the adrenal veins and arteries. Given the somewhat restricted location of the adrenal gland and the careful dissection needed for successful removal, techniques of robot-assisted laparoscopic adrenalectomy have been reported in experimental models and clinically.

Gill et al. demonstrated the feasibility of robotic adrenalectomy using the porcine model in 2000 (10). Using the Zeus robotic system, the Cleveland Clinic group successfully performed four robotic adrenalectomies. During one robotic adrenalectomy, an injury to the inferior vena cava required telorobotic suturing with 5-0 prolene suture. None of the remaining procedures were associated with complications, but the operative time for robotic adrenalectomy was roughly double the time required to perform the conventional laparoscopic procedure. In another experimental study comparing the Zeus robotic system to the *da Vinci* robotic system, Sung and Gill reported that robotic adrenalectomy was more intuitive with the *da Vinci* system, and that operative times using this system were significantly shorter than those reported with the Zeus robotic system (5).

The first clinical use of the *da Vinci* robotic system for robotic adrenalectomy was reported by Kim et al. in August, 2000 (11). Shortly thereafter, the first bilateral *da Vinci*-assisted adrenalectomy was reported in a human by Horgan and Vanuno (12). They reported their overall experience using the *da Vinci* system in 34 patients including the one patient in whom successful bilateral adrenalectomies were performed (12). Others have since reported their experience in performing robot-assisted adrenalectomy, yet overall available clinical data is limited (13,14). Given the limited clinical experience with robotic adrenalectomy, specific indications have not been clearly defined. It would be anticipated, however, that the indications for robotic adrenalectomy would be the same as the current indications for traditional laparoscopic adrenalectomy. Currently, robotic adrenalectomy has been limited to tumors <6 cm in diameter. The specific indications for the reported cases have included pheochromocytoma, active and inactive adenomas, and adrenal metastasis.

The technique of robotic adrenalectomy has been performed through a four or five port transperitoneal approach with the patient placed in a 45° lateral decubitus position. Port placement and the operative steps of robotic adrenalectomy are very similar to those performed for conventional laparoscopic adrenalectomy.

Bentas et al. reported one of the initial clinical experiences with *da Vinci*-assisted adrenalectomy in 2002 (13). Among the series of four patients undergoing robotic adrenalectomy, the mean tumor size was 3.8 cm, blood loss was minimal, and operative time ranged from 160 to 330 minutes. No intraoperative complication or open conversions were reported (13). Desai et al. also reported their experience with two patients and again noted minimal blood loss during the *da Vinci*-assisted procedures (14). However, they did report an adrenal capsular tear secondary to lack of tactile feedback with the *da Vinci* robot system and concluded that this was a technical disadvantage of the robotic technique when compared to the conventional laparoscopic or open adrenalectomy technique.

Perhaps the largest series to date on robotic adrenalectomy was published by Brunaud et al. (15). This prospective randomized study compared *da Vinci* unilateral adrenalectomy with the standard laparoscopic procedure. Fourteen patients were enrolled in each arm of the study for a total of 28 unilateral adrenalectomies. Mean operative time was longer with the *da Vinci* system (111 minutes vs. 83 minutes). Interestingly, operative time required for conventional laparoscopic procedures correlated with body mass index, whereas operative time required for robotic adrenalectomy did not correlate with body mass index. Additionally, operating time with the *da Vinci* system decreased later in the study as the surgeon's experience with the procedure increased. There were no significant differences between the two procedures with regards to open conversion rate (7% for both), morbidity, or duration of hospitalization (6.8 days) (15). Despite early reports showing feasibility of robotic adrenalectomy, further study is needed with greater patient enrollment to assess the true benefit of robotic versus laparoscopic adrenalectomy and specific indications for the robotic procedure.

Robotic Nephrectomy

Advanced robotic technology has previously been utilized for nephrectomy in clinical and experimental studies (5,10,16). Bowersox and Cornum initially evaluated a prototype master-slave robotic system for open nephrectomy, cystotomy closures, and ureteroureterostomies (16). Using the experimental system, all procedures were successful, and no intraoperative complications were encountered. Prolonged operative times were one disadvantage suggested by the authors for the experimental robotic system. Using the Zeus robotic system, Gill et al. first reported feasibility of laparoscopic telero-botnic nephrectomy and adrenalectomy in the animal model (10). In the study, the performance of standard laparoscopic nephrectomy and adrenalectomy was compared to that of the corresponding telero-botnic procedures in five farm pigs. The robot-assisted techniques required longer operative times, but the adequacy of surgical dissection and blood loss were equivalent.

The initial report of a telero-botnic laparoscopic nephrectomy in humans was reported by Guillonnet et al. using the Zeus robotic system in 2001 (17). All steps of telero-botnic nephrectomy were successfully performed with the robotic system. The procedure was safely performed with an operative time of 200 minutes and an estimated blood loss of <100 cc (17). To date, there remains a paucity of published results for robotic nephrectomy performed with either the *da Vinci* robotic system or the Zeus robotic system. Robotic nephrectomy has been slow to gain wide clinical acceptance, possibly related to the complexity of the procedure. The procedure requires that the

assistant surgeon perform essential steps of the operation including ligation of the renal vessels and placing the specimen in the retrieval bag. Thus, the assistant surgeon must possess advanced laparoscopic skills to perform the procedure.

Robotic Donor Nephrectomy

Laparoscopic donor nephrectomy is the new gold standard for kidney donation at many transplant centers. The development of laparoscopic donor nephrectomy has been revolutionary, yet increased operating room time and retrieval of shorter donor vessels especially in the early learning curve have been suggested as technical concerns (18,19). With the introduction of telerobotic surgical systems, some investigators have hypothesized that the enhanced dexterity and improved optics of systems like *da Vinci* may remedy reported technical concerns and thereby improve operative performance of laparoscopic donor nephrectomy. Using this premise, the initial clinical series of robot-assisted donor nephrectomies were reported by Horgan et al. in 2002 (18).

The indications and operative techniques for robotic donor nephrectomy are similar to those used for the standard laparoscopic procedure; however, to date the robotic technique has been utilized only for left donor nephrectomies. Robotic donor nephrectomy also utilizes both the *da Vinci* robotic system and the laparoscopic hand-assist device (18,19). After placing the patient in a 45° lateral decubitus position, a 7 cm infraumbilical incision is first made for the hand-port device, and four trocars (two reusable robotic trocars and two 10 mm standard trocars) are then positioned on the left side of the abdomen. During the robotic procedure, the assistant surgeon performs important standard laparoscopic maneuvers including retraction and exposure, division of the renal artery and vein, and removal of the kidney through the hand-port device.

In the initial report of 10 patients undergoing robot-assisted laparoscopic donor nephrectomy, Horgan et al. reported a mean operative time of 166 minutes and a mean estimated blood loss of 68 mL (18). The mean warm ischemia time was 85 seconds and all kidneys were functional upon transplantation. There were no intraoperative complications and no open conversions. In a related report, Horgan et al. compared the results of 12 robotic donor nephrectomies to 23 standard laparoscopic donor nephrectomies and 25 open donor nephrectomies (19). While the mean operative time was 50 minutes longer using the robotic technique, the authors reported multiple technical advantages including a three-dimensional view of the operative field and enhanced dexterity, which improved dissection of the vessels and allowed early identification of the ureter. The authors also reported that dissection of the upper pole was simplified by the articulating wrists of the *da Vinci* system (19).

LOWER URINARY TRACT

Robotic Radical Cystectomy and Urinary Diversion

Building on the clinical experience with *da Vinci*-assisted laparoscopic radical prostatectomy, the use of robotics has expanded to include extended pelvic lymph node dissections and radical cystectomy with urinary diversion. The current indications for robotic cystectomy are the same as those reported for laparoscopic radical cystectomy. Patients with large bulky tumors and obvious extravesical disease are not ideal candidates. Robotic cystectomy has now been reported in both men and women with or without a concurrent nerve-sparing technique using either an ileal conduit or an ileal neobladder urinary diversion (20–23).

Although minor variations have been reported among institutions, the technique of robotic cystectomy closely follows the operative steps of conventional laparoscopic radical cystectomy. After the patient is placed in dorsal lithotomy position and then steep Trendelenburg, five or six transabdominal ports are placed in similar fashion as for robotic prostatectomy. All steps of extended bilateral lymph node dissection and radical cystectomy can be performed solely with the *da Vinci* robotic system. The urinary diversion can then be performed entirely in an open fashion via the specimen extraction incision, entirely intracorporeally using only the *da Vinci* robot, or in combination with open and minimally invasive techniques (20–23).

Beecken et al. reported the first case of *da Vinci*-assisted laparoscopic cystectomy with intracorporeal formation of the ileal neobladder (20). The procedure was performed with an overall operative time of 510 minutes and an estimated blood loss was <200 cc. The *da Vinci* robot facilitated intracorporeal suturing for the urethral

anastomosis, construction of the neobladder, and the ureteroileal anastomosis (20). Bowel continuity was reestablished after a minilaparotomy was performed for specimen removal. Yohannes et al. reported some of the first cases of laparoscopy-assisted robotic cystoprostatectomy with ileal conduit urinary diversion for organ-confined urothelial carcinoma (21). The *da Vinci* robot was employed to perform bilateral lymph node dissection, cystoprostatectomy, and ileoureteral anastomosis. Total operative times were 600 and 720 minutes with blood loss of 435 and 1800 mL, respectively (21).

With a larger clinical experience, operative times and estimated blood loss have improved. Menon et al. reported a series of 14 nerve-sparing robot-assisted radical cystoprostatectomies with urinary diversion (22). The *da Vinci* system was utilized to perform all aspects of the surgery except for the urinary diversion, which was performed extracorporeally. For those undergoing an orthotopic neobladder, the *da Vinci* was also utilized to perform the urethrovaginal anastomosis. Mean operative time for the nerve-sparing cystoprostatectomy was 140 minutes and average blood loss for the entire procedure less than 150 mL. One complication of unexplained blood loss requiring exploration was reported (22). Results are currently not available in regard to postoperative continence and erectile function.

Robot-assisted female cystectomy with preservation of the uterus and vagina has been recently reported (23). Menon et al. published their series of three patients, for which the *da Vinci* robot was utilized to perform the cystectomy and urethrovaginal anastomosis. Posterior mobilization of the bladder via the cul-de-sac of Douglas facilitated preservation of the uterus and vagina. Urinary reconstruction was performed extracorporeally through a small midline incision. Average operating time for the cystectomy was 160 minutes with mean blood loss of less than 100 mL (23). It is known that the pneumoperitoneum created during laparoscopic and robotic procedures helps to reduce vascular bleeding. The group reasoned that the superior hemostasis afforded by the robotic system allowed them to avoid the significant vaginal bleeding that often accompanies reproductive sparing female cystectomies (23).

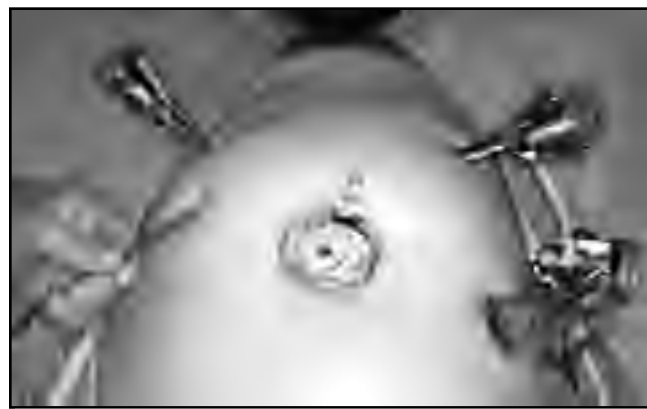Although the procedure has yet to demonstrate a decrease in length of hospitalization or length of overall procedure time, robot-assisted cystectomy appears to have a favorable clinical future. Those that perform this procedure have sited it to be technically much simpler than laparoscopic cystectomy or even robot-assisted radical prostatectomy. Additionally, the benefits of limited patient morbidity, cosmesis, and superb hemostasis as well as visualization provided by the robotic system cannot be ignored. We anticipate robot-assisted cystectomy to become more widely performed now that a standard technique has been described and demonstrated to be safe and effective.

Sacrocolpopexy

The current gold standard treatment for posthysterectomy vaginal vault prolapse is abdominal sacrocolpopexy. This technique involves suspending the vaginal vault anteriorly, posteriorly, or by closing the levator hiatus by an abdominoperineal approach. These open procedures are associated with significant morbidity and extended hospital stays. A vaginal approach was developed in an attempt to decrease morbidity associated with sacrocolpopexy; however, the success rates are consistently less than the abdominal technique (24). Laparoscopic sacrocolpopexy was developed to mimic the open procedure while decreasing the accompanying morbidity. Unfortunately, these procedures have been performed with significant difficulty and lengthy operating times, especially early in the learning curve (25). DiMarco et al. reported the first series of five robot-assisted laparoscopic sacrocolpopexies (24). The attempt was to reap the minimal invasive benefits of laparoscopic sacrocolpopexy while simplifying the procedure and decreasing operating room time.

Robotic sacrocolpopexy is indicated for vaginal vault prolapse after hysterectomy. Currently, the procedure has only been performed in grade 3–4 apical prolapse and grade 2–4 anterior prolapse. The preferred patient has had no or minimal prior abdominal surgeries. A transperitoneal approach is utilized after placement of five laparoscopic ports (Fig. 2). Robotic sacrocolpopexy follows similar operative steps as those performed with laparoscopic sacrocolpopexy (25). Retraction of the sigmoid colon and a steep Trendelenburg position provide exposure of the sacral promontory and vagina. Using the Cadie forceps and the hook electrocautery, the anterior vagina is dissected from the bladder. A customized vaginal retractor aids in dissection (24). Next, the peritoneal reflection is incised posteriorly to further mobilize the

FIGURE 2 ■ Port placement for robotic-assisted sacrocolpopexy. The 12-mm port for the camera is placed at the umbilicus. A 12-mm assistant port is placed subcostally lateral to the rectus and a 5-mm assistant port is placed one handbreadth inferior-laterally. The 8-mm robotic ports are placed lateral to the rectus two fingerbreadths superior to the iliac crest.



vagina. Anterior and posterior dissection is then carried out distally toward the introitus. The sacral promontory is now exposed by incision of the posterior peritoneum. Care should be taken to avoid injury to the sacral veins. A Silastic Y-graft is brought into the abdomen through a 10 mm port. Using the *da Vinci* robot system, the graft is sutured to the posterior vagina and then the anterior vagina using 1.0 Gore-Tex suture. The use of a 30° lens maximizes visualization. The tail of the graft is then sutured to the sacral promontory. There should be minimal tension on the vagina. The ureterosacral ligaments are then plicated and the posterior peritoneum closed over the graft.

In the initial series of five patients, DiMarco et al. reported an average operating time of 225 minutes. Hospital stay was 24 hours for all patients and none had recurrent prolapse at four-month follow-up (24). One complication of persistent vaginal bleeding was reported; however, this was attributed to a concurrently performed pubovaginal sling. While the technique of robotic sacrocolpopexy is now standardized, additional clinical experience is needed to fully understand the indications and limitations of the technique. This procedure is still in its infancy and as of yet long-term results are not available. Nonetheless, initial results have shown promise for robotic sacrocolpopexy and the technique appears to have important clinical implications in the future.

CONCLUSION

Aside from robot-assisted laparoscopic radical prostatectomy, clinical utilization of robotic systems for a variety of procedures in the upper and lower urinary tract is still in its infancy. Surgical techniques and feasibility of multiple robotic procedures have been described, but the data currently available is limited to small case series with little long-term follow-up. Telerobotic surgical systems were introduced to address the technical limitations of standard laparoscopy. The current robotic systems provide three-dimensional visualization of the operative field, improved dexterity (with tremor filtering and motion scaling software), and increased range of motion compared to standard laparoscopy. The benefit of these performance features appears greatest when performing advanced laparoscopic dissection techniques (i.e., prostatectomy and cystectomy) or intracorporeal suturing (i.e., pyeloplasty, prostatectomy, urinary diversion, and sacrocolpopexy); however, a clinical advantage remains scientifically unproven at this time.

In the skills laboratory, Yohannes et al. have previously shown that learning how to suture is faster with *da Vinci* than with standard laparoscopy (26). Furthermore, the investigators reported novice laparoscopists learned suturing with the robot quicker than experienced laparoscopists. Clinically, multiple centers have also successfully used robotics to perform complex laparoscopic tasks without any formal training in minimally invasive surgery (8,22,23). For instance, Bentas et al. had no experience with laparoscopic pyeloplasty before successfully embarking on their *da Vinci*-assisted procedures (8). In general, they concluded that telerobotics enabled inexperienced urologists to perform complex reconstructive procedures with more confidence and better results than could be obtained with standard laparoscopy. Nonetheless, a paucity of prospective randomized trials is currently

available to compare outcomes of laparoscopic surgery performed with or without telerobotics (15). This information would be helpful in defining the role of robotics for "trained" and "untrained" laparoscopists.

Limits are also currently present with telerobotics. Critical performance features are lacking with robotic surgery including even gross tissue palpation and force feedback. So, robotic surgery must be performed with increased reliance on visual versus tactile inputs. Telerobotic surgery is also associated with a significant learning curve not only for the operating surgeon but also more significantly for the operating room staff. An attempt should be made to establish a robotics "team" when embarking on these surgical procedures. In contrast to standard laparoscopy, the importance of the surgical assistant is critical to the flow of robotic surgery. Using standard laparoscopic instruments, the assistant surgeon is depended on to provide traction/countertraction, apply hemostatic clips, and introduce and remove suture. For this reason, the assistant surgeon must be proficient with at least basic laparoscopic tasks. At the present time, robotic surgery also utilizes more resources than standard laparoscopy. For instance, two surgeons are needed when performing robotic surgery: one at the remote control unit and one scrubbed at the operating table. Initial capital expenditures and per case costs are also more expensive at the present time for robotic surgery.

Robotic technologies have been recently introduced with fanfare, but increased clinical application and critical evaluation are needed. Robotics appears best targeted for complex laparoscopic tasks requiring delicate dissection or intracorporeal suturing. Robotics has already succeeded in increasing clinical applicability by permitting "untrained" open surgeons to perform complex laparoscopic tasks (8,22,23). Nonetheless, deficiencies currently exist for robotics, and the learning curve is not insignificant. With the anticipated introduction of improved robotic technologies and other technologies in the information age, the ongoing value of robotics must be carefully evaluated and proven to optimally benefit patient care.

REFERENCES

1. Brooks JD, Kavoussi LR, Preminger GM, et al. Comparison of open and endourologic approaches to the obstructed ureteropelvic junction. *Urology* 1995; 46:791-795.
2. Kim FJ, Herrell SD, Jahoda AE, et al. Complications of Acucise endopyelotomy. *J Endourol* 1998; 12:433-436.
3. Janetschek G, Peschel R, Bartsch G. Laparoscopic Fenger plasty. *J Endourol* 2000; 14:889-893.
4. Sung GT, Gill IS, Hsu TH. Robotic-assisted laparoscopic pyeloplasty: a pilot study. *Urology* 1999; 53:1099-1103.
5. Sung GT, Gill IS. Robotic laparoscopic surgery: a comparison of the daVinci and Zeus systems. *J Urol* 2001; 58:893-898.
6. Gettman MT, Neururer R, Bartsch G, et al. Anderson-Hynes dismembered pyeloplasty performed using the daVinci robotic system. *Urology* 2002; 60:509-513.
7. Gettman MT, Peschel R, Neururer R, et al. Laparoscopic pyeloplasty: comparison of procedures performed with the daVinci robotic system versus standard techniques. *Eur Urol* 2002; 42:453-458.
8. Bantas W, Wolfram M, Brautigam R, et al. daVinci robot assisted Anderson-Hynes dismembered pyeloplasty: technique and 1 year follow-up. *World J Urol* 2003; 21:133-138.
9. Yohannes P, Burjonrappa SC. Laparoscopic Anderson-Hynes dismembered pyeloplasty using the daVinci robot: technical considerations. *J Endourol* 2003; 17:79-83.
10. Gill IS, Sung GT, Hsu TH, Meraney AM. Robotic remote laparoscopic nephrectomy and adrenalectomy: the initial experience. *J Urol* 2000; 164:2082-2085.
11. Kim VB, Chapman WHH III, Albrecht RJ, et al. Early experience with telemanipulative robotic-assisted laparoscopic cholecystectomy using the daVinci. *Surg Laparosc Endosc Percutan Tech* 2002; 12:33-40.
12. Horgan S, Vanuno D. Robotics in laparoscopic surgery. *J Laparo Adv Surg Tech A* 2001; 11:415-419.
13. Bantas W, Wolfram M, Brautigam R, et al. Laparoscopic transperitoneal adrenalectomy using a remote-controlled robotic surgical system. *J Endourol* 2002; 16:373-376.
14. Desai MM, Gill IS, Kaouk JH, et al. Robotic-assisted laparoscopic adrenalectomy. *Urology* 2002; 60:1104-1107.
15. Brunaud L, Bresler L, Ayav A, et al. Advantages of using robotic daVinci system for unilateral adrenalectomy: early results. *Ann Chir* 2003; 128:530-535.
16. Bowersox JC, Cornum RL. Remote operative urology using a surgical telemanipulator system: preliminary observations. *Urology* 1998; 52:17-22.
17. Guillonneau B, Jayet C, Tewari A, et al. Robot assisted laparoscopic nephrectomy. *J Urol* 2001; 166:200-201.
18. Horgan S, Vanuno D, Benedetti E. Early experience with robotically assisted laparoscopic donor nephrectomy. *Surg Laparosc Endosc Percutan Tech* 2002; 12:64-70.

19. Horgan S, Vanuno D, Sileri P, et al. Robotic-assisted laparoscopic donor nephrectomy for kidney transplantation. *Transplantation* 2002; 73:1474–1479.
20. Beecken WD, Wolfram M, Engl T, et al. Robotic-assisted laparoscopic radical cystectomy and intra-abdominal formation of an orthotopic ileal neobladder. *Eur Urol* 2003; 44:337–339.
21. Yohannes P, Puri V, Yi B, et al. Laparoscopy-assisted robotic radical cystoprostatectomy with ileal conduit urinary diversion for muscle-invasive bladder cancer: initial two cases. *J Endourol* 2003; 17:729–732.
22. Menon M, Hemal AK, Tewari A, et al. Nerve-sparing robotic-assisted radical cystoprostatectomy and urinary diversion. *BJU Int* 2003; 92:232–236.
23. Menon M, Hemal AK, Tewari A, et al. Robot-assisted radical cystectomy and urinary diversion in female patients: technique with preservation of the uterus and vagina. *J Am Coll Surg* 2004; 198:386–393.
24. DiMarco DS, Chow GK, Gettman MT, et al. Robotic-assisted laparoscopic sacrocolpopexy for treatment of vaginal vault prolapse. *Urology* 2004; 63:373–376.
25. Antiphon P, Elard S, Benyoussef A, et al. Laparoscopic promontory sacral colpopexy: is the posterior, recto-vaginal, mesh mandatory? *Eur Urol* 2004; 45:655–661.
26. Yohannes P, Rotariu P, Pinto P, et al. Comparison of robotic versus laparoscopic skills: is there a difference in the learning curve? *Urology* 2002; 60:39–45.

SECTION **IX**

**LAPAROSCOPIC COMPLICATIONS:
ETIOLOGY, PREVENTION,
MANAGEMENT**

VASCULAR COMPLICATIONS DURING UROLOGIC LAPAROSCOPY

James R. Porter

Department of Urology, University of Washington Medical Center, Seattle, Washington, U.S.A.

■ INTRODUCTION

■ FREQUENCY OF LAPAROSCOPIC VASCULAR INJURY

■ ACCESS-RELATED INJURY

■ SUMMARY

■ REFERENCES

Of the major complications associated with urologic laparoscopic surgery, vascular injuries are the most common. They can also become the most devastating complications during laparoscopic procedures resulting in significant morbidity and death.

INTRODUCTION

Of the major complications associated with urologic laparoscopic surgery, vascular injuries are the most common (1–3). They can also become the most devastating complications during laparoscopic procedures resulting in significant morbidity and death.

These injuries often attract legal attention, and in one report, 62% of legal cases involving vascular injuries were settled in favor of the plaintiff (4). Too often, however, fear of litigation eliminates the opportunity to assess the cause and learn from the experience of others, and therefore many vascular injuries go unreported making the true incidence higher than that reported in the literature (5,6).

FREQUENCY OF LAPAROSCOPIC VASCULAR INJURY

Vascular injuries may occur due to errors in dissection or from access-related injuries and have been reported in 1.6% to 4.7% of urologic laparoscopic procedures (Table 1). Several series have reported their experience with vascular injury during urologic laparoscopic procedures; however, some studies have failed to distinguish vascular injury due to dissection from that due to access injuries.

Gill et al. noted vascular injuries in 3 (1.6%) of 185 patients undergoing laparoscopic nephrectomy with two of the three injuries due to error in dissection (7). Fahlenkamp et al. reviewed the German experience with laparoscopic complications and found 40 vascular injuries in 2407 patients, making vascular injuries the most frequent complication in that report (1). Thiel noted six major vascular injuries during 274 transperitoneal laparoscopic cases for an incidence of 1.7% (8). All were venous dissection injuries, and the authors noted that vessel injury was more likely to occur during complex laparoscopic procedures in patients who had undergone previous surgery in the region. This concept was supported by a report by Meraney et al. who reviewed the complications of retroperitoneal laparoscopic surgery and noted seven vascular injuries in 404 patients for an incidence of 1.7% (9). Five of seven vascular injuries occurred during dissection and the majority of vascular injuries in this series occurred in patients who had previous abdominal surgery. Rassweiler et al. reported 22 vascular injuries out of 482 laparoscopic nephrectomies for a rate of 4.6% (10). Vascular complications during laparoscopic donor nephrectomy were recognized in 2.3% of cases and included stapler misfire in two, laparoscopic clip dislodgement in two, and vessel laceration during dissection in four patients (11). In a review of the Mayo Clinic experience with laparoscopic nephrectomy, vascular injury was the most common intraoperative complication (2). Four patients sustained dissection injuries and all required open conversion for control. There was one epigastric artery injury that was managed conservatively, bringing the total number of vascular injuries to 5 (1.8%). Finally, Siqueria et al. compiled their experience with major complications in 213 laparoscopic nephrectomies and reported 10 (4.7%) vascular injuries (3). Seven of the injuries were due to dissection errors

TABLE 1 ■ Laparoscopic Vascular Injuries from Urologic Series

Series (Ref.)	Procedure	Cases	Vascular injury	Type
Gill et al. (7)	Laparoscopic nephrectomy	185	3 (1.6%)	2-Dissection injury 1-Access injury
Thiel et al. (8)	Transperitoneal laparoscopy	274	6 (1.7%)	6-Dissection injury
Rassweiler et al. (9)	Laparoscopic nephrectomy	482	22 (4.6%)	Not reported
Fahlenkamp et al. (1)	Multiple	2407	40 (1.7%)	40-Dissection injury
Meraney et al. (10)	Retroperitoneal laparoscopy	404	7 (1.7%)	5-Dissection injury
Hsu et al. (11)	Donor nephrectomy	353	8 (2.3%)	4-Dissection injury 2-Stapler misfire 2-Clip dislodgment
Siqueira et al. (3)	Laparoscopic nephrectomy	213	10 (4.7%)	4-Dissection injury 3-Access injury 2-Stapler misfire 1-Clip dislodgment
Simon et al. (2)	Laparoscopic nephrectomy	285	5 (1.8%)	4-Dissection injury 1-Access injury

and three were related to problems with access. Five of the seven dissection injuries resulted in emergent open conversion.

In nonurologic laparoscopy, vascular injury appears to be less frequent and is usually associated with access-related injuries as compared to errors during dissection (Table 2). In a review by Usal et al., vascular injury was noted in 0.11% to 0.25% of laparoscopic general surgery procedures, and the majority of these injuries were due to trocar misplacement (12). Saville and Woods noted four (0.1%) vascular complications out of 3591 laparoscopic procedures and all were due to trocar injury (13). Another review of laparoscopic cholecystectomy and appendectomy revealed nine (0.07%) vascular injuries and all were due to either trocar or insufflation needle injury (14). In the gynecologic literature, vascular injury complicating laparoscopic procedures were reported in 0.68% to 1.2% of cases (5). Fruhwirth et al. reported nine vascular injuries during gynecological procedures for a vascular injury rate of 0.8%, and all were due to access injuries (15). Chapron et al. reviewed 17 reported cases of major vascular injury in the French Society of Gynecological Endoscopy, and 76% of the injuries occurred while gaining access (16). Of the four cases of dissection injury, three occurred during dissection around vascular structures. Like the general surgery experience, most vascular injuries reported by gynecologic surgeons were due to trocar-related events and not errors of dissection. However, Nezhat et al. reviewed eight case reports of vascular injuries due to errors of dissection, and four of the eight were associated with laparoscopic lymphadenectomy while three injuries were attributed to distorted anatomy (17).

TABLE 2 ■ Laparoscopic Vascular Injuries from Nonurologic Series

Series (Ref.)	Procedure	Cases	Vascular injury	Type
Usal et al. (12)	Laparoscopic choley, appy	1372	3 (0.11%)	1-Access injury 2-Dissection injury
Saville and Woods (13)	Laparoscopic choley, appy Laparoscopic hernia	3591	4 (0.1%)	4-Access injury
Guloglu et al. (14)	Laparoscopic choley, appy		9 (0.07%)	9-Access injury
Fruhwirth et al. (15)	Laparoscopic gynecologic		9 (0.8%)	9-Access injury
Chapron et al. (16)	Laparoscopic gynecologic	Review	17	13-Access injury 4-Dissection injury
Nezhat et al. (17)	Laparoscopic lymphadenectomy Laparoscopic adhesiolysis	Review	8	8-Dissection injury

A comparison of nonurologic vascular injuries to that in the urologic literature reveals two important distinctions between the two experiences.

- Vascular injuries due to access-related events are present in all specialties, but the higher overall occurrence of vascular injuries in the urologic literature is probably due to a greater number of dissection injuries.
- The greater number of dissection injuries in the urologic literature and select gynecologic reports are due to procedures that demand dissection around major vascular structures such as laparoscopic nephrectomy and laparoscopic lymphadenectomy.

Vascular injury during dissection is the most frequent cause for emergent open conversion.

Although the rate of vascular injury is relatively low, these injuries tend to be the most common intraoperative complication (1,3,7,10,18,19).

Vascular injury during dissection is the most frequent cause for emergent open conversion (3,7,9,10,20).

Vascular injury during dissection tend to occur during procedures where dissection is required around large vessels as in laparoscopic nephrectomy or laparoscopic retroperitoneal lymph node dissection (20), but are rare in cases such as laparoscopic prostatectomy where large arteries are rarely encountered. Guillonnet et al. noted only three bleeding episodes significant enough to require open conversion out of 567 laparoscopic prostatectomies (21). While this appears to be the trend, there are exceptions. In a multicenter study by Cadeddu et al. involving 157 laparoscopic radical nephrectomies, there was not a single vascular injury due to errors dissection (22).

The majority of vascular injuries during urologic laparoscopy are due to errors in dissection. Most commonly, this is due to inadequate exposure of the vascular structure leading to either direct sharp injury or thermal injury to the vessel. The principle of dissecting from superficial to deep structures (from known to unknown) must be followed in order to avoid this type of injury. In addition, anatomic knowledge of the proximity of major vascular structures is essential to avoid inadvertent vascular injury. Disorientation during laparoscopic procedures can occur and has been associated with injury to the inferior vena cava (23) and the superior mesenteric artery (3). If the surgeon becomes disoriented during the procedure due to bleeding or unusual anatomy, it is best to visually scan the abdomen for available landmarks. If landmarks cannot be established, then consultation with a colleague may be helpful. If proper orientation is still unable to be obtained, then conversion to open surgery should be performed.

Once a dissection injury has occurred, control of the bleeding vessel may be a challenge due to several factors. First, bleeding from a vessel quickly obscures the source because blood pools around the injured vessel. Second, the injured vessel is often not completely exposed because the dissection injury often occurs during exposure of the vessel. Third, unlike open surgery, the application of manual direct pressure is difficult, and depending on the laparoscopic instrument in the abdomen, the quick application of pressure to the bleeding vessel may be impossible.

Once a vascular injury has occurred, an immediate assessment is required to determine whether an attempt at laparoscopic repair should be performed or if open conversion is necessary. If the surgeon is inexperienced, or if this is a case early in the learning curve, then immediate open conversion should be performed. However, if the surgeon is more experienced and the necessary instrumentation is available, then a laparoscopic repair may be attempted. The first principle is to provide tamponade to the bleeding area with the available instrument that is in the abdomen at the time of injury. Additional ports may be required to provide exposure and suction as needed.

The pneumoperitoneum should be maintained because this may decrease venous bleeding (8).

Once the area of bleeding has been identified, further exposure of surrounding structures should be carefully performed to allow complete visualization of the region. After adequate exposure has been obtained, the area of injury may be identified and repaired either with intracorporeal suturing or by judicious placement of clips. On occasion, an injury may be repaired by firing a vascular stapling device (9). Failure to control hemorrhage by any of these measures, or the occurrence of hemodynamic instability in the patient, should prompt immediate open conversion.

It is essential in any laparoscopic procedure to have an open laparotomy tray open and available in the room in the event that emergent laparotomy is required.

The pneumoperitoneum should be maintained because this may decrease venous bleeding.

It is essential in any laparoscopic procedure to have an open laparotomy tray open and available in the room in the event that emergent laparotomy is required.

The need for open conversion to control vascular injury appears to occur early in the laparoscopic experience of the surgeon. Meraney et al. noted that open conversion was required in three of their first four vascular injuries; however, three subsequent vascular injuries were controlled using laparoscopic techniques, and open conversion was not required to control vascular complications during their last 200 cases (9). Guillonnet et al. reported seven open conversions for laparoscopic prostatectomy in the first 70 patients, with three due to bleeding, but no conversions in the subsequent 497 cases (21). Thiel et al. noted successful laparoscopic repair of four consecutive venous injuries after open repair of the first (8).

In addition to dissection injuries, vascular injuries have also been reported due to malfunctioning of endoscopic stapling devices. These injuries may be caused by application of the stapling device over previously placed metal clips on adjacent branch vessels. This may result in bleeding from the divided vessel due to lack of staple closure, or a jammed stapling device that cannot be easily removed from the vessel. Chan et al. reported 10 occurrences of stapler malfunction in 565 cases for an incidence of 1.7% (24). In 5 of the 10 cases, malfunctioning of the staple device was due to operator error with application of the stapler over previously placed metal clips causing the stapler to misfire. Others have reported similar problems with the endoscopic stapling device (3,7,25).

There have been recent reports of major vascular injury due to inadvertent endoscopic stapler application across the vena cava (23) and the aorta (26). All injuries occurred during retroperitoneal laparoscopic nephrectomy. In one report, two patients suffered vena caval injury when the vena cava was thought to be the right renal vein (23). Both injuries were recognized intraoperatively with conversion to open laparotomy. Vascular surgical consultation led to a successful outcome in each case. Disorientation of the surgeon due to unfamiliar landmarks was thought to contribute to ligation of the vena cava. Sautter et al. reported an aortic ligation during retroperitoneoscopic nephrectomy that resulted from application of an endoscopic clip in the renal hilum during bleeding (26). Limited visibility of the hilum was noted. The patient presented postoperatively with neurologic symptoms, and complete occlusion of the aorta was diagnosed on angiography. The occlusion was successfully bypassed with an aortic tube graft. These cases demonstrate the importance of remaining oriented during laparoscopic procedures, especially when bleeding may obscure the operative field.

If bleeding cannot be controlled and is compromising operative visibility, then open conversion should be favored over blind application of vascular closure devices.

If bleeding cannot be controlled and is compromising operative visibility, then open conversion should be favored over blind application of vascular closure devices.

ACCESS-RELATED INJURY

Access-related injuries to abdominal viscera or retroperitoneal vascular structures are estimated to occur between 0.05% and 2.8% of laparoscopic procedures. While these are rare injuries, when they do occur, the consequences can be devastating with a mortality rate reported from 5% to 13%.

Access-related injuries to abdominal viscera or retroperitoneal vascular structures are estimated to occur between 0.05% and 2.8% of laparoscopic procedures (27,28). While these are rare injuries, when they do occur, the consequences can be devastating with a mortality rate reported from 5% to 13% (6).

A review by Chadler et al. of insurance claims and Food and Drug Administration Medical Device Reports of access-related injuries over a two-year period revealed bowel and retroperitoneal vascular injury comprised 76% of all injuries incurred in the process of establishing a primary port (6). The small bowel was the most common organ injured and nearly 50% of both large and small bowel injuries were unrecognized for 24 hours or longer. Delayed recognition, along with age greater than 59 years and major vascular injury, was an independent predictor of death. Shielded pyramidal cutting trocars were the most common trocar type associated with access injuries, and trauma from insufflation needles accounted for 18% of the injuries. Injuries were also observed with open, Hasson-type, blunt cannulas, which were associated with two deaths: one from unrecognized bowel injury and another from retroperitoneal vascular injury. The authors concluded that no entry technique or device is absolutely safe, and that access injuries to abdominal viscera and vessels may be more common than is currently reported in the literature.

Other reports of trocar injury have confirmed that delayed recognition is a predictor of death, and the most common vascular structures injured with an insufflation needle or primary trocar are the distal aorta, vena cava, iliac arteries, and iliac veins (17,29). A detailed review of the injuries caused by "safety" shielded trocars revealed 32 deaths out of 629 trocar injuries reported to the Food and Drug

Administration over a four year period (30). Twenty-six (81%) of deaths resulted from vascular injuries and six (19%) were due to bowel injuries. Eighty-seven percent of deaths from vascular injuries involved the use of shielded trocars and 9% involved optical access trocars. When the diagnosis of bowel injury was delayed, the mortality rate increased to 21%. In fact, the Food and Drug Administration mandated that trocar manufactures remove the word “safety” to describe disposable shielded trocars.

Laparoscopic access injuries in the urologic literature are reported as one of three injuries: visceral organ or vascular trauma, abdominal wall vessel laceration, or port site herniation. Kavoussi et al. reported 10 (2.7%) trocar-related injuries in 372 patients treated with laparoscopic pelvic lymph node dissection (18). Four of the injuries were due to laceration of the epigastric vessels, three were bladder injuries, two were due to injury to a superficial abdominal wall vessel, and one was a small bowel injury. Gill et al. noted four (2.2%) trocar injuries in 185 laparoscopic nephrectomy patients (7). There were two port-site hernias, one abdominal wall hematoma, and one trocar injury to the kidney resulting in open laparotomy. In a survey of pediatric urological laparoscopy, Peters noted abdominal wall herniations in 0.15% of patients (31). He also noted that significant complications occurred more frequently in patients in whom the Veress needle was used (2.55%) compared to the Hasson technique (1.19%, $p < 0.006$). While the type of access technique was found to be significant, the most important factor in predicting the occurrence of complications in this study was the experience of the practitioner.

A recent review of laparoscopic nephrectomy revealed the potential risks involved in using optical trocars to gain primary port access into the peritoneal cavity. After insufflation is performed with a Veress needle, an optical trocar is used to visually pass through each layer of the abdominal wall. The proposed advantage of the optical trocar is that direct visualization while passing the trocar should allow identification of intra-abdominal structures and thereby decrease the risk of injury to viscera. Thomas reviewed 1283 urological laparoscopic procedures and found four (0.31%) injuries due to optical trocars (32). Two injuries involved the epigastric vessels, one involved bowel mesentery, and one involved bowel. Siqueira et al. reported three (1.4%) access-related injuries from optical trocars in the series of 213 patients (3). One injury involved laceration of the inferior epigastric artery, which resolved with conservative treatment. The other two injuries involved the liver while passing an optical trocar. Both injuries were managed conservatively. Orvieto et al. recently reported an aortic injury from an optical trocar during laparoscopic radical nephrectomy (33). There was no pneumoperitoneum prior to placement of the optical trocar and the patient recovered uneventfully after the injury was treated by placing an aortic vascular stent.

Injury while using optical trocars has also been confirmed in the gynecologic literature. Sharp et al. reviewed Medline, the Food and Drug Administration Medical Device Reporting, and the User Facility Device Experience databases for reports of complications from optical-access trocars (34). They found only two case reports in the medical literature of serious complications from optical-access trocars, but 79 serious complications in the Medical Device Reporting and User Facility Device Experience databases. These injuries included 37 major vascular injuries, 18 bowel perforations, 20 cases of significant bleeding from other sites, three liver lacerations, and one stomach perforation. Four deaths resulted from these complications. Clearly, this report demonstrates that optical trocars are associated with significant injuries despite the ability to see tissues during insertion, and these injuries are under-reported in the medical literature.

The open technique of gaining laparoscopic access is not without complication as noted in a report by Peters and coworkers (35). The injury involved a segment of small bowel, which had been included in the purse-string suture placed around the access incision. Inspection of the primary access site from a secondary trocar identified the trapped bowel and the serosal defect was repaired. The conclusions of this case report were that care must be used when placing a purse-string suture, and the initial access site should be inspected from a secondary trocar site to look for injury. Two aortic injuries have also been reported during placement of Hasson-type cannulas: one occurred due to the scalpel injury during the initial skin incision and the other due to a sharp metal burr on the tip of the cannula (36).

There is no perfect access technique and no method is risk free. The management of access injuries should focus on prevention and recognition.

The open technique of gaining laparoscopic access is not without complication as noted in a report by Peters and coworkers.

There is no perfect access technique and no method is risk free. The management of access injuries should focus on prevention and recognition.



FIGURE 1 ■ Proximity of the umbilicus to the aortic bifurcation during Veress needle placement. Source: From Ref. 38.

The distance from the abdominal skin surface at the umbilicus to the ventral surface of the aorta can be less than 1 cm in a thin woman and children.

Prevention of primary trocar injury requires knowledge and control of the axial forces at work during application of the trocar.

Risk factors for intra-abdominal injury during closed entry techniques include thin patients, patients with previous abdominal surgery with adhesions, and application of excess axial force. Another important factor that influences trocar-related injury is the experience of the surgeon (31). Dixon reported seven iliac vascular injuries due to trocars or Veress needles during general surgical procedures, and inexperience on the part of the operating surgeon was demonstrated in all cases (37).

If a closed entry technique is employed using a Veress needle and blind primary trocar, then prevention requires clear knowledge of the underlying anatomy and their proximity to landmarks on the skin (Fig. 1).

The distance from the abdominal skin surface at the umbilicus to the ventral surface of the aorta can be less than 1 cm in a thin woman and children (39).

Some have abandoned the use of the Veress needle in thin patients and recommend an open Hasson technique (5). Others have suggested avoiding midline access altogether because of the potential risks, and advocate primary access in the left upper quadrant (40). If a patient has an incision from previous surgery, this area should be avoided and primary access should be obtained in a location remote from the incision, or an open access technique should be employed.

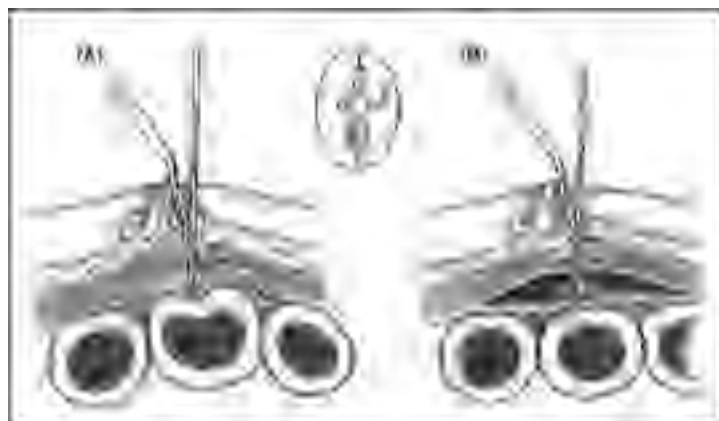
While the Veress needle may be smaller than a trocar, complications can occur with this device, and the Veress needle accounted for 18% of access-related injuries in a report by Chandler et al. (6). Veress needle placement was perceived as the most difficult aspect of laparoscopy as noted in a review by See et al. (41). Some have proposed that because of the smaller size of the Veress needle, injuries caused by these needles may be observed. However, Dixon and Carrillo reported three Veress needle injuries and all required immediate exploration and vascular control for resolution (37). He also notes that there may be multiple unrecognized injuries to surrounding structures and this warrants exploration.

When a Veress needle is passed, the abdominal wall should be elevated with penetrating towel clips and the Veress needle should be left open to permit air to enter the peritoneal space and allow the bowel and omentum to fall away (Fig. 2). Before CO₂ insufflation, aspiration, irrigation, reaspiration, and drop test should confirm the location of the needle. Any question as to the location of the needle should prompt removal. Once the needle is felt to be in the correct position, CO₂ insufflation should be started at low flow (1–3 L/min) and the initial pressure reading from the needle should be noted. A pressure reading greater than 8 to 10 mmHg or an occlusion reading from the insufflator should prompt the slow retraction of the needle until the pressure reading is acceptable. It is also important to communicate with the anesthesiologist at this time to inform them that insufflation is underway so that close monitoring can be performed. Any sudden change in the hemodynamics of the patient or end-tidal CO₂ reading should lead to cessation of insufflation.

Prevention of primary trocar injury requires knowledge and control of the axial forces at work during application of the trocar.

Some have suggested temporary overinflation of the abdomen with the Veress needle to 20 to 25 mmHg to maximize the space between abdominal wall and viscera as well as increase abdominal wall resistance (42). If a shielded, cutting-type trocar is

FIGURE 2 ■ Visceral deformation of displacement (A), and the importance of having an open stopcock for air entry (B) to allow omentum and bowel to drop away from the elevated ventral abdominal wall. Source: From Ref. 6.



used then the skin incision must be wide enough to allow the trocar to pass easily. The abdominal wall should be stabilized with towel clips and the angle of passage should take into account the underlying anatomy. Axial force control at this point is key and can be degraded by positioning that requires more muscle recruitment to exert a given amount of force, i.e., having the table too high, or reaching across the patient to put in a lateral port. Once the primary trocar is placed, its position should be confirmed immediately by passing the laparoscope through and observing for underlying injury. Secondary trocars are passed under direct vision, but care must be exercised during this procedure because injuries have occurred with secondary trocars, including injury to retroperitoneal vascular structures (6). Once a secondary trocar is in place, the primary entry site should be viewed to look for injury. In an effort to redirect axial force during trocar placement, radially expanding trocars (Fig. 3) have been developed and have been shown to be safe with a very low incidence of injury (6,43).

If the open, or Hasson, technique is used to gain access, care must be taken to avoid underlying bowel during the creation of the incision because exposure is limited. One of the criticisms of the Hasson technique is that there is loss of CO₂ from the cannula site, which can decrease the working space. Some surgeons have attempted to solve this problem by placing a purse-string suture around the cannula site. However, care must be exercised because complications have been reported with this technique as noted previously (35).

If vascular or bowel injury is suspected during Veress needle or primary trocar placement, immediate conversion to an open procedure should be performed. While a bowel injury may be recognized laparoscopically, the full extent of injury may be underappreciated by the view from the laparoscope and combined injury of bowel and vascular structures are well documented (6).

A high index of suspicion is required to recognize bowel injury due to trocar placement, because nearly half of all bowel injuries (47% for small bowel and 49% for colon) went undetected for 24 hours or greater, and delayed recognition of injury was an independent predictor of mortality (6). Vascular injuries due to trocar or Veress needle misplacement may go unrecognized for some time because of overlying mesentery and bowel, and the retroperitoneal position of major vascular structures. In addition, intraperitoneal CO₂ may compress the bleeding site and a steep Trendelenburg position may decrease venous bleeding as well (5). Therefore, it is important to assess all clinical signs of the patient if access injury is suspected. Consultation with the anesthesiologist should be performed to determine blood pressure, heart rate, and end-tidal CO₂. In young patients, blood pressure and heart rate may be maintained in the normal range for sometime before bleeding is apparent, and a change in end-tidal CO₂ may be the best indicator of vascular insult.

A thorough understanding of the anatomy of the anterior abdominal wall can minimize injury to abdominal wall vasculature during trocar placement.

The inferior epigastric artery courses on the posterior surface of the rectus muscle, upward and medially on a line from the midpoint of the inguinal ligament toward the umbilicus. At the level of the semilunar line, it changes course and heads

If vascular or bowel injury is suspected during Veress needle or primary trocar placement, immediate conversion to an open procedure should be performed. While a bowel injury may be recognized laparoscopically, the full extent of injury may be underappreciated by the view from the laparoscope and combined injury of bowel and vascular structures are well documented.

A thorough understanding of the anatomy of the anterior abdominal wall can minimize injury to abdominal wall vasculature during trocar placement.

FIGURE 3 ■ Radially dilating trocar converts axial force to a radial vector by diamond-shaped, skeletal elements embedded in an expandable sheath. Source: From Ref. 6.





FIGURE 4 ■ Course of the epigastric vessels in relation to surface anatomy.

Source: From Ref. 44.

If the epigastric artery is injured attempts at cautery are usually unsuccessful and the best method of control is suture ligation.

cephalad, running between the midline and lateral boarder of the rectus muscle (Fig. 4). Saber et al. determined the position of the inferior and superior epigastric vessels relative to the midline by evaluation of computed tomography scans in 100 patients (45). They found the epigastrics were between 4 and 8 cm from the midline at five different locations along the anterior abdominal wall, and described a “safe zone” outside of this range. While these findings may be anatomically correct and useful for patients in the supine position, this may have limited application in urologic laparoscopy when many patients are placed in a modified flank position. Clearly, the midline shifts toward the downward side in the flank position and even more so in obese patients. This makes using the midline as a reference point for trocar placement problematic.

The inferior epigastric vessels can be avoided by placing trocars in the midline, lateral to the boarder of the rectus muscle, or with direct visualization of the vessel from inside the abdomen. In thin patients, transillumination of the abdominal wall may allow the inferior epigastric vessels to be seen and this maneuver is also helpful to identify and avoid superficial vessels. In obese patients, the costal margin and iliac crest are usually palpable and can be used as reference points for trocar placement, because the midline is not a reliable landmark as mentioned above.

If the epigastric artery is injured attempts at cautery are usually unsuccessful and the best method of control is suture ligation.

This can be performed laparoscopically using a small-caliber piercing needle such as a Carter–Thomasen needle or a Stamey needle (44). The suture is passed on both sides of the bleeding site, perpendicular to the vessel. The suture may be tied on the skin over a gauze bolster or under the skin surface if the suture was passed within the trocar incision.

SUMMARY

- Vascular injury during laparoscopic is a rare complication, but is the most common major complication in many urologic procedures.
- Vascular injury may be due to errors of dissection or access-related trocar injury. These injuries can have devastating consequences resulting in significant morbidity and death.
- Vascular injuries are probably under-reported in the literature, and the true incidence is higher than realized.
- Avoiding dissection injuries requires strict adherence to principles of dissection such as working from superficial to deep structures.
- Successful management requires prompt control of the bleeding vessel and exposure, but early open conversion should be performed if control cannot be established or the surgeon has limited laparoscopic experience.
- There is no one completely safe method of gaining laparoscopic access, and great care must be employed in whatever technique is used.
- The successful management of laparoscopic access injuries rests on prevention, early recognition of injury, and immediate open conversion if injury is identified or suspected.

REFERENCES

1. Fahlenkamp D, Rassweiler J, Fornara P, Frede T, Loening SA. Complications of laparoscopic procedures in urology: experience with 2,407 procedures at 4 German centers. *J Urol* 1999; 162:765.
2. Simon S, Castle E, Ferrigni R, et al. Complications of laparoscopic nephrectomy: the Mayo clinic experience. *J Urol* 2004; 171:1447.
3. Siqueira TM, Kuo RL, Gardner TA, et al. Major complications in 213 laparoscopic nephrectomy cases: the Indianapolis experience. *J Urol* 2002; 168:1361.
4. Vilos GA. Litigation of laparoscopic major vascular injuries in Canada. *J Am Assoc Gynecol Laparosc* 2000; 7:503.
5. Leron E, Piura B, Ohana E, Mazor M. Delayed recognition of major vascular injury during laparoscopy. *Eur J Obstet Gynecol Reprod Biol* 1998; 79:91.
6. Chandler JG, Corson SL, Way LW. Three spectra of laparoscopic entry access injuries. *J Am Coll Surg* 2001; 192:478–491.
7. Gill IS, Kavoussi LR, et al. Complications of laparoscopic nephrectomy in 185 patients: a multi-institutional review. *J Urol* 1995; 154:479.
8. Thiel R, Adams JB, Schulam PG, Moore RG, Kavoussi LR. Venous dissection injuries during laparoscopic urological surgery. *J Urol* 1996; 155:1874.

9. Rassweiler J, Fornara P, Weber M, et al. Laparoscopic nephrectomy: the experience of the laparoscopy working group of the German Urologic Association. *J Urol* 1998; 160:18.
10. Meraney AM, Samee AA, Gill IS. Vascular and bowel complications during retroperitoneal laparoscopic surgery. *J Urol* 2002; 168:1941.
11. Hsu T, Su L, Ratner L, Kavoussi L. Renovascular complications of laparoscopic donor nephrectomy. *Urol* 2002; 60:811.
12. Usal H, Sayad P, Hayek N, et al. Major vascular injuries during laparoscopic cholecystectomy. An institutional review of experience with 2589 procedures and literature review. *Surg Endosc* 1998; 12:960.
13. Saville LE, Woods MS. Laparoscopy and major retroperitoneal vascular injuries (MRVI). *Surg Endosc* 1995; 9:1096.
14. Guloglu R, Dilege S, Aksoy M, et al. Major retroperitoneal vascular injuries during laparoscopic cholecystectomy and appendectomy. *J Laparoendosc Adv Surg Tech A* 2004; 14:73.
15. Fruhwirth J, Koch G, Mischinger HJ, et al. Vascular complications in minimally invasive surgery. *Surg Laparosc Endosc* 1997; 7:251.
16. Chapron CM, Pierre F, Lacroix S, et al. Major vascular injuries during gynecologic laparoscopy. *J Am Coll Surg* 1997; 185:476.
17. Nezhat C, Childers J, Nezhat F, et al. Major retroperitoneal vascular injury during laparoscopic surgery. *Hum Reprod* 1997; 12:480.
18. Kavoussi LR, Sosa E, Chandhoke P, et al. Complications of laparoscopic pelvic lymph node dissection. *J Urol* 1993; 149:322.
19. Ono Y, Kinukawa T, Hattori R, Gotoh M, Kamihira O, Ohshima S. The long-term outcome of laparoscopic radical nephrectomy for small renal cell carcinoma. *J Urol* 2001; 165:1867.
20. Nelson JB, Chen RN, Bischoff JT, et al. Laparoscopic retroperitoneal lymph node dissection for clinical stage 1 nonseminomatous germ cell testicular tumors. *Urology* 1999; 54:1064.
21. Guillonnet B, Rozet F, Cathelineau X, et al. Perioperative complications of laparoscopic radical prostatectomy: the Montsouris 3-year experience. *J Urol* 2002; 167:51.
22. Cadeddu JA, Ono Y, Clayman RV, et al. Laparoscopic nephrectomy for renal cell cancer: evaluation of efficacy and safety: a multicenter experience. *Urology* 1998; 52:773.
23. McAllister M, Bhayani SB, Ong A, et al. Vena caval transection during retroperitoneoscopic nephrectomy: report of the complication and review of the literature. *J Urol* 2004; 172:183.
24. Chan D, Bischoff JT, Ratner L, Kavoussi LR, Jarret TW. Endovascular gastrointestinal stapler device malfunction during laparoscopic nephrectomy: early recognition and management. *J Urol* 2000; 164:319.
25. Deng DY, Meng MV, Nguyen HT, Bellman GC, Stoller ML. Laparoscopic linear cutting stapler failure. *Urology* 2002; 60:415.
26. Sautter T, Sulser T, Suter S, et al. A severe complication of retroperitoneoscopic nephrectomy. *J Urol* 2001; 165:515.
27. Harkki-Siren P. The incidence of entry-related laparoscopic injuries in Finland. *Gyn Endo* 1999; 8:335.
28. Hulka JF, Levy BS, Parker WH, Phillips JM. Laparoscopic-assisted vaginal hysterectomy: American Association of Gynecologic Laparoscopists' 1995 membership survey. *J Am Assoc Gyn Laparosc* 1997; 4:167.
29. Nordestgaard AG, Bodily KC, Osborne RW, et al. Major vascular injuries during laparoscopic procedures. *Am J Surg* 1995; 169:543.
30. Bhoyrul S, Vierra MA, Nezhat CR, et al. Trocar injuries in laparoscopic surgery. *J Am Coll Surg* 2001; 192:677.
31. Peters CA. Complications in pediatric urological laparoscopy: results of a survey. *J Urol* 1996; 155:1070.
32. Thomas MA, Rha KH, Ong AM, et al. Optical access trocar injuries in urological laparoscopic surgery. *J Urol* 2003; 170:61.
33. Orvieto M, Breyer B, Sokoloff M, Shalhav AH. Aortic injury during initial blunt trocar laparoscopic access for renal surgery. *J Urol* 2004; 171:349–350.
34. Sharp HT, Dodson MK, Draper ML, et al. Complications associated with optical-access laparoscopic trocars. *Obstet Gynecol* 2002; 99:553.
35. Sadeghi-Nejad H, Kavoussi LR, Peters CA. Bowel injury in open technique laparoscopic cannula placement. *Urology* 1994; 43:559.
36. Hanney RM, Carmalt HL, Merrett N, Tait N. Use of the Hasson cannula producing major vascular injury at laparoscopy. *Surg Endosc* 1999; 13:1238.
37. Dixon M, Carrillo EH. Iliac vascular injuries during elective laparoscopic surgery. *Surg Endosc* 1999; 13:1230.
38. Hulka JF, ed. *Textbook of Laparoscopy*. New York: Grune and Stratton, 1985.
39. Nezhat F, Brill AI, Nezhat CH, et al. Laparoscopic appraisal of the anatomic relationship of the umbilicus to the aortic bifurcation. *J Am Assoc Gynecol Laparosc* 1998; 5:135.
40. Hunter JG. Invited commentary on "Three spectra of laparoscopic entry access injuries". *J Am Coll Surg* 2001; 192:490.
41. See WA, Fisher RJ, Winfield HN, Donovan JF. Laparoscopic surgical training: effectiveness and impact on urological surgical practice patterns. *J Urol* 1993; 149:1054.
42. Phillips G, Garryu R, Kumar C, Reich H. How much gas is required for initial insufflation at laparoscopy? *Gyn Endosc* 1999; 8:369.
43. Shekarriz B, Gholami SS, Rudnick DM, Duh Q, Stoller M. Radially expanding laparoscopic access for renal/adrenal surgery. *Urology* 2001; 58:683.
44. Green LS, Loughlin KR, Kavoussi LR. Management of epigastric vessel injury during laparoscopy. *J Endourol* 1992; 6:99–101.
45. Saber AA, Mesleman AM, Davis R, Pimentel R. Safety zones for anterior abdominal wall entry during laparoscopy: a CT scan mapping of epigastric vessels. *Ann Surg* 2004; 239:182.

LAPAROSCOPIC COMPLICATIONS: GASTROINTESTINAL

Ramakrishna Venkatesh

Minimally Invasive Urology, Division of Urology, Washington University School of Medicine, St. Louis, Missouri, U.S.A.

Jaime Landman

Department of Urology, Columbia University Medical Center, New York, New York, U.S.A.

- | | |
|--|--|
| <ul style="list-style-type: none"> ■ INTRODUCTION ■ ABDOMINAL ACCESS-RELATED BOWEL INJURIES <ul style="list-style-type: none"> Open Access Method Gastrointestinal Effects of Pneumoperitoneum ■ NON-ACCESS-RELATED BOWEL INJURIES ■ ELECTROCAUTERY BOWEL INJURY ■ MECHANICAL BOWEL INJURY ■ GASTRIC OR DUODENAL INJURIES ■ HEPATOBILIARY, SPLENIC, OR PANCREATIC INJURY | <ul style="list-style-type: none"> ■ PREVIOUS OPEN ABDOMINAL SURGERY AND LAPAROSCOPIC SURGERY ■ HAND-ASSISTED LAPAROSCOPY ■ TROCAR SITE HERNIA ■ RECTAL INJURY DURING RADICAL PROSTATECTOMY ■ SURGEON EXPERIENCE ■ SUMMARY ■ REFERENCES |
|--|--|

Intestinal injury is a rare but potentially fatal complication of abdominal laparoscopy.

INTRODUCTION

Intestinal injury is a rare but potentially fatal complication of abdominal laparoscopy. Review of large multi-institutional studies of urologic laparoscopy over the last decade reveals an overall complication rate from 4.4% to 16%, a conversion rate of 0.8% to 5%, and a mortality rate up to 0.9% (1–5). The combined incidence of reported bowel injury from the general surgical, gynecologic, and urologic literature is 1.3 per 1000 cases (6).

Gastrointestinal complications of urologic laparoscopy can occur intraoperatively while obtaining abdominal access, during dissection of viscera, or from an unrecognized intraoperative bowel injury. Postoperative bowel complications include a prolonged ileus or bowel obstruction from a trocar site or internal herniation.

The reported incidence of bowel injuries due to Veress needle and trocar insertion is 0.03% to 0.3%. Veress needle injuries are more common than trocar injuries.

ABDOMINAL ACCESS-RELATED BOWEL INJURIES

The reported incidence of bowel injuries due to Veress needle and trocar insertion is 0.03% to 0.3% (7–10). Veress needle injuries are more common than trocar injuries.

Correct Veress needle placement should be confirmed before proceeding with insufflation of the abdomen (Table 1). Bowel insufflation through a Veress needle may produce asymmetrical abdominal distension, insufflation of only a small amount of CO₂ (less than 2 L) before high intra-abdominal pressures are reached, and passage of flatus during insufflation. If these signs are identified, insufflation should be immediately terminated. A pneumoperitoneum may then be established using a second Veress needle or an open Hasson technique at a different site.

During Veress needle or trocar insertion, the stomach or bowel may be entered. Typically, transgression into a hollow viscus is immediately apparent because of aspiration of gastrointestinal contents.

Rarely, patients with urachal abnormalities, i.e., cysts or sinuses, may be encountered with a history of umbilical discharge, which should alert the surgeon to this possibility and high risk for viscus perforation. Once identified, the Veress needle bowel injury is managed based on the level of severity. If the Veress needle perforates any intra-abdominal hollow viscus and no leakage of enteric content is noted, conservative management can be undertaken. If the bowel defect appears to be a small puncture, a simple suture may be placed to close the needle hole. However, larger defects that may result from the Veress needle or from a trocar require formal repair. Formal repair of

During Veress needle or trocar insertion, the stomach or bowel may be entered. Typically, transgression into a hollow viscus is immediately apparent because of aspiration of gastrointestinal contents.

TABLE 1 ■ Safe Veress Needle and Trocar Insertion

Place patient in Trendelenburg position, make a 12 mm incision at the site of desired needle entry, spread the underlying fat with a Kelly clamp, and grasp the underlying fascia with two Allis clamps
Pass Veress needle (midline two “pops”) into the peritoneal cavity
Aspirate Veress needle for blood/bowel content
Irrigate needle with 5 cc of saline: fluid should inject without any force
Aspirate: there should be no return
Inject another 2–3 cc of saline (to push any aspirated fat, omentum, etc. away from the needle)
Drop test: fluid in the hub of the needle should flow into the peritoneal cavity
Advancement test: needle should be able to be advanced 1–2 cm without encountering any resistance (i.e., indicator in the hub of the needle should not move)
Ensure intra-abdominal pressure is low (<10 mmHg) when connected to the insufflator
Place first trocar after the intra-abdominal pressure reaches 15–25 mmHg
Use visual dilating obturator trocar for primary trocar insertion
Always insert secondary trocars under vision
Visually inspect each site of trocar entry (including that of the primary trocar) for bleeding or visceral injury
Source: From Ref. 11.

When a trocar-induced bowel injury is suspected, the surgeon should resist the temptation to remove the trocar, because the offending trocar can be used to identify the site of bowel injury expeditiously and minimize the leakage of bowel contents into the peritoneal cavity.

significant bowel injuries may be performed via open or laparoscopic technique based on the level of experience of the operating surgeon. A general surgeon should be consulted to help determine the level of injury and to help establish an intraoperative management strategy. Trocar-induced bowel injuries should typically occur only during insertion of the primary trocar; the primary trocar is the only access that is generally not placed under direct vision.

When a trocar-induced bowel injury is suspected, the surgeon should resist the temptation to remove the trocar, because the offending trocar can be used to identify the site of bowel injury expeditiously and minimize the leakage of bowel contents into the peritoneal cavity.

The site of primary trocar passage should always be considered as a suspect for injury, and after additional access is gained, the primary access site should be inspected to rule out a bowel injury. During upper abdominal trocar deployment, gastric perforation may occur as a result of trocar insertion into a distended stomach. Keeping patients without oral intake eight hours prior to surgery, and the insertion of an orogastric or a nasogastric tube are helpful in minimizing the risk of gastric injury.

If a trocar-based bowel injury is appreciated, the site of perforation should be carefully evaluated. The evaluation should include consideration of a possible through-and-through bowel injury.

- Penetrating bowel injuries should be managed like any other penetrating injury within the abdomen.
- Open conversion and traditional management are most typically performed.
- Small perforations or lacerations can be repaired primarily.
- Extensive bowel injuries require resection.
- If the patient has undergone bowel preparation and the surgeon is comfortable with laparoscopic reconstruction, repair of an injured hollow viscus can be carried out by laparoscopic intracorporeal suturing or stapling techniques.
- Consultation with a general surgeon is strongly recommended.

Despite consensus to the contrary, analysis of three prospective, randomized studies to date shows that that a Veress needle access technique for trocar insertion is no more hazardous than a direct vision trocar insertion (Hasson technique) (10,12,13). As with any technique, the skill and experience of the surgeon is the key. For Veress needle insertion, adherence to the proper Veress needle insufflation protocol is essential. Specifically, the needle should irrigate easily, aspiration should not yield blood or fecal matter, the surgeon should observe a positive drop test (fluid passes through needle into the peritoneal cavity), there should be unrestricted advancement of the needle by 1 to 2 cm after entry, and the initial insufflation pressures should be low (Table 1). If these signs are not all present, the needle should be withdrawn and passed again via the same site or a different site to minimize the potential for access-based injury.

Certain patients deserve special consideration as they represent an increased risk for access. Patients with very high or low body mass index can be a challenge. Similarly, patients with prior abdominal surgery should be approached with great caution. In the authors' experience, and documented in the literature, application of nonbladed (dilating) trocars minimize the risk of bowel and vascular injury (14,15).

Trocar access via any technique is generally safe. However, meticulous technique should always be applied to minimize the potential for injury. An open laparotomy set should be immediately available in the operating room during laparoscopic procedures for expeditious emergent conversion.

Before exiting the abdomen, careful and meticulous inspection of the bowel and trocar sites should be performed to identify any unrecognized bowel injury.

Before exiting the abdomen, careful and meticulous inspection of the bowel and trocar sites should be performed to identify any unrecognized bowel injury.

The open or Hasson technique is a safe method of access, and is recommended in patients with previous abdominal surgery, if there is difficulty in the establishment of pneumoperitoneum with Veress needle, or for children and very thin patients.

Open Access Method

The open or Hasson technique is a safe method of access, and is recommended in patients with previous abdominal surgery, if there is difficulty in the establishment of pneumoperitoneum with Veress needle, or for children and very thin patients.

However, just as with Veress needle access, bowel and vascular injuries have been described (7,8,16). Penfield reported an incidence of 0.2% complication rate among 10,840 open laparoscopies, including a 0.06% incidence of bowel injury (17). There are fewer reports of bowel injuries using Hasson's method of access than with the Veress needle technique. It is however useful for the laparoscopic surgeon to be proficient with both techniques.

Gastrointestinal Effects of Pneumoperitoneum

Halevy et al., in a series comparing open and laparoscopic cholecystectomy, have demonstrated that laparoscopic surgery results in significantly less disruption of normal gastrointestinal motility when compared to open surgery (18).

The mechanism(s) of decreased ileus with laparoscopic surgery remain(s) unclear. Another concern with abdominal laparoscopy has been gastroesophageal reflux. Despite the increased intra-abdominal pressures associated with insufflation, there has been no increased incidence of gastroesophageal reflux and regurgitation in patients undergoing laparoscopic procedures (19). However, the combination of elevated intra-abdominal pressures from the pneumoperitoneum, morbid obesity, and the application of the Trendelenburg position can increase the likelihood of regurgitation and aspiration of gastric contents. To avoid reflux, high-risk patients may be premedicated with 10 mg of intravenous metoclopramide. Also, administration of H₂ blockers can reduce gastric acidity and the associated morbidity if aspiration of gastric contents should occur. Finally, a cuffed endotracheal tube should prevent aspiration of stomach contents.

Halevy et al., in a series comparing open and laparoscopic cholecystectomy, have demonstrated that laparoscopic surgery results in significantly less disruption of normal gastrointestinal motility when compared to open surgery.

NON-ACCESS-RELATED BOWEL INJURIES

Bishoff et al. performed a retrospective review of bowel injuries during urologic laparoscopy in 915 cases at two institutions and reported an overall incidence of 0.8% non-access-related bowel injuries (6). The authors reported bowel perforation in two patients (0.2%) and serosal injury of the intestine or stomach in six patients (0.6%). Intraoperatively recognized bowel injuries occurred in six patients: three during staging pelvic lymph node dissection, two during pyeloplasty, and one during nephrectomy. Unrecognized bowel perforation during surgery occurred in two patients. Additionally, there were two patients referred from outside institutions who had unrecognized bowel perforation. In this series, three of the four patients with unrecognized bowel injuries had rapid progression to sepsis, and two subsequently died.

The authors observed that the postoperative signs and symptoms of laparoscopic bowel perforation were different from the classic postoperative symptoms of bowel perforation that occur with open surgery.

In the above series, all five patients with unrecognized bowel injuries presented in a characteristic manner that did not include traditional peritoneal signs. The initial presentation in each of these cases included persistent and relatively increased pain at a single trocar site without significant erythema or discharge. Each patient had leukopenia, and only one patient had fever greater than 38°C. Upon exploration, the painful trocar site was closest to the injured bowel segment. Abdominal distension and diarrhea were also noted. Two patients with colonic injuries after pelvic lymph node dissection had rapid onset of sepsis, without typical peritoneal signs, and died within four days.

The authors observed that the postoperative signs and symptoms of laparoscopic bowel perforation were different from the classic postoperative symptoms of bowel perforation that occur with open surgery.

TABLE 2 ■ Location of Bowel Injury, Treatment, and Outcome

Reference	Specialty	No. of pts	Bowel injury	Small intestine	Colon	Stomach	Recognized	Unrecognized	Treatment (No. pts/total)	No. of deaths
Harkki Siren and Kurki (20)	Gynecology	70,607	44	26	16	2	8	36	All laparotomy	
Bateman et al. (21)	Gynecology	2,324	6	3	2	1				
Wolfe et al. (22)	General surgery	381	2	1	1	0	0	2		2
Deziel et al. (23)	General surgery	77,604	109	69	35	5			Laparotomy (85/109)	5
Phillips et al. (24)	General surgery	51	0							
Schrenk et al. (25)	Gynecology; general surgery	4,672	10	6	4	0	6	4	Laparotomy (9/10)	1
Penfield (17)	Gynecology	10,840	6				4	2	All laparotomy	
Loffer and Pent (26)	Gynecology	32,719	64	44	11	9			Laparotomy (47/64)	
Kaali and Barad (27)	Gynecology	4,532	4						All laparotomy	
Casey et al. (28)	Gynecology	93	4	2	1	1	0	4	All laparotomy	
Davis et al. (29)	Gynecology	40	1				0	1	All laparotomy	
Chapron et al. (30)	Gynecology	1,191	8	1	7					
Bishoff et al. (6)	Urology	915	8	1	7		6	4		
Total		205,969	266	153	84	18	24	53		8

Source: From Ref. 6.

The authors also performed a Medline search on laparoscopic bowel injuries reported in the surgical and gynecological literature and discovered a total of 12 series with an overall incidence of 0.13% (266/205,969 cases) bowel injuries (both access and non-access-related), the majority (69%) of which were not recognized at surgery (Table 2) (6,17,20–30). Of the 266 patients with bowel injuries, eight patients died as a direct result of unrecognized intraoperative bowel injury. Small bowel injuries accounted for 58%, and colon and stomach injuries comprised 32% and 7%, respectively. Fifty percent of injuries resulted from application of electrocautery, and 32% of injuries were access related from Veress needles or trocars. Eighty percent of bowel injuries were managed by laparotomy and open repair.

The etiology of the unusual presentation of laparoscopic bowel injury compared to the open surgery is uncertain. It has been speculated that the possible lower immune and metabolic stimulus caused by laparoscopic surgery may allow more rapid progression toward sepsis before natural homeostatic responses occur (31–34). The absence of a large skin incision, which may be the site of maximum trauma, may result in less stimulation of acute phase reactants and reduced postoperative metabolic and cytokine response.

When bowel injury is recognized intraoperatively, immediate repair is indicated.

Several reports have demonstrated the safety of laparoscopic repair and avoidance of diverting colostomy. Colonic injuries in unprepared patients that require bowel resection should be considered for a diverting colostomy.

Almost all unrecognized injuries that present in the postoperative period will require open laparotomy.

On rare occasions, patients have been managed by total parenteral nutrition and percutaneous drainage or expectantly for sepsis and cardiovascular collapse. However, this is not considered a standard management strategy and should be reserved for highly selected cases.

In the postoperative period, if there is any concern for possible unrecognized bowel injury, a computed tomography scan of the abdomen with oral contrast should be performed expeditiously.

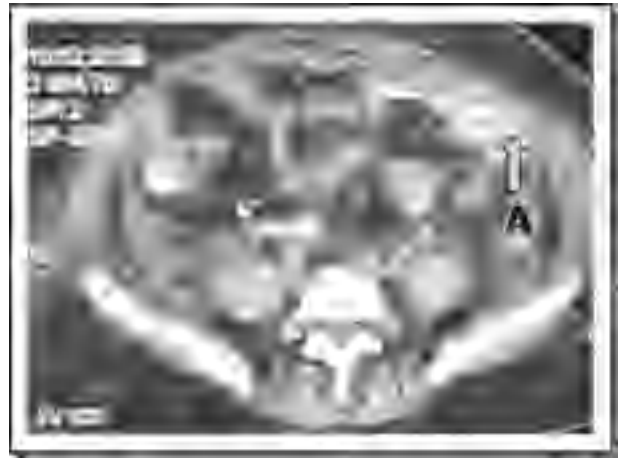
Computed tomography scan can identify bowel perforation, postoperative bleeding, urinoma, and urinary obstruction. Contrast in the peritoneal cavity and a local thickening of the bowel wall may be noted on computed tomography, and this finding should prompt immediate exploration (Fig. 1). At times, computed tomography scan with contrast may have to be done two or three times over a one- to two-week period before the diagnosis is made. A plain abdominal film may reveal an ileus. The finding

When bowel injury is recognized intraoperatively, immediate repair is indicated.

Almost all unrecognized injuries that present in the postoperative period will require open laparotomy.

In the postoperative period, if there is any concern for possible unrecognized bowel injury, a computed tomography scan of the abdomen with oral contrast should be performed expeditiously.

FIGURE 1 ■ Postoperative computed tomography scan of the abdomen in a patient four days after laparoscopic radical nephrectomy. Scan performed after administering oral contrast shows contrast outside the bowel lumen (A), suggestive of bowel perforation.



If the patient does not respond quickly to antibiotics and signs of peritonitis develop, laparotomy is mandated.

of free air is often seen up to two weeks after laparoscopy and is not absolutely indicative of bowel perforation.

If the patient does not respond quickly to antibiotics, and signs of peritonitis develop, laparotomy is mandated.

On exploration if there is suspected thermal bowel injury, the area of damage is usually more extensive than what is visually appreciated; hence, a wide excision should be performed to ensure removal of all potentially compromised tissue. The wound should be adequately drained, and the patient should have antibiotic coverage. Aggressive clinical and radiological monitoring will allow early recognition of bowel injury and will expedite early surgical exploration when warranted. A high level of suspicion and rapid clinical response are crucial in avoiding a disaster.

Thermal or energy-based bowel injuries represent some of the most serious complications of laparoscopic surgery. Monopolar electrosurgical current is attributed with the greatest number of instrument-related mishaps.

ELECTROCAUTERY BOWEL INJURY

Thermal or energy-based bowel injuries represent some of the most serious complications of laparoscopic surgery (6). Monopolar electrosurgical current is attributed with the greatest number of instrument-related mishaps.

In the 1990s, the incidence of complications related to laparoscopic electrosurgery has been reported to be 2 to 5 per 1000.

The most feared electrosurgical are bowel related and result from stray monopolar electrosurgical current. However, by using only metal ports and by never using plastic collars on metal ports, this problem can be greatly reduced. In recent years, the development of “active electrode monitoring” has been very helpful in detecting any “leak” of current. This equipment will immediately turn off the flow of electrical current whenever an insulation leak is detected.

Unfortunately energy-based bowel injuries are frequently not recognized during surgery, and manifest only in the postoperative period. The majority of patients present three to seven days postoperatively with abdominal pain, nausea, low-grade fever, and a moderate leukocytosis/leukopenia.

Patient's inability to void may be an early manifestation of bowel injury, or gastrointestinal bleeding can be an atypical manifestation of bowel injury. Knowledge of the biophysics of electrosurgery, and the mechanisms of electrosurgical injury are important to understanding and avoiding the potential complications of electrosurgery in laparoscopy. Electrosurgical injury can result from unrecognized energy transfer in the operational field or, less commonly, to unnoticed stray current outside the laparoscopic field. The stray current can result from insulation failure, direct coupling, or capacitive coupling. Capacitive coupling is the most worrisome of these complications because it is difficult for the surgeon to defend against this problem.

The most intuitive types of electrothermal injuries result from the direct application of an energy probe onto nontarget tissue as a result of unintended activation. Another form of electrosurgical injury results from defects in the insulation along the instrument. This type of insulation break may be increased when using a 5-mm insulated instrument through a 10-mm sleeve, because the 5-mm instrument is more likely to rub against the inside edge of a 10-mm trocar sleeve tip compared to a 5-mm one.

Unfortunately energy-based bowel injuries are frequently not recognized during surgery, and manifest only in the postoperative period. The majority of patients present three to seven days postoperatively with abdominal pain, nausea, low-grade fever, and a moderate leukocytosis/leukopenia.

Unfortunately, approximately 75% of electrothermal injuries are not recognized at the time of occurrence, and thus present in the postoperative period. The small bowel is the most frequently injured.

Prevention of electrosurgical injuries is paramount. The best way to avoid electrosurgical injury is to avoid the application of monopolar energy sources.

Direct coupling results from unintended contact of a noninsulated instrument like a laparoscope or metal-grasping forceps with the active electrosurgical instrument. More worrisome, however, is capacitive coupling, which occurs when electric current is transferred from an active electrode through intact insulation into adjacent conductive material such as bowel structures. Capacitive coupling can occur with a hybrid trocar sleeve, which has a plastic anchor, stopping the transmission of current from the metal trocar into the abdominal wall over a large surface and allow capacitive coupling to adjacent bowel resulting in burns. Activating the electrode in the air when not in use will create an “open” circuit, which can also result in a capacitive current effect. Use of electrosurgical accessory safety equipment, which monitors active electrode, actively shields against stray current.

Unfortunately, approximately 75% of electrothermal injuries are not recognized at the time of occurrence, and thus present in the postoperative period. The small bowel is the most frequently injured.

Symptoms of bowel perforation depending on the severity of the coagulation necrosis are usually seen three to seven days after the procedure. The reports of histopathologic findings have been reported to have significant influence on medical-legal claims. The features are an area of coagulation necrosis, absence of capillary ingrowth or fibroblastic muscle coat reconstruction and absence of white cell infiltration except in focal areas of viable borders.

Prevention of electrosurgical injuries is paramount. The best way to avoid electrosurgical injury is to avoid the application of monopolar energy sources.

We have altered our surgical technique to minimize the use of laparoscopic monopolar energy. Application of alternative energy sources such as ultrasound energy (i.e., Harmonic Scalpel^a) or SonoSurg^b and bipolar energy minimizes the need for monopolar energy sources and can reduce the risk of electrosurgical injuries. Electrosurgical injuries can also be prevented or minimized by regular equipment maintenance. The insulation on every piece of electrosurgical equipment should be checked prior to application. An active awareness by the surgical team of the principles of electrosurgery and the mechanisms of electrocautery injury can also be helpful in minimizing the risk of injury.

- The management of electrosurgical bowel injuries can be challenging.
- “Superficial” small thermal injuries to the bowel may be treated prophylactically with a laparoscopic-guided purse-string suture. However, as electrosurgical burns are more extensive than they appear visually, the purse-string suture should be placed well beyond the obvious demarcation of the injury.
- If there is any question as to the “superficial” nature of the bowel injury, more aggressive management strategies should be employed.
- If a deeper or perforating bowel injury is noted, a generous excision of the affected area of the bowel or, more commonly, a resection of a segment of bowel is required to prevent serious complications.

Thompson et al. reported on the conservative management of superficial thermal bowel injuries with observation in the hospital, hyperalimentation, and intravenous antibiotics (35). The authors reported that 2/33 (6%) patients with superficial appearing electrosurgical bowel injuries required laparotomy because these two cases resulted in acute perforation during the observation period. Clearly, however, intraoperative repair of damaged bowel is significantly safer and should be performed in every case of suspected electrosurgical bowel injury. Application of bipolar coagulation energy may be used to avoid visceral and vascular injuries associated with monopolar electrocautery, but thermal injury can still occur with bipolar instrumentation. The use of shielded instruments, bipolar electrosurgery, and visualization of the entire “hot” portion of the instrument will decrease the risk of inadvertent injury to adjacent tissues. A full abdominal inspection should be done at the beginning and end of each laparoscopic procedure to rule out any visceral injury. Careful application of energy sources is critical to minimize the risk of energy-based injuries; efforts should be made to avoid contact with nontarget tissues and other instrumentation, which may result in direct coupling. The insulation of each monopolar and bipolar instrument should be checked by the operative staff and the surgeon prior to application. Use of ultrasonic shears can prevent many of the complications associated with monopolar electrocautery, because ultrasound instruments do not apply current within the body

^aEthicon, Cincinnati, OH.

^bOlympus America Inc., Melville, NY.

and have less energy spread from the site of application compared to monopolar and bipolar instrumentation.

MECHANICAL BOWEL INJURY

Mechanical bowel injuries may result from different types of instruments, and may be either blunt or sharp. In the authors' experience, mechanical injuries most commonly occur outside the laparoscopic field of vision. Blind introduction of instruments or retraction, or dissection of the tissues outside of the field of vision is most commonly responsible for mechanical injury.

On recognition, the majority of mechanical injuries may undergo immediate repair by intracorporeal suturing, even though the patient has not had a formal bowel preparation. Bowel resection is rarely necessary considering the localized mechanical damage to the bowel.

The abdomen is irrigated copiously with 3 to 4 L of saline at the end of the procedure. More significant injuries may require excision of bowel segment, and consultation with a general surgeon should be considered for more extensive injuries.

If not recognized intraoperatively, fever, nausea, ileus, and other signs of laparoscopic bowel injury as previously described develop in the very early postoperative period. Diagnosis is suspected if the patient is not having an expected postoperative recovery. Again, computed tomography scan with oral contrast agent is invaluable and should be performed early if there is any suspicion of bowel injury. Once recognized, immediate return to the operating room for local excision or resection of the bowel with end-to-end anastomosis and peritoneal lavage with saline irrigation is performed.

Delicate handling of the tissue and care during introduction of the instruments through the laparoscopic trocars, preferably under direct vision, should prevent mechanical bowel injury. Additionally, instruments should not be left unattended within the abdominal cavity while they are not in use.

GASTRIC OR DUODENAL INJURIES

Inadvertant injury to the stomach can occur specifically during left nephrectomy or adrenalectomy. A small gastric perforation can be closed by intracorporeal laparoscopic purse-string suturing, if the surgeon is comfortable with laparoscopic suturing technique.

An abdominal drain is placed adjacent to the repaired site and the stomach is decompressed with a nasogastric tube. Injury to the duodenum during Kocherization is a very serious complication because duodenal leak has high morbidity and a potential mortality.

Duodenal injury occurs most frequently during renal surgery on the right side or during laparoscopic retroperitoneal lymphadenectomy. Duodenal injury is managed by open conversion and repair of the duodenal injury along with placement of an abdominal drain.

It may necessitate resection of a segment of the duodenum and duodenojejunal anastomosis. Intraoperative general surgical consultation is mandatory. Total parenteral nutrition may also be necessary. Gentle handling of tissues and avoidance of the use of energy close to the bowel segment should prevent the above injuries. Duodenal injury can be avoided in most cases by an active search for the duodenum during surgical procedures that require Kocherization. As soon as the ascending colon is reflected, the surgeon should begin an active search for the duodenum. While usually quite distinct, the duodenum can be decompressed and difficult to discern. Active searching for the duodenum increases the likelihood of identification without damaging this sensitive structure.

HEPATOBIILIARY, SPLENIC, OR PANCREATIC INJURY

Hepatic and splenic injury may result from Veress needle passage, initial trocar insertion, or an unmonitored auxiliary instrument.

Organomegaly noted on computed tomography imaging before laparoscopy should prompt lower abdominal or umbilical primary trocar placement. As haptic feedback is limited with laparoscopy, retraction injuries to organs, which are outside the surgeon's field of vision, are a common source of laparoscopic liver and splenic injury. Retraction injuries can be minimized by application of a mechanical self-retaining retraction system that is connected at one end to the side rails of the operating room table and

On recognition, the majority of mechanical injuries may undergo immediate repair by intracorporeal suturing, even though the patient has not had a formal bowel preparation. Bowel resection is rarely necessary considering the localized mechanical damage to the bowel.

Inadvertant injury to the stomach can occur specifically during left nephrectomy or adrenalectomy. A small gastric perforation can be closed by intracorporeal laparoscopic purse-string suturing, if the surgeon is comfortable with laparoscopic suturing technique.

Duodenal injury occurs most frequently during renal surgery on the right side or during laparoscopic retroperitoneal lymphadenectomy. Duodenal injury is managed by open conversion and repair of the duodenal injury along with placement of an abdominal drain.

Hepatic and splenic injury may result from Veress needle passage, initial trocar insertion, or an unmonitored auxiliary instrument.

Minor injuries to the liver or spleen may be controlled by compression onto the bleeding site with a rolled surgical gauze, or hemostatic cellulose gauze. Surgical hemostatic agents such as fibrin glue or Floseal® are also very useful for superficial injuries to the liver and spleen. If these measures fail, open surgical repair of a liver injury or splenectomy may be necessary.

Pancreatic injury can occur during left-sided renal or adrenal surgery.

In all cases of suspected pancreatic injury, an intra-abdominal suction drain is left in the left renal bed, and postoperatively, fluid from the drain is sent for amylase levels for evidence of pancreatic injury.

at the other end, to the shaft of the retracting instrument. The retractor can then be placed in position under direct vision and then locked in position. Unlike an assistant who may fatigue, the fixed retraction systems are indefatigable, reliable, and safe.

Minor injuries to the liver or spleen may be controlled by compression onto the bleeding site with a rolled surgical gauze, or hemostatic cellulose gauze. Surgical hemostatic agents such as fibrin glue or Floseal® are also very useful for superficial injuries to the liver and spleen. If these measures fail, open surgical repair of a liver injury or splenectomy may be necessary.

Injury to gall bladder can occur due to perforation. Laparoscopic cholecystectomy after general surgical consultation is appropriate.

Pancreatic injury can occur during left-sided renal or adrenal surgery.

Preoperative evaluation of the computed tomography scan help the surgeon identify a long tail of pancreas, which may drape over the adrenal gland or over a portion of Gerota's fascia. Careful dissection of the plane between the tail of pancreas and the Gerota's fascia should prevent trauma to the pancreas.

In all cases of suspected pancreatic injury, an intra-abdominal suction drain is left in the left renal bed, and postoperatively, fluid from the drain is sent for amylase levels for evidence of pancreatic injury.

If there is superficial injury to the pancreas, general surgical consultation is obtained and usually a drain in the region for few days should suffice. A major pancreatic duct injury may necessitate distal pancreatectomy by laparoscopic stapling technique or by an open conversion. If the laparoscopic technique is employed, a tissue load should be applied on the tail of the pancreas. If an open pancreatic duct is identified, this structure should be closed with a figure of eight suture to minimize the risk of leakage. In all cases of suspected pancreatic injury, a suction drain should be left in position.

PREVIOUS OPEN ABDOMINAL SURGERY AND LAPAROSCOPIC SURGERY

Previous abdominal surgery is generally considered a risk factor for bowel injury during subsequent laparoscopic access and dissection. The effect of previous abdominal surgery (open or laparoscopic) on urological laparoscopy in a single center was studied by Parsons et al. (36). Of the 700 patients 52% (366) had never undergone abdominal surgery, 15% (105) had history of abdominal surgery at the same anatomical region, and 33% (229) had abdominal surgery at a different region. The complication rates for patients who had no previous surgery, who had same-site surgery, and who had different site surgery were 4.8%, 9.4%, and 10.7%, respectively. Conversion to open surgery was 1.2%, 7.5%, and 5.7%, respectively. However, there was no statistical differences between the above three groups in terms of complication ($p = 0.11$) and conversion ($p = 0.08$) rates in patients with and without previous abdominal surgery.

Mechanical bowel preparation is recommended in patients with prior abdominal surgery due to the increased risk of bowel injury in these cases. Bowel preparation will not decrease the risk of bowel injury, but may avert a diverting colostomy if an injury should occur. Application of open direct vision (Hasson) trocar placement may help to minimize the risk of bowel injury in patients with prior abdominal surgery. Patients with prior abdominal laparoscopic surgery represent a special case. Pattaras et al. compared postoperative adhesion formation after open and laparoscopic procedures and demonstrated that de novo bowel adhesions following operative laparoscopy were minimal (37). While care is still required in patients with prior laparoscopic abdominal surgery, the risk of bowel injury is likely smaller compared to that in patients with prior open surgery.

HAND-ASSISTED LAPAROSCOPY

With the hand-assisted laparoscopic approach, a standard 6 to 8 cm incision is made at the outset of the procedure, and the pneumoperitoneum is commonly obtained via the hand-assisted device. With the hand-assisted laparoscopic approach, access-related bowel and vascular complications should be extremely rare. In contrast, wound complications such as herniation and infection are more common (38). Care should be taken to avoid inclusion of a bowel loop during closure of the hand-assisted device site,

©Baxter, Deerfield, IL.

because these are difficult wounds to close with the patient in a semilateral position. Prospective, randomized trials are in progress to truly compare the relative efficacy and safety of hand-assisted versus standard laparoscopic techniques.

TROCAR SITE HERNIA

If the bowel function does not return early, causes such as postoperative ileus, bowel perforation, or trocar site hernia causing bowel obstruction should be suspected.

Trocar site hernias are reported to occur in 0.77% to 3% of all types of laparoscopic procedures (39,40).

If the bowel function does not return early, causes such as postoperative ileus, bowel perforation, or trocar site hernia causing bowel obstruction should be suspected.

In adults, trocar sites of < 5 mm are at low risk for the development of incisional hernias. These sites are not closed in the adult, but are closed in the child. For >10 mm trocar insertion sites created by cutting bladed tipped trocars, the fascia is approximated with a single figure-of-eight absorbable suture using a Carter–Thomason cannula or other suture-assist device. Trocars should be removed under vision to identify any herniated omentum or intestine. CO₂ is largely evacuated before the removal of the trocars, and the valves of the cannula are closed to prevent sucking a bowel loop, up into the wound.

Of note, traditional bladed trocars create a fascial defect equal to the diameter of the trocar. In contrast, nonbladed dilating trocars create a defect half the diameter of the trocar. Thus, 12-mm dilating trocars should not require fascial closure because the fascial defect will only be 6-mm in size. In our experience, 12-mm dilating trocars are only closed when patients have a history of weak fascia (i.e., prior hernia), are malnourished, have been taking steroids, or have some other pathology, which can degrade the integrity of the normal fascia. With this technique, the authors have seen no hernias despite deployment of over a thousand dilating trocars. However, many surgeons, even when using nonbladed trocars, prefer to still close any midline abdominal port because it crosses no muscle. Although there are no reports in the literature, the authors are aware of a single adult case of a nonmidline trocar site herniation with a dilating trocar (41).

Trocar site herniation may manifest by localized abdominal discomfort, a palpable tender or a nontender bulge at the previous trocar site, or with signs of bowel obstruction. The diagnosis is made by computed tomography scan, which will show a loop of bowel protruding through the abdominal fascia. If suspected, exploration, either laparoscopic (via an uninvolved port site) or open, should be undertaken. Usually the bowel loop can be reduced without the need for resection.

RECTAL INJURY DURING RADICAL PROSTATECTOMY

Rectal injury during radical prostatectomy converts the case from a clean contaminated to a contaminated procedure and may increase the risk of septic complications, such as wound infection, pelvic abscess, peritonitis, rectourethral fistula, and death. The reported incidence of rectal injury during open radical prostatectomy ranges from 0% to 9%. The average incidence of rectal injuries reported in the larger series of laparoscopic radical prostatectomies is 1.7% (28/1647 procedures) (42). Guillonnet et al. reported 13 rectal injuries (1.3%) in their first 1000 laparoscopic transperitoneal radical prostatectomies (42). None of these patients had previous prostatic surgery, or had received preoperative radiotherapy or hormonal therapy. Of the 13 rectal injuries, 11 were diagnosed intraoperatively and primarily repaired. Of the 11 intraoperative rectal repairs, nine healed primarily without colostomy. Two patients who had intraoperative rectal repair by a single-layer closure developed fever and abdominal pain. Both were explored and required resuturing of small rectal defect without colostomy in one and the other required colostomy. Rectal injury was diagnosed postoperatively in two patients. Both of them presented with umbilical pain, fever, and abdominal distension after three and four days. One had a small rectal perforation, which was managed by colostomy only. The other patient had colostomy only, but developed a rectourethral fistula, which required perineal repair after three months. In the majority of the above cases (10/11), rectal injury occurred during non-nerve-sparing radical prostatectomy. Ten of 11 rectal injuries were recognized intraoperatively, the injuries occurred during the dissection of the posterior surface of the prostatic apex and in one during wide excision of the neurovascular bundle.

The management of rectal injuries during laparoscopic radical prostatectomy depends on the nature of the injury and the surgeon's experience. Minor rectal injuries identified intraoperatively may be closed laparoscopically if the surgeon is comfortable with laparoscopic reconstructive technique. Larger rectal injuries require laparotomy and bowel diversion.

The management of rectal injuries during laparoscopic radical prostatectomy depends on the nature of the injury and the surgeon's experience. Minor rectal injuries

identified intraoperatively may be closed laparoscopically if the surgeon is comfortable with laparoscopic reconstructive technique. Larger rectal injuries require laparotomy and bowel diversion.

Once rectal injury is recognized intraoperatively, the operative field is copiously irrigated with saline and povidone iodine, and the prostatectomy is completed. Thereafter, the margins of the rectal defect are clearly identified with an intrarectal metallic bougie or by digital rectal examination. The rectal wall mucosa and muscular layers are defined. The rectal wall is then closed in two layers, inner mucosa and outer seromuscular layer, with continuous sutures with a 3-0 polyglactin 17 mm half circle needle. The integrity of the repair is then checked by filling the rectum with air after it has been obstructed more proximally. Air is instilled via a rectal catheter to distend the rectal lumen, and the field is inspected. Filling the pelvis with sterile saline will help identify air bubbles. After irrigating the pelvic cavity again, vesicourethral anastomosis is performed. The posterior sutures are placed with careful attention not to incorporate the rectal wall, and the water tightness of the anastomosis is confirmed by filling the bladder with 180 mL of normal saline through the urethral catheter. Abbou and coworkers also report their experience of successful primary closure of rectal injury by laparoscopic intracorporeal suturing (43). In addition, these authors describe reinforcement of double-layered closure of rectal injury by a fat flap made from omentum for a transperitoneal approach or perirectal fat for an extraperitoneal approach.

A drain is placed posterior to the bladder close to the rectal repair and a second drain is placed anteriorly in the space of Retzius. Anal dilation is not required. Broad-spectrum antibiotics (third-generation cephalosporins and metronidazole) are given for five to seven days. Oral liquids are started the day after surgery and after passing flatus and a low-residue diet is initiated. A voiding cystourethrogram is performed after 10 to 14 days, and the urethral catheter is removed if there is no evidence of anastomotic leak or passage of flatus through the Foley catheter.

Rectal injury can occur when the Denonvilliers' fascia is not properly incised at the base of the prostate during the retrovesical dissection or more often during the apical dissection.

Early in one's experience, the use of an intrarectal bougie may facilitate detection of the plane of Denonvilliers' fascia and allow better detection of the limits of the rectal wall by movement of the rectum and tactile sensation produced by the bougie. Extreme care should be taken during prostate dissection in patients who had neoadjuvant hormonal ablation treatment, previous transurethral prostatectomy, previous rectal surgery, pelvic radiation, infection, and in those patients who have undergone multiple prostate biopsies or saturation biopsy of the prostate. In these patients, the natural planes of dissection are likely to be poor.

SURGEON EXPERIENCE

Studies have shown that the incidence of complications and the conversion rate decrease significantly after the surgeon has performed more than 40 to 50 laparoscopic procedures (4,44). Complications, as previously noted, are also related to the difficulty of the laparoscopic procedure. Laparoscopic training is now a part of all urological residency programs, and extensive training is now offered in more than 20 fellowships in the United States. Assisting in laparoscopic procedures and then independently performing procedures under the supervision of an experienced surgeon can be accomplished via a formal mentoring system. This should minimize major complications including bowel complications.

Rectal injury can occur when the Denonvilliers' fascia is not properly incised at the base of the prostate during the retrovesical dissection or more often during the apical dissection.

SUMMARY

- Laparoscopic bowel injury, if not promptly recognized and treated, can result in devastating consequences.
- The postoperative presenting symptoms and signs are not typical of bowel perforation following open surgery.
- Close postoperative clinical monitoring and serial imaging with computed tomography of the abdomen and pelvis are valuable.
- A low threshold for surgical exploration could be lifesaving.

- A thorough knowledge of the anatomy, surgeon's experience, and constant awareness of the potential problems associated with energy-based instrumentation are crucial in preventing majority of the gastrointestinal complications of urologic laparoscopy.
- Detailed preoperative discussion with the patient about all possible complications including bowel injury is mandatory.
- Proper patient selection, surgeon's experience, meticulous attention to detail, and knowledge of potential complications that are associated with each procedure are the most important factors in minimizing complications.

REFERENCES

1. Parsons JK, Varkarakis I, Rha KH, Jarrett TW, Pinto PA, Kavoussi LR. Complications of abdominal urologic laparoscopy: longitudinal five-year analysis. *Urology* 2004; 63(1):27–32.
2. Gomella LG, Abdel-Meguid TA, Sosa E, et al. Laparoscopic urologic surgery outcome assessment. *J LapEndosc Adv Surg Tech* 1997; 7:77–86.
3. Gill IS, Kavoussi LR, Clayman RV, et al. Complications of laparoscopic nephrectomy in 185 patients: a multi-institutional review. *J Urol* 1995; 154:479–483.
4. Fahlenkamp D, Rassweiler J, Fornara P, et al. Complications of laparoscopic procedures in urology: experience with 2,407 procedures at 4 German centers. *J Urol* 1999; 162:765–771.
5. Soulie M, Salomon L, Plante P, et al. Multi-institutional study of complications in 1085 laparoscopic urologic procedures. *Urology* 2001; 58:899–903.
6. Bishoff JT, Allaf ME, Moore RG, et al. Laparoscopic bowel injury: Incidence and clinical presentation. *J Urol* 1999 161:887–890.
7. Philips PA, Amaral JF. Abdominal access complications in laparoscopic surgery. *J Am Coll Surg* 2001; 192:525–536.
8. Mintz M. Risks and prophylaxis in laparoscopy: a survey of 100,000 cases. *J Reprod Med* 1977; 5:269–272.
9. Schafer M, Lauper M, Krahenbuhl L. Trocar and Veress needle injuries during laparoscopy. *Surg Endosc* 2001; 15:275–280.
10. Southern Surgeons Club. A prospective analysis of 1518 laparoscopic cholecystectomies. *NEJM* 1991; 324:1073–1078.
11. Clayman RV, McDougall EM: *Laparoscopic Urology*. St. Louis: Quality Medical Publishing, Inc., 1993:185.
12. Borgatta L, Gruss L, Barad D, et al. Direct trocar insertion versus Veress needle use for laparoscopic sterilization. *J Reprod Med* 1990; 35:891–894.
13. Byron J, Markenson G. A randomized comparison of Veress needle and direct trocar insertion for laparoscopy. *Surg Gyn Obstet* 1993; 177:259–262.
14. Nezhat F, Silfen SL, Evans D, et al. Comparison of direct insertion of disposable and standard reusable laparoscopic trocars and previous pneumoperitoneum with Veress needle. *Obstet Gyn* 1991; 78:148–150.
15. Venkatesh R, Landman J, Clayman RV, et al. Prospective randomized comparison of traditional cutting and dilating disposable trocars for laparoscopic access. *J Urol (Suppl)* 2002; 167(4):4.
16. Hanney RM, Carmalt HL, Merrett N, et al. Use of the Hasson cannula producing a major vascular injury at laparoscopy. *Surg Endosc* 1999; 13:1238–1240.
17. Penfield A. How to prevent complications of open laparoscopy. *J Reprod Med* 1985; 30:60–663.
18. Halevy A, Kais H, Efrati Y, et al. Continuous esophageal pH monitoring during laparoscopic cholecystectomy. *Surg Endosc* 1994; 8:1294–1296.
19. Schippers E, Ottinger AP, Anurov M, et al. Intestinal motility after laparoscopic vs. conventional cholecystectomy. An animal experiment study and clinical observation. *Langenbecks Arch Chir* 1992; 377:14–18.
20. Harkki Siren P, Kurki T. A nationwide analysis of laparoscopic complications. *Obst Gynec* 1992; 89:108.
21. Bateman BG, Kolp LA, Hoeger K. Complications of laparoscopy—operative and diagnostic. *Fertil Steril* 1996; 66:30.
22. Wolfe BM, Gardiner BN, Leary BF, Frey CF. Endoscopic Cholecystectomy: an analysis of complications. *Arch Surg* 1991; 126:1192.
23. Deziel DJ, Millikan KW, Economou SG, Doolas A, et al. Complications of laparoscopic cholecystectomy: a national survey of 4,292 hospitals and an analysis of 77,604 cases. *Am J Surg* 1993; 165:914; 43:572.
24. Phillips EH, Franklin M, Carroll BJ, et al. Laparoscopic colectomy. *Ann Surg* 1992; 216:703.
25. Schrenk P, Woisetschlager R, Reiger R, Wayand W. Mechanism, management and prevention of laparoscopic bowel injuries. *Gastrointest Endosc* 1996; 12(2):148–150.
26. Loffer FD, Pent D. Indications, contraindications and complications of laparoscopy. *Obst Gynec Surv* 1975; 30:407.
27. Kaali SG, Barad DH. Incidence of bowel injury due to dense adhesions at the sight of direct trocar insertion. *J Reprod Med* 1992; 60:617.
28. Casey AC, Rarias-Eisner R, Pisani AL, et al. What is the role of reassessment laparoscopy in the management of gynecologic cancers in 1995. *Gynec Oncol* 1996; 60:454.
29. Davis GD, Wolgamott G, Moon J. Laparoscopically assisted vaginal hysterectomy as definitive therapy for stage III and IV endometriosis. *J Rep Med* 1993; 38:557.

30. Chapron C, Querleu D, Mage G, et al. Complications de la coeliochirurgie gynécologique: étude multicentrique à partir de 7604 celioscopes. *J Gynec Obst Biol Reprod* 1992; 21:207.
31. Kloosterman T, von Blomberg BM, Borgstein P, Meijer S, et al. Unimpaired immune functions after laparoscopic cholecystectomy. *Surgery* 1994; 115:424.
32. Mealy K, Gallagher H, Hyland J, et al. Physiological and metabolic responses to open and laparoscopic cholecystectomy. *Br J Surg* 1992; 79:1061.
33. Harmon GD, Senagore AJ, Kilbride MJ, Warzynski MJ. Interleukin-6 response to laparoscopic and open colectomy. *Dis Colon Rectum* 1994; 37:754.
34. Landman J, Olweny, Sundaram CP, et al. Prospective comparison of the immunological and stress response following laparoscopic and open surgery for localized renal cell carcinoma. *J Urol* 2004; 171(4):1456–1460.
35. Thompson BH, Wheelless CR. Gastrointestinal complications of laparoscopic sterilization. *Obst Gynec* 1973; 41:669.
36. Parsons JK, Jarrett TJ, Chow GK, Kavoussi LR. The effect of previous abdominal surgery on urological laparoscopy. *J Urol* 2002; 168:2387–2390.
37. Pattaras JG, Moore RG, Landman J, et al. Incidence of postoperative adhesion formation after transperitoneal genitourinary laparoscopic surgery. *Urology* 2002; 59:37.
38. Strup SE, Trabulsi EJ, McGinnis, ED, et al. Complications of hand-assisted laparoscopic nephrectomy: a review of 118 consecutive cases. *J Urol* 2002; 167(suppl):168.
39. Munro MG. Laparoscopic access: complications, technologies, and techniques [Review]. *Curr Opin Obstet Gynecol* 2002; 14(4):365–374.
40. Shalhav AL, Barrett E, Lipshifft DA, et al. Transperitoneal laparoscopic renal surgery using blunt 12-mm trocar without fascial closure. *J Endourol* 2002; 6(1):43–46.
41. Lowry PS, Moon TD, D'Alessandro A, Nakada SY. Symptomatic port-site hernia associated with a non-bladed trocar after laparoscopic live-donor nephrectomy. *J Endourol* 2003; 17(7):493–494.
42. Guillonnet G, Gupta R, Fettouh El, Cathelineau X, Baumert H, Vallancien G. Laparoscopic Management of rectal injury during laparoscopic radical prostatectomy. *J Urol* 2003; 169:1694–1696.
43. Katz R, Borkowski T, Abbou CC, et al. Operative management of rectal injuries during laparoscopic radical prostatectomy. *Urology* 2003; 62(2):310–313.
44. Bennett CL, Stryker SJ, Ferreira MR, et al. The learning curve for laparoscopic colorectal surgery: preliminary results from a prospective analysis of 1194 laparoscopic assisted colectomies. *Arch Surg* 1997; 132(1):41–44.

LAPAROSCOPIC COMPLICATIONS: NEUROMUSCULAR

Dan B. French and Robert Marcovich

*Department of Urology, University of Texas Health Science Center at San Antonio,
San Antonio, Texas, U.S.A.*

<ul style="list-style-type: none"> ■ INTRODUCTION ■ ANATOMIC OVERVIEW <ul style="list-style-type: none"> Brachial Plexus Ulnar Nerve Median Nerve Femoral Nerve Obturator Nerve Peroneal Nerve ■ RISK FACTORS FOR NEUROMUSCULAR INJURY 	<ul style="list-style-type: none"> Patient Factors Operative Factors ■ TYPES OF INJURIES <ul style="list-style-type: none"> Rhabdomyolysis Peripheral Neuropathies Prevention and Management of Peripheral Neuropathy ■ SUMMARY ■ REFERENCES
--	---

INTRODUCTION

Laparoscopic surgery has benefited an immeasurable number of urologic patients in the past decade. Practitioners offer a laparoscopic approach because of its well-known advantages, including decreased postoperative pain, more rapid recovery, and improved cosmesis. Nevertheless, laparoscopy shares many of the risks of open surgery, including the potential for neuromuscular complications. Although rare, a neuromuscular injury can counteract the positive aspects of laparoscopy and result in prolonged recovery and increased, perhaps chronic, postoperative pain. Because most neuromuscular injuries occur outside of the operative field, and over a relatively prolonged time period, the surgeon must be particularly vigilant to guard against their occurrence before, during, and after the case.

Neuromuscular complications are generally well defined in the contemporary open surgical literature, but much less has been written about such injuries in the laparoscopic setting. Neuromuscular injuries comprise relatively minor incisional neuralgias, peripheral nerve damage, and limb- and life-threatening compartment syndromes resulting in rhabdomyolysis.

ANATOMIC OVERVIEW (1)

Brachial Plexus

The most common peripheral nerves or neural structures at risk for surgery-related injury in the upper extremity are the brachial plexus and the ulnar and median nerves, whereas in the lower extremity, the femoral, obturator, and peroneal nerves are at risk.

The brachial plexus (Fig. 1) is derived from the ventral rami of C5 through T1 and gives rise to most nerves supplying the arm. The plexus begins in the neck and proceeds into the axilla as it passes under the clavicle and over the first rib. The plexus can be divided into three different cords, but it is more important to understand that, from these cords, the terminal branches of the plexus become the radial, median, ulnar, musculocutaneous, and axillary nerves.

Ulnar Nerve

The ulnar nerve, receiving fibers from C8 and T1, courses anterior to the triceps muscle and then dives into the medial intermuscular septum. It then proceeds posterior to the medial epicondyle (Fig. 2). At this point, the nerve lies in a superficial position and is susceptible to trauma. The nerve is also vulnerable to compression in the cubital tunnel, which is composed of a tendinous arch joining the humeral and ulnar heads. The nerve then enters the forearm and supplies the flexor carpi ulnaris and half of the flexor digitorum profundus.

The most common peripheral nerves or neural structures at risk for surgery-related injury in the upper extremity are the brachial plexus and the ulnar and median nerves, whereas in the lower extremity, the femoral, obturator, and peroneal nerves are at risk.

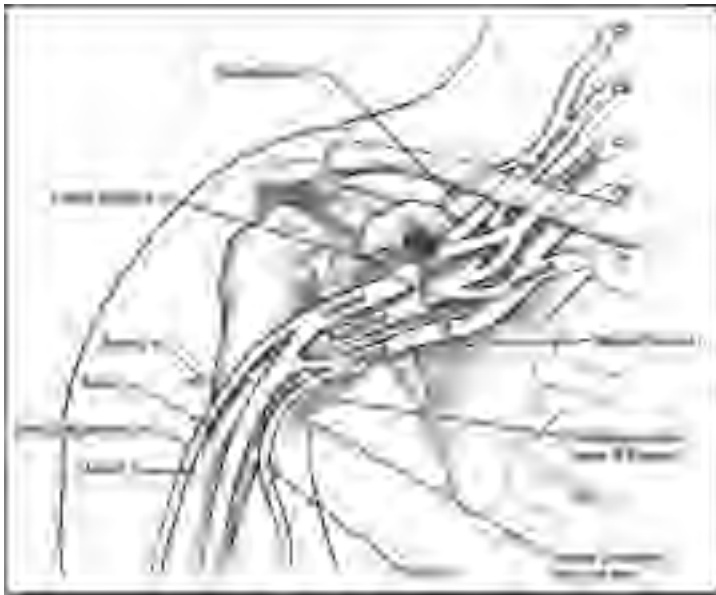


FIGURE 1 ■ The brachial plexus.

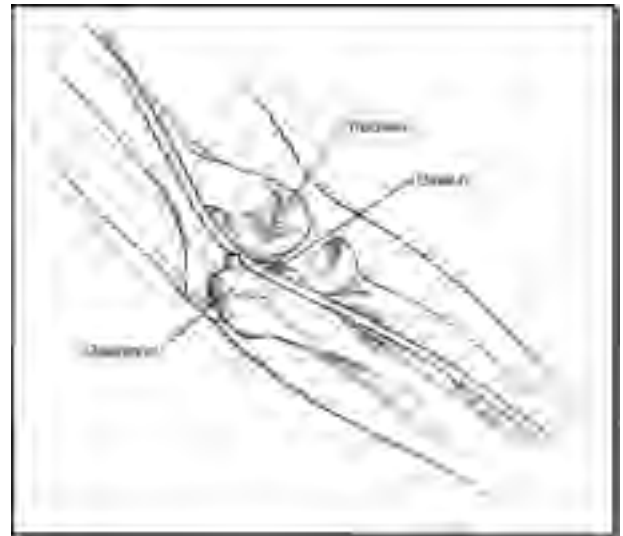
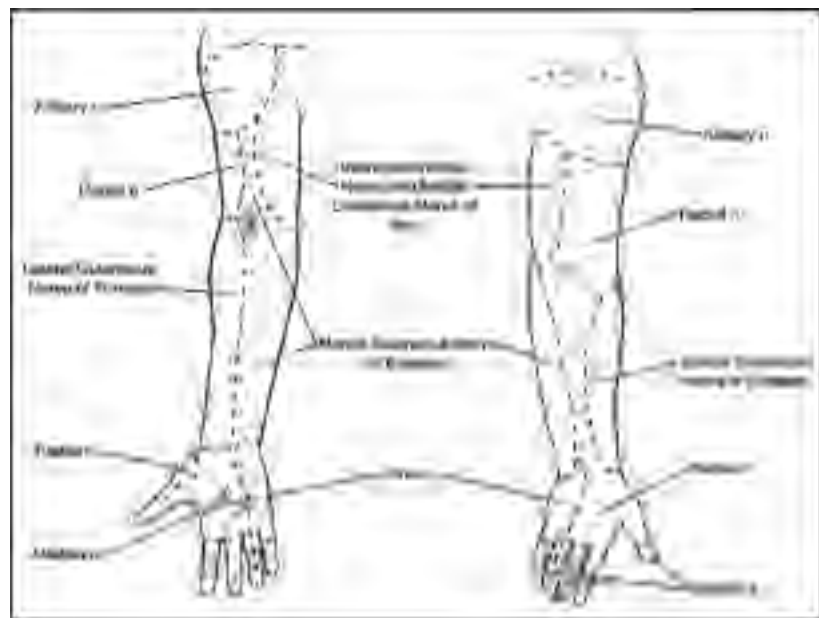


FIGURE 2 ■ Ulnar nerve running posterior to medial epicondyle.

FIGURE 3 ■ Sensory innervation of the upper extremity.



muscles. Its cutaneous innervation provides sensation to the fifth digit and half of the fourth digit along with sensation to that part of the hand (Fig. 3).

Median Nerve

The median nerve receives fibers from C6 through T1. It crosses from lateral to the brachial artery to the medial side in the middle of the arm. It then descends into the cubital fossa and enters the forearm with the brachial artery. It supplies the remainder of the flexor muscles not supplied by the ulnar nerve, including flexor pollicis longus and the other half of the flexor digitorum profundus. Cutaneous innervation provides sensation to the first, second, and third digits and that part of the hand on the palmar side (Fig. 3). On the dorsal side, it only provides sensation to the distal first through third digits.

Femoral Nerve

The femoral nerve is derived from the L2 to L4 roots of the lumbar plexus and, from the psoas muscle, runs deep to the inguinal ligament at its midpoint, and courses with and

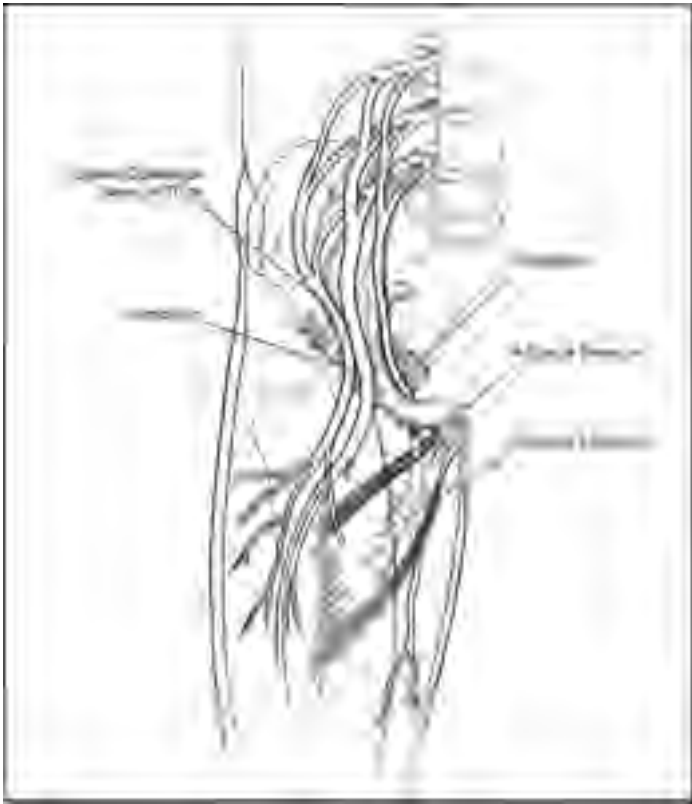


FIGURE 4 ■ Anatomy and motor innervation of femoral and obturator nerves.

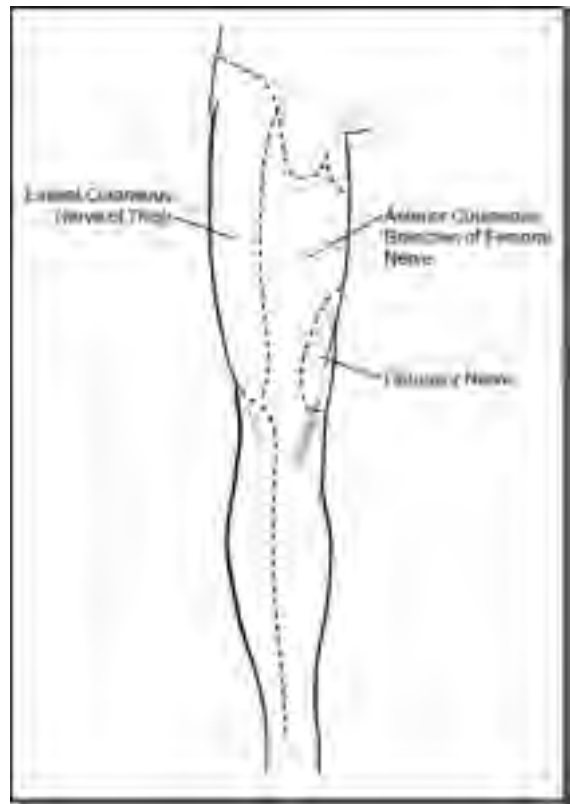


FIGURE 5 ■ Sensory innervation of the femoral and obturator nerves.

lateral to the femoral vessels in the thigh (Fig. 4). It innervates the anterior thigh muscles. Sensory innervation is to the anterior and medial thigh (Fig. 5).

Obturator Nerve

The obturator nerve also has its roots from L2 to L4 and courses from the lumbar plexus along the pelvic sidewall and into the obturator canal (Fig. 4). Lymph nodes reside in the extraperitoneal fat in close proximity to the obturator nerve along the pelvic sidewall. The obturator nerve supplies the thigh adductors including the adductors longus, brevis, and magnus. Sensory innervation is to the medial thigh (Fig. 5).

Peroneal Nerve

The common peroneal nerve (Fig. 6) is a branch of the sciatic nerve originating at the superior angle of the popliteal fossa. It leaves the fossa and winds around the head of the fibula, where it is susceptible to injury. Subsequently, it divides into its terminal branches, supplying the anterior muscles of the leg as well as the fibularis muscles. Motor functions of the peroneal nerve include dorsiflexion and plantarflexion of the foot (Fig. 7), whereas sensory innervation is to the lateral and anterior leg and dorsum of foot (Fig. 8).

TABLE 1 ■ Risk Factors for Neuromuscular Complications

Advanced patient age
Lean body habitus
Muscular build
Longer operative time
Extreme lithotomy or full flank position
Upper retroperitoneal procedure

RISK FACTORS FOR NEUROMUSCULAR INJURY

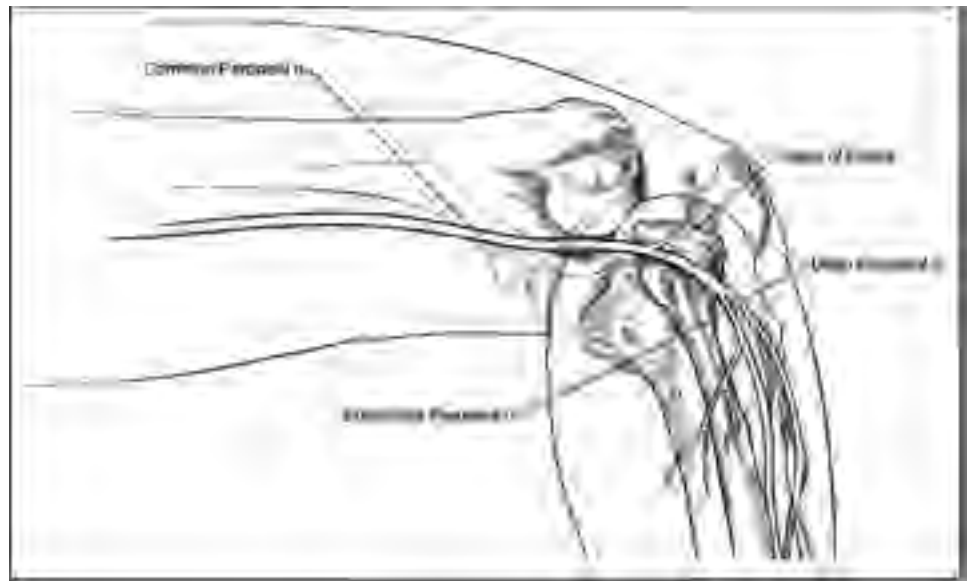
Patient Factors

Several risk factors for peripheral nerve injury and rhabdomyolysis related to the patient have been cited, including patient age and body habitus (Table 1).

Body Habitus

It seems logical that patients with less body fat would be more susceptible to compression injuries due to decreased natural padding of bony prominences. The literature on this topic is divided and varies according to which nerve is studied. Kvist-Poulsen and Borel found that femoral neuropathy after hysterectomy was not related to body habitus,

FIGURE 6 ■ Common peroneal nerve in proximity to head of fibula and bifurcating into deep and superficial peroneal nerves.



Although there is a paucity of literature on this as it pertains to laparoscopy, it would appear that the surgeon should be especially vigilant for nerve injuries in thin patients.

but to other factors such as type of retractor used (2), which would not apply in the laparoscopic setting. In contrast, Kwaan and Rappoport described brachial plexus stretch injuries occurring more frequently in patients of lighter body weight (3). The discrepancy in these findings may be explained by the fact that positioning during hysterectomy maintains the femoral nerve in anatomic position whereas the brachial plexus is susceptible to stretch or compression in various positions, including those likely to be used for retroperitoneal laparoscopy.

Although there is a paucity of literature on this as it pertains to laparoscopy, it would appear that the surgeon should be especially vigilant for nerve injuries in thin patients.

With respect to body weight and risk of rhabdomyolysis, Wolf et al. found in a survey of neuromuscular injuries during urologic laparoscopy that patients with rhabdomyolysis were significantly heavier than other patients with complications (4). Although generally heavier, some of these patients were relatively lean with a body mass index of less than 26, suggesting that muscle mass more than obesity may be a risk factor.



FIGURE 7 ■ Motor function of the peroneal nerves.

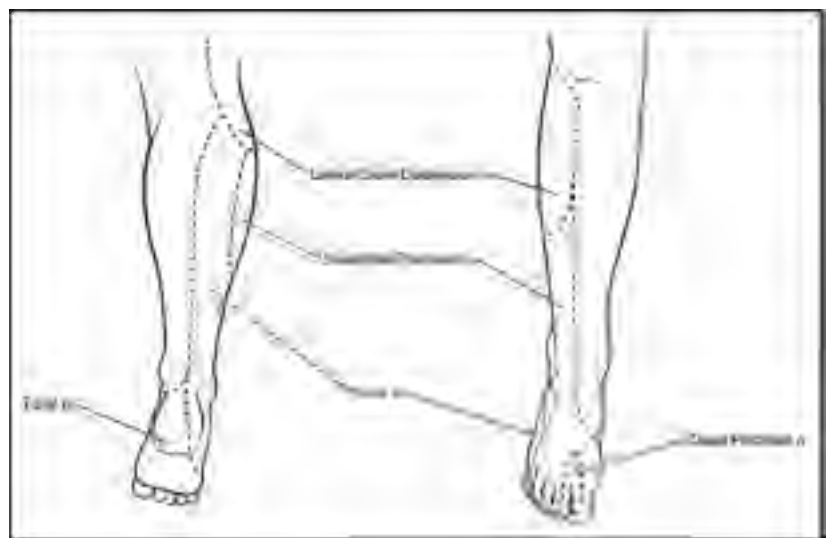


FIGURE 8 ■ Sensory innervation of the superficial and deep peroneal nerves.

Gender

Of the six patients who experienced rhabdomyolysis in the survey of Wolf et al., five (83%) were males (3). It is unlikely that male gender is an independent risk for rhabdomyolysis, but rather a surrogate for increased lean body mass.

Age

Advanced age may be a risk factor for the development of peripheral neuropathy postoperatively. Wolf et al. found that those patients with motor nerve palsies were the oldest group and postulated a higher prevalence of preexisting subclinical nerve deterioration in the elderly (3).

Operative Factors

Operative Time

Operative time is also a risk factor for rhabdomyolysis and peripheral nerve injury, making it a greater concern in laparoscopy, which can subject the patient to prolonged periods on the operating table. Rhabdomyolysis has been reported in as little as 4.5 hours in the full flank position (5), and similar times are reported for the lithotomy position.

In peripheral neuropathies caused by nerve compression or stretching, risk of nerve injury increases as operative time increases. Prolonged positioning in the lithotomy position is known to increase risk of lower extremity neuropathy (6).

Operative Position

The risk of peripheral nerve injury and rhabdomyolysis also depends on operative position. The occurrence of rhabdomyolysis during extreme lithotomy positioning is well documented. Wolf et al. found that all patients in their survey who developed clinical rhabdomyolysis were placed in the flank position. Although this condition was more common in patients in full flank position (67% of patients with rhabdomyolysis) versus modified flank (37%), table flexion did not appear to make a difference (3).

Operative positioning plays a major role in development of postoperative peripheral neuropathy. The flank position places upper extremity nerves at risk. The downside brachial plexus is at risk for compression injury in this position. The lithotomy position is associated with a host of lower extremity neuropathies, including femoral, peroneal, and sciatic neuropathies.

The flank and modified flank positions can be associated with postoperative pain in the upside shoulder secondary to stretch injury to the suprascapular nerve during circumduction or because of joint contusion (3). Wolf et al. found that patients who are thin and young with relatively free range of motion of the shoulder joint were at risk for this type of complication (3).

Upper Abdominal vs. Lower Abdominal Procedures

In their analysis of neuromuscular complications in urologic laparoscopy, Wolf et al. drew a distinction between upper retroperitoneal and lower retroperitoneal procedures (3). They found that upper retroperitoneal procedures were more than twice as likely (3.1% vs. 1.5%) to result in neuromuscular complication than lower retroperitoneal procedures. While the authors did not speculate as to the reason for this difference, it is likely that use of the flank position in upper retroperitoneal procedures may be a contributing factor.

TYPES OF INJURIES

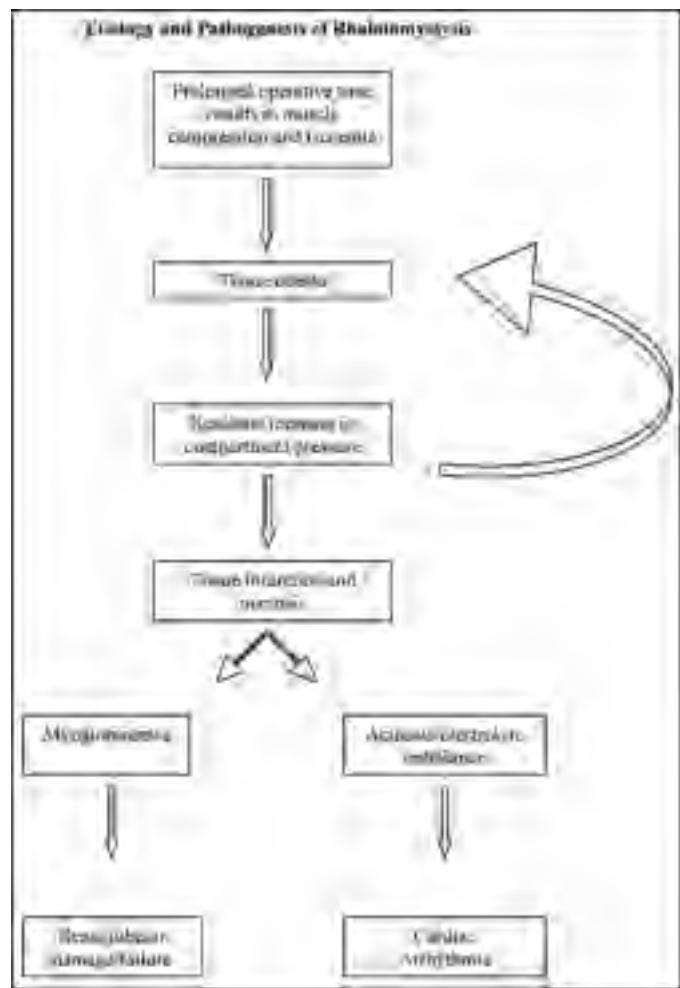
Rhabdomyolysis

Rhabdomyolysis is the most severe neuromuscular complication of laparoscopic surgery. Thirty percent of cases result in acute renal failure (7).

The pathogenesis of rhabdomyolysis is a cascade of events that begins with prolonged muscle compression (Fig. 9) leading to tissue ischemia. It has been estimated that ischemia develops at tissue pressures that are within 10–30 mmHg of diastolic blood pressure (8). As a result, the compressed ischemic tissue becomes edematous, precipitating a further rise in compartment pressures. This process is exacerbated when the patient is repositioned postoperatively and the ischemic compartment is reperfused. If this self-perpetuating cycle continues, tissue ischemia leads to necrosis, resulting in acidosis and release of myoglobin from damaged muscle cells. In the setting of metabolic acidosis, myoglobin and heme breakdown products cause renal tubular obstruction, contributing to acute renal failure (9).

The occurrence of rhabdomyolysis during extreme lithotomy positioning is well documented.

Rhabdomyolysis is the most severe neuromuscular complication of laparoscopic surgery. Thirty percent of cases result in acute renal failure.

FIGURE 9 ■ Pathogenesis of rhabdomyolysis.

Hypotension during the surgical procedure may potentiate rhabdomyolysis because the compartment pressure will more closely approach the diastolic blood pressure during such episodes. Hypotension should increase the surgeon's index of suspicion for rhabdomyolysis. Patients with peripheral vascular disease are felt to be at increased risk secondary to preexisting impairment of perfusion to the lower extremity myofascial compartments. Operative time is also another concern, as mentioned previously. With respect to positioning, extreme lithotomy and lateral decubitus using a kidney rest are the two positions associated with rhabdomyolysis for urologic procedures.

The first key to diagnosis is having a high index of suspicion when any of the aforementioned factors are present. The patient will complain of pain, often intense, at the site of tissue necrosis, and this may present even as soon as the patient is transferred to the recovery room. There is usually swelling and erythema of the affected area. The urine assumes a characteristic tea color caused by myoglobin pigment and tests positive for myoglobin. Serum creatine phosphokinase levels are markedly elevated, usually above 10,000–20,000 IU/L and sometimes over 100,000 IU/L, peaking several days postoperatively. Arterial blood gas will confirm metabolic acidosis. Imaging is usually not necessary for diagnosis, although Ali et al. described using a Tc^{99m} whole body bone scan to confirm the diagnosis in a case where the urine myoglobin was negative (10). Serum potassium and creatinine levels should also be monitored, ever mindful of the possibility for acute renal failure and all its sequelae.

Once rhabdomyolysis is suspected, treatment should be initiated promptly. Hydration, urinary alkalization, and diuresis are the mainstays of treatment.

These help minimize the toxic effects of myoglobin on the renal tubules. Bildsten et al. suggested the use of sodium bicarbonate intravenously at a dose of 50–100 mEq/L to keep urine pH above 6.5 and furosemide or mannitol in conjunction

Once rhabdomyolysis is suspected, treatment should be initiated promptly. Hydration, urinary alkalization, and diuresis are the mainstays of treatment.

with intravenous hydration to maintain urine output at or above 1.5 mL/kg/hr (11). Frequent monitoring of serum electrolytes is necessary until renal function has stabilized. If renal failure progresses, hemodialysis may be necessary in the acute setting until renal function has returned.

Peripheral Neuropathies

Pathogenesis

Injuries to peripheral nerves have several etiologies. It is commonly accepted that stretch, compression, generalized ischemia, or any combination thereof contribute to postoperative sensory or motor deficits. Compression can be from direct contact with a surface from positioning or it may be indirect as the nerve is stretched over a bony prominence. All of these factors ultimately result in ischemia or mechanical damage that lead to structural and/or functional derangement of the affected nerve (12). Alvine and Schurrer have suggested that subclinical neuropathies are present in many patients who suffer a postoperative nerve injury (13). This conclusion is based on the fact that nerve conduction velocities were abnormally slow in both the affected and contralateral ulnar nerves in patients with postoperative ulnar neuropathies. Most studies note an average time to onset of symptoms of three to five days (Table 2).

Brachial Plexus Palsy

The brachial plexus is at risk of injury due to stretching from surgical positioning. The brachial plexus (C5–T1) courses from its vertebral foramina into the axilla and lies near several bony prominences that can act as a fulcrum, contributing to stretch injury. Stretch is thought to be maximal at 90° abduction and slight extension (14). When positioning the patient, it would be prudent to avoid the combination of extension and abduction. The clinical sequelae of brachial nerve injury vary according to which part of the plexus, upper versus lower, is injured. Stretch injury usually affects the upper plexus (C5–C7). Injury to this part of the plexus usually results in decreased strength and weakness of the affected arm, and is usually painless, though radicular pain may occur. There also may be a sensory deficit of the first three digits and the lateral forearm. Lower plexus injury is rarely due to surgical positioning.

When it occurs, brachial plexus palsy is usually due to Trendelenburg positioning, with the patient supported by shoulder pads. Thus, the potential for this type of injury exists in patients undergoing laparoscopic radical prostatectomy and laparoscopic radical cystectomy, or any other procedure in which the patient is in steep Trendelenburg for a prolonged period of time.

When it occurs, brachial plexus palsy is usually due to Trendelenburg positioning, with the patient supported by shoulder pads. Thus, the potential for this type of injury exists in patients undergoing laparoscopic radical prostatectomy and laparoscopic radical cystectomy, or any other procedure in which the patient is in steep Trendelenburg for a prolonged period of time.

TABLE 2 ■ Summary of Peripheral Neuropathies

Nerve	Position	Cause of injury	Prevention of injury	Deficit
Brachial plexus (C5–T1)	Shoulder abduction + extension or use of shoulder braces in steep Trendelenburg	Stretch of the nerve roots	Avoiding 90° of abduction with extension and avoiding use of shoulder braces	Usually painless weakness of affected arm (C5–C7) or “waiter’s tip” deformity (C8–T1)
Ulnar nerve	Elbow flexion and pronation	Nerve compression as it passes through cubital tunnel	Avoid extreme elbow flexion and adding pressure to elbow with tape	Numbness or pain at elbow and along fifth digit. Weakness of flexion of fourth and fifth digits
Median nerve	Complete extension of elbow	Nerve stretch	Avoid complete elbow extension by padding under forearm	Pain or tingling of thumb, index, and middle fingers. Thenar muscle weakness
Peroneal nerve (L4, 5; S1, 2)	Lithotomy	Nerve compression by stirrups as nerve passes over head of fibula	Ensure weight of leg is supported by heel in stirrup, proper padding of lateral aspect of leg	Numbness of foot dorsum, weakness of foot and toe extension
Femoral nerve (L2–4)	Any	Direct surgical trauma to nerve	Care to avoid prolonged pressure or trauma to iliopsoas muscle intraoperatively	Numbness of anterior and medial thigh and weakness of quadriceps muscles
Obturator nerve (L2–4)	Any, but usually lithotomy	Direct surgical trauma to nerve	Careful intraoperative dissection and use of electrocautery	Pain radiating through medial thigh

Wolf et al. noted that none of their cases of pelvic laparoscopy with the patient in steep Trendelenburg suffered upper extremity injuries (3), but this was prior to the era of laparoscopic prostatectomy and cystectomy. Should injury to the lower portion of the plexus occur, it usually manifests as a motor deficit, with the arm favoring an adducted and posteriorly extended position known as a “waiter’s tip deformity.”

Ulnar Neuropathy

Symptoms of ulnar neuropathy are that of pain about the elbow or along the fifth digit and that side of the hand. Alternatively, the patient may experience tingling, paresthesia, hypesthesia, and/or numbness in the ulnar distribution (Fig. 3). Motor deficits include weakness in flexion of the fourth and fifth digits. Alvine et al. noted that six of their 17 patients with ulnar neuropathy were positioned in the flank position, and in all of these patients, the injury occurred in the arm contralateral to the side that was in contact with the operating table (12). Nerve damage is due to compression of the ulnar nerve in the cubital tunnel that results from elbow flexion. The nerve is more susceptible to external compression when in the pronated position. Thus, when positioning a patient, avoidance of prolonged and extreme elbow flexion as well as pronation is advisable. When taping the arm as it is brought across the body, as for laparoscopic nephrectomy in the modified flank position, it is best to avoid placing the tape directly over the unpadded elbow, because it may contribute to compression of the ulnar nerve.

Median Neuropathy

According to Warner, muscular patients with large biceps who do not usually fully extend their elbows are susceptible to stretch injury of the median nerve when the elbow is fully extended under anesthesia (Fig. 10) (11). Although not specific to laparoscopy, this scenario could potentially occur during laparoscopic surgery. Symptoms include pain or tingling in the middle finger, index finger, and thumb, and weakness of the thenar muscles. Prevention of this injury includes padding of the forearm to keep the elbow slightly flexed.

Peroneal Neuropathy

The common peroneal nerve is susceptible to compression injury because it courses around the head of the fibula (Fig. 6). Poor positioning in a leg holder can easily compress this bony prominence because it has little overlying tissue for natural padding. The peroneal nerve of the downside leg can also be compressed if not carefully padded when the patient is in flank position. Symptoms of peroneal neuropathy include weakness of foot and toe extension and numbness over the dorsum of the foot (Figs. 7 and 8). Positioning the foot in the leg holder with the weight of the legs supported by the heel and avoidance of direct contact with the fibular head or generous padding of this area will help prevent injury to the peroneal nerve.

Femoral Neuropathy

Femoral nerve injury results most commonly from retractor placement during open surgery and is therefore unlikely to be encountered after laparoscopic procedures. It is thought that retractors stretch the nerve or cause ischemia as they apply pressure to the iliopsoas muscle. It is conceivable that a direct injury could occur during laparoscopy from dissection along the pelvic sidewall. Femoral neuropathy manifests as weakness of the quadriceps muscles and sensory deficits of the anterior and medial thigh (Fig. 5).

Obturator Neuropathy

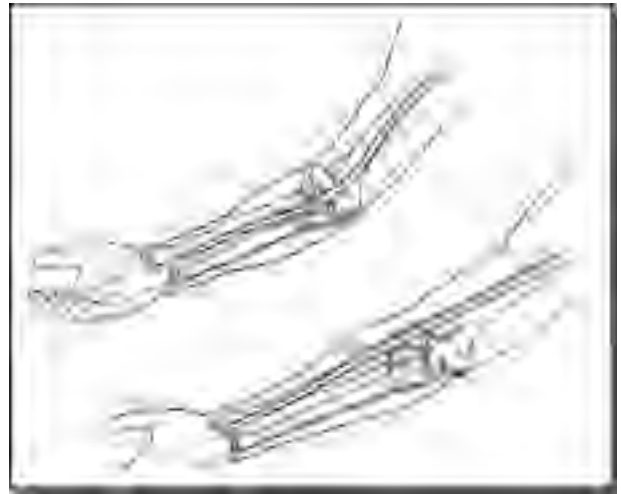Direct surgical trauma to the nerve, rather than positioning, causes obturator neuropathy. Wolf et al. reported this in two of 405 patients undergoing pelvic laparoscopic surgery (3). Stolzenburg noted a higher incidence of obturator nerve injury occurring in two of 70 patients undergoing laparoscopic prostatectomy (15), a series representing the authors’ initial experience with that procedure. Symptoms of obturator neuropathy include pain radiating from the groin down to the medial thigh and weakness of the thigh adductor muscles.

Direct surgical trauma to the nerve, rather than positioning, causes obturator neuropathy.

Abdominal Wall Neuralgias

Wolf et al. defined abdominal wall neuralgias as pain, impaired sensation, or hyperesthesia radiating from a port site (3). These were the most common type of neuromuscular complication reported in their survey, with an incidence of 1%. It is interesting to note that patients experiencing abdominal wall neuralgias had relatively low-body mass index, perhaps indicating a greater statistical likelihood of a trocar injury to a cutaneous nerve in patients with relatively less surface area compared to larger patients.

FIGURE 10 ■ Stretching of the median nerve with full extension of the elbow.



Prevention and Management of Peripheral Neuropathy

The most effective way to manage a neuromuscular injury is to prevent it from happening in the first place. The overall low incidence of such complications in both the open surgical and laparoscopic literature attests to how effective the surgical community has been in preventing their occurrence. The first principle is that all members of the operating room team, including the surgeon, assistant, anesthesiologist, scrub nurse, and circulator must contribute to ensuring that the patient is correctly positioned and padded. All joints must be in an anatomically normal position, avoiding both hyperextension and hyperflexion, as well as overabduction and overadduction. Joints, especially the shoulder, elbows, and knees should be supported with pillows or similar padding. If the operating table is to be repositioned during the case (as for laparoscopic nephrectomy in the modified flank position), it should be tested prior to draping the patient to ensure that minimal movement of the patient occurs in the new position, that joints remain appropriately supported, and that no unprotected areas come in contact with an unpadded surface. If the patient is secured to the operating table with tape, bony prominences should be protected with a towel or gel pad to avoid compression injury, especially during procedures in which the table positioning changes and potentially increases the pressure on these areas. Cushioning is particularly important for procedures expected to exceed five hours in order to minimize the risk of rhabdomyolysis. Prior to such procedures, it would be prudent to inform the patient of the possibility of neuromuscular injury and to document this in the preoperative surgical consent.

Fortunately, most peripheral neuropathies are self-limited, requiring no treatment other than observation and reassurance. Duration of symptoms is variable, but most resolve within weeks to months after the insult. Occasionally, symptoms persist past one year, and can even remain permanently. Consultation with a neurologist soon after symptoms are noted can help identify the reason for injury and possibly provide prognosis. The neurologist may perform electromyography or nerve conduction velocity studies to further elucidate the problem and can aid in recommending treatment, including physical therapy.

TABLE 3 ■ Incidence of Neuromuscular Complications in Selected Urologic Laparoscopic Series

Series (Ref.)	Year	No. of cases	Type of procedure	% Neuromuscular injury	Types of injury
Stolzenburg et al. (15)	2003	70	Lap prostatectomy	2.8	Obturator nerve palsy
Ramani et al. (16)	2003	399	Lap renal and adrenal	0.3	Psoas muscle laceration
Vallancien et al. (17)	2002	1311	Various	0.08	Obturator trauma during lap PLND
Dunn et al. (18)	2000	60	Lap radical nephrectomy	5.0	Sciatic and sural nerve dysfunction. Motor weakness right forearm
Guillonnet et al. (19)	2002	567	Lap prostatectomy	0.5	Compressive neuropraxia-2 Axonal degeneration-1
Fahlenkamp et al. (20)	1999	2407	Various	0.3	Ilioinguinal, iliohypogastric, femoral, and obturator nerve injuries
Thomas et al. (21)	1996	282	Lap PLND (85%) Lap renal surgery (15%)	0.7	Brachial nerve palsy

Abbreviations: PLND, pelvic lymphadenectomy; Lap, laparoscopic.

SUMMARY

- Neuromuscular complications from laparoscopic surgery are uncommon (Table 3) and probably no more likely to occur than in open surgery.
- Most neuromuscular complications are not specific to laparoscopy, though certain aspects of laparoscopy such as positioning of the patient and operative time can place patients at risk.
- Neuromuscular injuries range from abdominal wall neuralgia to potentially life-threatening rhabdomyolysis. Although uncommon, these injuries are often preventable.
- Preoperative knowledge of risk factors and attention to patient positioning and operative technique can minimize their incidence.
- In the case of rhabdomyolysis, early diagnosis and prompt treatment can minimize the gravity of the sequelae.

REFERENCES

1. Moore KL, Dalley AF II. Clinically Oriented Anatomy. 4th ed. Baltimore: Lippincott, 1999.
2. Kvist-Poulsen H, Borel J. Iatrogenic femoral neuropathy subsequent to abdominal hysterectomy: incidence and treatment. *Obstet Gynecol* 1985; 60:516–520.
3. Kwaan JHM, Rappoport I. Postoperative brachial plexus palsy. *Arch Surg* 1970; 101:612–615.
4. Wolf JS, Marcovich R, Gill IS, et al. Survey of neuromuscular injuries to the patient and surgeon during urologic laparoscopic surgery. *Urology* 2000; 55:831–836.
5. Dahlberg PJ, Howard RS. Rhabdomyolysis: an unusual post-operative complication. *J Urol* 1982; 127:520–521.
6. Warner MA, Martin JT, Schroeder DR, Offord KP, Chute CG. Lower extremity motor neuropathy associated with surgery performed on patients in a lithotomy position. *Anesthesiology* 1994; 81:6–12.
7. Brady HR, Brenner BM. Acute renal failure. In: Fauci AS, Braunwald E, Isselbacher KJ, et al., eds. *Harrison's Principles of Internal Medicine*. 14th ed. New York: McGraw-Hill, 1998:1505–1513.
8. Whitesides TE, Haney TC, Morimoto K, Harad H. Tissue pressure measurements as a determinant for the need of fasciotomy. *Clin Orthop* 1975; 113:43–51.
9. Knochel JP. Rhabdomyolysis and myoglobinuria. *Annu Rev Med* 1982; 33:435–443.
10. Ali H, Nieto JG, Rhany RK, Chandarlapaty SKC, Vaamonde CA. Acute renal failure due to rhabdomyolysis associated with the extreme lithotomy position. *Am J Kidney Dis* 1993; 22:865–869.
11. Bildsten SA, Dmochowski RR, Spindel MR, Auman JR. The risk of rhabdomyolysis and acute renal failure with the patient in the exaggerated lithotomy position. *J Urol* 1994; 152:1970–1972.
12. Warner MA. Perioperative neuropathies. *Mayo Clin Proc* 1998; 73:567–574.
13. Alvine FG, Schurrer ME. Post-operative ulnar-nerve palsy: are there pre-disposing factors? *J Bone Joint Surg Am* 1987; 69:255–259.
14. Dawson DM, Krarup C. Perioperative nerve lesions. *Arch Neurol* 1989; 46:1355–1360.
15. Stolzenburg J, Do M, Rabenalt R, et al. Endoscopic retroperitoneal radical prostatectomy: initial experience after 70 procedures. *J Urol* 2003; 169(6):2066–2071.
16. Ramani AS, Steinberg AP, Desai M, et al. Evaluation of age and comorbidity as risk factors after laparoscopic urologic surgery. *J Urol* 2003; 170(4):1115–1120.
17. Vallancein G, Cathelineau X, Baumert H, Doublet JD, Guillonnet B. Complications of transperitoneal laparoscopic surgery in urology: review of 1,311 procedures at a single center. *J Urol* 2002; 168(1):23–26.
18. Dunn MD, Portis AJ, Shalhar AL, et al. Laparoscopic versus open radical nephrectomy: a 9 year experience. *J Urol* 2000; 164(4):1153–1159.
19. Guillonnet B, Rozet F, Cathelineau X, et al. Perioperative complications of laparoscopic radical prostatectomy: the Montsouris 3-year experience. *J Urol* 2002; 167(1):51–56.
20. Fahlenkamp D, Rassweiler J, Fornara P, Frede T, Loening SA. Complications of laparoscopic procedures in urology: experience with 2,407 procedures at 4 German centers. *J Urol* 1999; 162:765–770.
21. Thomas R, Steele R, Ahuja S. Complications of urologic laparoscopy: a standardized 1 institution experience. *J Urol* 1996; 156:469–471.

Sidney C. Abreu*Section of Laparoscopy, ANDROS-Santa Helena Hospital of Brasilia, Brasilia, Brazil***João Batista G. Cerqueira***Section of Renal Transplantation, Federal University of Ceará, Fortaleza, Brazil***Gilvan Neiva Fonseca***Federal University of Goiás, Goiás, Brazil*

■ INTRODUCTION

■ INCIDENCE

■ ETIOLOGY

Pneumothorax

Pneumomediastinum

Pneumopericardium

■ DIAGNOSIS AND MANAGEMENT

■ PREVENTION

■ SUMMARY

■ REFERENCES

INTRODUCTION

Laparoscopic urology has evolved from relatively simple and limited procedures to the practice of a variety of sophisticated operations. As the complexity and number of laparoscopic cases expand, an increase in the number, magnitude, and spectrum of surgical related complications is inevitable.

INCIDENCE

The records of 619 patients that underwent major urologic laparoscopic procedures at the Cleveland Clinic and had at least one chest X-ray taken in the immediate or early postoperative period were analyzed (1). Of these patients, 438 (71%) had completely normal chest X-ray.

In a recent study from the Cleveland Clinic, medical pulmonary complications, surgical thoracic complications, and subclinical incidentally detected gas collections in the chest were identified in 12.6%, 0.5%, and 5.5% of patients, respectively.

Medical complications (12.6%) included pulmonary infiltrate/atelectasis (9.7%), pleural effusion (4.8%), and pulmonary embolus (0.3%). Surgical complications included symptomatic pneumothorax in four patients (0.35%), hemothorax in one (0.08%), and chylothorax in one (0.08%). Subclinical abnormal thoracic gas collections were radiographically noted in 34 of the 619 patients (5.5%) with a chest X-ray: 19 pneumomediastinum (3.1%), 10 pneumothorax (1.6%), and 5 pneumopericardium (0.8%) (Tables 1 and 2). No patient had an open conversion to complete the initial proposed operation. Only one patient (0.08%) required an open reexploration of the thorax in the entire series. There was no patient mortality due to a thoracic complication (1).

The number of transperitoneal and retroperitoneal procedures was equivalent. Retroperitoneal laparoscopy was associated with a higher incidence of abnormal thoracic gas collections (transperitoneal 3, retroperitoneal 33).

However, all these radiographic findings were incidental and asymptomatic, requiring no further intervention. On the other hand, the incidence of thoracic complications that required additional surgical intervention during transperitoneal and retroperitoneal laparoscopy was similar: one case and three cases, respectively (1).

ETIOLOGY**Pneumothorax**

Pneumothorax following abdominal laparoscopic procedures can result from a variety of causes. In patients without obvious iatrogenic pleural or diaphragmatic injury, congenital

In a recent study from the Cleveland Clinic, medical pulmonary complications, surgical thoracic complications, and subclinical incidentally detected gas collections in the chest were identified in 12.6%, 0.5%, and 5.5% of patients, respectively.

Retroperitoneal laparoscopy was associated with a higher incidence of abnormal thoracic gas collections (transperitoneal 3, retroperitoneal 33).

TABLE 1 ■ Distribution of Medical and Surgical Thoracic Complications

Procedure	Total no. of patients	Patients with postoperative chest X-ray	Normal postoperative chest X-ray	Medical pulmonary complications ^a	Surgical thoracic complications	Incidental abnormal gas collections
Radical nephrectomy	265	176	121	49	1	6
Partial nephrectomy	172	91	61	27	1	9
Nephroureterectomy	90	70	51	18	0	3
Renal cryoablation	88	71	37	28	2	6
Donor nephrectomy	175	73	64	12	0	4
Simple nephrectomy	19	7	4	2	2	0
Adrenalectomy	117	95	68	26	0	4
Radical prostatectomy	203	36	31	4	0	1
Total	1129	619	437	166 events in 142 pts (12.6%)	6 of 1129 pts. (0.5%)	34 of 619 chest x-rays (5.5%)

^a Including 3 cases of pulmonary embolism treated with IVC filter placement without mortality

Source: From Ref.1.

TABLE 2 ■ Surgical Thoracic Complications and Abnormal Gas Collections in the Chest

Procedure	Pneumothorax		Hemothorax	Chylothorax	Pneumo-mediastinum	Pneumo-pericardium	Total
	Requiring chest tube	No chest tube					
Radical nephrectomy	1	2			4		7
Partial nephrectomy		5 ^a			6 ^b		11
Nephroureterectomy					2	1 ^c	3
Cryoablation	1	2	1		3	1	8
Donor nephrectomy		1			2	1	4
Simplet nephrectomy	1†			1			2
Adrenalectomy					2	2 ^c	4
Radical prostatectomy		1					1
Total	3	11	1	1	19	5	40

^a One patient each required intra-operative diaphragmatic repair^b Concomitant pneumothorax in one patient^c Concomitant pneumomediastinum in one patient each

Source: From Ref.1.

During retroperitoneoscopy, subcutaneous emphysema extending up to the neck could potentially allow CO₂ to enter the superior mediastinum and apical pleural space.

diaphragmatic defects, such as a patent pleuroperitoneal canal or attenuated areas in the diaphragm due to improper embryonic fusion, may allow peritoneal CO₂ to gain access into the pleural space (2–4). Retroperitoneally insufflated CO₂ can dissect along natural musculofascial planes into the mediastinal space. Once inside the mediastinum, CO₂ can gain entry into the pleural cavity through the pulmonary hilum dissecting along pulmonary vasculature, or through a rupture in the mediastinal pleura resulting in pneumothorax formation (2,4). An apical pneumothorax can occur due to the rupture of apical blebs from barotrauma (positive pressure during mechanical ventilation) (3). Aspiration of the pneumothorax could determine whether it occurred due to endotracheal anesthesia and positive pressure ventilation, or due to tissue propagation of carbon dioxide. Other anesthesia-related issues such as pleural injury during central line placement or elevated maximum end-tidal carbon dioxide pressure can be potentially causative (3).

During retroperitoneoscopy, subcutaneous emphysema extending up to the neck could potentially allow CO₂ to enter the superior mediastinum and apical pleural space (2–4).

Inadvertent pleural or diaphragmatic injury is an obvious cause of pneumothorax during renal surgery, open or laparoscopic (5). In a series of 253 open flank operations, pleural injury occurred in 63 cases (25%) (6). In another series of 130 open extraperitoneal live donor nephrectomies, pleurotomy occurred in 11 cases (8.5%) (5). Pleural or diaphragmatic injuries can occur during two specific aspects of a laparoscopic procedure: port insertion or tissue dissection. Del Pizzo et al. recently documented pleural injury in 0.6% of 1765 patients undergoing laparoscopic renal surgery at four institutions (7). Pleurotomy occurred during transperitoneal laparoscopy (*N* = 8) while mobilizing the kidney (*N* = 6) or liver (*N* = 2), or during retroperitoneal port placement (*N* = 2). In the series from the Cleveland Clinic, two pleural/diaphragmatic injuries occurred during port insertion for retroperitoneoscopy. In the first case, patient's morbid obesity prevented adequate palpation and identification of the 12th rib, resulting in supracostal port placement with subsequent pleural and diaphragmatic injury. In the second case, the posterior 12 mm port transgressed the most inferior edge of the pleura, resulting in a pneumothorax.

Pneumothorax has also been reported following urological laparoscopic surgery in pediatric patients. Waterman et al. reported that out of 285 laparoscopic urologic procedures performed at their institution, pneumothorax developed in four pediatric patients (three females, one male) (8). Patient age ranged from 8 months to 11 years (mean 5.4 years). Laparoscopic surgical procedures performed included right upper pole partial nephrectomy, left upper pole partial nephroureterectomy, removal of left multicystic dysplastic kidney and bilateral Cohen reimplantation of ureters. Pneumothorax was suspected due to decreased oxygen saturations, subcutaneous emphysema, increased respiratory effort, and decreased chest lung sounds unilaterally (8). Pneumothorax was confirmed with chest X-rays. Conservative management of pneumothorax was used in three patients and a pigtail chest tube was used in one.

Pneumomediastinum

For pneumomediastinum to occur during transperitoneal laparoscopy, the abdominally insufflated CO₂ has to track through the aortic and esophageal hiatus into the mediastinum (2,4).

During retroperitoneal laparoscopy, the lack of subdiaphragmatic peritoneum may facilitate cephalad tracking of CO₂ along the aorta and cava toward the mediastinum (2,4). Therefore, pneumomediastinum may be more likely to occur during retroperitoneoscopy.

In reviewing 63 chest X rays following laparoscopic renal surgery, Wolf et al. identified asymptomatic pneumomediastinum not related to iatrogenic pleural injury in eight cases (13%) (9). Incidental pneumomediastinum occurred more commonly after extraperitoneal procedures (30%) compared to transperitoneal laparoscopy (4.6%). The same finding is reported by the Cleveland Clinic study where 18 (93%) of the 19 patients with pneumomediastinum had undergone retroperitoneal laparoscopy (1).

Pneumopericardium

The exact mechanism of a pneumopericardium formation is unclear. Persistent embryological communications between the pericardial and peritoneal cavities, or rupture of accumulated mediastinal CO₂ alongside a blood vessel are possible etiologic mechanisms (10,11). Although extremely rare, pneumopericardium can result in cardiac tamponade syndrome in the presence of continuous air flow under pressure.

During retroperitoneal laparoscopy, the lack of subdiaphragmatic peritoneum may facilitate cephalad tracking of CO₂ along the aorta and cava toward the mediastinum. Therefore, pneumomediastinum may be more likely to occur during retroperitoneoscopy.

Due to the high solubility of CO₂, in the select clinically stable patient with pneumothorax, pneumopericardium, and pneumomediastinum expectant management including close monitoring and serial chest X-rays is advocated.

Clinically significant pneumothorax may require intraoperative or early postoperative intervention.

DIAGNOSIS AND MANAGEMENT

Due to the high solubility of CO₂, in the select clinically stable patient with pneumothorax, pneumopericardium, and pneumomediastinum expectant management including close monitoring and serial chest X-rays is advocated.

Subclinical gas collections in the chest are usually asymptomatic, and require no further intervention. These abnormal chest gas collections are incidentally detected on routine postoperative X-ray. Perhaps in the early laparoscopic experience, all patients should undergo chest X-ray routinely in the recovery room. However, with evolving experience, postoperative chest X-rays should be obtained selectively only if there is any clinical suspicion of a thoracic complication, according to the patient's clinical status.

Clinically significant pneumothorax may require intraoperative or early postoperative intervention.

Routine postoperative chest X-ray may reveal an extensive pneumothorax with lung collapse requiring a thoracostomy tube. Intraoperatively, sudden hypotension or decrease in O₂ saturation may represent alert signs of a large pneumothorax. Therefore, cooperation between the anesthesiologist and surgical teams is crucial for the precise diagnosis of this complication. Filling the operative field with irrigation fluid can identify air bubbles coming from an inadvertent pleurotomy. A red rubber catheter can be inserted directly into the pleural space and figure-of-eight stitches can be placed laparoscopically to repair the pleural injury around the red rubber catheter, which is attached to continuous water-seal suction. Alternatively, the diaphragmatic rent can be laparoscopically suture repaired with the pneumoperitoneum pressure decreased to 5 mmHg and the anesthesiologist providing positive ventilatory pressure. In the Cleveland Clinic study, two patients developed large pneumothoraces recognized only postoperatively, necessitating chest tube drainage. In both cases, although no frank pleural or diaphragmatic injury was detected intraoperatively, the authors cannot rule it out (1). Similarly, in an open series of 253 flank procedures, two patients developed postoperative pneumothorax without any intraoperative recognition of pleurotomy (6). As such, a high index of suspicion should be maintained because pleural or diaphragmatic injury may not always be recognized intraoperatively.

Rare thoracic surgical complications such as hemothorax and chylothorax have also been reported (1). Acute hemothorax occurred following a retroperitoneoscopic kidney tumor cryoablation. Because of the particular body habitus and obesity (body mass index = 36) of this patient, bony landmarks were difficult to palpate resulting in undiagnosed supracostal placement of the posterior port. Following cryoablation, in the recovery room, the patient was hypotensive, and a chest X-ray demonstrated "whiteout" of the left hemithorax. A tube thoracostomy was inserted with return of fresh blood. An emergency open thoracotomy identified an intercostal arterial bleeder which was suture ligated. Additionally, a 3 cm diaphragmatic rent created by the supracostal port was identified and suture repaired.

Following synchronous bilateral retroperitoneal laparoscopic native nephrectomy for locally symptomatic, huge, autosomal dominant polycystic kidneys, a patient returned to the emergency room complaining of sharp left pleuritic pain with mild shortness of breath. A chest computed tomography scan revealed a large left pleural effusion causing collapse of the left lower lung. Abdominal computed tomography did not reveal any retroperitoneal fluid collection. Pleurocentesis retrieved 300 cc of milky chylous fluid high in chylomicrons and triglyceride. This chylothorax was successfully treated conservatively with low fat diet and medium-chain triglyceride supplementation.

If a diaphragmatic or pleural injury is recognized intraoperatively, the anesthesiologist should be notified immediately. Usually, with careful adjustment of ventilatory parameters, the patient remains clinically stable, allowing completion of the proposed laparoscopic procedure and repair of the diaphragmatic rent.

PREVENTION

If a diaphragmatic or pleural injury is recognized intraoperatively, the anesthesiologist should be notified immediately. Usually, with careful adjustment of ventilatory parameters, the patient remains clinically stable, allowing completion of the proposed laparoscopic procedure and repair of the diaphragmatic rent.

During transperitoneal laparoscopy, care should be taken not to injure the diaphragm while mobilizing the spleen and liver.

During port placement for retroperitoneal laparoscopy in obese patients, whenever the bony landmarks are not clearly identifiable, intraoperative ultrasonography can be employed to precisely locate the 12th rib, thus avoiding inadvertent supracostal port placement (12). When creating the retroperitoneal space, the balloon dilator should be positioned anterior to the psoas muscle and fascia. This maneuver prevents

A blunt tip trocar can be used as the primary port to prevent subcutaneous emphysema.

Full relaxation of the abdominal muscles, as well as avoidance of coughing and straining during laparoscopic procedures is additional precautions to prevent abnormal thoracic gas collections during transperitoneal and retroperitoneal laparoscopy.

stripping the psoas muscle of its investing fascia, and minimizes cephalad tracking of CO₂ along the psoas muscle fibers into the thoracic cavity (4).

A Blunt tip trocar can be used as the primary port to prevent subcutaneous emphysema.

This trocar has an internal fascial retention balloon and an external adjustable foam cuff, which combine to achieve an air-tight seal, thus eliminating air leakage at the primary port site.

Full relaxation of the abdominal muscles, as well as avoidance of coughing and straining during laparoscopic procedures is additional precautions to prevent abnormal thoracic gas collections during transperitoneal and retroperitoneal laparoscopy (13).

These precautions avoid sudden elevations of abdominal pressure above 20 mmHg, which may potentially force abdominal CO₂ through the diaphragmatic hiatus into the mediastinum.

SUMMARY

- Medical pulmonary complications, surgical thoracic complications, and subclinical incidentally detected gas collections in the chest may occur after laparoscopic procedures.
- Retroperitoneoscopy is associated with a higher incidence of abnormal gas collections.
- The select clinically stable patient with pneumothorax, pneumopericardium, and pneumomediastinum occurring after laparoscopy can be treated with expectant management, including close monitoring and serial chest X-ray.
- Clinically significant pneumothorax may require intraoperative or early postoperative intervention.
- An intraoperative diaphragmatic or pleural injury in a patient who remains clinically stable can be managed with careful adjustment of ventilatory parameters. The proposed laparoscopic procedure can be completed and the diaphragmatic rent repaired.
- Full relaxation of the abdominal muscles and avoidance of coughing and straining during laparoscopic procedures are additional precautions to prevent abnormal thoracic gas collections during transperitoneal and retroperitoneal laparoscopy.

REFERENCES

1. Abreu SC, Sharp DS, Ramani AP, et al. Thoracic complications during urological laparoscopy. *J Urol* 2004; 171(4):1451–1455.
2. Wolf JS, Stoller ML. The physiology of laparoscopy: basic principles, complications and considerations. *J Urol* 1994; 152:294.
3. Ramakrishna V, Kibel AS, Lee D, Rehman J, Landman J. Rapid resolution of carbon dioxide pneumothorax (capno-thorax) resulting from diaphragmatic injury during laparoscopic nephrectomy. *J Urol* 2002; 167:1387.
4. Ng CS, Gill IS, Sung GT, Whalley DG, Graham R, Schweizer D. Retroperitoneoscopic surgery is not associated with increased carbon dioxide absorption. *J Urol* 1999; 162:1268.
5. Olsson LE, Swana H, Friedman AL, Lorber MI. Pleurotomy, pneumothorax, and surveillance during living donor nephroureterectomy. *Urology* 1998; 52:591.
6. Poore RE, Sexton WJ, Hart LJ, Assimos DG. Is radiographic evaluation of the chest necessary following flank surgery? *J Urol* 1996; 155:849.
7. Del Pizzo JJ, Jacobs SC, Bishoff JT, Kavoussi LR, Jarret TW. Pleural injury during laparoscopic renal surgery: early recognition and management. *J Urol* 2003; 169:41.
8. Waterman BJ, Robinson BC, Snow BW, Cartwright PC, Hamilton BD, Grasso M. Pneumothorax in pediatric patients after urological laparoscopic surgery: experience with 4 patients. *J Urol* 2004; 171(3):1256–1258.
9. Wolf JS, Monk TG, McDougall EM, McLennan BL, Clayman RV. The extraperitoneal approach and subcutaneous emphysema are associated with greater absorption of carbon dioxide during laparoscopic renal surgery. *J Urol* 1995; 154:959.
10. Nicholson RD, Berman ND. Pneumopericardium following laparoscopy. *Chest* 1979; 76:605.
11. Knos GB, Sung YF, Toledo A. Pneumopericardium associated with laparoscopy. *J Clin Anesth* 1991; 3:56.
12. Abreu SC, Kaouk JH, Steinberg AP, Gill IS. Retroperitoneoscopic radical nephrectomy in a super-obese patient (body mass index 77 Kg/m²). *J Urol* 2004; 63(1):175–176.
13. Doctor NH, Hussain Z. Bilateral pneumothorax associated with laparoscopy. *Anesthesia* 1973; 28:75.

GYNECOLOGIC INJURIES INVOLVING THE URINARY SYSTEM

John E. Jelovsek and Tommaso Falcone

Department of Gynecology and Obstetrics, Cleveland Clinic Foundation, Cleveland, Ohio, U.S.A.

Paul K. Tulikangas

Division of Urogynecology, Department of Obstetrics and Gynecology, University of Connecticut, Hartford, Connecticut, U.S.A.

- INTRODUCTION
- GYNECOLOGIC DISORDERS THAT INVOLVE THE LOWER URINARY TRACT
- PREOPERATIVE GYNECOLOGIC EVALUATION
- UTERINE LEIOMYOMATA
- HYSTERECTOMY
- PELVIC ADHESIONS
- PELVIC INFLAMMATORY DISEASE
- ADNEXAL MASSES
- OVARIAN REMNANT
- CERVICAL CANCER
- ENDOMETRIOSIS
- FISTULA
- URINARY TRACT INJURY DURING GYNECOLOGIC PROCEDURES
- INJURY TO THE URETHRA
- INJURY TO THE BLADDER
- INJURIES TO THE URETER
- MANIPULATORS
- SUMMARY
- REFERENCES

INTRODUCTION

Potential gynecologic disorders that a laparoscopic urologic surgeon may encounter include a gynecologic disorder involving the lower urinary tract, a urinary tract injury that occurred during gynecologic laparoscopic surgery and requiring repair, or an incidental gynecologic disorder identified during a urologic procedure and requiring clinical management.

GYNECOLOGIC DISORDERS THAT INVOLVE THE LOWER URINARY TRACT

Beginning early in embryonic development of the female fetus, the cloaca is divided by the urorectal septum. The urogenital sinus then develops into the bladder, urethra, and lower vagina. The ureters continue to develop from the ureteric bud and join with the developing kidney. This early primordial relationship illustrates the intimate association between the lower urinary tract and the female reproductive system. As a consequence, pathologic processes affecting one system may inevitably involve both systems. It is imperative among surgeons of the female pelvis to have a thorough knowledge of the relationship shared between the gynecologic and urologic systems.

PREOPERATIVE GYNECOLOGIC EVALUATION

Pregnancy status should be determined in all females of reproductive age undergoing surgery. Any suspicion of a pelvic mass, abdominal enlargement, or enlarged uterus should prompt the discussion of the patient's pregnancy status. This is the most common form of pelvic mass in a reproductive age female.

The pregnancy status should be determined in all females of reproductive age undergoing surgery. Any suspicion of a pelvic mass, abdominal enlargement, or enlarged uterus should prompt the discussion of the patient's pregnancy status. This is the most common form of pelvic mass in a reproductive age female.

Pelvic masses including pregnancy, enlarged uteri due to leiomyoma or sarcoma, or adnexal masses are clinically sized using the weeks of gestational age scale. This provides clinicians with a standardized range to use while communicating about clinical assessment of a pelvic mass. The 12-week sized mass is palpated at the level of the pubic symphysis while a 20-week sized mass is palpated at the level of the patient's umbilicus. These sizes are typical for normal pregnancies.

It is not uncommon to perform laparoscopy in the pregnant patient. Although the effects to the fetus during laparoscopic surgery are currently unclear, it is generally agreed upon to closely monitor insufflation pressure.

It is not uncommon to perform laparoscopy in the pregnant patient. Although the effects to the fetus during laparoscopic surgery are currently unclear, it is generally agreed upon to closely monitor insufflation pressure.

Lachman et al. reported on 518 procedures performed during pregnancy. Forty-five percent were cholecystectomy, 34% adnexal surgery, and 15% appendectomy (1). Barnard et al. found that pressures greater than 15 mmHg seemed to decrease uteroplacental blood flow (2). Despite several series reporting that laparoscopy can be successfully performed during pregnancy, it is imperative upon the physician to appropriately assess and counsel the gravid patient regarding increased risks to both her and her fetus.

Minimal gynecologic parameters to be assessed preoperatively are:

- Pregnancy status
- Menstrual cycle history
- Pap smear history
- Patient's interest in future fertility
- Pelvic examination

The most important information is a history of irregular periods or postmenopausal bleeding. This should not be ignored, and if present an evaluation and/or appropriate consultation should be initiated. Typically, an ultrasound evaluation of the endometrium and an endometrial biopsy are performed.

If the patient has not yet completed her family, a discussion of the potential impact of the surgery on her future fertility is recommended. The general principle in modern gynecologic surgery is to be as conservative as possible, especially in women of reproductive age.

UTERINE LEIOMYOMATA

Uterine leiomyomata, usually referred to as fibroids, are the most common benign tumors of reproductive age women. The annual incidence of diagnosed leiomyomata in a cohort of U.S. women aged 25 to 44 was 12.8/1000 women years (3). Estimates show that between 140,000 and 180,000 hysterectomies are performed annually with the majority being performed for uterine leiomyomata (4). The majority of uterine fibroids are asymptomatic and will not require interventions or further investigations. In the properly selected woman with symptomatic fibroids, the result from selected treatment should be an improvement in the quality of life (5). The symptoms usually include abnormal bleeding, dysmenorrhea, or noncyclic symptoms such as pelvic pressure.

Leiomyomata may be located anywhere on the uterus, uterine cervix, or even retroperitoneal space. If large enough, fibroids can result in ureteral compression laterally against the pelvic sidewall. Pelvic exam should be performed preoperatively in an attempt to identify leiomyomata of sufficient size that may contribute to possible bladder symptomatology. These involve symptoms of stress incontinence or detrusor overactivity as they compress the bladder. The variety of positions of fibroids often places the ureter at risk during hysterectomy. Lateral fibroids may impinge upon the uterine vessels, causing them to be deviated as they run along the lateral aspect of the uterus. When clamping the vessels near the uterine cervix during hysterectomy, caution should be exercised to stay as close to the uterus as possible. This is done to avoid clamping excessive parametrial tissue that oftentimes places tension on the ureter medially.

Treatments for symptomatic leiomyomata can be classified as either medical or invasive therapy. Medical therapy includes nonsteroidal anti-inflammatory drugs, oral contraceptive pills, progestational agents, or GnRH agonists. Invasive therapy typically includes uterine artery embolization, coagulation, myomectomy, or hysterectomy. A large systematic review of the literature published from 1975 through 2000 concluded that there were almost no high quality evidence-based treatment strategies (6). When such evidence-based strategies are not interpretable, individual patient and clinician opinion are relied upon.

In the case of an incidental leiomyoma discovered at laparotomy for a primary urologic disease, no intervention is required. If the patient is symptomatic, then a preoperative discussion of her options should be obtained. If the size of the leiomyoma

impedes a proper surgical approach, this also should be discussed preoperatively, and an appropriate decision by the patient should be obtained.

HYSTERECTOMY

Because hysterectomy is one of the most commonly performed gynecologic procedures in the United States, it is no surprise that the majority of urologic injuries occur with this procedure. Most injuries to the ureter occur while attempting to clamp the uterine vessels near their path alongside the uterine cervix.

Because hysterectomy is one of the most commonly performed gynecologic procedures in the United States, it is no surprise that the majority of urologic injuries occur with this procedure. Most injuries to the ureter occur while attempting to clamp the uterine vessels near their path alongside the uterine cervix.

Efforts should be made to avoid lateral deviation into the parametrium, while isolating the uterine vessels. This oftentimes kinks the ureter, resulting in obstruction. It may also lead to ureterovaginal fistula. The second common site of injury to the ureter occurs when clamping the ovarian vessels as they pass through the infundibulopelvic ligament. The close approximation of the ureter medially and inferiorly as it enters the true pelvis often results in damage at this point. This may involve inadvertent clamping or thermal injury to complete transection. The most common site of injury to the bladder during hysterectomy occurs when separating the uterus and bladder anteriorly. Injury above the trigone may occur in this area.

In 1999, Gilmour et al. reviewed reports of lower urinary tract injury from 1966 to 1998 (7). Listed in Tables 1 and 2 are the frequencies of ureteral and bladder injuries after major gynecologic surgery.

The overall frequency of ureteral injury was 1.6/1000. The overall frequency of bladder injury was 2.6/1000. In 2004, the evaluate study included two parallel randomized trials of laparoscopic versus abdominal hysterectomy and laparoscopic versus vaginal hysterectomy (8). The primary outcome was rate of complications. In the laparoscopic versus abdominal trial, laparoscopy was associated with higher complications (11.1% vs. 6.2%, $p = 0.02$; difference, 4.9%, 95% confidence interval, 0.9–9.1). The number needed to treat to harm was 20. The rate of bladder and ureteral injuries was 2.1% and 0.9%, respectively, in the laparoscopic group versus 1% and 0% in the abdominal group. In the laparoscopic versus vaginal study, there was no difference in the rate of major complications (9.8% vs. 9.5%, $p = 0.92$; difference, 0.3%, –5.2% to 5.8%), and the number needed to treat to harm was 333.

PELVIC ADHESIONS

In the reproductive age female, there is concern regarding adhesion formation and resultant infertility. Adhesions are thought to interfere with ovum pickup by the tubal fimbriae. Although the evidence of external adhesions' contribution to decreased fertility is controversial, it is generally recommended to minimize the extent of damage to the serosal surfaces of both the ovary and fallopian tube in females of reproductive age. The potential decrease in fertility as a result of pelvic adhesions should be discussed with the patient.

Pelvic adhesions may result from previous surgery, inflammatory disorders, pelvic infection, or endometriosis. The pathogenesis involves creating a deperitonealized surface. When damage occurs to this surface, the repair process is rapid and essentially in place by eight days. The first process involves primitive mesothelial cells that repair serosal defects from the underlying mesenchyme. The second healing process occurs when fibrin deposits are laid down after three days (9). This results in adhesion formation.

There is a long held belief that adhesions cause chronic pelvic pain. Good evidence exists showing that adhesiolysis does not improve chronic pain. In 2003, Swank et al. reported 100 patients with continuous or intermittent abdominal pain thought to be due to adhesions from previous surgery of at least six months' duration (10). These patients were randomized to diagnostic laparoscopy versus diagnostic laparoscopy and lysis of adhesions. The authors found there was significant pain relief and improvement in generalized quality of life in both groups up to a year from surgery. However, there was no difference between groups, concluding that laparoscopic lysis of adhesions is not more beneficial than diagnostic laparoscopy alone. This may not apply to patients with an identifiable pelvic pathology such as endometriosis in which evidence supports resection of the pathology.

TABLE 1 ■ Frequency of Ureteral Injuries After Major Gynecologic Surgery

Study	Year	Operation	No. of operations	No. of ureteral injuries	No. of ureteral injuries/1000 operations	No. of injuries recognized intraoperatively	No. of injuries recognized postoperatively
Rosen et al.	1996	Open Burch colposuspension	929	4	4.3	0	4
Saidi et al.	1996	Major laparoscopic surgery ^a	953	4	4.2	0	4
Harkki-Siren et al.	1998	Laparoscopic hysterectomy	2,741	37	13.5	2	35
Liu and Reich	1994	Laparoscopic hysterectomy	518	1	1.9	0	1
Stanhope et al.	1991	Major abdominal surgery ^b	2,833	2	0.7	0	2
Daly and Higgins	1988	Major abdominal surgery ^b	1,093	16	14.6	8	8
Falk and Bunkin	1954	Adnexal surgery	567	1	1.8	0	1
Harkki-Siren et al.	1998	Total abdominal hysterectomy	43,149	17	0.4	0	17
Goodno et al.	1995	Total abdominal hysterectomy	2,469	8	3.2	NE	NE
Kunz	1984	Total abdominal hysterectomy	737	3	4.1	1	2
Dicker et al.	1982	Total abdominal hysterectomy	1,283	3	2.3	0	3
Amirikia and Evans	1979	Total abdominal hysterectomy	4,228	5	1.2	NE	NE
Thompson and Benigno	1971	Total abdominal hysterectomy	2,287	9	3.9	NE	NE
Falk and Bunkin	1954	Total abdominal hysterectomy	1,114	1	0.9	0	1
Holloway	1950	Total abdominal hysterectomy	808	6	7.4	1	6
Newell	1939	Total abdominal hysterectomy	944	8	8.5	0	5
Harkki-Siren et al.	1998	Subtotal abdominal hysterectomy	10,354	3	0.3	1	2
Falk and Bunkin	1954	Subtotal abdominal hysterectomy	1,577	1	0.6	1	0
Newell	1989	Subtotal abdominal hysterectomy	2,072	5	2.4	1	2
Stanhope et al.	1991	Major vaginal surgery ^c	2,546	16	6.3	0	16
Harkki-Siren et al.	1998	Vaginal hysterectomy	5,636	1	0.2	0	1
Goodno et al.	1995	Vaginal hysterectomy	1,054	5	4.7	NE	NE
Kudo et al.	1990	Vaginal hysterectomy	9,230	3	0.3	NE	NE
Dicker et al.	1982	Vaginal hysterectomy	568	0	0	0	0
Amirikia and Evans	1979	Vaginal hysterectomy	2,111	2	0.9	NE	NE
Thompson and Benigno	1971	Vaginal hysterectomy	1,533	1	0.7	NE	NE
Falk and Bunkin	1954	Vaginal hysterectomy	1,664	2	1.2	0	2
Copenhauer	1962	Vaginal hysterectomy	1,000	2	2.0	0	2
Edwards and Beebe	1949	Vaginal hysterectomy	570	2	3.5	0	2
Total			107,068	168		15	115

Note: NE = not able to elicit information about whether ureteric injury was diagnosed intraoperatively or postoperatively from the details provided in the report.

^aIncluding laparoscopic hysterectomy (with/without adnexectomy), ovarian cystectomy, and ablation of severe (grade 4) endometriosis (6).

^bIncluding total abdominal hysterectomy and/or other abdominal gynecologic operations for the treatment of pelvic conditions (5,30).

^cIncluding vaginal hysterectomy and/or other vaginal operations for the correction of vaginal prolapse.

TABLE 2 ■ Frequency of Bladder Injuries After Major Gynecologic Surgery

Study	Year	Operation	No. of operations	No. of bladder injuries	No. of bladder injuries/1000 operations	No. of injuries recognized intraoperatively	No. of injuries recognized postoperatively
Saidi et al.	1996	Major laparoscopic surgery ^a	953	11	11.5	8	3
Harkki-Siren et al.	1998	Laparoscopic hysterectomy	2,741	24	8.8	14	10
Ou et al.	1994	Laparoscopic hysterectomy	839	8	9.5	NE	NE
Liu and Reich	1994	Laparoscopic hysterectomy	618	6	11.6	5	1
Harkki-Siren et al.	1996	Total abdominal hysterectomy	43,149	54	1.3	9	45
Kunz	1984	Total abdominal hysterectomy	737	1	1.4	1	0
Dicker et al.	1982	Total abdominal hysterectomy	1,283	4	3.1	4	0
Amirikia and Evans	1979	Total abdominal hysterectomy	4,228	18	4.3	NE	NE
Falk	1967	Total abdominal hysterectomy	1,000	5	5.0	2	3
Graber et al.	1964	Total abdominal hysterectomy	819	16	19.5	11	5
Howkins	1963	Total abdominal hysterectomy	1,000	2	2.0	1	1
Holloway	1950	Total abdominal hysterectomy	808	8	9.9	6	2
Harkki-Siren et al.	1998	Subtotal abdominal hysterectomy	10,854	3	0.3	2	1
Harkki-Siren et al.	1998	Vaginal hysterectomy	5,636	1	0.2	0	1
Kudo et al.	1990	Vaginal hysterectomy	9,230	44	4.8	NE	NE
Dicker et al.	1982	Vaginal hysterectomy	568	9	15.8	8	1
Amirikia and Evans	1979	Vaginal hysterectomy	2,111	4	1.9	NE	NE
Copenhauer	1962	Vaginal hysterectomy	1,000	11	11.0	10	1
Allen and Peterson	1964	Vaginal hysterectomy	2,280	2	0.9	0	2
Total			89,754	231		81	76

Note: NE = not able to elicit information about whether ureteric injury was diagnosed intraoperatively or postoperatively from the details provided in the report.

^aIncluding laparoscopic hysterectomy (with/without adnexectomy), ovarian cystectomy, and ablation of severe (grade 4) endometriosis.

PELVIC INFLAMMATORY DISEASE

Pelvic inflammatory disease should always be considered in the differential diagnosis of acute febrile abdominal pain. Infections of the uterus, tubes, and ovaries may cause infertility and can cause life-threatening sepsis in a significant number of women.

The most frequent acute infection in reproductive age, nonpregnant women is pelvic inflammatory disease. It is an enormous public health problem. In 1998, direct costs were estimated to be around 1.9 billion (11). *Chlamydia* is the most common infectious disease reported to health departments among young, sexually active females. *Chlamydia* and *Neisseria gonorrhoea* are among the major causes of cervicitis and pelvic inflammatory disease. The U.S. Centers for Disease Control and Prevention, however, recommends coverage for a mix of pathogens not just limited to these two organisms. *Chlamydia* and *Neisseria gonorrhoea* are included as well as a mix of anaerobes, gram-negative facultative bacteria, and streptococci.

Diagnosis of pelvic inflammatory disease is a clinical diagnosis. It is made based upon historical and clinical exam findings including a thorough pelvic exam. Laparoscopy is not necessary for the diagnosis of pelvic inflammatory disease. However, many authors have described the diagnosis using the laparoscope. In 1969, Jacobson and Westrom described visual criteria for the laparoscopic diagnosis of salpingitis (12). These include hyperemia of the tubal surface, edema of the tubal wall, and exudate on the tubal surface or from the fimbriated ends when the tubes are patent. Adhesions from pelvic inflammatory disease are usually described as thin and filmy, and involve the fimbriated ends of the fallopian tubes. Patients with active pelvic inflammatory disease may show an erythematous uterus and fallopian tubes. A yellowish-green exudate is sometimes seen around the tubes and ovaries or in the posterior cul-de-sac.

Obstruction to the end of the fallopian tube may result in a hydrosalpinx or pyosalpinx. It is not uncommon to encounter hydrosalpinx inadvertently in an asymptomatic patient while performing laparoscopic surgery for other pathology. Data on management of hydrosalpinx are mixed. The presence of hydrosalpinx reduces the pregnancy rate in patients undergoing in vitro fertilization. Removal of the fallopian tube has been shown to improve fertility rates from in vitro fertilization. However, it is not recommended that an incidentally discovered hydrosalpinx should

The most frequent acute infection in reproductive age, nonpregnant women is pelvic inflammatory disease. It is an enormous public health problem.

be removed without prior discussion with the patient. Consultation regarding the patient's future fertility desires is imperative before attempting to remove an existing hydrosalpinx.

Most patients with pelvic inflammatory disease are treated on an outpatient basis. The Pelvic Inflammatory Disease Evaluation and Clinical Health Study reported on 35 months of follow-up in patients who were diagnosed with mild to moderate pelvic inflammatory disease (13). A single intramuscular dose of cefoxitin (2 g) with probenecid and oral doxycycline for 14 days was as effective as a 48-hour administration of cefoxitin every six hours and the doxycycline course. At 35 months there was no difference in pregnancy rates, recurrence of pelvic inflammatory disease, chronic pelvic pain, or ectopic pregnancy.

The most severe cases of pelvic inflammatory disease will progress to form tuboovarian abscess. These pockets of inflammation are associated with tissue induration and may involve the uterus, ovaries, tubes, and in many cases the bowel. There have been cases of tuboovarian abscess as a cause of ureteral obstruction (14). This can occur unilaterally or bilaterally. Usually, treatment of the tuboovarian abscess will relieve the induration of the periureteral tissues, resulting in resolution of the hydronephrosis. Removal of the offending organ containing the abscess should be considered. In patients who desire future fertility laparoscopic or computed tomography-guided drainage can be performed.

ADNEXAL MASSES

A common finding in both reproductive and nonreproductive age females is an adnexal cyst. These are sometimes found incidentally during urologic procedures. These may arise from the ovary, fallopian tube, or paratubal areas. In the reproductive age female, benign cysts usually include pelvic inflammatory disease, ectopic pregnancy, paratubal cysts, or Hydatid cysts of Morgagni. These cysts are remnants of the mesonephric or paramesonephric systems. They are usually less than 1 cm and simple. Physiologic cysts include corpus luteal cysts, follicular cysts, or theca lutein cysts.

The most common ovarian tumor in children and younger women is the mature cystic teratoma or dermoid cyst. These cysts contain the three embryologic germ cell layers: endoderm, mesoderm, and ectoderm. Consequently, they often contain hair, teeth, and sebaceous fluid within the cyst cavity. These cysts are notorious for causing ovarian torsion in children or during pregnancy. Caution should be exercised if rupture of this cyst occurs.

If ovarian cyst rupture occurs during laparoscopy, it is often helpful to place the patient in the reverse Trendelenburg position, to prevent the cyst contents from spreading throughout the pelvis. Using warm irrigation fluid, copiously irrigate the pelvic cavity to prevent the peritonitis that may result from the cyst contents.

In general, the suspicion for malignancy does increase in the postmenopausal patient. Not all adnexal masses in postmenopausal women are malignant, however. The rate of asymptomatic simple ovarian cysts in postmenopausal women ranges from 3.3% to 6.6% (15,16). In 116 women who had pelvic ultrasound screening by Conway et al., ovarian cysts resolved spontaneously in 27 women (23%) and persisted in 69 (59%); 20 women (17%) were lost to follow-up. These women were reevaluated every three to six months for five years. Eighteen had surgery, two-thirds undergoing laparoscopic unilateral or bilateral salpingo-oophorectomy (15).

Pelvic ultrasound is the single most important clinical test in predicting if an adnexal mass is benign or malignant. Typical benign characteristics include a thin cyst wall, with no internal projections/papillary excrescences, thin septa, or low echogenicity. Conway et al. reported that cysts removed from the 18 women noted above were benign cystic adenomas. These findings are consistent with a similar study by Hall and McCarthy (17) supporting that benign cystadenomas appear to be the most common histological finding in persistent simple postmenopausal cysts.

When the surgeon encounters a benign adnexal mass, one may proceed with ovarian cystectomy or oophorectomy if clinically indicated and the patient has given consent. Aspiration of ovarian cysts should not be performed to aid in a diagnosis. In 1994, a meta-analysis showed that aspiration of ovarian cysts had a negative predictive value of 58% to 98% in the diagnosis of malignancy (18). Aspiration does not prevent ovarian cysts from recurrence. When doubt arises as to malignancy status, an intraoperative consult by a gynecologist or gynecologic oncologist is recommended.

If ovarian cyst rupture occurs during laparoscopy, it is often helpful to place the patient in the reverse Trendelenburg position, to prevent the cyst contents from spreading throughout the pelvis. Using warm irrigation fluid, copiously irrigate the pelvic cavity to prevent the peritonitis that may result from the cyst contents.

Benign epithelial neoplasms such as serous cystadenoma, mucinous cystadenoma, cystadenofibroma, Brenner tumor, and tumors of low malignant potential begin to increase in incidence as the patient ages. The overwhelming majority of malignant ovarian cancer is epithelial in origin. During 1997 to 2001, the U.S. National Cancer Institute reported the age-adjusted incidence of ovarian cancer for all races to be 13.9 cases per 100,000 (95% confidence interval, 13.7–14.2). Half of all cases occur in women over the age of 65 (19). The most important risk factor is having a first-degree relative with a history of the disease. Most patients with epithelial ovarian cancer present with advanced disease including a pelvic mass associated with ascites and an increased CA-125 level. In surgery, multiple small nodules with metastases on intraperitoneal organs are often seen. The most commonly involved extrapelvic organs include the bowel, liver, omentum, and diaphragm. If one suspects malignancy it is suggested to obtain a tissue sample for pathology and abort the procedure or consult with a gynecologic oncologist.

OVARIAN REMNANT

Ovarian remnant syndrome is a condition of continued pelvic pain, ovarian follicle formation, and premenopausal levels of pituitary hormones. It is a complication of oophorectomy, where pieces of ovarian cortex are left behind. This tissue is responsive to pituitary hormones and can retain the ability to produce estradiol (20). It is often suspected in a patient with continued pelvic pain and a persistent adnexal mass after a bilateral oophorectomy. An increased risk of ovarian remnant is associated with performing oophorectomy, when the ovaries are adherent to the pelvic sidewall, rectosigmoid, and/or the cul-de-sac. This may occur in cases of endometriosis, pelvic adhesions, or pelvic inflammatory disease (21). The risk may also increase with misapplication or improper use of pretied surgical loops, staplers, or bipolar electrodesiccation (22). This results in the remaining ovarian tissue being scarred along the pelvic sidewall frequently involving the peritoneum adjacent to the ureter. In 1962, Kaufmann, a urologist, made the discovery of ovarian remnants during the investigation of patients with ureteral obstruction (23). The dissection can be tedious, often requiring removal of the remaining ovarian tissue by first entering the retroperitoneal space at the pelvic brim to identify and isolate the infundibulopelvic ligament containing the ovarian vessels and adjacent ureter as it enters the pelvis (24,25).

CERVICAL CANCER

The World Health Organization reports cervical cancer as the second largest cause of female cancer mortality worldwide with 288,000 deaths yearly. Roughly 510,000 cases of cervical cancer are reported each year with approximately 80% of these from developing countries. Human papilloma virus is a cause of cervical cancer with prevalence of approximately 630 million infections in the world.

Invasive cervical cancer is a well-known cause of both ureteral obstruction and invasion into the bladder. Although cervical cancer is clinically staged, the presence of hydronephrosis on imaging due to tumor fulfills one of two criteria for the diagnosis of Stage IIIB cervical cancer in the International Federation of Gynecology and Obstetrics staging system. The proximity of the distal third of the ureter to the upper vagina and lower uterine cervix make this area susceptible to the direct invasive nature of advanced cervical cancer. The predominant route of spread is from the cervix into the vaginal mucosa, into the uterine myometrium, into the paracervical lymphatics, and then into the pelvic nodes. This is followed by extension into the adjacent structures, wall of the pelvis, bladder, or rectum with possible resulting vesicovaginal or rectovaginal fistula. Most patients will ultimately die from bilateral ureteral obstruction and subsequent sepsis.

Treatment of cervical cancer with radiation or surgery has a high incidence of urologic complications. In 2001, Fujikawa reported on 271 patients who were treated with external beam therapy and intracavitary brachytherapy for cervical cancer. Eight percent had urologic complications requiring surgical intervention, while 13% had complications of the rectum or intestine (26). Spontaneous rupture of the bladder has also been reported by the same group.

Radical hysterectomy is used for early stage treatment of cervical cancer. This involves resection of the parametrial tissues including the uterosacral ligaments, portions of the cardinal ligaments, and upper third of the vagina. Radical hysterectomy has

been associated with changes in bladder compliance and bladder capacity (27). This often results from direct injury to the sensory and motor nerve supply to the bladder. It is not uncommon for individuals to have voiding dysfunction for over a month after surgery often requiring intermittent self-catheterization or continuous bladder drainage.

ENDOMETRIOSIS

Endometriosis is the presence of functioning endometrial tissue outside of the endometrium and myometrium. The clinical syndrome involves cyclic pelvic pain that begins just before menses and lasts throughout the days of menstrual flow, noncyclic chronic pelvic pain, and dyspareunia. It is associated with inflammation, immune system abnormalities (28), and neoangiogenesis often causing infertility, scarring of the fallopian tubes, dysmenorrhea, dyschezia, and dyspareunia. The prevalence of pelvic endometriosis is estimated to be around 10% (29) of reproductive age women and prevalent in 2% of postmenopausal women (30). Sources of estrogen in the postmenopausal patient primarily arise from the cytochrome p450 enzyme aromatase. Aromatase is primarily expressed in ovarian granulosa cells, placental syncytiotrophoblast, adipose tissue, skin fibroblasts, and the brain (31). Cases of endometriosis have been reported in the gastrointestinal tract, urinary tract, pulmonary, musculoskeletal, peripheral, and central nervous system.

In advanced cases of endometriosis, the pelvic exam reveals irregular and tender nodularity in the posterior fornix of the vagina in the area of the insertion of the uterosacral ligaments on the poster-apical portion of the vagina. An adnexal mass may also be palpated. Pelvic ultrasound may reveal echogenic cystic structures present in the adnexa containing debris consistent with blood present within the cyst walls.

Endometriotic implants vary in size and appearance. They range from the classically described "powder burn" appearance to reddish-blue nodules and ovarian cysts. The repetitive process of hemolysis and encapsulation of debris causes extensive scarring of the affected surface. These surfaces usually include the ovary and posterior cul-de-sac with involvement of the distal uterosacral ligaments. Extensive involvement will include the rectum, tubes and ovaries, and the bladder. The overall positive predictive value for laparoscopic visualization of endometriosis is 43% to 45% (32,33). This is similar to appropriate history taking and physical exam. It is preferable to have a pathologic diagnosis if one suspects an implant may be endometriosis.

First line therapy of endometriosis usually involves hormonal management. Medications include Danazol, an isoxazol derivative of 17 α -ethinyl testosterone, and progestational agents such as medroxyprogesterone acetate, norethindrone, or norgestrel. Gonadotropin releasing hormone agonists are also used. These agents down-regulate the pituitary gland causing a decline in gonadotropin levels, resulting in a castrating effect. Medical therapy seems to be useful in treatment of mild to moderate disease.

Surgical resection is a commonly used treatment for moderate to severe cases of endometriosis or those cases of failed medical management. It is recommended for cases of cyst formation, invasion or obstruction to the bowel, ureters, or bladder. Most patients with endometriosis will not have involvement of the lower urinary tract. However, in cases of extensive endometriosis, the ureters are frequently involved. The scarring results in fibrosis of the surrounding periureteral tissue, often leading to obstruction. It is often necessary to enter the retroperitoneal space releasing the ureter laterally, away from the affected implants along the pelvic peritoneum. The goal is to remove all diseased tissue and restore pelvic anatomy (34). However, in advanced cases of endometriosis, intentional and nonintentional ureterotomy are relatively common.

Data regarding surgical treatment for endometriosis causing recurrent pelvic pain are mixed. In 1994, Sutton et al. reported on a randomized, double-blind study of endometriosis ablation plus uterosacral nerve ablation versus sham surgery (35). Three months after laparoscopy, 56% of the surgically treated women continued to experience pain relief, whereas 48% of the sham operation women also experienced pain relief. Thus, for at least three months there is a persistent placebo effect of surgery. After six months, 22% of the sham operation women experienced pain relief, whereas 62.5% of the surgically treated women experienced pain relief (35). This study illustrates that even in the best of hands and when studied in a controlled and prospective manner, laparoscopic surgery in which lesions are ablated results in a nearly 40% failure rate six months after surgery.

Ureter repair in patients with endometriosis is difficult because of the extensive fibrosis. To access the endometriosis around the ureter, extensive dissection is performed with potential compromise of the blood supply. Repair of the ureter in these situations could lead to stenosis at the repair site. Experimental studies in the porcine model have shown that repair of the ureter after extensive dissection that is typical of endometriosis surgery has a higher rate of stenosis.

The most common form of vesicovaginal fistula in North America is injury to the bladder during hysterectomy.

Laparoscopic hysterectomy is the most common surgery associated with lower urinary tract injury.

Injury to the urethra is unusual during laparoscopic gynecologic surgery.

Cystotomy is the most common urinary tract injury.

Ureter repair in patients with endometriosis is difficult because of the extensive fibrosis. To access the endometriosis around the ureter, extensive dissection is performed with potential compromise of the blood supply. Repair of the ureter in these situations could lead to stenosis at the repair site. Experimental studies in the porcine model have shown that repair of the ureter after extensive dissection that is typical of endometriosis surgery has a higher rate of stenosis (36).

FISTULA

The most common form of vesicovaginal fistula in North America is injury to the bladder during hysterectomy.

In developing countries, the main cause is childbirth. Invasive cervical cancer or radiation therapy for this disease is also a contributor to the formation of vesicovaginal fistulas. Most fistulas resulting from hysterectomy occur during removal of the uterine cervix. The vaginal portion is usually located at the area where the vaginal cuff was sutured together, identified by the linear vaginal scar.

URINARY TRACT INJURY DURING GYNECOLOGIC PROCEDURES

Most urologic injuries that occur during gynecologic procedures are to the lower urinary tract. Laparoscopic hysterectomy is the most common surgery associated with lower urinary tract injury.

A large review in Finland found rates of urinary tract injury in laparoscopic hysterectomy of 22.8/1000. Urinary tract injury rates for trans abdominal hysterectomy and trans vaginal hysterectomy were 1.7/1000 and 0.4/1000, respectively (37). Unfortunately, the incidence of injury to the lower urinary tract has increased with the advent of new laparoscopic techniques (38). Hopefully, this number will decrease as surgeons gain more experience with advanced laparoscopic surgery.

The complexity of the laparoscopic procedure also increases the risk of injury to the lower urinary tract. The incidence of injury to the lower urinary tract after diagnostic laparoscopy is relatively low, less than 0.6/1000, whereas the risk of injury during operative laparoscopy was 3.0/1000. The majority of these injuries occurred during laparoscopic hysterectomy (39).

INJURY TO THE URETHRA

Injury can occur during suburethral sling procedures, often done in conjunction with laparoscopic hysterectomies and surgeries for pelvic organ prolapse. Typically, these injuries are managed either with prolonged catheter drainage or with surgical reanastomosis. Injury to the urethra is unusual during laparoscopic gynecologic surgery.

INJURY TO THE BLADDER

Cystotomy is the most common urinary tract injury (Table 2).

Dissection of the bladder off the lower uterine segment, cervix, and upper vagina is necessary for a total hysterectomy. Less dissection is needed for a supracervical hysterectomy and not surprisingly results in a lower rate of cystotomy (37). Cystotomy is also a common injury during the dissection for laparoscopic retropubic colposuspension (40).

When bladder injuries are not recognized intraoperatively they often lead to significant morbidity, including postoperative urinomas, bowel obstructions, infections, and fistula (41). Observation of gas in the Foley bag or bubbles at the time of cystoscopy is a common intraoperative sign of bladder injury during laparoscopy.

When an intraoperative injury is suspected, consultation with urologist and evaluation of the lower urinary tract are recommended. Typically this involves intravenous injection of Indigo carmine (5 cc) and cystoscopy. The bladder and both ureters should be evaluated in all cases.

Energy sources such as monopolar and bipolar electrocautery, CO₂ laser, and the ultrasonic scalpel can all be associated with injuries to the bladder or ureter. These energy sources were evaluated in an animal model to determine the accuracy of clinical

Small injuries to the dome of the bladder can often be managed with prolonged bladder drainage. When surgical repair is required, this can often be accomplished with laparoscopic suture techniques. If injury occurs at the time of hysterectomy, transvaginal repair is also an option.

assessment of the injuries and the extent of lateral spread. Laparoscopic assessment is as accurate as gross assessment of the injured tissue (42). Monopolar cautery has the greatest risk of lateral spread (43).

Small injuries to the dome of the bladder can often be managed with prolonged bladder drainage. When surgical repair is required, this can often be accomplished with laparoscopic suture techniques. If injury occurs at the time of hysterectomy, transvaginal repair is also an option.

The route chosen for repair should reflect the surgeon's ability and experience. A closed pelvic drain should be considered if the repair is not watertight.

INJURIES TO THE URETER

Older studies document ureteral injury rates of as high as 30% during major pelvic surgery (44). More recent studies, however, report ureteral injury rates of less than 2% (Table 1). Many ureteric injuries may be asymptomatic, ultimately resulting in loss of renal function (44). Current guidelines recommend identification and tracing the course of the ureter during all gynecologic surgeries (45).

Intraoperative consultation for a ureteric injury should involve assessment of both ureters and the bladder for potential injury.

Injury to the ureter—clinical scenarios and management:

- If there is concern regarding a possible ureteric injury but none can be visualized laparoscopically, evaluation with cystoscopy with confirmation of ureteral patency is adequate.
- If during this evaluation patency of a ureter cannot be confirmed, a ureteral stent should be placed.
- If the pelvic ureter is obstructed, it should be repaired. However, prior to pursuing surgical repair of the ureter, the patient medical record should be reviewed for possible causes of prior urinary tract injury.
- If there is any question regarding renal function or another upper urinary tract injury, an intraoperative urogram should be performed to confirm bilateral renal function.
- When the ureter has been obviously transected, laparoscopic ureteroureterostomy or reimplantation is an option (46,47).

Typically, injuries near the bladder are reimplanted, and injuries higher in the pelvis are reanastomosed. Laparoscopic reanastomosis has been documented in a number of gynecologic procedures. A retrograde ureteral stent is placed, and four interrupted sutures are placed circumferentially around the ureter. We have found it helpful to place a single interrupted suture to align the ends of the ureter to facilitate stent placement (47). When a tension-free ureteroureterostomy is not possible, reimplantation in the bladder should be considered. This is often done with a bladder flap. Fibrin glue and laser welding have been used successfully to repair ureterotomy in an animal model (48).

Another clinical scenario that occurs is injury to the ureter with an energy source but no ureterostomy. In this setting, bilateral ureteral patency should be confirmed. Passage of a ureteral stent in these cases has been reported with both successful and unsuccessful outcomes (49,50). Consideration should be given to surgical repair in these settings.

MANIPULATORS

By and large, one of the most difficult aspects of any laparoscopic surgeon when dealing with the female pelvis is uterine manipulation.

By and large, one of the most difficult aspects of any laparoscopic surgeon when dealing with the female pelvis is uterine manipulation.

The level of difficulty has been raised in many laparoscopic cases predominately due to inappropriate manipulation. This not only interferes with the procedure at hand but also limits the surgeon's inspection for other pathologies in the pelvis. A lubricated sponge stick can be placed into the posterior fornix of the vagina. There are several problems with this approach. It does not allow for the uterine fundus to be manipulated either out of the pelvis or into the pelvis away from the bladder.

Several uterine manipulators have been specifically designed just for these purposes. They are useful in procedures where the assistant holding traction may stand between the patient's legs allowing the surgeon to use both hands for the procedure. The Hulka tenaculum is a commonly used device for uterine manipulation. During the pelvic examination under anesthesia, the position (e.g., anteversion or retroversion) of the uterus is assessed. A single tooth tenaculum is used to grasp the anterior lip of the cervix. Gentle traction is pulled toward the examiner to straighten out the angle often present between the cervical canal and the anteverted or retroverted uterine fundus. The Hulka is then placed with the

curve of the tenaculum pointing in the direction of the uterine fundus. If the uterus is retroverted, flipping the tenaculum into the ante-verted position is performed once placed into the uterine cavity. When the uterus is placed in the anteverted position, the tooth is clamped on the anterior lip of the cervix, and the single tooth tenaculum is removed.

The Rumi manipulator is another useful device. This is placed in a similar fashion to the Hulka. Once placed, it may be locked into either an anteverted or retroverted position. Several other benefits of this device include the ability to inject dye into the uterus to assess tubal patency and the ability to accommodate the Koh device (51). This Koh device is useful during laparoscopic hysterectomy. The system consists of a pneumo-occluder and a cup, combined with a uterine manipulator usually the Rumi manipulator. The cup, which is both visible and palpable, is placed over the cervix to delineate vaginal fornices, thus ensuring safe desiccation and avoiding ureteral dissection during colpotomy (51).

SUMMARY

- Laparoscopic hysterectomy is the most common surgery associated with lower urinary tract injury.
- Cystotomy is the most common urinary tract injury. Small injuries to the dome of the bladder can often be managed with prolonged bladder drainage. When surgical repair is required, this can often be accomplished with laparoscopic suture techniques. If injury occurs at the time of hysterectomy, transvaginal repair is also an option.
- If there is concern regarding a possible ureteric injury but none can be visualized laparoscopically, ureteral patency should be confirmed. Otherwise, a ureteral stent should be placed. An obstructed pelvic ureter should be repaired.
- If there is any question regarding renal function or another upper urinary tract injury, an intraoperative urogram should be performed to confirm bilateral renal function.
- When the ureter has been obviously transected, laparoscopic ureteroureterostomy or reimplantation is an option.
- Injury to the urethra is unusual during laparoscopic gynecologic surgery. However, injury can occur during suburethral sling procedures, often done in conjunction with laparoscopic hysterectomies and surgeries for pelvic organ prolapse. Typically these injuries are managed either with prolonged catheter drainage or with surgical reanastomosis.
- If ovarian cyst rupture occurs during laparoscopy, it is often helpful to place the patient in the reverse Trendelenburg position to prevent the cyst contents from spreading throughout the pelvis. Using warm irrigation fluid, copiously irrigate the pelvic cavity to prevent the peritonitis that may result from the cyst contents.

REFERENCES

1. Lachman E, Schienfeld A, Voss E, et al. Pregnancy and laparoscopic surgery. *J Am Assoc Gynecol Laparosc* 1999; 6:347–351.
2. Barnard JM, Chaffin D, Droste S, Tierney A, Phernetton T. Fetal response to carbon dioxide pneumoperitoneum in the pregnant ewe. *Obstet Gynecol* 1995; 85:669–674.
3. Marshall LM, Spiegelman D, Barbieri RL, et al. Variation in the incidence of uterine leiomyoma among premenopausal women by age and race. *Obstet Gynecol* 1997; 90:967–973.
4. Quality AHRa. Nationwide Inpatient Sample (NIS) (electronic database, release 6), 1997.
5. Lefebvre G, Vilos G, Allaire C, et al. The management of uterine leiomyomas. *J Obstet Gynaecol Canada* 2003; 25:396–418; quiz 419–422.
6. Myers ER, Barber MD, Gustilo-Ashby T, Couchman G, Matchar DB, McCrory DC. Management of uterine leiomyomata: what do we really know? *Obstet Gynecol* 2002; 100:8–17.
7. Gilmour DT, Dwyer PL, Carey MP. Lower urinary tract injury during gynecologic surgery and its detection by intraoperative cystoscopy. *Obstet Gynecol* 1999; 94(5 Pt 2):883–889.
8. Garry R, Fountain J, Mason S, et al. The eVALuate study: two parallel randomised trials, one comparing laparoscopic with abdominal hysterectomy, the other comparing laparoscopic with vaginal hysterectomy [see comment] [erratum appears in *BMJ* 2004; 328(7438):494].
9. diZerega GS. The peritoneum and its response to surgical injury. *Prog Clin Biol Res* 1990; 358:1–11.
10. Swank DJ, Swank-Bordewijk SC, Hop WC, et al. Laparoscopic adhesiolysis in patients with chronic abdominal pain: a blinded randomised controlled multi-centre trial [see comment]. *Lancet* 2003; 361:1247–1251. [erratum appears in *Lancet* 2003; 361(9376):2250].
11. Rein DB, Kassler WJ, Irwin KL, Rabiee L. Direct medical cost of pelvic inflammatory disease and its sequelae: decreasing, but still substantial. *Obstet Gynecol* 2000; 95:397–402.
12. Jacobson L, Westrom L. Objectivized diagnosis of acute pelvic inflammatory disease. Diagnostic and prognostic value of routine laparoscopy. *Am J Obstet Gynecol* 1969; 105:1088–1098.
13. Ness RB, Soper DE, Holley RL, et al. Effectiveness of inpatient and outpatient treatment strategies for women with pelvic inflammatory disease: results from the Pelvic Inflammatory Disease Evaluation and Clinical Health (PEACH) Randomized Trial [see comment]. *Am J Obstet Gynecol* 2002; 186:929–937.

14. Conde Santos G, Bielsa Gali O, Arango Toro O, Alonso Gracia N, Gelabert Mas A. Extrinsic ureteral obstruction secondary to inflammatory gynecologic pathology. *Arch Espanol Urol* 2003; 56(2):181–185.
15. Conway C, Zalud I, Dilena M, et al. Simple cyst in the postmenopausal patient: detection and management. *J Ultrasound Med* 1998; 17:369–372; quiz 373–374.
16. Bailey CL, Ueland FR, Land GL, et al. The malignant potential of small cystic ovarian tumors in women over 50 years of age [see comment]. *Gynecol Oncol* 1998; 69:3–7.
17. Hall DA, McCarthy KA. The significance of the postmenopausal simple adnexal cyst. *J Ultrasound Med* 1986; 5:503–505.
18. Nicklin J, van Eijkeren M, Athanasatos P. A comparison of ovarian cyst aspirate cytology and histology. The case against aspiration of cystic pelvic masses. *Aust NZ J Obstet Gynaecol* 1994; 34:546–549.
19. Yancik R. Ovarian cancer. Age contrasts in incidence, histology, disease stage at diagnosis, and mortality. *Cancer* 1993; 71:517–523.
20. Scott RT, Beatse SN, Illions EH, Snyder RR. Use of the GnRH agonist stimulation test in the diagnosis of ovarian remnant syndrome. A report of three cases. *J Reprod Med* 1995; 40:143–146.
21. Steege JF. Ovarian remnant syndrome. *Obstet Gynecol* 1987; 70:64–67.
22. Nezhat CH, Seidman DS, Nezhat FR, Mirmalek SA, Nezhat CR. Ovarian remnant syndrome after laparoscopic oophorectomy. *Fertil Steril* 2000; 74:1024–1028.
23. Kaufman JJ. Unusual causes of extrinsic ureteral obstruction. I. *J Urol* 1962; 87:319–327.
24. Berek JS, Darney PD, Lopkin C, Goldstein DP. Avoiding ureteral damage in pelvic surgery for ovarian remnant syndrome. *Am J Obstet Gynecol* 1979; 133:221–222.
25. Price FV, Edwards R, Buchsbaum HJ. Ovarian remnant syndrome: difficulties in diagnosis and management. *Obstet Gynecol Surv* 1990; 45:151–156.
26. Fujikawa K, Miyamoto T, Ihara Y, Matsui Y, Takeuchi H. High incidence of severe urologic complications following radiotherapy for cervical cancer in Japanese women. *Gynecol Oncol* 2001; 80:21–23.
27. Sartori E, Zanagnolo V. Complications following radical hysterectomy for cervical carcinoma. *Recenti Prog Med* 2003; 94:562–567.
28. Gleicher N, el-Roeiy A, Confino E, Friberg J. Is endometriosis an autoimmune disease? *Obstet Gynecol* 1987; 70:115–122.
29. Olive DL, Schwartz LB. Endometriosis. *N Engl J Med* 1993; 328:1759–1769.
30. Magtibay PM, Heppell J, Leslie KO. Endometriosis-associated invasive adenocarcinoma involving the rectum in a postmenopausal female: report of a case. *Dis Colon Rectum* 2001; 44:1530–1533.
31. Vignali M, Infantino M, Matrone R, et al. Endometriosis: novel etiopathogenetic concepts and clinical perspectives. *Fertil Steril* 2002; 78:665–678.
32. Walter AJ, Hentz JG, Magtibay PM, Cornella JL, Magrina JF. Endometriosis: correlation between histologic and visual findings at laparoscopy. *Am J Obstet Gynecol* 2001; 184:1407–1411; discussion 1411–1413.
33. Stratton P, Winkel CA, Sinaii N, Merino MJ, Zimmer C, Nieman LK. Location, color, size, depth, and volume may predict endometriosis in lesions resected at surgery. *Fertil Steril* 2002; 78:743–749.
34. Wheeler JM, Malinak LR. Recurrent endometriosis: incidence, management, and prognosis. *Am J Obstet Gynecol* 1983; 146:247–253.
35. Sutton CJ, Ewen SP, Whitelaw N, Haines P. Prospective, randomized, double-blind, controlled trial of laser laparoscopy in the treatment of pelvic pain associated with minimal, mild, and moderate endometriosis. *Fertil Steril* 1994; 62:696–700.
36. Winkel CA. Evaluation and management of women with endometriosis. *Obstet Gynecol* 2003; 102:397–408.
37. Harkki-Siren P, Sjoberg J, Tiitinen A. Urinary tract injuries after hysterectomy. *Obstet Gynecol* 1998; 92:113–118.
38. Assimos DG, Patterson LC, Taylor CL. Changing incidence and etiology of iatrogenic ureteral injuries. *J Urol* 1994; 152:2240–2246.
39. Harkki-Siren P, Kurki T. A nationwide analysis of laparoscopic complications. *Obstet Gynecol* 1997; 89:108–112.
40. Tulikangas PK, Weber AM, Larive AB, Walters MD. Intraoperative cystoscopy in conjunction with anti-incontinence surgery. *Obstet Gynecol* 2000; 95:794–796.
41. Saidi MH, Sadler RK, Vancaillie TG, Akright BD, Farhart SA, White AJ. Diagnosis and management of serious urinary complications after major operative laparoscopy. *Obstet Gynecol* 1996; 87:272–276.
42. Tulikangas PK, Beesley S, Boparai N, Falcone T. Assessment of laparoscopic injuries by three methods. *Fertil Steril* 2001; 76:817–819.
43. Tulikangas PK, Smith T, Falcone T, Boparai N, Walters MD. Gross and histologic characteristics of laparoscopic injuries with four different energy sources [see comment]. *Fertil Steril* 2001; 75:806–810.
44. St. Martin EC, Trichel BE, Campbell JH, Locke CM. Ureteral injuries in gynecologic surgery. *J Urol* 1953; 70:51–57.
45. Guideline SP. Ureteral injuries in gynecologic surgery. *J Soc Obstet Gynaecol Can* 1999; 199:1338–1340.
46. Anderson KR, Clayman RV. Laparoscopic lower urinary tract reconstruction. *World J Urol* 2000; 18:349–354.
47. Tulikangas PK, Gill IS, Falcone T. Laparoscopic repair of ureteral injuries. *J Am Assoc Gynecol Laparosc* 2001; 8:259–262.
48. Wolf JS Jr., Soble JJ, Nakada SY, et al. Comparison of fibrin glue, laser weld, and mechanical suturing device for the laparoscopic closure of ureterotomy in a porcine model. *J Urol* 1997; 157:1487–1492.
49. Grainger DA, Soderstrom RM, Schiff SE, Glickman MG, DeCherney AH, Diamond MP. Ureteral injuries at laparoscopy: insights into diagnosis, management, and prevention [see comment]. *Obstet Gynecol* 1990; 75:839–843.
50. Winslow PH, Kreger R, Ebbesson B, Oster E. Conservative management of electrical burn injury of ureter secondary to laparoscopy. *Urology* 1986; 27:60–62.
51. Koh CH. A new technique and system for simplifying total laparoscopic hysterectomy. *J Am Assoc Gynecol Laparosc* 1998; 5:187–192.

LAPAROSCOPY: SELECT ASPECTS

Prokar Dasgupta and Ben Challacombe

Laparoscopic Urology and Robotics, Guy's Hospital and Guy's King's and Thomas's School of Medicine, London, U.K.

- INTRODUCTION
- BASIC PRINCIPLES OF IMMUNOLOGY
- LAPAROSCOPY AND SYSTEMIC IMMUNITY
 - Effects on Acute-Phase Response and Cytokines
 - Effect on Polymorphonuclear Lymphocytes
 - Effect on Delayed-Type Hypersensitivity and T Lymphocytes
 - Effect on Monocyte-Macrophage Function
- LAPAROSCOPY AND INTRAPERITONEAL IMMUNE FUNCTION
- TUMOR GROWTH, METASTASIS, AND IMMUNE FUNCTION
- LAPAROSCOPIC BOWEL INJURY
- IMMUNOLOGIC ASPECTS OF LAPAROSCOPIC UROLOGY
- FUTURE DIRECTIONS
- SUMMARY
- REFERENCES

INTRODUCTION

Since the first laparoscopic procedures involving diagnostic laparoscopy for gynecological pathology, surgeons have observed less postoperative pain, shorter recovery times, and better cosmesis with laparoscopy compared to conventional open surgery.

Open surgery is associated with a period of immunosuppression in the immediate postoperative period (1). Due to its minimally invasive nature, laparoscopic surgery is believed to lessen surgical trauma and so causes less disturbance of immune function. This may contribute to the rapid recovery noted after many laparoscopic operations. As a result, laparoscopic surgery has been investigated for a potential reduction in stress and immune responses.

A large number of animal—mainly rodent—and human studies have investigated the immune response to laparoscopic surgery by the measurement of a number of recognized immunological markers. As preservation of both systemic and intraperitoneal immunity is important in surgery in general and particularly in oncological procedures, an understanding of the impact of laparoscopy on immune function is highly relevant. A number of prospective and a few randomized controlled trials comparing laparoscopy to open surgery have been reported.

The immunologic benefits of laparoscopic surgery are most obvious in relatively atraumatic procedures such as cholecystectomy and antireflux surgery. For more complex procedures such as resection of colorectal cancer the benefits are less obvious and the evidence controversial.

Although laparoscopy for colorectal cancer may be associated with higher survival and lower recurrence rates (2), it has been related to high incidence of port site metastasis. This is comparable to the incidence of wound metastasis observed after open surgery (2). Long-term results from randomized trials are eagerly awaited.

As laparoscopy becomes established in the field of urology, the study of immunological dysfunction after procedures such as laparoscopic nephrectomy will become more important. At this time, data from randomized trials are sorely lacking. Perhaps, the laparoscopic equivalent of colorectal surgery is laparoscopic radical cystectomy for bladder cancer. Despite being a challenging technique with potential complications, laparoscopic radical cystectomy has a number of advantages compared to open radical cystectomy. Fluid loss from the bowel during surgery is lesser than open radical cystectomy and there is some evidence that in general the patient's immune system is better preserved with laparoscopy. In our experience of laparoscopic radical cystectomy with laparoscopic-assisted ileal conduit postoperative morbidity, blood

The immunologic benefits of laparoscopic surgery are most obvious in relatively atraumatic procedures such as cholecystectomy and antireflux surgery. For more complex procedures such as resection of colorectal cancer the benefits are less obvious and the evidence controversial.

transfusion and the use of high dependency/intensive care unit was lesser than that of a comparable contemporary group of patients undergoing open radical cystectomy. Postoperative ileus was shorter and patients were able to start enteral feeding much earlier. Mean hospital stay was short and full recovery very rapid. Early data also indicate that laparoscopic radical cystectomy is oncologically equivalent to open radical cystectomy. Surgical margins are usually negative and at follow-up of up to two years 3% of patients develop metastatic disease (3). Laparoscopic radical cystectomy would be an ideal procedure to study the immunological effects of urological laparoscopy as the difference in technique and recovery, compared to open radical cystectomy, are quite marked.

It is a sobering thought that surgical problems related to acquired immuno deficiency syndrome are becoming more common as the incidence of human immuno virus seropositivity increases. Patients with acquired immuno deficiency syndrome are living longer due to improved medical therapy. Laparoscopy is being applied more frequently for diagnostic and therapeutic purposes and these immunocompromised patients may benefit from decreased perioperative immune depression (4).

BASIC PRINCIPLES OF IMMUNOLOGY

We are all exposed to a large variety of infectious agents that would cause pathological damage if left unchecked. In majority of normal individuals, these infections are of limited duration and leave little damage because of the human defense mechanisms in the form of the immune system.

The human immune system has two major functional divisions—the innate and adaptive systems. Both act in concert, with innate immunity forming the first line of defense. Breaching of innate defenses leads to activation of the adaptive system. The two key features of the adaptive system are specificity and memory.

The function of the adaptive immune system is to recognize an antigen and mount an immune response to eliminate it. Generally speaking, there are two major types of immune responses—those against intracellular pathogens and those against extracellular microorganisms. The intracellular antigens, presented at the surface of the cells of the body are recognized by T lymphocytes and this was previously termed cell-mediated immunity. The extracellular antigens are recognized by antibodies produced by B lymphocytes, a process previously termed humoral immunity.

Another important distinction between the two arms of the immune system is that antibodies generally recognize intact antigens while T cells recognize antigen fragments presented to them with molecules encoded by the major histocompatibility complex. The human major histocompatibility complex is known as the human leucocyte antigen locus and is located on chromosome 6. There are four main blocks of genes on this locus—I, II, III, and IV.

There are two major types of T cell. CD8+ cells or cytotoxic T cells (Tc) recognize antigen fragments associated with major histocompatibility complex class I molecules while the CD4+ or helper T cells (Th) recognize antigen associated with major histocompatibility complex class II molecules presented on cells known as antigen presenting cells (Fig. 1). CD4+ Th cells are classified into Th1 and Th2 cells. Th1 cells increase cellular immunity while Th2 cells induce specific antibody production from B cells. If the antigen presenting cells are macrophages, the CD4+ cells release a variety of cytokines, which activate the macrophages to destroy the antigen. On the other hand, if the antigen presenting cell are B cells, the CD4+ cells help them to make antibodies (5). The term CD stands for “clusters of differentiation,” a nomenclature initially proposed in Paris in 1982 and subsequently updated at a workshop in Boston in 1993. There are around 151 CD clusters and subclusters but these are continually evolving particularly as a result of the human genome project. The complete sequence of the human genome now allows for medical researchers to consider studying the human as a “system,” and information gained from comparing normal and aberrant processes in other species can be applied to the comprehensive study of human disease mechanisms. These concepts provide great opportunities for di-oxy ribose nucleic acid or genetic-based diagnostic and therapeutic applications (6). An example of a long contiguous stretch of human sequence analyzed so far is the T-cell

FIGURE 1 ■ Interactions of Tc and Th lymphocytes. Abbreviations: MHC, major histocompatibility complex; Tc, T cytotoxic cells, TR, Thelper cells. Source: From Ref. 5.

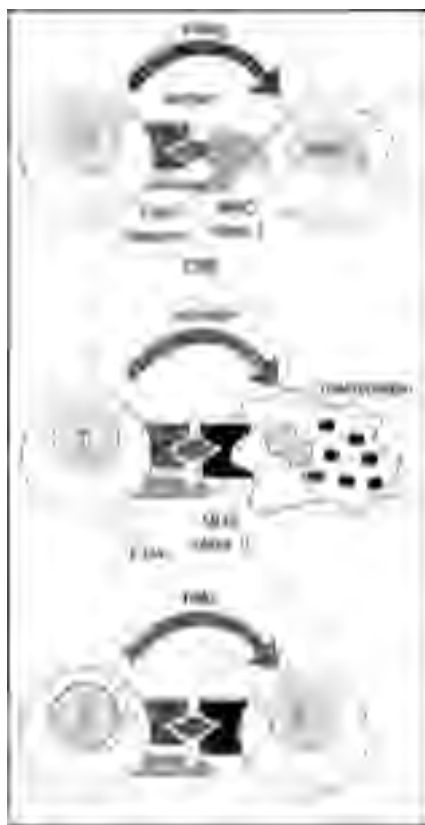


FIGURE 2 ■ Professor Elie Metchnikoff—Nobel Laureate who described phagocytosis as an immune defense mechanism.

receptor (7). There are 45 functional antigen recognition genes in the human beta T-cell receptor and it is possible to create arrays that interrogate the expression patterns of each of these genes during T-cell development. The expression of these genes can be studied to determine which kinds of T cells are triggered in response to surgical injury.

In addition, polymorphonuclear leukocytes or neutrophils and macrophages primarily phagocytose antigens for intracellular destruction in their lysosomes. The word phagocytosis or the ability to engulf microorganisms was coined by the Russian Nobel laureate, Elie Metchnikoff in 1883 (Fig. 2). Metchnikoff thought polymorphonuclears to be “microphages” as opposed to the larger “macrophages.” We owe our understanding of this arm of the immune system to Metchnikoff’s vision.

The overall immune response to surgical trauma is summarized in Figure 3.

LAPAROSCOPY AND SYSTEMIC IMMUNITY

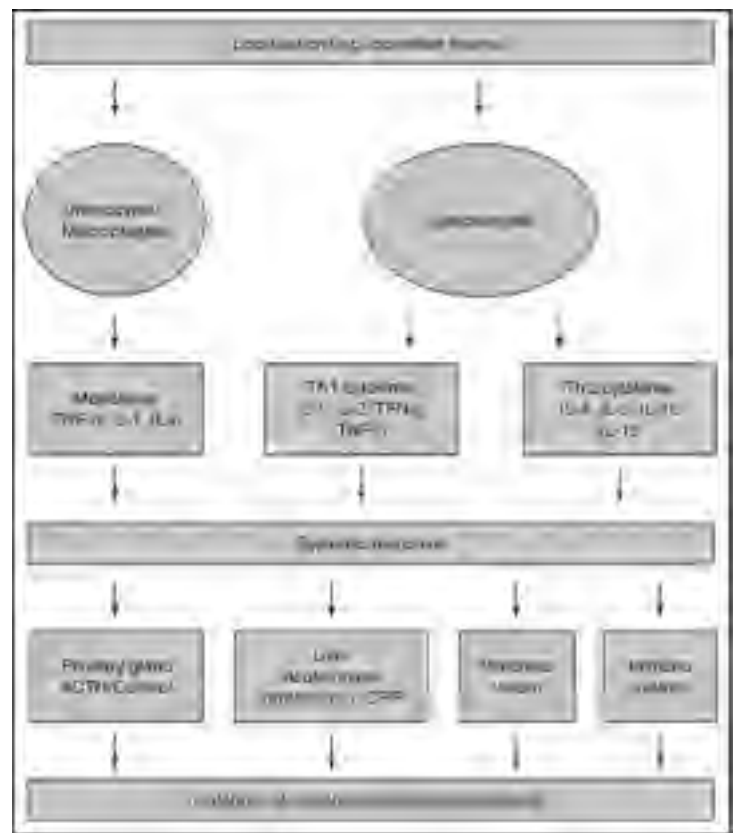
Laparoscopic surgery causes less tissue trauma than open surgery and is likely to be associated with better preservation of systemic immune function and contribute to quicker recovery (1,8,9).

In general, immunological function is depressed after open surgery, with adverse alterations in cytokine levels and changes in the function of cellular components of the systemic immune response (10–12). On the contrary, the body’s response to laparoscopy is one of lesser immune activation as opposed to immunosuppression (13).

The usual physiological reaction to injury is an early rise in serum stress hormone levels along with a decrease in cellular immune response. These manifest as a reduction in lymphocyte and macrophage interaction, decreased activity of natural killer

Laparoscopic surgery causes less tissue trauma than open surgery and is likely to be associated with better preservation of systemic immune function and contribute to quicker recovery.

FIGURE 3 ■ Immune responses to surgical trauma. Abbreviations: TNF, tumor necrosis factor; IL, interleukin; CRP, C reactive protein. Source: From Ref. 86.



cells, decreased lymphocyte and neutrophil chemotaxis, and a reduction in delayed-type hypersensitivity (14).

Effects on Acute-Phase Response and Cytokines

The acute-phase response and cytokines are important components of immunological function. Decreased production of cytokines reflecting a reduced inflammatory reaction after laparoscopy might be considered beneficial during the postoperative period.

C-reactive protein is the most widely studied acute-phase response protein following surgery. C-reactive protein levels usually rise 4 to 12 hours after surgery, peak at 24 to 72 hours and thereafter remain raised for about two weeks (12). Other acute-phase response proteins, such as fibrinogen and transferrin do not usually alter in a similar way in response to surgical trauma (15,16).

Postoperative C-reactive protein levels are significantly lower during the first two days after laparoscopic than after open surgery (17–19).

In a prospective randomized study of laparoscopic versus small-incision open cholecystectomy, Squirrell et al. (20) demonstrated significantly lower C-reactive protein levels following laparoscopic cholecystectomy. However, they found no differences in serum cortisol levels between the two groups and concluded that the neuro-endocrine component of the metabolic response, i.e., cortisol, was not influenced by the type of surgical access (20). These findings were contradicted by McMahon et al. (16), who found no differences in the levels of C-reactive protein or other acute-phase response proteins such as albumin and transferrin between laparoscopic and minilaparotomy cholecystectomy. Because open cholecystectomy in this study was performed through a much smaller incision than would normally be used for open surgical procedures, these results indicate that the trauma of abdominal access influences immunological function. Other studies of laparoscopic versus small-incision cholecystectomy also support this hypothesis (15).

The cytokines interleukin-1 (IL-1), tumor necrosis factor, and IL-6 are important molecules in acute-phase response (21,22). IL-1 and tumor necrosis factor receptors are believed to regulate cytokine activity and their serum levels indirectly reflect serum cytokine levels.

Postoperative C-reactive protein levels are significantly lower during the first two days after laparoscopic than after open surgery.

While no difference in soluble tumor necrosis factor receptor levels has been noted after laparoscopic and conventional surgery, serum IL-1 receptor levels are significantly lower after laparoscopy, indicating a lesser degree of inflammatory response to injury.

While no difference in soluble tumor necrosis factor receptor levels has been noted after laparoscopic and conventional surgery, serum IL-1 receptor levels are significantly lower after laparoscopy, indicating a lesser degree of inflammatory response to injury (23).

IL-6 expression is believed to be directly proportional to the extent of surgical trauma (24) and a significant difference has been found in plasma levels after open and laparoscopic cholecystectomy (17–19,25). In a randomized controlled trial of laparoscopic versus conventional colorectal resection, Schwenk et al. (26) demonstrated a postoperative increase in IL-6 in both groups, with a more marked response after open surgery. Leung et al. (27) randomized patients to either laparoscopically assisted or open resection of rectosigmoid carcinoma and found no increase in tumor necrosis factor- α levels in either group. Serum levels of both IL-1 β and IL-6 peaked two hours after operation, with a significantly smaller response after laparoscopic surgery. Others have found no consistency in IL-6 levels following different surgical approaches (28). Johnson et al. (29) demonstrated significantly higher serum IL-6 levels after laparoscopically assisted colectomy in dogs, compared with the conventional open approach, and Stage et al. (30) reported similar results in a prospective randomized clinical trial.

Hill et al. (31) failed to find any differences in the postoperative IL-6 level following laparoscopic and conventional inguinal hernia repair, which could be because the surgical insult caused by open hernia repair is not sufficient to generate increased levels of these markers. In a similar study, no difference in plasma cortisol, growth hormone, prolactin, and serum IL-6 levels was found following laparoscopic and open surgery for inguinal hernia, but a rise in C-reactive protein concentration and suppression of endotoxin-induced tumor necrosis factor- α production was recorded in both groups with greater changes after open hernia repair (32).

Kuntz et al. compared laparoscopically assisted and open colonic resection in a rat model and measured the serum levels of cortisone, neopterin, and IL-1 β just before, during, and after operation, and on the first and seventh postoperative days. They detected significant differences between the study groups for all three variables on the first postoperative day. After a week the levels of cortisone and neopterin had returned to normal (33).

Comparing laparoscopically assisted surgery for Crohn's disease with open surgery, Kishi et al. (34) found C-reactive protein levels and leukocyte counts to be lower following laparoscopic surgery. Hildebrandt et al. also compared open and laparoscopically assisted resection for Crohn's disease and found increased levels of C-reactive protein, IL-6, IL-10 but without any demonstrable difference between the two groups. However, they reported significantly lower plasma granulocyte elastase levels after laparoscopic surgery compared with the open operation (35). It needs to be kept in mind that inflammatory bowel conditions such as Crohn's disease and ulcerative colitis can themselves cause alterations in cytokine levels and any changes following surgery whether laparoscopic or open need to be interpreted with a degree of caution (1).

In summary, the outcomes of both animal and clinical studies clearly demonstrate lesser activation of cytokines IL-1, IL-6, and C-reactive protein following laparoscopic surgery compared with equivalent open procedures. However, differences in the activation of other cytokines such as tumor necrosis factor, IL-8, and changes in the levels of acute-phase response proteins like fibrinogen, albumin, and transferrin are less obvious.

The majority of the clinical studies have shown an immunological advantage of laparoscopic over open cholecystectomy. The same cannot be said for laparoscopic colectomy and inguinal hernia repair, where results supporting advantages of the laparoscopic approach have been inconsistent.

Effect on Polymorphonuclear Leukocytes

Surgical stress affects polymorphonuclear function in the postoperative period. The phagocytic and chemotactic activity of neutrophils is reduced after surgery (36). Several studies have demonstrated a significant increase in overall peripheral leukocyte numbers following open, but not laparoscopic, procedures (19,37). Sietses et al. did not observe any difference in polymorphonuclear count between patients undergoing laparoscopic and open Nissen fundoplication. However, they found a significant reduction in the phagocytic activity of polymorphonuclears after open surgery, which was not noted following laparoscopic fundoplication (38). They also found significantly greater surface expression of CD11b, a receptor important in polymorphonuclear migration, in patients undergoing open surgery compared with those having laparoscopy (38).

In summary, the outcomes of both animal and clinical studies clearly demonstrate lesser activation of cytokines IL-1, IL-6, and C-reactive protein following laparoscopic surgery compared with equivalent open procedures. However, differences in the activation of other cytokines such as tumor necrosis factor, IL-8, and changes in the levels of acute-phase response proteins like fibrinogen, albumin, and transferrin are less obvious.

Differences in stimulated free oxygen radical production have also been noted between open and laparoscopic techniques (38), suggesting a higher state of polymorphonuclear activation after open procedures. Likewise, the concentration of elastase, an indicator of polymorphonuclear activation, increases after both open and laparoscopic surgery, but returns to preoperative levels within three days after laparoscopic but not open surgery. The postoperative production of hypochloric acid, a potent neutrophil antimicrobial antioxidant, has been shown to fall significantly after open but not laparoscopic surgery (39).

Nies et al. (40) randomized patients with acute cholecystitis to undergo either laparoscopic or open cholecystectomy and found significantly greater intraoperative and postoperative histamine levels in patients after the former procedure. Histamine levels reached their highest levels during establishment of pneumoperitoneum and laparoscopic access.

Significantly less activation and preserved polymorphonuclear function correlate with the clinical observation of fewer postoperative septic complications following laparoscopic surgery.

Significantly less activation and preserved polymorphonuclear function correlate with the clinical observation of fewer postoperative septic complications following laparoscopic surgery. This suggests that a laparoscopic approach might be beneficial in the surgical management of intra-abdominal sepsis or peritonitis, although this remains a matter of debate as higher intra-abdominal pressure during laparoscopy may worsen clinical sepsis (1).

Effect on Delayed-Type Hypersensitivity and T Lymphocytes

Delayed-type hypersensitivity responses can indirectly reflect changes in T-lymphocyte populations in patients undergoing surgical procedures. Although it seems that delayed-type hypersensitivity is better preserved after laparoscopic than open surgery, it is still not clear which components of the cascade are responsible for this preservation of cellular immunological response (1,13).

Gutt et al. assessed cell-mediated immune function by measuring the size of skin pustules induced by intradermal injection of *Staphylococcus aureus* in rats undergoing laparoscopically assisted and open cecal resection. Animals having laparoscopic procedures had smaller and more rapidly healing pustules than their open surgical counterparts (41). Similarly, Allendorf et al. investigated cell-mediated immune function following laparoscopically assisted and open bowel resections in rats using delayed-type hypersensitivity responses to keyhole limpet hemocyanin and phytohemagglutinin antigens. The delayed-type hypersensitivity responses at two days to both of these antigens were significantly greater after laparoscopically assisted resection than after open surgery, but these differences were no longer evident on the third postoperative day (42). The same group also measured the effect of incision length and exposure method for cecal resection on postoperative immune function as assessed by delayed-type hypersensitivity response. Rats underwent laparotomy (7 cm incision), minilaparotomy (3.5 cm), or laparoscopy (via four ports). Cell-mediated immune responses following laparoscopic surgery were 20% greater than those were after open surgery with a long incision, indicating better preservation of systemic immunity (10).

Gitzelmann et al. compared the cell-mediated immune response following CO₂ pneumoperitoneum, extraperitoneal incision, and laparotomy in an animal model and demonstrated that delayed-type hypersensitivity responses and the ability to reject an immunogenic tumor were better preserved after CO₂ pneumoperitoneum than after extraperitoneal incision or laparotomy (43).

Peripheral lymphocytes are the effectors of cellular immunity and decreased T-cell function has been reported by several investigators following surgical stress (1,44). In an experimental study, Lee et al. (45) found a significantly lower lymphocyte proliferation rate after laparotomy than after CO₂ insufflation. No difference was found between insufflation and the anesthesia-only control group at any point in time. In an interesting study, they also demonstrated that the lower lymphocyte proliferation rate following open surgery was independent of the atmospheric environment, as they found no significant difference between laparotomy performed in room air or in a sealed CO₂ chamber (46).

Cristaldi et al. (47) found a reduction in natural killer cell numbers following both open and laparoscopic cholecystectomy, but the reduction was less after the latter. In a contradictory study, decreased natural killer cell cytotoxicity was noted following both laparoscopic and open procedures, with no advantage for the laparoscopic approach (48). Cristaldi et al. also reported a lower total lymphocyte count after conventional surgery compared with the equivalent laparoscopic approach. They demonstrated persistent depression of CD4⁺ cells following open but

Studies reported to date clearly indicate that T-cell function and cell-mediated immunity are better preserved after laparoscopic than after open surgery. Most clinical studies have compared laparoscopic to open cholecystectomy, and caution must be exercised when extrapolating these results to other operations where trauma of access may be significantly greater.

not after laparoscopic surgery (47). Vallina and Velasco (49) found the ratio of CD4+:CD8+ to be decreased to 13% below preoperative levels on the first day after laparoscopic cholecystectomy. This ratio normalized a week after surgery.

Lennard et al. (50) classified operations as major or minor and assessed the effect of open surgery on lymphocyte subpopulations. Based on this classification, open cholecystectomy was categorized as major surgery. Using the same classification, Evrard et al. compared changes in lymphocyte subpopulations following laparoscopic and open cholecystectomy. They reported that alterations in lymphocytes after laparoscopic cholecystectomy were equivalent to those seen in Lennard's minor surgery group classification (51).

Studies reported to date clearly indicate that T-cell function and cell-mediated immunity are better preserved after laparoscopic than after open surgery. Most clinical studies have compared laparoscopic to open cholecystectomy, and caution must be exercised when extrapolating these results to other operations where trauma of access may be significantly greater.

Effect on Monocyte-Macrophage Function

The monocyte-macrophages are responsible for phagocytosis and the principal source of tumor necrosis factor and IL-1 following T-cell stimulation. Gutt et al. investigated the phagocytic activity of rat macrophages by means of an intravascular carbon clearance test during conventional and laparoscopic fundoplication using pneumoperitoneum and gasless laparoscopy. Although the fastest carbon elimination half-life was found in rats undergoing gasless laparoscopy, carbon clearance after conventional laparoscopy was significantly greater than that associated with open surgery (52).

The monocyte-macrophage system also plays an important role as antigen presenting cells in association with human leucocyte antigen expression. A significant reduction in human leucocyte antigen-DR expression has been reported after open operation, but not after laparoscopic surgery. However, Brune et al. (53) found that this decrease in monocyte human leucocyte antigen-DR expression might not alter the antigen-presenting capacity of monocytes in either surgical group. Klava et al. assessed the potential role of IFN- γ by determining the capacity of monocytes to respond to this cytokine following open and laparoscopic surgical procedures. They observed that laparoscopic surgery is associated with a similar level of suppression of monocyte human leucocyte antigen-DR expression as seen after open surgery (54). This expression is refractory to further stimulation by IFN- γ . This is consistent with other reports (53) that have demonstrated similar suppression but with earlier return to normal levels after laparoscopic than open surgery.

Monocyte-mediated cytotoxicity correlates closely with Kupffer cell-mediated cytotoxicity and both of these cells play a key role in limiting tumor growth in the liver. Vittimberga et al. (55) observed no difference in cytokine response following laparoscopy and open surgery, but intracellular Kupffer cell signalling was slightly different between laparoscopy and laparotomy. On the other hand, Sietses et al. (56) investigated three different laparoscopic procedures and demonstrated that laparoscopic surgery preserves monocyte-mediated cytotoxicity in contrast to the conventional approach.

LAPAROSCOPY AND INTRAPERITONEAL IMMUNE FUNCTION

The advantages of less systemic immunosuppression following laparoscopic surgery may not necessarily be mirrored at the level of the peritoneal membrane. The choice of insufflation gas and intraperitoneal pressure are also known to modulate the local immune environment (57). The peritoneum plays a major role in the immunological response to abdominal surgery (58) and cytokine levels in the peritoneal fluid are known to steadily increase after laparotomy.

Peritoneal macrophages play an integral role in the inflammatory response to intra-abdominal infection and cancer (59). The scavenging action of these macrophages is partly mediated by the production of inflammatory cytokines, such as tumor necrosis factor- α . The use of CO₂ as the insufflating agent has been associated in some experimental studies with impaired production of tumor necrosis factor- α by peritoneal macrophages (59,60) and this may impair their scavenging ability.

Peritoneal macrophages harvested from rats that had undergone laparoscopy with CO₂ a day earlier produced significantly less tumor necrosis factor- α in vivo than macrophages from rats that had undergone gasless laparoscopy or laparotomy (61). This response persisted when macrophages were collected three days after operation

(62). In vitro experiments performed by West et al. (63) yielded similar results. Macrophage tumor necrosis factor and IL-1 responses to bacterial endotoxin were lower for cells incubated in CO₂ than in either air or helium. IL-1 inhibition occurred within 15 minutes of CO₂ exposure and IL-1 mRNA nucleic acid was similarly reduced. Tumor necrosis factor levels were inhibited only after prolonged incubation and persisted after removal of CO₂. Tumor necrosis factor mRNA nucleic acid levels remained unaffected. Hajri et al. (64) assessed systemic and peritoneal immune function in rats and found that the levels of tumor necrosis factor- α , IL-6, and inducible nitric oxide synthase gene transcription were significantly enhanced in peripheral white blood cells and depressed in peritoneal cells. These results indicate an impairment of peritoneal macrophage immune activity following CO₂ pneumoperitoneum.

The exposure of macrophages to CO₂ also causes impaired responsiveness to lipopolysaccharide-stimulated cytokine release, which can attenuate the cancer cell lysis activity of macrophages (60). In a human monocyte line, Jackson and Evans (59) demonstrated that exposure to a high concentration of CO₂ reduces macrophage cytokine secretion and phagocyte activity, and substantially reduces cytotoxic activity against colonic cancer cells. Exposure of cancer cells to this gas also causes significant intracellular acidification and might be associated with a higher tumor growth rate compared with that of cells exposed to helium. These findings have been contradicted by Evrard et al. (51), who found no change in the lymphocyte viability and no increase in lymphocyte lysis after CO₂ pneumoperitoneum during laparoscopic procedures. They suggested that this might be because of increased peritoneal bicarbonate production, leading to buffering of the effect of CO₂. They also showed that peritoneal lymphocytes were not destroyed by one hour of CO₂ pneumoperitoneum during laparoscopic cholecystectomy, whereas circulating lymphocyte subpopulations and cytokine levels were moderately suppressed. More efficient peritoneal bacterial clearance by macrophages has also been noted after laparoscopic surgery.

A Dutch group has shown in piglets that levels of IL-1, IL-6, tumor necrosis factor- α , macrophages, and polymorphonuclears were reduced by a laparoscopic approach and by exposure to CO₂ rather than air (65). Mice subjected to pneumoperitoneum, when compared to laparotomy and simple anesthesia groups, have significantly lower percentages of natural killer cells in peritoneal exudate (66). These natural killer cells were also shown to have less impaired cytotoxicity in the pneumoperitoneum group.

Puttick et al. (67) compared the immunological and physiological effects of conventional CO₂ insufflation at room temperature with CO₂ pneumoperitoneum at body temperature in patients undergoing laparoscopic cholecystectomy. They observed greater levels of cytokines (tumor necrosis factor, IL-1, IL-6) in the peritoneal fluid following pneumoperitoneum at room temperature.

The immune response at the peritoneal interface depends not just on the trauma of access but also on the type, pressure, and temperature of the insufflating gas.

The above studies indicate that the systemic immunological benefits observed after laparoscopic surgery may not apply at the peritoneal level and that CO₂ pneumoperitoneum attenuates the immune response of peritoneal macrophage (13). This is a paradoxical finding but has important implications when considering laparoscopy in the presence of intra-abdominal inflammation or sepsis.

The effects of surgery on the systemic immune response are summarized in Table 1 and major randomized controlled trials summarized in Table 2.

The above studies indicate that the systemic immunological benefits observed after laparoscopic surgery may not apply at the peritoneal level and that CO₂ pneumoperitoneum attenuates the immune response of peritoneal macrophage. This is a paradoxical finding but has important implications when considering laparoscopy in the presence of intra-abdominal inflammation or sepsis.

TABLE 1 ■ Effects of Open Surgery and Laparoscopy on the Systemic Immune Response

Immune marker	Open surgery	Laparoscopy
CRP	↑↑	↑
IL (1, 6, 8, 10)	↑↑	↑
Polymorphonuclear number	↑↑	↑
Polymorphonuclear function	↓↓	↓
Delayed hypersensitivity	↓↓	↓
Th1, Th2	↓↓	↓
CD4+:CD8+	↓↓	↓
Monocyte HLA-DR expression	↓↓	↓
Natural killer cell activity	↓	↓
Abbreviation: CRP, C reactive protein.		

TABLE 2 ■ Summary of Randomized Control Trials of Laparoscopy Compared to Open Surgery

Author (Ref.)	Condition	Type	Results
Dunker et al. (68)	Lap-assisted vs. open bowel resection	Human	No immunological difference
Wu et al. (69)	Lap vs. open bowel resection for cancer	Human	Serum cytokines lower after lap although no peritoneal differences
Lee et al. (70)	Lap-assisted vs. open cecectomy	Rats	Peritoneal macrophage and blood monocyte function better in lap
Solomon et al. (71)	Lap vs. open rectopexy for prolapse	Human	1L-6, serum cortisol, and CRP responses favored laparoscopy
Ordemann et al. (72)	Lap vs. open bowel resection for cancer	Human	CMI and cytokine response better preserved after laparoscopy
Tang et al. (73)	Lap vs. open colorectal cancer resection	Human	Lap-assisted colectomy does not confer immunological advantages
Leung et al. (27)	Lap vs. open rectosigmoid cancer resection	Human	Systemic cytokine response less after lap-assisted resection
Schwenk et al. (26)	Lap vs. open colorectal resections	Human	IL-6, CRP lower after laparoscopy
Mutter et al. (74)	Tumor manipulation in pancreatic cancer	Rats	Manipulation causes less tumor growth after laparoscopy
Squirrell et al. (20)	Lap vs. small incision cholecystectomy	Human	Similar neuroendocrine response in the two groups
Kuntz et al. (33)	Lap vs. open colonic resection	Rats	Lesser stress and immune response to laparoscopy
Allendorf et al. (75)	Tumor growth after laparoscopy	Mice	Tumors grow larger after laparotomy than laparoscopy

Abbreviations: IL, interleukin; CRP, C reactive protein; CMI, cell mediated immunity.

TUMOR GROWTH, METASTASIS, AND IMMUNE FUNCTION

For laparoscopic oncological surgery to stand the test of time, short- and long-term results must demonstrate equivalent margin status and cancer control when compared to open surgery. For laparoscopic nephrectomy, emerging data indicate that this is indeed the case as cancer-specific survival for similar stage disease is equivalent at five years. However reports of abdominal wall and port site metastasis has led to speculation that pneumoperitoneum may have a detrimental effect on tumor growth. Nine cases of port site metastasis after urological laparoscopy have been reported in clinical and experimental studies (76). Five have been after nephrectomy, one after bladder mass biopsy of a TCC, and three after pelvic lymph node dissection (two TCC bladders and one prostate cancer). Contributing factors such as high grade and stage of tumor, violation of tumor boundaries, no use of entrapment sack, torn entrapment bag, specimen morcellation, and ascites have been noted (76). Although it is likely that the etiology of port site metastases is multifactorial, some studies have suggested that local peritoneal immune suppression may play a pivotal role in the development of tumor metastases following laparoscopic surgery (77,78). It has been suggested that CO₂ might facilitate the implantation and growth of tumor cells (62).

Several investigators have demonstrated that the incidence of port site metastases can be reduced in experimental models by excluding CO₂ from the laparoscopic environment by using either gasless laparoscopy or helium insufflation (77,80,81). This suggests that carbon dioxide, in particular, may exert an adverse metabolic effect on tumor cells that facilitates their implantation and growth. Jacobi et al. investigated the impact of different laparoscopic environments on tumor growth in a rat model. They found that CO₂ significantly promoted tumor growth, associated with a significant increase in plasma levels of IL-10 and a decrease in tumor necrosis factor- α in the postoperative period, compared with helium insufflation (82).

Cell-mediated immunity is also believed to influence postoperative tumor growth. Allendorf et al. observed significantly less growth of extra-abdominal tumor following laparoscopy compared with open surgery in immunocompetent mice (83). Comparable growth of pancreatic tumor cells after laparoscopy and laparotomy was noticed when no manipulation of the tumor was performed. Manipulation however led to significantly increased tumor growth in the laparotomy rather than the laparoscopic group.

In addition to altered peritoneal and systemic immunity, the etiological process behind port site metastasis is thought to involve the aerosolization of tumor cells due to insufflation and desufflation. Preventative measures should include adequate equipment, technical preparation and meticulous technique, avoiding gas leakage, trocar fixation to prevent dislodgment, bag retrieval (impermeable bag if morcellation is performed), avoidance of laparoscopy in ascites, and minimal handling of the tumor. At present, it seems likely that the incidence of incisional tumor recurrence is similar after both open and laparoscopic approaches (76).

In addition to altered peritoneal and systemic immunity, the etiological process behind port site metastasis is thought to involve the aerosolization of tumor cells due to insufflation and desufflation. Preventative measures should include adequate equipment, technical preparation and meticulous technique, avoiding gas leakage, trocar fixation to prevent dislodgment, bag retrieval (impermeable bag if morcellation is performed), avoidance of laparoscopy in ascites, and minimal handling of the tumor. At present, it seems likely that the incidence of incisional tumor recurrence is similar after both open and laparoscopic approaches.

LAPAROSCOPIC BOWEL INJURY

Laparoscopic bowel injuries are a rare but potentially fatal complication, especially if initial recognition is delayed. Presentation is often atypical when compared with open surgery. Aldana and colleagues looked at laparoscopic bowel injury in a rabbit model using serum monocyte, neutrophil, and lymphocyte apoptosis as indicators of the immune response. They observed that open surgery resulted in a significant increase in programmed cell death compared with controls in the immediate postoperative period following bowel injury. In comparison, laparoscopic bowel injury resulted in a delayed response that only approached open surgery levels after two weeks. They concluded that this difference in degree of cellular death could be secondary to a smaller degree of stimulation of the immune response in laparoscopic surgery. When the period of laparoscopy was extended from one to five hours, the percentage of apoptosis was similar to that seen after open surgery and no animal undergoing a five-hour procedure survived to two weeks after bowel injury (84).

It is well recognized that patients with laparoscopic bowel injury following urological procedures do not present with the typical acute surgical abdomen.

It is well recognized that patients with laparoscopic bowel injury following urological procedures do not present with the typical acute surgical abdomen.

Bishoff et al. reported bowel perforation in 0.2% and bowel abrasion in 0.6% of cases. The latter were recognized and repaired at the time of injury but the patients with perforation presented postoperatively with single port site pain, abdominal distention, diarrhea, leukopenia, followed by cardiopulmonary collapse secondary to sepsis within 96 hours of surgery. These can be fatal injuries and it is important to recognize the initial unusual signs and reduction in leukocyte count (85). The overall incidence of bowel injury is 1.3/1000, most of which are unrecognized intraoperatively and need laparotomy to repair the injuries.

IMMUNOLOGIC ASPECTS OF LAPAROSCOPIC UROLOGY

Fornara et al. (86) reported a prospective, controlled, nonrandomized animal and patient study to determine the systemic response to laparoscopic and open surgical procedures. In the animal study, 26 female pigs aged six months underwent either a laparoscopic bilateral varix ligation followed by bilateral nephrectomy (group I), introduction of trocars (group II), or establishment of an open surgical approach (group III). In the patient study, 145 patients underwent various laparoscopic procedures (unilateral nephrectomy = 17, bilateral laparoscopic nephrectomy = 7, renal cyst marsupialization = 29, varix ligation = 17), open surgical procedures (nephrectomy = 42, inguinal orchidectomy = 8), or extracorporeal shockwave lithotripsy = 25). A weakness of this study is the fact that the patient groups are not evenly matched. IL-6, IL-10, and C-reactive protein were measured before, during, and after the operative procedure. In animals and patients, laparoscopy resulted in significantly lower serum levels of C-reactive protein during and in the postoperative period. Animals in group I showed a five-fold elevation, in group II a three-fold elevation, and in group III a nine-fold elevation of C-reactive protein. In patients, C-reactive protein was twice as high after open unilateral nephrectomy than after laparoscopic unilateral or bilateral nephrectomy. Elevation of IL-6 was less pronounced during laparoscopy, extracorporeal shockwave lithotripsy, and minor procedures like laparoscopic varix ligation or inguinal orchidectomy when compared to an open unilateral nephrectomy. IL-10 was not significantly different among the patient groups (Figs. 4 and 5). The authors concluded that the acute-phase response to operative trauma correlated more to the approach than to the extent of the procedure. Larger operations like nephrectomy trigger a marked systemic acute-phase reaction, which can be reduced by laparoscopic access. In minor operative procedures like varix ligation or exploration of cryptorchidism, laparoscopy offers technical advantages rather than minimal invasiveness as the immune response in these situations is much less.

The above findings were contradicted in a prospective study by Landman et al. (87). They compared the systemic immune and stress response of patients who underwent laparoscopic total nephrectomy and open nephrectomy for renal cell carcinoma (10,14). Unlike Fornara et al., this study concentrated on nephrectomy only for renal cancer rather than a comparison with other procedures. The open nephrectomy group comprised open radical (four), open total (two), and open partial (four) nephrectomies. Peripheral venous blood was collected preoperatively, intraoperatively, and at 24 hours, two weeks, four weeks, and three months postoperatively. Patients who had postoperative infection or illness in the three-month period following surgery were excluded




FIGURE 4 ■ IL-6 levels in laparoscopic (group V) or open nephrectomy (group VII). T0 = 24 hours preoperative, T1 = beginning of anesthesia, T2 = trocar insertion/skin incision, T3 = pneumoperitoneum/peritoneal incision, T4 = ligation of renal artery, T5 = end of procedure, T6 = six hours postoperative, T7 = 12 hours postoperative, T8 = 24 hours postoperative. Abbreviation: IL, inter leukin. Source: From Ref. 86.

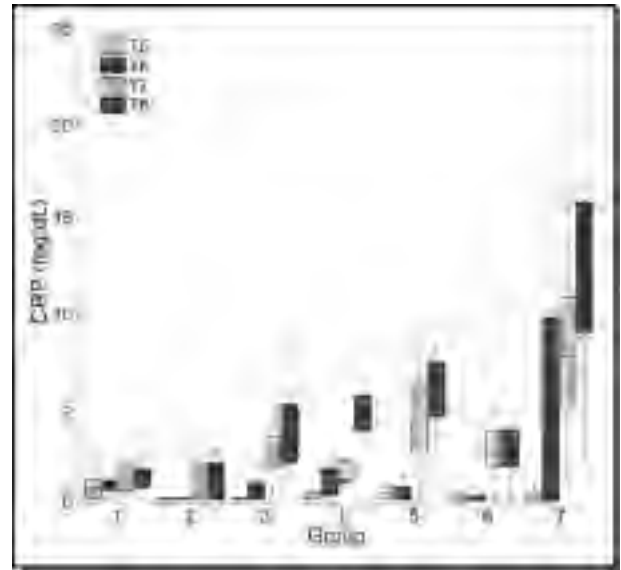


FIGURE 5 ■ CRP serum levels of group I = ESWL, group II = lap varix ligation, group III = lap renal cyst marsupialization, group IV = open inguinal orchidectomy, group V = lap unilateral nephrectomy, group VI = lap bilateral nephrectomy, group VII = open unilateral nephrectomy from T5–8 (T5 = trocar removal/wound closure, T6 = six hours postoperative, T7 = 12 hours postoperative, T8 = 24 hours postoperative). Abbreviation: CRP, C reactive protein. Source: From Ref. 86.

from study. Blood from these patients was analyzed for stress markers (adrenalin, noradrenalin, and cortisol), inflammatory response markers (C-reactive protein, white blood count, and leukocyte count), lymphocytic response markers (CD3, CD4, and CD8), cytokines (IL2 and IL4, INF α and tumor necrosis factor α), human leucocyte antigen-DR expression, and the proliferative response to mitogen stimulation using concanavalin A, phytohemagglutinin 10, and pokeweed mitogen. Unlike in other studies IL6 levels were not measured. Tumor histopathology and Fuhrman grade were similar between the two groups although mean tumor size was nonsignificantly smaller for the laparoscopic total nephrectomy group compared to the open nephrectomy group [4.5 ± 1.6 and 5.6 ± 2.4 cm, respectively ($p = 0.21$)]. Inflammatory and stress response markers were statistically similar for the groups at the measured time points. A significant difference between the groups was noted for the percentage and ratio of CD4+ and CD8+ lymphocytes, which is an indicator of immune activation of helper T cells. The ratios of CD4+:CD8+ were 2.7:1 for laparoscopic total nephrectomy and 1.8:1 for open nephrectomy. However, this difference was present preoperatively and sustained at all time points, thus being unlikely to represent a surgery-specific response. The cytokine response, HLA-DR, lymphocytic stimulation index for concanavalin A, phytohemagglutinin 10, and pokeweed mitogen were statistically similar for LRN and open nephrectomy at all time points. Age group analysis did show differences between the cohorts with respect to CD4+ and CD8+ lymphocytes in the 60 to 80-year olds. Additionally, in this age group intraoperative human leucocyte antigen-DR expression and tumor necrosis factor α production were higher in those undergoing open nephrectomy. In the 40 to 60-year-old group, the authors found higher 24-hour cortisol for open nephrectomy, percent CD4+ lymphocytes for laparoscopic total nephrectomy, and higher three-month proliferative capacity for laparoscopic total nephrectomy, as assessed by the phytohemagglutinin 10 index. These changes are shown in Figures 6–11. This study concluded that immunological and stress responses after laparoscopic total nephrectomy and open nephrectomy for renal cell carcinoma were similar and the few changes observed were likely to reflect preoperative changes or the effects of anesthesia. Perhaps longer anesthetic times for laparoscopic total nephrectomy masked any potential differences. It would have been useful if blood samples had been taken every 30 minutes during surgery while the patients were anesthetized to substantiate this




FIGURE 6 ■ Stress response after laparoscopic (lap) and open nephrectomy for localized renal cell carcinoma. Source: From Ref. 87.




FIGURE 7 ■ Inflammatory response after laparoscopic (lap) and open nephrectomy for localized renal cell carcinoma. Source: From Ref. 87.




FIGURE 8 ■ Lymphocytic response after laparoscopic (lap) and open nephrectomy for localized renal cell carcinoma. Source: From Ref. 87.




FIGURE 9 ■ HLA-DR response after laparoscopic (lap) and open nephrectomy for localized renal cell carcinoma. Source: From Ref. 87.

hypothesis. Preoperative immune dysfunction in renal cell carcinoma is known to be complex (88,89) and the findings of this study thus come as a surprise and do not explain the quicker short- and long-term recovery in patients undergoing laparoscopic total nephrectomy. It is feasible that for less extensive procedures, such as laparoscopic cholecystectomy, the laparoscopic approach is immunologically superior. In contrast, ablative laparoscopic renal surgery is quite extensive and may not have a definite immunological benefit, as assessed by current techniques to measure the immune response. Another possible explanation for the discrepancy may be the biology of renal cell carcinoma. It is feasible that the malignant disease process results in a significant alteration in immune function, such that differences between laparoscopic total nephrectomy and open nephrectomy are not detectable. Similar findings have been reported in randomized trials of surgery in colonic malignancy. Tang et al. (73) observed no difference in the immune response in laparoscopic-assisted versus open sigmoidectomy for colorectal cancer and Leung et al. (27) noted differences in the stress response but no differences in the immune response.




FIGURE 10 ■ Cytokine response after laparoscopic (lap) and open nephrectomy for localized renal cell carcinoma.
Source: From Ref. 87.




FIGURE 11 ■ Mitogen proliferative response after laparoscopic (lap) and open nephrectomy for localized renal cell carcinoma.
Source: From Ref. 87.

FUTURE DIRECTIONS

The majority of evidence appears to indicate that the preservation of immune function after an operative procedure confers advantages to the patient in terms of recovery and oncological outcome. It consequently seems likely that the deliberate stimulation of the immune system perioperatively may be a way to avoid the detrimental effects of surgery and upregulation of this nature may also result in improved cancer control. The early postoperative period may be an ideal time for induction of immune-based anti-cancer therapy, as tumor burden is at its lowest. Perioperative tumor vaccines may also be effective means of establishing specific immune responses against the tumor before resection (90). These concepts are being actively tested in experimental settings although they are yet to enter the clinical mainstream. It is likely that future basic science and clinical trials will identify specific areas of immune modulation in this challenging area.

Traditional methods of studying and manipulating the immune response have numerous shortcomings. They study individual components of the immune system rather than a collective “systems” response (6). The human genome project has made the “systems” approach to disease a reality. Simultaneous publication of draft versions of the genome in February 2001 in *Nature* and *Science* were important milestones and introduced major changes in medicine (91,92). Powerful tools for accurately deciphering biological information are now available. Emphasis is steadily shifting from structural genomics to functional genomics and proteomics. As a result, 21st century molecular biology in urology looks rather different and new and more effective preventive and therapeutic strategies are emerging (93,94). We urologists are getting familiar with acronyms like (expressed sequence tag—a short piece of di-oxy ribose nucleic acid sequence corresponding to a fragment of cdi-oxy ribose nucleic acid), (serial analysis of gene expression—a method that produces very short sequence tags used for gene identification), and SNP (single nucleotide polymorphisms—variations in single nucleotides between people, which may determine susceptibility and resistance to disease among different individuals), which were previously thought to be of little relevance.

High throughput tools are already providing us valuable information about important urological cancers. Like cancer, immune dysfunction is a “systems disease” and it is now obvious that the traditional method of searching for isolated genetic alterations is no longer useful. Microarray technology (95,96) allows a number of genes and genomic alterations to be studied at the same time. Some of these utilize high-speed robots such as Q-Bot. Bioinformatics is vital to make sense of this large amounts of genetic data. Such technology will allow us to better define and

compare the immunological changes after laparoscopy and open surgery. An example would be to study genetic changes associated with the T-cell receptor (Fig. 12). It would be possible to create oligonucleotide arrays that interrogate the expression patterns of each of these genes during T-cell development and their alterations after laparoscopic procedures. Commercially available signalling pathway gene arrays contain genes important to signal transduction that mediate the immune response and inflammation. These genes encode adhesion molecules, receptors, ligands, adaptors, kinases, regulators, transcription factors, and downstream effector proteins for each of these pathways. Signal transduction plays essential roles in immune cell activation, proliferation, differentiation, and apoptosis. Immune arrays that could prove useful in the field of laparoscopy are dendritic, antigen presenting cell arrays, and toll-like receptor signalling pathway arrays. These are available on chips of the size of a fingernail.

Combinatorial chemistry is an important tool where the idea is to synthesize a string of information using a combination of basic letters. For example, a combination of various molecules would lead to the creation of different three-dimensional shapes. Combinatorial chemistry can be used to facilitate the design and synthesis of new immunological targets in a rapid fashion.

Finally the most important tool for deciphering biological information is based on computational sciences. These are designed to collect, store, analyze, and ultimately distribute various types of biological information. A good example of this is the dissemination of collective information regarding the human genome project through GenBank and the Internet. This approach can only succeed through collaboration between computer scientists, applied mathematicians, biologists, and physicians (6,98).

Over the next few years, the systems' approach to immunology will become popular and this will certainly have an impact on the expanding field of minimally invasive urology.

FIGURE 12 ■ Location and complexity of genomic sequence of the human beta T-cell receptor. Source: From Ref. 97.



SUMMARY

- Most clinical and experimental studies support the view that laparoscopic surgery is associated with better preservation of postoperative systemic immune function than conventional surgery. Extrapolation of such data, however, requires further elucidation.
- Major surgery results in a period of cell-mediated immunosuppression, which can affect the patient's recovery.
- Open surgery is associated with higher levels of C-reactive protein and IL-6 than laparoscopy.
- Delayed-type hypersensitivity studies indicate that open methods lead to significantly more immunosuppression than laparoscopy. This difference becomes less obvious after prolonged major laparoscopic procedures and it is possible that longer anesthetic times may have an impact on the immune response.
- There is evidence of a short-lived greater shift towards Th2 function mainly through suppression of the Th1 lymphocytes after open surgery than after laparoscopy (90).
- Laparoscopy also leads to lesser decreases in HLA-DR expression and monocyte-mediated cytotoxicity than its open counterpart.
- Intraperitoneal immunity behaves independently of systemic immune function. The systemic benefits of laparoscopic surgery may not necessarily extend to the peritoneal interface.
- Further investigation on local peritoneal immunity is needed. The degree to which CO₂ pneumoperitoneum suppresses macrophage function is uncertain, as available data are conflicting.
- It is also impossible to draw firm conclusions with regards to bacterial clearance studies. At present, laparoscopic surgery appears to be equivalent to open surgery as regards oncological outcomes although long-term data are awaited.
- High throughput tools such as microarray technology may improve the way immunological responses to laparoscopic surgery are studied.

REFERENCES

1. Gupta A, Watson DI. Effect of laparoscopy on immune function. *Br J Surg* 2001; 88:1296–1306.
2. Kuhry E, Jeekel J, Bonjer HJ. Effect of laparoscopy on the immune system. *Semin Laparosc Surg* 2004; 11:37–44.
3. Rimington P, Dasgupta P. Laparoscopic and robotic radical cystectomy. *BJU Int* 2004; 93:460–461.
4. Endres JC, Salky BA. Laparoscopy in AIDS. *Gastrointest Endosc Clin N Am* 1998; 8:975–990.
5. Brostoff J, Scadding GK, Male D, Roitt IM. *Clinical immunology*. Chapter 1: 1.1–1.7. London: Mosby, 1991.
6. Dasgupta P, Nelson P. The human genome project and its impact on urology in the new millennium. *CME Urology* 2001; 2:79.
7. Rowen L, Koop BF, Hood L. The complete 685 kilobase DNA sequence of the human beta T-cell receptor locus. *Science* 1996; 272:1750–1762.
8. Grace PA, Quereshi A, Coleman J, et al. Reduced postoperative hospitalization after laparoscopic cholecystectomy. *Br J Surg* 1991; 78:160–162.
9. Faist E, Kupper TS, Baker CC, Chaudry IH, Dwyer J, Baue AE. Depression of cellular immunity after major injury. Its association with posttraumatic complications and its reversal with immunomodulation. *Arch Surg* 1986; 121:1000–1005.
10. Allendorf JD, Bessler M, Whelan RL, et al. Postoperative immune function varies inversely with the degree of surgical trauma in a murine model. *Surg Endosc* 1997; 11:427–430.
11. Slade MS, Simmons RL, Yunis E, Greenberg LJ. Immunodepression after major surgery in normal patients. *Surgery* 1975; 78:363–372.
12. Ohzato H, Yoshizaki K, Nishimoto N, et al. Interleukin-6 as a new indicator of inflammatory status: detection of serum levels of interleukin-6 and C-reactive protein after surgery. *Surgery* 1992; 111:201–209.
13. Vittimberga FJ Jr., Foley DP, Meyers WC, Callery MP. Laparoscopic surgery and the systemic immune response. *Ann Surg* 1998; 227:326–334.
14. Mayers I, Johnson D. The nonspecific inflammatory response to injury. *Can J Anaesth* 1998; 45:871–879.
15. Vander Velpen G, Penninckx F, Kerremans R, Van Damme J, Arnout J. Interleukin-6 and coagulation fibrinolysis fluctuations after laparoscopic and conventional cholecystectomy. *Surg Endosc* 1994; 8:1216–1220.
16. McMahon AJ, O'Dwyer PJ, Cruikshank AM, et al. Comparison of metabolic responses to laparoscopic and minilaparotomy cholecystectomy. *Br J Surg* 1993; 80:1255–1258.
17. Glaser F, Sannwald GA, Buhr HJ, Kuntz C, Mayer H, Klee F, et al. General stress response to conventional and laparoscopic cholecystectomy. *Ann Surg* 1995; 221:372–380.
18. Joris J, Cigarini I, Legrand M, et al. Metabolic and respiratory changes after cholecystectomy performed via laparotomy or laparoscopy. *Br J Anaesth* 1992; 69:341–345.
19. Mealy K, Gallagher H, Barry M, Lennon F, Traynor O, Hyland J. Physiological and metabolic response to open and laparoscopic cholecystectomy. *Br J Surg* 1992; 79:1061–1064.
20. Squirrell DM, Majeed AW, Troy G, Peacock JE, Nicholl JP, Johnson AG. A randomized, prospective, blinded comparison of postoperative pain, metabolic response, and perceived health after laparoscopic and small incision cholecystectomy. *Surgery* 1998; 123:485–495.

21. Cruickshank AM, Fraser WD, Burns HJ, Van Damme J, Shenkin A. Response of serum interleukin-6 in patients undergoing elective surgery of varying severity. *Clin Sci* 1990; 79:161–165.
22. Perlmutter DH, Dinarello CA, Punsal PI, Colten HR. Cachectin/tumor necrosis factor regulates hepatic acute phase gene expression. *J Clin Invest* 1986; 78:1349–1354.
23. Decker D, Lindemann C, Low A, Bidlingmaier F, Hirner A, von Ruecker A. Changes in the cytokine concentration (IL-6, IL-8, IL-1 ra) and their cellular expression of membrane molecules (CD25, CD30, HLA-DR) after surgical trauma. *Zentralbl Chir* 1997; 122:157–164.
24. Sakamoto K, Arakawa H, Mita S, et al. Elevation of circulating interleukin 6 after surgery: factors influencing the serum level. *Cytokine* 1994; 6:181–186.
25. Karayiannakis AJ, Makri GG, Mantzioka A, Karousos D, Karatzas G. Systemic stress response after laparoscopic or open cholecystectomy: a randomized trial. *Br J Surg* 1997; 84:467–471.
26. Schwenk W, Jacobi C, Mansmann U, Bohm B, Muller JM. Inflammatory response after laparoscopic and conventional colorectal resections—results of a prospective randomized trial. *Langenbecks Arch Surg* 2000; 385:2–9.
27. Leung KL, Lai PB, Ho RL, et al. Systemic cytokine response after laparoscopic-assisted resection of rectosigmoid carcinoma. A prospective randomized trial. *Ann Surg* 2000; 231:506–511.
28. Hu JK, Zhou ZG, Chen ZX, et al. Comparative evaluation of immune response after laparoscopic and open total mesorectal excisions with anal sphincter preservation in patients with rectal cancer. *World J Gastroenterol* 2003; 9:2690–2694.
29. Johnson DRE, Spencer MP, Cerra FB, Konstantidides F, Rothenberger DA, Madoff RD. Laparoscopic versus open colectomy: a comparative study of systemic stress response. *Surg Endosc* 1994; 8:447A.
30. Stage JG, Schulze S, Moller P, et al. Prospective randomized study of laparoscopic versus open colonic resection for adenocarcinoma. *Br J Surg* 1997; 84:391–396.
31. Hill AD, Banwell PE, Darzi A, Menzies-Gow N, Monson JRT, Guillou PJ. Inflammatory markers following laparoscopic and open hernia repair. *Surg Endosc* 1995; 9:695–698.
32. Akhtar K, Kamalky-Asl ID, Lamb WR, et al. Metabolic and inflammatory responses after laparoscopic and open inguinal hernia repair. *Ann R Coll Surg Engl* 1998; 80:125–130.
33. Kuntz C, Wunsch A, Bay F, Windeler J, Glaser F, Herfarth C. Prospective randomized study of stress and immune response after laparoscopic vs conventional colonic resection. *Surg Endosc* 1998; 12:963–967.
34. Kishi D, Nezu R, Ito T, et al. Laparoscopic-assisted surgery for Crohn's disease: reduced surgical stress following ileocelectomy. *Surg Today* 2000; 30:219–222.
35. Hildebrandt U, Kessler K, Pistorius G, et al. Granulocyte elastase and systemic cytokine response after laparoscopic-assisted and open resections in Crohn's disease. *Dis Colon Rectum* 1999; 42:1480–1486.
36. Polk HC Jr, George CD, Hershman MJ, Wellhausen SR, Cheadle WG. The capacity of serum to support neutrophil phagocytosis is a vital host defense mechanism in severely injured patients. *Ann Surg* 1988; 207:686–692.
37. Redmond HP, Watson RW, Houghton T, Condron C, Watson RG, Bouchier-Hayes D. Immune function in patients undergoing open vs. laparoscopic cholecystectomy. *Arch Surg* 1994; 129:1240–1246.
38. Sietes C, Wiezer MJ, Eijssbouts QA, et al. The influence of laparoscopic surgery on postoperative polymorphonuclear leukocyte function. *Surg Endosc* 2000; 14:812–816.
39. Carey PD, Wakefield CH, Thayeb A, Monson JR, Darzi A, Guillou PJ. Effects of minimally invasive surgery on hypochlorous acid production by neutrophils. *Br J Surg* 1994; 81:557–560.
40. Nies C, Krack W, Lorenz W, et al. Histamine release in conventional versus minimally invasive surgery: results of a randomised trial in acute cholecystitis. *Inflamm Res* 1997; 46(suppl 1):S83–S84.
41. Gutt CN, Kuntz C, Schmandra T, et al. Metabolism and immunology in laparoscopy. First workshop on experimental laparoscopic surgery, Frankfurt, 1997. *Surg Endosc* 1998; 12:1096–1098.
42. Allendorf JD, Bessler M, Whelan RL, et al. Better preservation of immune function after laparoscopic-assisted vs open bowel resection in a murine model. *Dis Colon Rectum* 1996; 39(suppl):S67–S72.
43. Gitzelmann CA, Mendoza-Sagaon M, Talamini MA, Ahmad SA, Pegoli W Jr, Paidas CN. Cell-mediated immune response is better preserved by laparoscopy than laparotomy. *Surgery* 2000; 127:65–71.
44. Brune IB, Wilke W, Hensler T, Holzmann B, Siewert JR. Downregulation of T helper type 1 immune response and altered pro-inflammatory and anti-inflammatory T cell cytokine balance following conventional but not laparoscopic surgery. *Am J Surg* 1999; 177:55–60.
45. Lee SW, Southall JC, Gleason NR, Huang EH, Bessler M, Whelan RL. Time course of differences in lymphocyte proliferation rates after laparotomy versus CO₂ insufflation. *Surg Endosc* 2000; 14:145–148.
46. Lee SW, Southall JC, Gleason NR, Huang EH, Bessler M, Whelan RL. Lymphocyte proliferation in mice after a full laparotomy is same whether performed in a sealed carbon dioxide chamber or in room air. *Surg Endosc* 2000; 14:235–238.
47. Cristaldi M, Rovati M, Elli M, et al. Lymphocytic subpopulation changes after open and laparoscopic cholecystectomy: a prospective and comparative study on 38 patients. *Surg Laparosc Endosc* 1997; 7:255–261.
48. Sandoval BA, Robinson AV, Sulaiman TT, Shenk RR, Stellato TA. Open versus laparoscopic surgery: a comparison of natural antitumoral immunity in a small animal model. *Am Surg* 1996; 62:625–631.
49. Vallina VL, Velasco JM. The influence of laparoscopy on lymphocyte subpopulations in the surgical patient. *Surg Endosc* 1996; 10:481–484.
50. Lennard TWJ, Shenton BK, Borzotta A, et al. The influence of surgical operations on components of the human immune system. *Br J Surg* 1985; 72:771–776.
51. Evrard S, Falkenrodt A, Park A, Tassetti V, Mutter D, Marescaux J. Influence of CO₂ pneumoperitoneum on systemic and peritoneal cell-mediated immunity. *World J Surg* 1997; 21:353–357.

52. Gutt CN, Heinz P, Kaps W, Paolucci V. The phagocytosis activity during conventional and laparoscopic operations in the rat. A preliminary study. *Surg Endosc* 1997; 11:899–901.
53. Brune IB, Wilke W, Hensler T, Feussner H, Holzmann B, Siewert JR. Normal T lymphocyte and monocyte function after minimally invasive surgery. *Surg Endosc* 1998; 12:1020–1024.
54. Klava A, Windsor A, Boylston AW, Reynolds JV, Ramsden CW, Guillou PJ. Monocyte activation after open and laparoscopic surgery. *Br J Surg* 1997; 84:1152–1156.
55. Vittimberga FJ, Nolan B, Perugini RA, Spector L, Callery MP. Laparoscopic surgery and Kupffer cell activation. *Surg Endosc* 2000; 14:1171–1176.
56. Sietses C, Havenith CE, Eijssbouts QA, et al. Laparoscopic surgery preserves monocyte-mediated tumor cell killing in contrast to the conventional approach. *Surg Endosc* 2000; 14:456–460.
57. Watson RW, Redmond HP, McCarthy J, Burke PE, Bouchier-Hayes D. Exposure of the peritoneal cavity to air regulates early inflammatory responses to surgery in a murine model. *Br J Surg* 1995; 82:1060–1065.
58. Badia JM, Whawell SA, Scott-Coombes DM, Abel PD, Williamson RC, Thompson JN. Peritoneal and systemic cytokine response to laparotomy. *Br J Surg* 1996; 83:347–348.
59. Jackson PG, Evans SRT. Intraperitoneal macrophages and tumor immunity: a review. *J Surg Oncol* 2000; 75:146–154.
60. West MA, Baker J, Bellingham J. Kinetics of decreased LPS-stimulated cytokine release by macrophages exposed to CO₂. *J Surg Res* 1996; 62:269–274.
61. Mathew G, Watson DI, Ellis TS, Jamieson GG, Rofe AM. The role of peritoneal immunity and the tumour-bearing state on the development of wound and peritoneal metastases after laparoscopy. *Aust N Z J Surg* 1999; 69:14–18.
62. Neuhaus SJ, Watson DI, Ellis T, Rofe AM, Mathew G, Jamieson GG. Influence of gases on intra-peritoneal immunity during laparoscopy in tumor-bearing rats. *World J Surg* 2000; 24:1227–1231.
63. West MA, Hackam DJ, Baker J, Rodriguez JL, Bellingham J, Rotstein OD. Mechanism of decreased in vitro murine macrophage cytokine release after exposure to carbon dioxide: relevance to laparoscopic surgery. *Ann Surg* 1997; 226:179–190.
64. Hajri A, Mutter D, Wacks S, et al. Dual effect of laparoscopy on cell-mediated immunity. *Eur Surg Res* 2000; 32:261–266.
65. Ure BM, Niewold TA, Bax NM, Ham M, van der Zee DC, Essen GJ. Peritoneal, systemic, and distant organ inflammatory responses are reduced by a laparoscopic approach and carbon dioxide versus air. *Surg Endosc* 2002; 16:836–842.
66. Fujii K, Izumi K, Sonoda K, Shiraishi N, Adachi Y, Kitano S. Less impaired cell-mediated immune response in the murine peritoneal cavity after CO(2) pneumoperitoneum. *Surg Today* 2003; 33:833–838.
67. Puttick MI, Scott-Coombes DM, Dye J, et al. Comparison of immunologic and physiologic effects of CO₂ pneumoperitoneum at room and body temperatures. *Surg Endosc* 1999; 13:572–575.
68. Dunker MS, Ten Hove T, Bemelman WA, Slors JF, Gouma DJ, Van Deventer SJ. Interleukin-6, C-reactive protein, and expression of human leukocyte antigen-DR on peripheral blood mononuclear cells in patients after laparoscopic vs. conventional bowel resection: a randomized study. *Dis Colon Rectum* 2003; 46:1238–1244.
69. Wu FP, Sietses C, von Blomberg BM, van Leeuwen PA, Meijer S, Cuesta MA. Systemic and peritoneal inflammatory response after laparoscopic or conventional colon resection in cancer patients: a prospective, randomized trial. *Dis Colon Rectum* 2003; 46:147–155.
70. Lee SW, Feingold DL, Carter JJ, et al. Peritoneal macrophage and blood monocyte functions after open and laparoscopic-assisted cecectomy in rats. *Surg Endosc* 2003; 17:1996–2002.
71. Solomon MJ, Young CJ, Evers AA, Roberts RA. Randomized clinical trial of laparoscopic versus open abdominal rectopexy for rectal prolapse. *Br J Surg* 2002; 89:35–39.
72. Ordemann J, Jacobi CA, Schwenk W, Stosslein R, Muller JM. Cellular and humoral inflammatory response after laparoscopic and conventional colorectal resections. *Surg Endosc* 2001; 15:600–608.
73. Tang CL, Eu KW, Tai BC, Soh JG, MacHin D, Seow-Choen F. Randomized clinical trial of the effect of open versus laparoscopically assisted colectomy on systemic immunity in patients with colorectal cancer. *Br J Surg* 2001; 88:801–807.
74. Mutter D, Hajri A, Tassetti V, Solis-Caxaj C, Aprahamian M, Marescaux J. Increased tumor growth and spread after laparoscopy vs laparotomy: influence of tumor manipulation in a rat model. *Surg Endosc* 1999; 13:365–370.
75. Allendorf JD, Bessler M, Kayton ML, et al. Increased tumor establishment and growth after laparotomy vs laparoscopy in a murine model. *Arch Surg* 1995; 130:649–653.
76. Tsivian A, Sidi AA. Port site metastasis in urological laparoscopic surgery. *J Urol* 2003; 169:1213–1218.
77. Watson DI, Mathew G, Ellis T, Baigrie CF, Rofe AM, Jamieson GG. Gasless laparoscopy may reduce the risk of port-site metastases following laparoscopic tumor surgery. *Arch Surg* 1997; 132:166–168.
78. Jacobi CA, Sabat R, Bohm B, Zieren HU, Volk HD, Muller JM. Pneumoperitoneum with carbon dioxide stimulates growth of malignant colonic cells. *Surgery* 1997; 121:72–78.
79. Neuhaus SJ, Watson DI, Ellis T, Rofe AM, Jamieson GG. The effect of immune enhancement and suppression on the development of laparoscopic port site metastases. *Surg Endosc* 2000; 14:439–443.
80. Mathew G, Watson DI, Rofe AM, Baigrie CF, Ellis T, Jamieson GG. Wound metastases following laparoscopic and open surgery for abdominal cancer in a rat model. *Br J Surg* 1996; 83:1087–1090.
81. Bouvy ND, Marquet RL, Jeekel H, Bonjer HJ. Impact of gas(less) laparoscopy and laparotomy on peritoneal tumor growth and abdominal wall metastases. *Ann Surg* 1996; 224:694–701.
82. Jacobi CA, Wenger F, Sabat R, Volk T, Ordemann J, Muller JM. The impact of laparoscopy with carbon dioxide versus helium on immunologic function and tumor growth in a rat model. *Dig Surg* 1998; 15:110–116.
83. Allendorf JD, Bessler M, Horvath KD, Marvin MR, Laird DA, Whelan RL. Increased tumor establishment and growth after open vs laparoscopic surgery in mice may be related to differences in postoperative T-cell function. *Surg Endosc* 1999; 13:233–235.

84. Aldana JP, Marcovich R, Singhal P, et al. Immune response to laparoscopic bowel injury. *J Endourol* 2003; 17:317–322.
85. Bishoff JT, Allaf ME, Kirkels W, Moore RG, Kavoussi LR, Schroder F. Laparoscopic bowel injury: incidence and clinical presentation. *J Urol* 1999; 161:887–890.
86. Fornara P, Doehn C, Seyfarth M, Jocham D. Why is urological laparoscopy minimally invasive? *Eur Urol* 2000; 37:241–250.
87. Landman J, Olweny E, Sundaram CP, et al. Prospective comparison of the immunological and stress response following laparoscopic and open surgery for localized renal cell carcinoma. *J Urol* 2004; 171:1456–460.
88. Dadian G, Riches PG, Henderson DC, et al. Immunological parameters in peripheral blood of patients with renal cell carcinoma before and after nephrectomy. *Br J Urol* 1994; 74:15–22.
89. Bohm M, Ittenson A, Philipp C, Rohl FW, Ansorge S, Allhoff EP. Complex perioperative immunodysfunction in patients with renal cell carcinoma. *J Urol* 2001; 166:831–836.
90. Carter JJ, Whelan RL. The immunologic consequences of laparoscopy in oncology. *Surg Oncol Clin North Am* 2001; 10:655–677.
91. International Human Genome Sequencing Consortium. Initial sequencing and analysis of the human genome. *Nature* 2001; 409:860–921.
92. Venter JC, Adams MD, Myers EW, et al. The sequence of the human genome. *Science* 2001; 291:1304–1351.
93. Williamson M, Naaby-Hansen S, Masters JRW. 21st Century molecular biology in urology. *BJU Int* 2001; 88:451–457.
94. Masuho Y, Matsumoto S, Isogai T, Nagai K, Nagahari K. The search for drug target molecules from genomics. *BJU Int* 2001; 88(suppl 2):11–17.
95. Bubendorf L. High-throughput microarray technologies: from genomics to clinics. *Eur Urol* 2001; 40:231–238.
96. Shergill IS, Freeman A, Mundy AR. Tissue microarrays in urology. *BJU Int* 2004; 94:22–25.
97. www.ensembl.org.
98. Dasgupta P. Genomics and urology. *BJU Int* 2002; 89:638–639.

LAPAROSCOPIC SURGERY IN THE HIGH RISK PATIENT

Assaad El-Hakim and Benjamin R. Lee

*Department of Urology, Long Island Jewish Medical Center,
New Hyde Park, New York, U.S.A.*

- PREVIOUS ABDOMINAL SURGERY
 - Open Access Technique
 - Alternative Sites for Introducing the Veress Needle
 - Optical Trocars
- COAGULATION DISORDERS
 - Platelets
 - Fresh Frozen Plasma

- Cryoprecipitate
- CARDIOPULMONARY DISORDERS
- ASCITES
- OBESITY
- ADVANCED AGE
- SUMMARY
- REFERENCES

In the setting of previous surgery, an extraperitoneal/retroperitoneal approach can be undertaken.

Alternatively, pneumoperitoneum can be created with a Veress needle that is inserted at least 3 cm away from previous abdominal incisions.

A previous abdominal surgery is not an absolute contraindication for laparoscopic procedures.

PREVIOUS ABDOMINAL SURGERY

The patient with previous abdominal surgery is at higher risk for visceral and vascular injuries during Veress needle and initial trocar insertion (1).

In the setting of previous surgery, an extraperitoneal/retroperitoneal approach can be undertaken. Urologic organs are well suited for this approach despite the more confined working space. Kidney, adrenal, ureteral, and prostate surgeries have all been described and successfully performed with the extraperitoneal approach. Alternatively, pneumoperitoneum can be created with a Veress needle that is inserted at least 3 cm away from previous abdominal incisions.

If pneumoperitoneum is obtained with Veress needle, insertion of the primary port is preferably performed with an optical trocar (Optiview^a or Visiport^b). Abdominal adhesions are more pronounced after bowel surgery and complex reconstructive procedures, particularly in the event of anastomotic leaks.

Prior abdominal or pelvic radiation is a major risk factor for adhesion formation due to chronic ischemia, and excessive care should be taken throughout these cases to prevent bowel injuries.

A previous abdominal surgery is not an absolute contraindication for laparoscopic procedures.

Open Access Technique

Advantages of open access technique in patients with previous laparotomies:

- The incidence of visceral and vascular injuries is significantly reduced.
- The risk of extraperitoneal insufflation is eliminated.
- Trocar site incisional hernia formation is decreased because the fascia is closed as part of the technique.
- In experienced hands, the open technique is cost effective and does not significantly increase the operative time.

Several open laparoscopic techniques have been described. The most commonly used is the Hasson technique (2). This is a safe method to enter the abdomen under direct open vision, and is especially suited for patients with abdominal adhesions from previous surgeries. A small (1–2 cm) skin incision is made away from previous scars. Blunt dissection is carried out until the anterior abdominal fascia is identified. The fascia is incised and the muscle fibers are spread. The underlying peritoneum is elevated

^aEthicon, Somerville, NJ.

^bU.S. Surgical Corp., Norwalk, CT.

with hemostatic clamps and incised. Two heavy, absorbable sutures are placed on either side of the fascial incision to secure the trocar in place and to prevent gas leakage. A 10–12 mm port with blunt trocar is inserted and CO₂ insufflation is performed through the port valve. The other ports are inserted under direct laparoscopic visualization away from adhesions. The preplaced fascial sutures are tied together at the end of surgery to close the defect.

Another open technique involves a small incision over the everted umbilicus at a point where the peritoneum is closest to the skin. This technique can be used in pediatric patients and in patients with previous surgery provided there is no midline incisions, portal hypertension, recanalized umbilical vein, umbilical pathologies such as a urachal cyst, sinus, or umbilical hernia. The umbilicus is everted with toothed grasping forceps and is incised in the sagittal plane. Two small retractors are inserted to expose the umbilical pillar or canal that runs from the undersurface of the skin down to the linea alba. Blunt dissection through this plane permits direct entry into the peritoneum. Once the peritoneal cavity is opened, a laparoscopic port with blunt internal trocar is then inserted under vision and insufflation started.

Lal et al. described a similar open technique without umbilical eversion whereby the umbilical cicatrix tube is used as a landmark to follow down to the linea alba where the peritoneum is adherent to the undersurface of the fascia. A supra- or subumbilical sagittal incision is used, provided no midline scar is present. This technique was performed in 525 consecutive cases with no complications or port site hernias (3). Another modification of the umbilical access named the mini-open technique or the umbilical stalk technique uses a 5 mm transumbilical incision and placement of a 5 mm blunt cannula without the trocar. The original authors employed this technique for four years in 600 patients without a midline laparotomy incision incorporating the umbilicus, and have accessed the abdomen safely for laparoscopy without any complications (4).

For a previously operated abdomen with a midline incision, the Veress needle should be placed in the upper left quadrant of the abdomen just lateral to the rectus sheath. Transrectus insertion of the Veress needle is discouraged because of risk of injury to the inferior epigastric vessels.

Alternative Sites for Introducing the Veress Needle

For a previously operated abdomen with a midline incision, the Veress needle should be placed in the upper left quadrant of the abdomen just lateral to the rectus sheath. Transrectus insertion of the Veress needle is discouraged because of risk of injury to the inferior epigastric vessels.

The Veress needle at the upper quadrant region needs to be passed more deeply into the abdomen in order to enter the peritoneal cavity because all layers of the abdominal wall are present here and the risk of preperitoneal insufflation is higher. Always insert the needle at a right angle from the skin surface. Another site of insufflation should be chosen in the presence of splenomegaly. The right upper quadrant is not the most optimal site because of the size of the liver and the presence of the falciform ligament. There are some reports of liver injury in cases of hepatomegaly.

In a patient with an upper abdominal scar, the Veress needle should be placed in the right lower quadrant. The left lower quadrant should generally be avoided in older patients since there are usually adhesions between the sigmoid colon and the abdominal wall secondary to subclinical episodes of diverticulitis. For patient with a previously operated abdomen in multiple quadrants, an open technique is optimal.

Optical Trocars

This is one of the techniques used to insert the initial trocar in patients with previous laparotomies. After pneumoperitoneum is obtained with the Veress needle, a 1 cm long incision is performed away from previous scars. Towel forceps are used to elevate the abdomen, and an optical trocar is introduced with the 0 degree telescope. The optical trocar is advanced slowly through the different planes of the abdominal wall using a full 180 degree rotational movement. The blunt blade at the tip of the trocar spreads the tissue under direct visual control. Entry into the peritoneal cavity is readily documented. This decreases the risk of injury to intra-abdominal organs. Thomas et al. used the optical access trocar as the initial trocar in 1283 urological laparoscopic procedures. The optical trocar was inserted at the umbilicus in 7.4% of patients, in the right upper quadrant in 34.7%, and in the left upper quadrant in 58.5%. There were four injuries (0.31%) associated with the optical access trocar, including one bowel injury, one mesenteric with retroperitoneal hematoma, and two epigastric vessel injuries (5).

Previous abdominal surgery does not appear to affect adversely the performance of subsequent urological laparoscopy.

Previous abdominal surgery does not appear to adversely affect the performance of subsequent urological laparoscopy.

Of 700 patients presenting to a single center for urological laparoscopy, 48% had a history of abdominal surgery. Overall, patients with no history of surgery compared to those with such a history tended to be older, predominantly female, and at significantly higher operative risk. Patients with a history of surgery who underwent nephrectomy or pyeloplasty were also more likely to have received blood transfusion perioperatively, which was probably related to their increased age and higher degree of medical comorbidity. There were no significant differences in operative blood loss, rate of conversion to open procedure, or rate of operative complications (6).

COAGULATION DISORDERS

The urologist may encounter disorders of hemostasis and coagulation either in the preoperative evaluation of the patients for elective surgery or in the perioperative care of patients with acute bleeding disorders. Diagnosis of the specific disorder involved requires an evaluation of the patient's history, physical examination, and appropriate laboratory tests.

An accurate history and physical examination of a patient scheduled to undergo elective operation offer the most valuable source of information regarding the risk of bleeding during surgery. A patient with a history of bleeding, easy bruisability (either spontaneous or traumatic), frequent or unusual mucosal bleeding, exceptionally high menstrual flow in females, prior history of significant or life-threatening hemorrhage associated with invasive procedures, or a family history of such problems may be at risk. A history of repeated severe epistaxis or abnormal laboratory tests may also be significant. The intake of medications should always be elicited. Especially important are drugs such as aspirin and nonsteroidal anti-inflammatory drugs, and because these preparations are widely available "over the counter," it is important to inquire specifically about them. Patients may not consider the intake of aspirin or nonsteroidal anti-inflammatory drugs as being important enough to mention when interviewed unless a specific question is asked. The most common cause of bleeding "disorders" is prescription drugs such as aspirin and warfarin. In addition, a history of liver dysfunction, renal dysfunction, or major metabolic or endocrine disorder is useful in directing preoperative screening. Hypercoagulability states and disorders include a history of deep venous thrombosis, pulmonary embolus, valvular disease, embolic or thrombotic cerebrovascular event, and atrial fibrillation.

Physical examination also provides valuable information. Evidence of excessive bruising, joint deformities, petechiae or ecchymosis, hepatosplenomegaly, excessive mobility of joints, or increased elasticity of the skin are symptoms of disorders associated with excessive perioperative bleeding. Evidence of amyloidosis (such as thickening of the skin or tongue), multiple myeloma, or other hematologic malignancies is also revealing.

It is beyond the scope of this chapter to detail all screening tests for bleeding and coagulation disorders. A hematologist should be involved in the perioperative management of these patients. The extent of laboratory testing needed for patients with a normal history and physical examination has been debated. Routine preoperative laboratory screening is useful for patients undergoing major procedures, especially involving body cavities or operations with significant dissection and the creation of raw surfaces, or patients with an abnormal history or physical examination. Routine preoperative testing is indicated for all patients undergoing urologic laparoscopy since it fulfills criteria of significant surgery. Patients with infection, sepsis syndrome (or the systemic inflammatory response syndrome), malnutrition, organ failure, and other major systemic disorders also warrant preoperative screening before surgical intervention.

In general, the commonly recommended tests include the prothrombin time, the partial thromboplastin time, a complete blood cell count with platelet count, and in some patients, a bleeding time.

The prothrombin time measures the function of factor VII as well as the *common pathway* factors (factor X, prothrombin/thrombin, fibrinogen, and fibrin). The partial thromboplastin time measures the *intrinsic* pathway and reflects the activity of all clotting factors except for platelet factor III, VII, and XII. For this reason, the test is complementary to the prothrombin time and may indicate deficiencies of other clotting factors or the presence of a circulating anticoagulant.

In general, commonly recommended tests include prothrombin time, partial thromboplastin time, complete blood cell count with platelet count, and in some patients, bleeding time.

All of the major coagulation factors are synthesized in the liver except for factor VIII, which is made in vascular endothelium and reticuloendothelial cells. The prothrombin time measures the activity of several of these factors, including factors I, II, V, VII, and X. Synthesis of prothrombin and factors VII, IX, and X depends on an adequate supply of vitamin K, which activates certain hepatic polypeptides by stimulating the synthesis of the calcium-binding residue, gamma-carboxyglutamic acid. An abnormal prothrombin time is commonly caused by vitamin K deficiency, liver disease, or both, and may rarely be seen with inherited abnormalities. Vitamin K, a fat-soluble vitamin that is found in many foods, is also produced by intestinal bacteria. Deficiency is most commonly seen in malnutrition and malabsorption syndromes, including failure to absorb dietary fat due to biliary obstruction or other causes of cholestasis. It may also be seen with antibiotic suppression of intestinal bacteria, especially when the patient is receiving inadequate oral or parenteral vitamin K replacement. Any acute or chronic liver disease may cause an abnormal prothrombin time by impairing the synthesis of essential clotting factors. Because the plasma half-life of these factors is typically less than one day, the prothrombin time responds rapidly to changes in hepatic synthetic function (7).

The platelet count identifies numbers of platelets, whereas the bleeding time estimates qualitative platelet function. None of the commonly recommended screening tests measures fibrinolytic function. Additional screening tests that may be used for specific patients include a fibrinogen level, the thrombin time, and screens for factor XIII levels. The thrombin time detects abnormalities of globulin, fibrinogen, excess fibrinolysis, and heparin-like substances. In patients suspected of having platelet dysfunction, additional assessments include platelet function tests (aggregation with epinephrine, adenosine diphosphate, collagen, and ristocetin). If a deficiency or specific factor is suspected, as in patients with a family history of hemophilia, then specific factor assays should be obtained (8).

Venous thromboprophylaxis should be considered for every patient undergoing laparoscopic urological surgery, especially certain populations with high-risk factors.

Patients who are elderly, obese, have a malignancy, or previous history of thrombosis are at increased risk of experiencing deep venous thrombosis and pulmonary embolus after surgery. Surgical factors are related to the extent of the operation and the type of anesthesia. Graduated compressive devices help to prevent thrombus formation and are suitable for low-risk patients. But those in the higher risk categories need to be anticoagulated as well. Subcutaneous unfractionated heparin and low molecular weight heparins have been found to be safe and effective in clinical practice.

Patients on aspirin or antiplatelet medication should stop these drugs 5–7 days preoperatively in order to normalize the bleeding time. In an emergency situation, desmopressin or platelet transfusion should be administered to avoid excessive risk of bleeding.

Patients on warfarin who are not at increased risk of thromboembolic events (such as previous history of venous thrombosis without recent recurrences) can stop the medication five days preoperatively, and resume the same dose on the first postoperative day if adequate hemostasis was obtained. Patients who are at moderate to high risk (atrial fibrillation), in whom warfarin cannot be stopped without replacement therapy, are started on subcutaneous low molecular weight heparin. These agents are stopped 12–24 hours before surgery and then resumed 12–24 hours postoperatively. If the prothrombin time did not normalize the day of surgery, vitamin K and/or fresh frozen plasma should be administered. Patients at very high risk should be converted on to intravenous heparin and monitored in hospital. Intravenous heparin is stopped six hours preoperatively to ensure normal partial thromboplastin time at the time of surgery, and heparin is resumed postoperatively as soon as the patient's condition permits. Warfarin is resumed when the patient is back on regular diet, and heparin is discontinued when coagulation tests have been within therapeutic levels for 48 hours. This period of overlap is called bridging and protects the patient from the initial transient prothrombotic effect of warfarin. There is always a fine balance between bleeding and hypercoagulability in these patients that needs to be judiciously determined in collaboration with the medical team.

Platelets

Platelet transfusions are indicated for patients suffering from or at significant risk of bleeding owing to thrombocytopenia and/or platelet dysfunction. Basic guidelines for platelet transfusion are outlined in Table 1. In general, platelets should not be transfused prophylactically in the absence of microvascular bleeding, a low platelet count in

Venous thromboprophylaxis should be considered for every patient undergoing laparoscopic urological surgery, especially certain populations with high-risk factors.

TABLE 1 ■ Suggested Transfusion Guidelines for Platelets

Recent (within 24 hours) platelet count 10,000/mm ³ (for prophylaxis)
Recent (within 24 hours) platelet count 50,000/mm ³ with demonstrated microvascular bleeding ("oozing") or a planned surgical/invasive procedure
Demonstrated microvascular bleeding and a precipitous fall in platelet count; patients in the operating room who have had complicated procedures or have required more than 10 U of blood and have microvascular bleeding, giving platelets assumes adequate surgical hemostasis has been achieved
Documented platelet dysfunction (e.g., prolonged bleeding time >15 minutes, abnormal platelet function tests) with petechiae, purpura, microvascular bleeding ("oozing"), or surgical/invasive procedure
<i>Unwarranted indications:</i>
Empirical use with massive transfusion when patient is not having clinically evident microvascular bleeding ("oozing")
Prophylaxis in thrombotic thrombocytopenic purpura/hemolytic uremic syndrome or idiopathic thrombocytopenic purpura; extrinsic platelet dysfunction (e.g., renal failure, von Willebrand's disease)

a patient undergoing a surgical procedure, or a platelet count that has recently fallen below 10,000/mm³. Previous guidelines recommended platelet transfusion for platelet counts of 20,000/mm³ for prophylaxis in stable patients without oozing or in those not undergoing surgical or invasive procedures. More recent data, however, suggest that a threshold of 10,000/mm³ causes no added bleeding while significantly reducing use of the resource (8). Patients receiving massive transfusion should not automatically receive prophylactic platelets in the absence of microvascular bleeding (9). In such patients, hypothermia effects depressed platelet function, and platelet transfusion is generally ineffective (10). Restoration of a normal temperature returns platelet function to normal and ameliorates microvascular bleeding. Ideally, platelets should be transfused after the temperature has been corrected.

Fresh Frozen Plasma

Fresh frozen plasma is used to replace labile clotting factors in patients with coagulopathy and documented deficiency of clotting factors. This condition may derive from liver dysfunction, congenital absence of clotting factor, or transfusion of factor-deficient blood products. A unit of fresh frozen plasma contains near-normal levels of all clotting factors. A unit of fresh frozen plasma increases clotting factor levels by about 3%. Adequate clotting is usually achieved with factor levels above 30%, although higher levels are advisable in patients undergoing operative or invasive procedures. The prothrombin time and the activated partial thromboplastin time can be used to assess patients for fresh frozen plasma transfusion and to follow the efficacy of administered fresh frozen plasma.

Guidelines for administration of fresh frozen plasma are listed in Table 2. Documentation of factor deficiency or abnormal prothrombin time or activated partial thromboplastin time in a patient with clinical bleeding minimizes unnecessary use of fresh frozen plasma. Fresh frozen plasma should not be used routinely by preset

TABLE 2 ■ Suggested Transfusion Guidelines for Fresh Frozen Plasma

Treatment of multiple or specific coagulation factor deficiencies with abnormal prothrombin time and/or activated partial thromboplastin time
Abnormal specific factor deficiency in the presence of one of the following:
Congenital deficiency of antithrombin III; factors II, V, VII, IX, X, and XI; protein C or S; plasminogen or antiplasmin
Acquired deficiency related to warfarin therapy, vitamin K deficiency, liver disease, massive transfusion, or disseminated intravascular coagulation
Also indicated as prophylaxis for the above if a surgical/invasive procedure is planned
<i>Unwarranted indications</i>
Empirical use during massive transfusion if patient does not exhibit clinical coagulopathy
Volume replacement
Nutritional supplement

formula after red blood cell transfusion. With the availability of equally effective but safer (albumin, hetastarch) and less expensive (crystalloids) solutions, fresh frozen plasma should not be used as a volume expander (11).

A new plasma product, solvent detergent plasma, has recently been approved by the U.S. Food and Drug Administration and is available from the American Red Cross. This product is essentially fresh frozen plasma that has been treated to inactivate enveloped viruses, particularly human immunodeficiency virus, hepatitis B, and hepatitis C. As a result, solvent detergent plasma should have a virtually zero risk of transmitting these infections. It is more expensive than fresh frozen plasma, and supplies are currently limited. Solvent detergent plasma is prepared from pools of 2500 U of fresh frozen plasma. The treatment with solvent detergent inactivates lipid-enveloped viruses, but does not inactivate non-lipid-enveloped virus such as hepatitis A and parvovirus (such transmission has been documented). It does not have any effect on prions, if indeed these can be transmitted by plasma transfusions (12). The benefits of using such a product would be offset by the use of many products that have not undergone viral inactivation. It appears reasonable to consider solvent detergent plasma for patients receiving plasma exclusively (or nearly so): coagulation factor deficiency, warfarin reversal, microangiopathic hemolytic anemia (thrombotic thrombocytopenic purpura, hemolytic uremic syndrome). Solvent detergent plasma would be contraindicated in the following: pregnancy, except at the time of delivery; neonates; chronic hemolytic anemia; sickle cell disease; patients undergoing chemotherapy or radiation; and patients receiving large amounts of other untreated blood components.

Cryoprecipitate

Cryoprecipitate is useful in treating factor deficiency (hemophilia A), von Willebrand's disease, and hypofibrinogenemia and may help treat uremic bleeding (13). Cryoprecipitate is usually administered as a transfusion of 10 single units.

Patients with severe cardiopulmonary diseases have higher surgical risks regardless of the approach. Due to their low cardiopulmonary reserve, these patients may develop important complications during and after laparoscopic surgery.

CARDIOPULMONARY DISORDERS

Patients with severe cardiopulmonary diseases have higher surgical risks regardless of the approach. Due to their low cardiopulmonary reserve, these patients may develop important complications during and after laparoscopic surgery.

Pneumoperitoneum is less well tolerated in these patients. CO₂ is quickly absorbed during laparoscopy (14). This gas is highly soluble in water and easily diffuses in body tissues. Because of its high diffusion coefficient relative to oxygen and other respiratory gases, it readily moves out of the peritoneal cavity owing to a high diffusion gradient caused by the difference in concentration of CO₂ between the intraperitoneal space and the surrounding components (e.g., blood). However, the characteristic of rapid absorption, which lessens the chance of a CO₂ gas embolus, may also lead to potential problems (e.g., hypercapnia, hypercarbia, associated cardiac arrhythmias). In particular, patients with chronic obstructive pulmonary disease may not be able to compensate for the absorbed CO₂ by increased ventilation; this may result in dangerously elevated levels of CO₂ in these patients. CO₂ also stimulates the sympathetic nervous system, which results in an increase in heart rate, cardiac contractility, and vascular resistance. Lastly, CO₂ is also stored in various body compartments (e.g., viscera, bones, muscles). After prolonged laparoscopic procedures, it may take hours before the patient has eliminated the extra CO₂ that has accumulated in these storage areas; again, this is more often the case in patients with pulmonary compromise (15,16).

The cardiovascular effects of pneumoperitoneum are diverse and are exaggerated in patients with cardiovascular disorders.

First, the effects of the pneumoperitoneum on venous return depend on atrial pressures, which, in turn, are a reflection of the hydration state of the subject. If atrial pressures are low (normal or hypovolemic state), then, during a pneumoperitoneum of up to 20 mmHg, venous return is reduced owing to increased compression of the vena cava from the pneumoperitoneum. If atrial pressures are high (hypervolemic state), the vena cava resists elevated intra-abdominal pressure, and venous return is actually enhanced. These principles apply only to an intra-abdominal pressure of up to 20 mmHg. Therefore, all patients, and in particular those with

The cardiovascular effects of pneumoperitoneum are diverse and are exaggerated in patients with cardiovascular disorders.

TABLE 3 ■ Differential Diagnosis of Ascites

Hypoalbuminemia
Hepatic congestion
Peritoneal infections
Neoplasms
Lymphatic obstruction
Meigs' syndrome, struma ovarii
Chronic pancreatitis or pseudocyst
Bile ascites
Urine ascites
Chylous ascites

The respiratory effects of pneumoperitoneum are also exaggerated in the patient with pulmonary disorders. Owing to increased intra-abdominal pressure, diaphragmatic motion is limited. Pulmonary dead space remains unchanged, but functional reserve capacity decreases.

Presence of ascites is considered a contraindication to laparoscopic surgery because of the increased risk of port site metastasis.

pulmonary disease, must be closely monitored for several hours after lengthy laparoscopic procedures. It is important for the anesthetist not to rely on central venous pressure readings for any clinical decision making. If information regarding vascular volume and central venous pressure is needed, a Swan-Ganz catheter should be placed.

Tachycardia and ventricular extrasystoles may be seen as results of hypercapnia (17). Peritoneal irritation may lead to vagal stimulation and subsequently to bradyarrhythmias. Also, dysrhythmias can serve as clinical warning signs for the occurrence of pneumothorax, hypoxia, and gas embolism (14).

The respiratory effects of pneumoperitoneum are also exaggerated in the patient with pulmonary disorders. Owing to increased intra-abdominal pressure, diaphragmatic motion is limited. Pulmonary dead space remains unchanged, but functional reserve capacity decreases (14).

The average peak airway pressure needed to keep up a constant tidal volume increases parallel to the increasing intra-abdominal pressure. Although usually not of great clinical importance in a healthy patient population, it is advisable to use positive end-expiratory pressure techniques when patients with lung disease undergo general anesthesia for a laparoscopic procedure (14).

The Trendelenburg position (used in lower urinary tract surgery) has an adverse effect on respiration as well. It elevates the diaphragm and decreases vital capacity. It can also lead to a dislocation of the endotracheal tube, which, in turn, may cause right mainstem bronchus intubation. Although of little clinical significance in healthy patients, the Trendelenburg position may cause pulmonary edema in patients with increased left-sided heart pressures.

Mechanical abdominal wall lift has been proposed as an alternative method of exposure in laparoscopic surgery to obviate or minimize the adverse physiologic effects of pneumoperitoneum in patients with high cardiopulmonary risk factors. Other theoretical advantages of this technology include minimization of the risk of CO₂ embolism in trauma patients and tumor dissemination in patients undergoing laparoscopic surgery for cancer. Abdominal wall lift systems do appear to reduce the adverse cardiovascular and respiratory effects, but they do so at the expense of surgical exposure, which is less optimal than that provided by the positive-pressure pneumoperitoneum. This reduced exposure increases the technical manipulation and exposure during the operation and, hence, the operating times. This problem is overcome by combination of abdominal wall lift with low-pressure (3–4 mmHg) pneumoperitoneum. This combination provides good surgical exposure without adverse cardiovascular consequences (18).

ASCITES

Presence of ascites is considered a contraindication to laparoscopic surgery because of the increased risk of port site metastasis.

Neoplastic ascites is usually secondary to primary hepatic neoplasms, metastases to liver or peritoneum, lymphomas, leukemias, or myeloid metaplasia. The differential diagnosis of ascites is shown in Table 3 (19).

The diagnosis of ascites is obtained by paracentesis and fluid analysis. Peritoneal effusion, like pleural effusion, can be subdivided as exudative or transudative based on its characteristics. The serum-ascites albumin gradient (serum albumin level/ascitic fluid albumin level) correlates directly with portal pressure and can also be used to classify ascites. Patients with gradients ≥ 1.1 g/dL have portal hypertension, and those with gradients < 1.1 g/dL do not; the accuracy of this method is in excess of 95% (20). A blood-ascitic fluid albumin gradient < 1.1 g/dL is suggestive of malignant ascites. The characteristics of malignant ascitic fluid include a bloody appearance, high total protein levels (> 2.0 g/dL), high LDH levels (> 200 IU), low glucose (< 60 mg/dL), and high red blood cell contents. An ascitic fluid polymorphonuclear leukocyte count $> 500/\mu\text{L}$ is suggestive of spontaneous bacterial peritonitis (19).

Tsivian and Sidi recently reviewed published experimental and clinical studies on port site metastases after urological laparoscopy. Nine cases of port site metastases have been described before 2003 (21). Etiological factors included the presence of ascites,

The presence of ascites (irrespective of type) has been previously recognized as a significant and independent risk factor for early port site recurrences in the general surgery and gynecology literature.

A body mass index of 40 or higher represents at least 100 lb of overweight status for men and 80 lb for women. In the United States, the age-adjusted prevalence of overweight in adults increased from 55.9% to 64.5% between the period 1988 and 1994 and the period 1999 and 2000.

Experience gained from laparoscopic bariatric surgery paved the way for laparoscopic surgery for almost all abdominal and retroperitoneal pathologies. Obesity was once considered a relative contraindication for urologic laparoscopic surgery; however, nowadays obese patients are probably better served with minimally invasive approaches that harbor fewer complications and offer faster recovery.

natural malignant disease behavior, host immune status, local wound factors, and insufficient technical experience of the surgeons and operating team. The authors suggested several preventive steps including avoiding laparoscopic surgery in patients with ascites.

The presence of ascites (irrespective of type) has been previously recognized as a significant and independent risk factor for early port site recurrences in the general surgery and gynecology literature (22,23).

OBESITY

Obesity poses a major challenge to the laparoscopic surgeon, both from the surgical (technical) and the medical aspect. Obesity has been recognized as an independent cardiovascular risk factor, and is associated with serious medical comorbidity including the metabolic syndrome, which is characterized by impaired glucose tolerance, dyslipidemia, and hypertension. Other medical conditions caused or aggravated by obesity include sleep apnea, daytime sleepiness, asthma, and gastroesophageal reflux. Physical disability, body image, and depressive illness can also be present. All these issues need to be factored in the treatment of such patients.

For adults, overweight has been defined by a body mass index (the weight in kilograms divided by the square of the height in meters) of 25 or higher, obesity by an index of 30 or higher, and extreme or "morbid" obesity by an index of 40 or higher.

A body mass index of 40 or higher represents at least 100 lb of overweight status for men and 80 lb for women. In the United States, the age-adjusted prevalence of overweight in adults increased from 55.9% to 64.5% between the period 1988 and 1994 and the period 1999 and 2000. The prevalence of obesity increased from 22.9% to 30.5%; the prevalence of extreme obesity increased from 2.9% to 4.7% (24).

The epidemic of obesity in the United States has spawned a second epidemic of bariatric surgery. The number of gastrointestinal surgeries performed annually for severe obesity increased from about 16,000 in the early 1990s to about 103,000 in 2003. This increase has been fueled by the increase in the number of people who are extremely obese; the failure of diets, exercise, and medical therapy; and the advent of laparoscopic procedures (25). Minimally invasive techniques have been used in bariatric surgery since 1993. Laparoscopic bariatric procedures have proven to be safe and conserve known benefits of laparoscopic surgery, including but not limited to a shorter recovery with an earlier return to normal activity (26,27).

Experience gained from laparoscopic bariatric surgery paved the way for laparoscopic surgery for almost all abdominal and retroperitoneal pathologies. Obesity was once considered a relative contraindication for urologic laparoscopic surgery; however, nowadays obese patients are probably better served with minimally invasive approaches that harbor fewer complications and offer faster recovery.

The acute major complications of open or laparoscopic surgery in the obese patient include pulmonary embolism, respiratory failure, cardiovascular events, wound infection, and bleeding. The most common late complication is incisional hernia. The level of risk is related to the specific procedure and the patient's age, degree of obesity, and other medical conditions. There is no comprehensive registry of such complications. Thus, it is difficult to obtain accurate data about the specific rates of serious complications and death that can be anticipated and that may occur even with excellent care.

Owing to the smaller access incision, wound infections and incisional hernias after laparoscopic surgery are expected to be less common than after open surgery. The extent of incisional hernia is related to the size of the initial incision. Incisional hernias after open surgery tend to be larger and require a more extensive repair with mesh, whereas incisional hernias that develop after laparoscopic surgery tend to be small and can be repaired with primary closure. Another easily recognized benefit of laparoscopic surgery in the obese patient is the reduced risk for retained instruments and laparotomy pads. Morbidly obese patients undergoing open surgery are at high risk for retained foreign objects. Another possible benefit of laparoscopy is the reduction in bowel obstruction because of the theoretical reduction in adhesion formation and the early return to normal bowel function.

In a comprehensive review of complications of laparoscopic bypass surgery in over 3400 patients as compared to open surgery, Podnos et al. reported that laparoscopic surgery in this morbidly obese population was associated with a decrease in wound

infection, incisional hernia, and mortality. However, there were no significant differences in the frequency of pulmonary embolism or pneumonia (28).

There are fewer reports in the urologic literature on laparoscopic surgery in the obese patient. However, contemporary series of laparoscopic nephrectomy, donor nephrectomy, adrenalectomy, and prostatectomy have been published and demonstrated safety and success of these complex procedures in obese patients.

Fugita et al. reviewed the Johns Hopkins series of intraperitoneal laparoscopic radical nephrectomy in the obese patient population. A body mass index greater than 30 was used to define obesity. Technical modifications included slightly greater insufflation pressures and a lateral shift in trocar sites. Of 101 patients, 32 were obese and 69 were not. The authors did not find significant differences in any of the analyzed parameters between the obese and nonobese patients, including operative time, time to ambulation, length of hospital stay, conversion rate to an open procedure, and complication rate. One conversion to an open procedure was required in both the obese and the nonobese laparoscopic groups (29). These authors concluded that obesity should not be considered a contraindication to laparoscopic nephrectomy. Similarly, Doublet et al. reported that retroperitoneal laparoscopic simple nephrectomy in obese patients was not associated with higher morbidity or longer hospitalization than in nonobese patients. In this series, eight patients had a body mass index 30 or greater and were compared to 40 nonobese patients. Of note, 22 patients were renal transplant recipients and underwent nephrectomy of native kidney (30). Fazeli-Matin et al. compared retrospectively the outcome of laparoscopic versus open renal and adrenal surgery in the obese patient (body mass index 30 or greater) at the Cleveland Clinic. The majority of laparoscopic procedures were performed using a retroperitoneoscopic approach. To insure adequate case matching, open group patients with factors precluding laparoscopic surgery were excluded from the study. There were 21 obese patients in each group and baseline parameters were comparable between groups. Surgical time between the laparoscopic and open groups was comparable; however, the laparoscopic group had decreased blood loss, quicker resumption of oral intake and ambulation, decreased narcotic analgesic requirements, shorter hospital stay, and quicker convalescence. The complication rate was similar (31).

The applicability of laparoscopic donor nephrectomy has also been reported in the obese donor. In a small series of 40 patients at the Georgetown Transplant Institute, the outcome of obese patients (body mass index >31) did not differ from nonobese donors (32). In a larger report, Jacobs et al. assessed 431 laparoscopic living donor nephrectomies. The markedly obese group consisted of 41 patients with a body mass index greater than 35. Forty-one controls with a body mass index less than 30 were matched to the obese donors. Donor operations in the markedly obese were significantly longer by an average of 40 minutes. Obese donors were more likely to require open conversion. More and larger laparoscopic ports were used in the markedly obese. The postoperative recovery of the gastrointestinal tract, hospitalization time, analgesic requirements, and total complications were equal in the two groups, although the obese donors' complications tended to be cardiopulmonary problems. But most importantly, the recipient graft function was equivalent between the two groups (33).

Markedly obese patients have an increased risk of complications from surgery, regardless of the approach.

Markedly obese patients have an increased risk of complications from surgery, regardless of the approach.

The current literature suggests that laparoscopic renal and adrenal surgery is technically feasible in the obese patient and results in decreased blood loss, quicker return of bowel function, less analgesic requirement, shorter convalescence, and reduced hospital stay as compared to open surgery. Upper tract laparoscopic surgery in this subset of patients does not seem to negatively impact the long-term functional and oncologic outcomes.

Less is known about lower tract laparoscopic surgery in obese patients. In a multi-institutional review of the incidence and factors contributing to conversion from laparoscopic radical prostatectomy to open prostatectomy among eight U.S. surgeons, obesity was found to be a major player. Of 670 operations, 13 (1.9%) were converted to open. Comorbidities associated with conversion were prior pelvic surgery and obesity (body mass index greater than 30). Six of the 13 conversions occurred in the surgeons' first five cases. Despite open conversion, the functional outcomes did not appear to be adversely affected (34). In another review of 100 consecutive cases of transperitoneal laparoscopic radical prostatectomy, prostate weight, androgen deprivation, and prior abdominal surgery did not significantly affect the operative time. However, obesity and the level of surgeon's experience increased the operative time by an average of 38 minutes (35).

In general, obese patients should initially be considered as relative contraindication to laparoscopic surgery until the learning curve has been overcome. In experienced hands, obese patients do benefit from the minimal invasiveness of laparoscopy. Regardless of approaches, obese patients remain at higher risks of medical and surgical complications due to associated comorbidities and technical difficulty. Appropriate patient selection, optimization of medical condition, and informed consent are paramount in this process.

Surgical planning and medical optimization of the patient condition are emphasized in the obese. The patient should be cleared for surgery by the medical team. Deep venous thrombosis prophylaxis is achieved with subcutaneous heparin or low molecular weight heparin, compressive lower extremity stockings or pneumatic sleeves, and early ambulation. Prophylactic antibiotics (first- or second-generation cephalosporins) are also administered perioperatively. Minor intraoperative modifications can facilitate the procedure in obese patients and these include proper trocar site selection, which is usually more lateral in upper tract surgery. We do not recommend routine use of higher insufflation pressure because it compromises ventilation; however, occasional increased pressure may achieve a larger working space.

In general, obese patients should initially be considered as relative contraindication to laparoscopic surgery until the learning curve has been overcome. In experienced hands, obese patients do benefit from the minimal invasiveness of laparoscopy. Regardless of approaches, obese patients remain at higher risks of medical and surgical complications due to associated comorbidities and technical difficulty. Appropriate patient selection, optimization of medical condition, and informed consent are paramount in this process.

ADVANCED AGE

Elderly patients are considered at high surgical risk because of the increased American Society of Anesthesiologists score generally due to associated comorbidities. In addition, normal physiologic changes of aging such as decreased cardiopulmonary reserve may predispose patients to increased complications from prolonged pneumo-peritoneum.

The minimally invasive nature of laparoscopic surgery in general offers several advantages over open surgery in the elderly patient population.

Dhose et al. described the cardiovascular and pulmonary changes induced by pneumoperitoneum in 16 patients aged >75 years and American Society of Anesthesiologists III. Cardiovascular monitoring included a radial artery catheter and a pulmonary artery catheter. Peritoneal insufflation resulted in improvement of cardiovascular function with increases in cardiac index, heart rate, mean arterial pressure, and SvO_2 , which was the result of a sympathetic stimulation. No change in preload, right ventricular end diastolic volume index and systemic vascular resistance was recorded. There was an increase in $PaCO_2$ 15 minutes after CO_2 insufflation and a further elevation after 60 minutes. There was no change in the intrapulmonary shunt pressure. This study demonstrated that pneumoperitoneum is well tolerated in older patients (36).

There are several reports documenting safety and efficacy of laparoscopic surgery in the elderly patient especially in the general surgery literature. In a study of 5884 consecutive patients who underwent an attempted laparoscopic cholecystectomy, 395 patients (6.7%) were older than 65 years. The results of laparoscopic cholecystectomy in patients aged 65–69 years were comparable with those reported in younger patients. Patients older than 70 years had a two-fold increase in complicated biliary tract disease and conversion rates because of the nature of the disease, but had a low mortality rate (2%) despite an increase in American Society of Anesthesiologists classification (37). Senagore et al. compared short-term outcomes in age-matched cohorts of patients undergoing laparoscopic versus open segmental colectomy in patients younger versus older than 70 years of age. The length of hospital stay was significantly shorter with laparoscopic surgery in both age cohorts. The direct hospital costs were significantly lower only with laparoscopic colectomy in the older cohorts. Using the physiologic and operative severity score for the enumeration of morbidity and mortality, it was noted that laparoscopy patients in both age groups experienced a rate of morbidity that was significantly lower than expected (38). Another study compared 65 patients (aged 70 and above) who underwent laparoscopic colorectal resection with 89 who had open surgery. Laparoscopic colorectal resection was found to be safe in elderly patients and was associated with more favorable short-term outcomes in terms of earlier return of bowel function, earlier resumption of diet, and shorter hospital stay. Laparoscopy was also associated with less cardiopulmonary morbidity (39).

Hsu et al. retrospectively reviewed the outcome of laparoscopic donor nephrectomy in six patients aged 65 years or older. The median donor age was 69.5 years, and the median American Society of Anesthesiologists score was II. The median operative time was 240 minutes, with a median blood loss of 300 mL. No intraoperative complications or open conversions occurred. Postoperatively, the median time to resumption

The minimally invasive nature of laparoscopic surgery in general offers several advantages over open surgery in the elderly patient population.

of oral intake was one day, and the median hospital stay was three days, and the median convalescence was two weeks. The one-year renal allograft survival was 100% (40). Fornara et al. reported findings for laparoscopic nephrectomy in 11 patients in comparison with open nephrectomy in 42 patients older than 65 years. Patients in the laparoscopy group demonstrated a significant decrease in blood loss and number of blood transfusions. In addition, benefits were shown for the analgesic consumption, hospital stay, and convalescence parameters for the laparoscopy group. Although the complication rates were comparable in both groups, an increase was observed in both groups for patients aged between 75 and 84 years (41).

SUMMARY

- In the carefully selected and prepared patient, previous abdominal surgery, coagulation disorders that have been reversed, obesity, and patients suffering from controlled cardiopulmonary disorders are still candidates for laparoscopy. Even with these risk factors, patients can still benefit from known advantages of laparoscopy over open surgery.
- Patients with severe cardiopulmonary diseases have higher surgical risks regardless of the approach. Due to their low cardiopulmonary reserve, these patients may develop important complications during and after laparoscopic surgery.
- The presence of ascites is considered a contraindication to laparoscopic surgery because of the increased risk of port site metastasis.
- Laparoscopic surgery is a safe option in the elderly population. Age alone should not be considered an absolute contraindication for laparoscopy.

REFERENCES

1. Lecuru F, Leonard F, Philippe Jais J, Rizk E, Robin F, Taurelle R. Laparoscopy in patients with prior surgery: results of the blind approach. *JLS* 2001; 5(1):13–16.
2. Hasson HM. A modified instrument and method for laparoscopy. *Am J Obstet Gynecol* 1971; 110(6):886–887.
3. Lal P, Sharma R, Chander R, Ramteke VK. A technique for open trocar placement in laparoscopic surgery using the umbilical cicatrix tube. *Surg Endosc* 2002; 16(9):1366–1370.
4. Carbonell AM, Harold KL, Smith TI, et al. Umbilical stalk technique for establishing pneumoperitoneum. *J Laparoendosc Adv Surg Tech A* 2002; 12(3):203–206.
5. Thomas MA, Rha KH, Ong AM, et al. Optical access trocar injuries in urological laparoscopic surgery. *J Urol* 2003; 170(1):61–63.
6. Parsons JK, Jarrett TJ, Chow GK, Kavoussi LR. The effect of previous abdominal surgery on urological laparoscopy. *J Urol* 2002; 168(6):2387–2390.
7. Goldman. Approach to the patient with liver diseases. *Cecil textbook of medicine*. Chapter 144. 21 ed. W.B. Saunders Company, 2000.
8. Fakhry SM, Rutherford EJ, Sheldon GF. Hematologic principles in surgery. Townsend: Sabiston textbook of surgery. 16th ed. Chapter 5. W. B. Saunders Company, 2001:68.
9. Reed RL, Ciavarella D, Heimbach DM, et al. Prophylactic platelet transfusion during massive transfusion: A prospective double-blind clinical study. *Ann Surg* 1986; 203:40.
10. Valeri CR, Cassidy G, Khuri S, et al. Hypothermia induced reversible platelet dysfunction. *Ann Surg* 1987; 205:175.
11. Plasma Consensus Panel. Fresh frozen plasma: Indications and risks. *JAMA* 1985; 253:551.
12. Chandra S, Groener A, Feldman F. Effectiveness of alternative treatments for reducing potential viral contaminants from plasma-derived products. *Thromb Res* 2002; 105(5):391–400.
13. Janson PA, Jubelirer SJ, Weinstein MJ, Deykin D. Treatment of the bleeding tendency in uremia with cryoprecipitate. *N Engl J Med* 1980; 303:1319.
14. Wolf JS, Stoller ML. The physiology of laparoscopy: basic principles, complications and other considerations. *J Urol* 1994; 152:294–302.
15. Puri GD, Singh H. Ventilatory effects of laparoscopy under general anaesthesia. *Br J Anaesth* 1992; 68:211–213.
16. Tolksdorf W, Strang CM, Schippers E, et al. The effects of the carbon dioxide pneumoperitoneum in laparoscopic cholecystectomy on postoperative spontaneous respiration. *Anesthetist* 1992; 41:199–203.
17. Scott DB, Julian DG. Observations on cardiac arrhythmias during laparoscopy. *Br Med J* 1972; 1:411–413.
18. Alijani A, Cuschieri A. Abdominal wall lift systems in laparoscopic surgery: gasless and low-pressure systems. *Semin Laparosc Surg* 2001; 8(1):53–62.
19. Ferri FF. Ascites. Practical guide to the care of the medical patient. Differential diagnosis. 5th ed. Chapter 2. Mosby, Inc., 2001:26.
20. Runyon BA. Care of the patients with ascites. *N Engl J Med* 1994; 330:339.
21. Tsivian A, Sidi AA. Port site metastases in urological laparoscopic surgery. *J Urol* 2003; 169(4):1213–1218.
22. Steinert R, Lippert H, Reymond MA. Tumor cell dissemination during laparoscopy: prevention and therapeutic opportunities. *Dig Surg* 2002; 19(6):464–472.

23. Wang PH, Yuan CC, Lin G, Ng HT, Chao HT. Risk factors contributing to early occurrence of port site metastases of laparoscopic surgery for malignancy. *Gynecol Oncol* 1999; 72(1):38–44.
24. Flegal KM, Carroll MD, Ogden CL, Johnson CL. Prevalence and trends in obesity among US adults, 1999–2000. *JAMA* 2002; 288:1723–1727.
25. Steinbrook R. Surgery for severe obesity. *N Engl J Med* 2004; 350(11):1075–1079.
26. Wittgrove AC, Clark GW, Schubert KR. Laparoscopic gastric bypass, Roux-en-Y: and results in 75 patients with 3–30 months follow-up. *Obes Surg* 1997; 6:500–504.
27. Belachew M, Legrand M, Vincent V, Lismonde M, LeDocte N, Deschamps V. Laparoscopic adjustable gastric banding. *World J Surg* 1998; 22:955–963.
28. Podnos YD, Jimenez JC, Wilson SE, Stevens CM, Nguyen NT. Complications after laparoscopic gastric bypass: a review of 3464 cases. *Arch Surg* 2003; 138(9):957–961.
29. Fugita OE, Chan DY, Roberts WW, Kavoussi LR, Jarrett TW. Laparoscopic radical nephrectomy in obese patients: outcomes and technical considerations. *Urology* 2004; 63(2):247–252.
30. Doublet J, Belair G. Retroperitoneal laparoscopic nephrectomy is safe and effective in obese patients: a comparative study of 55 procedures. *Urology* 2000; 56(1):63–66.
31. Fazeli-Matin S, Gill IS, Hsu TH, Sung GT, Novick AC. Laparoscopic renal and adrenal surgery in obese patients: comparison to open surgery. *J Urol* 1999; 162(3 Pt 1):665–669.
32. Kuo PC, Plotkin JS, Stevens S, Cribbs A, Johnson LB. Outcomes of laparoscopic donor nephrectomy in obese patients. *Transplantation* 2000; 69(1):180–182.
33. Jacobs SC, Cho E, Dunkin BJ, et al. Laparoscopic nephrectomy in the markedly obese living renal donor. *Urology* 2000; 56(6):926–929.
34. Bhayani SB, Pavlovich CP, Strup SE, et al. Laparoscopic radical prostatectomy: a multi-institutional study of conversion to open surgery. *Urology* 2004; 63(1):99–102.
35. El-Feel A, Davis JW, Deger S, et al. Laparoscopic radical prostatectomy — an analysis of factors affecting operating time. *Urology* 2003; 62(2):314–318.
36. Dhoste K, Lacoste L, Karayan J, Lehuède MS, Thomas D, Fuscuardi J. Haemodynamic and ventilatory changes during laparoscopic cholecystectomy in elderly ASA III patients. *Can J Anaesth* 1996; 43(8):783–788.
37. Bingener J, Richards ML, Schwesinger WH, Strodel WE, Sirinek KR. Laparoscopic cholecystectomy for elderly patients: gold standard for golden years? *Arch Surg* 2003; 138(5):531–535; discussion 535–536.
38. Senagore AJ, Madbouly KM, Fazio VW, Duepre HJ, Brady KM, Delaney CP. Advantages of laparoscopic colectomy in older patients. *Arch Surg* 2003; 138:252–256.
39. Law WL, Chu KW, Tung PH. Laparoscopic colorectal resection: a safe option for elderly patients. *J Am Coll Surg* 2002; 195(6):768–773.
40. Hsu TH, Su LM, Ratner LE, Kavoussi LR. Laparoscopic donor nephrectomy in the elderly patient. *Urology* 2002; 60(3):398–401.
41. Fornara P, Doehn C, Frese R, Jocham D. Laparoscopic nephrectomy in young-old, old-old, and oldest-old adults. *J Gerontol A Biol Sci Med Sci* 2001; 56(5):M287–M291.

LAPAROSCOPIC SURGERY DURING PREGNANCY

Michael D. Rollins and Raymond R. Price

Intermountain Healthcare/Salt Lake Clinic, Salt Lake City, Utah, U.S.A.

- INTRODUCTION
- ANATOMIC AND PHYSIOLOGIC CONSIDERATIONS
 - Uterus
 - Hemodynamics
 - Respiratory
 - Coagulation
 - Biochemical
- SPECIAL CONSIDERATIONS
 - Anesthesia
 - Radiological Issues
 - Timing of Surgery
 - Abdominal Insufflation/Exposure
 - Maternal and Fetal Monitoring
- ADVANTAGES OF LAPAROSCOPIC SURGERY
- SAFETY OF LAPAROSCOPY
- NONGYNECOLOGIC LAPAROSCOPIC PROCEDURES
 - Cholecystectomy
 - Appendectomy
 - Adrenalectomy
 - Splenectomy
 - Ureterolithotomy
 - Nephrectomy
- COMMON GYNECOLOGIC LAPAROSCOPIC PROCEDURES
 - Adnexal Mass and Adnexal Torsion
- RECOMMENDATIONS
- SUMMARY
- REFERENCES

INTRODUCTION

Surgical intervention in the gravid patient presents a dilemma in which the surgeon must weigh the risks and benefits not only to the mother but also to the fetus. Approximately one in 500 to one in 635 women will require nonobstetrical abdominal surgery during pregnancy (1,2). Acute appendicitis, cholecystitis, and intestinal obstruction are the three most common nonobstetrical emergencies requiring surgery during pregnancy (1). Other conditions requiring surgical intervention during pregnancy include symptomatic cholelithiasis, adrenal tumors, hematological disorders that involve the spleen, ovarian cysts, adnexal mass or torsion, heterotopic pregnancy, and abdominal pain of unknown etiology.

Complications following intra-abdominal surgery during pregnancy have been attributed to disease severity and delay in diagnosis rather than to the operative procedure itself (3,4). Common reasons for this delay include the patient and physician attributing signs and symptoms of disease to pregnancy, anatomic alterations of the gravid abdomen masking classic findings of diseases, and nonoperative management of patients due to concern of endangering the fetus with diagnostic and therapeutic procedures.

Laparoscopy has improved dramatically since its advent, resulting in changes to the operative management of several disease processes. Although pregnancy was once considered an absolute contraindication to laparoscopic surgery, it is now being performed with increasing frequency. Significant experience has accrued with laparoscopy during pregnancy to rule out ectopic pregnancy and to evaluate adnexal masses in the gynecologic literature with most patients having normal intrauterine pregnancies.

Regardless of the trimester in which laparoscopy was performed, there have not been increases in fetal loss or adverse long-term outcomes (5–7).

These experiences prompted general surgeons to begin offering laparoscopic appendectomy and cholecystectomy to pregnant patients in 1991 (8–10). Multiple retrospective studies have found no significant differences in birth weight, gestational duration, intrauterine growth restriction, infant death, or fetal malformation when comparing open to laparoscopic procedures during pregnancy (11–13). Laparoscopy for nonobstetrical abdominal conditions during pregnancy is rapidly becoming the

Regardless of the trimester in which laparoscopy was performed, there have not been increases in fetal loss or adverse long-term outcomes.

preferred approach, as maternal and fetal outcomes are generally excellent following surgery.

ANATOMIC AND PHYSIOLOGIC CONSIDERATIONS

Uterus

Many anatomical and physiologic changes occur during pregnancy altering the presentation of pathologic conditions (Table 1). The fundus of the uterus is generally located at the umbilicus at 20 weeks gestation and just inferior to the xiphoid process at 36 weeks (Fig. 1). This leads to displacement of the intra-abdominal organs, thus altering the location of abdominal pain and tenderness found with certain conditions such as acute appendicitis (14). In addition, while lying in the supine position, the uterus may compress the inferior vena cava and aorta causing a decrease in venous return to the heart and a decrease in placental perfusion, respectively.

It is important to place the gravid patient in the dependent position to shift the uterus off of the inferior vena cava and the aorta in order to avoid maternal hypotension and decreased placental perfusion during surgery.

The changing fundal height must be remembered and evaluated before accessing the abdominal cavity for laparoscopic procedures (Fig. 2). By altering the location of initial abdominal access according to fundal height and using maneuvers to elevate the abdominal wall during insertion, either the Hasson technique or Verres needle may be performed safely (12,13,15).

Initial placement of the Verres needle or trocar into the left subcostal region may be necessary as the uterus enlarges in the second and third trimesters (16,17). Ancillary trocars are then inserted under direct visualization, modifying their typical location according to the size of the uterus (18).

Hemodynamics

Many profound physiologic changes occur in the cardiovascular system during pregnancy. Blood volume expands by 30% to 40%. The expanded blood volume during pregnancy and the direct ionotropic effects of estrogen lead to an increased heart rate and stroke volume (19). Heart rate begins to increase at the fifth week of gestation and continues to rise until the 32nd week, at which time it is approximately 15% above non-pregnant values. Cardiac output increases by 30% to 50% at the end of the second

It is important to place the gravid patient in the dependent position to shift the uterus off of the inferior vena cava and the aorta in order to avoid maternal hypotension and decreased placental perfusion during surgery.

Initial placement of the Verres needle or trocar into the left subcostal region may be necessary as the uterus enlarges in the second and third trimesters. Ancillary trocars are then inserted under direct visualization, modifying their typical location according to the size of the uterus.

TABLE 1 ■ Normal Maternal Physiologic and Biochemical Changes

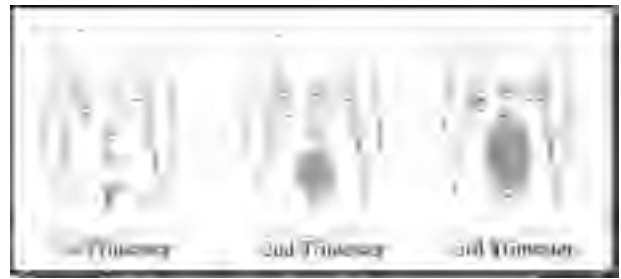
System	Increased	Decreased
Cardiovascular	Blood volume Cardiac output Lower extremity venous pressure	Peripheral vascular resistance
Respiratory	Minute ventilation	Functional residual capacity Total lung capacity
Gastrointestinal/ Hepatobiliary	Alkaline phosphatase Portal venous pressure Bile cholesterol saturation	Gastric, small intestine, colonic motility Gallbladder emptying
Hematologic	Red blood cell mass White blood cells Factors VII, VIII, X, XII, fibrinogen	Albumin Hematocrit Platelets
Renal	Glomerular filtration rate Oreatinine clearance Renin	Blood-urea-nitrogen Serum Cr Sodium
Endocrine	Aldosterone Free cortisol	

Source: From Refs. 19, 20, 25, 26, 28, 31,34.

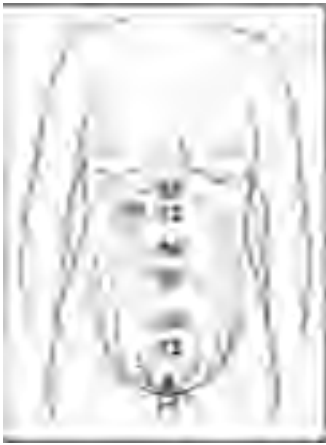

FIGURE 1 ■ Fundal height by gestational age in weeks. Source: From Ref. 139.

FIGURE 2 ■ Trocar placement for laparoscopic appendectomy changes by size of gravid uterus. Numbers indicate the order of insertion.



trimester with most of the increased cardiac output directed to the uterus and placenta. Maternal position largely affects cardiac output later in pregnancy. When lying in the supine position, the enlarged uterus compresses the inferior vena cava leading to a decrease in venous return and thereby a decrease in cardiac output (20). Compared to the lateral recumbent position, patients lying supine may experience a 10% to 30% decrease in cardiac output (21,22).

In nonpregnant patients, a 25% decrease in cardiac index is seen with induction of anesthesia with a further decrease to 50% normal after CO₂ insufflation and an increase in mean arterial pressure and systemic vascular resistance (23). A recent study from the Brigham and Women's Hospital demonstrated these same hemodynamic changes in pregnant patients undergoing laparoscopic surgery (24). There was no exaggerated cardiovascular response to CO₂ pneumoperitoneum during pregnancy as some have speculated might occur.

Respiratory

Alterations in the chest wall configuration and the diaphragm during pregnancy cause a restrictive pulmonary physiology. Minute ventilation increases throughout pregnancy to become almost 50% above normal at term (25). Pregnant patients are vulnerable to arterial oxygen desaturation secondary to the decreased residual lung volume and functional residual capacity caused by upward displacement of the diaphragm (26).

The upward displacement of the diaphragm is increased by CO₂ pneumoperitoneum. This has led to the recommendation that intra-abdominal pressures should be minimized during laparoscopic surgery with pressures less than 12 mmHg (27).

However, other authors have stressed the importance of adequate visualization of the intra-abdominal cavity and have used pressures up to 15 mmHg without increasing the incidence of adverse effects to either the mother or the fetus (12,13).

Coagulation

Pregnancy is considered a hypercoagulable state increasing the risk of thromboembolic phenomena due to increased venous stasis, vessel wall injury, and changes in the coagulation cascade. The effects of estrogen cause increased synthesis of clotting factors, particularly factors VII, VIII, X, and XII (28). Intra-abdominal vascular stasis secondary to inferior vena cava compression from the uterus also increases the risk of deep venous thrombosis during pregnancy with an incidence of approximately 0.1% to 0.2% (29).

CO₂ pneumoperitoneum causes a further increase in venous stasis, which is already present during pregnancy. Jorgensen et al. (30) demonstrated that abdominal insufflation up to 12 mmHg caused a statistically significant decrease in femoral blood flow velocity and an increase in femoral vein diameter, which could not be completely reversed with either intermittent pneumatic compression devices or intermittent electric calf stimulators.

Although pregnancy increases the synthesis of clotting factors, platelets normally decrease during pregnancy, possibly secondary to increased destruction (31,32). Approximately 8% of gravid patients will develop gestational thrombocytopenia with platelet counts between 70,000 and 150,000/mm³. These patients do not appear to experience increased complications and their platelet counts generally normalize by 1–2 weeks postpartum (33).

The upward displacement of the diaphragm is increased by CO₂ pneumoperitoneum. This has led to the recommendation that intra-abdominal pressures should be minimized during laparoscopic surgery with pressures less than 12 mmHg.

Biochemical

Normal variations in laboratory values occur during pregnancy (Table 1). The gravid patient experiences a physiologic anemia secondary to an increase in plasma volume, which exceeds the increase in red blood cell mass. This physiologic anemia of pregnancy reaches its nadir at 30–34 weeks' gestation. The pregnant state also causes a mild dilutional hypoalbuminemia with albumin levels at term being 25% lower than nonpregnant values (20). Alkaline phosphatase is elevated secondary to the effects of estrogen although other liver function tests remain normal. Alkaline phosphatase normally rises during the third trimester reaching values of 2–4 times greater than seen in nonpregnant patients. Leukocytosis is a normal result of pregnancy. During the first and second trimesters, white blood cell counts normally range from 6000 to 16,000 cells/mm³ (34). Furthermore, marked changes in adrenocortical function are associated with pregnancy, resulting in increased levels of aldosterone, cortisol, and free cortisol (20).

SPECIAL CONSIDERATIONS

Anesthesia

As many as 2% of pregnant women in the United States undergo anesthesia for surgical procedures unrelated to delivery (35,36). Anesthetic management strategies focus predominantly on the alterations in maternal physiology from anesthesia. Although teratogenic effects of anesthesia may be of concern to patients and physicians, no anesthetic agents have been found to definitively cause fetal malformations (37).

Gravid patients normally experience a compensatory respiratory alkalosis with a PaCO₂ ranging from 28 to 32 mmHg and a resultant pH of approximately 7.44 (38). Fetal PaCO₂ is directly related to maternal PaCO₂. With a rise in maternal PaCO₂, fetal heart rate increases reflecting fetal distress (39).

Pregnant sheep models have been used to demonstrate that not only periods of severe hypercarbia (PaCO₂ >60 mmHg) but also severe hypocapnia (PaCO₂ <29 mmHg) reduce uterine blood flow leading to fetal distress (40). These changes have not been documented during laparoscopic surgery with appropriate anesthetic monitoring and maintenance of normal maternal pH.

Maintenance of uteroplacental blood flow is central to fetal well-being with fetal asphyxia resulting from a decrease in uteroplacental blood flow. The pharmacologic agent of choice for maintaining maternal blood pressure is ephedrine. Other vasopressors such as alpha-agonists, dopamine, and epinephrine induce uterine artery vasoconstriction resulting in decreased uterine blood flow and should be avoided (38).

Other anesthetic considerations in the gravid patient are alterations in free drug concentrations as a result of expanded blood volume, low albumin, and increased alpha 1-glycoprotein. There is an increased risk of aspiration secondary to distortion of the gastric and pyloric anatomy from the gravid uterus and the hormonally induced decrease in lower esophageal sphincter tone (38).

Radiologic Issues

Fetal safety during diagnostic imaging is a primary goal for clinicians and patients. Significant radiation exposure may lead to chromosomal mutations, neurologic abnormalities, mental retardation, and an increased risk of childhood leukemia. For acute indications, the benefits of the mother usually outweigh the small fetal risk. Radiation dosage is the most important risk factor, but fetal age at exposure is also important (41,42). Radiological exposure is measured using units of either rad or centiGray (1 rad = 1 cGy). Fetal mortality is the greatest when exposure occurs within the first week of conception prior to oocyte implantation (41–43). The recommended radiation dose from approximately the first week of conception through week 25 is less than 5–10 rad (44). The most sensitive time period for central nervous system teratogenesis is between 10 and 17 weeks' gestation and nonurgent X-rays should be avoided during this time. In later pregnancy, the concern shifts from teratogenesis to increasing the risk of childhood hematologic cancer. The background incidence of childhood cancer and leukemia is approximately 0.2% to 0.3%. Radiation may increase that incidence by 0.06% per 1 cGy delivered to the fetus (44). Exposure of the fetus to 0.5 rad increases the risk of spontaneous abortion, major malformations, mental retardation, and childhood malignancy to one additional case in 6000 above baseline risk (41). Recommendations are that fetal risk is considered negligible at 5 rad or less and that the risk of malformation is

Pregnant sheep models have been used to demonstrate that not only periods of severe hypercarbia (PaCO₂ >60 mmHg) but also severe hypocapnia (PaCO₂ <29 mmHg) reduce uterine blood flow leading to fetal distress. These changes have not been documented during laparoscopic surgery with appropriate anesthetic monitoring and maintenance of normal maternal pH.

TABLE 2 ■ Fetal Radiation Exposure from Diagnostic Imaging Studies

Study	Decreased
Chest radiograph	<0.001
Abdominal series	0.245
Pelvic radiograph	0.04
Upper gastrointestinal series	0.05–0.1
Barium enema	0.3–4
HIDA scan	0.15
Chest computed tomography scan	0.01–0.2
Abdominal computed tomography scan	0.8–3
Pelvic computed tomography scan	2.2

Source: From Refs. 29, 41, 140.

significantly increased at doses above 15 rad (29). The accepted cumulative dose of ionizing radiation during pregnancy is 5 rad with no single diagnostic study exceeding this maximum (Table 2) (41).

- The American College of Radiology has stated that pregnant patients may undergo magnetic resonance imaging at any stage of pregnancy provided that the radiologist has a discussion with the patient regarding the risks of the study, the study cannot be delayed until delivery, and no other imaging modalities can provide the necessary information (47).
- The American College of Radiology has stated that pregnant patients may undergo magnetic resonance imaging at any stage of pregnancy provided that the radiologist has a discussion with the patient regarding the risks of the study, the study cannot be delayed until delivery, and no other imaging modalities can provide the necessary information (47).

Timing of Surgery

Operative intervention may be performed in any trimester if warranted by the patient's condition. Traditional recommendations, which were based on experiences with open surgical procedures during pregnancy, were to delay surgery until the second trimester if possible. A spontaneous abortion rate of 12% has been reported following open cholecystectomy in the first trimester, while 40% of patients undergoing open cholecystectomy in the third trimester experience preterm labor (48). Although surgery during the second trimester has generally been regarded as the safest due to a low rate of preterm delivery and a theoretically low rate of teratogenesis (49), one series reported a 5.6% risk of spontaneous abortion following open cholecystectomy (48). This experience has not been reproduced in the laparoscopic literature.

Recent large case series and one large retrospective review have demonstrated that pregnant patients may undergo laparoscopic surgery safely in any trimester without increased risk to the mother or fetus (11–13,50,51).

Additionally, delaying surgical intervention in patients with symptomatic gallstone disease during pregnancy may lead to further complications of gallstone disease such as acute cholecystitis and gallstone pancreatitis (50,52–54), which can lead to higher spontaneous abortion rates and preterm labor.

It has been suggested that the gestational age limit for successful completion of laparoscopic surgery during pregnancy is 26–28 weeks (55). This has been refuted by several studies in which laparoscopic cholecystectomy and appendectomy have been successfully performed late in the third trimester (12,13,16).

Abdominal Insufflation/Exposure

CO₂ is the primary gas used to create a pneumoperitoneum for laparoscopy in non-pregnant and pregnant patients. Gaseous carbon dioxide exchange occurs with intraperitoneal insufflation. There has been much concern in the past over the effects of CO₂ pneumoperitoneum on the fetus. While studies have demonstrated that fetal acidosis does occur in animal models during CO₂ pneumoperitoneum, there have been no long-term adverse effects noted (56–58). Furthermore, there is no evidence to support detrimental effects resulting from CO₂ pneumoperitoneum in humans (55). In the pregnant ewe model, observation has been made that CO₂ pneumoperitoneum

Recent large case series and one large retrospective review have demonstrated that pregnant patients may undergo laparoscopic surgery safely in any trimester without increased risk to the mother or fetus.

CO₂ insufflation has been used almost exclusively for abdominal exposure in the reported cases of successful laparoscopy during pregnancy. Pneumoperitoneum created with CO₂ appears to be safe when abdominal pressures are kept below 15 mmHg and physiologic end tidal CO₂ levels are maintained (30–40 mmHg).

Imperative to fetal well-being during laparoscopy is tight control of maternal hemodynamic and respiratory function in order to maintain a normal maternal pH.

results in a PaCO₂ to ETCO₂ gradient of 16–25 mmHg leading to fetal hypercapnia, hypertension, acidosis, and tachycardia (56,59). Although several studies have demonstrated that the fetus is slightly more acidotic than the mother and that EtCO₂ values lag behind corrections in PaCO₂, others have observed no change in fetal PaCO₂ when maternal sheep PaCO₂ was maintained within 37 ± 3.3 mmHg following CO₂ insufflation as well as a good correlation between PaCO₂ and EtCO₂ (56,58,60–62).

CO₂ insufflation has been used almost exclusively for abdominal exposure in the reported cases of successful laparoscopy during pregnancy. Pneumoperitoneum created with CO₂ appears to be safe when abdominal pressures are kept below 15 mmHg and physiologic end tidal CO₂ levels are maintained (30–40 mmHg) (12,13).

While there is no conclusive evidence in humans that CO₂ pneumoperitoneum is detrimental to the fetus, the concern has led to a search for alternative means of intra-abdominal exposure during laparoscopy. Gasless laparoscopy has been described using a mechanical abdominal wall lifting device and has been used for the management of ovarian cysts during early pregnancy with good success (63).

Maternal and Fetal Monitoring

Imperative to fetal well-being during laparoscopy is tight control of maternal hemodynamic and respiratory function in order to maintain a normal maternal pH.

Controversy exists over the use of maternal PaCO₂ versus EtCO₂ for monitoring maternal acid/base status as a result of conflicting animal data regarding the effects on the fetus as mentioned above. Some have argued that the pregnant ewe model may not be appropriate for the study of the effects of the pneumoperitoneum on maternal acidosis and have demonstrated that capnography adequately reflects maternal acid/base status in humans (64). Furthermore, several large studies have observed that EtCO₂ measurements may be used to monitor pregnant women undergoing laparoscopy safely and effectively without adverse fetal outcomes (12,13,55).

The fetus must also be monitored for signs of distress. One sign that may be easily detected is an increased fetal heart rate. While intraoperative fetal monitoring was once thought to be the most accurate method to detect fetal distress during laparoscopy, the literature to date in which intraoperative fetal monitoring was employed has not reported any abnormalities of fetal heart rate either during the procedure or postoperatively (50,65). This has led to the recommendation of preoperative and postoperative monitoring of the fetal heart rate, with no increased fetal morbidity having been reported (12,13).

ADVANTAGES OF LAPAROSCOPIC SURGERY

The most important benefit of laparoscopy is probably the prevention of undue delay in diagnosis (17). Advantages of laparoscopy in the pregnant patient:

- Decreased fetal depression due to lessened postoperative narcotic requirements (9,10,66,67)
- Lower risk of wound complications (8,9,68)
- Diminished postoperative maternal hypoventilation (9,10)
- Shorter hospital stays
- Decreased risks of thromboembolic events due to early mobilization
- Better intra-abdominal visualization reducing the need for uterine manipulation and thereby reducing the risk of uterine irritability (17)
- Decreased uterine irritability results in lower rates of spontaneous abortion and preterm delivery (69)

SAFETY OF LAParoscopy

Laparoscopic surgery during pregnancy for the management of both obstetrical and nonobstetrical disease is being performed with increasing frequency.

Numerous clinical reports have demonstrated that pregnant patients may undergo laparoscopic surgery safely in any trimester without an increase in maternal or fetal morbidity or mortality compared with open surgery.

A review of the Swedish Health Registry from 1973 to 1993, which included pregnant women who had undergone nonobstetric operations between weeks 4 and 20 of pregnancy, compared 2233 laparoscopic procedures to 2491 open procedures and found

Numerous clinical reports have demonstrated that pregnant patients may undergo laparoscopic surgery safely in any trimester without an increase in maternal or fetal morbidity or mortality compared with open surgery.

no significant differences in birth weight, gestational duration, intrauterine growth restriction, infant death, or fetal malformation (11).

A nationwide, multicenter, retrospective survey was carried out in Israel, that included all of the operations performed on pregnant women from 1990 to 2000. One hundred and ninety-two laparoscopies (first trimester 141, second trimester 46, third trimester 5) and 197 laparotomies (first trimester 63, second trimester 110, third trimester 24) were performed. Surgical procedures were performed for adnexal disease, appendicitis, cholecystitis, heterotopic pregnancy, Crohn's colitis (hemicolectomy), and bowel obstruction. No statistically significant differences were observed between laparoscopy and laparotomy in the prevalence of abortion, preterm labor, preterm delivery, intrauterine growth restriction, or fetal anomalies. Furthermore, immediate postoperative complications were lower in the laparoscopy group, including fever, pulmonary embolus, and premature contractions (70).

Short-term outcomes following laparoscopic surgery during pregnancy have been almost uniformly good. However, there is a paucity of data evaluating the long-term effects on the resultant children. To this end, a recent study was conducted that followed, from one to eight years, the children of 11 patients who underwent laparoscopy in their 16–28th weeks of pregnancy. Laparoscopic procedures included appendectomy, cholecystectomy, and lysis of adhesions. No delay in growth or development was experienced by the children (71).

NONGYNECOLOGIC LAPAROSCOPIC PROCEDURES

Cholecystectomy

Hormonal changes that occur during pregnancy predispose patients to gallstone formation. Progesterone inhibits cholecystokinin resulting in decreased gallbladder emptying and increased gallbladder residual volume. Both estrogen and progesterone lead to biliary cholesterol hypersaturation, which increases the risk of forming gallstones (72). During obstetrical ultrasound, 2% to 4% of women are found to have asymptomatic gallstones, while symptomatic disease presents in only 5–10 of 10,000 pregnancies (1). Symptoms of biliary disease are essentially the same in the pregnant patient as in the nonpregnant patient. Most liver function tests are unaffected by pregnancy and remain useful in the diagnosis of biliary disease in the gravid patient with abdominal pain. However, alkaline phosphatase, which is normally elevated during pregnancy, is less helpful in making the diagnosis of biliary disease (72). As in nonpregnant patients, ultrasound evaluation is the diagnostic imaging technique of choice for cholelithiasis (73).

Laparoscopic cholecystectomy continues to be the most common laparoscopic general surgical procedure performed during pregnancy (49). Some recommend that the initial management of symptomatic cholelithiasis should be nonoperative during pregnancy (74). However, this management strategy has been associated with a high recurrence of symptoms leading to hospitalization (50). In addition, nonoperative management of symptomatic cholelithiasis increases the risk of gallstone pancreatitis up to 13%, which leads to fetal loss in 10% to 60% of cases (75–77). Nonoperative management has also been associated with higher incidences of spontaneous abortions, preterm labor, and preterm delivery compared to those undergoing cholecystectomy (69). Arguments for early laparoscopic cholecystectomy include the high incidence of recurrence of symptoms in patients presenting with biliary colic, the potential complication of acute cholecystitis, and the severe complication of gallstone pancreatitis. One series reported a 57% symptom recurrence rate in patients with biliary colic managed nonoperatively as well as a 23% complication rate of acute cholecystitis and gallstone pancreatitis (50). The risk of relapse in pregnant patients with symptomatic gallstones is 92% if the patient presents in the first trimester, 64% when presenting in the second trimester, and 44% in those presenting in the third trimester (78). In a review by Graham et al. (65), there was a decreased risk of spontaneous abortion during the first trimester and decreased risk of preterm labor in the third trimester in women undergoing laparoscopic cholecystectomy for symptomatic cholelithiasis.

While the nonoperative management of symptomatic cholelithiasis increases the risk of gallstone pancreatitis, symptomatic choledocholithiasis remains relatively uncommon during pregnancy (79,80). For pregnant patients with complicated gallstone disease, endoscopic retrograde cholangiopancreatography with sphincterotomy and subsequent laparoscopic cholecystectomy offers a safe and effective therapeutic option (81,82).

Appendectomy

The diagnosis of acute appendicitis during pregnancy remains a difficult one. Both anatomic and physiologic changes that occur during pregnancy often mask the classic signs and symptoms. Although the single most reliable symptom of appendicitis in pregnant patients is right lower quadrant pain (83), this may be highly variable. Throughout pregnancy, the appendix migrates upward in the right lower and upper quadrants. This migration may shift the point of maximal tenderness superiorly and laterally, which in the case of a retrocecal appendix may cause back or flank pain leading to a misdiagnosis of urinary tract infection, nephrolithiasis, or pyelonephritis (72,84). In the majority of patients fever is not present and leukocytosis, which is normal during pregnancy, may confuse the clinical picture (34,72).

Appendicitis is the most common acute general surgical condition during pregnancy, with an incidence of appendectomy during pregnancy of one in 1500 to one in 3000 (1,2,85). When uncomplicated, appendicitis results in a 1.5% fetal loss rate. Perforation, which occurs in 10% of cases, increases the fetal loss rate to 35% and may lead to preterm labor and premature delivery in as many as 40% of patients (1,69).

Because of the difficulty in clinically diagnosing acute appendicitis, the negative appendectomy rate is much higher in the pregnant than nonpregnant patient, with misdiagnosis rates as high as 22% to 55% (15,86). The higher incidence of negative appendectomy in the gravid patient is likely due both to the anatomic and physiologic changes that occur during pregnancy as well as attempts to prevent perforation, since perforation results in high maternal and fetal morbidity and mortality. Up to one-quarter of pregnant women with appendicitis develop appendiceal perforation, and appendiceal rupture has been reported to occur twice as often in the third trimester (69%) as in the first and second trimesters (87–89). A 66% incidence of perforation has been reported in patients when surgery was delayed by more than 24 hours and a 0% incidence when patients were taken to surgery within 24 hours of presentation (90).

Many authors rely heavily on clinical judgment for the diagnosis of acute appendicitis in the gravid patient. However, some studies suggest that the use of helical computed tomography that exposes the fetus to 300 mrad and ultrasonography are highly accurate for diagnosing acute appendicitis during pregnancy and may help reduce the negative appendectomy rate (91,92). In a case series of 42 women with suspected appendicitis during pregnancy, graded compression ultrasonography was 100% sensitive, 96% specific, and 98% accurate in diagnosing acute appendicitis (92).

Laparoscopic adrenalectomy is being performed with increasing frequency in nonpregnant patients and is considered by some as the preferred approach.

Adrenalectomy

Laparoscopic adrenalectomy is being performed with increasing frequency in nonpregnant patients and is considered by some as the preferred approach (93).

Laparoscopic adrenalectomy for pheochromocytoma has been demonstrated to provide as much hemodynamic stability as open adrenalectomy during tumor manipulation with the added benefits of laparoscopic procedures (94). Nine cases of laparoscopic adrenalectomy during pregnancy have been reported in the literature for primary hyperaldosteronism, Cushing's syndrome, and pheochromocytoma (95–101). The retroperitoneal approach was used in one patient (97), whereas a transperitoneal approach was performed in the other eight.

Pheochromocytomas are responsible for 0.05% to 0.1% of all causes of hypertension and are rare during pregnancy with less than 200 cases reported in the literature (102,103). Although the most common symptoms in nonpregnant patients are hypertension, headaches, sweating, and palpitations, hypertension and headaches seem to predominate during pregnancy. While these tumors are rarely the cause of hypertension during pregnancy, if unrecognized or untreated they pose serious risks to both the mother and fetus. Maternal mortality rates have been reported in 17% to 48% and fetal demise in 26% to 54% of untreated cases (104–106). With early detection and treatment these mortality rates may be dramatically improved, with reported lows of 0% to 15% (105–107). Unfortunately, antenatal diagnosis is made in only 53% of cases (106).

Pheochromocytoma should be considered in the differential diagnosis of any pregnant patient developing hypertension prior to the 20th week of gestation. The diagnosis of pheochromocytoma can be made by measuring urinary catecholamines as with nonpregnant patients because these levels are unaffected by the pregnant state. Pre-eclampsia is high on the differential of hypertension during pregnancy but may be distinguished from pheochromocytoma by the presence of proteinuria, oliguria, and thrombocytopenia in the third trimester (108). Ultrasound and magnetic resonance imaging are the preferred localization studies.

Successful treatment of pheochromocytomas requires a multidisciplinary approach including the obstetrician, endocrinologist, anesthesiologist, and surgeon. Once the diagnosis is established, pharmacologic therapy should be started immediately. Alpha-adrenergic blockade with phenoxybenzamine is used to control hypertension and, if necessary, selective beta-blockade with metoprolol or atenolol is used to control tachycardia during pregnancy (103). Control of hypertension is vital in these patients because severe hypertension can result in uteroplacental insufficiency, early separation of the placenta, and fetal death. Phenoxybenzamine decreases the systemic peripheral vascular resistance and will allow for intravascular volume replacement before surgery. If diagnosed in the third trimester, removal of the tumor is delayed until after delivery if blood pressure can be controlled medically (100,109). To date, there have been four case reports of laparoscopic adrenalectomy for pheochromocytoma in the pregnant patient which were performed between 13 and 20 weeks gestation (99–101). General guidelines for laparoscopy during pregnancy were followed including dependent positioning without significant alterations in the standard technique used for nonpregnant patients. In each case, the mother delivered a healthy infant.

Laparoscopic splenectomy has been shown to be advantageous when compared to open splenectomy and is comparable to open splenectomy in terms of safety and efficacy in nonpregnant patients.

Splenectomy

Laparoscopic splenectomy has been shown to be advantageous when compared to open splenectomy and is comparable to open splenectomy in terms of safety and efficacy in nonpregnant patients (110).

Some authors advocate laparoscopic splenectomy as the procedure of choice for hematological conditions in nonpregnant patients (111). Autoimmune thrombocytopenic purpura is the most common autoimmune disorder encountered in the pregnant patient (112). ITP appears during pregnancy with an incidence of 1–2 cases per 10,000 pregnancies (113). No consensus has been reached as to the management of ITP during pregnancy. Maternal IgG antibodies cross the placenta leading to thrombocytopenia in the fetus and increased maternal platelet counts in response to treatment may not reliably predict fetal platelet counts. Maternal ITP may lead to intracerebral hemorrhage in the fetus or cause the fetus to experience life-threatening bleeding during the normal trauma of delivery. While immunoglobulin therapy is considered safe in pregnancy, it is expensive and steroid therapy may increase the incidence of pregnancy-induced hypertension, gestational diabetes, and infection (114).

Splenectomy has become the recommended treatment option during pregnancy for patients who are unresponsive to medical therapy (112,115). As more experience is obtained with splenectomy during pregnancy for ITP, surgery may play a larger role in the future as has happened with other procedures during pregnancy. To date, there have been four reported cases of laparoscopic splenectomy during pregnancy. The indications for surgery were refractory hematological disorders including antiphospholipid syndrome, hereditary spherocytosis, and autoimmune thrombocytopenia purpura (113,114,116,117). All patients did well postoperatively and delivered healthy infants.

Ureterolithotomy

Urolithiasis complicates one of 1500 pregnancies. Although there are metabolic and anatomic alterations during pregnancy that might predispose the pregnant patient to increased stone formation, urinary stones occur at similar rates in pregnant and nonpregnant patients (118). The modern approach to urolithiasis in pregnancy is initially conservative medical management (rest, hydration, analgesia, and antiemetics), as 70% to 80% of pregnant patients with symptomatic calculi will pass their stones. Patients with colic refractory to medical treatment, sepsis, obstruction of a solitary kidney, or social and psychological reasons may require a more aggressive approach (119,120).

Invasive therapy usually involves either (1) cystoscopy and stent placement with or without stone manipulation, (2) ureteroscopy and stone manipulation, or (3) placement of a percutaneous nephrostomy tube (118). Open surgery, while rarely indicated, is a viable alternative in selected patients. Premature delivery rates have been reported in 6.5%, 8.6%, and 11.9% of patients during the first, second, and third trimester, respectively (120). Extracorporeal shock wave lithotripsy and percutaneous nephrolithotomy are contraindicated in pregnancy.

Laparoscopic ureterolithotomy is considered a safe and reliable salvage intervention in nonpregnant patients using either a transperitoneal or retroperitoneoscopic approach (121,122). To date, there are no reports of laparoscopic ureterolithotomy during pregnancy.

Nephrectomy

The frequency of laparoscopic transperitoneal or retroperitoneoscopic nephrectomy for various diseases in nonpregnant patients has been increasing since its first report in 1991 (121). Although there are no reported cases of laparoscopic nephrectomy during pregnancy, it is possible that as experience with laparoscopy during pregnancy increases this may become a reasonable option.

COMMON GYNECOLOGIC LAPAROSCOPIC PROCEDURES

Adnexal Mass and Adnexal Torsion

The incidence of adnexal masses during pregnancy is 2% (123). Adnexal torsion, which is more common during pregnancy, occurs in about one in 1800 pregnancies (34,124). Most adnexal masses discovered during the first trimester of pregnancy are functional cysts and resolve spontaneously by the second trimester (18). Persistent masses are most commonly functional cysts or mature cystic teratomas, with the incidence of malignancy reported at 2% to 6% (125). Presenting symptoms of adnexal torsion include an abrupt onset of severe pain lateralized to the right or left lower quadrant of the abdomen, which is commonly associated with nausea and vomiting. Many pathologic diseases of the ovary and/or fallopian tube cause abnormal enlargement, which increases the risk of adnexal torsion. Prolonged torsion of the adnexa may lead to infarction of the fallopian tube and ovary, which if left untreated may ultimately lead to peritonitis and death (72). Complications from adnexal masses such as torsion, rupture, and hemorrhage requiring emergency surgery have been reported to occur in as high as 28% of patients, leading to adverse pregnancy outcomes including spontaneous abortion and preterm delivery in as many as 40% (126).

The two most common management strategies of adnexal mass during pregnancy are operative extirpation of the mass or expectant management (72). Multiple authors recommend expectant management of adnexal masses ≤ 6 cm with 82% to 94% of these resolving spontaneously (127,128). The high incidence of adverse pregnancy outcomes associated with emergency surgery as well as malignant potential has led some authors to recommend elective removal of all masses that persist until 16 weeks and are >6 cm (125,126). Torsion usually occurs between the 6th and 14th weeks of gestation (129). Current conservative management of adnexal torsion involves unwinding the adnexa and assessing its viability. Only the gangrenous adnexa needs complete removal of the adnexa (130). When an ovarian cyst is present, a complete ovarian cystectomy should be performed for histologic diagnosis (131). If rupture and bleeding occur, laparoscopic cystectomy and coagulation of the base is appropriate in the hemodynamically stable patient (72).

Laparoscopy has become the preferred approach for both the diagnosis and management of adnexal torsion (132). Ten percent to 15% of adnexal masses undergo torsion, and if diagnosed before tissue necrosis, adnexal torsion may be managed laparoscopically with adnexal-sparing laparoscopic detorsion, followed by progesterone therapy if the corpus luteum is removed (133,134). Laparotomy with salpingo-oophorectomy is required for necrosis and peritonitis (88). Previous case reports have demonstrated the safety of laparoscopic surgery performed during pregnancy for the management of adnexal torsion and adnexal mass with good outcomes for both the mother or fetus (131,135–140). Finally, a recent retrospective review, which included 88 pregnant women, examined the maternal and fetal outcomes following laparoscopy versus laparotomy for adnexal pathology in the first two trimesters of pregnancy and found no statistically significant increase in the rate of miscarriages, neonatal malformations, or preterm births between the two groups (17).

Laparoscopy has become the preferred approach for both the diagnosis and management of adnexal torsion.

RECOMMENDATIONS

More information has accumulated recently as laparoscopy has become more common during pregnancy. However, most of the data is found in case series and retrospective reviews, which limits the ability to provide absolute guidelines. Further controlled clinical studies are needed to clarify these guidelines, and revision may be necessary as new data appear. The current recommendations for laparoscopy during surgery are summarized in the following:

- Operative intervention may be performed in any trimester if warranted by the patient's condition.
- Pneumatic compression devices should be utilized.
- Fetal heart tones should be monitored pre- and postoperatively.
- Lead shielding and brief shots of fluoroscopy may be used judiciously.
- Either the Hasson or Verres technique may be used for initial abdominal cannulation depending on surgeon preference and level of comfort with each technique.
- Dependent positioning should be utilized to shift the uterus off of the inferior vena cava and the aorta.
- Pneumoperitoneum pressure should be kept between 10 and 15 mmHg.
- Obstetrics consultation should be obtained preoperatively.
- Maternal end tidal CO₂ should be maintained between 30 and 40 mmHg.
- Tocolytics should be used for perceived or documented uterine contractions.

SUMMARY

- Laparoscopy is being performed with increasing frequency during pregnancy for both obstetric and nonobstetric indications.
- While pregnancy was once considered an absolute contraindication to laparoscopy, numerous reports have demonstrated that laparoscopy may be performed safely in all trimesters of pregnancy without increased maternal or fetal morbidity or mortality.
- As laparoscopic techniques and instrumentation improve, it is likely that additional indications for laparoscopic surgery in the gravid patient will be identified.

REFERENCES

1. Kammerer WS. Nonobstetric surgery during pregnancy. *Med Clin North Am* 1979;63:1157–1164.
2. Kort B, Katz VL, Watson WJ. The effect of nonobstetric operation during pregnancy. *Surg Gynecol Obstet* 1993; 177:371–376.
3. Allen JR, Helling TS, Langenfeld M. Intraabdominal surgery during pregnancy. *Am J Surg* 1989; 158:567–569.
4. Mazze RI, Kallen B. Appendectomy during pregnancy: a Swedish registry study of 778 cases. *Obstet Gynecol* 1991; 77:835–840.
5. Samuelsson S, Sjoval A. Laparoscopy in suspected ectopic pregnancy. *Acta Obstet Gynecol Scand* 1972; 51:31–35.
6. Mazze RI, Kallen B. Reproductive outcome after anesthesia and operation during pregnancy: a registry study of 5405 cases. *Am J Obstet Gynecol* 1989; 161:1178–1185.
7. Thomas SJ, Brisson P. Laparoscopic appendectomy and cholecystectomy during pregnancy: six case reports. *JSL* 1998; 2:41–46.
8. Arvidsson D, Gerdin E. Laparoscopic cholecystectomy during pregnancy. *Surg Laparosc Endosc* 1991; 1:193–194.
9. Pucci RO, Seed RW. Case report of laparoscopic cholecystectomy in the third trimester of pregnancy. *Am J Obstet Gynecol* 1991; 165:401–402.
10. Weber AM, Bloom GP, Allan TR, et al. Laparoscopic cholecystectomy during pregnancy. *Obstet Gynecol* 1991; 78:958–959.
11. Reedy MB, Kallen B, Kuehl TJ. Laparoscopy during pregnancy: a study of five fetal outcome parameters with use of the Swedish Health Registry. *Am J Obstet Gynecol* 1997; 177:673–679.
12. Affleck DG, Handrahan DL, Egger MJ, et al. The laparoscopic management of appendicitis and cholelithiasis during pregnancy. *Am J Surg* 1999; 178:523–529.
13. Rollins MD, Chan KJ, Price RR. Laparoscopy for appendicitis and cholelithiasis during pregnancy: a new standard of care. *Surg Endosc* 2004; 18(2):237–41.
14. Hickey MS, Kiernan GJ, Weaver KE. Evaluation of abdominal pain. *Emerg Med Clin North Am* 1989; 7:437–452.
15. Lemaire BM, van Erp WF. Laparoscopic surgery during pregnancy. *Surg Endosc* 1997; 11:15–18.
16. Geisler JP, Rose SL, Mernitz CS, et al. Non-gynecologic laparoscopy in second and third trimester pregnancy: obstetric implications. *JSL* 1998; 2:235–238.
17. Soriano D, Yefet Y, Seidman DS, et al. Laparoscopy versus laparotomy in the management of adnexal masses during pregnancy. *Fertil Steril* 1999; 71:955–960.
18. Canis M, Rabischong B, Houille C, et al. Laparoscopic management of adnexal masses: a gold standard? *Curr Opin Obstet Gynecol* 2002; 14:423–428.
19. Gonik B. Intensive care monitoring of the critically ill pregnant patient. In: Creasy RK, Resnick R, eds. *Maternal-fetal Medicine: Principles and Practice*. Philadelphia: WB Saunders, 1989:845–874.
20. Gordon MC. Maternal physiology in pregnancy. In: Gabbe SG, Niebyl JR, Simpson JL, eds. *Obstetrics: Normal and Problem Pregnancies*. Philadelphia: Churchill Livingstone, 2002:63–91.
21. Elkayam UGN. Cardiovascular physiology of pregnancy. In: *Cardiac Problems in Pregnancy: Diagnosis and Management of Maternal and Fetal Disease*. Alan R Liss, New York, 1982:5–26.
22. Clark SL, Cotton DB, Pivarnik JM, et al. Position change and central hemodynamic profile during normal third-trimester pregnancy and post partum. *Am J Obstet Gynecol* 1991; 164:883–887.

23. Wahba RW, Beique F, Kleiman SJ. Cardiopulmonary function and laparoscopic cholecystectomy. *Can J Anaesth* 1995; 42:51–63.
24. Steinbrook RA, Bhavani-Shankar K. Hemodynamics during laparoscopic surgery in pregnancy. *Anesth Analg* 2001; 93:1570–1571, table of contents.
25. Hammond CB. The female reproductive system. In: Townsend CM, Beauchamp RD, Evers BM, eds. *Textbook of Surgery*. Philadelphia: WB Saunders, 2001:1619–1648.
26. Hume RF, Killiam AP. Maternal physiology. In: Scott JR, KiSaia J, Hammon DB, eds. *Obstetrics and Gynecology*. Philadelphia: JB Lippincott, 1990:93–100.
27. Society of American Gastrointestinal Endoscopic Surgeons (SAGES). Guidelines for laparoscopic surgery during pregnancy. *Surg Endosc* 1998; 12:189–190.
28. Malangoni MA. Gastrointestinal surgery and pregnancy. *Gastroenterol Clin North Am* 2003; 32:181–200.
29. Melnick DM, Wahl WL, Dalton VK. Management of general surgical problems in the pregnant patient. *Am J Surg* 2004; 187:170–180.
30. Jorgensen JO, Lalak NJ, North L, et al. Venous stasis during laparoscopic cholecystectomy. *Surg Laparosc Endosc* 1994; 4:128–133.
31. Pitkin RM, Witte DL. Platelet and leukocyte counts in pregnancy. *JAMA* 1979; 242:2696–2698.
32. Fay RA, Hughes AO, Farron NT. Platelets in pregnancy: hyperdestruction in pregnancy. *Obstet Gynecol* 1983; 61:238–240.
33. Burrows RF, Kelton JG. Incidentally detected thrombocytopenia in healthy mothers and their infants. *N Engl J Med* 1988; 319:142–145.
34. Sharp HT. The acute abdomen during pregnancy. *Clin Obstet Gynecol* 2002; 45:405–413.
35. Cohen SE. Nonobstetric surgery during pregnancy. In: Chestnut DH, ed. *Obstetric Anesthesia: Principles and Practice*. St. Louis: Mosby-Year Book, 1999:279.
36. Rosen MA. Management of anesthesia for the pregnant surgical patient. *Anesthesiology* 1999; 91:1159–1163.
37. Koren G, Pastuszak A, Ito S. Drugs in pregnancy. *N Engl J Med* 1998; 338:1128–1137.
38. Shay DC, Bhavani-Shankar K, Datta S. Laparoscopic surgery during pregnancy. *Anesthesiol Clin North Am* 2001; 19:57–67.
39. Newman W, Braid D, Wood C. Fetal acid–base status. 1. Relationship between maternal and fetal pCO₂. *Am J Obstet Gynecol* 1967; 97:43–51.
40. Walker AM, Oakes GK, Ehrenkranz R, et al. Effects of hypercapnia on uterine and umbilical circulations in conscious pregnant sheep. *J Appl Physiol* 1976; 41:727–733.
41. Toppenberg KS, Hill DA, Miller DP. Safety of radiographic imaging during pregnancy. *Am Fam Phys* 1999; 59:1813–1818, 1820.
42. Timins JK. Radiation during pregnancy. *N Engl J Med* 2001; 98:29–33.
43. Karam PA. Determining and reporting fetal radiation exposure from diagnostic radiation. *Health Phys* 2000; 79:S85–S90.
44. Mettler FA Jr, Wiest PW, Locken JA, et al. CT scanning: patterns of use and dose. *J Radiol Prot* 2000; 20:353–359.
45. Kanal E, Borgstede JP, Barkovich AJ, et al. American College of Radiology White Paper on MR Safety. *AJR Am J Roentgenol* 2002; 178:1335–1347.
46. McKellar DP, Anderson CT, Boynton CJ, et al. Cholecystectomy during pregnancy without fetal loss. *Surg Gynecol Obstet* 1992; 174:465–468.
47. Al-Fozan H, Tulandi T. Safety and risks of laparoscopy in pregnancy. *Curr Opin Obstet Gynecol* 2002; 14:375–379.
48. Glasgow RE, Visser BC, Harris HW, et al. Changing management of gallstone disease during pregnancy. *Surg Endosc* 1998; 12:241–246.
49. Barone JE, Bears S, Chen S, et al. Outcome study of cholecystectomy during pregnancy. *Am J Surg* 1999; 177:232–236.
50. Davis A, Katz VL, Cox R. Gallbladder disease in pregnancy. *J Reprod Med* 1995; 40:759–762.
51. Muench J, Albrink M, Serafini F, et al. Delay in treatment of biliary disease during pregnancy increases morbidity and can be avoided with safe laparoscopic cholecystectomy. *Am Surg* 2001; 67:539–542; discussion 533–542.
52. Visser BC, Glasgow RE, Mulvihill KK, et al. Safety and timing of nonobstetric abdominal surgery in pregnancy. *Dig Surg* 2001; 18:409–417.
53. Fatum M, Rojansky N. Laparoscopic surgery during pregnancy. *Obstet Gynecol Surv* 2001; 56:50–9.
54. Hunter JG, Swanstrom L, Thornburg K. Carbon dioxide pneumoperitoneum induces fetal acidosis in a pregnant ewe model. *Surg Endosc* 1995; 9:272–277; discussion 277–279.
55. Reedy MB, Galan HL, Bean-Lijewski JD, et al. Maternal and fetal effects of laparoscopic insufflation in the gravid baboon. *J Am Assoc Gynecol Laparosc* 1995; 2:399–406.
56. Curet MJ, Vogt DA, Schob O, et al. Effects of CO₂ pneumoperitoneum in pregnant ewes. *J Surg Res* 1996; 63:339–344.
57. Cruz AM, Southerland LC, Duke T, et al. Intraabdominal carbon dioxide insufflation in the pregnant ewe. Uterine blood flow, intraamniotic pressure, and cardiopulmonary effects. *Anesthesiology* 1996; 85:1395–1402.
58. Comitolo JB, Lynch D. Laparoscopic cholecystectomy in the pregnant patient. *Surg Laparosc Endosc* 1994; 4:268–271.
59. Soper NJ, Hunter JG, Petrie RH. Laparoscopic cholecystectomy during pregnancy. *Surg Endosc* 1992; 6:115–117.
60. Barnard JM, Chaffin D, Droste S, et al. Fetal response to carbon dioxide pneumoperitoneum in the pregnant ewe. *Obstet Gynecol* 1995; 85:669–674.
61. Akira S, Yamanaka A, Ishihara T, et al. Gasless laparoscopic ovarian cystectomy during pregnancy: comparison with laparotomy. *Am J Obstet Gynecol* 1999; 180:554–557.

62. Bhavani-Shankar K, Steinbrook RA, Brooks DC, et al. Arterial to end-tidal carbon dioxide pressure difference during laparoscopic surgery in pregnancy. *Anesthesiology* 2000; 93:370–373.
63. Graham G, Baxi L, Tharakan T. Laparoscopic cholecystectomy during pregnancy: a case series and review of the literature. *Obstet Gynecol Surv* 1998; 53:566–574.
64. Williams JK, Rosemurgy AS, Albrink MH, et al. Laparoscopic cholecystectomy in pregnancy. A case report. *J Reprod Med* 1995; 40:243–245.
65. Curet MJ, Allen D, Josloff RK, et al. Laparoscopy during pregnancy. *Arch Surg* 1996; 131:546–550; discussion 541–550.
66. Costantino GN, Vincent GJ, Mukalian GG, et al. Laparoscopic cholecystectomy in pregnancy. *J Laparoendosc Surg* 1994; 4:161–164.
67. Curet MJ. Special problems in laparoscopic surgery. Previous abdominal surgery, obesity, and pregnancy. *Surg Clin North Am* 2000; 80:1093–1110.
68. Oelsner G, Stockheim D, Soriano D, et al. Pregnancy outcome after laparoscopy or laparotomy in pregnancy. *J Am Assoc Gynecol Laparosc* 2003; 10:200–204.
69. Rizzo AG. Laparoscopic surgery in pregnancy: long-term follow-up. *J Laparoendosc Adv Surg Tech A* 2003; 13:11–15.
70. Tarraza HM, Moore RD. Gynecologic causes of the acute abdomen and the acute abdomen in pregnancy. *Surg Clin North Am* 1997; 77:1371–1394.
71. Fallon WF Jr, Newman JS, Fallon GL, et al. The surgical management of intra-abdominal inflammatory conditions during pregnancy. *Surg Clin North Am* 1995; 75:15–31.
72. Hiatt JR, Hiatt JC, Williams RA, et al. Biliary disease in pregnancy: strategy for surgical management. *Am J Surg* 1986; 151:263–265.
73. Cosenza CA, Saffari B, Jabbour N, et al. Surgical management of biliary gallstone disease during pregnancy. *Am J Surg* 1999; 178:545–548.
74. Scott LD. Gallstone disease and pancreatitis in pregnancy. *Gastroenterol Clin North Am* 1992; 21:803–815.
75. Printen KJ, Ott RA. Cholecystectomy during pregnancy. *Am Surg* 1978; 44:432–434.
76. Steinbrook RA, Brooks DC, Datta S. Laparoscopic cholecystectomy during pregnancy. Review of anesthetic management, surgical considerations. *Surg Endosc* 1996; 10:511–515.
77. DeVore GR. Acute abdominal pain in the pregnant patient due to pancreatitis, acute appendicitis, cholecystitis, or peptic ulcer disease. *Clin Perinatol* 1980; 7:349–369.
78. Borum ML. Hepatobiliary diseases in women. *Med Clin North Am* 1998; 82:51–75.
79. Baillie J, Cairns SR, Putman WS, et al. Endoscopic management of choledocholithiasis during pregnancy. *Surg Gynecol Obstet* 1990; 171:1–4.
80. Sungler P, Heinerman PM, Steiner H, et al. Laparoscopic cholecystectomy and interventional endoscopy for gallstone complications during pregnancy. *Surg Endosc* 2000; 14:267–271.
81. Mourad J, Elliott JP, Erickson L, et al. Appendicitis in pregnancy: new information that contradicts long-held clinical beliefs. *Am J Obstet Gynecol* 2000; 182:1027–1029.
82. Cunningham FG, McCubbin JH. Appendicitis complicating pregnancy. *Obstet Gynecol* 1975; 45:415–420.
83. Horowitz MD, Gomez GA, Santiesteban R, et al. Acute appendicitis during pregnancy. Diagnosis and management. *Arch Surg* 1985; 120:1362–1367.
84. Gurbuz AT, Peetz ME. The acute abdomen in the pregnant patient. Is there a role for laparoscopy? *Surg Endosc* 1997; 11:98–102.
85. Mahmoodian S. Appendicitis complicating pregnancy. *South Med J* 1992; 85:19–24.
86. Cappell MS, Friedel D. Abdominal pain during pregnancy. *Gastroenterol Clin North Am* 2003; 32:1–58.
87. Weingold AB. Appendicitis in pregnancy. *Clin Obstet Gynecol* 1983; 26:801–809.
88. Tamir IL, Bongard FS, Klein SR. Acute appendicitis in the pregnant patient. *Am J Surg* 1990; 160:571–5; discussion 575–576.
89. Ames Castro M, Shipp TD, Castro EE, et al. The use of helical computed tomography in pregnancy for the diagnosis of acute appendicitis. *Am J Obstet Gynecol* 2001; 184:954–957.
90. Lim HK, Bae SH, Seo GS. Diagnosis of acute appendicitis in pregnant women: value of sonography. *AJR Am J Roentgenol* 1992; 159:539–542.
91. Gagner M, Breton G, Pharand D, et al. Is laparoscopic adrenalectomy indicated for pheochromocytomas? *Surgery* 1996; 120:1076–1079; discussion 1079–1080.
92. Fernandez-Cruz L, Taura P, Saenz A, et al. Laparoscopic approach to pheochromocytoma: hemodynamic changes and catecholamine secretion. *World J Surg* 1996; 20:762–768; discussion 768.
93. Shalhav AL, Landman J, Afane J, et al. Laparoscopic adrenalectomy for primary hyperaldosteronism during pregnancy. *J Laparoendosc Adv Surg Tech A* 2000; 10:169–171.
94. Finkenstedt G, Gasser RW, Hofle G, et al. Pheochromocytoma and sub-clinical Cushing's syndrome during pregnancy: diagnosis, medical pre-treatment and cure by laparoscopic unilateral adrenalectomy. *J Endocrinol Invest* 1999; 22:551–557.
95. Aishima M, Tanaka M, Haraoka M, et al. Retroperitoneal laparoscopic adrenalectomy in a pregnant woman with Cushing's syndrome. *J Urol* 2000; 164:770–771.
96. Lo CY, Lo CM, Lam KY. Cushing's syndrome secondary to adrenal adenoma during pregnancy. *Surg Endosc* 2002; 16:219–220.
97. Janetschek G, Finkenstedt G, Gasser R, et al. Laparoscopic surgery for pheochromocytoma: adrenalectomy, partial resection, excision of paragangliomas. *J Urol* 1998; 160:330–334.
98. Demeure MJ, Carlsen B, Traul D, et al. Laparoscopic removal of a right adrenal pheochromocytoma in a pregnant woman. *J Laparoendosc Adv Surg Tech A* 1998; 8:315–319.
99. Pace DE, Chiasson PM, Schlachta CM, et al. Minimally invasive adrenalectomy for pheochromocytoma during pregnancy. *Surg Laparosc Endosc Percutan Tech* 2002; 12:122–125.
100. Gifford RW Jr, Manger WM, Bravo EL. Pheochromocytoma. *Endocrinol Metab Clin North Am* 1994; 23:387–404.
101. Brunt LM. Pheochromocytoma in pregnancy. *Br J Surg* 2001; 88:481–483.

102. Schenker JG, Chowder I. Pheochromocytoma and pregnancy. Review of 89 cases. *Obstet Gynecol Surv* 1971; 26:739–747.
103. Schenker JG, Granat M. Phaeochromocytoma and pregnancy—an updated appraisal. *Aust N Z J Obstet Gynaecol* 1982; 22:1–10.
104. Harper MA, Murnaghan GA, Kennedy L, et al. Phaeochromocytoma in pregnancy. Five cases and a review of the literature. *Br J Obstet Gynaecol* 1989; 96:594–606.
105. Hadden DR. Adrenal disorders of pregnancy. *Endocrinol Metab Clin North Am* 1995; 24:139–151.
106. Botchan A, Hauser R, Kupfermine M, et al. Pheochromocytoma in pregnancy: case report and review of the literature. *Obstet Gynecol Surv* 1995; 50:321–327.
107. Harrington JL, Farley DR, van Heerden JA, et al. Adrenal tumors and pregnancy. *World J Surg* 1999; 23:182–186.
108. Lozano-Salazar RR, Herrera MF, Vargas-Vorackova F, et al. Laparoscopic versus open splenectomy for immune thrombocytopenic purpura. *Am J Surg* 1998; 176:366–369.
109. Katkhouda N, Manhas S, Umbach TW, et al. Laparoscopic splenectomy. *J Laparoendosc Adv Surg Tech A* 2001; 11:383–390.
110. Martin JN Jr, Morrison JC, Files JC. Autoimmune thrombocytopenic purpura: current concepts and recommended practices. *Am J Obstet Gynecol* 1984; 150:86–96.
111. Iwase K, Higaki J, Yoon HE, et al. Hand-assisted laparoscopic splenectomy for idiopathic thrombocytopenic purpura during pregnancy. *Surg Laparosc Endosc Percutan Tech* 2001; 11:53–56.
112. Anglin BV, Rutherford C, Ramus R, et al. Immune thrombocytopenic purpura during pregnancy: laparoscopic treatment. *JSL* 2001; 5:63–67.
113. Gottlieb P, Axelsson O, Bakos O, et al. Splenectomy during pregnancy: an option in the treatment of autoimmune thrombocytopenic purpura. *Br J Obstet Gynaecol* 1999; 106:373–375.
114. Hardwick RH, Slade RR, Smith PA, et al. Laparoscopic splenectomy in pregnancy. *J Laparoendosc Adv Surg Tech A* 1999; 9:439–440.
115. Allran CF Jr, Weiss CA III, Park AE. Urgent laparoscopic splenectomy in a morbidly obese pregnant woman: case report and literature review. *J Laparoendosc Adv Surg Tech A* 2002; 12:445–447.
116. Houshiar AM, Ercole CJ. Urinary calculi during pregnancy. When are they cause for concern? *Postgrad Med* 1996; 100:131–138.
117. Tiselius HG, Ackermann D, Alken P, et al. Guidelines on urolithiasis. *Eur Urol* 2001; 40:362–371.
118. Biyani CS, Joyce AD. Urolithiasis in pregnancy. II: management. *BJU Int* 2002; 89:819–823.
119. Gaur DD, Trivedi S, Prabhudesai MR, et al. Laparoscopic ureterolithotomy: technical considerations and long-term follow-up. *BJU Int* 2002; 89:339–343.
120. Tailly GG. Modern approach to ureteral stones. *Sci World J* 2003; 3:853–866.
121. Bozzo M, Buscaglia M, Ferrazzi E. The management of persistent adnexal masses in pregnancy. *Am J Obstet Gynecol* 1997; 177:981–982.
122. Johnson TR Jr, Woodruff JD. Surgical emergencies of the uterine adnexae during pregnancy. *Int J Gynaecol Obstet* 1986; 24:331–335.
123. Sherard GB III, Hodson CA, Williams HJ, et al. Adnexal masses and pregnancy: a 12-year experience. *Am J Obstet Gynecol* 2003; 189:358–362; discussion 353–362.
124. Hess LW, Peaceman A, O'Brien WF, et al. Adnexal mass occurring with intrauterine pregnancy: report of fifty-four patients requiring laparotomy for definitive management. *Am J Obstet Gynecol* 1988; 158:1029–1034.
125. Thornton JG, Wells M. Ovarian cysts in pregnancy: does ultrasound make traditional management inappropriate? *Obstet Gynecol* 1987; 69:717–721.
126. Grimes WH Jr, Bartholomew RA, Colvin ED, et al. Ovarian cyst complicating pregnancy. *Am J Obstet Gynecol* 1954; 68:594–605.
127. Houry D, Abbott JT. Ovarian torsion: a fifteen-year review. *Ann Emerg Med* 2001; 38:156–159.
128. Oelsner G, Bider D, Goldenberg M, et al. Long-term follow-up of the twisted ischemic adnexa managed by detorsion. *Fertil Steril* 1993; 60:976–979.
129. Mage G, Canis M, Manhes H, et al. Laparoscopic management of adnexal torsion. A review of 35 cases. *J Reprod Med* 1989; 34:520–524.
130. Nichols DH, Julian PJ. Torsion of the adnexa. *Clin Obstet Gynecol* 1985; 28:375–380.
131. Struyk AP, Treffers PE. Ovarian tumors in pregnancy. *Acta Obstet Gynecol Scand* 1984; 63:421–424.
132. Argenta PA, Yeagley TJ, Ott G, et al. Torsion of the uterine adnexa. Pathologic correlations and current management trends. *J Reprod Med* 2000; 45:831–836.
133. Garzarelli S, Mazzuca N. One laparoscopic puncture for treatment of ovarian cysts with adnexal torsion in early pregnancy. A report of two cases. *J Reprod Med* 1994; 39:985–986.
134. Morice P, Louis-Sylvestre C, Chapron C, et al. Laparoscopy for adnexal torsion in pregnant women. *J Reprod Med* 1997; 42:435–439.
135. Nezhat F, Nezhat C, Silfen SL, et al. Laparoscopic ovarian cystectomy during pregnancy. *J Laparoendosc Surg* 1991; 1:161–164.
136. Parker WH, Levine RL, Howard FM, et al. A multicenter study of laparoscopic management of selected cystic adnexal masses in postmenopausal women. *J Am Coll Surg* 1994; 179:733–737.
137. Tazuke SI, Nezhat FR, Nezhat CH, et al. Laparoscopic management of pelvic pathology during pregnancy. *J Am Assoc Gynecol Laparosc* 1997; 4:605–608.
138. Parker J, Watkins W, Robinson H, et al. Laparoscopic adnexal surgery during pregnancy: a case of heterotopic tubal pregnancy treated by laparoscopic salpingectomy. *Aust N Z J Obstet Gynaecol* 1995; 35:208–210.
139. Katz VL. Prenatal care. In: Danforth's Obstetrics and Gynecology. Scott JR, Gibbs RS, Karlan BY, Haney AF, eds. Philadelphia: Lippincott Williams & Wilkins. 2003:1–20.
140. Kennedy A. Assessment of acute abdominal pain in the pregnant patient. *Semin Ultrasound CT MR* 2000; 21:64–77.

Abraham A. Nisim and Daniel R. Margulies

Department of Surgery, Cedars-Sinai Medical Center, Los Angeles, California, U.S.A.

■ INTRODUCTION AND BACKGROUND
■ PENETRATING INJURIES

■ BLUNT TRAUMA
■ REFERENCES

INTRODUCTION AND BACKGROUND

The primary goal in care of the injured patient is to quickly control hemorrhage; thus the role of laparoscopy has traditionally been limited. However, as laparoscopic surgical skills and equipment have improved, laparoscopy and thoracoscopy have increasingly been used for diagnostic and therapeutic purposes in hemodynamically stable trauma patients.

The role of laparoscopy in trauma was first described in the 1920s for its ability to identify hemoperitoneum (1). In the United States, Gazzangia in 1976 described the first series of trauma patients with either blunt or penetrating trauma, where laparoscopy was used for diagnosis (2). Laparoscopy has gained favor in many trauma centers due to decreased morbidity, pain, and potential complications associated with major operative wounds seen in standard laparotomy and thoracotomy incisions. At the same time, other minimally invasive techniques have been increasingly used in trauma, including observation with selective nonoperative management and the use of angiography.

Although laparoscopy has become the standard treatment for some general surgical operations (e.g., cholecystectomy), more traditional approaches such as computed tomography scanning, ultrasound, diagnostic peritoneal lavage, observation, and laparotomy remain as the standard of care in trauma. Yet, it is recognized that when laparotomy is used for diagnosis traditionally the negative or nontherapeutic laparotomy rates have been relatively high, ranging between 12% and 40%. Furthermore, the potential complications associated with negative laparotomies makes laparoscopy a desirable alternative. In addition, laparoscopy provides the potential ability to diagnose injuries missed as compared to use of imaging studies alone. Laparoscopy must be weighed against these approaches in deciding its appropriateness in the management of a given patient. Specifically, laparoscopy offers good visualization of the anterior and lateral abdominal walls but is more limited in its ability to visualize the retroperitoneal structures.

When laparoscopy was utilized either for diagnostic or therapeutic purposes, a decreased rate of negative laparotomies was clearly seen, as well as an overall decreased length of hospital stay.

Conversely, laparoscopy entails some additional patient risks over nonoperative options. Specifically, there is exposure to anesthesia and the possibility of creating a carbon dioxide pneumothorax (when a diaphragmatic injury is present), visceral or diaphragmatic injury, increased intracranial pressure, and potential hernia formation. In addition, there are costs associated with laparoscopy which would not be present if observation alone was employed.

Table 1 reviews the findings of eight studies of laparoscopy in trauma conducted between 1991 and 2003.

Eight studies examined the potential laparoscopic benefits in 1193 patients (Table 1) with abdominal trauma. When the goal was diagnostic alone, laparoscopy was successful in 53% to 81% of the cases. Laparoscopy was used therapeutically in 0% to 13% (19–47% of the cases were converted to laparotomy).

Currently, the role of laparoscopy in trauma is strictly limited to hemodynamically stable patients.

When laparoscopy was utilized either for diagnostic or therapeutic purposes, a decreased rate of negative laparotomies was clearly seen, as well as an overall decreased length of hospital stay.

Table 1 reviews the findings of eight studies of laparoscopy in trauma conducted between 1991 and 2003.

Currently, the role of laparoscopy in trauma is strictly limited to hemodynamically stable patients.

TABLE 1 ■ Laparoscopy for Abdominal Trauma: Collected Series

Author (refs.)	Year	Number of individuals evaluated laparoscopically (n)	No injuries requiring further surgical management (%)	Injuries treated laparoscopically (%)	Injuries requiring laparotomy (%)
Berci (3)	1991	150	81	0	19
Fabian (4)	1993	182	53	–	47
Fernando (5)	1993	33	70	–	30
Townsend (6)	1993	16	56	0	44
Smith (7)	1995	133	54	5	41
Sosa (8)	1995	121	62	3	35
Zantut (9)	1997	510	54	5	41
Chelly (10)	2003	48	58	13	29

Hemodynamically unstable patients require a streamlined, rapid approach in obtaining a diagnosis and providing treatment. As such, any delay (e.g., time necessary to perform a laparoscopic procedure) can potentially compromise patient care and is inappropriate.

The operating room has traditionally served as the forum for performing laparoscopic procedures. With the advent of smaller cameras that fit through a single Veress needle after insufflation, such procedures are also being performed in some emergency departments. The ability to safely perform laparoscopy in the emergency department on a stable patient by providing sedation and local anesthesia has the advantage of definitively ruling out intra-abdominal injuries. Combining such results with other diagnostic findings can potentially allow a patient to be discharged from the emergency department rather than be admitted for observation (a potential in saving costs to the patient and the hospital). However, as computed tomography scanning and ultrasound techniques have improved, the interest in this has waned.

PENETRATING INJURIES

Laparoscopy plays an important role in penetrating injury (2,4,7,9,11–22). In the absence of such findings, hospitalization may be unnecessary.

Specifically, in patients who sustain thoracoabdominal wounds, diagnostic methods such as peritoneal lavage, ultrasonography, and computed tomography scan are not as accurate, nor as helpful as laparoscopy in ruling out penetrations, allow. Laparoscopy for visual inspection of the diaphragm, evaluation of hepatic and splenic lacerations, and even identification of pericardium for possible hemopericardium, as well as anterior abdominal wall injury evaluation (7,11–13,24).

Laparoscopy is helpful in the tangential gunshot wound, where there is a concern for intra-abdominal injury. Should peritoneal penetration be ruled out via direct visualization utilizing this technique, further hospitalization of such patient is unnecessary. Laparoscopic management of selected abdominal gunshot wounds can be accomplished without morbidity (7,12,13,16–18,25). Such benefit extends to selected patients with missile wounds of uncertain trajectory through the peritoneal cavity. Zantut et al. reported that 58% (113 of 194) of stable patients with gunshot wounds, who were evaluated with laparoscopy, were discharged home with confidence after a brief hospital stay without the need for laparotomy (9).

Laparoscopic management of penetrating chest injuries has also been described. Laparoscopic evaluation of 110 patients with a penetrating wound to the left lower chest was described by Murray et al. in 1997. Importantly, all the patients were hemodynamically stable and without other indications for a celiotomy. Overall, 24% of the patients sustained a diaphragmatic injury (26). Spann et al. found in 31% of the patients, where a hemo- or pneumothorax was identified on chest X-ray, a diaphragmatic injury was later identified by laparoscopy. Some of these injuries were repaired laparoscopically, and others were repaired after conversion to celiotomy (27).

Diaphragmatic injury from penetrating trauma has also been evaluated utilizing thoracoscopy. Ochsner et al. and Uribe et al. found 9 out of 14 (64%) and 9 out of 28 (32%), respectively, of their patients with penetrating thoracoabdominal injury to have a diaphragm injury. In all of the above described patients, thoracoscopy was deemed to be a safe procedure (27–29).

A debate exists as to the preferred mode of approaching diaphragmatic injuries.

Specifically, in patients who sustain thoracoabdominal wounds, diagnostic methods such as peritoneal lavage, ultrasonography, and computed tomography scan are not as accurate, nor as helpful as laparoscopy in ruling out penetrations, allow. Laparoscopy for visual inspection of the diaphragm, evaluation of hepatic and splenic lacerations, and even identification of pericardium for possible hemopericardium, as well as anterior abdominal wall injury evaluation.

Laparoscopic management of penetrating chest injuries has also been described.

A debate exists as to the preferred mode of approaching diaphragmatic injuries.

Proponents of laparoscopy argue that the incidence of associated abdominal injuries for penetrating thoracoabdominal injuries is significant enough to warrant an evaluation of the diaphragm and the peritoneal cavity simultaneously. Furthermore, the utilization of double lumen intubations, which carries its own risks, is avoided. Those who favor thoracoscopy argue that this technique avoids insufflation pressures utilized with laparoscopy, which are associated with pneumothorax and hemodynamic changes. It is also argued that this technique is able to avoid violation of the peritoneal cavity in patients who do not have a diaphragmatic injury. Guth and Pachter evaluated 70 patients with penetrating abdominal or lower chest injuries with laparoscopy, yet found two patients who subsequently underwent thorotomy, suggesting that when laparoscopy is utilized primarily, significant intrathoracic injuries may be missed (30).

Different techniques for laparoscopic evaluation of the peritoneum are described, one such approach includes initially placing a 5 mm scope 4 cm above the umbilicus (port 1). Two additional 5 mm ports are placed, one in the suprapubic region (port 2) and a second in the region of the midline (port 3). The peritoneal cavity is inspected for blood or bile. Upon completion, the scope is moved to port 2. Utilizing atraumatic bowel graspers, the bowel is "run" from the ligament of Treitz to the ileum (9). Importantly, a missed bowel injury including perforation is a potential fatal complication. So, laparotomy must be performed in patients where any doubt of injury remains (22,23).

BLUNT TRAUMA

Computed tomography scan is the mode of choice in evaluating the hemodynamically stable patient with blunt trauma.

Computed tomography scan is the mode of choice in evaluating the hemodynamically stable patient with blunt trauma.

Certain circumstances have been described in which computed tomography scan results cannot completely rule out abdominal organ injury. For example, patients with pelvic fractures or retroperitoneal hematomas, who already have abdominal tenderness (thereby limiting clinical evaluation), are at increased risk for missed blunt hollow organ injury. Similarly, such occult findings may also exist in patients who suffer head or spinal cord injury. Although diagnostic peritoneal lavage, ultrasound, or repeat computed tomography scan may detect the injury, early laparoscopy establishes the diagnosis, thus allowing for earlier definitive treatment.

Some urologic injuries can be diagnosed and treated laparoscopically. In patients with blunt trauma to the abdomen consisting of an isolated bladder injury, one can laparoscopically evaluate the bladder and repair the injury with intracorporeal suturing techniques.

Furthermore, in a similar manner, patients with isolated ureteral injury can also be managed laparoscopically, usually with repair over a ureteral stent. When laparoscopy is used in the evaluation of gunshot wounds, any trajectory traveling close to the path of the ureter should be evaluated and explored laparoscopically to rule out injury. A final use of laparoscopy in urologic trauma is in performing planned laparoscopic nephrectomy for the management of the delayed atrophic traumatic kidney or for refractory renal hypertension secondary to renal arterial injury.

Some urologic injuries can be diagnosed and treated laparoscopically. In patients with blunt trauma to the abdomen consisting of an isolated bladder injury, one can laparoscopically evaluate the bladder and repair the injury with intracorporeal suturing techniques.

REFERENCES

1. Villavicencio RT, Aucar JA. Analysis of laparoscopy in trauma. *J Am Coll Surg* 1999; 189:11.
2. Rossi P, Mullins D, Thal E. Role of laparoscopy in the evaluation of abdominal trauma. *Am J Surg* 1993; 166:707.
3. Berci G, Sackier JM, Paz-Partlow M. Emergency laparoscopy. *Am J Surg* 1991; 161:332.
4. Fabian TC, Croce MA, Stewart RM, et al. A prospective analysis of diagnostic laparoscopy in trauma. *Ann Surg* 1993; 217:557.
5. Fernando HC, Alle KM, Chen J, et al. Triage by laparoscopy in patients with penetrating abdominal trauma. *Br J Surg* 1994; 81:384.
6. Townsend MC, Flancaum L, Choban PS, Cloutier CT. Diagnostic laparoscopy as an adjunct to selective conservative management of solid organ injuries after blunt abdominal trauma. *J Trauma* 1993; 35:647.
7. Smith RS, Fry WR, Morabito DJ, et al. Therapeutic laparoscopy in trauma. *Am J Surg* 1995; 170:632.
8. Sosa JL, Sims D, Martin L, Zeppa R. Laparoscopic evaluation of tangential abdominal gunshot wounds. *Arch Surg* 1992; 127:109.
9. Zantut LF, Ivatury RR, Smith RS, et al. Diagnostic and therapeutic laparoscopy for penetrating abdominal trauma: a multicenter experience. *J Trauma* 1997; 42:825.
10. Chelly MR, Major K, Spivak J, et al. The value of laparoscopy in management of abdominal trauma. *Am Surg* 2003; 69:957.
11. Zantut LFC, et al. Laparoscopy as a diagnostic tool in the evaluation of trauma. *Pan Am J Trauma* 1990; 2:6.

12. Ivatury RR, Simon RJ, Weksler B, et al. Laparoscopy in the evaluation of the intrathoracic abdomen after penetrating injury. *J Trauma* 1992; 33:101.
13. Ivatury RR, Simon RJ, Stahl WM. Selective celiotomy for missile wounds of the abdomen based on laparoscopy. *Surg Endosc* 1994; 8:366.
14. Smith RS, Fry WR, Tsoi EK, et al. Gasless laparoscopy and conventional instruments. The next phase of minimally invasive surgery. *Arch Surg* 1993; 128:1102.
15. Smith RS, Fry WR. Alternative techniques in laparoscopy for trauma. *Trauma Q* 1994; 10:291.
16. Livingstone DH, Tortella BJ, Blackwood J, et al. The role of laparoscopy in abdominal trauma. *J Trauma* 1992; 33:471.
17. Sosa JL, Arrillaga A, Puente I, et al. Laparoscopy in 121 consecutive patients with abdominal gunshot wounds. *J Trauma* 1995; 39:501.
18. Sosa JL, Baker M, Puente I, et al. Negative laparotomy in abdominal gunshot wounds: potential impact of laparoscopy. *J Trauma* 1995; 38:194.
19. Ortega AE, Tang E, Froes ET, et al. Laparoscopic evaluation of penetrating thoracoabdominal traumatic injuries. *Surg Endosc* 1996; 10:19.
20. Dalton JM, DeMaria EJ, Gore DC, et al. Prospective evaluation of laparoscopy in abdominal stab wounds. *J Trauma* 1994; 36:149.
21. Kawahara NT, Zantut LFC, Poggetti R, et al. The value of video laparoscopy in penetrating abdominal trauma. *Surg Endosc* 1996; 10:188.
22. Smith RS, Meister RK, Tsoi EK, Bohman HR. Laparoscopically guided blood salvage and autotransfusion in splenic trauma: a case report. *J Trauma* 1993; 34:313.
23. Fabian TC, McCord S. Therapeutic laparoscopy in trauma. *Trauma Q* 1994; 10:285.
24. Grewal H, Ivatury RR, Divakar M, et al. A critical evaluation of diagnostic modalities used in the detection of occult cardiac injury. *Injury* 1995; 26:305.
25. Ivatury RR, Simon RJ, Stahl WM. A critical evaluation of laparoscopy in penetrating abdominal trauma. *J Trauma* 1993; 34:822.
26. Murray JA, Demetriades D, Asensio JA, et al. Occult injuries to the diaphragm; prospective evaluation of laparoscopy in penetrating injuries to the left lower chest. *J Am Coll Surg* 1998; 187:626–630.
27. Spann JC, Nwariaku FE, Wait M. Evaluation of video-assisted thoracoscopic surgery in the diagnosis of diaphragmatic injuries. *Am J Surg* 1995; 170:628.
28. Ochsner MG, Rozycki GS, Lucente F, et al. Prospective evaluation of thoracoscopy for diagnosing diaphragmatic injury in thoracoabdominal trauma: a preliminary report. *J Trauma* 1993; 34:704.
29. Uribe RA, Pachon CE, Frame SB, et al. A prospective evaluation of thoracoscopy for the diagnosis of penetrating thoracoabdominal trauma. *J Trauma* 1994; 37:650.
30. Guth AA, Pachter HL. Laparoscopy for penetrating thoracoabdominal trauma: pitfalls and promises. *JSL* 1998; 2:123.

Osamu Ukimura

*Section of Laparoscopic and Robotic Surgery, Glickman Urological Institute,
Cleveland Clinic Foundation, Cleveland, Ohio, U.S.A.*

- GENERAL PRINCIPLES OF LAPAROSCOPIC ULTRASOUND
- TECHNIQUE
- DOPPLER ULTRASOUND
- UROLOGIC UTILITY OF LAPAROSCOPIC ULTRASONOGRAPHY
 - Adrenal Surgery
 - Renal Surgery
 - Renal Ablative Techniques
 - Renal Cyst Surgery

- Lymphocele Surgery
- Stone Surgery
- Retroperitoneal Space (Ureterolysis and Lymphadenectomy)
- Prostate Surgery
- PROSPECTS AND LIMITATIONS FOR LAPAROSCOPIC ULTRASONOGRAPHY AND NEW TECHNOLOGY
- SUMMARY
- REFERENCES

Inability to palpate tissues remains one inherent limitation of laparoscopic surgery; however, laparoscopic ultrasonography can compensate for the loss of tactile feedback by enabling the surgeon to “look” into tissues being operated upon.

Laparoscopic ultrasonography has the potential to improve anatomic localization of tumor or pathologic lesion, to improve visualization of cancerous extension, to guide real-time needle biopsy or ablative therapy, and to optimize the extent of surgical resection regarding completeness of tumor excision and preservation of functional anatomy.

The depth of ultrasound penetration with 7.5 MHz transducers is approximately 6–8 cm, which is commonly adequate for laparoscopic surgery, because laparoscopic ultrasonography scanning is performed directly on the surface of the target organ or lesion (contact scanning). Laparoscopic ultrasonography can detect stones as small as 1 mm, cysts as small as 2 mm, and tumors as small as 3 mm with reliable accuracy.

GENERAL PRINCIPLES OF LAPAROSCOPIC ULTRASOUND

Laparoscopic ultrasonography has been integrated into advanced laparoscopic urological surgery in recent years. This technology was initially applied in gastrointestinal surgery during the early 1990s since dedicated high-resolution B-mode (gray-scale two-dimensional image) laparoscopic ultrasound probes became available (1). Laparoscopic ultrasonography can provide the laparoscopic surgeon with information that may be unobtainable by laparoscopy alone.

Inability to palpate tissues remains one inherent limitation of laparoscopic surgery; however, laparoscopic ultrasonography can compensate for the loss of tactile feedback in laparoscopic surgery by enabling the surgeon to “look” into tissues being operated upon.

Laparoscopic ultrasonography can identify and characterize lesions seen on preoperative imaging and may potentially discover new lesions not detected by preoperative imaging or intraoperative laparoscopic inspection. The essential advantage of laparoscopic ultrasonography is the visualization of tissues beyond the two-dimensional laparoscopic picture, thereby enhancing the information available to the surgeon (2). As such, laparoscopic ultrasonography may enhance intraoperative surgical decision making.

Laparoscopic ultrasonography has the potential to improve anatomic localization of tumor or pathologic lesion, to improve visualization of cancerous extension, to guide real-time needle biopsy or ablative therapy, and to optimize the extent of surgical resection regarding completeness of tumor excision and preservation of functional anatomy.

TECHNIQUE

Linear-array transducer with frequency of 5–10 MHz (typically 7.5 MHz) is employed for laparoscopic ultrasonography. Laparoscopic ultrasonography probe consists of transducers mounted on or near the tip of a slender shaft. The shaft is usually 10 mm in diameter and at least 15–20 cm in length, and is introduced into the peritoneal or retroperitoneal cavity by way of a 10 mm port.

The depth of ultrasound penetration with 7.5 MHz transducers is approximately 6–8 cm, which is commonly adequate for laparoscopic surgery, because laparoscopic ultrasonography scanning is performed directly on the surface of the target organ or lesion (contact scanning). Laparoscopic ultrasonography can detect small lesions such as stones as small as 1 mm, cysts as small as 2 mm, and tumors as small as 3 mm with reliable accuracy (3).

There is sufficient moisture naturally to allow good acoustic contrast, although sterile saline or gel may be used as acoustic coupling medium, if necessary. A strictly rigid system often loses acoustic coupling because of its inability to maintain direct contact with the organ surface. Major limitations of laparoscopic ultrasonography are the facts that the probe entry is limited through the established laparoscopic port, and also that freedom of rigid-shaft movement is restricted. Because the rigid shaft is pivoting, the freedom of the scanning direction is limited, such that it is often difficult to maintain the probe in standard transverse and longitudinal orientations. An alternative, although suboptimal, approach to contact scanning using a nonflexible system is to fill the surgical cavity with fluid and scan through the fluid as an acoustic medium (stand-off scanning technique). The use of a flexible probe toward multiple directions is a more versatile approach and reduces the number of laparoscopic port sites and scanning time. Movement of the flexible portion of the probe is controlled by the operator using an external lever mechanism similar to that of a flexible endoscope. The ability to flex or extend the probe is of critical importance in maintaining contact with organs having curved surfaces such as the kidney.

In practice, during contact scanning, three basic probe maneuver techniques are used: lateral (sliding), rotational (angulation), and withdrawal (advancement) techniques.

In practice, during contact scanning, three basic probe maneuver techniques are used: lateral (sliding), rotational (angulation), and withdrawal (advancement) techniques (4).

In lateral movement technique, the probe shaft slides horizontally in contact with the surface of the target while the probe-to-surface geometry is maintained. In rotational technique, the probe shaft in the port is rotated (clockwise or counterclockwise). In withdrawal technique, the transducer surface is maintained in the same direction while the probe shaft is manipulated longitudinally using an advancement-withdrawal maneuver. Occasionally, combinations of these two or three scanning maneuvers are performed simultaneously. Using a combination of these techniques, the complete laparoscopic ultrasonography examination of, for example, the kidney takes less than 10 minutes. Although the learning curve for laparoscopic ultrasonography has been speculated to be between 20 and 50 procedures (5), the author believes that with the acquisition of basic ultrasound principles and a good knowledge of surgical anatomy, laparoscopic ultrasonography can be a straightforward procedure for many urologists. Working with an experienced partner or collaboration with the radiologist may accelerate the learning curve for urologists interested in laparoscopic ultrasonography. Laparoscopic ultrasonography can be performed at any time during laparoscopic surgery, most frequently, early during the course of surgery. Because laparoscopic ultrasonography can provide information regarding adequacy of tumor extirpation, it is recommended to keep the laparoscopic ultrasonography equipment available and the probe sterile until the end of the procedure so that laparoscopic ultrasonography scanning can be repeated whenever indicated. Picture-in-picture capability displays the laparoscopic ultrasonography image on the same screen as the laparoscopic image; the laparoscopic ultrasonography echo image is usually shown in the corner of the screen. This capability has eliminated the need of a separate screen for the ultrasound image, reducing surgeon strain and minimizing operating room equipment (2).

DOPPLER ULTRASOUND

Doppler ultrasound facilities allow identification of vessel anatomy and characterization of blood supply of and within the lesion. Spectral-wave-form analysis has capabilities to distinguish between arterial and venous flow, and to measure velocity as well as resistive index.

Doppler ultrasound facilities allow identification of vessel anatomy and characterization of blood supply of and within the lesion. Spectral-wave-form analysis has capabilities to distinguish between arterial and venous flow, and to measure velocity as well as resistive index.

Current laparoscopic ultrasonography probes can use B-mode and Doppler (color Doppler and/or power Doppler with spectral Doppler flow analysis) functions simultaneously.

In color Doppler mode, movement of objects toward the probe typically is presented in red, while movement away from the probe is in blue.

In color Doppler mode, it is useful to determine flow direction and velocity. The advantage of power Doppler function is that blood flow sensitivity is increased by a factor of three to five times in comparison with conventional color Doppler function. Power Doppler is much less angle dependent.

In power Doppler mode, the hue and brightness of the color signal represents the power in the Doppler signal, which is related to the number of red blood cells producing the Doppler shift. Power Doppler can visualize smaller vessels as well as slower flow vessels, achieving improved visualization of vascular borders and contours. The duplex imaging of both gray-scale and (color or power) Doppler allows one to distinguish between vascular and cystic structures.

In color Doppler mode, it is useful to determine flow direction and velocity. The advantage of power Doppler function is that blood flow sensitivity is increased by a factor of three to five times in comparison with conventional color Doppler function. Power Doppler is much less angle dependent.

Particularly, vascular involvement or extent of tumor thrombus within the vessels (especially renal hilum) can be delineated. Therefore, laparoscopic ultrasonography is capable of enhancing the accuracy of staging laparoscopy.

UROLOGIC UTILITY OF LAPAROSCOPIC ULTRASONOGRAPHY

Real-time visualization of blood flow will also provide significant physiologic and pathophysiologic information including tumor vascularity, lymph node involvement along vessels, and tumor resectability.

Real-time visualization of blood flow will also provide significant physiologic and pathophysiologic information including tumor vascularity, lymph node involvement along vessels, and tumor resectability.

Critical anatomic information provided by laparoscopic ultrasonography for technical success of laparoscopic adrenalectomy includes demonstration of fat plane between the adrenal gland and the aorta, inferior vena cava, kidney, renal pedicle, pancreas, liver, and diaphragm; ruling out local invasion into adjacent organs; locoregional lymph adenopathy; exclusion of adrenal vein thrombus; and dimension of adrenal gland, extracapsular extension, or lack thereof.

Adrenal Surgery

Recently several authors reported the utility of laparoscopic ultrasonography for surgical planning during laparoscopic adrenalectomy (6–12).

Critical anatomic information provided by laparoscopic ultrasonography for technical success of laparoscopic adrenalectomy includes demonstration of fat plane between the adrenal gland and the aorta, inferior vena cava, kidney, renal pedicle, pancreas, liver, and diaphragm; ruling out local invasion into adjacent organs; locoregional lymph adenopathy; exclusion of adrenal vein thrombus; and dimension of adrenal gland, extracapsular extension, or lack thereof.

Intraoperative laparoscopic ultrasonography screening of the area of interest entails slow advancement– withdrawal technique coinciding with slight rotational technique. To facilitate the ultrasound examination, saline irrigation can be added to the surgical field with the patient in the head-down position. Application of Doppler function is helpful in identifying the small vessels surrounding the adrenal gland, and maybe crucial in determining the distal extent of the adrenal and/or renal vein thrombus (12). Heniford et al. suggested that intraoperative laparoscopic ultrasonography effected a change in intraoperative technique in 68% of the 18 patients undergoing laparoscopic adrenalectomy, and that venous drainage of the adrenal organ could be delineated in all cases (6). Brunt et al., reporting in their experience with 28 patients, suggested that laparoscopic ultrasonography contributed to successful completion of the procedure in 11 of 28 cases (39%) and the adrenal vein was visualized in six cases (21%) (7).

Pautler et al. reported the use of laparoscopic ultrasonography during laparoscopic partial adrenalectomy in seven patients with a hereditary multifocal pheochromocytoma. Intraoperative laparoscopic ultrasonography differentiated normal adrenal parenchyma from the adrenal tumor mass, facilitating laparoscopic partial adrenalectomy (10). In select patients with significant concomitant intraperitoneal and retroperitoneal scarring from prior major abdominal or renal surgery, laparoscopic adrenalectomy assisted by laparoscopic ultrasonography can be performed by the transthoracic transdiaphragmatic approach (9). In addition, Hwang et al. reported that laparoscopic ultrasonography facilitated laparoscopic removal of paragangliomas in three of five cases, and not only assessed tumor margins but was also used to search for other potential retroperitoneal or adrenal masses not seen on preoperative imaging or laparoscopic inspection (12).

Renal Surgery

With growing experience, the repertoire of laparoscopic surgery for renal cell carcinoma has been cautiously expanded to select patients undergoing laparoscopic radical nephrectomy for locally invasive tumor, as well as for patients undergoing complex laparoscopic partial nephrectomy (13). Current experience has already confirmed the essential benefits of intraoperative laparoscopic ultrasonography during these difficult laparoscopic surgeries for renal cell carcinoma. Laparoscopic ultrasonography is now integral to our more technically advanced renal cancer cases.

Desai et al. reported their experience with laparoscopic radical nephrectomy in the presence of renal vein thrombus. Laparoscopic ultrasonography with color Doppler imaging was felt to be an essential intraoperative tool in patients suspected of having renal vein thrombus involvement, because it provides confident identification of the proximal extent of the tumor thrombus (14).

With the placement of the laparoscopic ultrasonography probe directly on the vena cava and renal vein, tumor-bearing and tumor-free areas in the proximal renal vein could be easily identified, despite the lack of tactile sensation (14,15).

Laparoscopic ultrasonography with Doppler imaging showed the uninvolved proximal segment of the renal vein with evidence of retrograde turbulent flow from the vena cava without any intraluminal mass, even after control of the renal artery.

With the placement of the laparoscopic ultrasonography probe directly on the vena cava and renal vein, tumor-bearing and tumor-free areas in the proximal renal vein could be easily identified, despite the lack of tactile sensation.

In patients undergoing nephron-sparing surgery for tumor, intraoperative laparoscopic ultrasonography is used to precisely delineate tumor size, depth of intraparenchymal extension, distance from the collecting system, and to evaluate for any unsuspected satellite renal masses. Such information gives the surgeon an excellent three-dimensional concept about planning the line of parenchymal incision vis-à-vis the deep margin of the tumor.

Intraoperative ultrasound provides excellent real-time visualization of the edge of the evolving ice ball, which itself is anechoic. This leading edge is clearly identified as a hyperechoic rim at the interface between frozen and unfrozen normal renal tissue.

By contact scanning from the renal surface opposite to the tumor, the deepest margin of the tumor is visualized; real-time visualization of obliteration of the deep margin of the tumor by the enlarging hyperechoic rim of the growing ice ball is one of the intraoperative parameters determining adequacy of cryoablation.

It is essential to recognize that real-time ultrasound monitoring of the evolving radio lesion is unreliable and inaccurate.

In patients undergoing nephron-sparing surgery for tumor, intraoperative laparoscopic ultrasonography is used to precisely delineate tumor size, depth of intraparenchymal extension, distance from the collecting system, and to evaluate for any unsuspected satellite renal masses (16). Such information gives the surgeon an excellent three-dimensional concept about planning the line of parenchymal incision vis-à-vis the deep margin of the tumor.

A proposed line of parenchymal incision is scored circumferentially around the tumor under laparoscopic ultrasonography guidance, maintaining an adequate margin of normal parenchyma. Steinberg et al. reported their experience in three complicated cases involving kidneys with concomitant main renal artery disease, wherein laparoscopic ultrasonography contributed to precise localization of the renal artery stenosis, aneurysm, and stent, thereby preventing injury during hilar clamping (17).

Renal Ablative Techniques

New minimally invasive energy-based probe ablative technologies are currently being applied to nephron-sparing surgery. Laparoscopic ultrasonography is used for precise placement of the ablative needle probe and real-time monitoring of cryoablation or other ablative procedures for the small renal tumor.

Cryoablation remains the most well-studied ablation alternative, especially laparoscopically (18–22). The first percutaneous application of cryosurgery for two patients with renal tumor was reported by Uchida et al. in 1995 (23).

Intraoperative ultrasound provides excellent real-time visualization of the edge of the evolving ice ball, which itself is anechoic. This leading edge is clearly identified as a hyperechoic rim at the interface between frozen and unfrozen normal renal tissue.

The use of end-fire laparoscopic ultrasonography probe has been reported to guide renal cryoablation (24); however, because the deepest margin of the mass is most at risk for incomplete freezing, use of a flexible side-fire laparoscopic ultrasonography probe positioned on the renal surface opposite to the tumor is preferable (25).

By contact scanning from the renal surface opposite to the tumor, the deepest margin of the tumor is visualized; real-time visualization of obliteration of the deep margin of the tumor by the enlarging hyperechoic rim of the growing ice ball is one of the intraoperative parameters determining adequacy of cryoablation.

Chosy et al. (26) reported that complete renal tissue ablation occurred at temperature around -20°C , and Baust et al. (27) showed that tissue destruction is achieved at 5–6 mm inside the edge of the advancing ice ball. Because injury of adjacent normal structures (such as the intestine, colon, pancreas renal hilum, and ureter) is a major concern, laparoscopic approach using real-time laparoscopic ultrasonography seems to be the safest approach for accurate targeting and reliable monitoring, with the advantage of surgically retracting organs and preventing incidental cryoinjury (22).

Gill et al. reported their experience with laparoscopic renal cryoablation in 56 patients for a mean tumor size of 2.3 cm. Over a follow-up of three years, average percent reduction in cryolesion size was 77% compared with the cryolesion size on postoperative day 1. No cryolesion could be identified in 38 patients at three years (19). Follow-up computed tomography-guided biopsy revealed persistent renal tumor in two patients, both of whom subsequently underwent uncomplicated laparoscopic radical nephrectomy, and who are currently alive with no evidence of disease. The longest and most rigorous clinical report of laparoscopic ultrasonography-assisted laparoscopic cryosurgery reported by Gill et al. has established the essential role of real-time laparoscopic ultrasonography monitoring during laparoscopic renal cryotherapy (19).

Radio-frequency ablation is being applied clinically in the treatment of small renal tumors (28–30). The radio-frequency ablation needle can be delivered percutaneously or laparoscopically, with progression of treatment being visualized under real-time ultrasonography. During ultrasound-guided radio-frequency ablation, the tumor surrounding the electrode becomes variably and irregularly hyperechoic, which usually resolves within minutes of initiating radio-frequency ablation; these ultrasonographically visible changes are thought to be due to microbubbles generated during tissue ablation.

It is essential to recognize that real-time ultrasound monitoring of the evolving radio lesion is unreliable and inaccurate.

It is necessary to investigate newer methods of real-time and in vivo monitoring of the spatial distribution of intraparenchymal patterns to achieve better monitoring of the evolving radio lesion. Varghese et al. reported that newer ultrasound thermal mapping technologies might fulfill this goal of temperature monitoring using a cross-corre-

lation algorithm applied to radiofrequency ultrasound echo signal data acquired at discrete intervals during heating (31).

High intensity–focused ultrasound for renal cell carcinoma is yet an experimental treatment modality. The first application of high intensity–focused ultrasound for four human renal tumors was reported by Vallancien et al. in the early 1990s (32,33). Vallancien et al. observed a hyperechoic spot with a back shadow, which appeared at the focal zone during high intensity–focused ultrasound insonation and which disappeared within a few minutes thereafter. The increased echogenicity of the insonated tissue may be related to a cavitation effect, which generates highly echogenic gas bubbles in the tissue. However, the appearance of such a hyperechoic spot does not guarantee adequate treatment. Accuracy of percutaneous high intensity–focused ultrasound effect may be limited by interference with the rib and by respiratory movement.

Variations in the extent of renal tissue damage, unpredictable complication of skin damage, and difficulty in assessing adequacy of treatment have prevented the wider spread use of percutaneous high intensity–focused ultrasound for kidney cancers compared to transrectal high intensity–focused ultrasound for the prostate (34).

Recently Paterson et al. developed and tested in the minipig model a laparoscopic probe that allows real-time ultrasound imaging during partial renal ablation using high intensity–focused ultrasound (35). This laparoscopic probe provides ultrasound imaging and energy delivery through the same probe. Thus, high intensity–focused ultrasound energy can be applied with direct contact on to the exterior surface of the kidney tumor under laparoscopy.

Variations in the extent of renal tissue damage, unpredictable complication of skin damage, and difficulty in assessing adequacy of treatment have prevented the wider spread use of percutaneous high intensity–focused ultrasound for kidney cancers compared to transrectal high intensity–focused ultrasound for the prostate.

Laparoscopic ultrasonography may be helpful for laparoscopic localization and drainage of difficult renal cysts.

Renal Cyst Surgery

Although percutaneous aspiration of renal cyst is diagnostic and may be therapeutic, unfortunately cysts typically recur. Laparoscopic decortication of the rare renal cyst that is symptomatically an effective minimally invasive alternative to percutaneous aspiration or open surgery.

Laparoscopic ultrasonography may be helpful for laparoscopic localization and drainage of difficult renal cysts (36–39).

Brown et al. employed laparoscopic ultrasonography in 21 patients with symptomatic renal cysts, allowing intraoperative identification of previously undetectable renal cysts (37). Elashry et al. reported their experience in two patients who underwent five laparoscopic ultrasonography-guided cyst marsupializations, suggesting that 10 MHz Color Doppler imaging contributed to discrimination of peripelvic cyst anatomic vasculature, permitting safe decortication of cysts adjacent to hilar vessels (38). This technique may also be helpful in patients with polycystic kidneys. Lee et al., in their recent reporting of their seven-year experience with laparoscopic cyst decortication for autosomal dominant polycystic disease patients with debilitating pain, opined that extensive laparoscopic cyst decortication can provide durable relief, improvement in blood pressure, and preservation or stabilization of renal function (39).

Lymphocele Surgery

Definitive management of the symptomatic lymphocele, following renal transplantation or pelvic lymph node dissection for prostate cancer, consists of surgical deroofing (marsupialization) and intraperitoneal drainage of the lymphocele. Percutaneous drainage and sclerotherapy is a suboptimal treatment because of high-recurrence rates and risk of infection. Laparoscopic lymphocelelectomy is an excellent alternative to the conventional open surgical approach, and is considered to be the primary treatment of choice today (40,41).

By providing intraoperative real-time information, laparoscopic ultrasound precisely guides the surgeon in selecting the safest location for initial laparoscopic entry into the lymphocele cavity, which is the most important step in this surgery.

To reduce the risk of complication, the use of laparoscopic (or intraoperative percutaneous) ultrasound is an essential adjunct, especially in the more complex, difficult-to-identify lymphocele (small; deep within the pelvis; and posterior, caudal, or medial to a renal allograft). ultrasound precisely localizes the lymphocele cavity and identifies its proximity to vital structures such as the iliac vessels, allograft, bowel, native ureters, and bladder (41–44).

By providing intraoperative real-time information, laparoscopic ultrasound precisely guides the surgeon in selecting the safest location for initial laparoscopic entry into the lymphocele cavity, which is the most important step in this surgery.

Stone Surgery

Most urinary stones are now treated by endourologic techniques and shock wave lithotripsy. However, occasionally, in the select patient with a combination of unique anatomical location, laparoscopic surgery may be indicated. Van Cangh et al. initially

Laparoscopic approach assisted by laparoscopic ultrasonography with color Doppler function facilitated accurate localization of the calculus and optimal selection of a relatively thin, avascular site for the nephrotomy, allowing complete stone fragment clearance.

reported the technique of laparoscopic nephrolithotomy in a patient with a 2 cm renal calculus who had previously failed extracorporeal shock wave lithotripsy and whose anteriorly located stone-bearing calyx precluded percutaneous extraction (45).

Laparoscopic approach assisted by laparoscopic ultrasonography with color Doppler function facilitated accurate localization of the calculus and optimal selection of a relatively thin, avascular site for the nephrotomy, allowing complete stone fragment clearance.

Miller et al. reported laparoscopic approach for symptomatic caliceal diverticula with thin overlying renal parenchyma, or for anterior lesions inaccessible to endourological techniques (46). Laparoscopic ultrasonography was a crucial adjunct for stone localization, particularly when parenchyma was not thinned or the precise diverticular cavity site was not readily apparent. Laparoscopic ultrasonography may also aid in locating stones within the renal pelvis during laparoscopic nephro/pyelolithotomy (47). Gill et al. reported combining flexible laparoscopic nephroscopy and flexible laparoscopic ultrasonography to identify calyceal calculi during laparoscopic ureterocalicostomy (48).

Retroperitoneal Space (Ureterolysis and Lymphadenectomy)

In fibrous retroperitoneal tissue after surgery, chemotherapy, or primary retroperitoneal fibrosis, laparoscopic identification of the ureter and the great vessels is sometimes difficult due to the scar formation with loss of normal anatomical landmarks. Trombetta et al. utilized a 7.5 MHz semiflexible laparoscopic Doppler ultrasound probe to identify the ureters adherent to the iliac vessels during a case of ureterolysis for retroperitoneal fibrosis, as well as the location of the renal vein, aorta, and mesenteric artery during retroperitoneal lymphadenectomy in a patient with testicular cancer (49). Laparoscopic ultrasonography can visualize and characterize tissues or lesions beyond those identified by laparoscopic examination, thus extending the repertoire of minimally invasive surgery.

Prostate Surgery

During laparoscopic radical prostatectomy, precise intraoperative identification of the neurovascular bundle, the prostate apex, and location of cancer nodule may potentially enhance postoperative functional outcomes and surgical margin status. Transrectal ultrasonography is currently one of the most precise imaging modalities for the prostate. Ukimura and Gill investigated the technical feasibility and utility of intraoperative real-time transrectal ultrasonography guidance during laparoscopic radical prostatectomy (50–52). The potential advantages of real-time transrectal ultrasonography guided laparoscopic radical prostatectomy were noted to be as follows: (i) visualization of the anatomical course of neurovascular bundle with special reference to its dimension and distance from the edge of the prostate, (ii) objective measurement of the physical adequacy of neurovascular bundle preservation during laparoscopic radical prostatectomy, in terms of preoperative and postoperative dimensions of the neurovascular bundle, number of visible vessels, and resistive index of the arterial flow within the neurovascular bundle, (iii) accurate identification of the prostate apex, (iv) provision for precise dissection of posterior bladder neck, vas deferens, and seminal vesicle, and safe release of the rectal wall, and (v) identification of the location of any hypoechoic nodule with or without suspicious extraprostatic extension in an attempt to decrease positive surgical margins (50–52).

PROSPECTS AND LIMITATIONS FOR LAPAROSCOPIC ULTRASONOGRAPHY AND NEW TECHNOLOGY

The most common applications of laparoscopic ultrasonography have been for hepatobiliary, pancreatic, gastrointestinal, and gynecological surgery. Several authors have reported that laparoscopic ultrasonography has the potential to enhance laparoscopic detection of intraabdominal metastasis and multifocal tumors in patients with gastroesophageal, liver, or pancreatic tumors (53–58). However, laparoscopic ultrasonography is sensitive in detecting macroscopic but not microscopic metastatic pelvic lymph nodes in patients with cervical carcinoma (59).

The recent availability of three-dimensional ultrasonography is an exciting arena for future investigation. Future aspects include the use of navigated three-dimensional laparoscopic ultrasonography in computerized simulation tools for multiple applicators, use of ultrasound energy for reliable tumor destruction, the possibility of highly precise monitoring of the therapeutic ablation while avoiding unnecessary sacrifice of adjacent blood vessels or collecting system (60).

Novel ultrasound technologies including the four-dimensional (dynamic three-dimensional, i.e., three-dimensional plus time) ultrasound imaging system, and the

ultrasound and computed tomography fusion system technology (real-time virtual sonography, providing real-time ultrasound image along with synchronized computed tomography/magnetic resonance imaging) (61) have been reported. These modalities are likely to enhance real-time guidance during tissue ablative therapy. Finally, laparoscopic ultrasonography tissue elastography imaging may help to compensate the laparoscopic surgeon's inability to palpate tissue, which has remained a significant limitation of laparoscopic surgery.

SUMMARY

- Reliable and reproducible real-time intraoperative visualization, without radiation exposure, is a definitive advantage of laparoscopic ultrasonography.
- There is evidence that laparoscopy in combination with laparoscopic ultrasonography results in better outcomes in laparoscopic surgeries such as nephron-sparing surgery, adrenalectomy, decortication of symptomatic renal cysts, marsupialization of difficult pelvic lymphoceles, or renal stone surgery.
- With increasing experiences in minimally invasive, ablative, functional-sparing, or reconstructive procedures, the role of intraoperative ultrasound is likely to expand.

REFERENCES

1. Fukuda M, Mima F, Nakano Y. Studies in echo laparoscopy. *Scand J Gastroenterol* 1982; 17:186–187.
2. Matin SF, Gill IS. Laparoscopic ultrasonography. *J Endourology* 2001; 15:87–92.
3. Kolecki R, Schirmer B. Intraoperative and laparoscopic ultrasound. *Surg Clin North Am* 1998; 78:251–71.
4. Machi J. Intraoperative and laparoscopic ultrasound. *Surg Oncol Clin North Am* 1999; 8:205–226.
5. Thompson DM, Arregui ME. Role of laparoscopic ultrasound in cancer management. *Semin Surg Oncol* 1998; 15:166–175.
6. Heniford BT, Iannitti DA, Hale J, Gagner M. The role of intraoperative ultrasonography during laparoscopic adrenalectomy. *Surgery* 1997; 122:1068–1073.
7. Brunt LM, Bennett HF, Teefey SA, Moley JF, Middleton WD. Laparoscopic ultrasound imaging of adrenal tumors during laparoscopic adrenalectomy. *Am J Surg* 1999; 178:490–495.
8. Kercher KW, Heniford BT, Marroum MC, Greene FL. Laparoscopic intraoperative ultrasonic localization and resection of an extra-adrenal pheochromocytoma. *J Laparoendosc Adv Surg Tech A* 1999; 9:511–515.
9. Gill IS, Meraney AM, Thomas JC, Sung GT, Novick AC, Lieberman I. Thoracoscopic transdiaphragmatic adrenalectomy: the initial experience. *J Urol* 2001; 165:1875–1881.
10. Pautler SE, Choyke PL, Pavlovich CP, Daryanani K, Walther MM. Intraoperative ultrasound aids in dissection during laparoscopic partial adrenalectomy. *J Urol* 2002; 168:1352–1355.
11. Kim JH, Ng CS, Ramani AP, et al. Laparoscopic radical adrenalectomy with adrenal vein tumor thrombectomy: technical considerations. *J Urol* 2004; 171:1223–1226.
12. Hwang J, Shoaf G, Uchio EM, et al. Laparoscopic management of extra-adrenal pheochromocytoma. *J Urol* 2004; 171:72–76.
13. Gill IS. Minimally invasive nephron-sparing surgery. *Urol Clin N Am* 2003; 30:551–579.
14. Desai MM, Gill IS, Ramani AP, Matin SF, Kaouk JH, Campero JM. Laparoscopic radical nephrectomy for cancer with level I renal vein involvement. *J Urol* 2003; 169:487–491.
15. Hsu TH, Jeffrey RB Jr., Chon C, Presti JC Jr. Laparoscopic radical nephrectomy incorporating intraoperative ultrasonography for renal cell carcinoma with renal vein tumor thrombus. *Urology* 2003; 61:1246–1248.
16. Gill IS, Desai MM, Kaouk JH, et al. Laparoscopic partial nephrectomy for renal tumor: duplicating open surgical techniques. *J Urol* 2002; 167:469–476.
17. Steinberg AP, Abreu SC, Desai MM, Ramani AP, Kaouk JH, Gill IS. Laparoscopic nephron-sparing surgery in the presence of renal artery disease. *Urology* 2003; 62:935–939.
18. Gill IS, Novick AC, Sobble JJ, et al. Laparoscopic renal cryoablation: initial clinical series. *Urology* 1998; 52:543–551.
19. Gill IS, Remer EM, Hasan WA, et al. Renal cryoablation: outcome at 3 years. *J Urol* 2005; 173:1903–1907.
20. Rodriguez R, Chan DY, Bishoff JT, et al. Renal ablative cryosurgery in selected patients with peripheral renal masses. *Urology* 2000; 55:25–30.
21. Nadler RB, Kim SC, Rubenstein JN, Yap RL, Campbell SC, User HM. Laparoscopic renal cryosurgery: the Northwestern experience. *J Urol* 2003; 170:1121–1125.
22. Lee DI, McGinnis DE, Feld R, Strup SE. Retroperitoneal laparoscopic cryoablation of small renal tumors: intermediate results. *Urology* 2003; 61:83–88.
23. Uchida M, Imaide Y, Sugimoto K, Uehara H, Watanabe H. Percutaneous cryoablation for renal tumors. *Br J Urol* 1995; 75:132–136.
24. Feld RI, McGinnis DE, Needleman L, Segal SR, Strup SE, Nazarian LN. A novel application for the end-fire sonographic probe: guidance during cryoablation of renal masses. *Am J Roentgenol* 1999; 173:652–654.
25. Remer EM, Hale JC, O'Malley CM, Godec K, Gill IS. Sonographic guidance of laparoscopic renal cryoablation. *Am J Roentgenol* 2000; 174:1595–1596.

26. Chosy SG, Nakada SY, Lee FT Jr., Warner TF. Monitoring renal cryosurgery: predictors of tissue necrosis in swine. *J Urol* 1998; 159:1370–1374.
27. Baust J, Gage AA, Ma H, et al. Minimally invasive cryosurgery—technological advances. *Cryobiology* 1997; 34:373–384.
28. Zlotta AR, Wildschutz T, Raviv G, et al. Radio Frequency interstitial tumor ablation (RITA) is a possible new modality for the treatment of renal cancer: ex vivo and in vivo experience. *J Endourol* 1997; 11:251–258.
29. Gervais DA, McGovern FJ, Arellano RS, MsDougal WS, Mueller PR. Renal cell carcinoma: clinical experience and technical success with radio-frequency ablation of 42 tumors. *Radiology* 2003; 226:417–424.
30. Ukimura O, Kawauchi A, Fujito A, et al. Radio-frequency ablation of renal cell carcinoma in patients who were at significant risk. *Int J Urol* 2004; 11:1051–1057.
31. Varghese T, Zagzebski JA, Chen Q, et al. Ultrasound monitoring of temperature change during radiofrequency ablation: preliminary in-vivo results. *Ultrasound Med Biol* 2002; 28:321–329.
32. Vallencien G, Chartier-Kasteler E, Chopin D, Veillon B, Brisset JM, Andre-Bougaran J. Focused extracorporeal pyrotherapy: experimental results. *Eur Urol* 1991; 20:211–219.
33. Vallancien G, Harouni M, Meillon B, et al. Focused extracorporeal pyrotherapy: feasibility study in man. *J Endourol* 1992; 6:173–181.
34. Harvey CJ, Pilcher JM, Eckersley RJ, Blomley MK, Cosgrove DO. Advances in ultrasound. *Clin Radiol* 2002; 57:157–177.
35. Paterson RF, Barret E, Siqueira TM, et al. Laparoscopic partial kidney ablation with high intensity focused ultrasound. *J Urol* 2003; 169:347–351.
36. Munch LC, Gill IS, McRoberts W. Laparoscopic retroperitoneal renal cystectomy. *J Urol* 1994; 151:135–138.
37. Brown JA, Torres VE, King BF, Segura JW. Laparoscopic marsupialization of symptomatic polycystic kidney disease. *J Urol* 1996; 156:22–27.
38. Elashry OM, Nakada SY, Wolf JS Jr., McDougall EM, Clayman RV. Laparoscopy for adult polycystic kidney disease: a promising alternative. *Am J Kidney Dis* 1996; 27:224–233.
39. Lee DJ, Andreoni CR, Rehman J, et al. Laparoscopic cyst decortication in autosomal dominant polycystic kidney disease: impact on pain, hypertension, and renal function. *J Endourol* 2003; 17:345–354.
40. Gill IS, Hodge EE, Munch LC, Goldfarb DA, Novick AC, Lucas BA. Transperitoneal marsupialization of lymphoceles: a comparison of laparoscopic and open techniques. *J Urol* 1995; 153:3706–3711.
41. Hsu TH, Gill IS, Grune MT, et al. Laparoscopic lymphocelelectomy: a multi-institutional analysis. *J Urol* 2000; 163:1096–1098.
42. Oyen O, Siwach V, Line PD, et al. Improvement of post-transplant lymphocele treatment in the laparoscopic era. *Transpl Int* 2002; 15:406–410.
43. Ishitani MB, DeAngelis GA, Siström CL, Rodgers BM, Pruett TL. Laparoscopic ultrasound-guided drainage of lymphoceles following renal transplantation. *J Laparoendosc Surg* 1994; 4:61–64.
44. Lucas BA, Gill IS, Munch LC. Intraperitoneal drainage of recurrent lymphoceles using an internalized Tenckhoff catheter. *J Urol* 1994; 151:970–972.
45. Van Cangh PJ, Abi Aad AS, Lorge F, Wese FX, Opsomer R. Laparoscopic nephrolithotomy: the value of intracorporeal sonography and color Doppler. *Urology* 1995; 45:516–519.
46. Miller SD, Ng CS, Streem SB, Gill IS. Laparoscopic management of caliceal diverticular calculi. *J Urol* 2002; 167:1248–1252.
47. Gaur DD, Agarwal DK, Purohit KC, Darshane AS. Retroperitoneal laparoscopic pyelolithotomy. *J Urol* 1994; 151:927–929.
48. Gill IS, Cherullo EE, Steinberg AP, et al. Laparoscopic ureterocalicostomy: initial experience. *J Urol* 2004; 171:1227–1230.
49. Trombetta C, Liguori G, Savoca G, Siracusano S. Intralaparoscopic ultrasound and Doppler sonography in urology. *Tech Urol* 1996; 2:165–170.
50. Ukimura O, Gill IS, Desai MM, et al. Intraoperative real-time transrectal ultrasonography during laparoscopic radical prostatectomy. *J Urol* 2004; 172:112–118.
51. Ukimura O, Gill IS. Real-time transrectal ultrasound guidance during nerve sparing laparoscopic radical prostatectomy: Pictorial essay. *J Urol* 2006; 175:1311–1319.
52. Ukimura O, Magi-Galluzzi C, Gill IS. Real-time transrectal ultrasound guidance during nerve sparing laparoscopic radical prostatectomy: impact on surgical margins. *J Urol* 2006; 175:1304–1310.
53. Foroutani A, Garland AM, Berber E, et al. Laparoscopic ultrasound vs triphasic computed tomography for detecting liver tumors. *Arch Surg* 2000; 135:933–938.
54. Flett ME, Lim MN, Bruce D, Campbell SH, Park KG. Prognostic value of laparoscopic ultrasound in patients with gastro-esophageal cancer. *Dis Esophagus* 14:223–226, 2001.
55. Tait IS, Yong SM, Cuschieri SA. Laparoscopic in situ ablation of liver cancer with cryotherapy and radiofrequency ablation. *Br J Surg* 2002; 89:1613–1619.
56. Kwon AH, Inui H, Kamiyama Y. Preoperative laparoscopic examination using surgical manipulation and ultrasonography for pancreatic lesions. *Endoscopy* 2002; 34:464–468.
57. Zhao ZW, He JY, Tan G, Wang HJ, Li KJ. Laparoscopy and laparoscopic ultrasonography in judging the resectability of pancreatic head cancer. *Hepatobiliary Pancreat Dis Int* 2003; 2:609–611.
58. Berber E, Garland AM, Engle KL, Rogers SJ, Siperstein AE. Laparoscopic ultrasonography and biopsy of hepatic tumors in 310 cases. *Am J Surg* 2004; 187:213–218.
59. Cheung TH, Lo WK, Yu MY, Yang WT, Ho S. Extended experience in the use of laparoscopic ultrasound to detect pelvic nodal metastasis in patients with cervical carcinoma. *Gynecol Oncol* 2004; 92:784–788.
60. Harms J, Feussner H, Baumgartner M, Schnerider A, Donhauser M, Wessels G. Three-dimensional navigated laparoscopic ultrasonography. First experiences with a new minimally invasive diagnostic device. *Surg Endosc* 2001; 15:1459–1462.
61. Ukimura O, Kaouk J, Remer E, et al. Real-time virtual sonography guided percutaneous radiofrequency ablation of renal tumor: initial experience. 101st American Urological Association Annual Meeting, Atlanta, May 19–24, 2006; *J Urol* 175 (suppl), Abstract #V1562 & #1717.

Yair Lotan and Jeffrey A. Cadeddu*Department of Urology, University of Texas Southwestern
Medical Center, Dallas, Texas, U.S.A.*

- INTRODUCTION
- THE IMPORTANCE OF PERSPECTIVE
- COST VS. CHARGE
 - Direct Costs
 - Indirect Costs
- CURRENT FINANCIAL STATE OF
LAPAROSCOPIC PROCEDURES
- LAPAROSCOPIC NEPHRECTOMY
- LAPAROSCOPIC PROSTATECTOMY
- SUMMARY
- REFERENCES

INTRODUCTION

The rise in national health-care costs has appropriately led to close scrutiny of the cost of new technologies. As the field of laparoscopy has matured, the focus is shifting from feasibility of techniques to utility and effectiveness. Along these lines, one aspect that is increasingly emphasized is the financial implications of laparoscopy. Prior to introduction of the technique, such issues as operative time and length of hospital stay did not play an important role in managing health-care costs. However, with the advent of laparoscopy, the decreased morbidity associated with laparoscopic techniques has highlighted cost advantages associated with decreased hospital stays. On the other hand, increased operative times and expensive equipment are noted as detrimental financial aspects.

This chapter is written to evaluate the various aspects of laparoscopy that impact health care-related costs and financial issues. There is no doubt that the safety and efficacy of a laparoscopic procedure is the most important determinant of whether a procedure should be performed. However, one cannot ignore the importance of cost in today's society and must recognize that responsible medical care requires physicians to consider the cost implications of various treatments. We will focus on costs associated with equipment, operative time, length of hospital stay, reimbursement rates, and both direct and indirect costs associated with laparoscopic surgery.

THE IMPORTANCE OF PERSPECTIVE

Any discussion of financial implications of laparoscopy must be examined from the perspective of the payer. However, in the U.S. health-care system, there are three "payer" perspectives: that of society, the hospital, and the patient. The perspective of the patient is the most difficult and subjective to evaluate as it depends on the patient's individual insurance, deductible level, and employment status.

The hospital's perspective usually includes most of the direct costs and is easier to measure. Furthermore, the patient perspective cost is directly related to this as the hospital cost is eventually charged to the patient. The hospital costs include the resources required to perform a procedure and immediate postoperative care. These, in addition to physician fees, represent the majority of costs from surgical procedures that do not include long-term postoperative care. Importantly, one should note that within each hospital system, the budget is divided into different departments. Savings garnered by decreased length of stay may decrease overall hospital cost, but may increase operating room supply costs (e.g., laparoscopy). Hospital administrations must, therefore, take a broader look at the financial implications of new technologies as they affect different cost centers in different ways.

The perspective of society involves both direct and indirect costs. As Medicare plays a large role in financing health care, a significant percentage of direct costs affect the overall national health-care budget. Society also is influenced by loss of productivity that results during the recovery phase of the postoperative period. These indirect costs can be difficult to measure, but can represent a significant loss of gross national revenue.

COST VS. CHARGE

It is difficult to evaluate the cost-effectiveness of a technique without comparing similar units of measurement. Many published evaluations use charge figures provided by the hospital system (1). These numbers are typically easier to obtain than cost figures, but do not reflect the true resource allocation as they account for profit margins. Different services in a hospital have different cost-to-charge ratios. Furthermore, rates for items, such as room and board, typically are determined based on the need to pay for both utilities, such as electricity and water, as well as services such as nurses' salaries. Also, as third party payer reimbursement of charges varies, what a hospital health-care system charges for laparoscopic surgery, gets paid, and actual costs can be very different. As such, when evaluating health system costs of a procedure or technology across a spectrum of hospitals and payers, actual costs, and not charges, must be reported.

Nevertheless, cost analyses of laparoscopic surgery can still be ambiguous. One issue is difficulty with the accurate assessment of the cost of capital equipment. Such items as a robot, laparoscopic ultrasound, camera, and televisions are usually paid from operating room capital budgets and amortized over many years. Depreciation costs and usage per case can only then be estimated. Conversely, costs of disposable equipment can be established with more accuracy but are still influenced by the vendor contract, which varies based on the volume of purchase.

Direct Costs

The three main components that determine the cost-effectiveness of laparoscopic procedures are laparoscopic equipment, operative time and length of hospital stay (2–8).

Equipment

A major difference in operative costs between open and laparoscopic surgery results from the added expense of specialized equipment. Equipment costs associated with laparoscopic surgery include capital and individual case costs. Items included in capital costs can have a relatively low per case cost, such as monitors, cameras, and CO₂ insufflators or can be expensive, such as the *da Vinci*[®] Surgical Robot.^a

- Capital equipment that is multipurpose (i.e., used for endoscopy—monitors and cameras) and is used by different specialties contributes minimal added expense on a per case basis.
- On the other hand, the *da Vinci* robot, which costs over \$1.4 million with a \$100,000 yearly service contract, can add over \$1000 per case even if utilized for 300 cases per year and amortized over seven years (7).

Such costs are not reimbursed to the hospital on a case basis and, in the case of the robot, can represent a significant financial burden.

The cost of operative equipment used during laparoscopic surgery can also vary significantly. Certain items such as trocars can be reusable or disposable while the decision about which hemostatic technology to use [e.g., Hem-O-Lok[®] clips^b (\$20) vs. an endoscopic stapler (Endo-GIA[®] at \$144 or with reticulating load at \$161) or endoscopic 5-mm clip applier^c (\$183)] can significantly influence the overall operative cost. For those performing hand-assisted laparoscopic procedures, a Gelport[®] Kit^d comes with a 10-mm clip applier, 2- to 12-mm and 2- to 5-mm trocars, but costs \$495. In specialized procedures, such as laparoscopic partial nephrectomy, the cheapest option to achieve hemostasis is suturing but this is technically difficult. Adjunct technologies such as

^aIntuitive Surgical Inc., Sunnyvale, CA.

^bWeck Closure Systems, Research Triangle Park, NC.

^cU.S. Surgical Corp., Norwalk, CT.

^dApplied Medical, Rancho Santa Margarita, CA.

^eFusion Medical Technologies, Mountain View, CA.

radiofrequency coagulation can add over \$1000 per case in equipment cost (8). Furthermore, agents such as fibrin glue and FloSeal® Matrix^e can cost an additional \$410 and \$192, respectively (9).

One factor that will affect operative cost is the change in cost of laparoscopic equipment with time. Though one would expect equipment costs to decrease with time (analogous to the retail personal computer market), in evaluating costs from two major suppliers of generic laparoscopic equipment (trocars, clip-appliers, staplers, endocatch bags) from the year 2000 to 2004, we found an increase in prices across the board of greater than 4% annually for hospitals with high volume contracts, despite an increase in number of procedures performed nationwide. The increase was even greater for hospitals with lower volume. Unfortunately, there is also no incentive at this time for reducing the cost of robot-related products due to the lack of market competition.

Operative times play a large role in determining overall operative cost as most hospitals incur a start-up cost for a procedure with additional costs calculated at 15- or 30-minute intervals.

Operative Times

Operative times play a large role in determining overall operative cost as most hospitals incur a start-up cost for a procedure with additional costs calculated at 15- or 30-minute intervals.

The cost of anesthesia also increases at similar time intervals. As such, each additional hour in the operating room can range between \$600 at our county hospital and \$1400 at the local children's hospital (6,10). Since the learning curve for many laparoscopic procedures is reflected in the operative time, urologists at the start of their learning curves will incur significantly more costly procedures overall. The impact can be significant as learning curves vary widely by procedure. For hand-assisted laparoscopic nephrectomy, Patel et al. reported that their operative time decreased from over 275 to less than 175 minutes only after their first 40 cases (11). Even more discouraging, Guillonneau et al. performed laparoscopic radical prostatectomy in over four hours for the first 100 cases before reaching a rate just under three hours (174 minutes) (12). On the other hand, some claim shortened learning curves and operative times with use of robot-assisted technology. Ahlering et al. noted a learning curve of only 12 patients to reach four-hour proficiency for robot-assisted prostatectomy with the mean operating time subsequently decreasing to 3.45 hours (range 2.5–5.1) (13). Whether this is sufficient to overcome the costs of the robotic technology remains to be demonstrated (7).

The main financial advantage for laparoscopy is the decreased hospital stay.

Hospital Stay

The main financial advantage for laparoscopy is the decreased hospital stay. Room and board costs per day at our institution are approximately \$400 and charges are significantly higher. As such, the reduced number of inpatient hospital days and earlier return of diet allows for costs saving both in room and board and intravenous fluids and medication. Such savings can compensate for added expenses in the operating room and result in cost superiority of some procedures, such as laparoscopic partial, radical and donor nephrectomy (2,8,14). Other procedures can become cost-equivalent/superior depending on the surgeon's operative time and length of stay at the hospital (3,4,6).

Reimbursement Rates

There are two competing issues that affect urologists' income from surgical procedures: reimbursement rates and operative time. While the operative approach should not be affected by prospective income from a procedure and, in an ideal world, a urologist should be reimbursed for the work and effort provided, this is not the case. In general, Medicare reimbursement rates for urologic procedures have decreased over the last 10 years. The Medicare reimbursement rates in Texas over the last 10 years for radical retropubic prostatectomy and radical nephrectomy decreased \$668 (\$2262 vs. \$1594) and \$457 (\$1700 vs. \$1243), respectively (15). Fortunately, reimbursement for laparoscopy procedures, such as radical nephrectomy, prostatectomy, and pyeloplasty, has stayed stable (<\$30 change) from 2001 to 2004. However, laparoscopic Medicare reimbursement rates, in 2004, are only slightly higher than open equivalent reimbursement rates for nephrectomy (\$92), prostatectomy (\$95), and pyeloplasty (\$147).

The net effect is a disincentive to perform laparoscopy due to the learning curve and increased operative times for many procedures.

Literature reviews performed to compare operative times for common procedures uniformly demonstrate shorter times for open versus laparoscopic procedures.

The net effect is a disincentive to perform laparoscopy due to the learning curve and increased operative times for many procedures.

Open surgery is shorter than laparoscopic pyeloplasty (168 minutes vs. 180 minutes) (4) and radical retropubic prostatectomy is on an average 40 minutes shorter than laparoscopic prostatectomy (160 minutes vs. 200 minutes) (7,12,16–19). Although nephrectomy times reported are similar between open and laparoscopic techniques among experienced laparoscopists (20) the (6,21–24) times are achieved only after the learning curve has been overcome. Urologists early in their learning curve have longer operative times. As such, the current reimbursement rates may not provide equal compensation for laparoscopic procedures on an hourly basis (15).

Indirect Costs

While the direct costs associated with laparoscopy are easiest to evaluate, the indirect cost advantages of laparoscopy should not be overlooked. Many patients who require urologic procedures are productive participants in the national economy. So, loss of global revenue due to loss of work impacts the entire health-care system. The earlier return to work that has been demonstrated for numerous laparoscopic procedures should not be overlooked. Dunn et al. reported a 4.5-week quicker return to normal activity for laparoscopic nephrectomy patients compared with a matched series of open nephrectomy patients (1). Buell et al. noted that patients after hand-assisted donor nephrectomy returned to work 25 days earlier than after open donor nephrectomy (29.1 days vs. 54.3 days; $p < 0.05$, respectively). Bhayani et al. found that time to complete convalescence was 30 days versus 47 days after laparoscopic radical prostatectomy and radical retropubic prostatectomy, respectively (25). Similar findings were found by Rassweiler et al. with a convalescence time of 27 days versus 52 days after laparoscopic radical prostatectomy and radical retropubic prostatectomy, respectively (19). As such, patients after laparoscopic procedures routinely return to work earlier and contribute to the national economy. According to the 2001 Census of Population and Housing from the United States Census Bureau, the average American worker earned approximately \$141 per day in 2000 dollars. So, a 15-day difference in return to work has a value to society of \$2115, which would clearly eliminate the incremental cost of most laparoscopic procedures.

CURRENT FINANCIAL STATE OF LAPAROSCOPIC PROCEDURES

As experience with laparoscopy has increased and operative times have improved, some laparoscopic procedures such as laparoscopic nephrectomy and partial nephrectomy have been shown to be cost superior despite higher equipment costs (2,8). On the other hand, procedures such as laparoscopic pyeloplasty, hand-assisted nephrectomy, donor nephrectomy, retroperitoneal lymph node dissection, and prostatectomy are more expensive but can reach cost-equivalence depending on a surgeon's individual operative time and length of hospital stay (3,4,6,7,26).

At this time, however, robot-assisted prostatectomy is significantly more costly than open surgery due to the cumulative added expense of robot purchase and maintenance, along with individual case equipment costs (7).

Currently, the most common urologic diseases to which laparoscopic techniques are applicable include kidney and prostate cancer. Understanding the economics of these procedures offers insight into the direction of laparoscopy as a whole.

LAPAROSCOPIC NEPHRECTOMY

While initial evaluations of laparoscopic nephrectomy found that the technique was more costly than open nephrectomy (1,27), we found that reductions in operative time and length of stay have allowed laparoscopic nephrectomy to be cost superior (Table 1) (2,14). Sensitivity analyses demonstrate that laparoscopic nephrectomy is cost superior with length of stay less than four days and operative time less than four hours (Fig. 1). Patients after laparoscopic nephrectomy are routinely discharged in less than four days (2,21,28,29) and operative times by experienced laparoscopists are invariably less than four hours (2,20–23). Short operative times can also compensate for increased equipment costs (Fig. 2).

As such, laparoscopic nephrectomy is a cost superior procedure when evaluating both direct and indirect costs.



At this time, however, robot-assisted prostatectomy is significantly more costly than open surgery due to the cumulative added expense of robot purchase and maintenance, along with individual case equipment costs.

As such, laparoscopic nephrectomy is a cost superior procedure when evaluating both direct and indirect costs.

TABLE 1 ■ Cost Comparison of Open and Laparoscopic Nephrectomy

	Laparoscopic nephrectomy (mean ± SD)	Open nephrectomy (mean ± SD)	p value ^a
Anesthesiologist fees ^b	348 ± 64	335 ± 36	0.625
Surgeon's fees ^c	1152	1474	<0.001 ^d
Total OR (OR costs + supplies) ^f	3557 ± 759	2487 ± 271	0.003 ^d
OR costs	2435 ± 496	2332 ± 283	0.625
Surgical supplies	1122 ± 361	155 ± 65	<0.001 ^d
Anesthesia costs (hospital)	229 ± 34	260 ± 37	0.075
Length of stay (day)	3.3 ± .91	6.1 ± 1.73	<0.001
Room and board ^e	1293 ± 357	2419 ± 682	<0.001
Studies (laboratory/radiology)	136 ± 31	255 ± 53	<0.001
Pharmacy (medications + supplies)	232 ± 110	484 ± 154	<0.001
Intravenous solutions	112 ± 66	315 ± 152	<0.001
Infusion pump	36 ± 24	93 ± 68	0.02
Hospital costs (all inclusive)	5968 ± 977	6870 ± 1182	0.097
Overall cost (hospital costs + professional fees)	7468 ± 1036	8679 ± 1195	0.037

^aStudent's *t*-test unless otherwise indicated.
^bAnesthesiologist fees based on 2000 Medicare (Texas) reimbursement rates of \$18 per unit.
^cSurgeon fees based on 2000 Medicare reimbursement.
^dMann-Whitney Rank Sum test.
^eRoom and board cost is \$395 per day.
^fLaparoscopic supplies include such disposable costs as: one Veress needle, one Visiport device, two to three disposable trocars, two to three endovascular staplers, one to two 5-mm clip appliers, and one laparoscopic sack.
Abbreviation: OR, operating room.
Source: From Ref. 2.

**FIGURE 1 ■** Two-way sensitivity analysis comparing costs for different operating times and lengths of hospitalization for laparoscopic nephrectomy. Source: From Ref. 2.**FIGURE 2 ■** Two-way sensitivity analysis comparing different costs of laparoscopic equipment and lengths of hospitalization for laparoscopic nephrectomy. Source: From Ref. 2.

LAPAROSCOPIC PROSTATECTOMY

Radical prostatectomy is the most common therapy for patients with prostate cancer and accounts for approximately half of the \$1.7 billion cost of prostate cancer treatment (30). In evaluating the cost of radical retropubic prostatectomy as compared to laparoscopic and robot-assisted prostatectomy, we found that radical retropubic prostatectomy was the least expensive approach with a cost advantage of \$487 and \$1726 over laparoscopic radical prostatectomy and robot-assisted prostatectomy, respectively (Table 2) (7). Even if the initial cost of purchasing a robot is excluded, the cost difference between radical retropubic prostatectomy and robot-assisted prostatectomy is \$1155.

TABLE 2 ■ Individual and Overall Costs for Radial Retropubic Prostatectomy, Laparoscopic Radical Prostatectomy, and Robot-Assisted Prostatectomy

Cost center	RRP (\$)	LRP (\$)	RAP ^a (\$)
Overall cost	5554	6041	7280
Operating room cost	2428	2876	2204
Equipment	75	533	1705
Surgeon professional fee	1594	1688	1688
Hospital room and board	988	514	474
Intravenous fluids/meds	150	78	72
Robot cost/ case (purchase + maintenance)	NA	NA	857

^aRobot purchase cost included.
Abbreviations: RRP, radical retropubic prostatectomy; LRP, laparoscopic radical prostatectomy; RAP, robot-assisted prostatectomy; NA, not applicable.
Source: From Ref. 7.




FIGURE 3 ■ Two-way sensitivity analysis evaluating costs of robot purchase and RAP (robot-assisted prostatectomy) equipment (assuming \$100,000 per year maintenance cost). Abbreviation: RAP, Robot-Assisted Prostatectomy. Source: From Ref. 7.




FIGURE 4 ■ Two-way sensitivity analysis evaluating laparoscopic radical prostatectomy length of stay and operating room time. Source: From Ref. 7.

This large difference in radical retropubic prostatectomy and robot-assisted prostatectomy costs resulted from a cost of \$857 per case, to pay for purchase and maintenance of the robot, and the high cost of equipment of \$1705. Even shorter operating room time (140 minutes vs. 160 minutes) and length of stay 1.2 days vs. 2.5 days) did not compensate for the added expenditure. At current costs for the robot (purchase, maintenance, and equipment) there is no individual decrease in length of stay or operating room time that would make robot-assisted prostatectomy cost-equivalent to radical retropubic prostatectomy. In order for robot-assisted prostatectomy to realistically become cost-equivalent or superior, there needs to be a decrease in both the purchase price of the robot and the cost of equipment per case (Fig. 3) (7).

Laparoscopic radical prostatectomy also costs more than radical retropubic prostatectomy primarily secondary to equipment costs (\$533) as the shorter length of stay (1.3 days vs. 2.5 days) compensates for the longer operating room time (200 minutes vs. 160 minutes). However, decreases in both length of stay and operating room time for laparoscopic radical prostatectomy will allow cost equivalence with radical retropubic prostatectomy (Fig. 4). Similarly, small decreases in equipment costs in conjunction with shorter operating room times can make laparoscopic radical prostatectomy financially superior (Fig. 5). Thus, while radical retropubic prostatectomy is currently the least costly approach, laparoscopic radical prostatectomy is cost-competitive with radical retropubic prostatectomy, whereas robot-assisted prostatectomy will require a significant reduction in the cost of the device and maintenance fees to be financially justified.

FIGURE 5 ■ Two-way sensitivity analysis evaluating laparoscopic radical prostatectomy equipment costs and operating room time.
Source: From Ref. 7.



SUMMARY

- The cost of a procedure should always be a secondary factor in determining the best treatment for an individual patient.
- However, with increasing national health-care costs, economic considerations are playing a greater role in medical care.
- Institutions and insurance companies are closely supervising expenditures and do influence the types of treatments available to physicians and patients.
- The development of drugs and new technologies by the health-care industry is also strongly driven by economic considerations.
- In order for physicians to be able to continue to provide the best and least morbid treatment, there is a need to understand the economic implications of different treatment modalities and strive to practice with fiscal responsibility.

REFERENCES

1. Dunn MD, McDougall EM, Clayman RV. Laparoscopic radical nephrectomy. *J Endourol* 2000; 14:849; discussion 855–887.
2. Lotan Y, Gettman MT, Roehrborn CG, Pearle MS, Cadeddu JA. Cost comparison for laparoscopic nephrectomy and open nephrectomy: analysis of individual parameters. *Urology* 2002; 59:821.
3. Ogan K, Lotan Y, Koeneman K, Pearle MS, Cadeddu JA, Rassweiler J. Laparoscopic versus open retroperitoneal lymph node dissection: a cost analysis. *J Urol* 2002; 168:1945; discussion 1949.
4. Gettman MT, Lotan Y, Roehrborn CG, Cadeddu JA, Pearle MS. Cost-effective treatment for ureteropelvic junction obstruction: a decision tree analysis. *J Urol* 2003; 169:228.
5. Lotan Y, Gettman MT, Roehrborn CG, Pearle MS, Cadeddu JA. Laparoscopic nephrectomy is cost effective compared with open nephrectomy in a large county hospital. *JSL* 2003; 7:111.
6. Lotan Y, Duchene DA, Cadeddu JA, Koeneman KS. Cost comparison of hand assisted laparoscopic nephrectomy and open nephrectomy: analysis of individual parameters. *J Urol* 2003; 170:752.
7. Lotan Y, Cadeddu JA, Gettman MT. The new economics of radical prostatectomy: cost comparison of open, laparoscopic and robot-assisted techniques. *J Urol* 2004; 172(4pt):1431–1435.
8. Lotan Y, Venkatesh R, Cadeddu JA, Landman J. Cost comparison for laparoscopic partial nephrectomy and open partial nephrectomy: analysis of individual parameters. *J Endourol* 2003; 17 (suppl 1):A98.
9. User HM, Nadler RB. Applications of FloSeal in nephron-sparing surgery. *Urology* 2003; 62:342.
10. Lorenzo AJ, Samuelson ML, Docimo SG, Baker LA, Lotan Y. Cost analysis of laparoscopic versus open orchiopexy in the management of unilateral non-palpable testicles. *J Urol* 2004; 172(2):712–716.
11. Patel V, Leveillee R, Blackmon M. Hand assisted laparoscopic nephrectomy: the learning curve and beyond. *J Endourol* 2002; 16(suppl 1):A160.
12. Guillonnet B, Rozet F, Cathelineau X, et al. Perioperative complications of laparoscopic radical prostatectomy: the Montsouris 3-year experience. *J Urol* 2002; 167:51.
13. Ahlering TE, Skarecky D, Lee D, Clayman RV. Successful transfer of open surgical skills to a laparoscopic environment using a robotic interface: initial experience with laparoscopic radical prostatectomy. *J Urol* 2003; 170:1738.
14. Kuo PC, Johnson LB, Sitzmann JV. Laparoscopic donor nephrectomy with a 23-hour stay: a new standard for transplantation surgery. *Ann Surg* 2000; 231:772.
15. Lotan Y, Cadeddu JA, Roehrborn CG, Stage KH. The value of your time: evaluation of changes in medicare reimbursement rates on the practice of urology. *J Urol* 2004; 172(5pt):1858–1862.

16. Benoit RM, Cohen JK. The relationship between quality and costs: factors that affect the hospital costs of radical prostatectomy. *Prostate Cancer Prostatic Dis* 2001; 4:213.
17. El-Feel A, Davis JW, Deger S, et al. Laparoscopic radical prostatectomy-an analysis of factors affecting operating time. *Urology* 2003; 62:314.
18. Lepor H, Kaci L. Contemporary evaluation of operative parameters and complications related to open radical retropubic prostatectomy. *Urology* 2003; 62:702.
19. Rassweiler J, Seemann O, Schulze M, Teber D, Hatzinger M, Frede T. Laparoscopic versus open radical prostatectomy: a comparative study at a single institution. *J Urol* 2003; 169:1689.
20. Jeschke K, Zussner F, Wakonig J, Meixel H, Henning K. Laparoscopic radical nephrectomy for RCC-single center experience with 215 patients in 54 month. *J Endourol* 2002; 16(suppl 1):A45.
21. Gill IS, Meraney AM, Schweizer DK, et al. Laparoscopic radical nephrectomy in 100 patients: a single center experience from the United States. *Cancer* 2001; 92:1843.
22. Guillonneau B, Bermudez H, Adomo-Rosa J, et al. Five years of experience in laparoscopic radical nephrectomy. *J Endourol* 2002; 16(suppl 1):A45.
23. Janetschek G, Jeschke K, Peschel R, Strohmeier D, Henning K, Bartsch G. Laparoscopic surgery for stage T1 renal cell carcinoma: radical nephrectomy and wedge resection. *Eur Urol* 2000; 38:131.
24. Grosso G, Pecoraro G, Grossi FS. Laparoscopic retroperitoneal radical nephrectomy: single center institution experience. *J Endourol* 2002; 16(suppl 1):A44.
25. Bhayani SB, Pavlovich CP, Hsu TS, Sullivan W, Su LM. Prospective comparison of short-term convalescence: laparoscopic radical prostatectomy versus open radical retropubic prostatectomy. *Urology* 2003; 61:612.
26. Buell JF, Hanaway MJ, Potter SR, et al. Hand-assisted laparoscopic living-donor nephrectomy as an alternative to traditional laparoscopic living-donor nephrectomy. *Am J Transplant* 2002; 2:983.
27. Wolf JS Jr, Marcovich R, Merion RM, Konnak JW. Prospective, case matched comparison of hand assisted laparoscopic and open surgical live donor nephrectomy. *J Urol* 2000; 163:1650.
28. Nelson CP, Wolf JS Jr. Comparison of hand assisted versus standard laparoscopic radical nephrectomy for suspected renal cell carcinoma. *J Urol* 2002; 167:1989.
29. Dunn MD, Portis AJ, Shalhav AL, et al. Laparoscopic versus open radical nephrectomy: a 9-year experience. *J Urol* 2000; 164:1153.
30. Gardner TA, Bissonette EA, Petroni GR, McClain R, Sokoloff MH, Theodorescu D. Surgical and postoperative factors affecting length of hospital stay after radical prostatectomy. *Cancer* 2000; 89:424.

LAPAROSCOPIC SURGERY AND THE COMMUNITY UROLOGIST

Scott D. Miller

Georgia Urology, Atlanta, Georgia, U.S.A.

- INTRODUCTION
- THE PRIVATE PRACTICE MODEL
- PATIENT OUTCOME
- BUILDING A LAPAROSCOPIC PRACTICE
 - Full-Time Commitment
 - Education
 - Technique

- Equipment
- Personnel
- Corporate Support and Marketing
- Networking
- SUMMARY
- REFERENCES

The true virtue of any medical technology is its ability to cross into the community setting. Only a portion of urologic disorders amenable to laparoscopic management are currently performed in this manner.

INTRODUCTION

Urologic laparoscopy has dramatically progressed over the past 10 years (1). To date, however, the large experiences exist mainly at academic centers.

The true virtue of any medical technology is its ability to cross into the community setting. Only a portion of urologic disorders amenable to laparoscopic management are currently performed in this manner (2–4).

Despite the increase in urologic laparoscopy fellowship training programs and laparoscopy experience in residency training programs, the current patient demand exceeds the availability of this surgical approach (5,6). This chapter focuses on the feasibility and methods of developing a full-service urologic laparoscopy practice in a community setting. These concepts, based on the experience of a nonfellowship trained surgeon, are pertinent to both the inexperienced and the formally trained laparoscopist. Regardless of previous training, continuous development is essential to succeed in this demanding arena.

THE PRIVATE PRACTICE MODEL

Between August 1995 and April 2004, 1092 advanced urologic laparoscopic procedures were performed by a single surgeon in a metropolitan area serving a population greater than three million people. Although these procedures took place in eight different facilities, more than 75% occurred at the same 450-bed hospital in order to simplify reproducibility. Because the early 1990s marked the infancy of modern urologic laparoscopy, no formal training was readily available. However, previous exposure included involvement in approximately 20 pure laparoscopic nephrectomies and various other less demanding laparoscopic procedures during residency training. Although only a small number of procedures were performed in the first year, the volume subsequently grew exponentially as a member of a four-physician group. During the third year, further growth occurred after merging with a large group totaling thirty urologists. However, partner referrals have only comprised between 15% and 40% of total laparoscopic procedures performed annually. The low proportion of internal referrals reflects initial reluctance to embrace the technology, geographical logistics, increasing outside referrals, and improved laparoscopic skills of the other physicians within the group.

Extreme care was used to balance the difficulty of the procedure with the level of “expertise” at the time. The chief considerations were patient anatomy (e.g., body habitus, previous surgery), comorbid conditions, and complexity of the urologic condition. With time, the indications for laparoscopic management of common urologic disorders expanded widely. Table 1 depicts the variety of patient characteristics. With experience, seemingly challenging endeavors can be overcome. Although various types of

TABLE 1 ■ Patient Characteristics

Age	1 mo–96 yr
Body mass index	16–52
Largest renal tumor	14 cm
Extra/retroperitoneal	96%
Prostate size	18–166 g

With carefully planned strategies, advanced urologic laparoscopy in a community setting can yield results comparable to major academic centers. The importance of balancing the complexity of procedures with the experience of the surgeon cannot be overemphasized.

TABLE 2 ■ Procedure Types

Procedure	Number
Nephrectomy	637
Radical	430
Simple	116
Partial	29
Nephroureterectomy	62
Prostatectomy	202
Pyeloplasty	93
Adrenalectomy	32
Miscellaneous	128

nephrectomy comprise the majority of cases, nearly half of the procedures represent a laparoscopic approach to a multitude of other urologic disorders (Tables 2 and 3).

Pure laparoscopic techniques were employed routinely, with the exception of 12 hand-assisted procedures. Almost 90% of cases were retroperitoneal or extraperitoneal. This approach was a surgeon preference based on attempts to decrease operative time, decrease patient morbidity, and mimic open surgery (7,8).

PATIENT OUTCOME

With carefully planned strategies, advanced urologic laparoscopy in a community setting can yield results comparable to major academic centers (9). The importance of balancing the complexity of procedures with the experience of the surgeon cannot be overemphasized.

Operative time, an important factor in the private practice setting (10), has become very reasonable (Table 4). In many cases, the operative time matches that expected for the equivalent open procedure. As shown in Figure 1, procedure time decreases with experience. Hospital stay has averaged less than 1.2 days, ranging from the same day to 32 days. Even when including total hospital days for related readmissions, the average remains below 1.2 days. The fairly consistent next-day discharge is felt to be a result of the predominantly extraperitoneal or retroperitoneal approach.

A total of 12 open conversions occurred during 5 nephrectomies, 3 partial nephrectomies, 2 prostatectomies, and two pyeloplasties. This low conversion rate (1.1%) is the result of careful patient selection and attempts toward detailed reproducibility of all procedural steps. The failure to progress in accordance with standard surgical principles was the typical reason for conversion. Emergent conversion for bleeding was never required. A global complication rate of 7% as detailed in Table 5 is comparable to previously published series (11–15). As a result of careful case selection, this rate remained stable from year to year (Fig. 2). Neither of the two deaths was related directly to an intraoperative issue. One patient expired from an acute myocardial infarction on postoperative day three. The other death was a result of a multitude of comorbid conditions including near end-stage renal disease, malignant hypertension, and severe vascular disease.

Increased operative time for laparoscopic versus open procedures is a common criticism. The three positional complications were defined as any new musculoskeletal or sensorimotor complaint, separate from the operative sites, lasting greater than two weeks. All three eventually resolved. When including thrombotic events (5) and pneumonia (6), all possibly time-related complications comprise only 1.3% of the total number of patients. One patient with a postoperative urinoma underwent both a stent placement and a percutaneous drain placement, thereby

TABLE 3 ■ Miscellaneous Procedures

Procedure	No.	Procedure	No.
Kidney	132	Vagina	35
Biopsy	41	Urethropexy	8
Pexy	39	Sacrococpopexy	22
Diverticulectomy	34	Vesicovaginal fistula	5
Cyst decortication	25	Other	28
Cryotherapy	24	RPLND	5
Bladder	4	Limited RPLND	5
Repair	7	Ureteral repair	2
Partial cystectomy	3	Ureterolysis	3
Reimplant ± Boari	6	Conduit	2
Augmentation	3	Stone	8
Cystectomy	3	Lymphocele	3


Abbreviation: RPLND, retroperitoneal lymph node dissection.

TABLE 4 ■ Operative Time

Procedure	Time (min)
Nephrectomy	105
Prostatectomy	230
Pyeloplasty	185
Adrenalectomy	95
RPLND	285

Abbreviation: RPLND, retroperitoneal lymph node dissection.

FIGURE 1 ■ Operative time with experience.



accounting for two of the seven returns to surgeries. Following failed laparoscopic pyeloplasty, one patient underwent laparoscopic nephrectomy, and three others were managed endoscopically. In addition, one patient required urethrorectal fistula repair following failed laparoscopic rectal repair during laparoscopic prostatectomy. One bowel injury required open conversion, but the others were managed laparoscopically. All patients with postoperative ileus or partial small bowel obstruction were managed nonoperatively.

As shown in Table 6, of the 459 patients with presumed renal cell carcinoma, 23 were actually benign and 19 were lost to follow-up. Overall disease-free survival is 96%. Of the 107 patients with greater than five-year follow-up, 91% are disease free. An additional 10 patients five years beyond surgery have not undergone radiographic imaging within the last 12 months. At least 6 of these 10 patients are known to be alive. These results are comparable to historical open and laparoscopic data (16–19).

Cancer control following nephroureterectomy and prostatectomy is also outlined in Table 6. Although a significant volume of long-term data has not yet accumulated, early outcome compares well with historical open data (20–22). Cancer control following nephroureterectomy and prostatectomy is also outlined in Table 6. Although a significant volume of long-term data has not yet accumulated, early outcome compares well with historical open data (20–22). The overall prostatectomy positive margin rate was 13%, but this fell below 11% in the last 100 patients. Thus far, only three patients have a detectable prostate-specific antigen.

The pyeloplasty success rate is outlined in Table 7. Similar to other centers, success in this category is defined as resolution of symptoms and postdiuretic half-time clearance of less than 15 minutes during nuclear renogram beyond 6 months (23–25). Asymptomatic failures with improved drainage were followed expectantly. All other failures underwent subsequent corrective procedures. Functional outcomes following laparoscopic radical prostatectomy (Tables 8 and 9) compare favorably to previously reported open and laparoscopic data (26,27). Erectile function was defined as a sexual health inventory for men score (28) of at least 18. Patients less than 12 months following surgery with lower sexual health inventory for men scores were excluded from this data. In addition, patients with a preoperative sexual health inventory for men score less than 23 were also excluded. Of course, the data continue to mature. Due to excellent visualization and precise suture placement, patency rates following laparoscopic anastomoses are excellent. No bladder

TABLE 5 ■ Complications

Complications	No.
Intraoperative	
Rectal injury	2
Other bowel injury	4
Early postoperative (<48 hr)	
Transfusion	12
Acute renal insufficiency	5
Position	3
Late postoperative	
Return to surgery	7
Myocardial infarction	3
Thrombosis	5
Pneumonia	6
Urinoma	3
Ileus/small bowel obstruction	10
Wound	10
Mortality	2

FIGURE 2 ■ Complications over time.




TABLE 6 ■ Cancer Control

Outcome	No.	Outcome	No.
Presumed renal cell carcinoma		Upper tract transitional cell carcinoma	
No evidence of disease	389	No evidence of disease	36
Nodal involvement	4	Nodal involvement	3
Local recurrence	3	Distant metastasis	2
Initial distant metastasis	3	Concurrent bladder	8
Subsequent distant metastasis	7	Subsequent bladder	12
Benign	23	Bladder cuff	1
Unrelated death	11	Prostatic adenocarcinoma	
Unknown	19	Organ-confined	146
		Extracapsular extension	12
		Seminal vesicle	3
		Nodal involvement	3
		Positive margins	27

neck contractures occurred following laparoscopic radical prostatectomy. All ureteroileal anastomoses and ureteroneocystostomies were successful.

Cost considerations are always difficult to assess. The hospital charges of two predominant procedures are evaluated in Table 10 for both open and laparoscopic methods at a single institution. Minimal difference exists between the two groups. When looking at previously reported data (29–31), a decreasing trend in cost for laparoscopic procedures makes the value-added benefits of this approach economically reasonable.

BUILDING A LAPAROSCOPIC PRACTICE

The average graduating urology resident is adept at performing most urologic procedures. Laparoscopy is the exception. Even a fellowship-trained laparoscopist should expect several years for their skills to mature. Fortunately, there are many ways to hasten the learning curve. The essential elements in achieving success are depicted in Figure 3.

TABLE 7 ■ Pyeloplasty Success Rate

	Normal function	Function <30%
Primary	98 %	89%
Secondary	92 %	71%

TABLE 8 ■ Postprostatectomy Continence at One Year

	Percentage
Dry	88
0 ppd	7
1–2 ppd	4
>2 ppd	1

Abbreviation: ppd, pads per day.

Videotaping procedures for future self-review or review by an experienced laparoscopist can be helpful, particularly when matched with patient outcome. In laparoscopy, past performance often predicts future returns.

Full-Time Commitment

Central to the process is a full-time commitment. This dedication need not be exclusive, but must be constant and unyielding. In other words, one can still practice general urology but still develop one's laparoscopic ability on a daily basis. Not surprisingly, each of the necessary elements is dependent upon the others.

Education

Education beyond formal training can be challenging. A busy practice and personal life leaves little extra time. Fortunately, many opportunities for learning urologic laparoscopy are available. In addition to traditional textbooks, an abundance of tips on the finer points of laparoscopy exists in the current peer-reviewed literature. With many of these sources available in electronic format, one can easily amass a library of references from the Internet.

Obviously, the best way to progress is to learn from the experience of others. Didactic lectures, live case observation, and videos are valuable methods. Although nothing duplicates the true operative experience, animate and inanimate labs are good options for developing specific technical aspects such as suturing (32–36). For the inexperienced laparoscopist, a preceptor or mentor should be mandatory prior to delving into any advanced case (37–39).

Videotaping procedures for future self-review or review by an experienced laparoscopist can be helpful, particularly when matched with patient outcome (40). In laparoscopy, past performance often predicts future returns.

Technique

As with any procedure, the setting can require a modification of the technique. In a private-practice setting, operative time can be more of a factor than in an academic institution. Willingness toward early open conversion for failure to progress will build

Specific technical modifications are often appropriate for the community urologist. For instance, in the absence of a motivated intern, the task of holding the camera is often best handled by the surgeon.

TABLE 9 ■ Postprostatectomy Erectile Function

Age	With PDEI (%)	Spontaneous (%)
<50	84	36
50-60	67	11
>60	56	11
Overall	72	21

Abbreviation: PDEI, phosphodiesterase inhibitor.

TABLE 10 ■ Hospital Cost

	Open	Laparoscopic
Prostatectomy	US \$19,500	US \$22,235
Radical nephrectomy	US \$16,500	US \$15,600

To a large degree, laparoscopy markets itself. However, one must take care to promote accurate expectations. Aggressive advertising and cash-only boutique practices imply near-perfect results. The best approach to marketing exists in the form of education. Sources for patients include a practice web site, brochures, prior patients, and community-targeted talks.

confidence in tackling more challenging procedures, thereby expanding the pool of potential laparoscopic cases.

Specific technical modifications are often appropriate for the community urologist. For instance, in the absence of a motivated intern, the task of holding the camera is often best handled by the surgeon.

In this series, the surgeon holds the camera greater than 50% and 90% of the operative time for radical prostatectomy and a retroperitoneal nephrectomy, respectively. This modification reduces both surgeon and assistant fatigue. In reality, with the exception of suturing, only one hand is usually used at a time for surgical maneuvers; the secondary hand usually holds a retractor, a task easily accomplished by the assistant. In any case, the multitude of steps involved in any procedure should be a collection of techniques used by others, molded into one's own style.

Equipment

Fortunately, laparoscopic equipment is readily available in any setting. The biggest problem is awareness. Companies that supply instrumentation often target their marketing efforts toward high volume institutions. Good sources of information include laparoscopic periodicals, trade shows, and Internet sites. However, the allure of the latest and greatest can be a double-edged sword. Although the right grasper could save 10 minutes off of a procedure, the best-engineered instrument will not replace proper technique. The most important equipment considerations revolve around multiuse, ergonomics, and patient safety, particularly early in one's experience.

Personnel

Every laparoscopic procedure is a team effort. The key personnel fulfill many functions beyond assisting the surgeon. Every aspect of success is dependent on the behind-the-scenes preparation, whether the day of the procedure or months prior. Input should be constantly recruited from everyone in the room. Key observations and modifications have been developed in this manner.

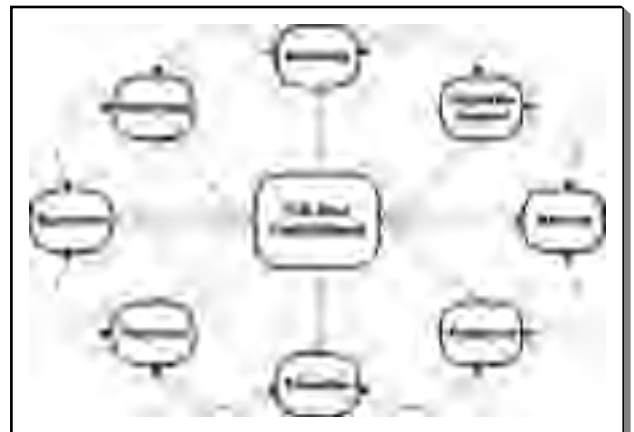
Corporate Support and Marketing

Corporate support is also a very important aspect in developing a laparoscopic practice. Equipment companies, hospitals, and one's own practice are great facilitators. This support comes in the form of training, educational materials, marketing opportunities, financial support, and patient referrals. An entire chapter could be dedicated to marketing a laparoscopic practice.

To a large degree, laparoscopy markets itself. However, one must take care to promote accurate expectations. Aggressive advertising and cash-only boutique practices imply near-perfect results. The best approach to marketing exists in the form of education. Sources for patients include a practice web site, brochures, prior patients, and community-targeted talks.

Of course, the best facilitators are hospital staff (particularly operating room staff), office staff, fellow physicians, and prior laparoscopic patients (and their family members). The smallest marketing opportunity can yield dividends in the future. As one's experience matures, data outcome analysis becomes the most valuable source of marketing material.

FIGURE 3 ■ Elements for building a laparoscopic practice.



Networking

Networking is a valuable tool for both education and marketing. The most important form of networking involves other laparoscopic surgeons, both within and outside the field of urology. Presentations at meetings and contributions to peer-reviewed literature help open this door. Of course, less formal networking opportunities exist almost on a daily basis. Friends, business associates, and community organizations are often interested in learning more about this fascinating field.

The proper balance among all of the essential elements in Figure 3 is the key ingredient for success. The aspiring urologic laparoscopist must balance complexity with ability, tools with technique, and technology with personnel. Most importantly, success will never be achieved if the demanding workload exceeds the enjoyment.

SUMMARY

- With carefully planned strategies and proper balance between the complexity of procedures and the experience of the surgeon, advanced urologic laparoscopy in a community setting can yield results comparable to major academic centers.
- A nonexclusive, but constant and unyielding full-time commitment is crucial to develop laparoscopic ability while practicing general urology.
- To develop specific technical aspects, didactic lectures, live case observation, videos, animate and inanimate labs are valuable methods. For the inexperienced laparoscopist, a preceptor or mentor should be mandatory prior to delving into any advanced case. Videotaping procedures for future self-review or review by an experienced laparoscopist can be helpful, particularly when matched with patient outcome.
- Specific technical modifications are often appropriate for the community urologist.
- Technical nuances of surgical equipment can be found in laparoscopic periodicals, trade shows, and Internet sites.
- Reliable teamwork can be achieved creating a laparoscopic team founded on mutual respect, which encourages the same personnel to be present for all laparoscopic cases.
- To a large degree, laparoscopy markets itself. However, one must take care to promote accurate expectations. The best approach to marketing exists in the form of education. Sources for patients include a practice web site, brochures, prior patients, and community-targeted talks. The smallest marketing opportunity can yield dividends in the future.
- Keys to successful laparoscopy in the community setting include the balance between complexity and ability, tools and technique, technology and personnel, and most importantly, workload and enjoyment.

REFERENCES

1. Clayman RV, Kavoussi LR, Soper NJ, et al. Laparoscopic nephrectomy: initial case report. *J Urol* 1991; 146:278.
2. Colegrove PM, Winfield HN, Donovan JF, Jr., et al. Laparoscopic practice patterns among North American urologists 5 years after formal training. *J Urol* 1999; 161:881.
3. Scherr DS, Ng C, Munver R, et al. Practice patterns among urologic surgeons treating localized renal cell carcinoma in the laparoscopic age: technology versus oncology. *Urology* 2003; 62:1007.
4. Shay BF, Thomas R, Monga M. Urology practice patterns after residency training in laparoscopy. *J Endourol* 2002; 16:251.
5. Shalhav AL, Dabagia MD, Wagner TT, et al. Training postgraduate urologists in laparoscopic surgery: the current challenge. *J Urol* 2002; 167:2135.
6. Taylor GD, Cadeddu JA. Applications of laparoscopic surgery in urology: impact on patient care. *Med Clin North Am* 2004; 88:519.
7. Sayad P, Ferzli G. The extraperitoneal approach and its utility. *Surg Endosc* 1999; 13:1168.
8. Stolzenburg JU, Do M, Rabenalt R, et al. Endoscopic extraperitoneal radical prostatectomy: initial experience after 70 procedures. *J Urol* 2003; 169:2066.
9. Gill IS, Meraney AM, Schweizer DK, et al. Laparoscopic radical nephrectomy in 100 patients: a single center experience from the United States. *Cancer* 2001; 92:1843.
10. Moran ME, Abrahams HM, Kim DH. Laparoscopic radical nephrectomy: financial disincentives by the Health Care Financing Administration. *J Endourol* 2003; 17:133.
11. Fahlenkamp D, Rassweiler J, Fornara P, et al. Complications of laparoscopic procedures in urology: experience with 2,407 procedures at 4 German centers. *J Urol* 1999; 162:765.
12. Gill IS, Kavoussi LR, Clayman RV, et al. Complications of laparoscopic nephrectomy in 185 patients: a multi-institutional review. *J Urol* 1995; 154:479.
13. Simon SD, Castle EP, Ferrigni RG, et al. Complications of laparoscopic nephrectomy: the Mayo clinic experience. *J Urol* 2004; 171:1447.
14. Soulie M, Seguin P, Richeux L, et al. Urological complications of laparoscopic surgery: experience with 350 procedures at a single center. *J Urol* 2001; 165:1960.

15. Vallancien G, Cathelineau X, Baumert H, et al. Complications of transperitoneal laparoscopic surgery in urology: review of 1,311 procedures at a single center. *J Urol* 2002; 168:23.
16. Chan DY, Cadeddu JA, Jarrett TW, et al. Laparoscopic radical nephrectomy: cancer control for renal cell carcinoma. *J Urol* 2001; 166:2095.
17. Portis AJ, Yan Y, Landman J, et al. Long-term followup after laparoscopic radical nephrectomy. *J Urol* 2002; 167:1257.
18. Rassweiler J, Tsivian A, Kumar AV, et al. Oncological safety of laparoscopic surgery for urological malignancy: experience with more than 1,000 operations. *J Urol* 2003; 169:2072.
19. Saika T, Ono Y, Hattori R, et al. Long-term outcome of laparoscopic radical nephrectomy for pathologic T1 renal cell carcinoma. *Urology* 2003; 62:1018.
20. Gill IS, Sung GT, Hobart MG, et al. Laparoscopic radical nephroureterectomy for upper tract transitional cell carcinoma: the Cleveland Clinic experience. *J Urol* 2000; 164:1513.
21. Guillonneau B, el-Fettouh H, Baumert H, et al. Laparoscopic radical prostatectomy: oncological evaluation after 1,000 cases at Montsouris Institute. *J Urol* 2003; 169:1261.
22. Han M, Partin AW, Pound CR, et al. Long-term biochemical disease-free and cancer-specific survival following anatomic radical retropubic prostatectomy. The 15-year Johns Hopkins experience. *Urol Clin North Am* 2001; 28:555.
23. Jarrett TW, Chan DY, Charambura TC, et al. Laparoscopic pyeloplasty: the first 100 cases. *J Urol* 2002; 167:1253.
24. Rehman J, Landman J, Sundaram C, et al. Missed anterior crossing vessels during open retroperitoneal pyeloplasty: laparoscopic transperitoneal discovery and repair. *J Urol* 2001; 166:593.
25. Sundaram CP, Grubb RL III, Rehman J, et al. Laparoscopic pyeloplasty for secondary ureteropelvic junction obstruction. *J Urol* 2003; 169:2037.
26. Catalona WJ, Carvalhal GF, Mager DE, et al. Potency, continence and complication rates in 1,870 consecutive radical retropubic prostatectomies. *J Urol* 1999; 162:433.
27. Olsson LE, Salomon L, Nadu A, et al. Prospective patient-reported continence after laparoscopic radical prostatectomy. *Urology* 2001; 58:570.
28. Rosen RC, Riley A, Wagner G, et al. The international index of erectile function (IIEF): a multidimensional scale for assessment of erectile dysfunction. *Urology* 1997; 49:822.
29. Link RE, Su LM, Bhayani SB, et al. Making ends meet: a cost comparison of laparoscopic and open radical retropubic prostatectomy. *J Urol* 2004; 172:269.
30. Lotan Y, Gettman MT, Roehrborn CG, et al. Laparoscopic nephrectomy is cost effective compared with open nephrectomy in a large county hospital. *JSL* 2003; 7:111.
31. Meraney AM, Gill IS. Financial analysis of open versus laparoscopic radical nephrectomy and nephroureterectomy. *J Urol* 2002; 167:1757.
32. Gupta R, Guillonneau B, Cathelineau X, et al. In vitro training program to improve ambidextrous skill and reduce physical fatigue during laparoscopic surgery: preliminary experience. *J Endourol* 2003; 17:323.
33. Hamilton EC, Scott DJ, Fleming JB, et al. Comparison of video trainer and virtual reality training systems on acquisition of laparoscopic skills. *Surg Endosc* 2002; 16:406.
34. Katz R, Nadu A, Olsson LE, et al. A simplified 5-step model for training laparoscopic urethrovesical anastomosis. *J Urol* 2003; 169:2041.
35. Scott DJ, Bergen PC, Rege RV, et al. Laparoscopic training on bench models: better and more cost effective than operating room experience? *J Am Coll Surg* 2000; 191:272.
36. Traxer O, Gettman MT, Napper CA, et al. The impact of intense laparoscopic skills training on the operative performance of urology residents. *J Urol* 2001; 166:1658.
37. Fabrizio MD, Tuerk I, Schellhammer PF. Laparoscopic radical prostatectomy: decreasing the learning curve using a mentor initiated approach. *J Urol* 2003; 169:2063.
38. Marguet CG, Young MD, L'Esperance JO, et al. Hand assisted laparoscopic training for postgraduate urologists: the role of mentoring. *J Urol* 2004; 172:286.
39. Rosser JC, Wood M, Payne JH, et al. Telementoring. A practical option in surgical training. *Surg Endosc* 1997; 11:852.
40. Nakada SY, Hedican SP, Bishoff JT, et al. Expert videotape analysis and critiquing benefit laparoscopic skills training of urologists. *JSL* 2004; 8:183.

LAPAROSCOPIC SURGERY: MEDICOLEGAL ASPECTS

Michael Perrotti, Peter J. Millock, and Michael E. Moran
Capital District Urologic Surgeons, Albany, New York, U.S.A.

- INTRODUCTION
 - Defining Negligence
 - Informed Patient Consent
 - Delegation and Communication
 - Laparoscopy and Litigation
 - Risk Management
- LAPAROSCOPIC COMPLICATIONS
 - Mechanism of Injury
 - Vascular Injury
 - Anterior Abdominal Wall Injury
 - Bowel Injury
- Urologic Injury
 - Delayed Complications
 - Prevention
 - Medicolegal Issues
- INFORMED CONSENT
 - Informed Consent Legalese
 - Costs of Training/Ethical Considerations of Certification
 - Medicolegal Considerations
- SUMMARY
- REFERENCES

INTRODUCTION

The medicolegal aspects of the burgeoning field of laparoscopic urologic surgery can be perceived as lagging behind the actual clinical applications. This should not come as any great surprise to those who have been at the forefront of laparoscopic urologic surgery. The rapidly changing nature of technology on the practice of urology is best seen in the application of laparoscopic techniques. Many aspects that have heretofore not been of significance are now increasingly apparent. For instance, the implications of training, skill acquisition, residency training and certification, the need for advanced postgraduate training, the learning curve for advanced laparoscopic surgery, robotic surgical interfaces, and our professional society's and association's guidelines or lack of them are now beginning to become important.

Laparoscopic complications are uniquely different in some aspects to their open counterpart. The complications themselves are directly proportional to the skill of the surgeon. These issues are essential to the understanding of the medicolegal aspects of laparoscopic urologic surgery and they must be mentioned with their attendant implications.

In New York State, these issues are further complicated by the Health Department's Memorandum, H-18, on June 12, 1992 because they outline the importance of making the patient aware of the "learning curve" and the right of a patient to know the surgeon's experience (1).

Every urologist interested in practicing laparoscopic surgery should be aware of these issues. In fact, the significance of the New York State's memo has begun to shift responsibility, liability, and litigation aspects to the detriment of the practitioner.

Absolute knowledge of the laparoscopic procedure, the patient's understanding, and current trends in urology are necessary. The perception that "minimally invasive surgery" means decreased risk should also be dispelled. Any disclosure of risks to the patient should be thoroughly documented in the medical record. As with any new procedure, the performance of a laparoscopic procedure early in a urologist's "learning curve" requires extensive counseling and impeccable documentation of disclosure to patients and their families.

Defining Negligence

When assuming the duty of care for another individual, one may be accused of breach of that duty. It is not surprising that a recent review indicated that urologists are not immune to such risk, and may be named the primary defendant in a medical malpractice lawsuit

Laparoscopic complications are uniquely different in some aspects to their open counterpart. The complications themselves are directly proportional to the skill of the surgeon.

In New York State, these issues are further complicated by the Health Department's Memorandum, H-18, on June 12, 1992 because they outline the importance of making the patient aware of the "learning curve" and the right of a patient to know the surgeon's experience.

These investigators found that the greatest percentage of claims arose from the categories of inpatient, adult, and surgical procedures, and that endourological procedures resulted in the greatest incidence of surgical claims. This was in contrast to an earlier report in 1977, which had shown vasectomy to be the most common claim generating procedure.

Crucial factors are: foreseeability of harm, magnitude of the risk imposed, the practicality of taking precautions, and reasonableness of the urologist's actions.

When appropriate, the surgeon must disclose and document the experience with the procedure and the results the surgeon has achieved. It is not acceptable for a urologist simply to advise the patient of the general results in the field and imply that his outcomes will be similar.

in the course of their career (2). Kahan et al. reported 259 medical malpractice claims against urologists consecutively closed between the years of 1995 and 1999 and carried by the St. Paul Insurance Companies.

These investigators found that the greatest percentage of claims arose from the categories of inpatient, adult, and surgical procedures, and that endourological procedures resulted in the greatest incidence of surgical claims. This was in contrast to an earlier report in 1977, which had shown vasectomy to be the most common claim generating procedure (3).

A medical malpractice suit implies negligence on the part of the physician. In discussing negligence, it is essential to examine the concept of "duty of care" (4). Negligence is a tort, that is, a civil rather than a criminal wrong. To prove negligence, the plaintiff (claimant, injured patient) must prove three essential components of the tort, and these are: (i) the existence of a duty to care to the patient, (ii) a breach of that duty by failing to adhere to the standard of care for that treatment or procedure, and (iii) as a consequence of that breach the patient suffers damage or harm.

In the relationship between the surgeon and patient, the duty of care unquestionably exists. The reported legal decisions address whether someone other than the surgeon, i.e., the hospital where the surgery is performed also has a duty (5,6). In accepting this duty as a physician, one accepts to take measures to avoid acts or omissions that one can foresee would be likely to injure one's patient. The importance of duty of care in the introduction of emerging technological advances to clinical practice is evident. This is made more complex by lack of defined guidelines for training and credentialing in new technologies, and a learning curve for the procedures that is ill defined. The court must first assess whether it is fair and just to impose a duty of care in the circumstances arising to a claim.

Whether or not there is a breach of duty of care will depend upon several factors. Important is whether a reasonable person (i.e., qualified peer) would have acted in the same way under the same circumstances.

Crucial factors are: foreseeability of harm, magnitude of the risk imposed, the practicality of taking precautions, and reasonableness of the urologist's actions.

The claimant will need to show that a reasonable person would have foreseen the risk of an adverse event, and must show that a reasonable person would have taken steps to avoid it. It is incumbent upon the physician to take all reasonable steps to minimize risks to the patient. In one case of inadvertent ureteral obstruction following hysterectomy, where the operating surgeon had taken reasonable steps to identify the ureters and had passed contrast medium through them to demonstrate their patency after hysterectomy and clearly documented the same, the Court was satisfied that all practical steps had been taken and the surgeon was not held to be negligent (7). By contrast, in another case where there was no mention that these steps were taken, the court did not rule in favor of the surgeon (8).

Reasonableness is assessed by measuring the acts of the urologist against the standard of care in that area as practiced by other professionals. The plaintiff must show that the doctor did not act in accordance with accepted practice. If the physician's actions are opposed by many healthcare professionals in the field, the doctor will have great difficulty in defending those actions.

New technologies and the absence of well-defined guidelines for skill acquisition and accreditation (i.e., laparoscopic partial nephrectomy) by professional societies may increase the liability of urologists performing these new procedures. It will be difficult to argue that a breach of duty of care did not occur. In such cases, there may be no "customary practice" and a court may focus more on whether physician secured the patient's informed consent through full disclosure of the significant risks associated with the proposed procedure and alternative therapies.

When appropriate, the surgeon must disclose and document the experience with the procedure and the results the surgeon has achieved (9,10). It is not acceptable for a urologist simply to advise the patient of the general results in the field and imply that his outcomes will be similar.

In a medical malpractice action, the plaintiff must show that a loss was suffered as a direct consequence of the breach of duty of care. The claimant's burden of proof is met if the claimant shows on the balance of probabilities (i.e., where it is considered more likely than not, to be the truth). Juries in malpractice cases rarely find against a physician for lack of informed consent alone without concomitant injury (11).

Informed Patient Consent

To obtain informed consent, the physician must have disclosed adequately all facts about the nature of the treatment, the risks involved, the available alternatives and risks,

There are three key elements of consent. The patient must be competent to give consent, the patient must be informed, and consent must be voluntary.

and reasonable expectations for the outcome of the proposed treatment (12,13). In this manner, the patient may come to understand the available treatment options for approaching the patient's medical condition.

There are three key elements of consent. The patient must be competent to give consent, the patient must be informed, and consent must be voluntary (14).

The actual consent form documents that risks and alternatives were discussed with the patient, but a signed piece of paper sufficient to show that the requirements for informed consent have been met needs to be obtained. Consent entails disclosure, which is the information shared with the patient. It is recommended that such discussion occur on more than one occasion for elective procedures, and that family members or other individuals close to the patient be present during these discussions. Documentation that such discussions occurred, the nature of these discussions, the specific treatments, and risks all need to be in the patient record. The importance of documentation is emphasized when a patient alleges that if the risks associated with a given procedure would have been known, then the patient would not have agreed to undergo treatment (15).

Reasonable guidelines regarding disclosure can be found in a report from the Australian Law Reform Commission (16). In that report, it is recommended that the physician discuss the magnitude of possible harm by addressing specific serious adverse events. The greater the likelihood of risk, the greater is the obligation to discuss the more frequent adverse events.

An honest estimate from personal experience is preferable to simply reporting results from the literature.

An honest estimate from personal experience is preferable to simply reporting results from the literature. As simple as this may seem, there may be a lack of consensus among surgeons regarding given risks of a particular procedure and their importance, and hence the informed consent will vary in practice among patients and physicians. This was illustrated by McManus and Wheatley (16) in studying the frequency of disclosure of certain risks prior to laparoscopic cholecystectomy in England. Two-hundred surgeons were asked to comment on the frequency with which they instructed their patients preoperatively about the risk of nine specific potential complications. The average number of laparoscopic cholecystectomies performed by the group annually was 72. Forty-four percent provided written information to patients preoperatively. For the nine potential risks (e.g., bile duct injury, retained calculi, port site hernia, shoulder tip pain, open conversion, wound infection, respiratory complications, thromboembolic complications, and death), only three of the nine were mentioned more than 50% of the time. Surprisingly, 25% never discussed bile duct injury, 22% mentioned it rarely, 27% always mentioned it, and 17% usually did. Quality-standardized written information may serve to be useful as an adjunct to oral discussions between physician and patient. Investigators in Belgium have evaluated patient opinion on the addition of a clear written explanation of risk to a preoperative information packet prior to laparoscopic surgery (17). These investigators propose that such written information would serve to better inform the patient compared to reliance on oral instruction only, and that such practice may lead to reduction in physician liability. In 100 consecutive patients undergoing laparoscopic surgery who received this information preoperatively, the majority of patients reported being pleased to receive information regarding the surgical technique (91%) and associated risks (97%). Although 41% reported feeling worried by the explanation of risk, none cancelled surgery, and the majority (95%) of patients agreed with such an approach to informed consent (18).

The concept of informed consent is very critical to the medicolegal issues surrounding laparoscopic surgery.

Delegation and Communication

Communication as it relates to medical liability is twofold: (i) communication between health care professionals, and (ii) communication between the doctor and patient who has experienced an adverse event. Just as timely intervention may lead to a good clinical outcome, a delay in recognition of the early signs of an adverse event may have disastrous results (i.e., hypotension following laparoscopy due to trocar injury to blood vessel treated with fluid administration for "patient being behind" with no hematocrit check. Delegation of responsibility to a junior doctor or surgical resident without proper supervision may lead to lack of recognition of the clinical signs and symptoms of complications. Similar confusion may occur when an insufficient sign out is given to a covering physician, or when the covering physician lacks experience with the procedure performed (i.e., laparoscopic nephrectomy). The covering physician may be unaware not only of specific events related to the case that day, but the procedure in

When the going gets tough ... the tough communicate!

general and associated risks. If a physician pioneering a new laparoscopic technique lacks support by nursing staff that have received in-service training about the procedure, they may not be aware that certain postoperative events should be cause for concern. Medical experts reviewing laparoscopic litigation will often be asked to discuss whether the recognition of injury was timely or delayed (19).

When the going gets tough ... the tough communicate!

Too often a physician will avoid seeing frequently a patient who has experienced an adverse event, and will find it difficult to communicate with family members of the patient. This is deleterious because the treating physician knows the patient best and may be the most qualified to provide ongoing care in a challenging environment. Consultants will benefit from the surgeons' input in piecing together the facts of the case. Any professional reviewing the case will evaluate not only the timeliness of the recognition of injury by the physician but will also be asked to comment on whether the correction of injury was standard, effective, or deleterious (19). For new techniques and in applying emerging technologies, a myriad of unforeseen complications may exist and a "standard" approach to the same is likely to be absent. In such cases, efforts should be made to obtain input from physicians who may have managed similar complications.

The importance of communicating with patients and their families cannot be overemphasized, particularly following an adverse event where many questions may arise (i.e., when will the tube be removed; what is the blood count; can a family member donate blood, etc.). Here again, as in the informed consent, documentation remains important. Patient representative groups have been emphasizing for years that most patients only seek an explanation of what has occurred and what to expect. The truly litigant patient is rare. Patients and family members who find the doctor difficult to contact will become increasingly frustrated.

Laparoscopy and Litigation

Laparoscopic cholecystectomy was widely adopted in 1990. Just four years later, litigation centering around bile duct injury for the laparoscopic technique surpassed similar litigation for open cholecystectomy by more than 20-fold (19). Kern suggests that this was in part due to the great deal of negative press surrounding laparoscopic injuries during cholecystectomy. In 1992, the *New York Times* reported, "Surgeons who rushed to use a new technique to remove gallbladders without adequate training have botched many procedures, New York State health officials and surgical experts say" (20). Certainly, the fact that bile duct injury may require reoperation, prolonged hospitalization, and potential long-term consequences such as biliary cirrhosis and portal hypertension must be considered a factor as well. Claims related to laparoscopic cholecystectomy remained the most common in a recent report by the Physician Insurers Association of America (21). The Physician Insurers Association of America obtains information from 19 medical insurance companies under a data sharing agreement. Fifteen companies are from the United States, and four are from Canada, the United Kingdom, and Ireland. The 2000 study analyzed 535 cases. The 163 cases that were settled resulted in payments to the plaintiff totaling \$34 million, and the average payment was \$212,000. After laparoscopic cholecystectomy, the laparoscopic procedures that followed in decreasing order of frequency were exploratory laparoscopy, tubal ligation, and laparoscopically assisted vaginal hysterectomy. Common injuries involved the bile duct, bowel, and ureter. Failure to identify the injury, once it occurred, predicted severity of outcome. Missed detection was likely due in part to the limitation of visualization to the working field during laparoscopic procedures or "keyhole" surgery. The injury was not identified in two-thirds of cases until after the procedure was concluded, and in some cases this delay was shown to result in serious adverse outcomes. Vascular injuries were more likely to be recognized immediately compared to bowel in which detection was delayed in over 50%. Trocar injuries were a significant cause of morbidity in this report, not only initial entrance but also all subsequently placed access ports.

The urologist may be relieved at the apparent absence of laparoscopic urologic procedures among the frequent offenders. One must note, however, the relatively recent adoption of laparoscopy in urology compared to general surgery and gynecology, which embraced laparoscopy over a decade ago. Also, the Physician Insurers Association of America reports an average lag time of 21 months from injury until a suit is filed, and an average of two to five years until a suit reaches a conclusion, and is, thereafter, available for our review (22). It would seem, therefore, that the magnitude of litigation in urology would increase.

There is evidence that laparoscopic injuries are more severe than their open counterpart (23). This may explain why laparoscopic injuries are associated with higher

rewards to the plaintiff. A case presented in Ref. 24 offers some insight into the potential seriousness of laparoscopic injuries. In that case, a 22-year-old female underwent laparoscopic cholecystectomy. With the exception of some "hypotension intraoperative," a laceration to a major vascular structure was missed and required reexploration six hours postoperatively. At return to surgery, the patient received an excess of blood products, had vascular repair, but ultimately expired. A lawsuit charged the attending surgeon with negligently inserting the trocar resulting in vascular laceration and lack of informed consent. The suit was settled in favor of the plaintiff. Serious vascular injury has been shown to occur in 0.7/1000 cases of laparoscopic cholecystectomy (25). The primary trocar insertion involved in the majority of cases.

Gawande (26) utilized records from the Physician Insurers Association of America to examine injuries during laparoscopic entry that provoked malpractice claims. The study was comprised of 135 cases reported in the United States between 1980 and 1999 and 111 cases from insurers in Europe, Australia, and Canada. There were 293 injuries in 246 patients overall. Injured structures were the small bowel ($n = 89$), colon ($n = 56$), iliac artery ($n = 48$), inferior vena cava or iliac vein ($n = 28$), mesenteric vessels ($n = 11$), urinary bladder ($n = 9$), aorta ($n = 8$), abdominal wall vessel ($n = 7$), liver ($n = 6$), stomach ($n = 4$), and other ($n = 27$). Injury recognition occurred sooner in the United States, and for all cases mortality increased with increasing delay in injury recognition. Delayed recognition in patients older than 59 years was significantly associated with a fatal outcome ($p < 0.001$). Over five years following the event, a greater percentage of cases remained open in the United States. In the United States there were 53 cases reported closed with payment (median, \$127,000; maximum, \$4,980,086), and outside of the United States there were 13 cases closed with payment (median, \$55,000; maximum, \$215,955).

Risk Management

Medical litigation has been referred to as a growth industry and will probably play a continuing role in the life of the physician (27). It is generally recognized that adverse events in the course of medical care far exceed the number of cases in litigation (28). Risk management includes discovery of the events surrounding adverse events. Discovery allows for identification of risk factors in practice and modification and implementation of safeguards and protocols. Often, a system is in place to assure that patient and family complaints are handled appropriately and open communication maintained between patient and caregivers. At our own institution, we recently discovered that the wrapping material for a patch applied during laparoscopic partial nephrectomy was neither counted nor radiopaque. When the surgeon postoperatively was concerned that this wrapping had not been removed from the patient, laparoscopic reexploration was performed and indeed the wrapping was located and removed. Following this case, a system was implemented to include counting of the wrapping and use of a radiopaque material.

The importance of recognizing potential physician liability when new laparoscopic techniques are introduced in clinical practice cannot be overstated. Urologists are implementing laparoscopy over a decade following our colleagues in general surgery and gynecology. It is essential to introduce these evolving complex minimally invasive procedures into clinical practice while maintaining patient safety and keeping our professional liability to a minimum.

The importance of recognizing potential physician liability when new laparoscopic techniques are introduced in clinical practice cannot be overstated. Urologists are implementing laparoscopy over a decade following our colleagues in general surgery and gynecology. It is essential to introduce these evolving complex minimally invasive procedures into clinical practice while maintaining patient safety and keeping our professional liability to a minimum.

In any discussion of the medicolegal aspects of laparoscopic urologic surgery, careful consideration of complications is mandatory to better understand the litigious potential.

LAPAROSCOPIC COMPLICATIONS

In any discussion of the medicolegal aspects of laparoscopic urologic surgery, careful consideration of complications is mandatory to better understand the litigious potential.

The morbidity and mortality associated with laparoscopic surgery is widely known (29–46). The relativity of these complications depends upon the literature and varies widely from earlier gynecologic series from the 1970s through the 1990s. In large series, the risk of a complication has been quoted to range from 0.19% to 2.9%. The mortality rate has been reported to approximate 0.057 deaths per 1000 procedures. The general surgical literature also has large numbers with advancing complexity of procedures from the 1980s through to the present. The complication rates have ranged from 2.3% to 5.1%. Mortality has been reported from 0% to 0.5%. It has been suggested that since most of this information comes from retrospective evaluation of large numbers of cases, that the true incidence of complications might be even higher. In addition, the gynecologic literature has been suspect when applications to other specialties, such as general surgery and urology because their series have a weighted preponderance

of young, healthy females. Many urologic and general surgical procedures are done on elderly patient populations with significant comorbid disorders such as diabetes and/or significant vascular disease. Specific complications have been evaluated and are known or approximated as follows: pneumoperitoneum complications = 0.7%, bleeding = 0.6%, perforation injuries = 0.3%, electrical injury = 0.2%, infections postoperatively = 0.1%, bowel burns = <0.1%, cardiac arrest = <0.1%, open laparotomy rate = 0.6%. These numbers are generated by review of large, principally gynecologic surveys, and do not include the complications that might be related to anesthesia such as aspiration pneumonia.

There are well-known factors that influence the risk of a laparoscopic procedure. These include environmental factors such as the integrity of instrumentation, the upkeep and quality of the technology. Another factor is the skill and experience of the surgeon. Widely quoted but with few studies to evaluate its impact is the “learning curve” for various types of laparoscopic procedures. It is known for many complex laparoscopic procedures that the complication rate is higher, when the case log is near its beginning. This issue is central to discussions of complications and complexly bound to discussions of training, credentialing, privileges, and competency. Phillips in 1977 stated that operator experience is the primary determinant of the incidence of laparoscopic complications. Phillips further noted an inverse correlation between the number of laparoscopic procedures performed and the incidence of complications: decreased numbers after 50 and 100 laparoscopic procedures. Other factors showing correlation with increased risk include previous abdominal surgery, obesity, male gender, advanced age, and diabetes mellitus. Some of these increased risk factors have been questioned recently, but the laparoscopic surgeon should be aware of the literature.

Complications can also be discussed in terms of their severity. Minor complications include subcutaneous emphysema, hand-shoulder syndrome (pain from retained gas beneath the diaphragm), ecchymosis at a trocar site. More significant complications are perforation of a viscus or major blood vessel, electrocautery injury, gas embolus, and open conversion. Most would argue that an open conversion from the laparoscopic approach is not a real complication; however, since an open operation carries with it more convalescence and risks, it deserves mentioning and can serve as a yardstick in measuring certain laparoscopic procedures and series. The Physician Insurers Association of America utilizes a National Association of Insurance Commissioners severity index score from 1 to 10, with 1 being emotional injury and 10 being death.

The most severe and potentially lethal complications associated with laparoscopic surgery are those injuries to the bowel and major vascular structures. Laparoscopic-associated injuries to vasculature or bowel are unusual and potentially catastrophic. Estimates of occurrence range from 0.06% to 0.3%. Manifestations can be early or delayed. Delayed diagnosis is definitely related to increased patient morbidity.

Mechanism of Injury

Access Injury

Laparoscopic surgery always carries the risk of inadvertent injuries that usually occur during the “learning curve” of various procedures. The exceptions to this rule, and some of the most feared injuries facing the laparoscopic urologist are those to vascular structures or bowel. These injuries are fortunately infrequent. The best method of managing these injuries is avoiding them. This is best accomplished by a thorough understanding of the equipment utilized during laparoscopy, high-risk maneuvers, mechanisms of injury, and recognizing when injury is present. Overall estimates of vascular and bowel injuries in large series are predominately quoted from older gynecologic literature. Vascular injuries have been difficult to quantify but occur at least in 0.1% of the cases. Bowel injuries have been variously reported between 0.06% and 0.3% (46).

Mechanisms of injury vary, however, most occurring during blind access maneuvers with the pneumoperitoneum needle or first trocar placement. The takeoff of the right common iliac artery lies directly below the umbilicus. It is crucial to angle the pneumoperitoneum needle 30° to 45° caudally and carefully control forward pressure to insure abdominal access yet avoided excessive forward penetration. The same approach holds for trocar insertions. Bowel injuries from needle or trocar insertions usually occur in the presence of adhesions. Access should be planned to stay as far away from previous surgical incisions as possible or utilize open techniques. A summary of major series and the data from Chandler et al. (47) is shown in Table 1.

The risk of an injury may be associated with the operative procedure as well as its complexity. As the type of surgery moves away from the linea alba, as so often occurs in urologic laparoscopy, the possible risk of injury to the abdominal wall itself may increase.

The risk of an injury may be associated with the operative procedure as well as its complexity. As the type of surgery moves away from the linea alba, as so often occurs in urologic laparoscopy, the possible risk of injury to the abdominal wall itself may increase.

TABLE 1 ■ A Summary of Major Injuries by Study Type

Author (discipline)	Cases	Year	Bowel	Major	Smaller vessel	Liver vessel	Stomach	Urinary bladder	Uterus	Other	Total (% coincidence)
<i>Procedure-based retrospective</i>											
Fahlenkamp (UROL)	2,407	1992-1998	—	—	—	—	—	—	—	—	6 (0.25)
Harkki-Siren (GYN)	102,812	1990-1996	29	6	5	0	0	3	0	8	51 (0.05)
Hashizume (GEN)	15,422	1991-1995	11	10	70	1	0	0	0	64	156 (1.0)
Hulka (GYN)	14,911	1995	36	14	368	0	0	0	0	0	418 (2.8)
Champault (GEN, GYN)	103,852	1988-1994	35	35	237	13	5	2	0	10	337 (0.32)
Deziel (GEN)	77,604	1989-1990	104	36	35	14	5	1	2	0	197 (0.25)
<i>Procedure-based prospective</i>											
Leonard (GYN)	1,033	1992-1998	2	1	6	0	0	3	1	4	17 (1.6)
Jansen (GYN)	25,764	1994	21	9	38	0	3	3	0	9	83 (0.3)
<i>Injury-based retrospective</i>											
Marret (GYN)	?	1994-1997	12	11	18	0	0	3	0	3	47 (NA)
Yuzpe (GYN)	?	1985-1987	77	85	0	0	8	37	65	272 (NA)	
Chandler (GEN, GYN, UROL)	?	1989-1999	218	239	70	13	11	19	7	17	594 (NA)

Source: From Ref. 47.

TABLE 2 ■ Review of the General Surgical Literature in 1999 for Cause of Injury

Procedure	No. of patients	No. with trocar complications	No. with reference to design
Hernia repair (transabdominal)	38	10 (26.3%)	4 (10.5%)
Lap. Nissen	57	8 (14.0%)	1 (1.7%)
Lap. colon	15	1 (6.7%)	0
Total	110	19 (17.3%)	5 (4.4%)

Source: From Ref. 28.

The Veress needle and laparoscopic trocar's design has been implicated as a potential source of laparoscopic access injury. Several interesting reports and literature reviews have focused upon this issue. Despite advances in trocar technology such as safety shields, the incidence of injury has not altered appreciably.

Many complex laparoscopic surgery reports are published but seem to ignore the potential for access injury. Leibl et al. (28) have reviewed the general surgical literature in 1999 and reported in Table 2.

The Veress needle and laparoscopic trocar's design has been implicated as a potential source of laparoscopic access injury. Several interesting reports and literature reviews have focused upon this issue. Despite advances in trocar technology such as safety shields, the incidence of injury has not altered appreciably.

In addition, the most common method of laparoscopic access remains the blind insertion of a Veress needle, followed by insufflation, and then a second blind trocar insertion. There now exist many types of devices for laparoscopic access. These include Veress needle, open trocars (Hasson-type), shielded pyramidal trocars, shielded blade trocars, conical trocars, radial expanding trocars, short-stroke knife optical trocars, and winged cone optical trocars. Chandler et al. (47) used three data sources to identify access injuries reported with all types of these devices: The Physician Insurers Association of America on U.S. laparoscopic injuries and a second Physician Insurers Association of America database from Europe, Australia, and Canada. The third database came from the United States Medical Device Reports to the Food and Drug Administration. Their study encompassed more than 280,000 laparoscopic procedures and is injury-based instead of procedure-based, thus providing little data on the true incidence or relative safety. The results by type of access device are summarized in Table 3 (47).

Basically all categories of contemporary access devices have been reported to cause some type of injury. In the Medical Device Reports reports, the Veress needle only accounted for 2% of reported injuries whereas the Physician Insurers Association of America noted them in 13% to 19% (which is probably closer to actual). From these databases, it is also known that injuries from secondary trocar insertion are rare. There were nine entry injuries from the Medical Device Reports data and nine from the Physician Insurers Association of America data. Five from the Medical Device Reports set were associated with shielded pyramidal trocars, three from shielded blade trocars, and one small bowel puncture with a radially expandable device. The severity of the injuries was also recorded from these data sets. More than half of the patients suffering an access injury (55% overall from all three cohorts) were scored using the National Association of

TABLE 3 ■ Chandler's Results from Several Large Databases Regarding the Type of Trocar Used and the Subsequent Injury

Device	MDR (n) ^a	%	PIAA (U.S.)/foreign (n) ^a	%U.S./%foreign
Shielded pyramidal	187 (3)	77.2	12 (1)/1	9/1
Shielded blade	21 (2)	8.7	— / —	— / —
Optical				
Short-stroke knife	6 (1)	2.5	2/ —	2/—
Winged cone	10 (2)	4.1	— / —	— / —
Veress needle	5	2.1	18/21	13/19
Unspecified trocar	4	1.7	85/91	64/80
Radially expandable sheath	4 (4)	1.7	— / —	— / —
Open blunt (Hasson)	2	0.8	16/ —	12/ —
Multiple-use pyramidal	2	0.8	— / —	— / —
Conical	1	0.4	— / —	— / —
Total	242 (12)	100.0	133 (1)/113	100/100

^an numbers in parentheses indicate that 12 of 235 (5%) devices other than the Veress needle or an open blunt cannula without prior insufflation.

Insurance Commissioners injury severity index indicating a major impairment or disability. In addition, there were 65 deaths from access injuries, all from primary access except one secondary trocar injury to the duodenum. Mortality was significantly lower in the two U.S. cohorts compared to the international group (11% vs. 22%, $p = 0.0008$). The international group had a more significant number of bowel injuries and a significantly greater proportion of patients presenting with a delay in diagnosis (60% international vs. 17% in the United States, $p < 0.001$) (47).

Lest the reader think that the open methods for laparoscopic access have no risk of injury, think again. Open techniques have been associated with serious potential risks of both major vascular and bowel injuries (48). The mechanisms for these injuries are nearly identical to the closed methods. That is the route of access is via a small incision down through the rectus fascia. The peritoneum is grasped and either opened with scissors or knife. This forward vector of force is all that is necessary in thin patients to injury a closely apposed vessel or bowel. Injuries have also been reported with this technique by placing holding fascial sutures that inadvertently catch underlying bowel. In addition, a Hasson cannula has been reported to injure the small bowel by constant pressure applied "off camera" during a prolonged laparoscopic surgery.

Pneumoperitoneum Injury

The complications of pneumoperitoneum are presented in Table 3. Certainly, not all patients experience detrimental complications associated with CO₂ insufflation, otherwise there would be no widespread interest in this approach to treating uropathology. Most of the consequences mentioned above are transient and the operative procedure can continue with continuous monitoring of the patient. Overall, Parsons et al. (49) has estimated that during urologic laparoscopic procedures that insufflation problems occur in about 3.5% of the cases.

Instrument Injuries

Instruments can cause unintended injury as well as the trocars used for laparoscopic access. Most of these injuries affect the bowel most commonly with lacerations, injury to the mesentery with bleeding being the most frequent. Since these types of injury are most prevalent during the operative dissection, they are frequently observed (50).

The most common type of nonobserved instrument injury comes from retraction. These can be punctures, lacerations, or hematomas from overzealous traction during exposure (51). Retraction instruments should always be positioned with video control, and any repositioning should be observed and monitored.

Following prolonged retraction with such devices, the retracted organ or area should always be thoroughly inspected. Small lacerations of the bowel's serosa can be oversown. Deeper lacerations or frank perforations should be individualized, but classic teaching would suggest open conversion and close inspection of the injury and debridement and closure. There has been successful laparoscopic management of bowel lacerations reported in the literature. Such patients should be managed with bowel rest, nasogastric suction, and antibiotics. Injuries have also been reported during both

The most common type of nonobserved instrument injury comes from retraction. These can be punctures, lacerations, or hematomas from overzealous traction during exposure. Retraction instruments should always be positioned with video control, and any repositioning should be observed and monitored.

laparoscopic renal and adrenal surgery to the liver and spleen (52). If the injuries are superficial, attempts to control the injury laparoscopically with gel foam, avitene, or with an argon beam coagulator have been reported. Open exploration for these injuries has likewise been described.

Electrocautery Injury

The explosion of laparoscopic procedures both in general surgery and urology has lead to rekindled interest in the risks of monopolar electrocautery, the use of alternative energy sources such as bipolar cautery, lasers, argon beam coagulation, and ultrasound activated devices (harmonic scalpel). These energy sources are predominately utilized for bloodless dissection and control of vascular structures, critical for the performance of laparoscopic surgery. In the survey of the American College of Surgeons, 86% of all surgical laparoscopists were using monopolar cautery. In a more recent survey in Germany, about 84% of all surgeons used monopolar cautery routinely in all laparoscopic cases. In an open surgical environment, monopolar electrocautery is relatively safe, with the major significant risk being skin burns (53). In the laparoscopic environment, however, potential complications are far more serious with mortality rates approaching 25% or more for inadvertent injuries to small and large bowel. The need for thorough review of the potential implications will greatly aid in the development of safe laparoscopic procedures for urologists in this burgeoning field. One should not forget the admonitions of experienced gynecologic surgeons from the 1970s and 1980s where routine editorial comments on the potential for harm with the indiscriminant use of monopolar electrocautery were published (54–56).

In review of the large volume of literature on high-frequency electrosurgery in laparoscopic environment, seven possibilities exist for a laparoscopic electrocautery injury (57). Thorough understanding of these mechanisms of potential laparoscopic injury will help facilitate the safe advancement of skills in laparoscopic surgery. The first potential modality of electrocautery injury laparoscopically is the application of an active electrode to nontargeted tissue. This occurs when an electrically charged instrument is inadvertently activated such as stepping on the foot pedal at the wrong time or touching another conductive instrument with cautery activated. Since the surgical field of view tends to be rigidly controlled to the point of surgical dissection, these injuries are usually noticed by the surgeon at the time of injury. The second possibility for electrocautery injury occurs when a restricted return pathway is encouraged. This happens when over cautery is achieved at the tip of the active electrode, increasing tissue impedance and alternative return pathways must be sought by the active electrode. Here, for instance, when dividing adhesion to a visceral structure, if the peritoneal side is stringently cauterized the pathway may return by way of the bowel and cause inadvertent bowel injury. These two are often in the direct line of sight during operative procedures and careful avoidance of utilizing too much monopolar electrocautery where tissue charring occurs should be avoided. The third mechanism of potential electrocautery injury occurs when overheating of the active electrode is present. Here, again, if the tips of electrocautery instrument become charred or stuck with tissues, heat dissipation by free flow of the electrical current is impaired and the tips of the active electrode become quite hot. By simply touching an adjoining visceral structure with the hot electrode thermal damage can ensue. This typed of injury has been reported in the urologic literature, where the obturator nerve was injured during laparoscopic lymph node dissection with what appeared to evolve as a conductive thermal burn, but progressed even after the first week postoperatively. The next four other methods of possible electrocautery injury in a laparoscopic environment have a tendency to occur outside of the surgeon's line of sight and, therefore, have much greater potential for patient morbidity and mortality. The fourth type of injury occurs when conductive instruments are energized inadvertently. The classic example of this would be where the surgical instruments are all converging toward the targeted area of dissection, the electrode is activated and the instrument is too close to another such as the laparoscope itself, which then conducts the current in a stray fashion to a structure outside the line of sight.

Electrocautery injuries are often not noticed and can be quite severe, resulting in delayed presentation of peritonitis secondary to fecal contamination or urinary extravasation 7 to 10 days following the surgical procedure. Patients often present with very minimal symptoms but rapidly decompensate and, in many instances, may require more than one surgical intervention for repair.

The fifth potential method of inadvertent electrocautery injury occurs when insulation failures occur on the active electrode within a trocar cannula. There are two subcategories where the type of injury depends on the type of trocar used and whether or not a plastic fascial screw is present in the abdominal wall. Obviously, when an

Electrocautery injuries are often not noticed and can be quite severe, resulting in delayed presentation of peritonitis secondary to fecal contamination or urinary extravasation 7 to 10 days following the surgical procedure. Patients often present with very minimal symptoms but rapidly decompensate and, in many instances, may require more than one surgical intervention for repair.

insulation failure occurs within the trocar, the trocar will become electrified if it is a conductive medium. Even in instances where the trocar is not conductive, such as with plastic cannulas, failures in these can result in inadvertent conduction to the abdominal wall. Studies with biopsy of the skin sites from laparoscopic cannula sites have proven that thermal necrosis occurs at trocar sites, both metallic and plastic. When a plastic fascial screw further insulated the trocar from the abdominal wall, an insulation failure within the trocar is potentially even more dangerous. The activated electrode can build up a capacitance charge and leaking from this can arc to a nearby visceral structure. These will often be missed since they are outside of the targeted area of laparoscopic surgery and can have the same devastating consequences of the previous electrocautery injuries described. The sixth mechanism of a laparoscopic electrocautery injury occurs when insulation failure occurs outside of the trocar on the active electrode. These insulation failures are often small and not noticed and the potential for current arcing to a nontargeted viscus is highly likely (58). If the surgeon is careful to inspect the tract of the pathway of the surgical procedure, these can be identified during the laparoscopic procedure. There have been reported cases of insulation failure injuries with electrothermal injury to the small and large bowel, corrected laparoscopically at the time of the primary procedure. Careful inspection of all active electrodes should occur outside of the abdomen prior to instigating the laparoscopic procedure.

These types of injuries are best avoided by simple inspection of the instruments and routine maintenance of the instruments. All insulation can eventually wear down and insulation failures are a real clinical dilemma.

These types of injuries are best avoided by simple inspection of the instruments and routine maintenance of the instruments. All insulation can eventually wear down and insulation failures are a real clinical dilemma.

Disposable instruments are less likely to have insulation failure since they are one time use and are discarded at the conclusion of each case. If, however, during the course of a complex laparoscopic procedure, the same instrument is passed multiple times through a trocar, the insulation can get worn down through the process of insertion and reinsertion. The seventh and final modality wherein inadvertent laparoscopic electrocautery injuries occur are secondary to capacitive leakage of current from the active electrode. This probably occurs in a laparoscopic environment more than previously thought. As the electrode is activated, the charge builds up and moves through the conductive electrode. If at any point the flow is interrupted by restricting the return pathway or any point wherein the active electrode becomes close enough to another conductor, current can leak from the active electrode to another return site pathway by discharging this built-up current. Since this can occur at any location along the insertion site of the active electrode, many times it will occur outside of a surgeon's operative view and again poses a major potential risk for subsequent electrothermal injury.

There are entire textbooks, meetings, and courses on the rational use of electrocautery in laparoscopic surgery. Methods exist however to minimize these risks. First, always know your laparoscopic electrosurgical generator (59). The patient should be well grounded, with a broad return pathway (pad) in correct orientation. The electrocautery instruments and any other instrument in the peritoneal cavity should be inspected to insure adequate insulation. When the cautery is activated, it should only be applied by the surgeon and no assistant movement should be allowed. There should be no use of forced coagulation, but recent investigations utilizing spray coagulation suggest it might have utility. The newer microprocessor-controlled electrocautery units should be preferred over the older units. One such instrument is called "Instant Response^{TM/a}" (60). This is a self-regulating, feedback-controlled electrosurgical unit that allows tissue conditions to be fed back to the microprocessors within the electrical generator. These capabilities allow the generator to tailor the electrical output to local laparoscopic conditions. Cutting and coagulation performance are enhanced in these new age systems; this may allow safer performance of monopolar electrocautery in the future. In addition, the behavior of the insulation material on the outside of laparoscopic instruments, usually plastic, is being evaluated. Alterations of this coating may improve the efficiency and alter the desired effects making tailored devices of the future possible. Bipolar systems have an advantage over monopolar electrocautery by confining the energy between the twines of the active electrode and return electrode at the instrument's tip. Complex microprocessing electrosurgical generators and improved instrument manufacturing have improved these devices significantly (61). Such a device was used by Guilloneau et al. to perform the first large series of laparoscopic radical prostatectomies in Paris. If alternative methods of cautery are available and the surgeon is comfortable with the technology, the harmonic scalpel accomplishes similar

^aValley Lab, Boulder, CO.

tasks to the electrocautery without an active current being utilized (62,63). Cutting and coagulation can be accomplished using either electromagnetic or mechanical energy, thus avoiding electrocautery completely. Electromagnetic energy sources rely on heat derived from either light (lasers) or radiofrequency waves (electrosurgery) to produce tissue cutting and coagulation (62). The tissue temperatures from these sources often reach 100°C or greater (64). Since collagen denaturation and protein coagulation occurs between 60°C and 80°C, tissue desiccation and charring ensue. Using mechanical energy, the ultrasonically activated devices (harmonic scalpel) rely on vibratory motion to generate heat from internal tissue friction to cut and coagulate. This method generates lower tissue temperatures from 80°C to 90°C, which is sufficient for coagulation but not for desiccation or charring. Using either a laser or an ultrasonically activated device totally avoids the risk of inadvertent electrocautery injury.

Vascular Injury

Major vascular injury during access for laparoscopic surgery is a well-described and much-feared complication (65). This probably is because of its dramatic presentations such as near instantaneous instability of the patient's hemodynamic state or sudden large volume blood from the Veress needle or trocar and also because of the high rate of mortality.

Major vascular injury as the cause of death following a laparoscopic surgery is second only to anesthesia complications, at 15%. Pneumoperitoneum needle injuries account for the vast majority of major vascular injuries reported.

In reviewing the gynecologic literature, 11 of 15 such injuries were noted from needle placement and only two out of fifteen from trocar placement (66). The distal aorta and right common iliac artery are not surprisingly the most prone to injury. This is because the distance from the anterior abdominal wall to the retroperitoneal vasculature may be as little as 2 cm in thin people. Injuries to the inferior vena cava, the left hepatic vein, the abdominal aorta, and the inferior phrenic vessels have all been reported as well. These injuries are most often the result of the laparoscopic dissection, and not from laparoscopic access methods. Hallmark features of these injuries include immediate bloody return from the needle and/or rapid deterioration of the hemodynamic status of the patient (67). Once a major vascular injury is suspected, the Veress needle or trocar should not be moved medially or laterally. The offending access portal should be left in place and open exploration should be performed. At exploration, bleeding is typically confined to the retroperitoneum even with extensive vascular lacerations. Most arterial injuries can be oversewn with simple, nonabsorbable sutures after obtaining proximal and distal control of the injured vessel. Rarely, the iliac vein has been lacerated along with the iliac artery. More extensive injuries have required prosthetic replacement of the injured blood vessel (68,69). These vascular injuries are the reason why open surgical instruments should be immediately available during all laparoscopic cases. At least two reported deaths are attributed to laparoscopic vascular injuries, and sequelae resulting from peripheral ischemia have resulted in successful litigations in the United States (70,71).

Although best avoided by careful instrument placement, and thorough understanding of anatomy and procedures it is equally important to be prepared for a major vascular catastrophe. An adequate response in a controlled yet rapid fashion can spare further morbid sequelae.

Early involvement by skilled vascular surgeons is associated with less permanent disability. Anticipation of this injury is essential. An open set of operative instruments should be available. If injury occurs during pneumoperitoneum insertion, avoid lateral displacement of the needle and remove it. Observe the patient's vital signs and draw a stat baseline hemoglobin and hematocrit. If vitals and serum parameters remain stable, open laparoscopic access should be accomplished or the procedure should be terminated and rescheduled another day. If vital signs indicate instability or serum parameters indicate continued hemorrhage, immediate laparotomy is indicated. Trocar injuries are usually more severe. The first indication may not be blood in the trocar but hemodynamic instability of the patient. If vascular injury is suspected do not remove the trocar or desufflate the abdomen but turn off the insufflator to avoid massive CO₂ embolization. A midline celiotomy is performed and the trocar is used to guide the exploration. The trocar should not be touched until proximal and distal vascular control is obtained. Vascular injuries can also be encountered during dissection. These are usually smaller vessels or branches and rarely laceration of larger veins (femoral vein). Pressure is usually sufficient to tamponade the bladder until the field can be cleared and carefully explored to attempt laparoscopic salvage. During pelvic lymph adenectomy

Major vascular injury as the cause of death following a laparoscopic surgery is second only to anesthesia complications, at 15%. Pneumoperitoneum needle injuries account for the vast majority of major vascular injuries reported.

An adequate response in a controlled yet rapid fashion can spare further morbid sequelae.

bleeding from an accessory obturator vein or artery can be very difficult to control laparoscopically. Despite the greatest care, these vascular structures can be inadvertently torn or cut. Electrocautery or argon beam coagulation is not advisable choices in this scenario because of the risk of thermal injury to the obturator nerve (72). All alternatives to augmenting hemostasis should be considered. Chemical augmentation of hemostasis is possible with microfibrillar collagen (Endo-Avitene^{TMb}) or fibrin glue (73). Occasionally the bleeding is severe and significant, warranting immediate exploration. Again, leave the trocars and pneumoperitoneum intact so that celiotomy can be performed quickly. The laparoscope can be placed in the midline to aid in countertraction for the knife during this maneuver.

Finally, major lacerations to large veins can go unnoticed during laparoscopic procedures because of the pressure of pneumoperitoneum.

It is advisable that inspection of the operative site at the conclusion of the procedure be accomplished with minimal abdominal pressures, 2–4 mmHg, prior to removal of any trocars.

In addition, a good rule of thumb for all laparoscopic surgery is that the first instrument active on the table is the laparoscopic suction/irrigation unit, and that it is the last off the table for the conclusion.

The vasculature of the anterior abdominal wall can also be injured during laparoscopy (74), most often secondary to trocar injuries to the inferior or superior epigastric artery or vein. The inferior epigastric vessels are much more commonly injured than the superior epigastric vessels.

Anterior Abdominal Wall Injury

This has been attributed to the more lateral course of the inferior epigastrics along the rectus muscles compared to the more medial distribution for the superior epigastrics. The inferior epigastric artery is also larger than the superior epigastric. It has been reported that injuries to the superior epigastric artery are more likely to stop on its own than the inferior epigastric. Multiple techniques have been described for controlling bleeding from these sites. Resectoscopes have been placed via the trocar site and fulguration of the bleeding point has been described. This is difficult if the bleeding is significant or if a large amount of adipose tissue is present. Medial or lateral displacement of the trocar may temporize hemorrhage by pressure tamponade. A Foley catheter has successfully been placed via the trocar, insufflated with 30 cm³ of saline, the upward traction utilized to tamponade the bleeding. Percutaneous sutures placed via a Stamey needle have also successfully ligated abdominal wall bleeding (75). Because the epigastrics are anatomically located in predictable patterns, just medial to the lateral border of the rectus abdominus these injuries should be avoidable. But as pointed out previously, the more complex the operation, the more likely that staying within the safe boundaries of known drainage patterns can be compromised. It is best to identify the anterior abdominal wall vasculature by transillumination with the laparoscope prior to placing any trocars near the vicinity of these vessels. By using the smallest trocar necessary, the risk of a major injury to the epigastric vessels is also reduced. Some have suggested not angling the trocar radically towards the midline from lateral locations to avoid shear that could damage vascular tributaries. Use of cone-shaped blunt-tip trocar or a radially dilating “step trocar” can minimize chances of injury to the inferior epigastrics. Finally, it is critically important to inspect all trocar sites both at the beginning of the laparoscopic case and at its conclusion. Trocars have been known to damage a blood vessel but not result in serious bleeding until it has been removed. This is thought to occur secondary to tamponade of the vessel by the trocar and pneumoperitoneum.

Liebl et al. (28) investigated the risk of abdominal wall injuries by evaluating bleeding from access sites in complex general surgical cases. They noted that the risk of injury of a blood vessel in the anterior abdominal wall was not only associated with the type of surgery being performed but also the type of trocar utilized. The trocar’s tip design is itself a significant factor in causing bleeding from access via the abdominal wall. They reviewed the surgical literature and found very rare accounts of this problem in laparoscopic hernia surgery (0.8%), in laparoscopic Nissen fundoplication (3%), and in laparoscopic colon surgery (3.4%). In evaluating various trocar tip designs, they noted that the rate of anterior abdominal wall bleeding was reduced from sharp-cutting tipped trocars (0.83% to 0.33%) to 0 when cone-shaped trocars were used.

It is advisable that inspection of the operative site at the conclusion of the procedure be accomplished with minimal abdominal pressures, 2–4 mmHg, prior to removal of any trocars.

The vasculature of the anterior abdominal wall can also be injured during laparoscopy, most often secondary to trocar injuries to the inferior or superior epigastric artery or vein. The inferior epigastric vessels are much more commonly injured than the superior epigastric vessels.

^bMedChem Products, Woburn, MA.

Bowel Injury

The other group of catastrophic injuries a urologic laparoscopist could encounter involves the bowel (76). These injuries represent the third most common cause of death from laparoscopic surgery following anesthesia complications and major vascular injury.

Unlike major vascular injury, many bowel injuries go unrecognized at the time of the laparoscopic procedure. This is because they have a tendency to be small and often out of the line of sight during the laparoscopic procedure. That is to say, they occur off camera and are thus easily overlooked.

Unlike major vascular injury, many bowel injuries go unrecognized at the time of the laparoscopic procedure. This is because they have a tendency to be small and often out of the line of sight during the laparoscopic procedure. That is to say, they occur off camera and are thus easily overlooked.

Consequently, patients present in a delayed fashion often after being discharged from the hospital and return complaining of abdominal pain or frank peritonitis. This delay fosters fecal contamination and increases the potential morbidity and mortality of this complication. Bowel injuries usually are penetrating stab wounds secondary to pneumoperitoneum needle or trocar punctures. They can also occur secondary to lacerations of the mesentery and subsequent devascularization, lacerations from retraction, and thermal injuries from electrocautery. Predisposing conditions, such as previous surgery with adhesion formation have already been mentioned (77). Again, the gynecologic literature is the dominant source for large series (78). Estimates are that almost half (42.8%) of intestinal injuries are undetected at the time of laparoscopy. Obviously, these injuries are best dealt with at the time of occurrence. Pneumoperitoneum needle injury need not be sutured, unless a laceration is also present with fecal contamination. Mini-perforations of the colon have been successfully followed with conservative measures, bowel rest, and intravenous antibiotics (79). Trocar injuries are usually much more extensive. Historically, acute large bowel perforations have been treated by prompt laparotomy, often with creation of a temporary stoma. The problem is fecal contamination from the unprepped colon (80). Increasing reports of traumatic series where closure and drainage are effective therapeutic modalities following copious irrigation. The increasing ability to be able to reconstruct visceral abdominal structures has yet to be demonstrated to produce adequate repairs.

Currently, a contaminating injury to the small or large bowel is best handled by open repair with or without proximal fecal diversion.

Currently, a contaminating injury to the small or large bowel is best handled by open repair with or without proximal fecal diversion.

Delayed presentation of bowel injury represents the other major group of patients (50,51,76). This includes those patients who have a needle or trocar injury that are missed during the laparoscopy are usually present with peritonitis between 14 and 72 hours post procedure. Thermal injuries to the bowel are also capable of delayed perforations and peritonitis. These perforations can present from 7 to 12 days following the laparoscopic procedure. In one series, a total of 10 thermal bowel injuries were noted in 3600 laparoscopic sterilization procedures (0.3%), again half were unrecognized (35). Of those recognized, four out of five were superficial serosal burns <0.5 cm in diameter and were managed successfully by observation, bowel rest, and intravenous antibiotics.

Laparoscopic urologic surgery is not similar to gynecologic sterilization procedures or laparoscopic cholecystectomy (78). The exact risks inherent in these newer procedures are not yet known. Early reports from multi-institutional series of laparoscopic pelvic lymph node dissection demonstrate a 15% complication rate (55 out of 372 cases). Of these complications, 7 out of 55 (12.7%) required immediate exploration, three vascular, and one bowel injury. An additional 6 out of 55 (10.9%) required delayed explorations, of which half involved bowel injuries (66).

Injuries to vascular structures and bowel are an ever-present possibility during laparoscopic surgery. They are best avoided by a thorough understanding of the equipment, meticulous attention to detail, and systematic inspection of the abdomen upon entrance and prior to exiting. Patient mortality is the major risk or missing an injury to either of these structures. Morbidity can be diminished by prompt identification of the injury and open exploration.

Although gynecologic pelvic surgery is the most likely type of surgical procedure to produce a laparoscopic bladder injury, an impressive number have been reported from relatively small (by comparison to the gynecologic literature) numbers of laparoscopic pelvic lymph node dissections for staging prostate cancer.

Urologic Injury

The most commonly injured urinary organ is the bladder, and the most common instrument causing injury is the Veress needle (81). Primary trocar injuries of the bladder have also been reported and secondary trocar injury to this structure is rare, with few reported cases.

Although gynecologic pelvic surgery is the most likely type of surgical procedure to produce a laparoscopic bladder injury, an impressive number have been reported from relatively small (by comparison to the gynecologic literature) numbers of laparoscopic pelvic lymph node dissections for staging prostate cancer (82–85).

In addition, laparoscopic herniorrhaphy series have a growing literature of this complication as well. The most common site within the bladder to be injured is in the midline dome. This most commonly occurs when the bladder is overdistended and a suprapubic trocar is being inserted (86). Small bladder stab wounds are capable of closing spontaneously if adequate drainage is maintained. Larger, more irregular injuries require formal closure, usually sutured two or three layered plus adequate drainage with a large Foley catheter and a drain. This has been accomplished laparoscopically by many authors. Fortunately, the diagnosis of bladder injury is made during the laparoscopic procedure. This is noted when the indwelling Foley catheter bag is filled by CO₂ gas, if the urine turns bloody, or in high-risk cases by distending the bladder with sterile saline at the conclusion of the case.

Less common injuries have been reported to the ureter, the urachus, and the kidney (87). The urachal report was noted to occur during placement of an access trocar and patency of the normally obliterated connection to the bladder. Ureteral injuries are most common during laparoscopic-assisted vaginal hysterectomy when taking down the vascular ovarian pedicles. Additional injuries have been reported from thermal coagulation with electrocautery and laser ablation of endometriosis. Nezhat and Nezhat (83) has described the laparoscopic correction of ureteral transection with the performance of a laparoscopic ureteroneocystomy (Lynch-Gregoir type). Injuries have also been published with laparoscopic colon resections, pelvic lymph node dissections, and laparoscopic radical prostatectomy series. These injuries are always rare, and their incidence appears to be not rising (49,88–94). A final rare reported complication has been noted during a laparoscopic nephrectomy in a patient with an antecedently placed percutaneous nephrostomy catheter. In this case, the kidney was ruptured secondary to the tethering effect of the nephrostomy tube during placement of one of the trocars (87).

Delayed Complications

Hernias

There is a growing amount of literature on the risk of postoperative laparoscopic hernia formation following trocar removal (95–99). The standard custom has been to close the fascia in all trocar sites 10 mm in diameter or above. The literature would suggest that although the risk of port site herniation is uncommon below the 10 mm cutoff it is by no means certain. In fact, children and obese patients are significantly at risk of herniation from the 5 mm trocars and smaller (100).

The estimated risk of developing a trocar site hernia is about 0.77% to 3.0%. This compares to the open operative counterpart risk of 10% of all cases following conventional laparotomy. The smallest trocar site currently reported with postoperative complication is a 3 mm umbilical port site. The umbilicus has been investigated as the site most likely to develop this complication. In fact, this has not held up to scrutiny (101). Any laparoscopic trocar site appears to be likely to develop herniation. Organs that can be herniated and cause symptoms include the bowel, omentum, preperitoneal fat, and rarely the large bowel (or mesentery) (102). It is important to realize that an outward pressure is produced as the laparoscopic cannulas are removed, which fosters entrapment of loose tissues such as the small bowel or omentum. This is even more likely to occur if the flapper valve of the trocar is held open during its removal. This creates a suction-like effect drawing any underlying structures into the trocars transabdominal path (103). Much work remains to be done regarding the optimal method of access site management. The evolution of the science behind this fundamental part of laparoscopic surgery is burgeoning and the potential for needless injury from this source is beginning to be questioned (104).

Wound Infections

Laparoscopic wounds, trocar sites, are different from open surgical wounds. A foreign body is introduced through the anterior abdominal wall or flank, it is locked into position with sutures or fascial screws, and it is manipulated throughout the operation by instruments that are passing and extracting to perform the work of surgery remotely (105). Infection at the trocar site has long been a clinical concern but there is no evidence that the incidence of wound infection is higher than in open surgery. In fact, there is some evidence that the risk of wound infection is less with laparoscopic procedures particularly in some high-risk populations (106–110).

The need for routine laparoscopic cases to receive prophylactic antibiotics remains controversial (111,112). In large series of laparoscopic cholecystectomy this probably is not necessary, but these cases tend to be much quicker than the usual urologic

The estimated risk of developing a trocar site hernia is about 0.77% to 3.0%.

laparoscopic case (49). In one recent prospective, randomized study on the use of prophylactic antibiotics, there was no effect on incidence and severity of infections between both groups (113). Multivariate analysis showed that diabetes mellitus and colic episodes within 30 days before surgery were independent factors significantly associated with the onset of infectious complications. Laparoscopic surgery performed for known infectious diseases such as appendicitis do show significant benefits for the routine use of prophylactic antibiotics. In a large prospective multicenter evaluation of patients operated on for appendicitis, Koch et al. demonstrated that in this high-risk group wound infections occurred in 2.5% of 4968 patients. Laparoscopic wound infections were again statistically significantly lower than with open appendectomy ($p < 0.001$) and that routine use of prophylaxis resulted in lowering the rate in both the open and laparoscopic groups. Other high-risk surgeries for wound infection have been operations upon the bowel. Laparoscopic surgical resection of the small bowel is necessary for radical cystectomy and ileal conduit formation. In a recent publication of 500 consecutive laparoscopic colorectal resections, Poulin et al. reported an incidence of postoperative wound infections of 7.2% (includes infections of both the anterior abdominal wall and perineum) (114).

Poulin et al. stated that the laparoscopic procedures have the same rate of infectious complications compared to the open counterpart. As such, the complexity of the surgery and the actual laparoscopic procedure may affect the rate of postoperative trocar site infection.

Poulin et al. stated that the laparoscopic procedures have the same rate of infectious complications compared to the open counterpart. As such, the complexity of the surgery and the actual laparoscopic procedure may affect the rate of postoperative trocar site infection.

In the urologic literature, several large series estimates that the postoperative trocar site infection rate is very low, 0.06 (49,88–90).

Port Site Metastases

Incisional metastases following open resection for cancer is an infrequent but known risk of cancer surgery (115). The first reported case of cancer recurrence was in 1978 in a patient with ovarian cancer (116). Reports for certain kinds of cancer such as colon cancer have notoriously high rates, ranging from 0.6% to 0.8%. The laparoscopic port site risk has been noted to be as high as 1.1% raising some concern about laparoscopic cancer surgery. Though rare, incisional metastatic disease is a morbid complication to patients nearing the end of life and decreases the potential for cure in patients to near zero. The port site has been portrayed to be a breeding site for tumor implantation because of the trauma that occurs in the port site (117). If viable tumor were to be seeded into such a tract, some have speculated that port site recurrence might occur. Little science and few clinical trials are available to evaluate this phenomenon but recent work has been progressing. In urologic practice, one large extensive, retrospective review identified etiologic factors such as natural malignant disease behavior (transitional cell carcinoma), host immune status, local wound factors, laparoscopy-related factors such as aerosolization of tumor cells (harmonic scalpel vs. electrocautery plumes), type of insufflant gas (CO_2 , nitrous oxide, helium, and room air), and surgical skill. Suffice it to say, that the risk of port site metastasis in urologic laparoscopic surgery seems not to be rising with associated increase in the numbers of cases (118). Methods to reduce risk should be actively employed. Attempts at reducing manipulation of the specimen should be employed during all laparoscopic procedures. Wu et al. (119) clearly demonstrated that by decreasing the inoculum of intraperitoneal cells lead to a decreased wound implant rate. Others have shown that the use of potentially cytotoxic agents such as providone-iodine solution and chemotherapeutic agents will decrease tumor implantation rates (120).

Others

A whole host of other injuries have been reported in the expanding literature of laparoscopic surgery. Hypothermia during surgery is a well-recognized result of having patients exposed for surgery in relatively cold ambient operating room environments (121). In addition, the insufflation of the abdomen with room temperature CO_2 gas might increase the potential incidence of this condition.

CO_2 gas is typically at 21.1°C at insufflation, whereas the peritoneal cavity is 35.52°C to 36.2°C. Fortunately, the peritoneum and its contents expose the insufflated gas to a large surface area, and the gas usually reaches equilibrium temperatures rather quickly. The mesenteric circulation receives 10% of the cardiac output and the estimated surface area of the peritoneal cavity is equal to that of the cutaneous surface (1–2 m²). One study by Ott (121) showed that 5 L of CO_2 gas took only 7.5 minutes to reach equilibrium to the previous intra-abdominal temperature (121).

CO_2 gas is typically at 21.1°C at insufflation, whereas the peritoneal cavity is 35.52°C to 36.2°C.

Core temperatures decreased at a rate of 0.3°C for each 50 L of CO₂ used during continuous infusion during a laparoscopic case. It is advisable, especially during prolonged laparoscopic procedures to warm the patient with an external warmer throughout the procedure to minimize the risk of hypothermia.

Core temperatures decreased at a rate of 0.3°C for each 50 L of CO₂ used during continuous infusion during a laparoscopic case. It is advisable, especially during prolonged laparoscopic procedures to warm the patient with an external warmer throughout the procedure to minimize the risk of hypothermia.

Adhesion formation following laparoscopic procedures is often thought to be reduced secondary to a lessened inflammatory response; however, they can and do occur (122,123). Intraperitoneal adhesion formation with the formation of long-term complications of bowel obstruction can be due to inflammation caused by fibrin clot accumulation or direct manipulative injury and subsequent repair processes to the bowel. In numerous studies, laparoscopic procedures routinely demonstrate less risk of subsequent adhesion formation than the open counterpart (123). Controversy continues as to whether instilling a solution of lactated Ringer's or normal saline with or without an antibiotic leads to even fewer adhesions. In addition, additives such as heparin, hyaluronic acid, and tolmentin have also been postulated to decrease the risk of this unusual complication (124).

Other rare risks of laparoscopic surgery include injury to nerves (125). The most commonly injured nerve would be the motor obturator nerve during a laparoscopic pelvic lymph node dissection. Injuries can be direct, that is cutting, lacerating, or crushing the nerve. More likely however, is an indirect nerve injury that can occur by conduction of electrical current (72). These types of nerve injuries manifest insidiously during the postoperative recovery period. Since the nerve is not transected, it gradually becomes less viable and incomplete nerve conduction gradually gives way to a more complete injury. This injury has been also reported to occur with the long thoracic nerve that can be injured with a conductive injury to the inner aspect of the anterior abdominal wall. These patients demonstrate loss of motor function such as inability to adduct the leg with injury to the obturator nerve and winging of the scapula with injury to the long thoracic nerve. Most of the time, a thermal conductive injury to the nerve will resolve over time. This is probably secondary to axonal regeneration. Severed nerves however will not recover unless repaired. An observed injury to a major motor nerve should prompt repair of the injury.

Another category of rare laparoscopic injuries are those associated with retained foreign bodies (126). It is hard to imagine that with the abdomen closed and only trocars traversing the abdominal wall that foreign bodies could be left behind, but in fact this has occurred. As complex intraperitoneal laparoscopic surgeries arise, the inherent complexities and the use of more portals for assistance and retraction will carry an increased risk for foreign body retention. Retroperitoneal dilation balloons can rupture and pieces of the balloon are capable of being left behind (127,128). In one of the largest reported series of retroperineoscopy, Gaur noted that in 351 procedures the retroperitoneal balloon ruptured in several cases, but Gaur et al. (127) state that balloon rupture causes no tissue damage. Adams et al. (128) did report that balloon rupture could lead to excessive times for hunting for fragments. Since the balloon material is typically not radiopaque, only visual exploration can discover their presence. Moore et al. (129) noted that a balloon inflated with liquid created less energy release than a similarly inflated balloon with gas. Laparoscopic clips likewise are foreign and if left behind can cause future consequences (130). Migration of these metallic foreign bodies can happen (131). Finally, the urinary bladder has been identified as the final repository of some of these foreign bodies, such as microtacks that are becoming popular for the performance of laparoscopic hernia repairs (132).

Prevention

It is always preferable to have no complications. This is rarely ever entirely possible, but there are many factors that can be controlled and deserve mentioning here.

First and foremost, the inexperienced or unskilled laparoscopic surgeon is more likely to have significant complications (133). Gaining experience and skill is mandatory. This is best done in a supervised well-controlled environment. Second, the instruments and equipment should be thoroughly familiar with the surgeon (71). Dull trocars, too small of an incision, uncontrolled forward force are all capable of producing catastrophic consequences, particularly major vascular injuries. Simple positional changes can facilitate complex maneuvers such as access, displacement of viscera, or allow straighter trajectory for an instrument. Perpendicular insertion of access instruments such as the Veress needle or trocar can lead to uncontrolled forceful insertions, which is asking for trouble. Lateral deviation of the needle or trocar can also shear into the abdominal wall or any underlying structures and should be avoided until full visual control has been established. An inadequate pneumoperitoneum reduces the working

It is always preferable to have no complications. This is rarely ever entirely possible, but there are many factors that can be controlled and deserve mentioning here.

Forceful thrusting with any laparoscopic device should never occur. As mentioned previously, force, especially in a closed pressurized environment, is never good.

Finally, make sure that all trocar insertion sites have an adequate skin incision to avoid insertion with unintended forward thrust.

Complications of laparoscopic surgery are a major concern for the patient and the surgeon. There is no doubt that the incidence of injury is proportional to the skill and experience of the surgeon.

Why would a urologist who has spent half a life time training and improving own skills at open urologic surgery wish to start a laparoscopic practice? The only answer lies in the fact that things go well, as they most often do, the patient does much better having not been traumatized to the degree that occurs during standard operative techniques. As Sir Alfred Cushieri has so eloquently phrased, "the ego of the surgeon must always be subservient to the needs of the patient."

space for the surgeon and impairs the ability to see peripherally. Whenever the field of view appears to become obscured, consider loss of pneumoperitoneum.

Forceful thrusting with any laparoscopic device should never occur. As mentioned previously, force, especially in a closed pressurized environment, is never good.

Anatomical landmarks should be sought, for laparoscopic anatomy is more statistical and less visual. That is to say, the probability of variability of anatomical structures especially vascular ones should always be forefront in the thoughts of the laparoscopic surgeon. During dissection and accidentally avulsing an accessory vein or artery is the wrong time to consider the possibility of it being there (134).

Finally, make sure that all trocar insertion sites have an adequate skin incision to avoid insertion with unintended forward thrust.

Port site herniation is an interesting problem from a preventative position. As in open surgery, the surgeon is near the conclusion of the operation and the fundamentals of closure can be at times rapidly applied or not fully attended (101,102). Some simple principles apply: do not remove a cannula with their flapper valves open, use the smallest trocar possible (risk of postoperative herniation varies directly with the trocar size), visualize the removal of each trocar, close the fascia of all cannula sites larger than 5 mm (in children and diabetics consider closing the 5 mm ones as well), shake the abdominal wall after the cannulas are removed and before placing fascial closure stitches to reduce the likelihood of viscera protruding into the trocar paths, and if the peritoneum is going to be closed, do so tightly. There are reports of underlying bowel and omentum protruding into large preperitoneal cavities following attempts to close the peritoneum. This could lead to small bowel obstruction and significant postoperative pain.

Medicolegal Issues

Using Chandler et al.'s data discussed previously, the U.S. claims were more likely to have an indemnity payment than those foreign, but this value was not statistically significant. The mean payment for National Association of Insurance Commissioners severity and outcome codes for 2 to 5 was \$18,000; for codes 6 and 7 (significant and major permanent, respectively) was \$654,000; and if the outcome was fatal the payment was \$351,000. A summary of their claims outcome data is summarized in Table 4 (47).

Complications of laparoscopic surgery are a major concern for the patient and the surgeon. There is no doubt that the incidence of injury is proportional to the skill and experience of the surgeon.

The reasons for these observations are probably related to the mechanical disadvantages of working within a confined environment, isolating the surgeon from the normal tactile and sensory ability that is taken for granted with a patient opened. These drawbacks may be overcome in the future by even more advanced digital fusion technologies such as robotic-assisted surgery and microrobotic surgery, virtual reality simulation similar to aviation trainers, endoluminal surgical techniques, and genetic manipulation (136).

Why would a urologist who has spent half a life time training and improving own skills at open urologic surgery wish to start a laparoscopic practice? The only answer lies in the fact that things go well, as they most often do, the patient does much better having not been traumatized to the degree that occurs during standard operative techniques. As Sir Alfred Cushieri (137) has so eloquently phrased, "the ego of the surgeon must always be subservient to the needs of the patient."

INFORMED CONSENT

The risks of laparoscopy are still significant. It is widely recognized that the risk of litigation is influenced by the thoroughness and documentation of informed patient

TABLE 4 ■ A Summary of Indemnity Payments for Litigation of Laparoscopic Malpractice

Outcomes	United States	Europe/Australia/Canada
Years after event (±SD)	5.4 ± 3.0	5.7 ± 2.2
Open without resolution (n)	37 (27%)	83 (70%)
Closed (n)	98 (73%)	36 (30%)
With payment	53 (54%)	13 (36%)
Median payment (\$)	127,000	55,000
Payment range (\$)	7,500-4,980,000	1,500-315,955
Principal payment correlate	Incremental disability	Death

consent and alternatives to the procedures. Complications should be “reasonably” described. Presented here is a detailed description of the risks of urologic laparoscopy from which the physician can more readily generate the required disclosure.

Currently, there is a medical malpractice crisis ongoing in the United States (138). Surgeons are the prime target for burgeoning malpractice litigation. Despite the many “potential” benefits of laparoscopic surgery, medical malpractice concerns could be considered as a potential detriment to the acquisition of these advanced skills. Data from medical insurance companies indicate a definite rise in malpractice claims. The real rise in laparoscopic surgeries began in late 1989 (139). If complications reflect the learning curve of new surgeries and new surgeons, one could have expected a plateau of malpractice activity soon following this date. This in fact, has not occurred. There has been a steady, continuous rise in both the number of malpractice claims and the percentage of claims with pay out to the plaintiff (140). Also, when a jury finds in favor of the plaintiff in a laparoscopic malpractice suit, the probable result will be a higher award than in a similar open procedure. Though no one can say what is the driving force in this evolution, the most compelling explanation is that the patients are going into to these types of “minimally invasive” or “band-aid” operations with unrealistic expectations. That is to say that the patient perceives that something less significant is going to happen to them than if they were to undergo a “real” operation. Patients are told that the laparoscopic procedure will cause less postoperative pain, that they will recover quicker, that they can resume normal activities more quickly, and that they will have little scars. Add an actual complication and the disappointment to the patient is hard to minimize, especially when the patients have to suffer the “horror” of scarring, prolonged hospital stays, and the possibility of several operations to repair an inadvertent injury. It is not a difficult scenario for a jury to find in favor of the plaintiff.

Informed Consent Legalese

The jargon utilized by the legal system can be overwhelming. Some basic definitions are warranted for review (141). A plaintiff is the person who alleges malpractice. The defendant is the laparoscopic urologic surgeon, an assistant, and possibly the hospital where the surgery was performed. A complication is some difficulty, problem, or change in the patient’s health that is unintended. Negligence is the failure to exercise the degree of care considered reasonable under the circumstances, resulting in an unintended injury to the plaintiff. Damages are the estimated valuation of the injury sustained. Informed consent is the process, whereby the patient is informed about treatment options, alternative treatment modalities, the risks of treatment, the benefits of treatment and must provide for the answering of a patient’s questions (142).

For many patients, the occurrence of a complication automatically demonstrates negligence. The primary defense of a laparoscopic surgeon to an allegation of lack of informed consent is documentation of adequate informed consent.

The medical record can be the surgeon’s best friend or worst enemy. It behooves the laparoscopic urologic surgical practitioner to understand fully the requirement of adequate informed consent (143). Although persons other than the surgeon may obtain the patient’s signature on an informed consent document, may hand out educational pamphlets, and show videos of surgical decision making, the surgeon must go through those obligatory steps just outlined and would be well advised to document it all in the patient record.

The issue of complications rates and trends in laparoscopic surgery are far more advanced in gynecology and general surgery than they are in urology (134,144–146). In fact, there have been little published data on complication rates following laparoscopic urologic surgery because series have tended to be small, follow-up still is short, and multi-institutional collaborations are just beginning to report. Laparoscopic complications can be grouped into those that are generally related to laparoscopy (access, exit, pneumoperitoneum injuries) and those that are specifically related to the procedure (laparoscopic nephrectomy, laparoscopic radical prostatectomy, etc.). It is important to note that procedural-related complications should be independent of the approach, thus unique to the operation being performed. This is important because an individual who has an unusually high procedural-related complication rate indicates an error in judgment or technique. Current trends from malpractice databases indicate that injuries general to laparoscopy are in the minority of lawsuits, under 25%, and declining (146). Knowledge on trends in complications serves two purposes; it allows the surgeon insight into the problems encountered by others practicing similarly. It is obvious that if you are aware of possible complications, you are more apt to try to prevent it from occurring.

For many patients, the occurrence of a complication automatically demonstrates negligence. The primary defense of a laparoscopic surgeon to an allegation of lack of informed consent is documentation of adequate informed consent.

The risk of laparoscopic malpractice in general surgery centers around three specific complications in 90% of cases: bile duct injury, perforating bowel injury, and major vascular injury. Currently, about two-thirds of laparoscopic complications are bile duct injuries during laparoscopic cholecystectomy and though interesting for those curious about injury, injury prevention, malpractice issues, and preventative mechanisms, there is little significantly relevant to urologic discussions; so attention will be focused upon the remaining 34% of laparoscopic injuries. Currently 12% of injuries are bowel related, 10% are vascular, and 11% are other injuries. In this other category includes a hodgepodge of various complications including fistula formation (2%), burns (2%), retained gall stones (1%), retained foreign body (1%), and others (ureteral or bladder injury, incidental splenectomy, etc., 6%) (21,26). Because most surgeons still utilize the blind Veress needle method for pneumoinsufflation because the risks are quite small, the primary common access complication is from the initial trocar access. Blind trocar insertion injuries can probably be eliminated or significantly reduced if open insertion techniques are utilized. It has been estimated that the surgeon automatically reduces risk to the patient by 20% by utilization of open laparoscopic access. Open laparoscopic access does not eliminate injury to underlying viscera and vessels, but it reduces the probability (147).

Informed consent is derived from judicial decisions and not statute. One exception is New York Public Health § 2805-d enacted as Chapter 109 of the New York Laws of 1975 (148). A person facing the prospect of surgery must be aware of the untoward side effects that are known to result from the proposed surgical procedure, the intended beneficial effects of the proposed surgical procedure, and the alternative reasonable ways to address the patient's problems. These risks, benefits, and alternatives must be discussed with every patient or the patient's legal guardian in order to insure that informed consent is secured. The problem with these terms comes in the derived method of interpretation. The court differ on how much information must be divulged to each patient in order to make each decision informed? The early rule was that a physician had to disclose what a "reasonable doctor" would provide under the circumstances. Later, courts required physicians to disclose what a "reasonable patient" would wish to know before making a decision (149).

Informed consent cannot be obtained from the patient who is impaired such that the patient lacks capacity to give consent (150). Certainly, it is not wise for a patient to be asked to sign the consent form in the operative holding area (151). Most laparoscopic urologic surgeries are thought of as elective procedures. Therefore, the time afforded the patient to make an informed decision should be documented. With information provided to the patient and family well in advance, the patient may pose questions, confer with other physicians, or ask for a second opinion (152). This ideally minimizes the duress experienced when the consent is obtained. When patients are minors or incapacitated, discussions should be held in the same fashion with the patient's legal guardian. In the case of an emergency, the physician must inform the patient to the best of his ability and within the constraints of time and the patient's severity of illness (150). It should be remembered that there are three varying perspectives that alter negligence: the patient's, the doctor's, and the lawyer's.

Legal counsels recommend four steps to lower your litigation risks (134). First is secured via a thorough informed consent. Second is communicative clarity with the patient. Third is demonstrating concern for the patient's medical condition. Fourth is mastering technically difficult procedures.

The legal implications of any reasonable patient implies that if a surgeon lacks familiarity with a given endoscopic procedure, it is advisable to inform the patient that this is the first time the surgeon is performing the procedure (54).

Some would advise with common knowledge about the "learning curves" of various laparoscopic operations that the patient deserves to know how many the surgeon has performed (154).

The risks of laparoscopic urologic surgery are changing. In 1987, Weinberg et al. (155) were the first to suggest that practical experience and the number of complex ureteropyeloscopies represented a fundamental variable in the number and seriousness of complications. They noted that in centers where greater than 50 ureteropyeloscopies were performed per year the success rate was noted to be 84%, whereas if less than 20 cases were done the success rate was 78% (all stone removals). Major ureteral injury in this review was 4.4% with total complication rates of 10% (including postoperative fever). Complications were twice as likely to occur at centers where fewer than 20 cases were performed versus centers that did more than 50 cases (155). Whether these same trends apply to laparoscopic urologic surgery is not yet known. The abundant surgical literature would support this claim that the complication rates do go down as the number of cases the surgeon performs increases.

Legal counsels recommend four steps to lower your litigation risks. First is secured via a thorough informed consent. Second is communicative clarity with the patient. Third is demonstrating concern for the patient's medical condition. Fourth is mastering technically difficult procedures. The legal implications of any reasonable patient implies that if a surgeon lacks familiarity with a given endoscopic procedure, it is advisable to inform the patient that this is the first time the surgeon is performing the procedure.

Costs of Training/Ethical Considerations of Certification

Following initial reports of laparoscopic cholecystectomy, surgical practice in the United States has undergone substantial change. There has been a torrential outpouring of interest to learn new endoscopic techniques. The costs absorbed by practitioners to attend courses were hefty and few academic centers availed themselves of the early training experience (156). Some groups started small businesses of training surgeons, as the demand was so acute and the courses themselves proved financially rewarding. This scenario is not entirely different to the training conditions of the late 1800s in the United States, where Halsted (157) stated, “the man who had settled his tuition bill was thus practically assured of his degree, whether he had regularly attended lectures or not.”

The history of postgraduate surgical education is very limited. The laparoscopic boom of the early 1990s changed all of this. Traditional academic centers were bypassed by industry and practicing surgeons began courses “for profit” in unregulated fashion, with no defined objectives, and with no consideration of surgical application of skilled technique. Dr. Seymour Schwartz (158) stated at one point, “the speed of change has resulted in a scenario where the more senior educators, usually those responsible for the structure and format of educational programs, are the least informed about modern elements.” The patient was the ultimate denominator in this process of an unregulated sprint for application of complex technology to a common clinical condition. Since organized, academic medicine was unwilling or unable to halt this process, the State of New York issued a memorandum in 1992 that training and credentialing surgeons needs further scrutiny (159). As of 1999, according to the American Board of Surgery, the mean number of advanced laparoscopic procedures performed by graduate trainees was fewer than 10 (160). The American Board of Urology has not issued any information regarding graduate training patterns for U.S.-trained urologists, but surveys among endourologists at leading academic centers suggests that no letters of credential support has yet been issued for laparoscopic urologic surgery.

Interestingly, the Society of American Gastrointestinal Endoscopic Surgeons (161) approved guidelines for granting privileges to general surgeons performing laparoscopy in May of 1990. Individual institutions are currently encouraged to develop their own guidelines on accreditation. The Society of American Gastrointestinal Endoscopic Surgeons board of governors developed and issued the “framework of postresidency training” in 1994, to serve as a template for the American Medical Association’s guidelines for postresidency training and credentialing. In 1997, in cooperation with both U.S. Surgical Corp. and Ethicon Endo-Surgery, Society of American Gastrointestinal Endoscopic Surgeons commenced biannual courses in advanced laparoscopic surgery. By 1998, Society of American Gastrointestinal Endoscopic Surgeons published its first manual on laparoscopic surgery and began work on an interactive computer-based program to enhance surgical laparoscopic skill, called the fundamentals of laparoscopic surgery program (161). No other organized group, other than the Society of Laparoscopic Gynecologists has been more proactive in the educational concerns that continue to haunt advanced laparoscopic technology and their clinical application. Frank Spencer’s (162) presidential address of the International Cardiovascular Society 25 years ago is a poignant today as it was then, “Clearly a large part of education, especially in this age of rapid obsolescence of knowledge within a few years, should be in the postresidency years. This seems particularly significant to me, for over 90% of the operations I currently perform simply did not exist when I finished my residency.”

Postresidency education is such a critical issue in light of modern laparoscopic accomplishments that it should become a central issue to our governing boards and societies.

The American Board of Medical Specialties created a task force to investigate competencies (163). They realized that they must adopt a method of reviews that would cover the training of physicians as a continuum from residency through retirement. “Depth as well as breadth can be discerned as physicians explore levels of expertise ranging from novice to master,” states Leach (164) in a recent article. The Accreditation Council for Graduate Medical Education in 1999 endorsed six general competencies: patient care, medical knowledge, practice-based learning and improvement, professionalism, interpersonal and communication skills, and system-based practice. The “Professor,” Sir William Osler (165), once stated, “the whole art of medicine is an observation ... but to educate the eye to see, the ear to hear, and the finger to feel take time ... to start a man on the right path, is all we can do.”

Medicolegal Considerations

Kohn et al. (166) have estimated that between 44,000 and 98,000 deaths annually have been attributed to medical error in their work *To Err is Human*. As the endoscopic surgeon is entirely dependent upon the technology and skill, there has been increased emphasis

Postresidency education is such a critical issue in light of modern laparoscopic accomplishments that it should become a central issue to our governing boards and societies.

on comparing the laparoscopic surgeon to the airline pilot. In aviation, the pilot is expected to perform with a risk of failure less than 0.0001%. If the same holds to laparoscopic surgery, with laparoscopic cholecystectomy (the most commonly performed laparoscopic procedure in the world) as the yardstick, then bile duct injury rate of 0.5% seems unacceptable (167). Most complications can be prevented by complete control of the technology and the procedure. The fact that an increase in the performance of laparoscopic surgery has led to rise in the numbers of malpractice litigation should not be surprising. In fact, the Association of Trial Lawyers of America set a specialized subdivision in 1994, the Laparoscopic Litigation Group, that advises lawyers on how to approach laparoscopic surgery cases. Most laparoscopic surgery cases that go to a jury verdict, favor the defendant (47). One source of in-depth information comes from the Physician Insurers Association of America involving laparoscopic injuries in the United States. The Physician Insurers Association of America is a trade association of physician- and dentist-owned professional liability insurers, with more than 60 member companies that insure greater than 60% of all U.S. private practice groups. There are also affiliated groups in Europe, Australia, and Canada (24). One recent study abstracted claims from this group from 1980 to 1999 and identified 364 U.S. claims and from 1986 to 1999 identified 137 non-U.S. claims. For each case they utilized the National Association of Insurance Commissioners severity index coding (47).

Chandler et al. (47) found that 594 structures or organs were injured in 506 patients, ranging in age from 9 to 86 years. The mean age was 41.6 years and 86% of the patients were women. Two organs or structures were injured in 64 patients, and three or more structures were damaged in 11 individuals. Laparoscopic cholecystectomies comprised 51% of the Physician Insurers Association of America claims in the United States whereas gynecologic laparoscopy comprised 47% of non-U.S. claims. The most frequently injured structure was the small bowel ($n = 146$, 25.4%), iliac artery ($n = 106$, 18.5%), colon ($n = 70$, 12.2%), iliac or other vein ($n = 51$, 8.9%), mesenteric vessel(s) ($n = 42$, 7.3%), aorta ($n = 37$, 6.4%), inferior vena cava ($n = 25$, 4.4%), abdominal wall vessels ($n = 229$, 3.8%), urinary bladder ($n = 19$, 3.3%), liver ($n = 13$, 2.3%), major visceral vessel ($n = 10$, 1.6%), stomach ($n = 9$, 1.6%), and other ($n = 24$, 4.2%). The severity of the injury using the National Association of Insurance Commissioners score was reflected in the fact that more than half of survivors (55%) were scored as 4, indicating major temporary impairment or disability. Sixty-five fatalities were reported. Mortality was significantly lower in the U.S. cases than in the non-U.S. cases. Logistic regression showed that an age greater than 59 years was the sole significant predictor of survival from a major laparoscopic injury. Injury to major viscera vessels and delay in diagnosis greater than 24-hours were significant variables. Looking at indemnity payments, those made in U.S. cases were significantly greater median payments than those from non-U.S. cases. The mean payment for National Association of Insurance Commissioners severity codes 2–5 was \$118,000; for codes 6 and 7 it was \$654,000, and for fatal outcomes the award was \$351,000. The payment for plaintiffs in the United States ranged from \$7500 to \$4,980,086. In non-U.S. cases, the range was \$1500 to \$315,955. These findings particularly underscore the subtleness, lethality, and litigious attractiveness of laparoscopic bowel injuries. Electrosurgery injuries are particularly catastrophic even if they are noticed. The depth of thermal necrosis is difficult if not impossible to assess at the time of occurrence, and perforation might not occur at all. Most electrosurgical injuries occur out of the surgeon's line of sight and are missed. This presents that same subtle presentation, which requires careful attention and high degree of suspicion. These injuries are all more likely to occur during the surgeon's initial experience with advanced laparoscopic procedures (24,47).

SUMMARY

- Routine urologic laparoscopic surgery is no longer futuristic, but actual clinical practice at some institutions. Horizons for expanding the laparoscopic surgical realm are broad (168).
- Manufacturers, research engineers, optical engineers, roboticists, computer engineers, software engineers, communications specialists, and surgeons must be able to constructively work together in order to minimize the time to perfect new instruments and procedures (169,170).
- The doctor-patient relationship must always be of foremost concern to the laparoscopic surgeon. The trust in the surgeon for allowing the patient to be the first to have this procedure done cannot be underestimated. Ethically, the laparoscopic surgeon must be forthright in assessing own skills, the mastery of the laparoscopic procedure, the indications of the procedure, and must maintain healthy skepticism of newer procedures until adequate data are available (171-174).

- The proctor for laparoscopic urologic surgery has to date benefited from unprecedented legal immunity. Proctoring and peer reviews remain mechanisms utilized by physicians to ensure high-quality outcomes, and as such, continue to receive comprehensive legal immunity in order to prevent reprisals (175). The law is clear that the some kind of proctorship is necessary for physicians to begin to practice advanced technologic surgeries, neither legal cases nor the Joint Commission on Accreditation of Hospitals provides much guidance on the process to fulfill this responsibility (176).
- New technology has an apparent life cycle with five stages: (i) feasibility (technical performance, applicability, safety complications, morbidity, mortality); (ii) efficacy (benefit for the patient demonstrated in centers of excellence); (iii) effectiveness (benefit for the patient under normal conditions, reproducible with widespread application); (iv) costs (benefit in terms of cost effectiveness); (v) gold standard (177).

REFERENCES

1. New York State Department of Health Memorandum H-18, June 12, 1992.
2. Kahan SE, Goldman HB, Marengo S, Resnick MI. Urological medical malpractice. *J Urol* 2001; 165:1638–1642.
3. Koontz WW, Russel JB. Thought on the prevention of urologic liability claims. *Trans Am Assoc Genitourin Surg* 1977; 68:33.
4. Corcaran M. What is negligence? *BJU Int* 2000; 86:280–285.
5. Garmisa SP. Informed consent. *Chicago Daily Law Bulletin*, May 14, 2004.
6. Tammelleo AD. Are hospitals required to obtain patients' consent to surgery? 41 *Hospital Law's Regan Report*, June 1, 2000.
7. Hendy v Milton Keynes Health Authority (No 2). *QBD Med LR* 1992; 3(1):119.
8. Hooper v Young. Court of Appeal (1998) *Lloyd's Rep. Med*, 61.
9. Hatlie MJ. Climbing the learning curve. New technologies, emerging obligations. *JAMA* 1993; 270:1364–1365.
10. Reingold PD. The admissibility of evidence in malpractice cases: the performance records of practitioners. *Brooklyn Law Rev* 1992; 58:75–80.
11. Mackauf SH. Identifying medical malpractice cases: attorneys find recurring themes in the types of claims they handle. *New York Law J* 2001.
12. Provider-specific quality of care data: a proposal for mandatory disclosure. *Brooklyn Law Rev* 1992; 58:85.
13. Jones B. Legal aspects of consent. *BJU Int* 2000; 86:275–279.
14. Walter P. The doctrine of informed consent: to inform or not to inform. 71 *St. John's Law Rev* 1997; 543:454.
15. Hickey JD, Cowan J. Risk management and medicolegal issues in urology. *BJU Int* 2000; 86:271–274.
16. McManus PL, Wheatley KE. Consent and complication: risk disclosure varies widely between individual surgeons. *Ann R Coll Surg Engl* 2003; 85:79–82.
17. Australian Law Reform Commission. *Informed Decisions About Medical Procedures*. Canberra: ALRC, 1989.
18. Wijtenburg E, Navez B, Combier E, Guiot P. Patient's opinion about written information before laparoscopy: a consecutive series of 100 cases. *Acta Chir Belg* 2002; 102:17–19.
19. Kern KA. Medicolegal perspectives on laparoscopic bile duct injuries. *Surg Clin North Am* 1994; 74:979–984.
20. Altman LK. Surgical injuries lead to new rule. *New York Times*, June 19, 1992:1.
21. Ferriman A. Laparoscopic surgery: two thirds of injuries initially missed. *BMJ* 2000; 321:784.
22. Adelman SH, McBryde AM. Can using emergent technology incur liability? *Bull Am Coll Surg* 1998; 83:18–24.
23. Chandler JG, Voyles CR, Floore TL, Bartholomew LA. Litigious consequences of open and laparoscopic surgical mishaps. *J Gastrointest Surg* 1997; 1:138–145.
24. Avery JK. Price of the learning curve? *J Tenn Med Assoc*; 1994; 87:338–339.
25. Hashizume M, Sugimachi K. Needle and trocar injury during laparoscopic surgery in Japan. *Surg Endosc* 1997; 11:1198–1201.
26. Gawande A. *Complications. A Surgeon's Notes on an Imperfect Science*. New York: Picador, 2002.
27. MacCordick C, Lecuru F, Rizk E, Robin F, Boucaya V, Taurelle R. Morbidity in laparoscopic gynecologic surgery. *Surg Endosc* 1999; 13:57–61.
28. Leibl BJ, Schmedt C-G, Schwarz J, Kraft K, Bittner R. Laparoscopic surgery complications associated with trocar tip design: review of the literature and own results. *J Laparoendosc Adv Surg Techn* 1999; 9:135–140.
29. Capelouto CC, Kavoussi LR. Complications of laparoscopic surgery. *Urology* 1993; 42:2–12.
30. Adamek HE, Maier M, Benz C, Huber, Schilling D, Rieman JF. Severe complications in diagnostic laparoscopy. 9 years experience in 747 examinations. *Med Klin* 1996; 91:694–697.
31. Andrei B. Myomectomy by pelviscopy. *Int Surg* 1996; 81:271–275.
32. Karki-Sirren P, Kurki T. A nationwide analysis of laparoscopic complications. *Obstet Gynecol* 1997; 89:108–112.

33. Hulka J, Peterson HB, Phillips JM, Surrey MW. Operative laparoscopy: American Association of Gynecologic Laparoscopists' 1993 membership survey. *J Am Assoc Gynecol Laparosc* 1995; 2:133-136.
34. Ortiz J, Buquet R, Singla J, Rivero L. Complications in laparoscopy. *J Am Assoc Gynecol Laparosc* 1995; 2:S38.
35. Peterson H, Hulka J, Phillips J. American Association of Gynecologic Laparoscopists' 1988 membership survey on operative laparoscopy. *J Reprod Med* 1990; 35:587-589.
36. Querleu D, Chapron C. Complications of gynecologic laparoscopic surgery. *Curr Opin Obstet Gynecol* 1995; 7:257-261.
37. Riedel H, Camara O, Schulze G, Brosche T, Blaut T. Pelviscopic survey in Eastern Germany. *J Am Assoc Gynecol Laparosc* 1996; 3:S42.
38. Saidi MH, Vancaillie TG, White AJ, Sadler RK, Akright BD, Farhart SA. Complications of advanced operative laparoscopy: a review of 452 cases. *J Am Assoc Gynecol Laparosc* 1994; 1:S31.
39. Phillips JM. Complications in laparoscopy. *Int J Gynecol Obstet* 1977; 15:157-162.
40. Shantha TR, Harden J. Laparoscopic cholecystectomy: anesthesia-related complications and guidelines. *Surg Laparosc Endosc* 1991; 3:173-178.
41. Kane MJ, Krejs GJ. Complications of laparoscopy in Dallas: a 7 year prospective study. *Gastrointest Endosc* 1984; 30:237-240.
42. The Southern Surgeons Club. A prospective analysis of 1518 laparoscopic cholecystectomies. *N Engl J Med* 1991; 324:1073-1078.
43. Wolfe BM, Gardiner BN, Leary BF, Frey CF. Endoscopic cholecystectomy: an analysis of complications. *Arch Surg* 1991; 126:1192-1198.
44. Ball TJ. Laparoscopic cholecystectomy: complications call for caution. *Pract Gastroenterol* 1991; 15:31-45.
45. Philips PA, Amaral JF. Abdominal access complications in laparoscopic surgery. *J Am Coll Surg* 2001; 192:525-536.
46. Moran ME. The management of laparoscopic injuries of the bowel or blood vessels. *Min Invasive Ther* 2:289-291.
47. Chandler JG, Corson SL, Way LW. Three spectra of laparoscopic entry access injuries. *J Am Coll Surg* 2001; 192:478-491.
48. Hanney RM, Carmalt HL, Merrett N, Tait N. Use of Hasson cannula producing major vascular injury at laparoscopy. *Surg Endosc* 1999; 13:1238-1240.
49. Parsons JK, Varkarakis I, Rha KH, Jarrett TW, Pinto PA, Kavoussi LR. Complications of abdominal urologic laparoscopy: longitudinal five-year analysis. *Urology* 2004; 63:27-32.
50. Birns ME. Inadvertent instrumental perforation of the colon during laparoscopy: non-surgical repair. *Gastrointest Endosc* 1989; 35:54.
51. Virardell F, Seres I, Marti VA. Complications of peritoneoscopy: a survey of 1,455 examinations. *Gastrointest Endosc* 1968; 14:178.
52. Sadeghi-Nejad H, Kavoussi LR, Peters CA. Bowel injury in open technique laparoscopic cannula placement. *Urology* 1994; 43:559-560.
53. Wu M-P, Ou C-S, Chen S-L, Yen YET, Rowbotham R. Complications and recommended practices for electrosurgery in laparoscopy. *Am J Surg* 2000; 179:67-73.
54. State of New York Department of Health. Health Department issues advisory on laparoscopic surgery. *DOH News* 1992; June 14:1-14.
55. The risks of laparoscopic electrosurgery. *Health Dev* 1995; 24:4-5.
56. Monopolar electrosurgical safety during laparoscopy. *Health Dev* 1995; 24:6-27.
57. Voyles CR, Tucker RD. Education and engineering solutions for potential problems with laparoscopic monopolar electrosurgery. *Am J Surg* 1992; 164:57-62.
58. Remorgida V, Anserini P, Prigione S, Magnasco A, Fulcheri E. The behaviour of plastic-insulated instruments in electrosurgery: an overview. *Min Invas Ther Allied Technol* 1999; 8:77-81.
59. Kennedy JS, Buysse SP, Lawes KR, Ryan TP. Recent innovations in bipolar electrosurgery. *Min Invas Ther Allied Technol* 1999; 8:95-99.
60. Eggleston JL, Kennedy JS, Platt RC, Taylor KD. 'Instant Response™' electrosurgery generator for laparoscopy and endoscopy. *Min Invas Ther Allied Technol* 1997; 5(6):491-495.
61. Haag R, Cuschieri A. Recent advances in high-frequency electrosurgery: development of automated systems. *J R Coll Surg Edinb* 1993; 38:354-364.
62. Amaral JF, Chrostek CA. Experimental comparison of the ultrasonically-activated scalpel to electrosurgery and laser surgery for laparoscopic use. *Min Invas Ther Allied Technol* 1997; 6:324-331.
63. Kanehira E, Kinoshita T, Omura K. Ultrasonically-activated devices for endoscopic surgery. *Min Invas Ther Allied Technol* 1999; 8:89-94.
64. Kinoshita T, Kanehira E, Omura K, Kawakami K, Watanabe Y. Experimental study on heat production by a 23.5 kHz ultrasonically activated device for endoscopic surgery. *Surg Endosc* 1999; 13:621-625.
65. Dixon M, Carillo EH. Iliac vascular injuries during elective laparoscopic surgery. *Surg Endosc* 1999; 13:1230-1233.
66. Baadsgaard SE, Bille S, Egeblad K. Major vascular injury during gynecologic laparoscopy. Report of a case and review of published cases. *Acta Obstet Gynecol Scand* 1989; 68:283.
67. Lazasides MK, Arvanitis DP, Liatas AC, Doyantas JN. Iatrogenic and non-iatrogenic arterial trauma: a comparative study. *Eur J Surg* 1991; 157:17.
68. Oza KN, O'Donnell N, Fisher JB. Aortic laceration: a rare complication of laparoscopy. *J Laparoendosc Surg* 1992; 2:235-237.
69. McAllister M, Bhayani SB, Ong A, et al. Vena caval transection during retroperitoneoscopic nephrectomy: report of the complication and review of the literature. *J Urol* 2004; 172:183-185.

70. Regier H. Litigation in laparoscopy. *Gen Surg News* 1998; 8:1–8.
71. Special report on laparoscopy litigation group. *Laparoendosc Surg Update* 1995; 3:121–123.
72. Fishman J, Moran ME, Carey R. Obturator neuropathy after laparoscopic lymphadenectomy. *Urology* 1993; 42:198–200.
73. Low RK, Moran ME, Goodnight JE. Laparoscopic hemostasis: microfibrillar collagen hemostat during directed biopsy. *J Laparoendosc Surg* 1993; 3:415–420.
74. Green LS, Loughlin KR, Kavoussi L. Management of epigastric vessel injury during laparoscopy. *J Endourol* 1992; 6:95.
75. Hinsl K, Neal P. Management of epigastric vessel injury during laparoscopic nephrectomy. *Western Section AUA : Precis*, 1992:310.
76. Thompson EH, Wheelless CR. Gastrointestinal complications of laparoscopy sterilization. *Obstet Gynecol* 1973; 41:669.
77. Lecuru F, Leonard F, Jais JP, Rizk E, Robin F, Taurelle R. Laparoscopy in patients with prior surgery: results of blind approach. *JSL* 2001; 5:13–16.
78. Yuzre AA. Pneumoperitoneum needle and trocar injuries in laparoscopy. A survey on possible contributing factors and prevention. *J Reprod Med* 1990; 35:485.
79. Christie JP, Marrazzo J. Miniperforation of the colon not all postpolypectomy perforations require laparotomy. *Dis Colon Rectum* 1991; 34:132.
80. Livingston DH, Bartholomew BJ, Blackwood J, Machiedo GW, Rush BJ. The role of laparoscopy in abdominal trauma. *J Trauma* 1992; 33:471.
81. Schapira M, Dizerens H, Essinger A, Wauters JP, Loup P, von Niederhausen W. Urinary ascites after gynecologic laparoscopy. *Lancet* 1978; i:871–872.
82. Stengel JN, Felderman ES, Zamora D. Ureteral injury: complication of laparoscopic sterilization. *Urology* 1974; 4:341–342.
83. Nezhat C, Nezhat F. Laparoscopic repair of ureter resected during operative laparoscopy. *Obstet Gynecol* 1992; 80:543–544.
84. Gomel V, James C. Intraoperative management of ureteral injury during operative laparoscopy. *Fert Steril* 1991; 55:416–419.
85. Grainger DA, Soderstrom RM, Schiff SF, Glickman MG, DeCherney AH, Diamond MP. Ureteral injuries at laparoscopy: insights into diagnosis, management, and prevention. *Obstet Gynecol* 1990; 75:839–843.
86. Fahlenkamp D, Voge W, Andrehs G. Laparoscopic bladder repair after intraperitoneal bladder rupture. *Min Invas Ther Allied Technol* 1998; 5:467–469.
87. Hsu YS, Chiu AW, Chen KK, Chang LS. Inadvertent puncture of the kidney by a trocar during retroperitoneoscopic ureterolithotomy. *Min Invas Ther Allied Technol* 1998; 3:281–283.
88. Shuford MD, McDougall EM, Chang SS, LaFleur BJ, Smith JA Jr., Cookson MS. Complications of contemporary radical nephrectomy: comparison of open vs. laparoscopic approach. *Urol Oncol* 2004; 22:121–126.
89. Steiner H, Peschel R, Janetschek G, et al. Long-term results of laparoscopic retroperitoneal dissection: a single-center 10-year experience. *Urology* 2004; 63:550–555.
90. Abreu SC, Sharp DS, Ramani AP, et al. Thoracic complications during urologic surgery. *J Urol* 2004; 171:1451–1455.
91. Dumas K, Alivizatos G. Complications of laparoscopic urologic surgery. *Arch Esp Urol* 2002; 55:730–736.
92. Soulie M, Salomon L, Seguin P, et al. Multi-institutional study of complications in 1085 laparoscopic urologic procedures. *Urology* 2001; 58:899–903.
93. Soulie M, Seguin P, Richeux L, et al. Urologic complications of laparoscopic surgery: experience with 350 procedures at a single institution. *J Urol* 2001; 165(6 Pt 1):1960–1963.
94. Kumar M, Kumar R, Hemal AD, Gupta NP. Complications of retroperitoneoscopic surgery at one centre. *BJU* 2001; 87:607–612.
95. Keating J, Hill A, Schroeder D, Whittle D. Laparoscopy in the diagnosis and treatment of acute small bowel obstruction. *J Laparoendosc Surg* 1992; 2:239–244.
96. Ballem RV, Kenny R, Giuliano M. Small bowel obstruction following laser laparoscopic cholecystectomy: a case study. *J Laparoendosc Surg* 1993; 3:313–314.
97. Stelzner F. The abdominal wall and the development of and treatment of hernias. *Langenbecks Arch Chir* 1994; 379:109–119.
98. Plaus WJ. Laparoscopic trocar site hernias. *Laparoendosc Surg* 1993; 3:57–70.
99. Spier LN, Lazzaro RS, Procaccino A, Geiss A. Entrapment of small bowel after laparoscopic herniorrhaphy. *Surg Endosc* 1993; 7:535–536.
100. Bergemann JL, Hibbert ML, Harkins G, Narvaez J, Asatom A. Omental herniation through a 3-mm umbilical trocar site: unmasking a hidden umbilical hernia. *J Laparoendosc Adv Tech* 2001; 11:171–173.
101. Harold KL, Goldstein SL, Nelms CD, et al. Optimal closure method of five-millimeter trocar sites. *Am J Surg* 2004; 187:24–27.
102. Sanz-Lopez S, Martinez-Ramos C, Nunez-Pena JR, deGopegui MR, Pastor-Sirera L, Tamames-Escobar S. Incisional hernias after laparoscopic vs open cholecystectomy. *Surg Endosc* 1999; 13:922–924.
103. Bowrey DJ, Blom D, Crookes PF, et al. Risk factors and the prevalence of trocar site herniation after laparoscopic fundoplication. *Surg Endosc* 2001; 15:663–666.
104. Elashry OM, Nakada SY, Wolf JS Jr., Figenshau RS, McDougall EM, Clayman RV. Comparative clinical study of port-closure techniques following laparoscopic surgery. *J Am Coll Surg* 1996; 183:335–344.
105. Meynaud-Kraemer L, Colin C, Vergnon P, Barth X. Wound infection in open versus laparoscopic appendectomy. A meta-analysis. *Int J Technol Assess Health Care* 1999; 15:380–391.

106. Koch A, Schreiber LD, Mokros W, Rupprecht H, Lippert H. Quality assurance in appendicitis—what has changed? Analysis of 2 prospective multicenter quality assurance studies. *Zentralbl Chir* 2000; 125(suppl 2):185–191.
107. Balague Ponz C, Trias M. Laparoscopic surgery and surgical infection. *J Chemother* 2001; 13:17–22.
108. Winslow ER, Fleshman JW, Birnbaum EH, Brunt LM. Wound complications of laparoscopic vs. open colectomy. *Surg Endosc* 2002; 16:1420–1425.
109. Podnos YD, Jimenez JC, Wilson SE, Stevens CM, Nguyen NT. Complications after laparoscopic gastric bypass: a review of 3464 cases. *Arch Surg* 2003; 138:957–961.
110. Winslow ER, Brunt LM. Perioperative outcomes of laparoscopic versus open splenectomy: a meta-analysis with an emphasis on complications. *Surgery* 2003; 134:647–653.
111. Al-Ghnam R, Benjamin IS, Patel AG. Meta-analysis suggests antibiotic prophylaxis is not warranted in low-risk patients undergoing laparoscopic cholecystectomy. *Br J Surg* 2003; 90:365–366.
112. Anderson AD, McNaught CE, Jain PK, MacFie J. Randomised trial of symbiotic therapy in elective surgical patients. *Gut* 2004; 53:241–245.
113. Koch A, Zippel R, Marusch F, Schmidt U, Gastinger I, Lippert H. Prospective multicenter study of prophylaxis in operative treatment of appendicitis. *Dig Surg* 2000; 17:370–378.
114. Poulin EC, Schlachta CM, Seshadri PA, Cadeddu MO, Gregoire R, Mamazza J. Septic complications of elective laparoscopic colorectal resection. *Surg Endosc* 2001; 15:203–208.
115. Curet MJ. Port site metastases. *Am J Surg* 2004; 187:705–712.
116. Dobronze Z, Wittmann T, Karascony G. Rapid development of malignant metastases in the abdominal wall after laparoscopy. *Endoscopy* 1978; 10:127–130.
117. Zmora O, Gervaz P, Wexner SD. Trocar site recurrence in laparoscopic surgery for colorectal cancer: myth or real concern? *Surg Endosc* 2001; 15:788–793.
118. Tsivian A, Sidi AA. Port site metastases in urologic laparoscopic surgery. *J Urol* 2003; 169:1213–1218.
119. Wu JS, Jones DB, Guo LW, et al. Effects of pneumoperitoneum on tumor implantation with decreasing tumor inoculum. *Dis Colon Rectum* 1998; 41:141–146.
120. Lee SW, Gleason NR, Bessler M, Whelan RL. Peritoneal irrigation with povidone-iodine solution after laparoscopic-assisted splenectomy significantly decreases port-tumor recurrence in a murine model. *Dis Colon Rectum* 1999; 42:319–326.
121. Ott DE. Laparoscopic hypothermia. *J Laparoendosc Surg* 1991; 1:127–131.
122. Buckman FR, Sargent L, Gervin AS. A unifying pathologic mechanism in the etiology of intraperitoneal adhesions. *J Surg Res* 1976; 20:1–5.
123. Menzies D. Postoperative adhesions: their treatment and relevance in clinical practice. *Ann R Coll Surg Engl* 1993; 75:147–153.
124. LeGrand EK, Rodgers KE, Girgis W, et al. Efficacy of tolmentin solution for adhesion prevention in rabbit and rat models. *J Surg Res* 1994; 56:67–71.
125. Pellegrino MJ, Johnson EW. Bilateral obturator nerve injuries during urologic surgery. *Arch Phys Med Rehabil* 1987; 69:46–47.
126. Kandioler-Eckersberger D, Niederle B, Herbst F, Wenzl E. A magnetic probe to retrieve broken metallic parts of instruments during laparoscopic procedures. *Surg Endosc* 2002; 16:208–209.
127. Gaur DD, Rath SS, Ravandale AV, Gopichand M. A single-centre experience of retroperitoneoscopy using the balloon technique. *BJU Int* 2001; 87:602–606.
128. Adams JB II, Micali S, Moore R, Babayan RK, Kavoussi LR. Complications of extraperitoneal balloon dilation. *J Endourol* 1996; 10:375–378.
129. Moore RG, Demaree RD, Sanda MG, Kavoussi LR. Retroperitoneoscopy: effects of insufflation media on surrounding tissue during balloon rupture. *J Endourol* 1995; 9:67–71.
130. Yao CC, Wong HH, Chen CC, Wang CC, Yang CC, Lin CS. Migration of endoclip into duodenum: a rare complication after laparoscopic cholecystectomy. *Surg Endosc* 2001; 15:217.
131. Nottingham JM. Mechanical small bowel obstruction from a loose linear cutter staple after laparoscopic appendectomy. *Surg Laparosc Endosc Percutan Tech* 2002; 12:289–290.
132. Hahnfeld LE, Nakada SY, Moon TD. Identification of microtack in the bladder after laparoscopic pelvic surgery. *Urology* 1999; 54:162.
133. Rubsamen DS. Professional liability newsletter. 1993; 23:1–4.
134. Kern KA. Malpractice litigation involving laparoscopic cholecystectomy. Cost, cause, and consequences. *Arch Surg* 1997; 132:392–398.
135. McDougall EM. Prevention and treatment of complications of laparoscopic surgery. Highlights. *Post Grad Course Urol* 1992:10–12.
136. Keehner MM, Tendick F, Meng MV, et al. Spatial ability, experience, and skill in laparoscopic surgery. *Am J Surg* 2004; 188:71–75.
137. Sir Cushieri A. Minimal access surgery and the future of interventional laparoscopy. *Am J Surg* 1991; 161:404–407.
138. Kavic MS. The US medical liability system—a system in crisis. *JLS* 2004; 8:1–2.
139. Das S. Urologic laparoscopy: the future is now. *Urol Clin North Am* 2001; 28:1–3.
140. US Department of Health and Human Services. Confronting the new health care crisis: improving health care quality and lowering cost by fixing our medical liability system. <http://aspe.hhs.gov/daltcp/home.html>.
141. Burns CR. Legacies in law and medicine. Canton, Massachusetts: Watson Publishing International, 1977:1–17.
142. Donovan JF. Legal issues in laparoscopy. *Contemp Urol* 1992:74–81.
143. Faden RR, Beauchamp TL. A history and theory of informed consent. New York: Oxford University Press, 1986:123–129.

144. The Southern Surgeons Club. A prospective analysis of 1,518 laparoscopic cholecystectomies performed by Southern U.S. surgeons. *N Engl J Med* 1991; 324:1073–1078.
145. Kavoussi LR, Sosa E, Chandhoke P, et al. Complications of laparoscopic pelvic lymph node dissection. *J Urol* 1993; 149:322.
146. U.S. Department of Health and Human Services. Update on the medical litigation crisis: not the result of the “insurance cycle.” <http://aspe.hhs.gov/daltcp/home.html>.
147. Perone N. Conventional versus open laparoscopy. *Am Fam Physician* 1983; 27:147–149.
148. New York Public Health §2805-d. Chapter 109 of the New York Laws, of 1975.
149. Twersky AD, Cohen NB. Comparing medical providers: a first look at the new era of medical statistics. 58 *Brooklyn L Rev* 1992; 5:26–27.
150. Weindling P. The origins of informed consent: the International Scientific Commission on Medical War Crimes, and the Nuremberg Code. *Bull Hist Med* 2001; 75:37–71.
151. Bates T. Ethics of consent to surgical treatment. *Br J Surg* 2001; 88:1283–1284.
152. Bunch WH. Informed consent. *Clin Orthop Rel Res* 2000; 378:71–77.
153. Katz J. Reflections on informed consent: 40 years after its birth. *J Am Coll Surg* 1998; 186:466–474.
154. Moore MJ, Bennet CL. The learning curve for laparoscopic cholecystectomy. The Southern Surgeons Club. *Am J Surg* 1995; 170:55–59.
155. Weinberg JJ, Ansong K, Smith AD. Complications of ureteroscopy in relation to experience: report of survey and author experience. *J Urol* 1987; 137:384–385.
156. Reinhardt UE. Academic medicine’s financial accountability and responsibility. *JAMA* 2000; 284:1136–1138.
157. Halsted WS. The training of the surgeon. *Am Med* July 1904; 9:69–75.
158. Schwartz IS. The evolution of medical education. *Surgery* 1999; 1:17–18.
159. New York State Department of Health. Laparoscopic surgery. Memorandum no. 92-20, 1992.
160. Soper NJ. Society of American Gastrointestinal Endoscopic Surgeons and surgical education. Assuring that history does not repeat itself. *Surg Endosc* 2001; 15:775–780.
161. Society of American Gastrointestinal Endoscopic Surgeons. Granting of privileges for laparoscopic general surgery. *Am J Surg* 1991; 161:324.
162. Spencer FC. Deductive reasoning in the lifelong continuing education of a cardiovascular surgeon. *Arch Surg* 1976; 111:1177–1183.
163. Brasel KJ, Bragg D, Simpson DE, Weigelt JA. Meeting the Accreditation Council for Graduate Medical Education competencies using established residency training program assessment tools. *Am J Surg* 2004; 188:9–12.
164. Leach DC. The ACGME competencies: substance or form? *J Am Coll Surg* 2001; 192:396–398.
165. Osler W. On the need of radical reform in our methods of teaching senior students. *Med News* 1903; 82:49–53.
166. Kohn LT, Corrigan JM, Donaldson MS, eds. *To Err is Human: Building a Safer Health System*. Washington, D.C.: National Academy Press, 1999.
167. Trunkey DD, Botney R. Assessing competency: a tale of two professions. *J Am Coll Surg* 2001; 192:385–395.
168. Carroll PR. Laparoscopic urologic surgery: differentiating what should be done from what can be done [editorial]. *J Urol* 1994; 151:1603–1604.
169. Wickham JEA. From butcher to bioengineer. *J Urol* 1991; 145:159A.
170. Margolis LH. The ethics of accepting gifts from pharmaceutical companies. *Pediatrics* 1991; 88:1233.
171. Velanovich V. Laparoscopic vs. open surgery. A preliminary comparison of quality-of-life outcomes. *Surg Endosc* 2000; 14:16–21.
172. Hunter JG. Clinical trials and the development of laparoscopic surgery. *Surg Endosc* 2001; 15:1–3.
173. Bergamaschi R. Farewell to see one, do one, teach one? *Surg Endosc* 2001; 15:637.
174. Meijer DW. Safety and quality assurance of endoscopic surgery [editorial]. *Surg Endosc* 2001; 11:147.
175. Livingston EH, Harwell JD. The medicolegal aspects of proctoring. *Am J Surg* 2002; 184:26–30.
176. Chenen AR. Proctoring can be a legal quagmire. *Mod Healthcare* 1984; 15:190–193.
177. Mosteller F. Innovation and evaluation. *Science* 1981; 211:881–886.

THE FUTURE

J. Daniell Rackley and Anthony Atala

*Department of Urology, Wake Forest University Baptist Medical Center,
Winston-Salem, North Carolina, U.S.A.*

- INTRODUCTION
- BASIC PRINCIPLES OF TISSUE ENGINEERING
- BIOMATERIALS FOR GENITOURINARY TISSUE ENGINEERING

- Bladder
- Kidney—Therapeutic Cloning and Stem Cells
- SUMMARY
- REFERENCES

INTRODUCTION

The entire genitourinary system is subject to a variety of possible insults from the beginning of development through adult life. Tissue loss may result from acquired disease as well as congenital disorders—infection, trauma, malignancy, iatrogenic injury, obstruction, and other disease processes. Also, many children are born with conditions that render their urinary tract organs suboptimal or nonfunctional, such as spina bifida or renal parenchyma loss from posterior urethral valves. In the past, damaged organs have been replaced with autologous and allogenic tissues. While both of these solutions have enabled patients to lead more normal lives, both are fraught with potential complications inherent in the donated tissue. For example, urinary diversion with intestine may have sequential electrolyte abnormalities, and renal transplantation may lead to multiple complications associated with immunosuppression. The field of regenerative medicine stems from the desire to create replacement tissues, for patients whose own tissues are deficient, with functionally and physiologically equivalent tissues that are not subject to rejection by the body's immune system.

Tissue engineering applies the concepts of cell transplantation, materials science, and engineering in an effort to develop biological substitutes that can restore and maintain normal function. As this technology improves and these concepts become more and more clinically applicable, minimally invasive methods of tissue harvest and transfer will be sought. Laparoscopy, no doubt, will be at the forefront, as tissue engineering makes its way into clinical practice.

BASIC PRINCIPLES OF TISSUE ENGINEERING

The source of donor tissue can be heterologous, allogenic, or autologous; autologous is preferred as this method avoids tissue rejection by the immune system and immunosuppressive drugs can be avoided. When autologous cells are used, a biopsy is obtained from the host and the cells are dissociated and expanded, and later returned to the same host as new tissue that is not immunogenic.

Tissue engineering “entails” the use of donor tissue that is dissociated into individual cells. The cells are either implanted directly into the host, or expanded in culture, attached to a biodegradable support matrix, and reimplanted after expansion (1–3).

In its early phases, cell-based tissue engineering was limited by the inability to grow specific cell types in sufficient quantities for implantation. Many cell types, including urothelium, seemed to have a natural senescence that prevented their expansion in vitro. However, several protocols have been developed over the past two decades that have improved urothelial growth and expansion in the laboratory (4,5). Improved understanding of the privileged sites for precursor cells in specific organs and the conditions that promote differentiation has led to techniques that have overcome the difficulties of in vitro cell expansion. Cilento et al. demonstrated that

Tissue engineering “entails” the use of donor tissue that is dissociated into individual cells. The cells are either implanted directly into the host, or expanded in culture, attached to a biodegradable support matrix, and reimplanted after expansion.

Reported studies demonstrated that it would be possible to harvest autologous bladder cells from human patients, grow and expand them in vitro, attach them to a support matrix, and use them in the same patient for reconstructive purposes.

Biomaterials should provide a three-dimensional space for cells to form into new tissues; they should allow for delivery of the desired cells for tissue replacement and appropriate bioactive factors (cell adhesion peptides, growth factors) to desired sites in the body, and guide the development of new tissues with appropriate function.

The ideal biomaterial should also be biocompatible. The biomaterial should persist for an appropriate amount of time to allow for adequate replacement of normal tissue, but it should be absorbed by the host without inflammation.

Three basic classes of biomaterials have been utilized in the engineering of genitourinary organs: naturally-derived materials (e.g., collagen and alginate), acellular tissue matrices (e.g., bladder submucosa and small intestinal submucosa), and synthetic polymers [e.g., polyglycolic acid, polylactic acid, and poly(lactic-co-glycolic acid)].

a urothelial strain from a single specimen, initially covering a surface area of 1 cm², could be expanded to cover an area of 4202 m² (the equivalent area of one football field) in eight weeks.

Reported studies demonstrated that it would be possible to harvest autologous bladder cells from human patients, grow and expand them in vitro, attach them to a support matrix, and use them in the same patient for reconstructive purposes.

Bladder, ureter, and renal pelvis cells can equally be harvested, cultured, and expanded in a similar fashion. The next step is clinical application of these techniques in humans, and major advances have been achieved in the past decade, which will make the use of autologous cells in patients for expansion a possibility.

BIOMATERIALS FOR GENITOURINARY TISSUE ENGINEERING

Biomaterials should provide a three-dimensional space for cells to form into new tissues; they should allow for delivery of the desired cells for tissue replacement and appropriate bioactive factors (cell adhesion peptides, growth factors) to desired sites in the body, and guide the development of new tissues with appropriate function (6).

In tissue engineering, a scaffold that allows cell adherence and regeneration is essential. The materials that are used as scaffolding should replicate the biologic and mechanical function of the native extracellular matrix.

The majority of mammalian cell types are anchorage-dependent and must have a cell-adhesion substrate for survival; biomaterials provide a cell-adhesion substrate that can deliver cells to specific sites in the body with high loading efficiency. The scaffolding also provides mechanical support against in vivo forces, thereby maintaining the integrity of the predefined structure until the cells have matured into the desired three-dimensional structure.

A foreign body response should be avoided as it leads to rejection and/or necrosis and ultimately failure of the graft. As the scaffolding is metabolized by the host, its degradation products should be nontoxic, nonimmunogenic, and removed from the host at the appropriate rate such that the concentrations of these products remain at a tolerable level. Furthermore, the biomaterial should provide an environment in which cell behavior is not altered. Cell adhesion, proliferation, migration, and differentiation should promote functional tissue formation.

The ideal biomaterial should also be biocompatible. The biomaterial should persist for an appropriate amount of time to allow for adequate replacement of normal tissue, but it should be absorbed by the host without inflammation.

The naturally derived materials have the potential advantage of cellular recognition and biologic response. However, synthetic polymers can be reproduced on a large scale with controlled properties of strength, degradation rate, and microstructure.

Collagen, the most abundant structural protein in the body, is readily purified from both animal and human tissues with an enzyme treatment and salt/acid extraction. Collagen generates minimal inflammatory response, and it has been approved by the U.S. Food and Drug Administration for many types of medical applications, including wound dressings and artificial skin. Collagen implantation is limited by its relatively rapid degradation from sequential attacks by lysosomal enzymes. Acellular tissue matrices are collagen-rich matrices prepared by mechanical and/or chemical removal of the cellular components from tissues leaving only the supportive scaffolding behind. This artificial extracellular membrane slowly degrades after implantation and is replaced by true extracellular matrix proteins synthesized and secreted by transplanted or ingrowing cells.

Three basic classes of biomaterials have been utilized in the engineering of genitourinary organs: naturally-derived materials (e.g., collagen and alginate), acellular tissue matrices (e.g., bladder submucosa and small intestinal submucosa), and synthetic polymers [e.g., polyglycolic acid, polylactic acid, and poly(lactic-co-glycolic acid)].

Alginate, a polysaccharide isolated from seaweed, has been used as an injectable cell delivery vehicle and a cell immobilization matrix owing to its gentle gelling properties in the presence of divalent ions such as calcium. Alginate is limited by its lack of a biologic recognition domain and limited range of mechanical properties.

Polyesters of naturally occurring alpha-hydroxy acids, including polyglycolic acid, polylactic acid, and polylactic glycolic acid, are used widely in tissue engineering. The Food and Drug Administration has approved the use of these polymers for a multitude of clinical applications including sutures. These polymers contain ester bonds, which are hydrolytically labile, allowing their degradation by nonenzymatic hydrolysis. Their degradation byproducts are nontoxic—natural metabolites that are eliminated from the

host in the form of water and carbon dioxide. These materials can be constructed such that they degrade in several weeks to several years by altering the crystallinity, initial molecular weight, and the copolymer ratio of lactic to glycolic acid. Also, these polymers are thermoplasts, which allows them to be formed into the appropriate three dimensional scaffolds with a desired microstructure, gross shape, and dimension by various techniques, including molding, extrusion, solvent casting, phase separation techniques, and gas foaming techniques. These techniques can be used to process biomaterials into porous sponges and fiber meshes, which have high porosity and a high surface area-to-volume ratio; these properties enhance the effectiveness of the scaffold. Other biodegradable synthetic polymers including poly(anhydrides) and poly(ortho-esters) also can be used to fabricate scaffolds for genitourinary tissue engineering with controlled properties.

Bladder

Neobladders and bladder augmentations are being performed with increasing frequency. Obviously, there is an enormous need for bladder replacement tissue. The gastrointestinal segments that are currently used lack the physiologic and mechanical properties of urothelium. While gastrointestinal tissues are designed to absorb specific solutes, the urothelium is designed for urine storage, not the transfer of electrolytes. Despite the acceptable functional results of enterocystoplasty and orthotopic neobladder, numerous complications can arise from the combination of intestine (with its associated heterotopic epithelium) and the urinary tract (7). Metabolic, infectious, and calculus complications, as well as the morbidity associated with enteric surgery have driven numerous investigators to explore the use of alternative materials and tissues for bladder replacement or repair.

The success of using cell transplantation strategies for bladder reconstruction depends on the ability to use donor tissue efficiently and to provide the right conditions for long-term survival, differentiation, and growth.

Numerous nonenteric biological and synthetic materials have been used for bladder augmentation and bladder replacement in animal models. A variety of complications have occurred with the use of synthetic materials that have limited its widespread use (8). Tissue engineering with selective cell transplantation is a feasible strategy to create new, functional bladder tissue (9).

Using cellular tissue engineering, composite bladder tissue of urothelium and muscle cells can be expanded *in vitro* and seeded onto a polymer scaffold, generating sheets of cells (4). Other early experiments demonstrated that the engineered bladder tissue implanted into mice formed composite tissue with layers of muscle cells lining multilayered epithelial sheets.

To test the effects of implanting engineered bladder tissue in continuity with the urinary tract, an animal model was used. Subtotal cystectomies were performed in dogs (1,10). Urothelial and muscle cells were separately expanded from an autologous bladder biopsy. A collagen-based matrix derived from allogenic bladder submucosa served as the vehicle for cell delivery.

The augmented bladders demonstrated cellular organization consisting of a trilayer of urothelium, submucosa, and muscle.

Radiographic and urodynamic studies revealed compliant, large-capacity bladders. An average bladder capacity of 95% of the precystectomy volume was achieved in the tissue-engineered bladder specimens (Fig. 1).

Laparoscopic bladder augmentation is being done in humans (11); however, laparoscopic bladder augmentation with engineered tissue has only recently been described in animal models.

The success of using cell transplantation strategies for bladder reconstruction depends on the ability to use donor tissue efficiently and to provide the right conditions for long-term survival, differentiation, and growth.

The augmented bladders demonstrated cellular organization consisting of a trilayer of urothelium, submucosa, and muscle.

Laparoscopic bladder augmentation is being done in humans; however, laparoscopic bladder augmentation with engineered tissue has only recently been described in animal models.



FIGURE 1 ■ (A) The native canine bladder prior to trigone-sparing cystectomy. (B) The engineered neo-organ is anastomosed to the trigone. (C) The implant, decompressed by a transurethral and suprapubic catheter, is wrapped with omentum.

Nonetheless, this animal study demonstrated that laparoscopic bladder augmentation with engineered tissue is technically feasible, and can be performed safely in a large animal model.

Clayman and coworkers developed a laparoscopic technique for augmentation cystoplasty with engineered tissues in minipigs (12). The animals underwent successful laparoscopic partial cystectomy and closure with patch augmentation utilizing various free grafts (acellular) materials. Cell-seeded graft materials were not used in this study. Laparoscopic partial cystectomy was first performed through a transperitoneal approach. The excised bladder specimen was measured and a biodegradable patch twice that size was used. Four Vicryl corner sutures were placed to assist with intra-abdominal orientation and fixation to the bladder wall. The patch was placed into the abdomen through one of the 12 mm ports and oriented to the bladder wall by aligning the four preplaced sutures with the corners of the bladder defect. The corners were secured with an absorbable Lapra-Ty clip, and the anastomosis was completed with an EndoStitch with 4-0 Vicryl sutures. The bladder was drained with a urethral catheter for one week. Mean operative time was three hours, and blood loss was minimal in all cases. Two of 31 pigs had post-op complications—one control animal had an anastomotic leak, and one animal with a human placental membrane patch developed a leak in the patch. The majority of the augmented bladders contracted over time, because the scaffolds were acellular, and not seeded with cells.

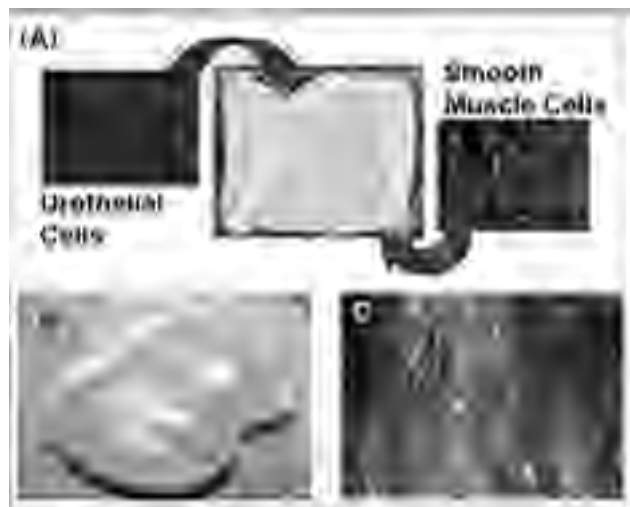
Nonetheless, this animal study demonstrated that laparoscopic bladder augmentation with engineered tissue is technically feasible, and can be performed safely in a large animal model.

Recently, Clayman and coworkers in collaboration with our research team, have performed total bladder replacement with allogenic bladder submucosa coated with urothelial and detrusor cells (13). Five minipigs underwent neobladder creation with acellular bladder submucosa, while 10 minipigs underwent bladder replacement with bladder submucosa coated cells. All surgeries were performed with laparoscopy. All animals were evaluated with urodynamics, radiological studies, and serum chemistry pre- and postoperatively.

The bladder submucosa coated cells was prepared from hemicystectomy specimens obtained from the test animals laparoscopically. Urothelial and muscle cells were cultured using previously described techniques, and expanded separately. The urothelial cells were seeded on the luminal surface of the acellular bladder submucosa, and muscle cells were seeded on the opposite side. The grafts were then fashioned into a neobladder and implanted into the animals after a total cystectomy.

Three technical points should be noted about the laparoscopic neobladder, as this technique has not been previously described. First, the neobladder itself was created by fashioning the bladder submucosa coated cells composite into a 50 cc sphere over an inflated catheter balloon extracorporeally (Fig. 2). The neobladder was closed with running 4-0 Vicryl in a horizontal mattress. Second, the urethral anastomosis was completed by aligning the bladder submucosa coated cells with the urethral stump. This was facilitated by preplacing stay sutures in the bladder submucosa coated cells neobladder at 6 and 12 o'clock position. The remainder of the anastomosis was closed with interrupted sutures. Also, two methods of ureteral implantation were described. Six pigs received end-to-side anastomoses to the dome of the bladder submucosa coated cells with

FIGURE 2 ■ Tissue-engineered neobladder. (A) Tri-layer grafts of host urothelial and detrusor cells seeded onto bladder submucosa. (B) Acellular collagen matrix (after cell seeding). (C) Electron microscopy of cellular collagen matrix (after cell seeding).



placement of a JJ (double-J) ureteral stent. Four pigs had the ureteral anastomoses performed using the “dunk” technique. Two small openings were created at the dome of the bladder submucosa coated cells prior to its placement into the abdomen. One of the mobilized ureters was placed through one of the openings and out of the other. The medial surface of the ureter that entered and exited the neobladder was sewn to the medial surface of the contralateral ureter and then gently pulled until both ureteral orifices were inside the bladder submucosa coated cells graft. Each ureter was fixed to the exterior of the neobladder with sutures. This technique precluded the use of stents. Any leaks in the neobladder after closure were closed with 4-0 Vicryl. Omentum was mobilized to cover the neobladder in six pigs. All procedures were successfully completed laparoscopically.

Over time, bladder capacity decreased in both the bladder submucosa coated cells and acellular bladder submucosa groups, but more severely in the acellular bladder submucosa bladders. The mean survival for acellular bladder submucosa and bladder submucosa coated cells bladders was 52 and 65 days, respectively. One animal in the bladder submucosa coated cells group died on postoperative day 2 secondary to leakage at the bladder dome and urinary ascites. The remaining deaths were due to progressive uremia requiring euthanasia. Small contracted bladders with bilateral hydroureteronephrosis were noted on autopsy studies. The urethral anastomoses were narrowed but patent in both bladder types. There were no appreciable differences with regard to ureteral implantation in the end to side or dunk technique. Cystoscopic examination of the bladder submucosa coated cells grafts appeared endoscopically similar to normal bladder with gross appearance of submucosal and surface vessels. All reimplants were patent but somewhat narrowed; each demonstrated reflux on cystograms performed before animal sacrifice.

The creation of a neobladder using engineered bladder tissue and laparoscopic techniques is technically possible.

While more advancements in technology are needed before this approach is clinically applicable in humans, this attempt may represent the future of tissue engineering and laparoscopy.

The creation of a neobladder using engineered bladder tissue and laparoscopic techniques is technically possible.

Kidney—Therapeutic Cloning and Stem Cells

Approximately 70,000 people in the United States are on a transplant wait list due to renal disease. The two currently available options for such patients are dialysis and renal transplantation. Both options are life-sustaining, but both are associated with significant morbidity and mortality. Dialysis is often poorly tolerated, and transplantation is burdened with severe donor shortages as well as the complications that accompany immunosuppression. This has motivated researchers to develop alternative solutions for end-stage renal disease. Previous methods of tissue engineering of renal tissue involved extracorporeal systems comprising biologic and synthetic components. Somatic cell nuclear transfer theoretically can reduce or eliminate the immune response of allogenic grafts.

Genetically identical renal tissue has been produced applying the principles of tissue engineering and therapeutic cloning in a large animal model, the cow (*Bos Taurus*) (14).

Stem cells were created by isolating and microinjecting single bovine skin fibroblast donor cells into the perivitelline space of donor enucleated oocytes (nuclear transfer). Renal cells were isolated from a cloned metanephros and expanded until the desired number of cells was obtained. The renal cells were then seeded onto scaffolds consisting of three collagen-coated cylindrical polycarbonate membranes. Renal devices were constructed by connecting catheters to the ends of three membranes. The catheters functioned as a collecting system that drained into a reservoir, thereby creating a renal neo-organ with a mechanism for collecting excreted fluid. The devices were then subcutaneously implanted back into the same steer from which the genetic material was derived. The renal devices were explanted after 12 weeks and studied.

On gross inspection, the renal units appeared intact, and yellow, urine-like fluid was seen in the reservoirs. Chemical analysis of this fluid suggested unidirectional secretion of urea nitrogen and creatinine, as well as filtration and reabsorption of glucose and other electrolytes (Fig. 3). Histological examination of the retrieved implants demonstrated extensive vascularization of the renal units, and self-assembly into glomeruli and tube-like structures. A continuum between the glomeruli, tubules, and polycarbonate membrane was observed that allowed passage of urine into the collecting system reservoir. Renal specific proteins were detected in the renal units with immunohistochemical analysis and Western blot analysis. Reverse transcription-polymerase chain reaction analysis confirmed the transcription of renal-specific ribose nucleic acid in the cloned specimens. The cloned renal cells also produced both erythropoietin and 1, 25-dihydroxyvitamin D₃, important endocrine metabolites produced by a normal kidney.

Genetically identical renal tissue has been produced applying the principles of tissue engineering and therapeutic cloning in a large animal model, the cow (*Bos Taurus*).

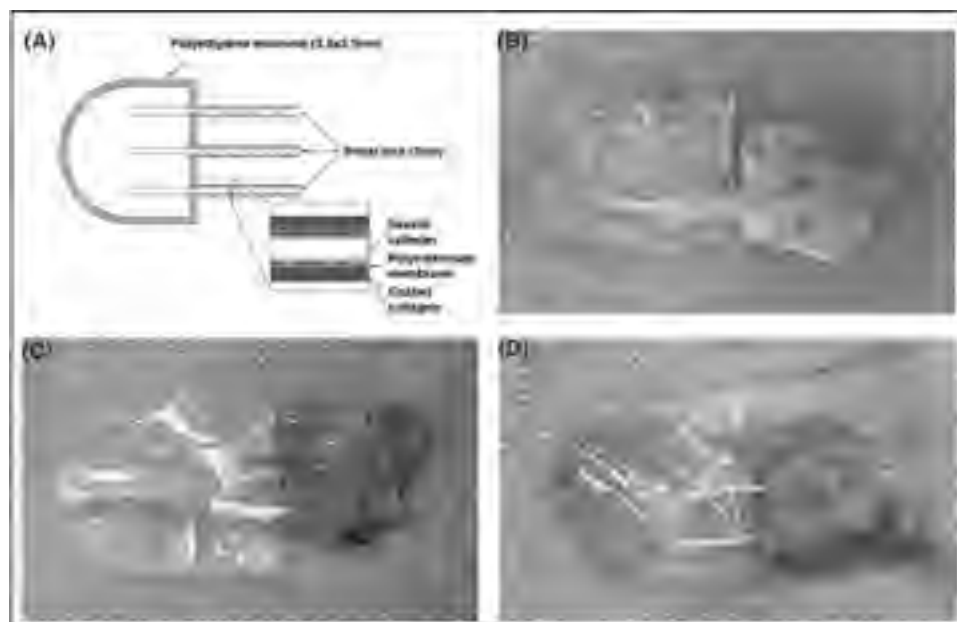


FIGURE 3 ■ (A) Illustration of renal unit and units retrieved three months after implantation. (B) Unseeded control. (C) Seeded with allogeneic control cells. (D) Seeded with cloned cells, showing the accumulation of urine-like fluid.

The goal of therapeutic cloning, as described above, is to produce tissues that are genetically identical to those of the donor. Other researchers have demonstrated that animals produced by somatic cell nuclear transfer inherit their mitochondria entirely or in part from the recipient oocyte and not from the donor cell (14). Theoretically, these foreign mitochondrial proteins derived from the oocyte could produce an immune response from the donor after transplantation. We investigated the possibility of an immune response to the cloned renal units described above with delayed-type hypersensitivity testing in vivo and Elispot analysis of interferon-gamma-secreting T-cells in vitro. Neither test demonstrated an immune response to the cloned renal tissue, suggesting that rejection will not necessarily occur in the presence of oocyte-derived mitochondrial deoxyribonucleic acid. This finding offers the possibility that renal tissue can be derived via nuclear transfer and that these tissue may be implanted in a host without the histocompatibility issues that plague other forms of allotransplantation.

SUMMARY

- Both tissue engineering and laparoscopy sit at the forefront of the technological advancements that are being achieved in urologic surgery.
- Remarkable achievements in laparoscopy over the past two decades have dramatically reduced the morbidity associated with many procedures.
- Regenerative medicine offers the hope that patients with organ loss can receive tissues that are functionally and genetically identical to those that were lost.
- Tissue engineering efforts are currently underway for virtually every organ and tissue type within the urinary tract.
- As these two technologies mature, it may become only a matter of time until their paths cross in a way that will advance the field of organ and tissue replacement.

REFERENCES

1. Yoo JJ, Meng J, Oberpenning F, Atala A. Bladder augmentation using allogenic bladder submucosa seeded with cells. *Urology* 1998; 51:221.
2. Yoo JJ, Park HJ, Lee I, Atala A. Autologous engineered cartilage rods for penile reconstruction. *J Urol* 1999; 162:1119.
3. Atala A, Vacanti JP, Peters CA, Mandell J, Retik AB, Freeman MR. Formation of urothelial structures in vivo from dissociated cells attached to biodegradable polymer scaffolds in vitro. *J Urol* 1992; 148:658.
4. Cilento BG, Freeman MR, Schneck FX, Retik AB, Atala A. Phenotypic and cytogenetic characterization of human bladder urothelia expanded in vitro. *J Urol* 1994; 152:665.

5. Liebert M. Basic science research on the urinary bladder and interstitial cystitis: new genetic approaches. *Urology* 2001; 57:7.
6. Kim BS, Mooney DJ. Development of biocompatible synthetic extracellular matrices for tissue engineering. *Trends Biotechnol* 1998; 16:224.
7. McDougal WS. Metabolic complications of urinary intestinal diversion. *J Urol* 1992; 147:1199.
8. Elbahnasy AM, Shalhav A, Hoenig DM, Figenshau R, Clayman RV. Bladder wall substitution with synthetic and non-intestinal organic materials. *J Urol* 1998; 159:628.
9. Atala A. Autologous cell transplantation for urologic reconstruction. *J Urol* 1998; 159:2.
10. Oberpenning F, Meng J, Yoo JJ, Atala A. De novo reconstitution of a functional mammalian urinary bladder by tissue engineering. *Nat Biotechnol* 1999; 17:149.
11. Gill IS, Rackley RR, Meraney AM, Marcello PW, Sung GT. Laparoscopic enterocystoplasty. *Urology* 2000; 55:178.
12. Portis AJ, Elbahnasy AM, Shalhav AL, et al. Laparoscopic augmentation cystoplasty with different biodegradable grafts in an animal model. *J Urol* 2000; 164:1405.
13. Rehman J, Lee DI, Landman J, et al. Laparoscopic porcine total bladder reconstruction using allogenic bladder submucosa coated with cells (bladder submucosa coated cells): anatomical urodynamic, and histopathological outcome. *J Urol* 2002; 167:60.
14. Lanza RP, Chung HY, Yoo JJ, et al. Generation of histocompatible tissues using nuclear transplantation. *Nat Biotechnol* 2002; 20:689.

Bijan Shekarriz

*Department of Urology, SUNY, Upstate Medical University,
Syracuse, New York, U.S.A.*

- INTRODUCTION
- PRINCIPLES OF DISSECTION
- EXPERIMENTAL DATA IN UROLOGY
 - Laparoscopic Nephrectomy
 - Laparoscopic Partial Nephrectomy
 - Laparoscopic Retroperitoneal Lymphadenectomy

- CLINICAL APPLICATIONS IN UROLOGY
- FUTURE PERSPECTIVES
- SUMMARY
- REFERENCES

INTRODUCTION

The principle of hydrodissection is the use of a stream of water to expand and delineate surgical planes. Hydrodissection was originally described for gynecologic pelvic procedures (1–3), and performed using a suction–irrigation probe (5-mm diameter) by injecting normal saline at 300 mmHg into the subperitoneal space to enter the space of Retzius (2). Hydrodissection was also used to develop tissue planes in the avascular pelvic area during laparoscopic hysterectomy (3). The pressures used were in the range of 200 to 800 mmHg (1). Another indication for hydrodissection was laparoscopic cholecystectomy by injecting 50 mL of saline with a cyst aspiration needle between liver and gallbladder (4). This technique resulted in less bleeding, fewer incidence of gallbladder perforation, and faster dissection.

Although similar in principle, hydro-jet technology utilizes an extremely thin high-pressure stream of saline (5). It has been routinely used in industry as a “cutting tool” for different materials such as metal, ceramic, wood, and glass (6). In the surgical field, hydro-jet has been used for both blunt dissection and cutting. Saline is the currently used fluid for surgical dissection. The application of saline between tissue layers creates surgical planes. Moreover, the high-pressure stream of saline can be used as a sharp knife to cut parenchymal organs depending on the tissue density and the pressure utilized (5). The application of parameters, such as water pressure, probe characteristics (diameter and configuration), and a specific hydro-jet temperature, has made selective dissection and cutting of tissues of various consistencies and elasticities feasible. Papachristou and Barters first used hydro-jet technology for liver resections in dogs (7). Vessels and bile ducts were preserved. Later, hydro-jet technology was used for selective dissection of liver parenchyma during hepatic resection in human. Hydro-jet dissection resulted in decrease blood loss compared to conventional tissue fracture technique during hepatic resection (8). Experimental and clinical laparoscopic hepatic resection using this technology was later reported (9,10). Further experience demonstrated the feasibility of this technology for resection of a wide range of parenchymal organs such as brain, kidney, and lungs (11–14). Clinical experience for dissection of brain parenchyma using hydro-jet has been recently reported (11). Using a maximum pressure of 7 bar, small vessels could be preserved. In a porcine model and recently in human, this technology was applied for laparoscopic cholecystectomy using the newer generation device, HelixTM Hydro-Jet (Fig. 1) (15,16). In a prospective clinical study, 80 patients were randomized to undergo laparoscopic cholecystectomy using standard ($n = 40$) or hydro-jet–assisted ($n = 40$) dissection techniques.

The rate of intraoperative complications including hemorrhage and injury to the adjacent organs was less using hydro-jet dissection compared to standard laparoscopic cholecystectomy. Hydro-jet resulted in a selective dissection of connective tissue preserving blood vessels and the cystic duct.

The rate of intraoperative complications including hemorrhage and injury to the adjacent organs was less using Hydro-Jet dissection compared to standard laparoscopic cholecystectomy. Hydro-jet resulted in a selective dissection of connective tissue preserving blood vessels and the cystic duct.

^aErbe U.S.A., Inc., Marietta, GA.



FIGURE 1 ■ Helix™ Hydro-Jet generator. A digital monitor displays the actual pressure during dissection.



FIGURE 2 ■ The angled tip dissection probe of the Helix™ Hydro-Jet device. Continuously monitored and adjustable high-pressure saline is directed through the 120- μ m nozzle at the tip, which can also be used for blunt dissection.

After the introduction of newer generation devices and improved dissection probes, hydro-jet was introduced into the field of laparoscopic urologic surgery.

Hydro-jet technology facilitates isolation of the cystic artery and duct as well as dissection of the gallbladder so that subsequent coagulation of liver bed was often not necessary.

In the urologic surgery, hydro-jet technology was initially used for experimental applications during open surgical procedures, such as partial nephrectomy using older generation devices (12).

After the introduction of newer generation devices and improved dissection probes, hydro-jet was introduced into the field of laparoscopic urologic surgery.

A major advancement for laparoscopic application was the introduction of an angled tip probe that allowed simultaneous saline application and blunt dissection with the probe (Fig. 2) (5).

PRINCIPLES OF DISSECTION

Figure 3 demonstrates the principle of retroperitoneal dissection using hydro-jet technique. Similar principles apply to resection of renal parenchyma.

Retroperitoneal Dissection Using Hydro-Jet Technique

- Saline application results in expansion of the retroperitoneal space and creation of surgical planes (Fig. 3A and B).
- The thin stream of high-pressure saline allows selective separation of surrounding connective tissue components from the vessels and nerves.
- Utilizing a specific range, saline displaces fibrous and collagenous tissue leaving the vessels and nerves intact without injury due to tissue selectivity (Fig. 3C).
- Combined hydro-jet dissection and blunt dissection with the angled tip dissector allow dissection of vital structures such as nerves and vessels (Fig. 3D).
- The flow of saline allows a clear view for the operator.

During partial nephrectomy, the tissue selectivity allows precise cutting through the parenchyma with preservation of vessels and collecting system. These structures can then be selectively coagulated or ligated.

A theoretical question raised is the issue of dissemination of cancer cells while performing hydro-jet dissection for malignant disease. However, the application of saline is performed in the same surgical field as for conventional dissection and away from the pathology to be removed. Therefore, it is unlikely that saline application will result in cancer dissemination. At present, there are no reports of dissemination of cancer cells after various clinical applications.




FIGURE 3 ■ Schematic of the effects of the water jet using the Helix™ Hydro-Jet. (A) Retroperitoneal space prior to application of hydro-jet. (B) Application of saline to the retroperitoneal tissue in a linear fashion results in expansion of retroperitoneal soft tissue. (C) The vessels and nerves are preserved due to tissue selectivity. (D) Using sharp dissection with hydro-jet and blunt dissection with the angled tip probe, the nerve structures and blood vessels are identified, freed and isolated.

EXPERIMENTAL DATA IN UROLOGY

Laparoscopic Nephrectomy

Initially, hydro-jet was employed to perform laparoscopic nephrectomy (5). In an experimental model, 14 pigs underwent unilateral laparoscopic nephrectomy using the hydro-jet and a conventional laparoscopic nephrectomy contralaterally. A Muritz 1000^b hydro-jet generator was utilized. An adjustable water pressure gauge allowed manual control up to a maximum pressure of 30 bar and coagulation was applied via a bipolar probe. The angled end of the probe allowed both blunt dissections with concomitant high-pressure saline application. Results were compared with regard to ease of anatomic dissection, complications, and operative time between the two techniques. Overall, laparoscopic nephrectomy was successful in all animals. No vascular injury secondary to dissection or significant intraoperative hemorrhage was noted. The minor bleeding was of a diffuse nature secondary to blunt dissection. The estimated blood loss was minimal (<50 mL) in both groups. The mean dissection time was 27 (range: 16–34) and 40 (range: 25–65) minutes for hydro-jet–assisted and conventional technique, respectively ($p < 0.001$). The mean normal saline used during hydro-jet dissection was 195 mL (range, 150–250 mL). No further experimental or clinical studies are currently available using this technology for dissection during laparoscopic nephrectomy.

Laparoscopic Partial Nephrectomy

With the application of laparoscopic techniques for partial nephrectomy, several technical aspects needed to be addressed. The primary technical problems arise mainly from dissection of the renal parenchyma, transection of intrarenal vessels and control of parenchymal bleeding, and closure of collecting system. Inability to complete the dissection safely and hemorrhage were the main reasons for conversion to an open surgical approach. To improve dissection, we conducted an experimental study to evaluate the feasibility of this technique for laparoscopic partial nephrectomy (13). In this pilot study, 10 partial nephrectomies were performed in five pigs using a Muritz 1000 hydro-jet generator. A maximum pressure of 30

^bEuromed Medizintechnik, Schwerin, Germany.

The tissue selectivity of Hydro-Jet allowed precise cutting through the renal parenchyma in a virtually bloodless field. The remaining vessels were then coagulated under direct vision. Similarly, renal collecting system was preserved by Hydro-Jet and selectively transected allowing proper closure of the collecting system. Although excellent results were obtained using this technique, the need for hilar occlusion has been debated.

In summary, current experimental data support that temporary hilar control is advantageous for better visualization during laparoscopic partial nephrectomy. Other factors, such as extent and location of parenchymal segments to be resected and tissue vascularity are, however, important variables, which cannot be addressed precisely by experimental protocols. Only a well-performed clinical study can address these issues.

bar was utilized for cutting of the parenchyma. Temporary hilar control was obtained during this study. Coagulation was applied using a bipolar probe. Laparoscopic partial nephrectomy was successful in all animals with no need for conversion to open surgery. No surgical complications including vascular injuries secondary to dissection occurred. There was no significant intraoperative bleeding. The mean dissection time was 45 ± 9 minutes and the mean warm ischemia time was 17 ± 3 minutes. The average amount of normal saline used during each procedure was 195 mL (range, 250–350 mL). Histological evaluation of renal parenchyma did not reveal any acute changes such as necrosis attributable to hydro-jet use. A clear view of the operative field was maintained at all times.

The tissue selectivity of hydro-jet allowed precise cutting through the renal parenchyma in a virtually bloodless field. The remaining vessels were then coagulated under direct vision. Similarly, renal collecting system was preserved by hydro-jet and selectively transected allowing proper closure of the collecting system. Although excellent results were obtained using this technique, the need for hilar occlusion has been debated.

In a recent experimental study utilizing the Helix Hydro-Jet device, no hilar control was obtained. Using lower pressures (16–22 bar), laparoscopic partial nephrectomies were successful (17). It appears that using various pressures, partial nephrectomies can be performed with or without temporary hilar control with respective advantages and disadvantages (18). To address the issue of hilar control and optimal pressure for partial nephrectomy, we performed further experiments in an ex vivo and in vivo porcine model using the Helix Hydro-Jet (18,19). In the ex vivo model, a continuous saline perfusion of renal artery was performed (Fig. 4). A pressure range of 180 to 360 psi (14–25 bar) was utilized. In this model, our results indicated that overall in unperfused kidney, lower pressures were as effective. Optimal pressure in perfused kidney appeared to be 305 psi (21 bar) (Fig. 5). In vivo model, a pressure range of 225 to 290 psi (16–20 bar) with vascular control and a pressure range of 225 to 360 psi (16–25 bar) without vascular control appeared to be optimal for laparoscopic partial nephrectomy. Furthermore, our results indicated that resection of renal parenchyma without hilar control was associated with small vessel hemorrhage from cortical tissue, which may obscure the operating field although larger vessels are preserved. Visualization was improved with vascular control. The combination of Hydro-Jet cutting with bipolar cautery for control of isolated blood vessels was ideal.

In summary, current experimental data support that temporary hilar control is advantageous for better visualization during laparoscopic partial nephrectomy. Other factors, such as extent and location of parenchymal segments to be resected and tissue vascularity are however important variables, which cannot be addressed precisely by experimental protocols. Only a well-performed clinical study can address these issues.

Laparoscopic Retroperitoneal Lymphadenectomy

To explore other indications for hydro-jet technology, we evaluated the feasibility of this technology for nerve-sparing retroperitoneal lymphadenectomy. In an experimental



FIGURE 4 ■ Ex vivo kidney perfusion model to study the impact of renal perfusion and various pressures during Hydro-Jet application.



FIGURE 5 ■ Ex vivo demonstration of the effect of Hydro-Jet on renal parenchyma. Note tissue selectivity with separation of renal parenchyma and preservation of a net of vasculature and collecting system.

Our experimental data demonstrated the feasibility of retroperitoneal lymphadenectomy using the hydro-jet technology.

study, three pigs underwent retroperitoneal lymphadenectomy using hydro-jet dissection (20). Animals were sacrificed at the end of the procedure. The procedure was completed in all animals. All lymphatic tissue below the level of renal artery to the bifurcation of the aorta was removed. The pressure range was 300 to 400 psi (21–30 bar) initially. No injury to adjacent great vessels was noted during dissection while the sympathetic nerve fibers in retroperitoneum were preserved. The dissection time was 20 to 30 minutes and amount of normal saline used was less than 200 mL.

Our experimental data demonstrated the feasibility of retroperitoneal lymphadenectomy using the hydro-jet technology.

CLINICAL APPLICATIONS IN UROLOGY

Limited clinical applications have been reported in urology for partial nephrectomy, radical prostatectomy and retroperitoneal lymphadenectomy using the hydro-jet technique. The majority of these procedures were completed using open technique. In a clinical study, 24 patients underwent open renal sparing surgery for various indications including renal tumors (21). The dissection was performed without hilar control. The dissection time was 14 to 40 minutes with no significant blood loss. A pressure range of 16 to 22 bar was utilized. In a preliminary study at the University of Toronto, we performed six open partial nephrectomies using hydro-jet (unpublished data). The procedure was successful in all subjects with selective preservation of blood vessels, which were controlled using bipolar or monopolar forceps or selective ligation. Temporary hilar control was achieved in the majority of patients. In our experience, lack of hilar control was associated with more blood loss during larger resections. The time spent for dissection was 20 to 30 minutes. The mean estimated blood loss was 265 mL (range: 150–500 mL). There were no intraoperative or postoperative complications. The pathology revealed renal cell carcinoma in all patients. At a mean follow-up of 12 months, all patients were disease free. Currently, there is no reported experience with this technology for laparoscopic partial nephrectomy in human.

Hydro-jet technology also has been used for nerve-sparing approach during open and laparoscopic radical prostatectomy (unpublished data). The use of this technique facilitates isolation and preservation of neuromuscular bundles. However, no long-term functional data are currently available.

More recently, we have reported preliminary data using this technology for nerve-sparing retroperitoneal lymphadenectomy (20). The optimal pressure used for retroperitoneal lymphadenectomy was in the range of 225 to 305 psi (16–21 bar) in human. The dissection properties in this pressure range are similar to higher pressure with preservation of smaller blood vessels and nerves. Retroperitoneal lymphadenectomy was performed in five men with testicular cancer. The lymphadenectomy was primary in two and post chemotherapy in three patients. The primary diagnosis was seminoma in one and nonseminoma in four.

Hydro-jet nerve-sparing retroperitoneal lymphadenectomy permitted tissue selectivity with preservation of vascular structures and sympathetic nerves. The soft tissue and lymphatics were removed with the high-pressure saline stream assisted by blunt dissection. The nerve fibers were grossly resistant to the pressure used and were isolated individually. Sympathetic nerve fibers leading to the hypogastric plexus were isolated and preserved (Fig. 6).

The dissection time was comparable to the conventional technique. The mean estimated blood loss was 450 mL. There were no intraoperative or postoperative complications. The pathology revealed residual embryonal carcinoma in one, teratoma in two and fibrosis in two. At a mean follow-up of 24 months, all patients reported return of ejaculation and no retroperitoneal recurrences have occurred.

FUTURE PERSPECTIVES

The issue of cost of Hydro-Jet technology has not been addressed in the literature as yet. There is initial capital cost and ongoing maintenance. The probes and saline cartridge are disposable. Whether this cost increase can be justified by improved surgical dissection and decreased complication rates remains to be elucidated. For some applications, Hydro-jet dissection may replace existing and often more costly technologies. Furthermore, a multidisciplinary use of this technology for various surgical procedures would potentially improve local utility and spread the costs. Further studies in larger numbers of patients including cost comparisons are necessary to assess the financial burden of this technology.

Hydro-jet nerve-sparing retroperitoneal lymphadenectomy permitted tissue selectivity with preservation of vascular structures and sympathetic nerves. The soft tissue and lymphatics were removed with the high-pressure saline stream assisted by blunt dissection. The nerve fibers were grossly resistant to the pressure used and were isolated individually. Sympathetic nerve fibers leading to the hypogastric plexus were isolated and preserved.

FIGURE 6 ■ Intraoperative photograph of dissection of the postganglionic retroperitoneal sympathetic nerves using the Helix™ Hydro-Jet. The right nerve roots at the vertebral levels of L2–L4 seen from the patient's right side.



SUMMARY

- Initial experimental and clinical studies with hydro-jet technology demonstrated the feasibility and advantages of this technology as a dissection tool during open and laparoscopic procedures.
- Clinical application of this technology in the field of laparoscopic urology has been limited.
- Further experience and prospective comparative studies are necessary to evaluate the ideal clinical indications in the future.

REFERENCES

1. Burke RK. Bipolar electrocautery is a vital component of an efficient, integrated hydro-dissection system. *Endosc Surg Allied Technol* 1993; 1:107.
2. Nezhat CH, Nezhat F, Seidman DS, et al. A new method for laparoscopic access to the space of Retzius during retropubic cystourethrectomy. *J Urol* 1996; 155:1916.
3. Ostrzenski A. A new laparoscopic abdominal radical hysterectomy: a pilot phase trial. *Eur J Surg Oncol* 1996; 22:602.
4. Naude GP, Morris E, Bongard FS. Laparoscopic cholecystectomy facilitated by hydrodissection. *J Laparoendosc Adv Surg Tech A* 1998; 8:215.
5. Shekarriz B, Shekarriz H, Upadhyay J, et al. Hydro-jet dissection for laparoscopic nephrectomy: a new technique. *Urology* 1999; 54:964.
6. Summers DA: *Waterjetting Technology*. London: Taylor & Francis, 1995.
7. Papachristou DN, Barters R. Resection of the liver with a water jet. *Br J Surg* 1982; 69:93.
8. Baer HU, Stain SC, Guastella T, et al. Hepatic resection using a water jet dissector. *HPB Surg* 1993; 6:189.
9. Baer HU, Metzger A, Barras JP, et al. Laparoscopic liver resection in the large white pig—a comparison between waterjet dissector and ultrasound dissector. *Endosc Surg Allied Technol* 1994; 2:189.
10. Rau HG, Buttler E, Meyer G, et al. Laparoscopic liver resection compared with conventional partial hepatectomy—a prospective analysis. *Hepatogastroenterology* 1998; 45:2333.
11. Piek J, Oertel J, Gaab MR. Waterjet dissection in neurosurgical procedures: clinical results in 35 patients. *J Neurosurg* 2002; 96:690.
12. Hubert J, Mourey E, Suty JM, et al. Water-jet dissection in renal surgery: experimental study of a new device in the pig. *Urol Res* 1996; 24:355.
13. Shekarriz H, Shekarriz B, Upadhyay J, et al. Hydro-jet assisted laparoscopic partial nephrectomy: initial experience in a porcine model. *J Urol* 2000; 163:1005.
14. Shekarriz H, Shekarriz B, Burk CG, et al. Hydro-jet-assisted pneumonectomy: a new technique in a porcine model. *J Laparoendosc Adv Surg Tech A* 2002; 12:371.
15. Shekarriz H, Shekarriz B, Upadhyay J, et al. Hydro-Jet assisted laparoscopic cholecystectomy: initial experience in a porcine model. *JSL* 2002; 6:53.
16. Shekarriz H, Shekarriz B, Kujath P, et al. Hydro-Jet-assisted laparoscopic cholecystectomy: a prospective randomized clinical study. *Surgery* 2003; 133:635.
17. Corvin S, Oberneder R, Adam C, et al. Use of hydro-jet cutting for laparoscopic partial nephrectomy in a porcine model. *Urology* 2001; 58:1070.
18. Shekarriz B. Hydro-jet cutting for laparoscopic partial nephrectomy in a porcine model. *Urology* 2002; 60:199.
19. Shekarriz B, Upadhyay J, Jewett M. Further experience with Hydro-Jet dissection for renal-sparing surgery [abstr]. *BJU Int* 2002.
20. Shekarriz B, Upadhyay J, Jewett M. Neve-sparing retroperitoneal lymphadenectomy using Hydro-Jet dissection: initial experience. *J Endourol*. In press. *J Endourol*; 18:273.
21. Basting RF, Djakovic N, Widmann P. Use of water jet resection in organ-sparing kidney surgery. *J Endourol* 2000; 14:501.

Jose R. Colombo, Jr., Osamu Ukimura, and Inderbir S. Gill

*Section of Laparoscopic and Robotic Surgery, Glickman Urological Institute,
Cleveland Clinic Foundation, Cleveland, Ohio, U.S.A.*

- PATHOPHYSIOLOGY
- VISCERAL TISSUE EXPANSION IN URINARY TRACT
- DESAI STUDY
 - Percutaneous Insertion of Ureteral Expansion Balloon
 - Chronic Ureteral Expansion
- Laparoscopic Augmentation Ureterocystoplasty
- RESULTS
- CLINICAL STUDY
- CLINICAL IMPLICATIONS
- REFERENCES

Tissue substitutes for reconstructive procedures of the urinary bladder, such as augmentation cystoplasty, are needed in a variety of acquired and congenital pediatric and adult urological diseases. Amongst the various self-tissue substitutes such as buccal mucosa, scrotal skin, pericardium, or allograft tissues, which can be used for a variety of urologic reconstructive procedures, only vascularized intestinal segments have been successful as regards reconstructive surgery of the urinary bladder (1–5). However, use of intestinal segments in urinary tract reconstruction is associated with significant potential disadvantages, including metabolic complications, complicated infections, stone and tumor formation, and a variety of surgical risks associated with bowel surgery (1). These disturbances are exaggerated in patients with compromised renal function, and in children.

Currently, various vascularized intestinal segments are most commonly used as tissue substitutes for bladder augmentation.

Although it is difficult to estimate the total number of surgical cases performed in the United States, in which such excessive substitute tissue is needed, a recent article from a single pediatric hospital reported their experience with 483 cases of bladder augmentation during 25 years (6). The disadvantages of using intestinal segments in urinary tract reconstruction include metabolic changes, mucus production, high incidence of early and late surgical complications, and stone/tumor formation (1). These disturbances may be exaggerated in patients with compromised renal function, and in children. In a search for more suitable tissue for bladder reconstruction, a variety of sources have been explored (1–5,7). The majority of these sources are still considered experimental, lacking any meaningful long-term clinical or experimental follow-up results.

Chronic tissue expansion is an established concept for creating new tissue in plastic surgery. Expansion of native skin has been successfully employed in various surgical disciplines such as breast reconstruction, craniofacial surgery, and plastic reconstructive surgery in patients with extensive burns (8). The expanded, new tissue, created by chronic stretch, replicates the morphometric and functional characteristics of the native tissue. A large body of literature has been accumulated to explore the mechanisms involved in tissue expansion in response to chronic stretch. This literature demonstrates that the mechanisms behind the principle of stretch-induced cellular growth involve a network of several integrated cascades that include growth factors, extracellular, cytoskeletal and transmembrane structures, ion channels; protein kinases, second messenger systems; and transcriptional factors (9–29).

This multifaceted network is initiated by a mechanical stimulus that sets into play a series of precise reactions through what has been referred to as the stretch-induced signal transduction pathway (9).

Currently, various vascularized intestinal segments are most commonly used as tissue substitutes for bladder augmentation.

Chronic tissue expansion is an established concept for creating new tissue in plastic surgery.

This multifaceted network is initiated by a mechanical stimulus that sets into play a series of precise reactions through what has been referred to as the stretch-induced signal transduction pathway.

PATHOPHYSIOLOGY

Chronic stretch-induced tissue expansion is accompanied by increased expression of several growth factors and receptors that may contribute to cell proliferation and tissue remodeling required for expansion. In smooth muscle cells, these proteins include members of the transforming growth factor, epidermal growth factor, basic fibroblast growth factor, platelet-derived growth factor, and nerve growth factor families (9–14). In bladder smooth muscle cells, mechanical stretch increased expression of heparin-binding epidermal growth factor-like growth factor and one of its receptors, ErbB1, resulting in inhibition of apoptosis (10). Stretch also induced production of nerve growth factor by urinary tract smooth muscle cells (11), and lower urinary tract obstruction induced hypertrophy of bladder afferent and efferent neurons that appeared to require increased nerve growth factor expression (12). The latter finding supports the hypothesis that obstruction-induced tissue expansion induces remodeling of the neural networks.

Stretch-induced tissue expansion also involves extracellular matrix production, which is required for stretch-induced cell proliferation (9). In vascular smooth muscle cells, mechanical strain-induced fibroblast growth and extracellular matrix production were accompanied by increased expression of transforming growth factor- β 1 and inhibited by a transforming growth factor- β 1 neutralizing antibody (13). Rapid tissue expansion also may injure ureteral tissue more seriously than slow expansion, with associated ischemia and inflammation. Transforming growth factor- β 1 may be the main regulating factor for both the repair process and inflammatory response. We observed two to threefold increases in transforming growth factor- β 2 expression in porcine chronic expanded versus native ureteral tissues (30).

Chronic tissue expansion has also been shown to induce angiogenesis, with associated ischemia, which in turn can stimulate production of vascular endothelial growth factor (14). Ischemia induced by tissue expansion may also determine the degree of any ensuing fibrosis. In our preliminary study, no change in vascular endothelial growth factor expression was observed in the expanded ureteral tissue (30). It should be noted that all of the above-cited literature regarding mechanisms of stretch-induced tissue remodeling pertains to cutaneous (skin) tissue expansion on cultured cells.

VISCERAL TISSUE EXPANSION IN URINARY TRACT

Tissue expansion techniques have also successfully been used in genitourinary tract tissues in the experimental setting (30–33). In 1996, Lailas and colleagues (31) initially reported chronic ureteral expansion for subsequent open ureterocystoplasty in a rabbit model. Ten rabbits underwent unilateral ligation at the ureterovesical junction and ipsilateral nephrectomy. A silicone catheter was placed into the proximal ureter and connected to a titanium injection port, which was placed subcutaneously at the level of costal margin. Two weeks later a saline antibiotic was injected in the port daily, limited by the pressure in the system. Within six weeks, the ureter was opened longitudinally on the anterior aspect, reconfigured into a U-shaped patch, anastomosed to the bladder and covered with an omental flap. A suprapubic tube was placed for 10 days after the procedure. After six months the animals were euthanized. The cystogram showed a mean increase of 260% in the bladder capacity. Urodynamic studies were compatible with a low-pressure, high-capacity bladder. In 1998, Ikeguchi and associates (32) performed chronic segmental ureteral expansion in eight pigs. A latex balloon was located in the distal ureter inserted through the renal parenchyma open surgically. A 10F Malecot nephrostomy was also placed. Daily ureteral dilation (150–1000 mL) was performed with 1–50 cm³ daily over a period of 2–4 weeks, with no anesthesia required. After this, an open ureterocystoplasty and reconstruction of the ipsilateral ureter were performed. A transurethral catheter was maintained for one week. Cystograms revealed an increased bladder capacity. The animals were sacrificed after four weeks, and the histological sections showed preservation of ureteral architecture with epithelial regeneration. In 2003, we initially reported a completely minimally invasive approach for chronic ureteral balloon expansion followed by laparoscopic augmentation ureterocystoplasty in a survival porcine model (30).

The methodology of visceral tissue expansion in the genitourinary system has yet to be refined to a place where it can have a real practical use by urologists, to the extent that skin expansion has become an accepted part of plastic reconstructive surgery.

Although the potential for ureteral tissue expansion in the context of urinary tract reconstruction has been preliminarily explored, none of the investigators have taken the

The methodology of visceral tissue expansion in the genitourinary system has yet to be refined to a place where it can have a real practical use by urologists, to the extent that skin expansion has become an accepted part of plastic reconstructive surgery.

issue far enough to explore the cellular and molecular mechanism involved in visceral tissue expansion and remodeling.

Encouraged by the above principles and potential usefulness of expanded ureteral tissue, we have pursued development and proof of concept of a methodology that would enable us to obtain excess ureteral tissue with minimally invasive surgical techniques. The expanded ureteral tissue can be used in open or laparoscopic surgical techniques in a variety of reconstruction applications for the lower urinary tract. Further, our preliminary studies have provided stimulus for pursuit of biological markers possibly responsible for visceral tissue remodeling.

DESAI STUDY

The study was performed in 35 to 40 kg female farm pigs, after approval from the Animal Research Committee of our institution. The initial five animals were used to develop the prototype design and insertion technique of the ureteral expansion balloon, its inflation schedule, and the technique of laparoscopic ureterocystoplasty. Subsequently, five animals entered the survival study.

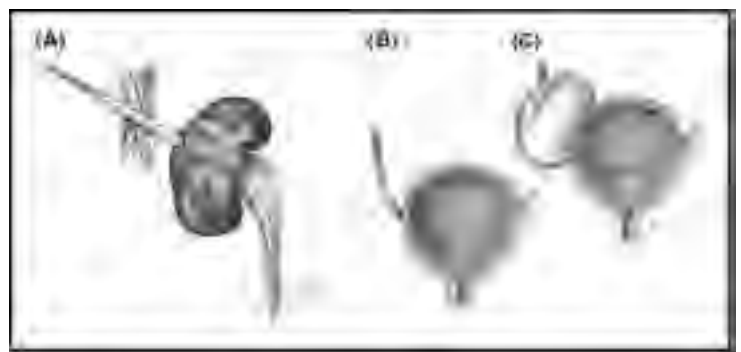
Percutaneous Insertion of Ureteral Expansion Balloon

All five chronic animals underwent unilateral (right three, left two) percutaneous insertion of the ureteral expansion balloon^a; a dual-channel balloon catheter: one for inflation, and the other for proximal nephrostomy drainage (Fig. 1). Initially, a 5F open-ended ureteral catheter was inserted cystoscopically into the ipsilateral renal collecting system. The animal was then positioned prone, and percutaneous renal access was obtained under fluoroscopic guidance. A 0.035 inch Glide-wire^a was manipulated antegrade down the ureter and retrieved through the bladder, and the open-ended ureteral catheter was removed. Using an antegrade 5F ureteral catheter, the Glide-wire was replaced with a 0.035 in Amplatz Superstiff guidewire^a. The percutaneous tract was dilated using a single-step dilator, and a 20F peel-away sheath was positioned in the renal pelvis. A 21F 10 cm ureteral

FIGURE 1 ■ Ureteral expansion was performed using a novel silicone balloon TUEC catheter having two channels: a smaller channel to inflate balloon (c1) and a larger fenestrated channel to drain kidney (c2). The 14F shaft has multiple holes to facilitate proximal urinary drainage. The balloon (b) has one radiopaque marker (m1 and m2) at its either end to facilitate fluoroscopic confirmation during placement. Additional radiopaque marker (m3) on shaft immediately proximal to last drainage hole should lie within kidney. Terminal end of catheter is fashioned into a pigtail to facilitate retention in bladder. Single-step dilator (d) is used to position 20F peel-away sheath (s) within renal collecting system.



FIGURE 2 ■ Procedures of percutaneous insertion of TUEC, and inflation of balloon. Balloon position. (A) Deflated balloon is positioned in juxtavesical ureter. (B) Incremental progressive inflation of balloon causes chronic expansion of juxtavesical ureter. (C) Expanded juxtavesical ureter. Note laterally based vascular supply to expanded ureteral segment from internal iliac vessels.



^aMicrovasive, Natick, MA.

The inflation could be carried out without anesthesia or analgesia while the overnight fasting animal was busily eating.

dilation balloon (Uromax^a) was used to dilate the entire ureter in a stepwise fashion over a period of two minutes to facilitate subsequent passage of the novel expansion device. The adequately lubricated balloon expansion catheter was gradually manipulated antegrade into the ureter over the Superstiff guidewire (Fig. 2A). The balloon, flanked by radiopaque markers, was positioned in the juxtavesical ureter and distended with 2.5 to 3 mL of contrast medium to secure it in position (Fig. 2B). The excess proximal length of the catheter exiting the animal's back was tunneled subcutaneously so that only the inflation and drainage ports were visible outside the skin.

The inflation could be carried out without anesthesia or analgesia while the overnight fasting animal was busily eating.

Chronic Ureteral Expansion

Starting the day after placement of the ureteral expansion balloon, the ureter was gradually dilated by daily incremental instillation of a dilute (1:4) contrast solution. Ureteral expansion was monitored radiologically every 7 to 10 days (Fig. 3).

Laparoscopic Augmentation Ureterocystoplasty

Laparoscopic ureterocystoplasty was performed in all five animals after 3 to 4 weeks of ureteral expansion. All procedures were performed using a four-port transperitoneal approach with the pig under general anesthesia. Initially, the ureteral balloon was completely deflated, and the amount of fluid aspirated was measured. The balloon was subsequently refilled with the same amount of dilute antibiotic solution to facilitate intraoperative identification and to prevent intraoperative spillage of potentially infected fluid should inadvertent puncture of the balloon occur intraoperatively. After port placement, the pelvic organs were examined laparoscopically. The expanded ureter was identified as a readily visible bulge adjacent to the urinary bladder. The medial peritoneum overlying the expanded ureter was incised to expose the ureteral wall. The fallopian tube and ovary on the ipsilateral side were mobilized away from the ureter. The bladder was mobilized by dividing the medial umbilical ligament and the superior vesical pedicle and incised laterally in a longitudinal fashion from just above the ureteral orifice up to the dome. The ureteral orifice and intramural ureter were preserved. While in the initial two animals the bladder dome was not excised, in the latter three approximately 80% of the bladder was removed. The medial wall of the expanded ureteral segment was then incised using a J-hook monopolar cautery electrode, thus opening the expanded ureteral segment medially. Care was taken to minimize any mobilization of the ureter, thus maintaining intact the laterally based vascularity of the expanded ureter (Fig. 4). The length, site, and orientation of the ureteral incision were tailored to correspond to the bladder defect (Fig. 5). After the ureteral incision was completed, the balloon was deflated and the catheter removed. The in-line tissue-expanded ureteral patch was then anastomosed to the bladder in a running fashion using 2-0 Vicryl sutures on a computed tomography-1 needle with freehand intracorporeal laparoscopic suturing and knot-tying techniques (Fig. 6). After the posterior wall was sutured, an 18F red rubber urethral catheter was inserted antegrade into the urethra through the bladder neck. The anterior wall was then sutured to complete the augmentation ureterocystoplasty. A 22F Malecot suprapubic catheter was left indwelling and brought out through the suture line in the initial two animals only. A 22F




FIGURE 3 ■ Light microscopic examination of: (A) normal ureter, (B) tissue-expanded ureter that reveals muscle hypertrophy and hyperplasia, and variable inflammatory infiltrate, and (C) native bladder. Note: The expanded ureter (B) more closely resembles the thickness of the bladder wall (C) than the normal ureter (A).




FIGURE 4 ■ Plain radiographs of abdomen document progressive ureteral expansion (A) at one week with 12 mL volume. (B) At two weeks, volume in balloon has increased to 46 mL. (C) At 25 days just prior to augmentation ureterocystoplasty with 140 mL in the balloon.

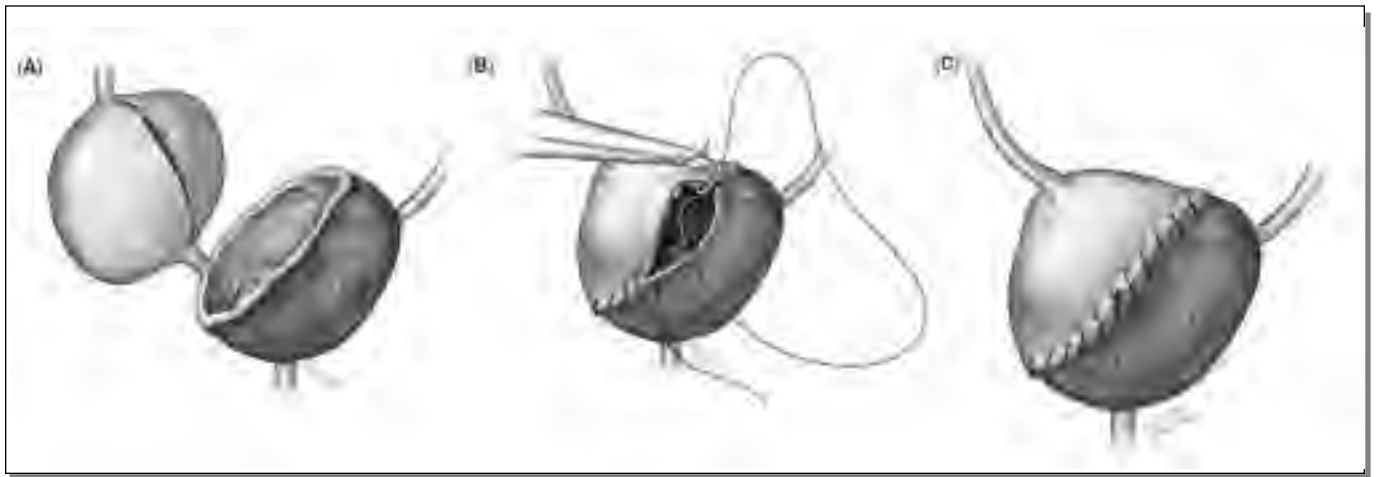

FIGURE 5 ■ Steps during the laparoscopic ureterocystoplasty.

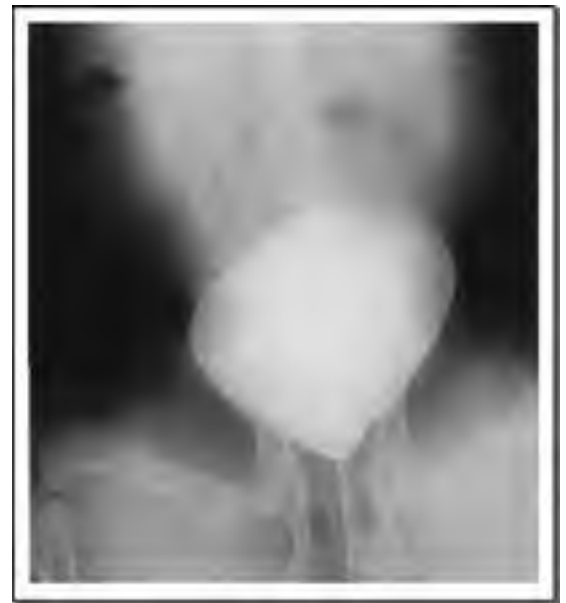

FIGURE 6 ■ Cystogram performed immediately prior to autopsy at three months. Augmented bladder reveals capacity of 600 mL. There is grade II reflux in the right ureter.

tube drain was positioned in the prevesical space in all five animals and brought out through a port site. The animals were returned to the chronic animal care facility.

Oral antibiotics were administered until urethral catheter was removed. The suprapubic catheter was removed after seven days, and the urethral catheter was removed after 14 days if not spontaneously expelled earlier. The drain, if not spontaneously expelled, was removed a day after the urethral catheter was removed. All animals underwent laboratory, radiologic, urodynamic, and histologic investigations (Table 1). Additionally, transmission electron microscopy of the expanded ureter and measurement of vascular endothelial growth factor and transforming growth factor- β 2 in expanded ureteral tissue were performed in selected animals. Animals were euthanized at 15 days ($N = 1$), one month ($N = 1$), two months ($N = 1$), and three months ($N = 2$).

RESULTS

Percutaneous Insertion of Ureteral Expansion Balloon

Percutaneous insertion was technically successful with satisfactory balloon placement in all five animals. The mean operative time required for balloon insertion was 52 ± 6 minutes, and there were no complications (Table 2).

TABLE 1 ■ Investigation Schedule

	Timing
Laboratory: Complete blood count, metabolic profile, urinalysis and culture	Prior to balloon insertion Prior to augmentation ureterocystoplasty Prior to euthanasia
Radiologic	
Plain film	Weekly during balloon inflation Prior to augmentation ureterocystoplasty
Cystogram	At 1-month follow-up Prior to euthanasia
Intravenous urogram	Prior to euthanasia
Urodynamics	Prior to euthanasia
Cystoscopy	At 1-month follow-up (N = 2) Prior to euthanasia
Histology	
Light microscopy	During augmentation cystoplasty At euthanasia
Transmission electron microscopy	During augmentation cystoplasty (N = 2)
Tissue cytokine assay (VEGF and TGF- β 2)	During augmentation cystoplasty (N = 5) ^a

^aSeven tissue biopsies were obtained from the five animals at the time of augmentation ureterocystoplasty for cytokine assay.

The inflation could be carried out without anesthesia or analgesia while the overnight fasting animal was busily eating.

Chronic Ureteral Expansion

All five animals underwent successful ureteral expansion over a mean of 25 ± 1.4 days (Table 3). The mean final volume of the ureter was 177.1 ± 41.3 mL. The mean volume of fluid instilled was 12.7 ± 0.9 mL in the first week, 38.4 ± 4.3 mL in the second week, 66.2 ± 17.4 mL in the third week, and 59.8 ± 28.4 mL in the fourth week. The mean daily inflation volume was 1.8 ± 0.1 mL in the first week, 5.5 ± 0.6 mL in the second week, 11.3 ± 2.5 mL in the third week, and 16.1 ± 1.8 mL in the fourth week. All five awake animals readily tolerated the daily incremental instillation of dilute contrast solution without apparent pain or discomfort.

The inflation could be carried out without anesthesia or analgesia while the overnight fasting animal was busily eating.

Radiologic volumetric assessment of the ureteral balloon during the phase of ureteral expansion was commensurate with the amount of fluid instilled. We did not note any complications during ureteral expansion. Proximal urinary drainage through the fenestrated channel of the ureteral expansion catheter was adequate in all five animals.

Laparoscopic Augmentation Ureterocystoplasty

Laparoscopic ureterocystoplasty was technically successful in all five animals without need for open conversion in any case. The mean operative time was 156 ± 41.1 minutes (range 115–210 minutes), and the mean estimated blood loss was 29 ± 16 mL (range 10–50 mL). One animal had a small-bowel serosal tear, which was readily suture repaired laparoscopically. Some periureteral adhesions were encountered in the vicinity of the expanded ureter, which could readily be lysed laparoscopically. Intraoperatively, at the time of ureterocystoplasty, the expanded ureter appeared thick and highly vascular, with areas of urothelial denudation. Intraoperative instillation of saline through the urethral catheter at the end of the ureterocystoplasty revealed a

TABLE 2 ■ Intraoperative Data

Mean time for balloon insertion (min)	52 ± 10.6 (39–68)
Mean time for bladder augmentation (min)	156 ± 41.1 (115–210)
Estimated blood loss (mL)	29 ± 16 (10–50)
Subtotal cystectomy performed (N)	3
Ureteral stenting (N)	2
Urethral catheter (N)	5
Suprapubic catheter (N)	4
Open conversion (N)	0
Intraoperative complications (N)	Serosal bowel tear repaired laparoscopically (1)

TABLE 3 ■ Balloon Inflation Data

Animal	Duration (days)	First week		Second week		Third week		Fourth week		Final anticipated volume (mL) ^c	Final aspirated volume (mL) ^d
		Mean daily volume increase (mL) ^a	Final volume (mL) ^b	Mean daily volume increase (mL)	Final volume (mL)	Mean daily volume increase (mL)	Final volume (mL)	Mean daily volume increase (mL)	Final volume (mL)		
1	23	1.6 (0.5–3)	11.5	6.4 (3.5–10)	45	10 (10–10)	50	14.5 (14–15)	29	135.5	120
2	24	1.7 (0.5–3)	12	4.9 (3.5–9)	34	10 (10–10)	50	14.6 (14–15)	44	140	132
3	26	1.8 (1–3)	13	5 (3.5–9)	35	10.8 (10–15)	65	18.6 (15–20)	93	206	200
4	26	1.9 (0.5–3)	13.5	5.6 (4–10)	39	13 (12–15)	91	17.4 (15–20)	87	230.5	216
5	26	1.9 (0.5–3)	13.5	5.6 (4–10)	39	12.5 (12–15)	75	15.3 (15–16)	46	173.5	170
Mean	25	1.8	12.7	5.5	38.4	11.3	66.2	16.1	59.8	177.1	167.6

^aTotal volume of fluid introduced into balloon in a week divided by number of days injected. Although inflation was performed daily, a few days were skipped for logistical reasons.

^bTotal volume of expansion achieved during week.

^cEstimated amount of fluid in balloon at end of expansion process.

^dActual volume of fluid aspirated from ureteral expansion balloon immediately prior to augmentation ureterocystoplasty. This volume was slightly less than the anticipated volume. There are two possible explanations: (1) some immeasurable fluid loss may occur during balloon inflation because of sudden movement of the animal, and (2) some fluid may not be completely aspirated from balloon.

watertight anastomosis in all five cases. Postoperative complications were seen in two animals: lower ureteral obstruction and pyelonephritis with urosepsis.

Urodynamic, Cystography, and Cystoscopy Data

Over a follow-up ranging from 15 days to 3 months, the mean bladder capacity was 574 ± 221.3 mL (range 380–940 mL). The P_{ves} at maximum capacity was 14 ± 4.5 cmH₂O (range 8–20 cmH₂O), and bladder compliance was 71.7 mL/cmH₂O (range 35.3–188 mL/cmH₂O). Uninhibited detrusor contractions were not evident on urodynamic evaluation in any of the five animals (Table 4). Cystography revealed ipsilateral reflux in four renal units: grade II in one animal, grade IV in two animals, and grade V in one animal (Fig. 7). At autopsy, one renal unit demonstrated lower-ureteral obstruction and therefore showed no reflux on cystography. There was no contralateral reflux in any renal unit. In all four refluxing units, the refluxed contrast drained from the kidney immediately after the bladder was emptied, thereby ruling out any ureteral obstruction. Additionally, the cystogram did not reveal contrast extravasation in any case.

Cystoscopy was performed in all animals at one month and at autopsy. By one month, the bladder revealed a fully regenerated mucosa in four animals; one animal euthanized at 15 days still had patchy areas of denuded mucosa.

Laboratory Data

Laboratory examination revealed minimal metabolic alterations in four animals. One animal that developed pyelonephritis and urosepsis had evidence of azotemia,

TABLE 4 ■ Radiologic Data

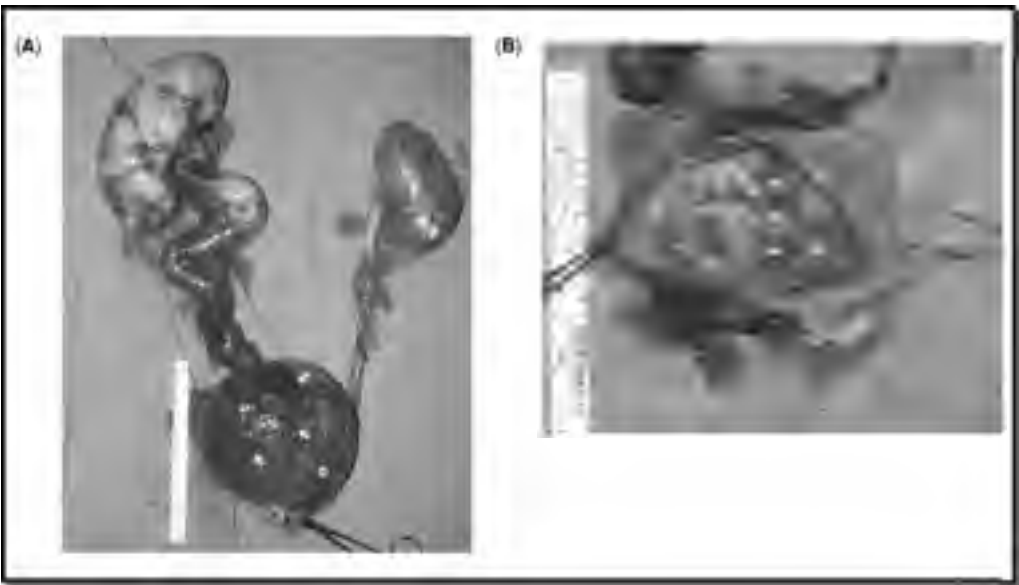
						Urodynamics ^b			
Animal	Follow-up (weeks)	Subtotal (80%) cystectomy	Cytogram ^a		Bladder capacity (mL)	Pves(cmH ₂ O)		Compliance (mL/cmH ₂ O)	Involuntary bladder contractions
			Ipsilateral reflux (grade) ^c	Anastomotic leak?		Resting	Full capacity		
1	2	No	2	No	600	3	20	35.3	Absent
2	4	No	4	No	380	2	12	38	Absent
3	8	Yes	—	No	940	3	8	188	Absent
4	12	Yes	4	No	430	4	12	53.8	Absent
5	12	Yes	5	No	520	6	18	43.3	Absent
Mean	—	—	—	—	574	3.6	14	71.7	—

^aCystographic examination was performed at one month (N = 3) and at autopsy (N = 5) by injecting contrast through a urethral catheter. In all refluxing renal units, obstruction was ruled out by documentation of prompt drainage of contrast from the collecting system.

^bUrodynamics, in the form of filling cystometrogram, was performed in each animal immediately prior to autopsy. The animal was anesthetized and placed supine on the table. The bladder was filled through a 6F urethral catheter, and intravesical pressure was recorded through a separate 6F urethral catheter connected to manometer tubing. Parameters recorded included total bladder capacity, resting and end filling pressures, bladder compliance, and involuntary detrusor contractions.

^cNo animal developed contralateral reflux.

FIGURE 7 ■ Autopsy photographs. (A) Augmented bladder and both renal units. Healed suture line between expanded ureteral patch (u) and native bladder (b) is seen (arrows). (B) Interior of augmented bladder shows demarcation (arrows) between expanded ureter (u) and native bladder (b). Notice complete epithelization of expanded ureteral patch.



hyponatremia, hyperkalemia, and acidosis (Table 5). The mean serum creatinine concentration was 1.3 ± 0.2 mg/dL at baseline, 0.9 ± 0.2 mg/dL at bladder augmentation, and 2.0 ± 0.9 mg/dL at euthanasia.

Autopsy Data

At autopsy, the ureteral patch appeared well vascularized, and the ureterocystoplasty suture line was healed in all five animals. The ipsilateral renal parenchyma appeared grossly normal in three cases, with pre-euthanasia intravenous urography revealing prompt opacification with mild hydronephrosis. One animal with a lower ureteral obstruction revealed thinning of parenchyma and poor function on intravenous urography. At autopsy, the obstruction was found to be the result of flimsy synechia formation at the junction where the upper, normal caliber ureter entered the expanded ureteral segment. The animal with pyelonephritis and urosepsis had a grossly scarred kidney that was nonfunctioning on intravenous urography.

Histologic examination of the expanded ureter harvested at the time of autopsy revealed persistent muscle hypertrophy and hyperplasia, a fully regenerated transitional epithelium, and variable amount of fibrosis.

Histologic Data

Histologic examination of the expanded ureter harvested at the time of autopsy revealed persistent muscle hypertrophy and hyperplasia, a fully regenerated transitional epithelium, and variable amount of fibrosis.

Light microscopic examination of biopsies of the expanded ureter obtained at the time of augmentation cystoplasty revealed muscle hypertrophy and hyperplasia, mucosal atrophy, and variable inflammatory infiltrate.

Electron Microscopic Data

Transmission electron microscopy performed on the ureteral tissue obtained at the time of laparoscopic augmentation revealed cellular evidence consistent with muscular hypertrophy and hyperplasia.

TABLE 5 ■ Serum Biochemical Data

	Prior to ureteral balloon expansion	Prior to augmentation cystoplasty	Prior to euthanasia
Mean serum cretinine (mg/dL)	1.3 ± 0.2 (1.1–1.4)	0.9 ± 0.2 (0.7–1.1)	2.0 ± 0.9 (1.4–3.4)
Mean serum potassium (mEq/L)	139.4 ± 3.3 (136–143)	135.5 ± 7.0 (127–144)	132.5 ± 9.7 (119–140)
Mean serum sodium (mEq/L)	4.3 ± 0.2 (4.1–4.5)	4.4 ± 0.2 (4.1–4.6)	4.7 ± 0.6 (4.1–5.4)
Mean serum chloride (mEq/L)	97.2 ± 3.4 (93–102)	95.5 ± 6.5 (88–103)	88 ± 18.9 (66–100)
Mean serum CO ₂ (mEq/L)	27 ± 3.3 (24)	27.8 ± 0.5 (27–28)	24 ± 5.7 (16–19)
Mean anion gap	15.2 ± 3.9 (9–19)	12.3 ± 1.0 (11–13)	18.3 ± 11.4 (10–35)
Mean hemoglobin (mg/dL)	11.6 ± 0.3 (11.3–12)	9.6 ± 1.0 (8.7–10.9)	10.3 ± 2.6 (8.8–14.1)
Mean hematocrit (%)	39.8 ± 2.0 (37.7–42.3)	32.0 ± 3.4 (29.1–35.8)	35.3 ± 8.1 (27.7–46.8)

Growth Factor Assay Data

Preliminary data on growth factor expression in expanded ureteral tissue obtained and snap frozen at the time of augmentation ureterocystoplasty revealed a two to threefold increase in transforming growth factor- β 2 (median, 44 pg/mL; range, 27–49 pg/mL) over controls (normal ureter, 16 pg/mL). There was no increase in vascular endothelial growth factor expression in the expanded ureteral tissue compared with control samples.

CLINICAL STUDY^b

After percutaneous placement of the balloon device, in-line expansion of the distal ureter was achieved on an outpatient basis over 23–38 days to a volume of upto 218 mL. Notably, all three patients did not require any analgesia during this entire expansion process.

After percutaneous placement of the balloon device, in-line expansion of the distal ureter was achieved on an outpatient basis over 23–38 days to a volume of upto 218 mL. Notably, all three patients did not require any analgesia during this entire expansion process.

Following our laboratory experiments and upon availability of the opportunity in two outside medical centers, we performed this procedure in three patients outside the United States, in India ($N=2$) and Brazil ($N=1$), with the approval of the ethical committee at each local institution. Clinical data from these patients have been encouraging, supporting our laboratory data. Specifically, we treated two women and one man, aged 14, 65, and 54 years, respectively. Each patient suffered from a noncompliant bladder with reduced capacity (range 15–150 mL).

Operative time for the laparoscopic augmentation ureterocystoplasty ranged from two to three hours, and blood loss was 25 to 50 mL. Each patient commenced oral intake on the same day and ambulated within 24 hours. Hospital stay ranged from six to eight days. There were no infections or other complications at any stage of this study. Postoperatively, bladder capacity increased significantly to 250 to 280 mL at two-month follow-up. The first patient has now completed two-year follow-up with durable success. All three patients have experienced significant, even dramatic, improvement in voiding symptoms, and the renal function is well preserved.

The availability of a urothelium-lined, muscle-backed, vascularized, autogenous, in-line tissue material for purposes of augmentation, and possibly even replacement, of the urinary bladder would indeed be a major advance.

The availability of a urothelium-lined, muscle-backed, vascularized, autogenous, in-line tissue material for purposes of augmentation, and possibly even replacement, of the urinary bladder would indeed be a major advance.

CLINICAL IMPLICATIONS

This could potentially eliminate the use of bowel (and its attendant morbidity) in urinary tract reconstruction. Potentially, such a bladder substitute could have mucosal, myogenic, and neurogenic attributes that approximate those of a functionally intact urinary bladder. Our proposal represents a concerted effort at establishing and developing this novel field of visceral tissue expansion.

The search for the ideal tissue substitute for bladder augmentation is ongoing. Currently, intestinal segments remain most commonly used for bladder augmentation. Although the results of augmentation cystoplasty using various bowel segments have generally been acceptable, these tissues are associated with absorptive metabolic changes, mucus production, and stone formation, the magnitude of which is dependent on the length and segment of bowel used (34). Significant research in the past few decades has focused on alternative tissue substitutes for urinary tract reconstruction. These have included tissue-engineered materials, xenografts such as small-intestinal submucosa, and techniques such as autoaugmentation and de-epithealized bowel (1–3). Some of these techniques, although promising, have either been insufficiently durable or require considerable refinement.

The ureter, with its transitional epithelium, is potentially an optimal tissue for bladder augmentation (5).

Augmentation ureterocystoplasty has been reported, with encouraging long-term urodynamic results, and limited, if any, metabolic changes. However, the amount of ureteral tissue needed to provide a urodynamically acceptable bladder augmentation can be obtained only in a patient with a large megaureter. Therefore, currently, augmentation ureterocystoplasty is limited to the occasional patient with a megaureter and a nonfunctioning kidney who requires bladder augmentation.

Thus, although the potential for ureteral tissue expansion for urinary tract reconstruction has been demonstrated, further characterization of the biology of ureteral expansion and refinement of technique are necessary prior to its clinical application. The Desai study was designed specifically to address the following crucial issues: (i) the

The ureter, with its transitional epithelium, is potentially an optimal tissue for bladder augmentation.

^bGill et al., unpublished data.

feasibility of percutaneous insertion of the ureteral expansion device; (ii) the efficacy of this novel balloon in expanding the ureter to the desired volume while simultaneously providing adequate drainage of the renal unit; (iii) a safe and reliable time line schedule and regimen for ureteral balloon expansion; (iv) the technical feasibility of performing laparoscopic augmentation ureterocystoplasty using the tissue-expanded ureter; and (v) the biologic nature of the expanded ureteral tissue and its efficacy in providing a urodynamically adequate bladder augmentation in a survival porcine model.

Postoperative complications occurred in two animals. One animal, whose ureter was unstented, developed lower-ureteral stenosis, hydroureteronephrosis, and poor ipsilateral renal function, and the other animal had pyelonephritis with urosepsis. At autopsy, the animal with lower-ureteral obstruction revealed flimsy adhesion formation at the junction of the expanded ureter with the proximal normal-caliber ureter. There was no transmural fibrosis on histologic examination of the stenotic area. This obstruction probably represents cross-healing of the opposite ureteral walls following mucosal denudation during the expansion process and can potentially be avoided by stenting at the time of augmentation ureterocystoplasty until re-epithelization is complete.

Our survival porcine study demonstrates that progressive, incremental ureteral tissue overexpansion can be carried out safely and reliably with a percutaneously placed expansion balloon. This ureteral expansion is well tolerated and can be performed over a 3- to 4-week period to create a sizeable reservoir for bladder augmentation. The expanded ureter is thick and vascular and reveals histologic and electron microscopic features of durable ureteral smooth-muscle hypertrophy and hyperplasia. This expanded tissue can be used laparoscopically to augment the bladder. Such augmented bladders possess good urodynamic properties over a three-month follow-up period.

This approach has the potential to provide native, urothelium-lined tissue for augmentation or, possibly, replacement of the urinary bladder.

Concerted research in this arena will lead to further development of this novel field of visceral tissue expansion.

This approach has the potential to provide native, urothelium-lined tissue for augmentation or, possibly, replacement of the urinary bladder.

REFERENCES

1. McDougal WS. Metabolic complications of urinary intestinal diversion. *J Urol* 1992; 147:1199–1208.
2. Oberpenning F, Meng J, Yoo JJ, Atala A. De novo reconstitution of a functional mammalian urinary bladder by tissue engineering. *Nat Biotechnol* 1999; 17:149–155.
3. Elbahnasy AM, Shalhav A, Hoenig DM, Figenshau R, Clayman RV. Bladder wall substitution with synthetic and non-intestinal organic materials. *J Urol* 1998; 159:628–637.
4. Snow BW, Cartwright PC. Bladder autoaugmentation. *Urol Clin North Am* 1996; 23:323–331.
5. Dewan PA, Close CE, Byard RW, Ashwood PJ, Mitchell ME. Enteric mucosal regrowth after bladder augmentation using demucosalized gut segments. *J Urol* 1997; 158:1141–1146.
6. Soergel TM, Cain MP, Misseri R, Gardner TA, Koch MO, Rink RC. Transitional cell carcinoma of the bladder following augmentation cystoplasty for the neuropathic bladder. *J Urol* 2004; 172:1649–1651.
7. Churchill BM, Aliabadi H, Landau EH, et al. Ureteral bladder augmentation. *J Urol* 1993; 150:716–720.
8. Neumann CG. The expansion of an area of skin by progressive distention of a subcutaneous balloon: use of the method for securing skin for subtotal reconstruction of the ear. *Plast Reconstr Surg* 1957; 19:124–130.
9. De Filippo RE, Atala A. Stretch and growth: the molecular and physiologic influences of tissue expansion. *Plast Reconstr Surg* 2002; 109:2450–2462.
10. Nguyen H, Park J, Peters C, et al. Cell-specific activation of the HB-EGF and ErbB1 genes by stretch in primary human bladder cells. *In vitro cell. Dev Biol Anim* 1999; 35:371.
11. Persson K, Sando JJ, Tuttle JB, Steers WD. Protein kinase C in cyclic stretch-induced nerve growth factor production by urinary tract smooth muscle cells. *Am J Physiol* 1995; 269(4 Pt 1):C1018–C1024.
12. Steers WD, Kolbeck S, Creedon D, Tuttle JB. Nerve growth factor in the urinary bladder of the adult regulates neuronal form and function. *J Clin Invest* 1991; 88(5):1709–1715.
13. O'Callaghan CO, Williams B. Mechanical strain increases matrix synthesis by human vascular smooth muscle cells: the role of TGF[β]. *J Hypertens* 1998; 16(suppl 2):S16.
14. Shweiki D, Itin A, Soffer D, Keshet E. Vascular endothelial growth factor induced by hypoxia may mediate hypoxia-initiated angiogenesis. *Nature (Lond)* 1992; 359:843–845.
15. Takei T, Mills I, Arai K, Sumpio BE. Molecular basis for tissue expansion: clinical implications for the surgeon. *Plast Reconstr Surg* 1998; 102:247–258.
16. Schmidt C, Pommerenke H, Durr F, et al. Mechanical stressing of integrin receptors induces enhanced tyrosine phosphorylation of cytoskeletally anchored proteins. *J Biol Chem* 1998; 273:5081.
17. Wang N, Butler JP, Ingber DE. Mechanotransduction across the cell surface and through the cytoskeleton. *Science* 1993; 260:1124.
18. Ingber DE, Dike L, Hansen L, et al. Cellular tensegrity: exploring how mechanical changes in the cytoskeleton regulate cell growth, migration, and tissue pattern during morphogenesis. *Int Rev Cytol* 1994; 150:173–224.
19. Vasioukhin V, Bauer C, Yin M, et al. Directed actin polymerization is the driving force for epithelial cell–cell adhesion. *Cell* 2000; 100:209.

20. Kirber MT, Walsh JV Jr., Singer JJ. Stretch activated ion channels in smooth muscle: a mechanism for the initiation of stretch-induced contraction. *Pflügers Arch* 1988; 412:339.
21. Sachs F. Mechanical transduction by membrane ion channels: a mini review. *Mol Cell Biochem* 1991; 104:57.
22. Nakayama K. Calcium-dependent contractile activation of cerebral artery produced by quick stretch. *Am J Physiol* 1982; 242:H760.
23. Ruoslahti E. Stretching is good for a cell. *Science* 1997; 76:1345.
24. Nishibe S, Wahl MI, Hernandez-Sotomayor SM, et al. Increase of the catalytic activity of phospholipase C-gamma 1 by tyrosine phosphorylation. *Science* 1990; 50:1253.
25. Seger R, Krebs EG. The MAPK signaling cascade. *FASEB J* 1995; 9:726.
26. Takei T, Rivas-Gotz C, Delling CA, et al. Effect of strain on human keratinocytes in vitro. *J Cell Physiol* 1997; 173:64.
27. Tenor H, Hatzelmann A, Wendel A, et al. Identification of phosphodiesterase IV activity and its cyclic adenosine monophosphate-dependent up-regulation in a human keratinocyte cell line (HaCaT). *J Invest Dermatol* 1995; 105:70.
28. Chien S, Li S, Shyy YJ. Effects of mechanical forces on signal transduction and gene expression in endothelial cells. *Hypertension* 1998; 31 (1 Pt 2):162.
29. Komuro I, Kaida T, Shibasaki Y, et al. Stretching cardiac myocytes stimulates protooncogene expression. *J Biol Chem* 1990; 265:3595.
30. Desai MM, Gill IS, Goel M, et al. Ureteral tissue balloon expansion for laparoscopic bladder augmentation: survival study. *J Endourol* 2003; 17:283–293.
31. Lailas NG, Cilento B, Atala A. Progressive ureteral dilation for subsequent ureterocystoplasty. *J Urol* 1996; 156:1151–1153.
32. Ikeguchi EF, Stifelman MD, Hensle TW. Ureteral tissue expansion for bladder augmentation. *J Urol* 1998; 159:1665–1668.
33. Liatsikos EN, Dinlenc CZ, Kapoor R, Bernardo NO, Smith AD. Tissue expansion: a promising trend for reconstruction in urology. *J Endourol* 2000; 14:93–96.
34. Bar-Sagi D, Feramisco JR. Induction of membrane ruffling and fluid-phase pinocytosis in quiescent fibroblasts by ras proteins. *Science* 1986; 233:1061.

M. Marberger and Y. K. Fong*Department of Urology, University of Vienna, Vienna, Austria*

- INTRODUCTION
- RADIOSURGERY
- MECHANICAL TISSUE TRIPSY
- THERMAL TISSUE ABLATION
 - High-Intensity Focused Ultrasound
 - Extracorporeal High-Intensity Focused Ultrasound Tissue Tripsy in Prostatic Disease

- Testis Tumors
- Renal Tumors
- SUMMARY
- REFERENCES

INTRODUCTION

An old dream of mankind foresees targeted tissue destruction within the body from an extracorporeal energy source with a no-touch technique, and no damage to surrounding structures. Rapidly developing technology now appears to be gradually moving this approach from science fiction to the doorsteps of clinical realm.

RADIOSURGERY

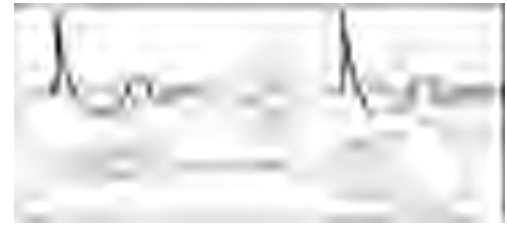Radiation destroys sensitive dividing cells by mitosis-linked death. High-energy external beam radiation affects tissues surrounding the target area with wide margins and even with modern planning techniques can therefore not be applied for truly focal tissue ablation in radiosensitive organs. Brachytherapy permits sharply defined ablation, but requires placing of the radioactive material within the target, and therefore does not constitute an extracorporeal technique. These problems are in part overcome by using stereotactic techniques to apply highly focused radiation. Pioneered in neurosurgery for the treatment of intracranial tumors, they exceed the scope of this treatise. A frameless image-guided radiosurgical device (Cyberknife) has recently been evaluated for focal renal ablation in a porcine model (1). The system combines a lightweight 6 mV linear accelerator mounted on a robotic arm with an image-to-image algorithm for target localization. An adequate conformal radiation dose is delivered by focusing a multitude of radiation beams at the target zone, yet directing the individual beams along different pathways so that the surrounding tissues are not exposed to a harmful dose. With a targeted dose of up to 40 Gy, complete fibrosis of the target zone was achieved without any apparent damage to surrounding structures (1).

MECHANICAL TISSUE TRIPSY

By forcing water through a small nozzle under high pressure at 10–50 kg/cm² parenchymatous tissue can be removed, whereas vessels >200 µm in diameter remain undamaged (2). This tissue skeletonization by water-jet facilitates subsequent hemostasis by electrocautery or suturing and is being utilized clinically, such as for partial hepatectomy or nephrectomy. Structures up to diameter of ~500 µm can be dissected by using probes generated to longitudinal and transverse oscillation of 200–300 µm by ultrasound in the 20–50 kHz range. By combining mechanical tissue fragmentation with thermal sealing of larger vessels with the heat generated during the tissue fragmentation process, ultrasound dissectors permit blood-free dissection of even heavily vascularized structures, and have become standard surgical equipment today (2–9). Both techniques, however, can only be utilized upon contact, and not by an extracorporeal approach.

The success with extracorporeal shock wave lithotripsy, and in particular analysis of its side effects on soft tissues (10), generated interest in using shock-wave energy

FIGURE 1 ■ Profile of extracorporeal shock wave as used for lithotripsy; the negative pressure phase results in cavitation bubble formation. Source: From Ref. 12.



A number of in vitro and in vivo experimental studies with the electromagnetic and electrohydraulic shock-wave sources used for lithotripsy have documented shock-wave-induced cellular damage in the focal area, but the microenvironments of the cells treated impact significantly on the shock-wave effect. If tumor cells in suspension are treated, the effect is significantly more pronounced than when the same type and number of cells are immobilized in gelatine.

In vivo studies on more complex in vivo models with implanted tumors have yet failed to define structured effects of shock waves as used in lithotripsy other than hemorrhage and signs of mechanical tissue dissipation.

for extracorporeal tissue ablation. The relatively weak acoustic shock waves used for lithotripsy exert both positive and negative pressures up to 100 and 10 Mpa, respectively (11). Especially, the latter are sufficient to cause cavitation from liquid failure at numerous sites near the focus. As the liquid fails, the vapor-filled cavities that are initially developed collapse with enormous force (Fig. 1). Asymmetric high-speed liquid microjets with velocities of 130–170 m/sec are generated at their surface, which are considered to be the primary mechanisms for stone disintegration and also for trauma to the soft tissue surrounding (3,13). Because of the high speed of the bubble breakdown there is virtually no temperature rise within the focus (14). Homolytic cleavage of molecules may also result in free radical formation, and this has been speculated to result in an additional focal tumoricidal effect (15,16).

A number of in vitro and in vivo experimental studies with the electromagnetic and electrohydraulic shock-wave sources used for lithotripsy have documented shock-wave-induced cellular damage in the focal area (17–19), but the microenvironments of the cells treated impact significantly on the shock-wave effect. If tumor cells in suspension are treated, the effect is significantly more pronounced than when the same type and number of cells are immobilized in gelatine (20–23).

Clearly, secondary physical effects such as microjet formations, blast effects, compressions, and tensile stress factors also play major roles in cellular damage. Similar studies have also shown a potentiating effect of shock waves on cytotoxic agents such as cisplatin, vinblastin, doxorubicin or 4-hydroperoxycyclophosphoride and cytokines (24–28). The effect diminishes rapidly after shock-wave exposure, suggesting transient increases in cell membrane permeability as a result of direct mechanical damage of cellular structures being the main mechanism involved. Clearly, single cell suspension models are simply insufficient to study cytotoxic shock-wave effects.

In vivo studies on more complex in vivo models with implanted tumors have yet failed to define structured effects of shock waves as used in lithotripsy other than hemorrhage and signs of mechanical tissue dissipation (18,28–31).

Tissue cavitation within the focal zone can be augmented by increasing the negative pressure of the shock wave, but more effectively by increasing the frequency of shock waves generated to more than 10 exposures per second (i.e., >10 Hz) (Fig. 2). By using ultrasound shock waves generated from piezoceramic elements mounted on a concave disk and focused to a joint focus (Fig. 3), both high frequencies and site intensities can be obtained, which result in immediate cellular disruption within the focus. This technique has been defined as “high-energy shock wave” tissue tripsy or “pyrotherapy” and has received considerable experimental and phase II clinical attention (32–35).

Vallancien's group (32) described an extracorporeal apparatus for in-depth tissue ablation based on this mechanism. The system is an adaptation of a lithotripter (PyrotechTM). The energy source consists of multiple transducer elements and has a focal length of 15 cm. The site intensity has been quoted to exceed 10,000 W/cm², but precise data are not available. A 3.5 MHz sectorial imaging transducer with a focal length of 14 cm is positioned in the center of the therapy elements. The focal area is 10 mm high × 2 mm wide for 50% power at –6 dB. The energy source head is positioned in a large bag of cavitation-free water below a waterproof membrane in the middle of a treatment bed (Fig. 3). During high-energy shock wave, the bubble formation with the focal zone increases progressively; these bubbles subsequently collapse rapidly. This rapid collapse compresses the gas inside the bubble without heat exchange with the surrounding tissue and results in a local temperature increase. Therefore, high-energy shock wave is considered to make use of both the mechanical and more limited, the thermal effects of ultrasound. This extracorporeal device has been tested under numerous experimental conditions, and preliminary human trials involving prostate, kidney, and bladder pathology have been reported.

^aEDAP, Vaulx en Velin, France.

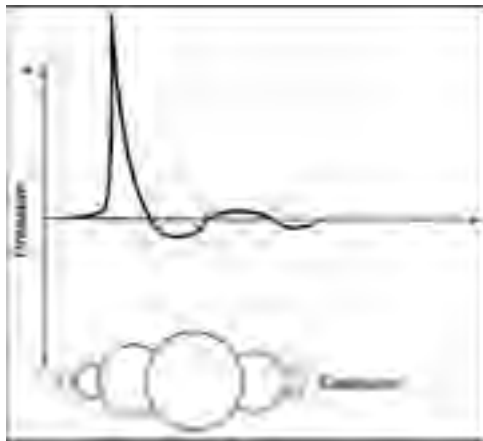


FIGURE 2 ■ Cavitation processes within the focal zone are augmented by increasing the negative pressure of the shock wave and by increasing shock wave generation beyond 10 HA, so that the next shock wave hits the focal zone before the cavitation bubbles generated by the previous shock wave have fully collapsed. Source: From Ref. 12.

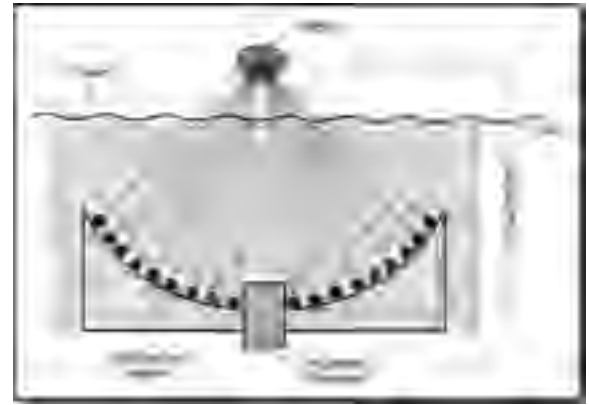


FIGURE 3 ■ Schematic depiction of system for extracorporeal high-energy tissue tripsy: ultrasound shock waves are generated at high frequency from multiple piezoceramic elements focused to a joint focus. A cushion filled with gas-free water serves for air-free coupling of the shock waves to the skin. Source: From Ref. 32.

Vallancien and colleagues (32) studied sequential histologic effects of high-energy shock wave on 110 kidneys of white landrace pigs. Immediately after treatment, a high area of congestion with hemorrhage and exudation was present. After 24 hours, coagulative necrosis appeared. On day 7, the target area was completely necrotic, and at day 90, fibrotic scarring was seen in the treated area. In humans, the histologic impact of extracorporeal ultrasonic tissue tripsy on renal tissue was also studied (33). Patients with renal cancer ($n = 5$), renal atrophy ($n = 2$), or complex stones ($n = 1$) were subjected to extracorporeal ultrasonic tissue tripsy prior to nephrectomy. The treated volume averaged 4 cm³, the mean number of shots was 195, and the skin–focal point distance averaged 68 mm. Immediately after the procedure, treated areas showed intense congestion with severe hyperemia and marked alterations of microcapillaries. The results were identical to those observed in the porcine kidney. After 48 hours, early signs of limited subcapsular necrosis with a persistent zone of hyperemia were detected. Side effects were moderate: two patients noticed skin burns, but otherwise, no significant adverse effects were seen. The high-energy shock wave method has also been applied to ablate prostatic tissue. Although intraprostatic coagulative necrosis was demonstrable, the transabdominal approach proved to be poorly suited because the bony pelvis shields the prostate. Vallancien and colleagues could target the prostate adequately in only 50% of cases.

The Pyrotech device has also been used to treat superficial bladder tumors. After an experimental study, a phase I/II clinical trial was initiated (34,35). In the first series, five patients with single recurrent superficial bladder tumor were treated immediately prior to transurethral resection. In all five cases, a change in the appearance of the tumor was noted. In two cases, the tumor was completely destroyed and histology showed coagulative necrosis. In a subsequent phase II trial, 20 patients with superficial bladder tumors were treated with this technique. Of these, 15 (75%) had normal urinary cytology results and cystoscopy at one month. In 67% of the patients with a primary tumor, there was no recurrence at one year; the remaining 33% developed recurrent tumors (35).

In phase II clinical studies with HESWL, no tumor progression or occurrence of metastases was observed during follow-up of 3–21 months (33,35). Nevertheless, the risk of cell dissemination appears to remain an inherent problem of tumor destruction based primarily on mechanical forces. Although some authors have specifically studied this aspect and observed no enhancement of tumor metastases (31,36,37), there remains a cause for concern for the clinical application of high-energy shock wave to treat malignant tumors. Moreover, systems with multiple transducers targeting a joint focal area have proven difficult to focus in clinical practice.

Although the majority of these studies yielded encouraging data, high-energy shock wave has not been introduced into broader clinical use for oncologic indications

Although the majority of these studies yielded encouraging data, high-energy shock wave has not been introduced into broader clinical use for oncologic indications to date. This is mainly attributable to insufficient tumor targeting and the fact that cell damage from high-energy shock wave is mediated primarily via the mechanical effects of ultrasound (i.e., tissue cavitation), which is difficult to target, control, and predict. Reliable destruction of deep lying tissues (a prerequisite for use in oncologic indications) is hard to achieve with current high-energy shock wave devices.

to date. This is mainly attributable to insufficient tumor targeting and the fact that cell damage from high-energy shock wave is mediated primarily via the mechanical effects of ultrasound (i.e., tissue cavitation), which is difficult to target, control, and predict. Reliable destruction of deep lying tissues (a prerequisite for use in oncologic indications) is hard to achieve with current high-energy shock wave devices.

THERMAL TISSUE ABLATION

Heating above 47°C results in protein degradation of tissues, with the extent of damage depending on the time of heat exposure and, to a lesser degree, the type of tissue and its structure. With heating >60°C, protein degradation of all biologic tissues becomes instantaneous, and irreversible coagulation necrosis of the targeted structure occurs. Temperatures beyond this range can be achieved in vivo using extracorporeal high-intensity focused ultrasound.

High-Intensity Focused Ultrasound

As an ultrasound wave propagates through biologic tissues, or any medium that is not ideally viscoelastic, it is progressively absorbed and the energy is converted to heat. If the ultrasound beam is brought to a tight focus at a selected depth within the body, the high energy density produced in this region results in temperatures exceeding the threshold level of protein denaturation. As a consequence coagulative necrosis occurs.

The antineoplastic effect of high-intensity focused ultrasound has been clearly demonstrated in vivo in a number of experimental settings.

These data demonstrate that high-intensity focused ultrasound applied extracorporeally is capable of inducing precise, well-controlled contact- and irradiation-free in-depth tissue destruction. However, it needs to be emphasized that none of these experimental studies were 100% successful.

As an ultrasound wave propagates through biologic tissues, or any medium that is not ideally viscoelastic, it is progressively absorbed and the energy is converted to heat. If the ultrasound beam is brought to a tight focus at a selected depth within the body, the high energy density produced in this region results in temperatures exceeding the threshold level of protein denaturation. As a consequence coagulative necrosis occurs.

The energy drops sharply outside the focal zone so that overlying and surrounding tissues remain unchanged. This creates an extremely sharp border between ablated and undamaged tissues. The size and location of the ablated region depend on the shape of the piezoceramic element and its respective focusing system, the ultrasound frequency and duration of insonication, the absorption coefficient of the incident tissues, and the site intensity achieved (12,38,39). In a defined biologic environment, the size of the thermal lesion can be controlled by the power and duration of the ultrasound pulse (40). With higher in situ intensities (>3500 W/cm³), cavitation phenomena with bubble implosion and mechanical tissue disruption are added, which are more difficult to control (41,42).

The antineoplastic effect of high-intensity focused ultrasound has been clearly demonstrated in vivo in a number of experimental settings.

Kishi and coworkers (43) reported on a significant reduction of implanted glioma tumors following high-intensity focused ultrasound-treatment using 1000 W/cm² for two seconds at a frequency of 0.944 MHz. Fry and Johnson (44) implanted hamster medulloblastoma cells in rats, which were subsequently treated by high-intensity focused ultrasound (900 W/cm², 1 MHz, seven seconds). The tumor cure rate was 29% in rats treated with high-intensity focused ultrasound and 40% in rats given a combination of high-intensity focused ultrasound and chemotherapy. Moore et al. (45) studied the effect of high-intensity focused ultrasound on the Morris 3924-A hepatoma implanted in rats. The tumor volumes in treated animals were substantially smaller than those in the untreated control group. However, although the entire tumor was included in the target zone, no tumor was completely destroyed. Chapelon and associates (46) reported on the effect of high-intensity focused ultrasound on the Dunning R3327 prostatic adenocarcinoma implanted in Copenhagen rats. In Study 2 of this series, 25 rats with AT2 subline implants were treated with an acoustic intensity of 820 W/cm². Complete tumor necrosis was achieved with this acoustic intensity in 24 cases (96%), and 16 lesions (64%) appeared to be cured, whereas all rats in the control group died of progressive tumor growth within 60 days of tumor implantation.

These data demonstrate that high-intensity focused ultrasound applied extracorporeally is capable of inducing precise, well-controlled contact- and irradiation-free in-depth tissue destruction. However, it needs to be emphasized that none of these experimental studies were 100% successful.

In all series, some local recurrences were seen or viable cells were identified within the target zone. The reason for this phenomenon is not fully understood; most likely, the efficacy of each high-intensity focused ultrasound shot might vary, and the penetration of the ultrasound beam into tissue could be reduced in certain circumstances, such as by tissue (micro)cavitation.

The potential use of high-intensity focused ultrasound for oncologic indications raises the important issue of whether such treatment hinders or accelerates the formation of distant metastases. In various studies, no evidence of increased rate of metastases has been reported (Table 1) (46–50). Chapelon and associates (46) determined the impact of high-intensity focused ultrasound on the development of metastases of

TABLE 1 ■ Rate of Metastases After in Vivo High-Intensity Focused Ultrasound of Experimental Tumors

Authors	Model	Rate of metastasis controls (%)	HIFU (%)
Goss and Fry (47)	Joshida sarcoma	43	26
Yang et al. (48)	Hepatoma 3924° in rats	21	4
Chapelon et al. (46)	Dunning R3327, prostate Ca, rats	28	16
Kaketa et al. (49)	Horie sarcoma rats	44	24
Oosterhof et al. (50)	T-6 Dunning R3327 prostate Ca, rats	25	23

Abbreviation: HIFU, high-intensity focused ultrasound.

experimental prostate cancer. In the control population 28% of the animals developed distant metastases, whereas in the high-intensity focused ultrasound-treated animals this percentage dropped to 16%. Similar findings were reported by Oosterhof and colleagues (50) using a T-6 Dunning R3327 rat prostate cancer subline, which was implanted in the hind limb of Fisher–Copenhagen rats. Metastases were seen in 23% of the high-intensity focused ultrasound-treated animals compared with 25% of the sham-treated animals. From these data, it can be concluded that high-intensity focused ultrasound applied to cancer tissues does not accelerate the development of distant metastases; indeed, numerous studies suggest that high-intensity focused ultrasound treatment reduces the rate of metastases (Table 1). As a result, high-intensity focused ultrasound has received considerable experimental and clinical attention.

Extracorporeal High-Intensity Focused Ultrasound Tissue Tripsy in Prostatic Disease

All systems presently used for therapeutic high-intensity focused ultrasound for urologic indications have a single transducer, which is focused either by having a concave shape or with acoustic lenses. The former are smaller and therefore have mainly been utilized for intracavitary use, such as transrectal high-intensity focused ultrasound of prostate cancer. As the focal lengths thus needed are smaller, frequencies in the 3–4 MHz range can be used. They produce small but very precisely defined lesions. Larger areas are ablated by moving the transducer electronically and adding one lesion to another (Fig. 4).

The approach was first used clinically to ablate the transition zone in obstructive benign prostatic enlargement. Although both experimental and phase II clinical studies showed high-intensity focused ultrasound for benign prostatic enlargement to be safe and minimally invasive, long-term results were disappointing (51–57). In spite of treatment times in spinal anesthesia of around 60 minutes, tissue ablation with larger median lobes or calcification was frequently insufficient. Obstruction at the bladder neck was often not permanently eliminated because of the development of scar tissue, and the treatment result was poorly predictable in the individual patient.

Gelet et al. (41) pioneered the use of transrectal high-intensity focused ultrasound for the treatment of localized prostate cancer.

Gelet et al. pioneered the use of transrectal high-intensity focused ultrasound for the treatment of localized prostate cancer.

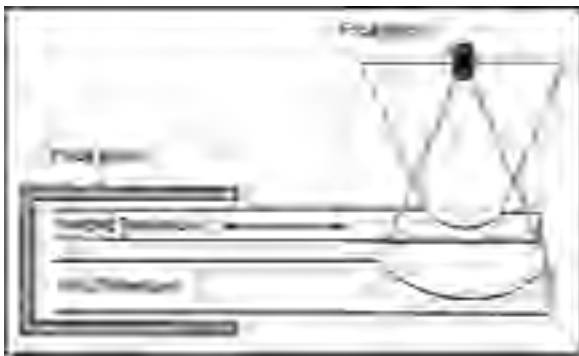


FIGURE 4 ■ System for transrectal high-intensity focused ultrasound: separate transducers for imaging and therapy incorporated in a joint transrectal probe are used intermittently (Ablatherm™, EDAP, Paris, France). *Source:* From Ref. 12.

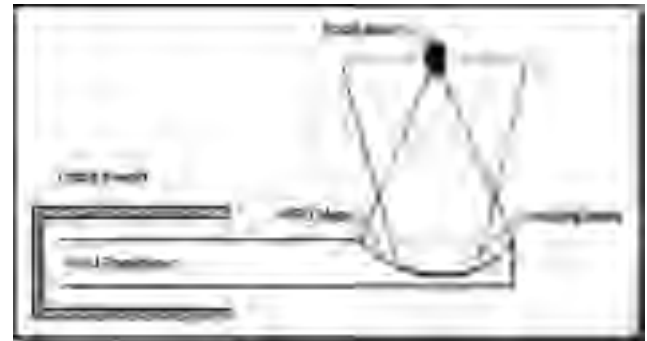


FIGURE 5 ■ System for transrectal HIFU: the same transducer operating at 4.0 MHz is used for imaging and therapy (Sonoblade™, Focus Surgery, Indianapolis, Indiana). *Source:* From Ref. 12.

Using a system that utilized a 2.25 MHz therapeutic transducer and a 7.5 MHz probe that was advanced intermittently for imaging (Fig. 4), Gelet et al. (58) treated patients in spinal or general anesthesia in the lateral decubital position. Rectal burns and unreliable tissue destruction in borderline target zones in early series could be overcome by raising the treatment frequency to 3.0 MHz (41,58–60). Therapeutic complete high-intensity focused ultrasound ablation of the entire prostate requires long treatment times in regional anesthesia, and is particularly difficult to achieve in the anterior segments of larger prostates. In a prospective study, Madersbacher et al. (40) attempted targeted ablation of localized cancers as defined by hypoechoic ultrasonographic appearance and selective biopsy. They used a system where the central zone of 4 MHz transducer used for high-intensity focused ultrasound therapy is also utilized for imaging (Fig. 5). In 10 patients whose prostates were removed prospectively after high-intensity focused ultrasound, residual cancers were demonstrated in seven patients in other areas, proving that complete ablation of the prostate is needed for curative treatment. The study also showed that the lesion grew towards the probe, i.e., towards the rectum, rendering it difficult to ablate tissue anterior to the urethra.

By restricting high-intensity focused ultrasound ablation to localized cancer in prostates <40 mL in volume and utilizing the intrarectal balloon to flatten the prostate by compression, the anterior segment is better reached. Four hundred and two patients were treated in this manner in a phase II/III study (62). Although 27.9% of patients required two treatment sessions, an overall 87.2% of 288 patients had negative biopsies at follow-up and a median prostate specific antigen nadir of 0.4 ng/mL was achieved with a minimum follow-up of six months (62). Thüroff and Chaussy (63) circumvent the problem of prolonged catheterization by combining high-intensity focused ultrasound with transurethral resection of the transition zone during the same session. In 232 patients with clinically organ-confined prostate cancer, follow-up biopsies were negative in 84% of patients and prostate specific antigen remained stable in 83% of patients with a median follow-up of 27 weeks. Nevertheless, the need to retreat in 7.7% of patients already with this short follow-up and treatment times in anesthesia of >2 hours clearly show the need for improvement of the technique before this can be considered standard treatment. Improved lesioning by more rapid study cycles, longer focal length ultrasound transducers, and ideally phased array transducers with variable focal length and monitoring of the treatment effect by on-line magnetic resonance imaging thermometry (64–66) may be feasible solutions to these problems in the near future. Better patient selection may likewise be a key for improving results. High-intensity focused ultrasound may be most beneficial in patients with local recurrence after radiation failure (67). Finally, experimental data suggest that high-intensity focused ultrasound may promote tumor immune response even with sublethal treatment and enhance other systemic treatment approaches, such as in vivo gene transfer (68,69).

Testis Tumors

The testicle appears as an ideal organ for extracorporeal high-intensity focused ultrasound as it is easily accessible, even for transducers with short focal lengths, with almost no interfering acoustical interphases, and because ultrasonography permits superb visualization of testicular tumors. Clearly, a unilateral testicular tumor in the presence of a normal contralateral testicle would always be treated by orchiectomy. About 2% of all malignant testicular tumors are bilateral, either synchronous or metachronous. To avoid anorchia organ sparing tumor excision and subsequent irradiation of the residual testis with 16–20 Gy to eradicate Ca in situ is usually considered the therapy of choice (70). Although the recurrence rate is <6% with this approach, ~20% of the patients ultimately lose the testis and need permanent androgen replacement therapy (70).

Using a high-intensity focused ultrasound system originally developed for transrectal high-intensity focused ultrasound, Madersbacher et al. exposed four patients with metastatic prostate cancer to transcutaneous high-intensity focused ultrasound prior to orchiectomy. The scrotum was submerged in saline, the testicle immobilized with a sling around the base of the scrotum, and target lesions within the testicle of 8 × 8 mm ablated at a frequency of 4.0 MHz and site intensity of 1680 W/cm². Histology showed definite signs of necrosis, with detachment of the germinal epithelium, shrinkage of nuclei and cell disintegration in the target zone, and targeted lesion and obtained lesion corresponding in size and location (71).

A clinical phase II study in patients with tumors in the solitary testis in whom the contralateral testis had been removed for a malignant tumor demonstrated the possibility of cure with high-intensity focused ultrasound and postoperative irradiation (71).

A clinical phase II study in patients with tumors in the solitary testis in whom the contralateral testis had been removed for a malignant tumor demonstrated the possibility of cure with high-intensity focused ultrasound and postoperative irradiation.

In the meantime, seven patients with tumors in a solitary testis were treated in this manner, with a mean follow-up of 42 months and follow-up over five years in four patients (61). The only patient to develop a recurrent tumor in the series refused postoperative irradiation. This testicle was removed and histology showed the recurrent tumor to be an embryonal carcinoma in a different location, with the high-intensity focused ultrasound-treated area tumor free. All other patients remain tumor free, with normal levels of serum testosterone and no need for androgen replacement (61).

Renal Tumors

Up to two-thirds of kidney tumors diagnosed today are detected incidentally in asymptomatic patients, and up to half have a diameter of <3 cm. Their tendency to grow is usually low and up to 14% may actually be benign (72–75). As they are also frequently detected in elderly patients with significant comorbidity, there is a material interest in less invasive treatment modalities than the standard surgical procedures. Well over a third of these are in a peripheral, exophytic location that render them well discernible by ultrasonography and accessible to an energy ablative approach.

Percutaneous techniques using either cryoablation or thermal coagulation are widely employed for this today but the need to puncture the tumor with the potential risk of hemorrhage and tumor spillage raises some caveats. Transrectal high-intensity focused ultrasound systems operating in the 4MHz range have been modified for laparoscopic use.

In porcine kidneys they permit reproducible partial kidney ablation with no damage to surrounding structures (76), especially when fitted with an integrated 6.5 MHz imaging transducer. For extracorporeal high-intensity focused ultrasound ablation, however, penetration at this frequency is too short, even in small laboratory animals (77). In the 1–1.5 MHz frequency range, the penetration of the transducer increases and the focal zone becomes more cigar shaped. Chapelon et al. (78) and Watkin et al. (79) were able to obtain significant renal lesions with an extracorporeal approach in vitro and in vivo in large animals with experimental systems of this type, but targeting proved difficult and skin burns occurred frequently. Two recent developments seem to have overcome these problems and have revived clinical interest in extracorporeal high-intensity focused ultrasound of renal tumors: the Storz Medical and the Chongqing devices for extracorporeal high-intensity focused ultrasound.

The Storz Medical extracorporeal high-intensity focused ultrasound system^b consists of a cylindrical piezoceramic element generating ultrasound waves of 1 MHz, which are focused at a depth of 10 cm with a parabolic reflector (Fig. 6). A 3.5 MHz ultrasonic transducer is integrated centrally for in-line imaging of the focal area. Ultrasound waves are coupled into the body through a flexible polyurethane cushion filled with degassed water. Electrical power can be increased up to 1.8 kW. The focal zone ($p_{\max}/2$) has an ellipsoidal shape of approximately 12×3 mm in biologic tissues. At 400 W power and penetration through 10 cm of porcine muscle in vitro, this provides calculated site intensities of 1430 W/cm^2 . In porcine kidneys, insonicated ex vivo reproducible lesions of coagulative necrosis with central areas of liquefaction were obtained, with the size correlating to pulse duration and power (80). Köhrmann et al. (81) tested the system in vivo on the renal parenchyma of kidneys removed for nononcological reasons and observed similar lesions of irreversible tissue damage.

In a curative attempt in vivo in a patient with three tumors in a solitary kidney, two were completely ablated by extracorporeal high-intensity focused ultrasound, with a follow-up of six months (81).

This prototype has been available at the Department of Urology, University of Vienna, Medical School, for phase II clinical testing since April 2001 (89). 16 kidney tumors in 16 patients were insonicated extracorporeally. The procedure was always performed in general anesthesia, with attempts to reduce respiratory movement of the kidney by briefly stopping ventilation during insonication. As the treatment procedure is evolving, the treatment parameters varied over time, with electrical power being raised up to 1.8 kW, pulse durations of four or six seconds, and up to 70 pulses administered. The system was also changed technically by increasing the diameter of the reflector from 100–144 mm and changing its aperture from 64° to 84° , reducing its focal length from 10–8 cm, and most notably, by adding a mechanical arm directing the applicator.

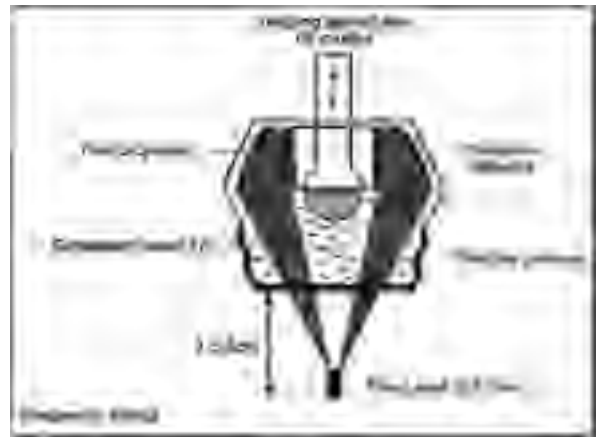
In two elderly patients, each with a small tumor, the same procedure was performed with curative intent and the entire tumor was treated with 70 pulses of six

Percutaneous techniques using either cryoablation or thermal coagulation are widely employed for this today but the need to puncture the tumor with the potential risk of hemorrhage and tumor spillage raises some caveats. Transrectal high-intensity focused ultrasound systems operating in the 4MHz range have been modified for laparoscopic use.

In a curative attempt in vivo in a patient with three tumors in a solitary kidney, two were completely ablated by extracorporeal high-intensity focused ultrasound, with a follow-up of six months.

^bStorz Medical System, Kreuzlingen, Switzerland.

FIGURE 6 ■ Schematic drawing of treatment arm of Storz™ system for extracorporeal high-intensity focused ultrasound. A cylindrical transducer generating ultrasound at 1 MHz is focused with an acoustical lens to a focus 3×12 mm in situ; a flexible cushion filled with degassed water permits a variable focal length of 3.5–8 cm and an integrated B-mode transducer provides imaging of the target area. Source: From Ref. 80.




seconds duration at 1.8 kW. Follow-up magnetic resonance imagings showed some shrinkage of the tumor in one patient, but no complete radiological remission. In the other patients only a lesion of 10×10 mm was targeted in the tumor. The tumors were then removed in the same anesthesia with the standard surgical procedure. Some erythema of the skin were noted in the five patients subjected to the highest doses, but never skin burns. At surgery, all structures appeared normal and specifically no alterations were noted on the surface of the kidney. Macroscopically limited zones of bluish discoloration and focal hemorrhage were seen in the targeted zone in five kidneys. Histological changes suggestive of acute tissue necrosis (82) were detected in the nine tumors that had been subjected to the highest U.S. dose. They only comprised 15–35% of the area targeted, and were considerably smaller than lesions observed with similar energy settings in normal renal parenchyma or experimental studies (80). Nevertheless, the changes were only observed within the targeted area, and surrounding structures always appeared normal.

In the Chongqing “high-intensity focused ultrasound” extracorporeal device^c, exchangeable ellipsoidal therapeutic transducers of 12 or 15 cm diameter are mounted around a central 3.5 MHz diagnostic transducer and positioned within a basin filled with degassed water under the patient table. Depending on the transducer used, frequencies of 0.8, 1.2, and 1.6 MHz, and focal lengths of 100, 130, 135, 150, and 160 mm are available. The in vivo focal region for the 1.6 MHz transducer was calculated at 3.3×1.1 mm, with only minor differences for the other transducers. In situ intensities are estimated as ranging between 5.000–20.000 W/cm² (83). Ablation can be achieved by placing individual lesions side by side as with all other systems, but the device also has the capacity to achieve more rapid ablation through “painting out” the target area in sequential linear tracks. Smooth, three-dimensional movement of the activated transducer enables this process, and by exposing the same target area 2–6 times, the volume of ablated tissue increases in a linear fashion (Fig. 7) (83). At these energy levels cavitation processes are clearly also involved, but detailed experimental and clinical studies provided no evidence for tumor cell dissemination (88). Because of the high in situ intensities used, treated tissues become hyperechoic on ultrasonography and this effect is used for on-line targeting and feedback. Wu et al. (84) have employed this system for the treatment of 1038 patients with malignant tumors, mainly of the liver, breast, and soft tissues. In spite of large-volume ablations and reportedly good tumor control, side effects were low, and mainly consisted of fever in up to 20% and skin burns in 5% of the patients. The authors also mention treating 27 patients with renal tumors, and in a more recent report they give details of a subgroup of 13 patients with tumors 2–15 cm in diameter. Patients were treated in anesthesia with a 0.8 MHz transducer with a focal length of 135 mm, at a scanning speed of 2–5 mm and track length of 20–40 mm. At a median treatment time of 5.4 hours and a median 1.3 sessions per patient, the tumors were completely ablated in three patients and between 40% and 70% in the rest (85).

A similar system was installed at the Churchill Hospital, Oxford, United Kingdom in May 2002 and has been in use in phase II clinical trials since November 2002. Sixteen patients have been treated in phase II clinical trials, four with renal tumors, and the remaining 12 with liver tumors (88). All patients have been treated under general anesthesia, and respiratory movement is minimized by selective intubation, with ventilation of only the contralateral lung during ultrasound exposures. Acoustic powers of 180–300 W have been

^cChongqing HAIFU, Chongqing, China.

FIGURE 7 ■ Schematic depiction of the treatment principle involved in the Chongqing HAIFU system: The target is dissolved into multiple two-dimensional ultrasound slices at 5–10 mm interval, which in sum establish a three-dimensional image of the target. With directional movement of the transducer, each slice is treated, and the effect is monitored by immediate reimaging thereafter. Source: From Ref. 83.



used, and the most common exposure regime has been the placement of single lesions adjacent to one another (with an overlap of half the transverse diameter of the focus). Maximum transverse diameters of the target renal tumors have ranged from 2.5–5.4 cm, and according to the trial protocol, only a proportion of each renal tumor was exposed to high-intensity focused ultrasound. Estimated treated volumes range from 4.0–8.0 cm³. No skin burns were seen despite the high exposure powers, and the most significant adverse event reported has been a transient bruising sensation. Magnetic resonance and color Doppler imaging after two weeks provided an early indication of the treatment outcome, and following an interval of approximately six weeks post-high-intensity focused ultrasound, three of the four patients with renal tumors progressed to surgery.

At the time of high-intensity focused ultrasound treatment, the hyperechoic changes on ultrasonography, which are characteristic of successful ablation, were not seen in any of the treatments despite the very high acoustic powers used. A small region of reduced contrast uptake on magnetic resonance imaging in one patient, and reduced perfusion color Doppler sonography in another patient indicated a possible volume of ablation. Unfortunately, these regions could not be identified confidently on histological examination, and other than some adherent Gerota's fascia and fat necrosis in the perinephric fat, no conclusive evidence of successful ablation has been found in the other three excised renal tumors. However, the sample size is too small to draw meaningful conclusions and results have been considerably more encouraging in the treated liver tumors. Treatment parameters will be adjusted as the trial progresses, and if consistent ablation continues to prove difficult, the combination approach of embolization plus high-intensity focused ultrasound as employed in China (83) will be explored.

The process of developing a thermal lesion by high-intensity focused ultrasound in vivo, over sound propagation and absorption to heat generation, conduction and adequate temperature distribution, is subject to a multitude of variables. These are especially difficult to control with high-intensity focused ultrasound of renal tumors.

Respiratory movement has been proven a major problem. Even with controlled ventilation placing one small lesion precisely next to the other has proven virtually impossible. Automated coordination between insonication and ventilation and "painting" the lesion with continuous insonication rather than placing one lesion next to another may further improve this.

Acoustic interphases result in absorption and reflection phenomena and therefore significantly impact the site and size of the lesion. In high-intensity focused ultrasound of renal tumors overlying ribs present a major challenge. Although they only marginally influence focal position, high-intensity focused ultrasound beam and peak intensity are impacted significantly, and with direct insonication the rib may even be damaged. The use of wider apertures of the beam, directing it through the intercostal spaces, dose adjustments, and perhaps even shielding of sensitive areas with acoustic absorbers should solve the problem (86). More difficult to compensate for are acoustic interphases within the kidney, and specifically within the tumor. Structural inhomogeneity may be pronounced even in small tumors, yet is difficult to define at the time of treatment. This is obviously also the main reason for the less consistent lesioning in renal tumors than in normal renal

The process of developing a thermal lesion by high-intensity focused ultrasound in vivo, over sound propagation and absorption to heat generation, conduction and adequate temperature distribution, is subject to a multitude of variables. These are especially difficult to control with high-intensity focused ultrasound of renal tumors.

parenchyma. This mainly impacts on lesion size (87, 88). Higher site intensities, obtained by either increasing power input, longer pulse duration, retreating the same area repeatedly or by combining these parameter modifications, appear as the most obvious solutions. Ideally, the problems could be overcome with the availability of a reliable method for assessing tissue necrosis at the time of high-intensity focused ultrasound application so that the dosage can be adapted individually. Hyperechogenic changes on gray-scale ultrasonography signalize a high-intensity focused ultrasound effect at this point, but not necessarily complete necrosis. Presently, this can only be monitored on-line by extremely complex rapid magnetic resonance imaging thermometry (88), which appears nonfeasible in a clinical setting at the time. Given current progress in ultrasound densitometry of microperfusion changes, new options may rapidly appear on the horizon. Until then the only practical solution lies in ongoing phase II clinical studies as reported herein.

SUMMARY

- Although the majority of the reported studies yielded encouraging data, high-intensity focused ultrasound has not been introduced into broader clinical use for oncologic indications to date. In fact, tumor targeting is insufficient and cell damage from high-intensity focused ultrasound is difficult to target, control, and predict with current high-intensity focused ultrasound devices.
- The antineoplastic effect of high-intensity focused ultrasound has been clearly demonstrated in vivo in a number of experimental settings. high-intensity focused ultrasound applied extracorporeally is capable of inducing precise, well-controlled contact- and irradiation-free in-depth tissue destruction. However, it needs to be emphasized that none of these experimental studies were 100% successful.
- Compared to high-intensity focused ultrasound ablation of lesions in the liver, breast, prostate, and testes extracorporeal high-intensity focused ultrasound ablation of renal tumors is certainly more challenging. Promising results from other centers in China using the Chongqing "HAIFU" device give cause for optimism, but our own results show that it must definitely be categorized as experimental at present. Nevertheless, as early clinical experience with ESWL of urolithiasis has shown, relatively minor technical improvements may suddenly bring the clinical breakthrough.

REFERENCES

1. Ponsky LE, Crownover RL, Rosen MJ, et al. Initial evaluation of Cyberknife technology for extracorporeal renal tissue ablation. *Urology* 2003; 61:498–501.
2. Krawitt DR, Addonizio JC. Ultrasonic aspiration of prostate and bladder tumors and stones. *Urology* 1987; 30:579–742.
3. Papchristou DN, Bartens R. Resection of the liver with a water jet. *Br J Surg* 1982; 69:93–94.
4. Higashihara E. Mechanical energy in urology for non-lithiasis treatment. In: Marberger M, ed. *Application of newer forms of therapeutic energy in urology*. Oxford: Isis Medical, 1995:1–13.
5. Basting RF, Djakovic N, Widmann P. Use of water jet resection in organ-sparing kidney surgery. *J Endourol* 2000; 14:501–505.
6. Chopp RT, Shah BB, Adonizio JC. Use of ultrasonic surgical aspirator in renal surgery. *Urology* 1983; 22:157–159.
7. Hodgson WJ, Del Guercio LRM. Preliminary experience in liver surgery using the ultrasonic scalpel. *Surgery* 1984; 2:230–234.
8. Gill BS, MacFadyen BV Jr. Ultrasonic dissectors and minimally invasive surgery. *Semin Laparosc Surg* 1999; 6:229–234.
9. Schmidbauer S, Hallfeldt KK, Sitzmann G, Kantelhardt T, Trupka A. Experience with ultrasound scissors and blades (UltraCision) in open and laparoscopic liver resection. *Ann Surg* 2002; 235:27–30.
10. Lingeman JE, Mc Ateer JA, Kempson SA, et al. Bioeffects of extracorporeal shock-wave lithotripsy. *Urol Clin North Am* 1988; 15:507–514.
11. Coleman AJ, Saunders JE. A survey of the acoustic output of commercial extracorporeal shock-wave lithotripsy. *Ultrasound Med Biol* 1989; 15:213–227.
12. Madersbacher S, Marberger M. Therapeutic applications of ultrasound in urology. In: Marberger M, ed. *Application of newer forms of therapeutic energy in urology*. Oxford: ISIS, 1995:115–136.
13. Crum LA. Cavitation microjets as a contributory mechanisms for renal calculi disintegration in shock-wave. *J Urol* 1988; 140:1587–1590.
14. Filipczynski L, Wojcik KS. The estimation of transient temperature elevation in lithotripsy and in ultrasonography. *Ultrasound Med Biol* 1991; 17:715–721.
15. Suhr D, Bruemmer F, Huelser DF. Cavitation generated free radicals during shock-wave exposure: investigators with cell-free solutions and suspended cells. *Ultrasound Med Biol* 1991; 17:761–768.
16. Morgan TR, Laudone VP, Heston WDW, et al. Free radical production by high energy shock waves—comparison with ionizing irradiation. *J Urol* 1988; 139:186–189.
17. Russo P, Stephenso RA, Mies C, et al. High energy shock waves suppress tumor growth in vitro and in vivo. *J Urol* 1986; 135:626–628.
18. Randazzo RF, Chaussy CG, Fuchs GJ, et al. The in vitro and in vivo effects of extracorporeal shock-wave on malignant cells. *Urol Res* 1988; 16:413–426.

19. VanDongen JW, VanSteenbrugge GJ, Romijn JC, Schroeder FH. The cytotoxic effect of high energy shock waves on human prostatic tumor cell lines. *Eur J Cancer Clin Oncol* 1989; 25:1173–1179.
20. Kohri K, Vemura T, Iguchi M, et al. Effect of high energy shock-waves on tumor cells. *Urol Res* 1990; 18:101–105.
21. Smits GAH, Oosterhof GON, Ruyter AE, et al. Cytotoxic effects of high energy shock-waves in different in vitro models: influence of the experimental set-up. *J Urol* 1991; 145:171–175.
22. Brummer F, Brenner J, Brauner T, et al. Effect of shock-waves on suspended and immobilized LI220 cells. *Ultrasound Med Biol* 1989; 15:229–239.
23. Gambihler S, Delius M, Brendel W. Biological effect of shock waves: cell disruption, vitality and proliferation of LI210 cells exposed to shock waves in vitro. *Ultrasound Med Biol* 1990; 16:587–594.
24. Prat F, Sibille A, Luccioni C, et al. Increased chemotoxicity to colon cancer cells by shock-wave induced cavitation. *Gastroenterology* 1994; 106:937–944.
25. Woerle K, Steinbach P, Hofstadter F. The combined effects of high-energy shock waves and cytostatic drugs or cytokines on human bladder cancer cells. *Br J Cancer* 1994; 69:58–65.
26. Gambihler S, Delius M. In vitro interaction of lithotripter shock-waves and cytotoxic drugs. *Br J Cancer* 1992; 66:69–73.
27. Maruyama M, Asano T, Nakagohri T, et al. Application of high energy shock waves to cancer treatment in combination with cisplatin and ATX-70. *Anticancer Res* 1999; 19:1989–1993.
28. Cornel EB, Oosterwijk E, Van de Streek JD, et al. High energy shock waves induced increase in the local concentration of systemically given TNF-alpha. *J Urol* 1994; 152:2164–2166.
29. Russo P, Mies C, Huryk R, et al. Histopathologic and ultrastructural correlations of tumor growth suppression by high energy shock-waves. *J Urol* 1987; 137:338–341.
30. Oosterhof GON, Smits GA, De Ruyter AE, Schalken JA, Debruyne FM. Effects of high-energy shock-waves combined with biological response modifiers in different human kidney cancer xenografts. *Ultrasound Med Biol* 1991; 17:391–399.
31. Hoshi S, Orikasa S, Kuwahara M, et al. High energy underwater shock wave treatment on implanted urinary bladder cancer in rabbits. *J Urol* 1991; 146:439–443.
32. Vallancien G, Chartier-Kastler E, Chopin D, Veillon B, Brisset JM, Andre-Bougaran J. Focused extracorporeal pyrotherapy: experimental results. *Eur Urol* 1991; 20:211–219.
33. Vallancien G, Harouni M, Veillon B, et al. Focused extracorporeal pyrotherapy: feasibility study in man. *J Endourol* 1992; 6:173–181.
34. Chartier-Kastler E, Chopin D, Vallancien G. The effects of focused extracorporeal pyrotherapy on a human bladder tumor line (647V). *J Urol* 1993; 149:643–647.
35. Vallancien G, Harouni M, Giullonneau B, Veillon B, Bougaran J. Ablation of superficial bladder tumors with focused extracorporeal pyrotherapy. *Urology* 1996; 47:204–207.
36. Holmes RP, Yeaman LI, LI WJ, et al. The combined effects of shock waves and cisplatin on rat prostate tumors. *J Urol* 1990; 144:159–163.
37. Gamarra F, Naegele M, Lumper W, et al. Acute effect of shock waves on tumors assessed by magnetic resonance imaging. Possible role of blood flow reduction. *Invest Radiol* 1993; 28:611–618.
38. Fry FJ. Intense focused ultrasound in urology. *Eur Urol* 1993; 23(suppl 1):2–7.
39. Ter Haar GR, Robertson G. Tissue destruction with focused ultrasound in vivo. *Eur Urol* 1993; 23:8–11.
40. Madersbacher S, Pedevilla M, Vingers L, Susani M, Marberger M. Effect of high-intensity focused ultrasound on human prostate cancer in vivo. *Cancer Res* 1995; 55:3346–3351.
41. Gelet A, Chapelon JY. Effects of high-intensity focused ultrasound on malignant cells and tissues. In: Marberger M, ed. *Application of newer forms of therapeutic energy in urology*. Oxford: ISIS, 1995:107–114.
42. Lacoste F, Schlosser J, Vallancien G. The benefit of electronic scanning in extracorporeal HIFU. In: Andrew MA, Crum LA, Vaezy S, eds. *Proceedings, 2nd international symposium on therapeutic ultrasound*. Seattle: University of Washington, 2003:314–322.
43. Kishi M, Mishima T, Itakura T. Experimental studies of effects of intense ultrasound on implantable murine glioma. In: Kazner E, deVlieger M, Muller HR, McCready VR, eds. *Proceeding of 2nd European congress on ultrasonics medium*. Amsterdam: Excerpta Medica, 1975:28–33.
44. Fry FJ, Johnson LK. Tumor irradiation with intense ultrasound. *Ultrasound Med Biol* 1978; 4:337–341.
45. Moore WE, Lopez RM, Matthews DE, et al. Evaluation of high intensity therapeutic ultrasound irradiation in the treatment of experimental hepatoma. *J Pediatr Surg* 1989; 24:30–33.
46. Chapelon JY, Margonari J, Vernier F, Gorry F, Eccocharde R, Gelet A. In vivo effects of high-intensity ultrasound on prostatic adenocarcinoma Dunning R3327. *Cancer Res* 1992; 52:6353–6357.
47. Goss SA, Fry FJ. The effect of high intensity ultrasonic irradiation on tumor growth. *IEEE Trans Sonics Ultrason* 1984; 31:491–496.
48. Yang R, Reilly CR, Rescoria FJ, et al. High-intensity focused ultrasound in the treatment of experimental liver cancer. *Arch Surg* 1991; 126:1002–1009.
49. Kaketa K, Wagai T, Mizuno S, et al. Medical application of intense ultrasound, III: destruction of malignant tumor by intense focused ultrasound. In: *Annual report (1970) of the Medical Ultrasonics Research Center*. Tokyo, Japan: Juntendo University School of Medicine, 1971:35–39.
50. Oosterhof GO, Cornel EB, Smith GA, Debruyne FM, Schalken JA. Influence of high-intensity focused ultrasound on the development of metastases. *Eur Urol* 1997; 32:91–95.
51. Foster RS, Bihrl R, Sanghvi NT, et al. Production of prostatic lesions in canines using transrectally administered high-intensity focused ultrasound. *Eur Urol* 1993; 23:330–336.
52. Madersbacher S, Kratzik C, Szabo N, Susani M, Vingers L, Marberger M. Tissue ablation in benign prostatic hyperplasia with high-intensity focused ultrasound. *Eur Urol* 1993; 23(suppl 1):39–43.
53. Madersbacher S, Kratzik C, Susani M, Marberger M. Tissue ablation in benign prostatic hyperplasia with high intensity focused ultrasound. *J Urol* 1994; 152:1956–1961.
54. Bihrl R, Foster RS, Sanghvi NT, Donohue JP, Hood PJ. High intensity focused ultrasound for the treatment of BPH: early U.S. clinical experience. *J Urol* 1994; 151:1271–1275.
55. Uchida T, Yokoyama E, Iwamura M, et al. High intensity focused ultrasound for benign prostatic hypertrophy. *Int J Urol* 1995; 2:181–185.

56. Sanghvi NT, Foster RS, Bihle R, et al. Noninvasive surgery of prostate tissue by high intensity focused ultrasound: an updated report. *Eur J Ultrasound* 1999; 9:19–29.
57. Madersbacher S, Schatzl G, Djavan B, Stulnig T, Marberger M. Long-term outcome of transrectal high-intensity focused ultrasound therapy for benign prostatic hyperplasia. *Eur Urol* 2000; 37:687–694.
58. Gelet A, Chapelon JY, Bouvier R, et al. Treatment of prostate cancer with transrectal focused ultrasound: early clinical experience. *Eur Urol* 1996; 29:174–183.
59. Gelet A, Chapelon JY, Bouvier R, Pangaud C, Lasne Y. Local control of prostate cancer by transrectal high intensity focused ultrasound therapy: preliminary results. *J Urol* 1999; 161:156–162.
60. Gelet A, Chapelon JY, Bouvier R, Rouviere O, Lyonnet D, Dubernard JM. Transrectal high intensity focused ultrasound for the treatment of localized prostate cancer: factors influencing outcome. *Eur Urol* 2001; 40:124–129.
61. Kratzik C, Schatzl G, Lackner J, Marberger M. Transcutaneous high-intensity focused ultrasound can cure testicular cancer. *Urology* 2006; 67:1269–1273.
62. Thuroff S, Chaussy C, Vallancien G, et al. High-intensity focused ultrasound and localized prostate cancer: efficacy results from the European multicentric study. *J Endourol* 2003; 17:673–677.
63. Thuroff S, Chaussy C. The impact of the energy dose of transrectal high-intensity focused ultrasound for the treatment of prostatic cancer. *J Urol* 2004; 171(suppl 1):271.
64. Chauhan S, Lowe MJ, Davies BL. A multiple focused probe approach for high intensity focused ultrasound based surgery. *Ultrasonics* 2001; 39:33–44.
65. Sokka SD, Hynynen KH. The feasibility of MRI-guided whole prostate ablation with a linear aperiodic intracavitary ultrasound phased array. *Phys Med Biol* 2000; 45:3373–3383.
66. Lizzi FL, Muratore R, Deng CX, et al. Radiation-force technique to monitor lesions during ultrasonic therapy. *Ultrasound Med* 2003; 29:1593–1605.
67. Gelet A, Chapelon JY, Poissonnier L, et al. Local recurrence of prostate cancer after external beam radiotherapy: early experience of salvage therapy using high-intensity focused ultrasonography. *Urology* 2004; 63:625–629.
68. Kramer G, Steiner GE, Gröbl M, et al. Response to sublethal heat treatment of prostatic tumor cells and of prostatic tumor infiltrating T cells. *Prostate* 2004; 58:109–120.
69. Huber PE, Pfisterer R. In vitro and in vivo transfection of plasmid DNA in the Dunning prostate tumor R3327-AT1 is enhanced by focused ultrasound. *Gene Ther* 2000; 7: 1516–1526.
70. Heidenreich A, Weissbach L, Hotl W, et al. Organ sparing surgery for malignant germ cell tumors. *J Urol* 2001; 166:2161–2165.
71. Madersbacher S, Kratzik C, Susani M, Pedevilla M, Marberger M. Transcutaneous high-intensity focused ultrasound and irradiation: an organ-preserving treatment of cancer in a solitary testis. *Eur Urol* 1998; 33:195–201.
72. Pantuck AJ, Zisman A, Belldgrun AS. The changing natural history of renal cell carcinoma. *J Urol* 2001; 166:1611–1623.
73. Rendon RA, Stanietzky N, Panzarello T, et al. The natural history of small renal masses. *J Urol* 2000; 164:1143–1197.
74. Frank I, Blue ML, Cheville JC, et al. Solid renal tumors analysis of pathological features related to tumor size. *J Urol* 2003; 170:2217–2220.
75. Schachter LR, Bach AM, Snyder M, Kattan MW, Russo P. The impact of tumor location histological subtype of renal cortical tumors. *J Urol* 2004; 171:472.
76. Paterson RF, Barret E, Siqueria TM, et al. Laparoscopic partial kidney ablation with high intensity focused ultrasound. *J Urol* 2003; 169:347–351.
77. Adams JB, Moore RG, Anderson JA, et al. High intensity focused ultrasound ablation of rabbit kidney tumors. *J Endourol* 1996; 10:71–75.
78. Chapelon JY, Margonari J, Theillere Y, et al. Effect of high energy focused ultrasound on kidney tissue in the rat and the dog. *Eur Urol* 1992; 22:147–152.
79. Watkin NA, Morris SB, Rivens H, Ter Harr GR. High intensity focused ultrasound ablation of the kidney in a large animal model. *J Endourol* 1997; 11:191–196.
80. Köhrmann KU, Michel MS, Steidler A, Marlinghaus E, Kraut O, Alken P. Technical characterizations of an ultrasound source for noninvasive thermoablation by high-intensity focused ultrasound. *BJU Int* 2002; 90:248–252.
81. Köhrmann KU, Michel MS, Gaa J, Marlinghaus E, Alken P. High intensity focused ultrasound as noninvasive therapy for multifocal renal cell carcinoma: case study and review of the literature. *J Urol* 2002; 167:2397–2403.
82. Susani M, Madersbacher S, Kratzik CH, Vingers L, Marberger M. Morphology of tissue destruction induced by focused ultrasound. *Eur Urol* 1993; 23:34–38.
83. Wu F, Chen WZ, Bai J, et al. Pathological changes in human malignant carcinoma treated with high intensity focused ultrasound. *Ultrasound Med Biol* 2001; 27:1096–1106.
84. Wu F, Wang ZB, Chen WZ, et al. Extracorporeal high intensity focused ablation in the treatment of 1038 patients with solid carcinomas in China: an overview. *Ultrason Sonochem* 2004; 11:149–154.
85. Wu F, Wang ZB, Chen WZ, Bai J, Zhu H, Qiao TY. Preliminary experience using high intensity focused ultrasound for the treatment of patients with advanced stage renal malignancy. *J Urol* 2003; 170:2237–2240.
86. Kennedy JE, Clarke RL, Ter Haar GR. The effects of absorbers such as ribs in the HIFUS beam-path on the focal profile. In: Andrew MA, Crum LA, Vaezys, eds. *Proceedings, 2nd international symposium on therapeutic ultrasound*. Seattle: University of Washington 2003:185–192.
87. Ter Haar G, Kennedy J, Wu F. HIFUS treatments: dosimetric considerations. In: Andrew MA, Crum LA, Vaezys, eds. *Proceedings, 2nd international symposium on therapeutic ultrasound*. Seattle: University of Washington 2003:307–313.
88. Marberger M, Schatzl G, Cranston D, Kennedy JE. Extracorporeal ablation of renal tumors with high intensity focused ultrasound. *Br J Urol* 2005; 95:52–55.
89. Smith NB, Buchanan MT, Hynynen K. Transrectal ultrasound applicator for prostate heating monitored using MRI thermometry. *Int J Radiat Oncol Biol Phys* 1999; 43:217–225.

Mehran Anvari

Department of Surgery, McMaster University, St. Joseph's Healthcare,
Hamilton, Ontario, Canada

■ INTRODUCTION	Current Applications of Robot-Assisted
■ TELEMENTORING	Remote Telepresence Surgery
History	Nontechnical Issues Surrounding
Center for Minimal Access Surgery	Telementoring and Robot-Assisted Remote
Telementoring Program	Telepresence Surgery
■ ROBOT-ASSISTED REMOTE TELEPRESENCE	Benefits and Future Potential
SURGERY	■ REFERENCES

INTRODUCTION

Advances in laparoscopic surgery in the past decade have been rapid and have impacted most surgical disciplines. However, in few instances has the approach become the standard of care. While its application to simple and increasingly complex surgeries has been shown to offer a number of benefits including shorter hospital stays and recovery times, lower complication rates, and superior cosmetic results, the primary factor preventing many surgeons from offering advanced laparoscopic surgery is lack of training.

The learning curve for such procedures may be long and many of the skills required simply cannot be acquired in a classroom setting. The complication rates encountered during the learning curve and the medicolegal concerns raised have caused many surgeons to shy away from unsupervised attempts at gaining experience, which was the hallmark of the early years of minimally invasive surgery revolution.

On-site mentorship (1) has been shown to be the most effective means of enhancing the training experience and reducing the learning curve mishaps.

However, for surgeons in smaller communities, access to the expertise of skilled laparoscopic surgeons concentrated in tertiary care teaching hospitals can be difficult. Thus, completing the supervised practice or mentoring recommended by the Society of American Gastrointestinal Endoscopic Surgeons (1) is a major impediment to many aspiring advanced laparoscopic surgeons. As a result, laparoscopic surgery for many procedures is not available to patients in rural communities without involving travel to a distant urban center and is completely unavailable in less technologically advanced parts of the world. However, recent advances in telecommunications and computer-aided surgical systems (robotic surgery) have the potential to revolutionize the field of surgery through the development of programs in telementoring and robot-assisted remote telepresence surgery, resulting in access to a complete range of minimally invasive techniques for patients in rural or remote areas.

Telementoring utilizes modern videoconferencing technology to allow an expert surgeon to observe a distant surgery in "real time" and provide interactive instruction and guidance throughout the procedure.

Utilizing Integrated Services Digital Network, Internet protocol, or satellite technology, telementoring provides a means for surgeons to acquire laparoscopic skills under the supervision of an experienced expert, ensuring high standards of surgical quality and patient care. However, it also has a number of significant limitations, mainly the fact that the expert surgeon is not physically present to assist and is unable to react and take over in case of complications or unexpected developments.

Robot-assisted remote telepresence surgery utilizes robotic surgical systems together with advanced telecommunications technology to allow a surgeon to operate

On-site mentorship has been shown to be the most effective means of enhancing the training experience and reducing the learning curve mishaps.

Telementoring utilizes modern videoconferencing technology to allow an expert surgeon to observe a distant surgery in "real time" and provide interactive instruction and guidance throughout the procedure.

Although such systems hold tremendous potential to transform the nature of surgical care, they have a number of obstacles that should be overcome, including prohibitively high start-up costs, safety concerns, and technical limitations of the existing systems. In addition to technology-related concerns, there are a number of issues concerning liability, confidentiality, and licensing, which will have to be addressed before telementoring and telerobotic surgery can gain widespread acceptance.

from a remote location. The surgeon gains physical telepresence through the use of a master–slave telesurgical system with three robotic arms. One arm holds the scope and the camera and two perform surgical tasks. The surgeon's workstation provides a high-resolution view of the surgical field and the computer system transmits the movements of the surgeon's hands to the robotic arms.

Although such systems hold tremendous potential to transform the nature of surgical care, they have a number of obstacles that should be overcome, including prohibitively high start-up costs, safety concerns, and technical limitations of the existing systems. In addition to technology-related concerns, there are a number of issues concerning liability, confidentiality, and licensing, which will have to be addressed before telementoring and telerobotic surgery can gain widespread acceptance.

TELEMENTORING

History

The first reported case of interactive real-time surgical teaching from a distant location was in 1965 when DeBakey utilized broadband satellite to transmit guidance in cardiothoracic surgery to Europe from the United States (2). However, rapid communication developments during the 1990s have been, at least in part, behind the recently expanding body of literature reporting telementoring to be a safe and feasible option for surgical teaching.

In 1994, Kavoussi et al. (3) reported use of the AESOP[®] arm^a, a robotic arm capable of holding and manipulating the laparoscopic camera to perform three telementored surgeries in which the instructing surgeon was located in a separate room. Aside from the robotic arm repeatedly detaching from the camera, the procedures were performed successfully. In a series of 23 urologic procedures performed at the Baltimore Medical School, 22 were successfully completed laparoscopically by a junior surgeon with mentoring from an expert surgeon located in a separate building (4). Rosser et al. evaluated the role of telementoring in the teaching of advanced laparoscopic procedures. In a two-phase study, phase 1 involved four colonic resections during which the mentoring surgeon was present in the operating room and four colonic resections performed with the mentor located in a truck on the hospital grounds. Phase 2 involved two Nissen funduplications mentored from within the operating room and two during which the mentor was located five miles away. In phase 1, audio and visual signals were transmitted via coaxial cable and in phase 2, coding and decoding algorithm-mediated compression technology and existing T-1 landlines were used. The authors reported no significant difference in mean operating times or surgical outcomes for the telementored procedures as compared to those in which the mentor was physically present (5). Early reports on the use of long-distance telementoring include an adrenalectomy performed in 1998 between Austria and the United States (6), and a series of five laparoscopic herniorrhaphies, completed on board an American aircraft carrier by the ship's surgeon while under the guidance of an experienced surgeon located in the United States. The surgeons were linked via the Battle Group Telemedicine System, which provided real-time audio and visual information (7).

Lee et al. reported results of transcontinental trial involving the United States and both Thailand and Austria in 1998 in which an electrocautery instrument could be controlled by the telementor. All surgeries, which included a nephrectomy, a varicocelelectomy, and an adrenalectomy, were completed without complications (8). Since this time, numerous groups have reported successful telementoring of a wide range of procedures over substantial distances (9–13).

Center for Minimal Access Surgery Telementoring Program

In Canada, telementoring is currently in routine clinical use, providing community surgeons in two rural cities with access to the expertise of expert laparoscopic surgeons, without the need for extensive travel.

Surgeons at the Centre for Minimal Access Surgery (St. Joseph's Healthcare, McMaster University, Hamilton, Ontario, Canada) routinely mentor surgeons at two community hospitals, one in Northern Ontario and the other in Northern Quebec. Procedures performed to date include laparoscopic funduplications, splenectomies, hernia repairs, and colonic resections (14). The telecommunications (two-way audio and visual connections) are conducted over either integrated services digital network lines or the Internet Protocol network, which connects most hospitals in Canada.

In Canada, telementoring is currently in routine clinical use, providing community surgeons in two rural cities with access to the expertise of expert laparoscopic surgeons, without the need for extensive travel.

^aComputer Motion, Santa Barbara, CA.

TABLE 1 ■ Outcomes for 19 Telementored Procedures Involving Four Mentees

Procedure	No. of cases	Length of stay (day) ^a	No. of complications	Mentor's assessment of surgical quality ^a	Mentee's assessment of utility of mentoring ^a
Colon resection	10	5	1	4 out of 5	4 out of 5
Nissen fundoplication	5	3	1	4 out of 5	4 out of 5
Splenectomy	2	2	0	5 out of 5	4 out of 5
Ventral hernia	1	6	0	4 out of 5	4 out of 5
Reversal of Hartmann's	1	7	1	4 out of 5	3 out of 5

^aMedian values.

Detailed questionnaires administered to both the mentoring surgeon and the mentee following each telementoring procedure have been utilized to evaluate the success of each session. Details of 19 procedures performed between November 1992 and July 1993 are given in Table 1.

Telementoring has permitted the community surgeons involved to adopt advanced laparoscopic procedures while providing patients with the same standard of care as at tertiary care centers and has facilitated a reversal of the recent trend toward centralization of health care services. The Centre for Minimal Access Surgery plans to extend this service to include eight teaching hospitals and 32 rural communities within the next few years.

Technical Requirements and Considerations

Recent advances in telecommunications have encouraged the development and evaluation of surgical telementoring as equipment required becomes more readily available. Early telementoring occurred over short distances utilizing hard-wired connections. However, telecommunication currently utilizes integrated services digital network, a fully digital system readily available in many areas via commercial telephone line. These lines offer sufficient bandwidth to ensure adequate image quality. However, ultimately, internet protocol networks are likely to become the medium of choice due to reliability, safety, wide availability, and recent ability to offer quality of service (15). It should be noted that low-bandwidth connections can and have successfully been used in remote areas where telecommunications are limited. However, operators must minimize camera motion and slow movements in compensation (16).

Due to the reliance on technology, telementoring has raised significant concerns regarding patient safety. Loss of communications, poor image transmission, and equipment failure at either location are all possibilities that must be considered well in advance of any surgeries.

It is of utmost importance that a comprehensive plan exists to deal with all eventualities, including system failures and intraoperative complications. Because the mentor is not physically present to take over if required, such a plan must ensure that in case of a serious system failure or other complication, the local surgeon has the expertise and technical assistance necessary to complete an open procedure if required.

ROBOT-ASSISTED REMOTE TELEPRESENCE SURGERY

Robot-assisted remote telepresence surgery has the potential to address the deficiencies inherent in telementoring by offering true telepresence for the expert surgeon in the operating room of the learner, thus allowing the expert to assist or perform a part or all of the surgery as necessary and to slowly train the local surgeon in performing the advanced laparoscopic procedures safely. Robot-assisted remote telepresence surgery utilizes a multiple-arm robotic platform controlled by the surgical console located remotely hundreds or thousands of miles away and connected to each other via broad band telecommunication via either fiber-optic landlines or possibly satellite. Two-way audio and video connections facilitate communication between the remote surgeon and the local operative team, and views of the operating room in addition to those of the surgical field allow the remote surgeon to become immersed in the operative environment.

Current Applications of Robot-Assisted Remote Telepresence Surgery

In 2001, Marescaux et al. successfully utilized the Zeus TS system to perform the world's first transatlantic telerobotic surgery in which the remote surgeon, working from a

It is of utmost importance that a comprehensive plan exists to deal with all eventualities, including system failures and intraoperative complications. Because the mentor is not physically present to take over if required, such a plan must ensure that in case of a serious system failure or other complication, the local surgeon has the expertise and technical assistance necessary to complete an open procedure if required.

In 2001, Marescaux et al. successfully utilized the Zeus TS system to perform the world's first transatlantic telerobotic surgery in which the remote surgeon, working from a console located in New York City, performed a cholecystectomy on a patient located 3800 miles away in Strasbourg, France.

console located in New York City, performed a cholecystectomy on a patient located 3800 miles away in Strasbourg, France (17).

The procedure was completed without technical difficulties or complications in 54 minutes. Dissection of the cystic duct and artery and the dissection of the gallbladder off the liver were performed by the remote surgeons while the local operative team was responsible for exposure of structures and clip application in addition to robotic arm setup, induction of pneumoperitoneum, and trocar placement. Electrocoagulation was initiated by a local assistant upon voice command from the remote surgeon. The telecommunication link for this procedure was accomplished via a private dedicated asynchronous transfer mode. This terrestrial fiber optic network provided a bandwidth of 10 Mbps and resulted in a latency of only 155 msec. A duplicate backup line was also available in the event of disruption of the main line. However, such services are not available in many locales and are prohibitively expensive, further limiting their utility at the present point of time.

Routine Use of Robot-Assisted Remote Telepresence Surgery

In February 2003, the Centre for Minimal Access Surgery in Ontario, Canada established the first remote telerobotic surgical service (18,19). This unique service links a teaching hospital (St. Joseph's Healthcare) in Hamilton with a community hospital over 400 km away, providing patients with access to advanced laparoscopic surgery in a rural community setting. The service utilizes the Zeus-TS microjoint system, which provides telepresence for the experienced laparoscopic surgeon, and three robotic arms that are placed by the local surgeon. Telecommunication is via a virtual private network, which utilizes a public telecommunication infrastructure to provide remote hospitals with secure access to urban centers. The goal of a virtual private network is to provide the same capabilities as private dedicated networks, but at a much lower cost.

Since the inaugural surgery on February 28, 2003, 22 telerobotic surgeries have taken place with no major complications, no conversions to open procedures, and lengths of stay comparable to those seen in tertiary care centers.

Procedures completed to date include funduplications, right hemicolectomies, anterior resections, sigmoid colon resections, and inguinal hernia repairs. The system allows the local and remote surgeon to interchange roles as necessary, thus permitting the remote surgeon to either act as the primary surgeon or demonstrate plans for dissection to the local surgeon, who had received partial training in advanced laparoscopic procedures through short courses and mentoring/telementoring.

Initial experience with robot-assisted remote telepresence surgery strongly suggests that this technology has the potential to revolutionize the delivery of healthcare, especially in rural or remote areas where access to advanced laparoscopic surgical procedures is limited or nonexistent. However, there are a number of financial, technical, ethical, and medicolegal issues that will have to be resolved before remote telepresence surgery becomes widely accepted.

Technical Considerations

Initial experiences with remote telepresence surgery have raised a number of technical issues. Firstly, development of robotic platforms to support remote telepresence surgery has been slow. To date, only the Zeus robotic system permits control of the robotic arms via a telecommunication link. However, the system is no longer commercially available following the recent merger of Computer Motion Inc. with Intuitive, manufacturer of the Da Vinci robotic system. Development of new robotic platforms that are more compact, portable, and easy to set up will be critical to the widespread adoption of this technology.

Rapid, accurate, and secure transmission of large quantities of data is critical to the success and safety of telerobotic surgery, and while Internet protocol-virtual private network and asynchronous transfer mode networks are available in many areas, they are not currently available in many remote or undeveloped areas. Currently, the use of satellite technology is not feasible due to excessive time delays (often in excess of 1 sec). Although surgeons can readily adapt to latency, there is varying evidence in the literature regarding the point at which latency leads to significant difficulty or increased errors.

Surgeons have been shown to have the capability to adapt to latencies of 500–700 msec but Fabrizio et al. (20) suggest that delays beyond 700 msec lead to decreased surgical performance.

Utilizing internet protocol/virtual private network networks, latencies of less than 200 msec are typical, of which the majority (more than 80%) is due to coding and decoding algorithm compression and decompression of the video signals. Current coding and decoding algorithm devices were designed for use in applications such as videoconferencing in which image quality is of primary concern and latency is not an important

Since the inaugural surgery on February 28, 2003, 22 telerobotic surgeries have taken place with no major complications, no conversions to open procedures, and lengths of stay comparable to those seen in tertiary care centers.

Surgeons have been shown to have the capability to adapt to latencies of 500–700 msec but Fabrizio et al. suggest that delays beyond 700 msec lead to decreased surgical performance.

issue. Development of new compression/decompression devices that are better suited to telepresence surgery could significantly reduce latency and shorten operating times.

Safety concerns surrounding telerobotic surgery are similar to those described for telementoring, because the remote surgeon is not physically present to take over in the event of a communication failure, robotic equipment failure, or operative complications. Use of a second redundant communication line provides an instantly available backup in case of a failure of the primary line. However, it is critical that the local and remote surgical teams outline in advance a plan of action and ensure that the local surgeon can successfully complete the procedure in the event of a system failure.

Nontechnical Issues Surrounding Telementoring and Robot-Assisted Remote Telepresence Surgery

As with the development of any new technology, telementoring and telepresence surgery have raised a number of issues related to confidentiality, liability, licensing across political borders, and assessment of the credentials of the parties involved.

Any transmission of data such as that used for telementoring or remote telesurgery via a telecommunication network poses the potential for a security breach. Encryption of the data minimizes this risk, but also adds an additional minimal time delay to transmission times. Because the data being transmitted includes medical images and identifying personal information, it is essential that all patients understand and accept that the potential still exists for inadvertent release of confidential information.

Due to the collaboration between distant institutions, telementoring and telerobotic surgery have also raised a number of legal concerns. There are no clear guidelines in existence to define the extent of liability of remote and local surgeons during telesurgical procedures. Traditionally, the party providing direct patient care has assumed liability; however, activities such as telementoring and telerobotics blur the lines that define direct care of a patient. During telementoring sessions, the mentoring surgeon has no ability to physically intervene in the case of unexpected events but nevertheless has the ability to influence the course of the procedure. The remote surgeon plays a substantially larger role during telepresence surgery, including functioning as the primary surgeon during some procedures. Thus, liability must ultimately be shared by both parties. The situation could be further complicated in the case of international collaborations in which jurisdictional conflicts may also exist. At present, no definitive solutions exist and any legal issues arising will have to be handled on a case-by-case basis. Before initiating any telementoring or telerobotic program, it is essential that both parties ensure that they are individually protected and that they reach a fundamental agreement regarding the identity of the “most responsible” physician.

Issues regarding licensing also arise when considering the establishment of a telementoring or telepresence surgery program. In cases involving mentoring or telesurgery across state or provincial boundaries, the remote surgeon must be licensed to practice in the jurisdiction in which the patient is receiving care. This requirement has the potential to impede the development of surgical support networks in which remote surgeons would potentially have to obtain licensure for a large number of jurisdictions, a costly and time-consuming endeavor. As the technology becomes more widespread, licensing bodies will most certainly need to develop new guidelines to address the unique requirements of telemedicine.

In both telementoring and telerobotic surgery, the quality of patient care is highly dependent on both the instructional and surgical skills of the remote surgeon. However, at the current time, there are no formal guidelines in place to assess these skills. As robotic assisted surgery gains in popularity, some institutions are adopting guidelines for credentialing (21). In general, these guidelines require clinical privileges for the equivalent open and laparoscopic procedures, a training course in the use of the surgical robotic system, and a step-wise progression from observation to assisting to supervised performance of the procedures. At the current time, no such guidelines exist for establishment of the credentials of telementoring surgeons. Furthermore, the success of telementored procedures is also dependent on the skills of the mentored surgeon. A minimum level of basic laparoscopic skills and thorough preparation specific to the procedure being performed are important prerequisites.

Benefits and Future Potential

Both telementoring and remote telepresence surgery offer tremendous potential to enhance the quality of surgical care offered to patients in rural or remote areas. At the current time, access to advanced laparoscopic procedures requires transfer to a distant

urban center. However, remote telesurgery enables these patients to remain in their community under the care of their local surgeon, yet have their procedure mentored or even performed by an expert surgeon at a distant teaching hospital. Creation of extensive remote telesurgery networks has the potential to reverse the recent trend toward centralization of advanced surgical care and to offer an improved level of care to patients in traditionally underserved regions. As the technology develops further, it may be possible for an expert surgeon to guide a nonsurgeon through emergency surgical techniques in order to save the life of patients in remote areas with no immediate access to advanced medical care.

Telementoring and remote telepresence surgery also have the potential to provide novice laparoscopic surgeons with a convenient and efficient means of safely gaining experience in minimally invasive techniques.

At present, it is especially difficult for community surgeons to access the advice and instruction of expert surgeons, and this limitation has seriously impeded the widespread adoption of laparoscopic techniques. Utilizing remote telepresence technology, even surgeons in remote areas can benefit from the support of a distant expert surgeon and can confidently offer advanced laparoscopic procedures to their patients without the high complication rates that usually accompany the learning curve for such procedures. Telepresence surgery can also permit experienced surgeons to collaborate, thus encouraging the development of new surgical techniques and enhancing the quality of surgery during technically challenging procedures.

The speed with which these new technologies are adopted will depend on their demonstrated ability to address the needs of the surgical community. Also, a number of obstacles including medicolegal responsibilities and licensing issues need to be addressed before the majority of surgeons would be willing and able to utilize these services on a regular basis.

Telementoring and remote telepresence surgery also have the potential to provide novice laparoscopic surgeons with a convenient and efficient means of safely gaining experience in minimally invasive techniques.

REFERENCES

1. Society of American Endoscopic Surgeons. Guidelines for the surgical practice of telemedicine. *Surg Endosc* 2000; 14:975-979.
2. Allen D, Bowersox J, Jones GG. Telesurgery. Telepresence. Telementoring. Telerobotics, *Telemed Today* 1997; 5:18-20.
3. Kavoussi LR, Moore RG, Partin AW, Bender JS, Zenilman ME, Satava RM. Telerobotic assisted laparoscopic surgery: initial laboratory and clinical experience. *Urology* 1994; 44:15-19.
4. Moore RG, Adams JB, Partin AW, Doumo SG, Kavoussi L. Telementoring of laparoscopic procedures: initial clinical experience. *Surg Endosc* 1996; 10:107-110.
5. Rosser JC, Wood M, Payne JH, et al. Telementoring: a practical option in surgical training. *Surg Endosc* 1997; 11:852-855.
6. Janetschek G, Bartsch G, Kavoussi LR. Transcontinental interactive laparoscopic telesurgery between the United States and Europe. *J Urol* 1998; 160:1413.
7. Cubano M, Poulouse B, Talamini M, et al. Long distance telementoring: a novel tool for laparoscopy aboard the USS Abraham Lincoln. *Surg Endosc* 1999; 13:673-678.
8. Lee BR, Bishoff JT, Janetschek G, et al. A novel method of surgical instruction: international telementoring. *World J Urol* 1998; 16:367-370.
9. Taniguchi E, Ohashi S. Construction of a regional telementoring network for endoscopic surgery in Japan. *IEEE Trans Inf Technol Biomed* 2000; 4:195-199.
10. Bauer JJ, Lee BR, Bishoff JT, Janetschek G, et al. International surgical telementoring using a robotic arm: our experience. *Telemed J* 2000; 6:24-31.
11. Micali S, Virgili G, Vannozzi E, Grassi N, et al. Feasibility of telementoring between Baltimore (USA) and Rome (Italy): the first five cases. *J Endourol* 2000; 14:493-496.
12. Bove P, Stoianovici D, Micali S, Patriciu A, et al. Is telesurgery a new reality? Our experience with laparoscopic and percutaneous procedures. *J Endourol* 2003; 17:137-142.
13. Rodrigues Netto N Jr, Mitre AI, Lima SV, et al. Telementoring between Brazil and the United States: initial experience. *J Endourol* 2003; 17:217-220.
14. Sebahang H, Hegge S, McKinley C, Anvari M. Telementoring: an important enabling tool for the community surgeon [abstr]. *Surg Endosc* 2004; 18(suppl):S284.
15. Eadie LH, Seifalian AM, Davidson BR. Telemedicine in surgery. *Br J Surg* 2003; 90:647-658.
16. Broderick TJ, Harnett BM, Merriam NR, et al. Impact of varying transmission bandwidth on image quality. *Telemed J* 2001; 7:47-53.
17. Marescaux J, Leroy J, Rubino F, Smith M, et al. Transcontinental robot-assisted remote telesurgery: feasibility and potential applications. *Ann Surg* 2002; 235:487-492.
18. Pirisi A. Telerobotics brings surgical skills to remote communities. *Lancet* 2003; 361:1794-1795.
19. Anvari M, McKinley C, Stein H. Establishment of the world's first telerobotic remote surgical service: for provision of advanced laparoscopic surgery in a rural community. *Ann Surg*. 2005; 241: 460-464.
20. Fabrizio MD, Lee BR, Chan DY, Stoianovici D, et al. Effect of time delay on surgical performance during telesurgical manipulation. *J Endourol* 2000; 14:133-138.
21. Ballantyne GH, Kelley WE. Granting clinical privileges for telerobotic surgery. *Surg Laparosc Endosc Percutan Tech* 2002; 12:17-25.

VIRTUAL REALITY AND SIMULATION IN UROLOGY

Robert M. Sweet

*Department of Urologic Surgery, University of Minnesota, Minneapolis,
Minnesota, U.S.A.*

Jeffrey Berkley

*Department of Industrial Engineering, University of Washington, Seattle,
Washington, U.S.A.*

- INTRODUCTION
- HISTORY
- VIRTUAL REALITY ROLE IN PROCEDURAL TRAINING
- BUILDING A VIRTUAL REALITY SIMULATOR
 - Step 1: Define a Desired Skill Set and Learning Objectives
 - Step 2: Design a Curriculum and Analyze Where Simulation Would be Most Useful
 - Step 3: Justify the Application
 - Step 4: Define the Metrics
 - Step 5: Recognize Which Sensory Modes are Important and Should/Can Be Simulated
 - Step 6: Computer Processing Needs
 - Step 7: Build Team Collaborations
 - Step 8: Build and Render the Model
 - Step 9: Texture Maps and Special Effects
 - Step 10: Medical Instrumentation
 - Step 11: Tracking Solutions
 - Step 12: Orientation and Calibration of Metrics
 - Step 13: Digital Acquisition Devices (Input/Output Boxes)
- Step 14: Collision Detection and Deformation
- Step 15: Displays
- Step 16: Raw Data Collection Repositories
- Step 17: Graphics-User Interfaces
- Step 18: Usability Studies
- Step 19: Validity/Reliability Studies
- Step 20: Commercialization
- Step 21: Implementation for Training
- Step 22: Define the Learning Curve
- Step 23: Implementation for Assessment/Credentialing
- SURVEY OF VIRTUAL REALITY UROLOGICAL SIMULATORS
- COGNITIVE SIMULATION ENGINES
- COMPLETE PROCEDURES
 - Transurethral Resection of the Prostate Skills: A Potential Training Crisis
 - Virtual Reality Training for Ureteroscopic Skills
 - Virtual Reality Training for Laparoscopic Skills
- SUMMARY
- REFERENCES

INTRODUCTION

The focus of this chapter is virtual reality simulation and its role in urological applications. Virtual reality is one component of a true renaissance that is occurring in the surgical education curriculum. As hardware and software technology improve, it becomes possible to simulate a wider variety of surgical scenarios. Not only is it possible to prepare for such scenarios outside of the operating room but it is now possible to use the computer to automatically evaluate student performance and identify their specific training needs.

Every year at least 44,000 Americans die of medical errors. Medical errors are the seventh leading cause of death in the United States, greater than car accidents, breast cancer, or AIDS.

Pharmacy errors are no longer the leading cause of medical complications; procedural errors are. Indeed, there is an ever-increasing public scrutiny of medical training and the use of the operating room for teaching purposes.

Simulation is a promising alternative to training inside the operating room. Factors that support a shift toward simulation training include diminished resident work hours, increased operating room costs, the ACGME competency movement, and special training issues associated with the acquisition of minimally invasive surgical skills.

Many authors argue that the operating room is not the best environment for training (1,2). In fact, a recent survey of program directors demonstrated that 92% of respondents felt that there is a need for technical skills training outside of the operating room (3). However, the fact remains that to date there is a paucity of effective evaluation

Every year at least 44,000 Americans die of medical errors. Medical errors are the seventh leading cause of death in the United States, greater than car accidents, breast cancer, or AIDS.

When considering virtual reality in surgery, the key is to obtain “mimesis,” or to trick the mind into believing that it is immersed in a real-life task.

Training might focus on a subtask or an entire procedure in order for the student to achieve necessary technical skills.

Aerospace, military, industrial, and medical simulation applications all share the common pretense that for a trainee to interact with a complex system, there must be a thorough understanding of the overall system and the relevance of each subcomponent.

tools available that fully implement the power of simulation training as appropriate for a procedural skills training curriculum (4). Physical model simulators have been employed in many centers and have been shown to be effective in training some basic technical skills. Unfortunately, many of these training models do not convey a sense of “presence” to the student, and the models are not often coupled with objective metrics and training feedback. Virtual reality models represent an attractive solution to the above-mentioned shortcomings of physical model simulators. In particular, virtual reality simulation is very amenable to minimally invasive surgery and great strides have been made in select applications.

When considering virtual reality in surgery, the key is to obtain “mimesis,” or to trick the mind into believing that it is immersed in a real-life task.

It is important to acknowledge that even the most advanced simulators do not replicate the exact look and feel of a real procedure. However, for a simulator to be effective, the mind must set aside a sense of disbelief when encountering an artificial yet similar set of visual, tactile, auditory, and olfactory sensations. The student should feel that there are real consequences to mistakes made with a virtual patient, just as there would be with a real patient.

Professional athletes, musicians, actors, performers, and even surgeons have employed simulation training in a variety of fashions for decades.

Training might focus on a subtask or an entire procedure in order for the student to achieve necessary technical skills.

On the simplest level, mental imagery techniques can be used to associate technical aspects of a procedure with cognitive rehearsal. This alone works well for relatively predictable activities, such as a 50 m swim or a gymnastic floor routine. The athlete commits to memory a list of steps required for performing a certain routine and then envisions performing each of those steps by the athlete. However, such training becomes difficult in situations where there is a reliance on multiple people, as they work with complex equipment while battling the physical forces of nature. For example, simulating scenarios on the battlefield or in outer space can be very complex and training errors can have serious repercussions. In these “less controlled environments,” the aid of computer simulation to associate technical and cognitive learning can be very advantageous. Not only does simulation reinforce the learning of a particular technique but also how to deal with unexpected situations.

Simulation has been prevalent in industries such as aerospace, engineering, and the military since the 1950s. Complex tasks are evaluated not only to understand the overall problem but also to define individual components and how each part contributes to form the entire system. At the core of this process are information systems, which provide virtual prototyping of models. The tools include process and flow diagrams, interface requirement documents, and an overall design plan (5).

Aerospace, military, industrial, and medical simulation applications all share the common pretense that for a trainee to interact with a complex system, there must be a thorough understanding of the overall system and the relevance of each subcomponent. Such an understanding is necessary for a trainee to undertake the learning of many skill tasks that may involve life and death decisions.

A number of reasons for the limited role of simulation in the field of medicine compared to other industries have been postulated. One might blame the circumspect nature of medical professionals and their inability to see the “big picture” of technological advancements while trying to address patient demands with minor, incremental improvements (6). Another factor is the lack of a true funding source for efforts in surgical education. There is a significant shortfall in resources provided by government funding agency for supporting medical postgraduate education initiatives (7). The government does allocate money to residency programs. However, this money does not go to educational initiatives directly, but goes to the hospital to cover salaries and overhead assumed to exist because of the perceived inefficiencies associated with the training of residents. The end result is that medical institutions have little money allocated to buy surgery simulators and consequently the market for commercially developed simulators is quite small. Just the same, medical professionals expect the quality of surgical simulators to exceed that of common video games, even though the market for video games is many orders of magnitude greater than that of surgery simulators. Compounded by the reality that there are still a number of unsolved technical issues that prevent the creation of a truly accurate virtual prototype of the human body, there remains a large gap between expectations from the medical community and what industry is capable of delivering.

As compared to industrial and military applications, simulating the biological world includes additional complex layers of interactivity and unpredictability.

As compared to industrial and military applications, simulating the biological world includes additional complex layers of interactivity and unpredictability.

When considering the modeling of mechanical systems and how they interact with the physics of nature, we have a pretty thorough understanding of the overall system and the contribution of the individual components. Unfortunately, we have just barely scratched the surface of understanding on how genes and cells interact with each other and what this means from a physiological standpoint. Clearly, this becomes even more complex when considering and attempting to predict the output of important psychosocial factors and surgical manipulations on the “black box” organ of the human body: the brain. This is a critical thing to consider, which often frustrates our engineering colleagues who like to translate phenomenon into formulas. How then are we to simulate what we may not understand completely in the real world? Currently, the information systems for our model—the human patient—merely consist of the patient’s chart (history, physical examination, and laboratory studies), and imaging modalities (the video monitor, magnetic resonance imaging, computed tomography, ultrasound, etc.) (5,8). Regrettably, these data are insufficient to create a true virtual prototype of our model. Such a human surrogate in cyberspace would be based on patient-specific data from historical, genetic, molecular, biochemical, physiological, and digital imaging sources (9). However, even without the complete data set necessary to create a truly accurate model, virtual reality still continues to aid us in the process of understanding the human body through virtual analysis that employs “block box” methodologies such as neural networks, genetic algorithms, and hidden Markov models (10).

HISTORY

In the mid-1970s, Myron Krueger coined the term “artificial reality” to describe the ability to simulate synthetic realities with the aid of computers. In 1987, a computer scientist named Jaron Lanier coined the term “virtual reality.” It was during this period that a visionary general surgeon, Richard Satava, recognized that the concepts described by Krueger and Lanier could be applied to medical training. Dr. Satava has since led a crusade to apply this technology to medical procedures through countless lectures and multidisciplinary conferences like “Medicine Meets Virtual Reality” and by funding projects in this area through the Department of Defense.

Excited by the potential for virtual reality training, pioneering academic surgeons began widely promoting virtual reality technology. However, the initial hype led to false expectations and the surgical community became highly critical of early surgery simulation.

Excited by the potential for virtual reality training, pioneering academic surgeons began widely promoting virtual reality technology. However, the initial hype led to false expectations and the surgical community became highly critical of early surgery simulation.

At the time, virtual reality and medical simulation projects were limited by technological factors such as computing processing speed, graphical display hardware, data storage capacity, and data transmission bandwidth. Another significant problem was that computer scientists developed the initial surgery simulators without sufficient collaboration with surgeons. As a result, projects were often demonstrations of computer science and engineering principals that did not necessarily address the needs of the medical community. Applications demonstrated “proof of concept,” but initially did not result in practical tools that could be used for medical education. As a result, the majority of the medical community considered surgical simulators impractical, expensive, unrealistic, and lacking of proper validation for use.

Successful simulation projects now involve not only collaborations between members of the medical and computer sciences but also the cognitive sciences.

Successful simulation projects now involve not only collaborations between members of the medical and computer sciences but also the cognitive sciences.

Cognitive scientists remind us that it is paramount that a simulator provide effective training, not perfect realism (11,12).

Simulation fidelity should be matched with training requirements because high fidelity simulators are not necessary for all tasks. It is the embedded instructional features in a simulator that make training effective (13).

Simulation fidelity should be matched with training requirements because high fidelity simulators are not necessary for all tasks. It is the embedded instructional features in a simulator that make training effective.

Repeatedly practicing something incorrectly without instructional feedback on the correct method will just reinforce bad behavior. It is also advantageous to embed carefully crafted scenarios with “triggers” that provide opportunities to practice and assess important behaviors. Such an example in urology would be to provide cues for the user to diagnose and manage a CO₂ embolism management during a laparoscopic radical nephrectomy. Salas and Burke (13) have stated, “Simulators should not only capture performance outcomes, but must also capture the moment-to-moment actions and behaviors.” Such detailed moment-to-moment information is necessary in order to provide feedback as to how to improve performance. Salas and Burke stress that the education experience should be guided toward learning key competencies and that there is a reciprocal partnership between subject matter experts and learning/training specialists (13).

VIRTUAL REALITY ROLE IN PROCEDURAL TRAINING

While every simulator differs, in theory the primary advantage that virtual reality simulation of medical procedures has over inanimate synthetic models is its ability to track and log everything the user is doing during the task and provide useful feedback. This creates a safe and truly learner-centered environment that is comfortable and efficient, while not requiring the presence of mentor supervision. The option of adding mentored supervision, of course, is always possible and often desirable to enhance the learning experience (Table 1).

With current technology, patient-specific models can be imported into the simulation environment, allowing for the practice of specific cases prior to performing them in real life (14).

Berkley et al. (15) has begun work on this for urological applications with funding from the Defense Advanced Research Projects Agency. Many simulators have curricula built into their software, which train the cognitive aspects of the procedure as well as case scenarios and basic skills training modules. The user can focus on those subtasks, which cause the most difficulty and the proctor and the student can track progress over time and when the trainee reaches criterion levels set by experts on the simulator, they could then be given permission to “practice on patients” under supervision.

The use of virtual reality simulators to test new instruments is also a potential advantage for industry to develop cutting edge technology and train their sales staff.

In the United Kingdom, live animal operations are banned under the Cruelty to Animals Act of 1876, and there is some pressure in the United States to follow suit. While the current line of thinking in the United States is that the advantages of live animal surgery in training surgical skills seem to outweigh the pitfalls, it is always of great benefit to find alternatives to such a practice.

With current technology, patient-specific models can be imported into the simulation environment, allowing for the practice of specific cases prior to performing them in real life.

The use of virtual reality simulators to test new instruments is also a potential advantage for industry to develop cutting edge technology and train their sales staff.

BUILDING A VIRTUAL REALITY SIMULATOR

A list of steps will be defined for constructing a simulator in order to promote discussion on various important issues related to surgery simulation. This list is intended to generalize so that it may be applied to a wide variety of surgical procedures rather than specific applications.

Step 1: Define a Desired Skill Set and Learning Objectives

Successful simulation projects require extensive input from the subject matter expert. When choosing physician collaborators, simulation developers need to look for physicians who are expert teachers/communicators first and technical experts second.

The first and arguably most important contribution the physician can make is defining the application or the procedure being simulated. Such a choice should be driven by training need first and apparent capability to simulate the skill set second, as

TABLE 1 ■ Advantages/Disadvantages of Virtual Reality Simulators in 2004

Advantages	Disadvantages
Objective metrics	Expensive to develop
Learner centered	Expensive to purchase
Immediate user feedback	Lack of funding sources
Patient-specific data	Fidelity
Testing of new instruments	Validation lacking
Safe	Technology needs to recapitulate biology
Ability to break down complex tasks into modules	Need to define the metrics
Assessment capability	Need to define the standards
Does not require mentored supervision	Requires intense multi-disciplinary collaborations to build
Can build in curriculum	Lack of curriculum
Can discern cognitive versus technical errors	
Can track motion	
Animal welfare	

Because the training need is the crux of the whole project, the physician needs to continuously supervise development to assure that the training needs are the focus and are properly being addressed. If training needs are not addressed, then the quality of graphics and model interaction become irrelevant.

The cognitive component of the procedure, or how and when these skill sets are put together, is the true backbone of the procedure. It has been approximated that 85% of what is learned for a given surgical procedure lies in the cognitive domain. The virtual reality simulator has the unique ability to dissect these domains allowing for critical and instructive analysis of causality of errors and techniques at a level much higher than inanimate simulators and even mentored instruction.

Curriculum development and implementation is probably best done by a team of subject matter experts (urologists) in consultation with an expert in medical education.

it is only with extensive discussion/bridging of the knowledge gap between computer scientists and physicians that the distinction between what can and a cannot be accomplished is defined.

Because the training need is the crux of the whole project, the physician needs to continuously supervise development to assure that the training needs are the focus and are properly being addressed. If training needs are not addressed, then the quality of graphics and model interaction become irrelevant.

There are essentially four learning domains that need to be considered:

- The affective domain (ability to manage a team, focus, attention, etc.)
- The cognitive domain (judgment, knowledge)
- The visual-spatial domain (ability to navigate in virtual space)
- The psychomotor domain (motor skills)

Some attempts have been made to measure the affective domain, but its abstract nature makes it more difficult to assess and quantify. Studies examining the effect of stress and lack of sleep in the operating room and subjective evaluation of interpersonal skills are examples of such studies (16–23).

Every urologic procedure is made up of several “skill sets,” which can be thought of as building blocks. Performance of these isolated skill sets lies primarily in the visual-spatial and psychomotor domains. Thus, simulators created to simulate these basic tasks are only measuring and assessing these learning components.

The cognitive component of the procedure, or how and when these skill sets are put together, is the true backbone of the procedure. It has been approximated that 85% of what is learned for a given surgical procedure lies in the cognitive domain. The virtual reality simulator has the unique ability to dissect these domains allowing for critical and instructive analysis of causality of errors and techniques at a level much higher than inanimate simulators and even mentored instruction.

With this in mind, subject matter experts need to critically examine a given urological procedure for its cognitive, visual-spatial, and psychomotor components and look for the best opportunities by which simulation may help lessen the learning curve. The learning objectives can then be defined.

Step 2: Design a Curriculum and Analyze Where Simulation Would Be Most Useful

The next step is to design a curriculum targeted towards accomplishing those learning objectives. The design of your simulator will be such that it will hopefully be able to address the gaps in learning opportunities, which you have identified. Curriculum development is tedious and difficult work, but developers need to keep in mind that in the end it will be the “curriculum” and not the technical components of the simulator that will be validated and implemented.

Curriculum development and implementation is probably best done by a team of subject matter experts (urologists) in consultation with an expert in medical education.

Step 3: Justify the Application

The motivation to build a virtual reality simulator may include training, testing of new instrumentation, academic research, promotion of a new product, or simply financial. Regardless of the reason for building a simulator, the following guidelines are provided to help in choosing the appropriate procedures to simulate:

1. *The application should represent a commonly performed or required skill set and/or disease process:* Given the time, effort, and expense required to build a simulator, it is important that a simulator can be applied to a wide audience. For example, a simulator for training tasks such as laparoscopic port placement, Veress needle insertion, or full procedures for common diseases such as laparoscopic radical prostatectomy may be more widely used than a simulator that teaches laparoscopic excision of a urachal cyst.
2. *The skill sets embedded in the application should represent a prolonged learning curve:* If a skill set is not difficult to master, traditional training methodologies may be sufficient. Making a simulator or a module intended to train the bagging of a kidney specimen may be less useful than one for completing the urethral anastomosis during a laparoscopic radical prostatectomy.
3. *The application should address training issue that typically subject patients to risk. Patient safety should be a top priority and a driving force behind the creation of any surgical simulator:*

This issue is magnified in laparoscopic surgery, as it can be more difficult for the trainer to monitor and recover from an error performed by a trainee as compared to that which may occur in an open case. One example of a procedure that presents training risk for patients would be the hilar dissection during a laparoscopic nephrectomy.

4. *The application should address skill sets characterized by a significant training gap between preparation training and patient practice:* This issue is prevalent throughout laparoscopic urology since only the most recent graduates from select residency programs or laparoscopic fellowships received concentrated training in this arena. An entire generation of urologists is currently reliant on weekend courses, training videos, box trainers, and mentors to perform complex skills that many believe are the standard of care. It might be questioned that the skills gained from these training mechanisms adequately carry over to the operating room. With little or no objective assessment of skills prior to credentialing, it can be difficult to determine whether a trainee is ready to work with patients.
5. *Choose an application that is amenable to simulation:* It is important to choose a procedure that can be represented given the current level of technology. This used to be a significant limiting factor because the technology did not exist to address issues such as rendering complex tissue structures and their deformation. However, more recently, the consensus has been that most laparoscopic procedures could theoretically be simulated with acceptable accuracy. However, while we still lack an accurate model of the human body, it remains difficult to represent characteristics such as fluid flow and electrochemical reactions. Applications that are dependent on such intricate modeling, given current technology, may be doomed to failure.

TABLE 2 ■ Suggested Specific Metrics that Can Be Used for Outcomes Analysis

Economy of motion
Purposefulness of motion
Absence of motion (indecision)
Path length
Time to completion
Sequence of steps
State analysis (still, moving)
Force measurements
Errors
Missed target
Tissue tearing
Bleeding
Organ perforation
Burning of wrong tissue
Recovery from error
Response latency (time to recover from error)
Final product (e.g., leaking, inaccurate)
Global assessment of performance
Source: From Ref. 27.

Expert systems that rely on knowledge or reasoning that emulates the performance of human subject matter experts can also be created. Such expert systems might be based on encoded rule statements that reflect individual or gathered expertise in a field.

In endoscopic procedures, the simulation of how objects appear and interact visually is the most dominate.

Step 4: Define the Metrics

In order to objectively measure performance, developers need to choose what specific elements are important to track. Key metrics need to be chosen and calibrated by a consensus of subject matter experts (in this case physicians) (24). These include a taxonomy/definition of errors and a method by which results can be integrated and reported for individual users as well as groups of users (25,26).

In 2001, Satava et al. organized a surgical skills workshop attended by an assembly of representatives from surgical societies and boards responsible for the education, training, and certification of surgeons. The primary purpose was to begin standardizing nomenclature and assessment methods so that the entire surgical education, training, and evaluation community could communicate more effectively and have a common basis to compare statistical results (27). The product of such a consensus could provide critical information to the developers of simulation technology. A similar consensus publication examining medical errors has been held and the manuscript is in progress.

Table 2 shows only an initial baseline of possible metrics that may make it possible to assess and assign the degree of competency for a trainee. However, the debate over proper metrics continues and undoubtedly the list presented in Table 2 will grow with time. For example, recent simulation discussion has focused on efficient use of OR resources (preoperative planning, equipment, ancillary staff if appropriate, gas/fluid management, amount of energy delivery), which may prove important for evaluating training over a variety of medical procedures.

With the collection and classification of such data, criterion levels for each key metric can be established to define the levels of performance listed in Table 3.

Expert systems that rely on knowledge or reasoning that emulates the performance of human subject matter experts can also be created. Such expert systems might be based on encoded rule statements that reflect individual or gathered expertise in a field.

The expert system would then display “reasoning” via a rule interpreter in order to reach a decision, come to a conclusion, or give up on a particular problem.

Step 5: Recognize Which Sensory Modes Are Important and Should/Can Be Simulated

Surgeons rely on a variety of sensory feedback to execute complex hand–eye motor tasks and make important decisions. It is therefore important to determine which sensory feedback modalities are important to relay in a simulated environment. The types of feedback will vary from procedure to procedure.

In endoscopic procedures, the simulation of how objects appear and interact visually is the most dominate.

TABLE 3 ■ Levels of Performance

Novice
Competent
Proficient
Expert
Master

Source: From Ref. 27.

In fact, in robotic laparoscopic applications, the only feedback to the surgeon is visual. It can be debated whether or not the addition of haptic feedback (force feedback and tactile feedback) would add a significant benefit. In contrast, the inclusion of haptic feedback is very relevant when simulating open procedures. If such feedback cannot be adequately represented, then a simulator may prove ineffective.

Glossary of sensory feedback in surgery simulation

- *Presence*: The sensation of actually being “there.”
- *Immersion*: The state where the individual is absolutely focused on the task at hand.
- *Navigation*: The ability to move through the environment.
- *Interaction*: The ability to move and feel/touch objects in the environment.

The terms “presence” and “immersion” are often mistakenly interchanged, but they do have distinct meanings. For example, a child playing a video game may be immersed in the game and not realize what is going on around them. However, the child probably does not believe to be actually in the video game world. If the video game established a sense of presence, then the children would feel that they themselves are jumping over mushrooms and eating coins. As demonstrated, any video game (simulator) can create immersion, but as far as surgical simulation is concerned, a simulator must represent the multimodal senses of visual, tactile, auditory, and olfactory realism to enable the feeling of presence (28).

With new-generation tracking devices, navigation through virtual environments is possible as the trainee physically performs the hand/eye motor tasks used in real surgical procedures. However, in many cases, common tracking electronics may not fit within the construct of a variety of surgical instrument or their accuracy might be effected by metal, electric, and magnetic fields. This can impose limitations on a number of procedures that can be completely simulated to endoscopic procedures, laparoscopic procedures, procedures using Seldinger technique, and simple open procedures such as intubation, incisions, and simple suturing.

Another important factor to consider when addressing sensory feedback is the concept of clue conflict. Motion sickness can result when the body tries to interpret conflicting clues as they are received over multiple senses.

For example, when visual cues of physical orientation do not match vestibular feedback, an individual is likely to become sick. In simulation, this can occur when the frame refresh rate is too slow. The trainee can also become disoriented when visual cues do not match physical motion, such as when a trainee attempts to move an object in one plane but sees the object moving in a different plane. When one is first learning endoscopy, this may occur during actual procedures due to the fulcrum effect (Fig. 1), but with repeated patterned sensory stimuli (training), these senses adapt and this conflict resolves.

Auditory realism is important in surgical virtual reality applications.

The sounds of the operating room can provide very important cues that the surgeon needs to respond to, such as the sounds of electrocautery, verbal cues from the patient or other operating room personnel, and the pulse oximeter.

Another important factor to consider when addressing sensory feedback is the concept of clue conflict. Motion sickness can result when the body tries to interpret conflicting clues as they are received over multiple senses.

The sounds of the operating room can provide very important cues that the surgeon needs to respond to, such as the sounds of electrocautery, verbal cues from the patient or other operating room personnel, and the pulse oximeter.

FIGURE 1 ■ Laparoscopic simulators.

Haptics is the study of the psychomotor experience of tactile proprioception and force feedback.

Haptic fidelity refers to the rate at which haptic signals are updated.

Fidelity also depends upon the speed of movement of an object through the environment.

Open procedures require high-fidelity force feedback and tactile feedback. Unlike laparoscopic procedures, open surgery tools do not work through a fulcrum that diminishes the forces as well as tactile feedback.

While such sounds are usually quite simple to represent in a virtual environment, they can add a significant degree of realism to a simulator. One concept, or technique, which allows for enhanced auditory realism, is known as convolving. Convolving involves filters and intertwines signals and renders them in three-dimensional space. These are used in virtual reality applications to recreate sounds that give directional cues. Such directional feedback can also prove quite valuable in simulation.

Haptics is the study of the psychomotor experience of tactile proprioception and force feedback.

Force feedback is the counterbalanced sense of a magnitude of force perceived when a force is applied to an object and is directional in nature. This needs to be discriminated from tactile feedback, which is nondirectional sensation. Some examples of tactile feedback are vibration, texture, and temperature. Such information is transmitted to the user through an “actuator” via mechanical and/or electric means.

Relatively speaking, simulation of haptics is very computationally expensive. When considering integrating haptics into a simulator, one must pay special attention to the magnitude and number of forces that must be applied. Basic physical principals dictate that all forces on an object must sum to zero or the object will be set in motion. Therefore, if a force feedback device is resisting the push from a trainee, the force feedback device must also push on a grounded object (such as the floor or a secure desk) in the exactly opposite direction so that all force vectors sum to zero. Otherwise, the force feedback device might fly right out of the simulator. Representing one point of force feedback is feasible, such as pushing/pulling on one point of a surgical instrument. A single robotic arm might be connected between the floor and the instrument to effectively render one vector of force by controlling motor torques in the joints of the robotic arm. However, force feedback becomes much more complicated as more points of interaction are added. Imagine what would be necessary to accurately render the appropriate sense of touch over the entire hand as might be required for some open surgical procedure. This would necessitate several different vectors of force applied over a number of contact points on the hand. It simply is not practical to attach a robotic arm to each of these points of force feedback.

Haptic fidelity refers to the rate at which haptic signals are updated. Different haptic phenomena require different degrees of fidelity to convince the trainee that a sensation is realistic. In general, directional force feedback requires less fidelity than tactile force feedback. The deformability of objects within the environment is also a factor to consider. The more deformable an object, the less fidelity is required. Accurate simulation of collision with rigid objects requires higher fidelity, as the degrees of change in force can be dramatic for small displacement. In other words, small, quick changes in motion can generate large forces, which are difficult to keep up with. While it may be possible to simulate contact of soft deformable objects at only 300 updates per second, rigid object contact may require well over 1000 updates for accurate feedback. In comparison, human vision only requires about 30 updates in order for animation to be perceived as smooth.

Another factor to consider is the complexity of the object surface being manipulated. If the instrument collides with more than one structure in a short amount of time, sampling update rate again needs to compensate.

Fidelity also depends upon the speed of movement of an object through the environment. Obviously, a fast moving object is more likely to collide with more surfaces and require higher fidelity than a slow moving object.

Force feedback can occur over multiple degrees of freedom. There may be directional forces along the x , y , and z coordinate planes. There may be torques resulting from rotations. Grip may need to be accommodated. The more the degrees of force feedback, the more difficult it is to accommodate a complex task in simulation.

Many applications do not require force feedback such as those designed to just assess cognitive decision-making skills. Others rely on physical models to provide force feedback such as the PercMentor (Simbionix). The UW transurethral resection of the prostate simulator utilizes a tension-based system,^a while many of the laparoscopic force feedback device uses a linkage-based device such as the Laparoscopic Surgical Workstation by Immersion.

Open procedures require high-fidelity force feedback and tactile feedback. Unlike laparoscopic procedures, open surgery tools do not work through a fulcrum that diminishes the forces as well as tactile feedback.

^aMantis, Mimic Technologies, Seattle, WA.

The use of sense of smell is probably underappreciated during surgical procedures.

The use of sense of smell is probably underappreciated during surgical procedures. Digiscents, Inc. is a company that has manufactured the ability to reproduce thousands of every day scents with a small cartridge that contains 128 primary odors. The combinations of these primary odors claim to effectively simulate virtually every smell. Some potential applications could include the smell associated with bowel injury and excessive cautery.

It is not always possible to represent all sources of sensory feedback in a virtual environment. In some cases, a possible alternative is cross-sensory substitution. In this case, one sensory stimulus is substituted for another. For example, speech might be converted into a visual display of text that can be read. It is important to be careful when employing cross-sensory substitution because the more you divert from standard sensory feedback, the greater the potential that simulation training will not carry over to the operating room.

In many applications, it is advantageous to incorporate additional sensory feedback that may not be found in the real procedure. Extra visual, audio, or haptics cues may help a beginner to initially learn a particularly difficult task. As the trainee becomes more comfortable with the task, this extra feedback is removed and the trainee is forced to rely on feedback that is actually found in the operating room. Sometime in the future, it may even be possible to add additional feedback to real procedures.

Augmented reality is the concept of superimposing transparent (not opaque) virtual images in real time over the real world as a frame of reference. Such a concept has already been demonstrated in an application that highlights the location of nerves during robotic radical prostatectomy.

Augmented reality is the concept of superimposing transparent (not opaque) virtual images in real time over the real world as a frame of reference. Such a concept has already been demonstrated in an application that highlights the location of nerves during robotic radical prostatectomy.

Step 6: Computer Processing Needs

On an average, computation power doubles every 18 months—a trend that has become known as Moore's law. This translates to an annual 67% increase in computing power. Since 1990, the growth in storage capacity has been outpacing Moore's law by a wide margin, advancing 12 times faster than processing speed (29). Data transmission technology has developed at a more modest rate with a 50% annual increase in bandwidth (Nielsen's law). Enormous amounts of data can now be processed in milliseconds and graphical rendering is approaching photorealism. High-end graphical applications use to require expensive workstations with a price tag greater than \$50,000. Now the same performance can be achieved on a personal computer that costs less than \$2000. All of this has led to remarkable advances in virtual reality and the improvements have not gone unnoticed by the medical community.

The processing power required for different simulators will vary because each simulated procedure will require different levels of graphical rendering, collision detection, deformation modeling, and haptic feedback. Processing power will directly affect latency and frame refresh rate.

Latency is a measure of the time between when a person moves a tracking device and when the computer displays the result of that tracking on the video screen. As latency exceeds 1/10th of a second, most people will become distracted by the disconnection between their actual movement and what they see moving graphically.

Frame refresh rate refers to the number of still images displayed per second. When the frame update rate is less than 20 frames per second, most people will perceive animation as jumpy or flickering. When displaying stereoscopic images (three-dimensional projections), the refresh rate needs to be at least twice as high to achieve smooth animation.

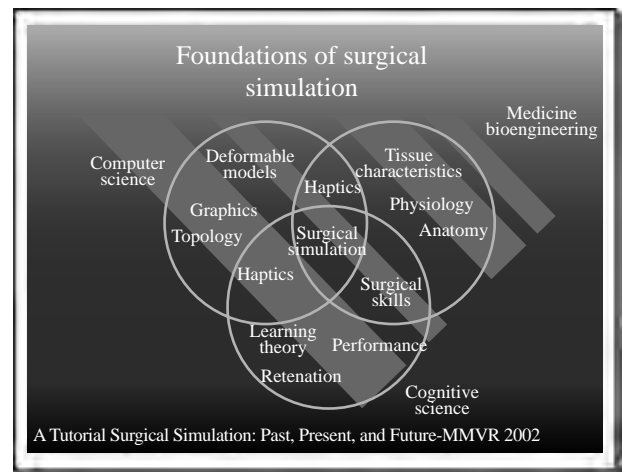
When considering processing power, one needs to consider not only the central processing unit but also the processing power of the graphics card. If the processing power of either is too low, the likely result will be extended latency and low refresh rates. The bus speed of a processor refers to the speed at which it can import and export data. Processing speed can become irrelevant if it takes too long to transfer data to and from the processor. Similarly, the speed of computer memory (or RAM) can create a performance bottleneck. To a lesser degree, the speed of hard drive storage can also affect performance. Finally, for computationally intensive applications, it can be very advantageous to use multiprocessor systems that divide processing labor between multiple processors and perform computations in parallel.

Latency is a measure of the time between when a person moves a tracking device and when the computer displays the result of that tracking on the video screen. As latency exceeds 1/10th of a second, most people will become distracted by the disconnection between their actual movement and what they see moving graphically.

Step 7: Build Team Collaborations

All of the disciplines involved in creating medical virtual reality simulation applications are highly technical and they therefore require extensive collaborations. Tendick et al. presented a Venn diagram showing the complexity of such a process.

FIGURE 2 ■ Source: From Tendick et al. *Medicine Meets Virtual Reality*, 2002.



Conferences such as “Medicine Meets Virtual Reality” and programs sponsored by TATRC, which occur annually, have bridged this gap in understanding between healthcare workers, behavioral scientists, and engineers. As a result, numerous productive collaborations have been initiated. As in any complex new discipline, the leading investigators in the field have pushed their knowledge and understanding towards the center of the chart shown in Figure 2.

Key team contributors often include virtual world programmers, graphics animation/modeling artists, and hardware/interface experts. It also helps to have a behavioral scientist familiar with learning theory to help guide the design and metrics. Finally, a subject matter expert physician is necessary to guide the whole process, perform frequent usability studies, as well as provide the medical content.

Step 8: Build and Render the Model

There are many modeling software programs including Maya[®],^b Rhinoceros-three-dimensional[®],^c etc, that allow models to be constructed and then exported for use in virtual environments. Often, a number of applications are used to create a complete set of simulation models.

The simplest models are based on two-dimensional images or pictures. This is often employed when simulating fluoroscopic procedures.

For example, a single image, or series of images, captured during a real procedure may be augmented during simulation to give the impression that the image or images are being captured in real time. The movement of a guide wire may be rendered on top of a fluoroscopy picture by updating only the pixels that represent the guide wire.

Creating three-dimensional models of tissue structures can be quite challenging. Typically, a set of medical images is sectioned, where contours are extracted from a structure of interest (using applications such as NIH Image and ScanTool). These two-dimensional contours are then used to create a three-dimensional model. The contours might simply be used to guide the artistic creation of a three-dimensional model using freeform modeling software. Another option is to connecting the contours with polygons to form a surface. It is also possible to fit a set of equations to the contours in order to define a surface or solid model.

Polygonal models are the most common models used in three-dimensional visualization.

They form a computationally “cheap” representation and are very versatile. Hardware-accelerated rendering of polygons is common. The most general class of polygon models can be called a “polygon soup,” which is a collection of polygons that are not geometrically connected and have no topology available. If the polygons form a closed manifold, then the model has well-defined inside and outside, which is very helpful when performing collision detection. If the manifold is convex, then this structure is even better suited for collision detection algorithms.

Parametric surface models are also popular. These surfaces are defined by equations, such as nonuniform rational B-splines. To render the geometries defined by these

The simplest models are based on two-dimensional images or pictures. This is often employed when simulating fluoroscopic procedures.

Polygonal models are the most common models used in three-dimensional visualization.

^bAlias Systems Corp, Toronto, Canada.

^cRobert McNeel and Associates, Seattle, WA.

representations, the equations are used to find a set of polygons to represent the object surface. One big advantage of parameterized surfaces is that polygon resolution can be set to match the rendering capabilities of a particular computer. In addition, collision detection is very efficient with parametric surfaces.

Volumetric models can be constructed of voxels, elements or implicit primitives. Unlike surface models, volumetric models include information about the interior of the geometry. This can be very helpful for governing collision detection and deformation modeling.

If a model is to be used only for visualization, a voxel representation is likely the most appropriate. A voxel is essentially a small cube (like a three-dimensional pixel) that is uniform in color and shading. Voxelized models are three-dimensional representations created by stacking together a series of two-dimensional image slices (such as computer tomography, magnetic resonance imaging, or ultrasound images). The regions in-between the slices are filled in by interpolating, or morphing, from one image to the next. Most medical imaging systems are capable of generating three-dimensional voxel models. Unfortunately, voxel models lack a surface definable with normal vectors. This can make it difficult to apply lighting effects (such as shading and reflection) and to enable collision detection and force feedback. Voxel representations can also require a tremendous amount of computer memory and storage.

One example of a widely used database enabling the construction of volumetric models is the National Library of Medicine's Visible Human Project.

This database consists of detailed sets of scans taken of a deceased human subject. Not only does this data set include computer tomography and magnetic resonance images, the subject was also physically sectioned (frozen and then sliced into thin slabs) so that pictures could be taken of the slices.

A greater degree of interaction can be achieved with volumetric models based on elements. An element might take the shape of a tetrahedron or cube. The elements are then pieced together, like a set of Legos to achieve a three-dimensional volumetric model. Each element may have its own color, shape, and specific behavior. Element models are ideally suited for deformation modeling.

An extension of element-based models is an implicit representation. Rather than using thousands of small elements to form a model, a small number of implicit primitives can be blended together to form complex geometric structures. Examples of implicit primitives are cubes, spheres, cones, cylinders, etc. These objects can be defined with simple equations that determine if a coordinate in three-dimensional space is inside, outside or on the surface of the object. A number of different implicit primitives can be used to create a complex shape using Boolean operations (union, difference, subtraction). The big advantage of implicit models is that collision detection is very efficient. A disadvantage is that the implicit equations must still be converted to a set of polygons that can be rendered. Finding these polygons can be very computationally intensive. It should be noted that implicit surfaces (a two-dimensional version of an implicit solid) sometimes have applications in simulation. Implicit surfaces are built from primitives such as triangles, squares, circles, etc. A closed manifold convex polygon model is essentially an implicit surface model.

A more detailed delineation of the types of volumetric models is illustrated in Figure 3.

Once the model has been created, it needs to be rendered. Rendering engines such as Open graphics library, Sun Systems, Direct X (Microsoft), etc. automatically determine three-dimensional perspective, lighting, shading, and allows the developer to apply texture images (Fig. 4).

Step 9: Texture Maps and Special Effects

Texture maps can be applied to polygon models in order to make them look like a real tissue structure. A texture map is synonymous to a two-dimensional sticker that is


One example of a widely used database enabling the construction of volumetric models is the National Library of Medicine's Visible Human Project.

An extension of element-based models is an implicit representation.

FIGURE 3 ■ Volumetric model types.



FIGURE 4 ■ Three-dimensional rendering of volumetric model.



Developers can provide data derived from in vivo or in vitro experiments that can be used to create algorithms in the virtual environment.

wrapped around the three-dimensional surface. A texture map might be a picture of the real anatomy or a set of pictures stitched together to form a visually appealing skin. It is also possible to use video clips to form a “live” texture map so that the look of the surface changes over time (30).

Developers can provide data derived from in vivo or in vitro experiments that can be used to create algorithms in the virtual environment.

The University of Washington did this when calibrating blood flow, irrigant, and prostate tissue resection algorithms, for their transurethral resection of the prostate simulator, as well as when obtaining information on the material properties of organs/tissues (30–32). Another possible use of texture mapping is for tissue blanching.

Special effects make models look more realistic. A technique known as bump mapping is commonly employed. This is a technique by which individual pixels on the two-dimensional texture map are illuminated to different degrees to give the impression that the surface is textured rather than flat (Fig. 5). Lighting sources can also be simulated in order to add ambient light, specular and diffuse light to a scene. Without lighting, it is very difficult to perceive an object as three-dimensional. Shadowing can also help to improve visual realism.

Other special effects such as bleeding across solid tissue surfaces, irrigation, smoke, electrocautery, fragmentation, and debris are frequently modeled using particle-flow methods (Fig. 6).

Step 10: Medical Instrumentation

Mock-ups or real instrumentation such as a blunt “needle” as in the PercMentor by Symbionix,^d or a retrofitted resectoscope/foot pedal as in the case for the UW transurethral resection of the prostate simulator can be fabricated for a simulator (Figs. 7 and 8). Every application will call for different instrumentation requirements. Often the instruments need to be properly fitted with tracking devices, which track the relative components in space with respect to the virtual patient. Because these tracking devices are sometimes large and have connecting wires, it can be challenging to integrate them with a medical instrument without significantly changing the look and feel of the instrument.

FIGURE 5 ■ (A) Model of the urethra, prostate, and bladder rendered without lighting. (B) Model of the urethra, prostate, and bladder rendered with lighting. (C) Model of the urethra, prostate, and bladder rendered with lighting and a texture map. *Source:* From Ref. 33.

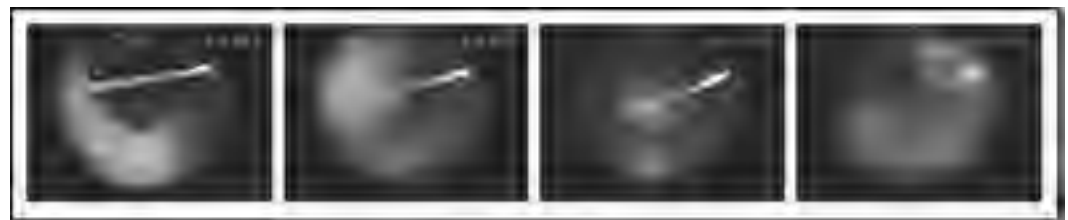



FIGURE 6 ■ Video texture maps created in vitro for the UW TURP simulator. *Source:* From Ref. 30.

^dPercMentor, Symbionix, Cleveland, OH.



FIGURE 7 ■ UW TURP simulator with ACMI 27French resectoscope. Polyhemus tracking devices located on the Iglesias working element and within an empty camera “shell” in this case provide for tracking.



FIGURE 8 ■ Blunt needle for percutaneous access.

Tracking devices are electrical/mechanical components attached to the surgical instruments and/or the simulator, which can track and locate where your instrument or model is in space.

Step 11: Tracking Solutions

Tracking devices are electrical/mechanical components attached to the surgical instruments and/or the simulator, which can track and locate where your instrument or model is in space.

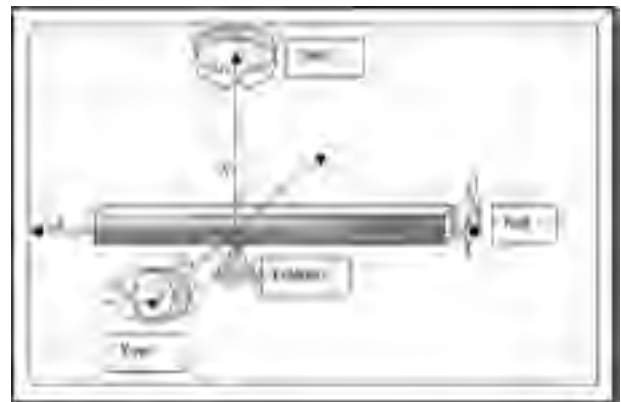
Depending on the application, they can provide multiple degrees of freedom (Fig. 9). The most basic tracking device is an “on and off” switch that is one degree of freedom. A simple example of two degrees of freedom tracking device is the mouse. The mouse moves only in one plane and yields position coordinates in terms of X and Y.

In general, most spatial movement can be defined with six degrees of freedom. This includes spatial positioning in the horizontal (X), vertical (Y), and depth (Z) directions. In addition, three degrees of orientation (rotation, yaw, and pitch) can be defined.

In some cases, more than the standard six degrees of freedom will be required. For example, suturing involves seven degrees of freedom for each hand (translation in the X, Y, and Z direction, rotation about the X-, Y-, and Z-axis, and grip). Another example of a simulator requiring additional degrees of tracking freedom is transurethral resection of the prostate simulation. To track a resectoscope, it is necessary to include the rotation of the stopcocks, loop extension, camera rotation, foot pedals, etc.

In order to provide visual realism, tracking devices need at least 30–60 Hz (or updates per second). Most people will not perceive an upgrade in animation quality beyond this update level. Force feedback requirements are much higher. To simulate smooth force feedback with soft tissue, it is usually necessary to update position tracking at no less than 300 Hz. Requirements are even higher when modeling hard tissue

FIGURE 9 ■ Degrees of freedom defined for an instrument working on a fulcrum, is present with endoscopy. In many endoscopic applications, there is a fixed entry port into a body cavity, and therefore movement along the X- and Y-axes does not usually occur. Most endoscopic applications need at least four degrees of freedom (movement along the Z axis, pitch, roll, and yaw). In open procedures and laparoscopic simulations where port placement may vary, tracking along the X- and Y-axes would also be desirable.



structures, such as bone. Typically a tracking should be sampled at over 1000 Hz to accurately model the feel of hard objects.

A number of companies sell tracking hardware, such as Ascension and Polhemus®. Building your own tracking systems using optical encoders and fiducial markers is also possible and can be much more affordable. Many force feedback systems include their own tracking capability, such as the Phantom^e and the Mantis.^f

Orientation and calibration can be accomplished using in vivo or ex vivo techniques.

When at all possible, it is important to try and avoid relying on subjective calibration of metrics, even from the most experienced subject matter experts. Haptics calibration is notoriously unreliably consistent between subjects.

For the purposes of interactivity and data acquisition, any analog data (measured in terms of voltage) need to be converted into a digital format.

A crucial element of virtual reality simulation is determining when a surgical tool has collided with tissue structures or other tools.

The difficulty with surgery simulation is that there are usually a number of deformable object in the scene.

Step 12: Orientation and Calibration of Metrics

Once the model has been created, it needs to be oriented properly with respect to the instrument/tracking devices. The metrics also need to be properly calibrated.

Orientation and calibration can be accomplished using in vivo or ex vivo techniques. One example of an in vivo technique involved the calibration of irrigation flow for the UW transurethral resection of the prostate simulator, in which flow rates in and out of the bladder under different stopcock settings and scope diameters were recorded with a uroflowmeter. An example of an ex vivo technique involved the calibration of blood loss with the UW transurethral resection of the prostate simulator, where bleeding movies were quantified and captured under different fluid flow states (30).

When at all possible, it is important to try and avoid relying on subjective calibration of metrics, even from the most experienced subject matter experts. Haptics calibration is notoriously unreliably consistent between subjects.

Step 13: Digital Acquisition Devices (Input/Output Boxes)

For the purposes of interactivity and data acquisition, any analog data (measured in terms of voltage) need to be converted into a digital format.

This is accomplished with the use of digital acquisition or interface devices or input/output boxes. These devices are fairly inexpensive and effectively translate actions made by the simulator's tools from electrical signals to meaningful code translated by the computer. They also integrate tracking input with display and haptic output through either a USB, firewire, or parallel port. Examples of devices that might require analog to digital conversion include dials and switches, optical encoders for tracking, and strain gauges that monitor applied forces.

Step 14: Collision Detection and Deformation

A crucial element of virtual reality simulation is determining when a surgical tool has collided with tissue structures or other tools.

In addition, tool contact can force one tissue structure into other tissue structures, which in turn could lead to even more collisions. Determining if and where collisions take place can be very computationally expensive. As discussed in step 8, models are typically rendered in terms of polygons. The objective is to determine if a point on the surface of one object has crossed the face of a polygon on another object. There can be tens of thousands of nodes (the corners of the surface polygons) on the tools and tissue structures in a scene that must be tested against tens of thousands of polygons.

A variety of techniques have been created to avoid the necessity to test every point against every polygon. The objective is to cull all the model polygons into smaller sets of "probable" collision polygons. Finding collisions with rigid objects is relatively straightforward. This is because all the polygons on an object stay in relative position to each other. For this reason, it is possible to sort surface polygons into a number of bounding volumes, such as a sphere, cube, or cylinder that can help collision algorithms zero in on polygons of probable collision. By first testing a point to see which bounding volume it is in, it becomes possible to reduce the total number of polygons that might come into collision. This is one reason why implicit solid models (as discussed in step 8) can offer tremendous performance advantages when it comes to collision detection. It is also possible to put bounding volumes within bounding volumes to further subdivide a model into probable collision polygons. This type of architecture is often referred to as a voxel tree.

Specific hardware is often added to the computer platform just to accommodate collision detection. As mentioned in step 6, multiprocessor computers are sometimes used in simulation. Often the reason is so that one of the processors can be dedicated to collision detection. Graphics cards can also be converted to collision detection systems.

The difficulty with surgery simulation is that there are usually a number of deformable object in the scene.

^eSensable Technologies, Woburn, MA.

^fMimic Technologies, Seattle, WA.

Once an object deforms, techniques such as using a voxel tree, become ineffective because polygons are likely to stray out of their original bounding volumes. For this reason, a tremendous amount of research has been dedicated to methodologies for reducing the computational cost of collision detection when using deformable models. This is a complex issue that routinely receives a lot of focus at conferences such as MM virtual reality and SIGGRAPH.

After collision takes place, another difficult problem is determining how a model should deform. This often requires even more computation than collision detection.

Soft tissue is an extremely complex material and very difficult to accurately model. Not only does soft tissue contain three phases (solid, liquid, and gas) but also material properties vary significantly from person to person, tissue structure to tissue structure, and even within the same tissue body.

While continuum mechanical-based methods have been demonstrated to accurately model tissue structures such as cartilage, the majority of soft tissue types have yet to be modeled. More importantly, the methodologies that exist are so computationally intensive that it can take hours, or even days, just to model a single scenario for tissue deformation. This hardly applies to virtual reality where a new solution must sometimes be found a thousand times a second.

There is definitely a long way to go before modeling tissue deformation in surgery simulation becomes highly precise. However, as long as the deformation modeling is realistic enough to promote learning, it might be deemed “good enough.” Most simulators actually employ “video game-like” techniques that completely ignore the tissue material properties. Spring models are most commonly used. Techniques vary, but many simply place a linear representation of a spring on the edge of every tetrahedron in a volumetric element model (step 8). Moving a node on a model compresses a set of springs that then in turn push into other nodes. Iterating through all the springs will result in a global deformation. One example of a spring-based model is the LapMentor simulator sold by Simbionix.

Beyond the problem of the inherent instability that often makes spring models appear to “flutter,” spring models are also very difficult to calibrate. Determining an appropriate stiffness for every spring to approximate realistic deformation can be extremely difficult and labor intensive. Also, a spring model does not maintain its overall volume as is natural for most materials. Just the same, the trade-off is fast performance for limited accuracy.

A number of new techniques based on continuum mechanics have started to emerge. Finite element modeling is the industry standard for modeling stress, strain, and deformation in objects such as bridges, mechanical parts, car frames, cell phones, prosthetics, and more. Unfortunately, this methodology in its raw form does not lend itself to real-time applications. Fortunately, some versions of the technique have been recently adapted for application to surgery simulation. Now it is possible to measure a subject's soft tissue material properties and plug them in to a finite element model. Examples of finite element modeling-based simulators include the suturing simulator developed at the University of Washington and the robotic prostatectomy simulator currently under development at Mimic Technologies, Seattle, Washington, U.S.A.

While finite element models are more accurate than spring models in terms of stability, deformation, and force feedback, the method still has its limitations.

In particular, a lot of computation is required to build the mathematical representation of a finite element mesh. When the mesh is altered, such as when cutting through skin, the mathematical representation of the mesh must be updated. Significant mesh updates can be difficult to accommodate in real time. This limits the use of finite element models to certain surgery scenarios.

Step 15: Displays

Examples of common displays used in virtual reality include head-mounted displays, shutter glasses, autostereoscopic systems, CAVES, and video monitors. Current video monitors in surgery are a common interface for relaying images captured through a variety of scope designs. This interface is the easiest to recreate in simulation, since the standard PC uses a monitor interface anyway. However, as simulation and surgery progress, an understanding of other more immersive-type displays should be understood.

When people think of virtual reality, they often think of stereoscopic display or three-dimensional views that pop right out of the screen. The eye captures two-dimensional images on the retina and the human mind perceives distance or depth by using the many available depth cues. The physiological cues include accommodation, convergence, and binocular parallax. Accommodation is the eye muscle tension needed to change the focal

Soft tissue is an extremely complex material and very difficult to accurately model. Not only does soft tissue contain three phases (solid, liquid, and gas) but also material properties vary significantly from person to person, tissue structure to tissue structure, and even within the same tissue body.

While finite element models are more accurate than spring models in terms of stability, deformation, and force feedback, the method still has its limitations.

length of the eye lens in order to focus at a particular depth. Convergence refers to the muscle tension required to rotate each eye so that it is facing the focal point. Binocular parallax means that each eye sees a slightly different view. Psychological cues that contribute to seeing in three-dimensional including relative size, occlusion of far objects by close ones, linear per-spective, shading, texture gradients, atmospheric effects such as color and haze, and motion parallax.

Common run time graphics (such as Open GL) automatically calculate shading, occlusion, relative size, texture, atmospheric effects, etc. This allows the perception of distance in a two-dimensional display, but objects do not appear to pop out of the screen. To display a scene in stereo, it is necessary to address accommodation, convergence, and/or binocular parallax. Stereoscopic displays typically rely only on binocular parallax, where each object in a virtual scene is shown to each eye at a slightly different angle and view position (relative to each eye). Methods for displaying different views to each eye include color filters, polarizing filters (which requires a three-dimensional projection system), shuttered vision, and directional filters.

Stereoscopic display can be achieved with a simple cathode ray computer monitor and shutter glasses.

Shutter glasses alternately occluded each eye and this is synchronized with the computer screen. This makes it possible to show a different display to each eye. Because stereoscopic display requires two separate alternating views, the refresh rate must be doubled as compared to that required for standard animation. If the overall refresh rate is less than 60 Hz (30 Hz per eye), then many viewers will perceive a flicker in the display. Shutter glasses can also be coupled with large projection displays, such as found in theme parks or IMAX theaters.

It should be noted that using shutter glasses with a display screen is not considered a “true” three-dimensional display. This is because accommodation and convergence are ignored as the screen is always the same distance away. Many people will get a headache from extended viewing with these displays because there remains a conflict between the perceived distance of virtual objects and the actual focal distance of the display.

Autostereoscopic systems do not require glasses and divide two-dimensional displays into two sets of viewable pixels, which are displayed to each eye separately. The downside is that this display required a fixed viewing position.

At the sacrifice of display resolution, multiple sets of pixels can be utilized, which enables more stereo viewing positions and wider viewing freedom. Some advanced systems will track the viewer’s eye positions and adjust the aim of each pixel set so that they follow the eyes.

Head-mounted displays consist of an image source with collimating optics (each eye sees a different display). The head-mounted display image may be a cathode ray tube (like a small TV), a liquid crystal display (like a laptop screen), or a virtual retinal display by which images are displayed directly on the retina (34).

A feature typically coupled with head-mounted displays is head tracking. This makes it possible to update the user’s view based on where their head is relative to the virtual scene.

Volumetric displays are an emerging technology that allows for true three-dimensional display.

These systems show pixel information in a predefined volume of three-dimensional space, rather than just a flat two-dimensional surface. One application of a volumetric display uses a varifocal mirror that oscillates at a high rate enabling variable focal distances. By synchronizing the image shown on a reflecting screen with the optical power of the mirror, any point of a given volume can be illuminated. Another experimental display uses the concept of emissive volume. This display has given volume filled with a medium that can emit light from any part of its interior as a result of an external excitation (such as from different wavelength lasers). One key problem with this approach is finding the appropriate substrate to serve as the medium. Another approach is the rotating screen. A flat screen rotates at around 600 rpm. For every angular position of the screen, an optical system projects a scene corresponding to the perspective associated with the screen angle. The final result is the three-dimensional image of the object, viewable in 360°. Most volumetric displays are still in experimental development and it may be some time before they find a commercial market.

CAVE® is a room-sized advanced visualization solution that combines high-resolution DLP™ based stereoscopic projection technology and three-dimensional computer graphics to create the illusion of complete sense of presence in a virtual environment.

The CAVE was the first virtual reality technology in the world to allow multiple users to immerse themselves fully in the same virtual environment at the same time. This

Stereoscopic display can be achieved with a simple cathode ray computer monitor and shutter glasses.

Autostereoscopic systems do not require glasses and divide two-dimensional displays into two sets of viewable pixels, which are displayed to each eye separately. The downside is that this display required a fixed viewing position.

Head-mounted displays consist of an image source with collimating optics (each eye sees a different display). The head-mounted display image may be a cathode ray tube (like a small TV), a liquid crystal display (like a laptop screen), or a virtual retinal display by which images are displayed directly on the retina.

Volumetric displays are an emerging technology that allows for true three-dimensional display.

CAVE® is a room-sized advanced visualization solution that combines high-resolution DLP™ based stereoscopic projection technology and three-dimensional computer graphics to create the illusion of complete sense of presence in a virtual environment.

CAVES are quite expensive and have not been widely utilized for medical simulation, but are beginning to be explored as a tool for medical team/disaster and immersive training.

is accomplished by using four, five, or six projection surfaces and numerous projectors that relay stereoscopic images when viewed with three-dimensional glasses (glasses based on either color filters, polarizing filters, or shuttered vision). CAVE systems are usually coupled with three-dimensional “pointer” tools that can be used to interact with the environment and each other.

CAVES are quite expensive and have not been widely utilized for medical simulation, but are beginning to be explored as a tool for medical team/disaster and immersive training.

Holograms are images made on high-resolution film that captures patterns of light waves emanating from an object when illuminated by a laser. When light shines through this special film, the light patterns are reproduced, giving a three-dimensional effect. Holograms usually involved fixed scenes with no animation.

Step 16: Raw Data Collection Repositories

Virtual reality simulators can automatically collect enormous amounts of data relevant to a subject’s performance. Not only should data collection and storage be considered per training institution, but all training institutions collectively that utilize simulation training. These data need to be organized in a useful and meaningful fashion. What may be meaningful to one may be useless to another. Therefore, efforts to create consolidated, centralized databases for simulators have been made. One such example of such a database was created at the University of Washington by Weghorst, Fried, and colleagues (Fig. 10).

Step 17: Graphics-User Interfaces

A user-friendly graphics user interface is usually present on all computer-based simulators. It is an interface that allows the user to navigate through training modules and select and adjust features of the simulator by pressing graphical buttons, pulling down menus, adjusting sliders and/or by entering data in designated fields.


An intuitive interface can be crucial for efficient utilization of a simulator. The graphics user interface should allow the user to easily access simulation didactics, and cognitive training for issues related to the psychomotor/visual-spatial tasks to be completed. (recommended at the Conference on Surgical Errors, Washington, D.C., 2003). This embeds a curriculum, allows the simulator to be used independent of a mentor, and allows for more accurate characteristic of the subject’s performance. Some commonly used modalities for graphics user interface design include Microsoft Foundation Class, Redmond, Washington (MFC environment-typical windows buttons/menus) and HTML-based interaction common in most websites.

An intuitive interface can be crucial for efficient utilization of a simulator.

Step 18: Usability Studies

As each of the above major components of the simulator has been completed, informal usability studies with the subject matter expert should be done on a frequent basis. Developers intimately familiar with a simulator may not be able to fairly judge how easy a simulator will be to use and if the simulator is adequately addressing the learning objectives defined in step 1. Repetitive testing throughout development will help to insure that developers and subject matter experts are on the same page. Once the complete package is deemed realistic, accurately measures and logs metrics, is cutout user-friendly and adequately meets the training needs defined by the subject matter expert, the simulator is ready to undergo rigorous validation studies.

FIGURE 10 ■ AHRQ sponsored centralized database for simulators, University of Washington.



Validation studies must be conducted before a simulator can be implemented in the curriculum of training programs and considered for use as an assessment tool. Validation results of a training simulator should be reproducible.

Step 19: Validity/Reliability Studies

Validation studies must be conducted before a simulator can be implemented in the curriculum of training programs and considered for use as an assessment tool. Validation results of a training simulator should be reproducible.

Validation protocols should be even more rigorous if the simulator is to be used as a tool for trainee assessment as the stakes are much higher for tools of assessment. In appropriate use of assessment, data could be used to discipline existing practitioners, prevent others from entering the field, or performing certain tasks.

Though the cognitive science community has a much more sophisticated grasp on validation measures, Litwin has provided translation for application of medical surveys while Gallagher et al. (35) has provided translation for use in surgical simulators.

When considering the validation of a simulator, a number of validity criteria should be considered:

1. *Face validity*: A type of validity assessed by having experts review the contents of a test to see if it seems appropriate. It is a very gross, subjective type of validation and usually only used when building the simulator.
2. *Content validity*: An estimate of the validity of a testing instrument based on a detailed examination of the contents of the test items. It is also subjective in nature. It is obtained when asking experts to review each item to determine whether it is appropriate to the task intended to be trained. The overall cohesiveness of the simulator is assessed, determining whether it contains the realism, steps, and skills that are used in a given procedure.
3. *Construct validity*: A set of procedures to evaluate a testing instrument based on the degree to which the test items identify the quality, ability, or trait it was designed to measure. This is a much more complex measure of validity and there are many constructs that can be examined. The most basic example is the ability of an assessment tool to differentiate experts and novices performing a given task.
4. *Concurrent validity*: An evaluation in which the relationship between the test scores and the scores on another instrument purporting to measure the same construct are related. It can be thought of as a subset of construct validity. It is achieved when testing a simulator versus gold standard methods of training. One problem with this method in surgical skills training is that very often no gold standard exists.
5. *Discriminate validity*: An evaluation that reflects the extent to which the scores generated by the assessment tool actually correlate with factors with which they should correlate. Another subset of construct validity, it is a sophisticated analysis looking at correlations. One example is a simulator's ability to differentiate ability levels within a group with similar experience, such as discriminating abilities of all the residents in postgraduate year 1.
6. *Predictive validity*: The extent to which the scores on a test are predictive of actual performance. Predictive validity is probably the most important validation measure to be considered given our training dilemma. It predicts who will and who will not perform actual surgical tasks well.

A reliable simulator measures something in a reproducible manner.

A reliable simulator measures something in a reproducible manner. Standards of acceptable reliability depend on the purpose of the test and the cost of misclassification. Usually expressed as a value between 0 and 1, it represents the proportion of the variability in scores attributable to true differences between subjects (36,37). Wanzel et al. (38) used a reliability of ≥ 0.8 , as there was a high cost of misclassification because they were using their tool for assessment.

One of the common pitfalls for validation studies in the surgical sciences has been to use the same device that is being used for training (the intervention), as the very same tool used for evaluation pre- and post-training. Such a design merely shows that training on an instrument leads to improvement on that very instrument and lacks tangible evidence of translation to clinical skills.


For subjective evaluation, the agreement between two different observers is known as inter-rater reliability and agreement between observations on the same subject on two separate occasions is known as intra-rater reliability.

For virtual reality simulators that generate objective data, this is less of an issue, but validation of these instruments has and should continue to be correlated with reliable subjective evaluation.

One useful measurement to obtain once a simulation tool has been embedded in the curriculum for some time is what is called a training transfer ratio (Fig. 11). This is

For subjective evaluation, the agreement between two different observers is known as inter-rater reliability and agreement between observations on the same subject on two separate occasions is known as intra-rater reliability.

FIGURE 11 ■ In this hypothetical example, the slope of the line at any point would represent the training transfer ratio (TTR). For a novice who has logged five simulation hours, this may be equivalent to five operating room hours ($TTR = 1.0$), as they may get more benefit from the simulator, while someone who has logged 15 operating room hours in this case would have a $TTR = 0.40$. Clearly, the value of simulation at different levels of training is unknown and this would need to be worked out for each skill task.



defined as the number of simulated case hours equivalent to one operative case hour. Such a ratio may not be quite so simple as simulated cases may be more useful for less experienced trainees than for those with experience. This ratio truly represents the derivative or slope of the learning curve at any given point during training, which is just that a “curve.” In the aviation industry, this ratio has been estimated as half hour simulated time = one hour logged in a real plane.

Step 20: Commercialization

Once a simulator has achieved at least face and content validity, it may be considered for commercialization. A simulator may prove to be an extremely valuable training tool, but if it is too expensive for most training institutions to purchase, there is no chance that the simulator will be marketable. Effective implementation of step 2 will insure that there is a demand for a simulator and therefore justify development, manufacturing, and marketing expenses.

There are a variety of routes to take when commercializing a simulator. While a number of companies have been founded on new simulators, the most likely rout to commercialization is licensing the technology to an existing simulation company. There have been a number of academically developed simulators, which have been licensed to commercial entities.

Successful licensing depends on enlisting the help of an academic institution's department of technology transfer and licensing. A relationship between developers and technology transfer officials should be established at the onset of development so that plans can be made to protect future intellectual property.

Without proper legal documentation of the intellectual property, there is nothing to keep industry from reproducing what it sees discussed in publications and that which is demonstrated at conferences.

It is therefore important to follow university protocol when demonstrating the simulator to the public. Otherwise, commercialization potential might be forfeited.

Besides preparing legally for the licensing of a simulator, it is important to consider how a company might integrate a simulator into their current product line. Thorough documentation of methodology and software code is a must. Rarely will a simulator be used “as is” once a company licenses it. Typically, code and methods are adapted to fit within the architecture of a company's existing simulation platform and training protocol. The more difficult it is to decipher licensed code and methods, the more hours a company will have to invest in integration. The greater the integration effort required on behalf of a company, the less value they see in a license agreement.

Step 21: Implementation for Training

It is the author's belief that in order to be implemented into training programs, a simulator should at least achieve reliable face, content, and construct validity.

Predictive validity is probably not necessary for the purposes of training. Again the simulator must fit into a curriculum and it is that curriculum that must be supported. A plan for integration into curriculum should be discussed at the onset of development to insure that there is a place for the simulator after it is completed.

Step 22: Define the Learning Curve

As a virtual reality simulator is used at multiple institutions for the purposes of training, enormous amounts of data can be collected to show how a trainee learns a given procedure. After a simulator has been implemented into curriculum for a number of years,

Successful licensing depends on enlisting the help of an academic institution's department of technology transfer and licensing. A relationship between developers and technology transfer officials should be established at the onset of development so that plans can be made to protect future intellectual property.

It is therefore important to follow university protocol when demonstrating the simulator to the public. Otherwise, commercialization potential might be forfeited.

It is the author's belief that in order to be implemented into training programs, a simulator should at least achieve reliable face, content, and construct validity.

The use of virtual reality simulators for screening resident applicants, resident assessment, and physician credentialing should likely be reserved until after predictive validity and learning curves have been reliably established, since then and only then accurate projections as to a subject's performance can be made.

true learning curves with associated outcomes and standard deviations can be established. This makes it possible for the learning curves of surgical procedures to be truly defined and targets for remediation can be validated and implemented.

Step 23: Implementation for Assessment/Credentialing

The use of virtual reality simulators for screening resident applicants, resident assessment, and physician credentialing should likely be reserved until after predictive validity and learning curves have been reliably established, since then and only then accurate projections as to a subject's performance can be made.

The stakes are otherwise too high in these situations to rely on less rigorous methods of validity and a lack of the establishment of a learning curve. The use of simulators for assessment and credentialing is destined to play an important role in medical education; however, it may take the better part of a decade before this becomes a reality.

SURVEY OF VIRTUAL REALITY UROLOGIC SIMULATORS

Surgical simulation modules have been classified according to whether they train the technical components of a procedure or strictly the cognitive components. Basic skills trainers train basic psychomotor and/or visual spatial skills that are proposed to translate into improved skills in clinical application. Simple task trainers focus on a specific construct within the context of a procedure like trocar insertion. Many of the existing box trainer physical models are examples of simple task simulators. Complex task trainers focus on a more complicated construct such as percutaneous access to the kidney or the renal hilar dissection and transection. Complete procedure modules allow the user to do cases from start to finish and may include simple and complex task trainers as submodules. The UW transurethral resection of the prostate simulator and the ureteroscopic module for UroMentor are examples of such trainers. Cognitive training modules are designed to provide for training and assessment of medical decision making and interactive mental surgical rehearsal and are less focused on the visual-spatial/psychomotor components. The following is a review of known current applications.

Digital Rectal Examination Simulators

Digital rectal examination for prostate cancer is an important basic skill for any urology training program. The gold standard method of teaching prostate cancer detection is either on patients with a repeat examination being done by the trainer or with a physical model simulator like the one provided by Merck, Heath Edco,^g "prostate training kit." Unlike many of the other skill sets in urology where visual feedback dominates over tactile feedback, with digital rectal examination, the sense of touch is paramount. Using a silicon graphics inc. workstation, four prostates were modeled, which were similar to the Merck physical models, and a PHANTOM haptic interface was used to provide force feedback.

Medical students had a 67% correct diagnosis rate of malignant versus nonmalignant cases compared with 56% for urology residents. Residents felt the content (force feedback) lacked realism and concurrent validity was not demonstrated, as residents were able to correctly identify malignancy on the Merck trainer (gold standard) 96% of the time (39).

Pugh et al. designed a pelvic examination simulator that also uses force feedback, which is now owned and distributed by Medical Education Technologies Inc. (METI).^h It will soon include a digital rectal exam module.

Percutaneous Access

Percutaneous access is a skill set that requires excellent visual-spatial awareness and experience.

Simbionix designed a module on the UroMentor platform called PercMentorⁱ that attempts to train these skills. It provides a mannequin and a needle that is tracked as it enters the virtual anatomy. The kidney exhibits respiratory variation and the trainee has

Medical students had a 67% correct diagnosis rate of malignant versus nonmalignant cases compared with 56% for urology residents. Residents felt the content (force feedback) lacked realism and concurrent validity was not demonstrated, as residents were able to correctly identify malignancy on the Merck trainer (gold standard) 96% of the time.

Percutaneous access is a skill set that requires excellent visual-spatial awareness and experience.

^gWaco, Texas, U.S.A.

^hSarasota, Florida, U.S.A.

ⁱSimbionix, Lod, Israel.

to navigate the needle into the calyx and slip a wire past the virtual stone. The user learns c-arm manipulation and can either use the standard fluoroscopic view or the anatomical view as a teaching aid. Metrics include time to task, injury to blood vessels, perforation of the collecting system, amount of contrast used, and rib injuries. Matsumoto et al. presented data in abstract form showing that novice residents from two residency programs who train on the simulator have fewer attempts, use less fluoroscopy, and have fewer errors on the simulator than those who do not train between trials. Content, construct, concurrent and predictive validity studies are currently lacking but are underway. Training in ultrasound-guided access and percutaneous lithotripsy/nephrolithotomy currently are not features of this simulator, but would add substantially to this product.

One of the oldest cognitive “simulators” is the surgical atlas.

COGNITIVE SIMULATION ENGINES

One of the oldest cognitive “simulators” is the surgical atlas. Frank Hinman Sr.’s *Atlas of Urological Surgery* has been an invaluable source and reference for physicians in practice as well as urology trainees to prepare them cognitively for the cases they were to encounter. The use of videotapes, though a less accessible media, added another level of presence. Both of these training tools are effective but passive in nature.

Computer-based simulators created to train the cognitive aspects of procedural training arguably provide “virtual reality,” though they are less immersive in nature than those that also provide technical skills training. Considering that it has been argued that 85% of performing a surgical procedure involves the cognitive domain, cognitive simulators have probably been unrightfully de-emphasized and underutilized in surgical curriculum. A couple of examples with a potential role in urologic curriculum have been provided. Advanced cardiac life support is required of every new surgical intern. One of the first computer-based medical simulators was designed by Dr. Howard Schwid, an anesthesiologist in Seattle, Washington. The anesthesia simulator recorder to train management of critical events combined a graphic display of the operating room with mouse-driven input and uses an integrated set of physiological and pharmacological models to predict patient responses. It has undergone multi-institutional content, concurrent, construct and predictive validity for management of emergency situations in a population of anesthesiology trainees. Such a program has not been tested in residents of other specialties, but could be examined for its utility in surgical curriculum (40–48). Sweet et al. recently designed SimPraxis™, a software engine that provides interactive cognitive simulation and rehearsal of complex open surgical procedures. It has a DVD format and runs on a standard laptop and combines the simple format of an atlas with video as well as mentored instruction and provides objective feedback to the user. The prototype pelvic lymph node trainer begins with the indications, technical tips, and potential complications of the surgery from an expert author. It challenges the user to choose the actor (surgeon or assistant) and the appropriate instrument and then to apply the instrument in the correct position for each of the defined tasks of the operation. When performed correctly, the simulator plays the video clip of the subtask with commentary. Incorrect cognitive decisions are followed by instruction on the proper technique and the user is then allowed to try again. A “practice” mode provides mentorship in the form of hints from a “virtual” expert in the field. A “testing” mode is web-enabled and designed to monitor and log the user’s selections including any requests for assistance. The software logs the frequency and types of errors. This record is then available for submission to residency directors, CME administrators, and/or later review by the user. Face and content validity have been established and construct, concurrent and predictive validity studies are underway (49).

The simplicity of such an approach circumvents some of the financial/technical roadblocks that virtual reality technical skills trainers have encountered.

When designed and studied in coordination with their technical skills trainer counterparts, cognitive trainers may actually be able to determine not only if an error has occurred but also dissect whether it was an error in cognition, psychomotor skills, or visual spatial orientation.

When designed and studied in coordination with their technical skills trainer counterparts, cognitive trainers may actually be able to determine not only if an error has occurred but also dissect whether it was an error in cognition, psychomotor skills, or visual spatial orientation.

COMPLETE PROCEDURES

Transurethral Resection of the Prostate Skills: A Potential Training Crisis

Transurethral resection of the prostate remains the gold standard surgical procedure for successfully treating medically refractory lower-urinary tract symptoms of benign prostatic hyperplasia or benign enlargement of the prostate (50,51), a chronic and potentially

progressive condition that is symptomatic in approximately 5.6 million men in the United States alone.

The resection skills acquired during the performance of this procedure are also thought to translate to those used to resect benign and cancerous lesions in the bladder (TURBT) and in ablating posterior urethral valves in infants (TURPV). This set of skills remains a core skill set for a urologist in training (52).

TURP is challenging to teach and learn.

Transurethral resection of the prostate is challenging to teach and learn. Performing this procedure involves the ability to work in a small three-dimensional space while receiving two-dimensional visual feedback requiring the operator to have or develop unique visual-spatial abilities. It also requires that the operator have adept psychomotor abilities, as one has to continuously and simultaneously navigate the scope and the loop while managing the electrical current with the use of both hands and a foot pedal. Additionally, the procedure is performed in a fluid environment and the field is often visually obscured by tissue and blood, which can be disorienting to the training resectionist.

TURP is potentially dangerous.

Transurethral resection of the prostate is potentially dangerous. Within this small amount of space, there are also many potential anatomical hazards, where an error in judgment, visual-spatial or psychomotor skill could potentially result in devastating consequences such as total urinary incontinence, rectal injury, ureteral injury, dorsal vein injury with profuse blood loss, erectile dysfunction, and life-threatening levels of hyponatremia. Historically, such a small margin of error coupled with the “disconnect” that exists between the operators and the patient that inherently exists with all endoscopic procedures has made training this skill set challenging.

Transurethral resection of the prostate outcomes vary widely in the community and are probably technically dependent.

Transurethral resection of the prostate outcomes vary widely in the community and are probably technically dependent.

Much like any procedural skill in medicine, when a urologist becomes board certified, the ability to perform technically challenging procedures such as transurethral resection of the prostate is not discriminated from the urologist’s judgment and cognitive skills, which are measured via oral and written examinations. This fact as well as financial incentives has led many practicing urologists to pursue “alternative” or “minimally invasive” methods to deal with bladder outlet obstructive symptoms. While promising, and useful in many settings, none of these procedures has ever “outperformed” transurethral resection of the prostate in treating either the subjective symptoms of bladder outlet obstruction or objective measurements such as peak urinary flow rates and ability to empty one’s bladder completely (51). In fact, depending on the series, transurethral resection of the prostate gives symptom relief anywhere from five to 20 years and the minimally invasive treatments follow-up data are only 3–5 years in evolution. Even within this period of time, 10% to 20% of patients undergoing an office bladder outlet reductive procedure go on to have a transurethral resection of the prostate anyway (51,53). The published morbidity of transurethral resection of the prostate is also quite variable. Average length of hospital stay ranges from 1.5 to 4 days, the incidence of urinary tract infections ranges from 4% to 20%, the reintervention rate (within 30 days after treatment) ranged from 0% to 14%, erectile dysfunction ranged from 0% to 21% and retrograde ejaculation ranged from 50% to 80% (53–61). Part of the discrepancy can be explained by different outcome measures, though many argue that this is due to a variable of surgical technique. Past studies have been unable to examine or quantify this, as we have lacked a standardized objective way of measuring transurethral resection of the prostate skills.


A decade ago, residents performed 120 TURPs on average prior to graduating from a residency program. This number has declined in the last decade.

Historically, this training problem was addressed with sheer case volume. A decade ago, residents performed 120 transurethral resection of the prostates on average prior to graduating from a residency program. This number has declined in the last decade (Fig. 12).

With the advance of medical management and less effective but lucrative “minimally invasive procedures,” transurethral resection of the prostates are performed less frequently, but still remain the gold-standard therapy. The mean number of transurethral resection of the prostates a graduating resident had performed in 2002 has reached a plateau at 62 (ACGME). Without the benefits of a learning curve or objective data to reference, our group surveyed 72 board-certified urologists at the American Urological Association 2002 meeting and the perceived mean number of transurethral resection of the prostates they felt was necessary before entering independent practice was 66.8; a number well above the mean and encompassing a majority of the graduating residents in the United States (31).

Given all the mentioned issues, simulation model training for transurethral resection of the prostate has been pursued. The first reported virtual reality transurethral resection of the prostate simulator was described by Lardenois et al. in 1990 (62) after having seen a colonoscopy simulator. Since 1999, Kumar et al. have

FIGURE 12 ■ ACGME data on the mean number of TURPs done by U.S. urology residents. Source: From Ref. 30.



worked on a TUR simulator, which uses an optical tracking device and a hybrid/computer-generated and physical prostate model. The loop is tracked with a potentiometer and the scope is tracked in space. It was constructed as a virtual three-dimensional training aid to eventually be used in the operating room, but lacked features such as bleeding. Two urologists evaluated the content and felt that a poor frame refresh rate, a lack of bleeding and model movement and permanent deformation of the model as well as deformation secondary to absorbing fluid all contributed to made the trainer inaccurate in vitro. Validation studies are currently lacking but in vivo studies are in progress (63,64). Ballaro et al. (65) also created a virtual reality transurethral resection of the prostate simulator, but it lacked real-time interactivity and tactile feedback. Manyak et al. (66) also describe a simulator for lower urinary tract procedures, which adds haptics force feedback. No validation studies have been described in the literature for any of these trainers.

Sweet et al. began development of the UW virtual reality transurethral resection of the prostate trainer in 2000. Using Alias®, a virtual polygonal model of the urethra, prostate, bladder, and the loop was created de novo. Instrumentation and interaction was accomplished by securing two Polhemus tracking devices to an iglesias and a camera shell provided by ACMI®. A Bovie® foot pedal was used, and the electrical signal is transmitted to an SGI Octane® graphics computer through a TNG-3® interface box. A physical model of the penis and pelvis was created in collaboration with Simulab Corp®. using prosthetic materials. Computer graphics animation in Alias was used to recreate noninteractive portions of the simulation such as urine efflux and chip movement. Upon collision between the loop and the model, cutting was accomplished by “pushing” the anatomy of the model to accommodate the intersection between the loop and the tissue. Texture maps of prostatic urothelium, bladder urothelium, resection bed, and fat were obtained using digital footage from actual transurethral resection of the prostate procedures. Recognizing that dealing with hemostasis was a critical skill set to learn during transurethral resection of the prostate, an in vitro model for bleeding during transurethral resection of the prostate and a bleeding movie library taken from an in vitro model of the lower genitourinary tract under controlled fluid flow conditions were created. Fluid flow detection by the use of potentiometers attached to the stopcocks that trigger the changing of the blood flow movies is also employed. The result was a realistic interactive simulation of blood flow under fluid conditions. A force feedback device was then integrated using a custom Mantis device[‡]; didactics and a graphics user interface have been put on the front end and subtask training modules have been added, which train orientation, cutting, and coagulation skills independently. The simulator can log motion and force data as well as operative errors, grams resected, blood loss, irrigant volume, foot pedal use, and differential time spent with orientation, cutting, or coagulation. The result is a complete transurethral resection of the prostate simulator that can provide objective feedback to the user. Version 1.0 was validated by 72 board-certified urologists and 19 novices at the AUA 2002 and face, content, and construct validity of the simulator was established (31). Based on these data, the simulator has been upgraded and the authors endorsed the simulator for training but cautioned its use for assessment and accreditation, though the simulator was also able to discriminate differences of skill within groups (unpublished data). Plans are underway to perform a multi-institutional predictive validity study examining the simulator’s ability to improve performance in

[‡]Mimic Technologies, Seattle, WA.

the operating room with residents and the ability of subtask training to improve performance in medical students. If strong predictive validity is established with this multi-institutional design, use for assessment accreditation could be considered. It is being distributed as a beta-prototype to select institutions and ideally it would be expanded to other transurethral procedures as well.

Virtual Reality Training for Ureteroscopic Skills

Currently, the most widely distributed virtual reality simulator in urology is UroMentor.^k It runs on a personal computer and offers a high-level object-oriented application program interface available for use with either Microsoft Direct X or Open GL platforms (67). Simultaneous endoscopic and fluoroscopic views are displayed on the monitor and the user interacts with a mannequin with a multitude of virtual instruments including a flexible cystoscope, and rigid and flexible ureteroscopes. Tracking of the scopes with relation to the model is transmitted via a sensor on the endoscope and three sensors in the workstation. The model is volumetric in nature and created from data from digitized computer tomography and magnetic resonance imaging and the textures were obtained from endoscopic images during a real procedure. Like UW transurethral resection of the prostate, UroMentor provides a modular approach to train important subtasks for ureteroscopic and cystoscopic skills sets.

Shah and Darzi showed construct validity of a visual-spatial subtask cystoscopic module in UroMentor, which assesses the user's ability to find 10 flags in the bladder, which indicates that they have inspected the entire bladder. Seven experts outperformed 10 novices on the first trial both in the mean number of flags seen (9.57 vs. 8.0, $P = 0.01$) and the mean time to complete the task (2.33 vs. 4.89 minutes, $P = 0.03$). The experts did show improvement in speed between trials 1 and 2, but then remained the same up until trial 10. The medical students improved between the first and the 10th trial as far as speed ($P = 0.0005$) and approached significance with regards to seeing more flags ($P = 0.05$) (68). This study provided construct validity for the cystoscopy module, as experts outperformed novices presumably based on their prior experience on real cases. The authors also questioned the face validity, as finding flags did not accurately represent finding lesions in the bladder, though the fact that experts felt the simulator was realistic argues against this statement. Because the same instrument that was used for evaluation was also used for training and correlation with performance in the operating room was not examined, predictive validity was not established in this study (68).

Two other groups examined populations of novices (medical students) and UroMentor's ability to simulate and train ureteroscopic skills. Groups from the University of Texas Southwestern and Western Ontario University independently evaluated the acquisition of basic ureteroscopy skills using UroMentor using medical students ($N = 21$ and 20 , respectively). The students were tested and randomized to training versus no training and retested on the simulator. Subjective assessment by a single subject matter expert (Western Ontario University) and two subject matter experts who were blinded to the randomization schedule was also performed. Significant improvements in performance were evident in multiple parameters within the trained groups in both studies. The authors believed the simulator to have face validity and convergent validity, as the subjective evaluation seemed to correlate with parameters tracked by the simulator. In a later study, the University of Texas Southwestern group confirmed construct validity by stratifying performance on UroMentor with clinical experience (69,70).

The group at University of Texas Southwestern also examined concurrent validity of the ureteroscopic module by examining whether training on UroMentor translated to improvement of performance on a cadaver. Sixteen medical students and 16 residents had baseline skills evaluation with UroMentor. Just the student group then underwent five hours of supervised training on the simulator and the two groups repeated the UroMentor ureteroscopic task and also performed diagnostic ureteroscopy in a male cadaver with subjective global assessment done by three faculty observers. The blinded status of these observers is unknown. Virtual reality and cadaver performances correlated closely in students but not in residents. Year of training correlated more on the cadaver performance than with the virtual reality performance. Medical students were unable to perform cadaver ureteroscopy comparable to residents despite the five hours of virtual reality training. The authors concluded that UroMentor may shorten the learning curve

^kSimbionix, Lod, Israel.

early in training for ureteroscopic skills, but it was unable to over-ride the impact of clinical training (71).

The University of Texas Southwestern group examined UroMentor's ability to be used as an assessment tool. The authors examined the relationship between validated basic human performance testing and performance on UroMentor. Eighteen medical students underwent 13 validated tests and these skills were compared with performance of ureteroscopy on UroMentor. These performances were then used to create a model devised to predict performance on UroMentor rated by experts in a second group of 14 medical students after they completed the basic performance tests. They found that visual-spatial short-term memory capacity was the most prevalent limiting resource in the model building group and nondominant upper extremity steadiness was the most prevalent limiting resource in the model testing group. They also noted that the model was able to predict expert evaluation performance in some but not all instances (63% within $\pm 10\%$ agreement with expert rating on virtual reality performance) (72).

Virtual Reality Training for Laparoscopic Skills

The explosion of laparoscopic procedures in urology today led by such pioneers as Gill, Clayman, Guilloaneau, and Kavoussi are being associated with clear health benefits to Urology patients when compared to the open techniques. As laparoscopic approaches are validated as the standard of care, the dissemination, acquisition and certification of laparoscopic skills presents itself as a huge challenge. The American College of Surgeons recommends the granting of clinical privileges based upon evaluation of education, training, experience, and demonstrated current competence. The Society of American Gastrointestinal Endoscopic Surgeons expands this to include credentialing in diagnostic laparoscopy, hands-on experience either in a residency/fellowship or recognized didactic course, and observation of cases by a mentor proctor.

An additional problem is that urology lacked a procedure common enough to adequately maintain particular skills. Laparoscopic pelvic lymph node dissection in the 1990s paved the way for laparoscopic renal, prostate, and bladder procedures. Laparoscopic fellowships and mini-fellowships have been successful in the early adopters of this technology. Training courses with hands-on, porcine, cadaver, inanimate, and virtual reality simulators have emerged as attractive alternatives but must be associated with mentored learning opportunities for quality assurance. The summary of pertinent models and validation studies primarily revolves around laparoscopic cholecystectomy and may or may not be translatable to urological applications.

Inanimate Models (Box and Video Trainers)

For basic laparoscopic skills acquisition, inanimate trainers consisting of box and/or video trainers have been developed and utilized in urology programs and are usually relatively inexpensive, but all of them require mentored supervision for the purposes of data acquisition and assessment with its inherent cost. Some examples of inanimate trainers who have been validated include the "Rosser drills," which showed improvement in movements between the first and fourth trial (73,74). Reznick et al. (75,76) validated a "bench station" examination, which includes a global assessment scale that is widely used. The University of Kentucky established face and construct validity of their inanimate models for laparoscopic skills to perform laparoscopic appendectomy, cholecystectomy, and herniorrhaphy (77). The LTS 2000 (Hasson et al.) physical model simulator showed a positive correlation between the hours of practice on the simulator and basic gynecologic laparoscopic maneuvers and prospectively was able to reliably and reproducibly detect different levels of laparoscopic expertise in general surgery and OBGYN residents (78–80). A pilot study for laparoscopic urethrovesical anastomosis was performed by Katz et al., where they report a training program consisting of (1) passing a 30 cm polyglactin ligature between two needle holders, (2) intracorporeal knot tying, (3) intracorporeal suturing, (4) performing a linear anastomosis, and (5) performing a circular running anastomosis. Chicken skin and cardboard were used for this model. This is a very pertinent application, but validation studies are lacking. Other newer generation box video trainers include LapMan.¹

In an objective scoring system for laparoscopic cholecystectomy done in a multi-institutional fashion by Eubanks et al. (81), the moves of a laparoscopic procedure were dissected into distinct goals associated with distinct deviations from the proper procedure (errors). This objectivity was based on reliable subjective assessment of videotaped

¹Simulab, Seattle, WA.

procedures. Derossis et al. from McGill University and Coleman et al. at University of Texas Southwestern established construct validity for their training model as well.

Rosen et al. at the University of Washington designed a robot called the Blue Dragon that, when connected to the instruments, is able to track all motion and translate movements into signatures providing true objective assessment. Their objective was to develop a skill scale using statistical Markov models (10,32,82–84). Five novice surgeons and five expert surgeons performed two minimally invasive surgical procedures (cholecystectomy and Nissen fundoplication) in a porcine model. An instrumented laparoscopic grasper equipped with a three-axis force/torque sensor was used to measure the forces/torques at the hand/tool interface synchronized with endoscopic video of the operative maneuvers (Fig. 13). Three types of analysis were performed on the raw data: (1) video analysis encoding the type of tool-tip/tissue interaction, (2) vector quantization encoding the force/torque data into clusters (signatures), and (3) Markov modeling for evaluating surgical skill level. The video analysis was performed by two expert surgeons encoding the video of each step of the surgical procedure frame by frame (NTSC—30 frames per second). The expert encoding process used a taxonomy of 14 different tool maneuvers (Table 4). These 14 interactions encompass all the possible tool/tissue interactions identified during our previous video analysis of surgical procedures. Each identified surgical tool/tissue interaction had a unique F/T pattern. For example, in the laparoscopic cholecystectomy, isolation of the cystic duct and artery involves performing repeated pushing and spreading maneuvers (PS-SP—Table 4), which are accomplished by applying pushing forces mainly along the Z-axis (F_z) and spreading forces (F_g) on the handle. These 14 tool/tissue interactions allowed us to encode each surgical procedure.

Virtual Reality Models For Laparoscopy

Schijven and Jakimowicz (85) did a thorough review of virtual reality laparoscopic simulators as of October, 2003. They surveyed eight of the main commercially active virtual reality companies regarding their laparoscopic products. Their results are summarized in Table 5.

- Immersion Medical: Gaithersburg, MD (www.immersionmedical.com)
- Medical Education Trainers Incorporated (METI), Cincinnati, OH (www.meti.com)
- Mentice: Goteburg, Sweden (www.mentice.com)
- Symbionix: Cleveland, OH (www.symbionix.com)
- Simulab: Seattle, WA (www.simulab.com)

FIGURE 13 ■ Instrumented endoscopic grasper. (A) Three-axis force/torque sensor (modified ATI-Mini model) implemented on the outer tube of a 10 mm reusable Storz grasper equipped with interchangeable tips (Babcock, curved dissector, and atraumatic grasper) and a force sensor located on the instrument handle. (B) Real-time user interface of force/torque information synchronized with the endoscopic view of the procedure using picture-in-picture mode. Source: Rosen et al., 1999.

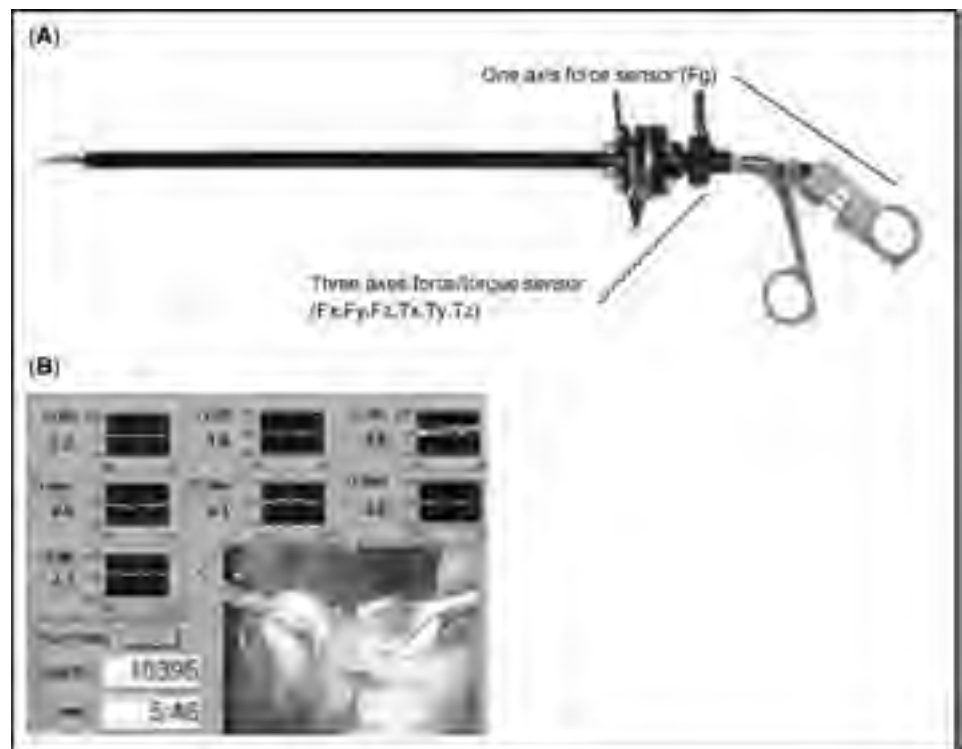


TABLE 4 ■ Definition of Tool/Tissue Interactions and the Corresponding Directions of Forces and Torques Applied During MIS

Tool/tissue interaction	Type	Acronym	Force/torque						
			F_x	F_y	F_z	T_x	T_y	T_z	F_g
Idle	I	ID	NA	NA	NA	NA	NA	NA	NA
Grasping	I	GR							+
Spreading	I	SP							—
Pushing	I	PS			—				
Sweeping (lateral retraction)	I	SW	±	±		±	±		
Grasping-pulling	II	GR-PL			+				+
Grasping-pushing	II	GR-PS			—				+
Grasping-sweeping	II	GR-SW	±	±		±	±		+
Pushing-sweeping	II	PS-SP			—				—
Pushing-sweeping	II	PS-SW	±	±	—	±	±		
Sweeping-sweeping	II	SW-SP	±	±		±	±		—
Grasping-pulling-sweeping	III	GR-PL-SW	±	±	+	±	±		+
Grasping-pushing-sweeping	III	GR-PS-SW	±	±	—	±	±		+
Pushing-sweeping-sweeping	III	PS-SW-SP	±	±	—	±	±		—

Abbreviation: NA, not applicable.
Source: Rosen et al. 1999.

- Simquest: Silver Spring, MD (www.simquest.com)
- ReachIn Technologies: Stockholm, Sweden (www.reachin.se)
- Surgical Science: Goteburg, Sweden (www.surgical-science.com)
- Red Llama Technology Group, LLC: Seattle, WA, cognitive simulation (www.redllamatech.com)
- Mimic Technologies: Seattle, WA, haptics (www.mimic.ws)

The minimally invasive surgical trainer-virtual reality (Mentice, Sweden) deserves special mention as it has undergone the most rigorous validation studies. Minimally invasive surgical trainer-virtual reality system runs on a desktop PC (400 MHz Pentium II, 64 Mb RAM) with tasks viewed on a 17 in cathode ray tube monitor. The frame rate is approximately 15 frames/sec. The laparoscopic instruments^m provided six degrees of freedom and a foot pedal is provided to provide diathermy. Abstract targets appear within the operating space according to the specific skill task selected and can be grasped and manipulated with virtual instruments. Each task is objectively scored and quantified. Seymour, Gallagher, and Satava performed a series of validation studies reliably confirming face, content, construct, discriminate and predictive validity (86–89). Their “Virtual Reality to OR” predictive validity study whereby they prospectively randomized 16 residents to training versus no training and established baseline video performance metrics on laparoscopic cholecystectomy in the operating room both before and after the intervention is a landmark study in simulation validation (89). Grantcharov et al. (90) confirmed these findings in their Virtual Reality to OR study. Virtual Reality to OR of minimally invasive surgical trainer-virtual reality has been expanded to a multi-institutional predictive validity study. Gallagher et al. did use minimally invasive surgical trainer-virtual reality

TABLE 5 ■ Surgical Simulation Companies

	Validation in urology					
	Face	Content	Construct	Concurrent	Discriminate	Predictive
UroMentor	Yes	No	Yes	Yes	±	±
PercMentor	Yes	No	No	No	No	No
UW TURP	Yes	Yes	Yes	No	Yes	No
MIST VR ^a	Yes	Yes	Yes	Yes	Yes	Yes
Pelvic LND	Yes	Yes	No	No	No	No

^aValidated for general surgical applications, not urology applications.

^mImmersion Corp., San Jose, CA.

to study controls versus urology trainees versus urology consultants with the intent to determine whether or not minimally invasive surgical trainer-virtual reality could be useful in aptitude testing. They found that minimally invasive surgical trainer-virtual reality, which is primarily a visual-spatial assessment tool, was not useful for this purpose (91). Various modules for the ProCedicus, minimally invasive surgical trainer-virtual reality system are available. There is a KSA module which provides an abdominal environment for more advanced laparoscopic training such as scope and instrument navigation, pick and pass, cutting, suturing, needle passing, and diathermy. Arthroscopy, urology, gynecology, interventional cardiology, and radiology are available for the ProCedicus platform. Force feedback is optional (www.mentice.com).

LapMentorⁿ is an upper-end virtual reality laparoscopic trainer, which allows for the completion of entire general laparoscopic procedures. There are basic skills task modules such as instrument navigation, object manipulation, clipping, and cutting. Virtual patient cases are also present with accountability for different port placement sites. They acquired and employed Xitact's force feedback system to provide haptic feedback. Urologic applications are under development and validation studies are preliminary at this point (www.simbionix.com).

LapSim^o offers nine basic laparoscopic skills training modules ranging from navigation to grasping, cutting, clip applying, and suturing. Force feedback is optional. Construct validity has been mixed. Duffy et al. (92) established construct validity for the simulator to distinguish between novices, trainees, and experts. Ro et al. (93) with a smaller number of subjects and only looking at one trial, actually showed that novices outperformed experts on instrumentation, suturing, and dissection modules. In a prospective design, however, naive subjects trained on the LapSim virtual-reality part-task trainer performed better on live surgical tasks in a porcine model as compared with those trained with a traditional box trainer (94). The software was recently upgraded and modules to include more advanced skill training and gynecologic procedures added (www.surgical-science.com).

The Haptica ProMis^p trainer is a PC-based hybrid box and virtual reality trainer for laparoscopic skills. The Haptica trainer has undergone content and construct validity studies by Emory and the Imperial College of London. Significant differences between the performance of laparoscopic cholecystectomy subtasks were found between novices, trainees, and experts (95). Interestingly enough, Gallagher et al. found that older subjects (ages 60–69) performed significantly worse than younger subjects (ages 30–39, 40–49) on the box-trainer task for correct incisions (13.1 vs. 19.3, $p < 0.008$) and incorrect incisions (12.3 vs. 2.5, $p > 0.05$). They also performed worse on the virtual reality task for time (132 vs. 71, $p < 0.05$), error (99 vs. 41, $p < 0.05$) and economy of movement (22.8 vs. 11.7, $p < 0.05$) (www.haptica.com).

As laparoscopic skills become more widely disseminated, laparoscopic skills trainers representing complete procedures for laparoscopic urology procedures are desperately needed and are currently under development by numerous universities and simulation companies.

As laparoscopic skills become more widely disseminated, laparoscopic skills trainers representing complete procedures for laparoscopic urology procedures are desperately needed and are currently under development by numerous universities and simulation companies.

SUMMARY

- The ultimate goal of surgical education is to ensure competency, reduce error, and improve patient safety.
- The primary methods of assessment in medical education are based on testing factual knowledge.
- The ACGME core competencies and the OSATS and OSCE have provided a foundation for a paradigm shift in this concept. In the information age, factual knowledge may be less important.
- "The student should not be taught what to know, but rather where to find information (trusted sources), how to discriminate among the literally thousands of facts, and, once the correct information is found, how to make the correct decision."
- Virtual reality simulation is a promising tool that when built into such a dynamic curriculum will be used for objectively training and assessing procedural cognitive and technical skills.
- A mechanism of funding for postgraduate education skill acquisition, development, training validation, and assessment needs to be implemented before this goal becomes a reality.

ⁿSimbionix, Cleveland, OH.

^oSurgical Science, Göteborg, Sweden.

^pDublin, Ireland.

REFERENCES

1. Cohen R, MacRae H, Jamieson C. Teaching effectiveness of surgeons. *Am J Surg* 1996;171:612.
2. Haluck RS, Krummel TM. Computers and virtual reality for surgical education in the 21st century. *Arch Surg* 2000;135:786.
3. Haluck RS, Marshall RL, Krummel TM, et al. Are surgery training programs ready for virtual reality? A survey of program directors in general surgery. *J Am Coll Surg* 2001;193:660.
4. Kerfoot BP, Mitchell ME, Novick AC. Grappling with the evaluation of clinical competencies: a view from the Residency Review Committee for Urology. *Urology* 2002;60:223.
5. Satava RM. Disruptive visions: a robot is not a machine—systems integration for surgeons. *Surg Endosc* 2004;18:617.
6. Satava RM. Disruptive visions: surgeon responsibility during the era of change. *Surg Endosc* 2002;16:733.
7. Bridges M, Diamond DL. The financial impact of teaching surgical residents in the operating room. *Am J Surg* 1999;177:28.
8. Satava RM. Information age technologies for surgeons: overview. *World J Surg* 2001;25:1408.
9. Satava RM. Disruptive visions. *Surg Endosc* 2002;16:1403.
10. Rosen J, Richards C, Hannaford B, et al. Hidden Markov models of minimally invasive surgery. *Stud Health Technol Inform* 2000;70:279.
11. Satish U, Streufert S. Value of a cognitive simulation in medicine: towards optimizing decision making performance of healthcare personnel. *Qual Saf Health Care* 2002;11:163.
12. Gorman PJ, Meier AH, Rawn C, et al. The future of medical education is no longer blood and guts, it is bits and bytes. *Am J Surg* 2000;180:353.
13. Salas E, Burke CS. Simulation for training is effective when. *Qual Saf Health Care* 2002;11:119.
14. Radetzky A, Nurnberger A. Visualization and simulation techniques for surgical simulators using actual patient's data. *Artif Intell Med* 2002;26:255.
15. Berkley J. Development of a simulation platform for the da Vinci surgical system: 1 year summary. Seattle: Mimic Technologies Inc., 2005, Defense Advanced Research Projects Agency Contract # MDA972-03-P0034.
16. Christensen EE, Dietz GW, Murry RC, et al. The effect of fatigue on resident performance. *Radiology* 1977;125:103.
17. Denisco RA, Drummond JN, Gravenstein JS. The effect of fatigue on the performance of a simulated anesthetic monitoring task. *J Clin Monit* 1987;3:22.
18. Condon RE. Fatigue and resident performance. *Bull Am Coll Surg* 1990;75:15.
19. Uhrich ML, Underwood RA, Standeven JW, et al. Assessment of fatigue, monitor placement, and surgical experience during simulated laparoscopic surgery. *Surg Endosc* 2002;16:635.
20. Reiter ER, Wong DR. Impact of duty hour limits on resident training in otolaryngology. *Laryngoscope* 2005;115:773.
21. Veldenz HC, Scott KK, Dennis JW, et al. Impaired residents: identification and intervention. *Curr Surg* 2003;60:214.
22. Sawyer RG, Tribble CG, Newberg DS, et al. Intern call schedules and their relationship to sleep, operating room participation, stress, and satisfaction. *Surgery* 1999;126:337.
23. Asken MJ, Raham DC. Resident performance and sleep deprivation: a review. *J Med Educ* 1983;58:382.
24. Satava RM. Commentary. The need for metrics in surgical education. *Surg Endosc* 1999;13:1082.
25. Satava RM. Disruptive visions: surgical education. *Surg Endosc* 2004;18:779.
26. Fried MP, Satava R, Weghorst S, et al. Identifying and reducing errors with surgical simulation. *Qual Saf Health Care* 2004;13(suppl 1):i19.
27. Satava RM, Cuschieri A, Hamdorf J. Metrics for objective assessment. *Surg Endosc* 2003;17:220.
28. Sweet R. Virtual reality education simulation: a new reality in urologic education? *Contemp Urol* 2005;17:21.
29. LoPiccolo P. Gaming: 2010. Computer graphics world, 2004.
30. Sweet R, Porter J, Oppenheimer P, et al. Simulation of bleeding in endoscopic procedures using virtual reality. *J Endourol* 2002;16:451.
31. Sweet R, Kowalewski T, Oppenheimer P, Weghorst S, Satava R. Face, content and construct validity of the University of Washington virtual reality transurethral prostate resection trainer. *J Urol* 2004;172(5 Part 1):1953.
32. Rosen J, Hannaford B, MacFarlane MP, et al. Force controlled and teleoperated endoscopic grasper for minimally invasive surgery—experimental performance evaluation. *IEEE Trans Biomed Eng* 1999;46:1212.
33. Berkley J, Volleweider M, Sweet RM, Satava RM. 3-D volumetric modeling of the urethral/prostate/bladder complex. Seattle, Washington: Defense Advanced Research Projects Agency, 2005.
34. Viirre E, Pryor H, Nagata S, et al. The virtual retinal display: a new technology for virtual reality and augmented vision in medicine. *Stud Health Technol Inform* 1998;50:252.
35. Gallagher AG, Ritter EM, Satava RM. Fundamental principles of validation, and reliability: rigorous science for the assessment of surgical education and training. *Surg Endosc* 2003;17:1525.
36. Martin JA, Regehr G, Reznick R, et al. Objective structured assessment of technical skill (OSATS) for surgical residents. *Br J Surg* 1997;84:273.
37. Faulkner H, Regehr G, Martin J, et al. Validation of an objective structured assessment of technical skill for surgical residents. *Acad Med* 1996;71:1363.
38. Wanzel KR, Ward M, Reznick RK. Teaching the surgical craft: from selection to certification. *Curr Probl Surg* 2002;39:573.
39. Burdea G, Patounakis G, Popescu V, et al. Virtual reality-based training for the diagnosis of prostate cancer. *IEEE Trans Biomed Eng* 1999;46:1253.
40. Schwid HA. A flight simulator for general anesthesia training. *Comput Biomed Res* 1987;20:64.

41. Schwid HA. Electrocardiogram simulation using a personal computer. *Comput Biomed Res* 1988;21:562.
42. Schwid HA, O'Donnell D. The anesthesia simulator-recorder: a device to train and evaluate anesthesiologists' responses to critical incidents. *Anesthesiology* 1990;72:191.
43. Schwid HA, O'Donnell D. Educational computer simulation of malignant hyperthermia. *J Clin Monit* 1992;8:201.
44. Schwid HA, O'Donnell D. Anesthesiologists' management of simulated critical incidents. *Anesthesiology* 1992;76:495.
45. Schwid HA, O'Donnell D. The anesthesia simulator consultant: simulation plus expert system. *Anesthesiol Rev* 1993;20:185.
46. Schwid HA. Computer simulations and management of critical incidents. *Acad Med* 1994;69:213.
47. Schwid HA, Rooke GA, Ross BK, et al. Use of a computerized advanced cardiac life support simulator improves retention of advanced cardiac life support guidelines better than a textbook review. *Crit Care Med* 1999;27:821.
48. Schwid HA, Rooke GA, Carline J, et al. Evaluation of anesthesia residents using mannequin-based simulation: a multiinstitutional study. *Anesthesiology* 2002;97:1434.
49. Tran L, Sweet RM. Content validity of the SimPraxis™ pelvic lymph node dissection interactive cognitive trainer. Presented at the Northwest Urological Society, Vancouver, B.C., December 2004.
50. Holtgrewe HL. Surgical management of benign prostatic hyperplasia in 2001—a pause for thought. *J Urol* 2001;166:177.
51. AUA guideline on management of benign prostatic hyperplasia (2003). Chapter 1: Diagnosis and treatment recommendations. *J Urol* 2003;170:530.
52. Joyner BD. An historical review of graduate medical education and a protocol of accreditation council for graduate medical education compliance. *J Urol* 2004;172:34.
53. Gravas S, Laguna MP, De La Rosette JJ. Application of external microwave thermotherapy in urology: past, present, and future. *J Endourol* 2003;17:659.
54. Mebust WK, Holtgrewe HL, Cockett AT, et al. Transurethral prostatectomy: immediate and post-operative complications. Cooperative study of 13 participating institutions evaluating 3,885 patients. *J Urol* 1989;141:243–247; *J Urol* 2002;167:5.
55. Ahmed M, Bell T, Lawrence WT, et al. Transurethral microwave thermotherapy (Prostatron version 2.5) compared with transurethral resection of the prostate for the treatment of benign prostatic hyperplasia: a randomized, controlled, parallel study. *Br J Urol* 1997;79:181.
56. D'Ancona FC, Francisca EA, Witjes WP, et al. High energy thermotherapy versus transurethral resection in the treatment of benign prostatic hyperplasia: results of a prospective randomized study with 1 year of followup. *J Urol* 1997;158:120.
57. Dahlstrand C, Walden M, Geirsson G, et al. Transurethral microwave thermotherapy versus transurethral resection for symptomatic benign prostatic obstruction: a prospective randomized study with a 2-year follow-up. *Br J Urol* 1995;76:614.
58. Flanigan RC, Reda DJ, Wasson JH, et al. 5-year outcome of surgical resection and watchful waiting for men with moderately symptomatic benign prostatic hyperplasia: a Department of Veterans Affairs cooperative study. *J Urol* 1998;160:12.
59. Francisca EA, d'Ancona FC, Hendriks JC, et al. A randomized study comparing high-energy TUMT to transurethral resection of the prostate: quality-of-life results. *Eur Urol* 2000;38:569.
60. Littlejohn JO Jr., Ghafar MA, Kang YM, et al. Transurethral resection of the prostate: the new old standard. *Curr Opin Urol* 2002;12:19.
61. Roos NP, Wennberg JE, Malenka DJ, et al. Mortality and reoperation after open and transurethral resection of the prostate for benign prostatic hyperplasia. *N Engl J Med* 1989;320:1120.
62. Lardennois B, Clement T, Ziade A, et al. Computer stimulation of endoscopic resection of the prostate. *Ann Urol (Paris)* 1990;24:519.
63. Kumar PV, Gomes MP, Davies BL, et al. A computer assisted surgical trainer for transurethral resection of the prostate. *J Urol* 2002;168:2111.
64. Gomes MP, Barrett AR, Timoney AG, et al. A computer-assisted training/monitoring system for transurethral resection of the prostate structure and design. *IEEE Trans Inf Technol Biomed* 1999;3:242.
65. Ballaro A, Briggs T, Garcia-Montes F, et al. A computer generated interactive transurethral prostatic resection simulator. *J Urol* 1999;162:1633.
66. Manyak MJ, Santangelo K, Hahn J, et al. Virtual reality surgical simulation for lower urinary tract endoscopy and procedures. *J Endourol* 2002;16:185.
67. Michel MS, Knoll T, Kohrmann KU, et al. The URO Mentor: development and evaluation of a new computer-based interactive training system for virtual life-like simulation of diagnostic and therapeutic endourological procedures. *BJU Int* 2002;89:174.
68. Shah J, Darzi A. Virtual reality flexible cystoscopy: a validation study. *BJU Int* 2002;90:828.
69. Jacomides L, Ogan K, Cadeddu JA, et al. Use of a virtual reality simulator for ureteroscopy training. *J Urol* 2004;171:320.
70. Watterson JD, Beiko DT, Kuan JK, et al. Randomized prospective blinded study validating acquisition of ureteroscopy skills using computer based virtual reality endourological simulator. *J Urol* 2002;168:1928.
71. Ogan K, Jacomides L, Shulman MJ, et al. Virtual ureteroscopy predicts ureteroscopic proficiency of medical students on a cadaver. *J Urol* 2004;172:667.
72. Johnson DB, Kondraske GV, Wilhelm DM, et al. Assessment of basic human performance resources predicts the performance of virtual ureterorenoscopy. *J Urol* 2004;171:80.
73. Rosser JC, Rosser LE, Savalgi RS. Skill acquisition and assessment for laparoscopic surgery. *Arch Surg* 1997;132:200.
74. Pearson AM, Gallagher AG, Rosser JC, et al. Evaluation of structured and quantitative training methods for teaching intracorporeal knot tying. *Surg Endosc* 2002;16:130.
75. Reznick R, Regehr G, MacRae H, et al. Testing technical skill via an innovative "bench station" examination. *Am J Surg* 1997;173:226.

76. Reznick RK. Virtual reality surgical simulators: feasible but valid? *J Am Coll Surg* 1999;189:127.
77. Adrales GL, Park AE, Chu UB, et al. A valid method of laparoscopic simulation training and competence assessment. *J Surg Res* 2003;114:156.
78. Fichera A, Prachand V, Kives S, et al. Physical reality simulation for training of laparoscopists in the 21st century. A multispecialty, multi-institutional study. *JSLs* 2005;9:125.
79. Hasson HM, Kumari NV, Eekhout J. Training simulator for developing laparoscopic skills. *JSLs* 2001;5:255.
80. Hasson HM. Interrupted laparoscopic suture secured with the needle-through-the-sliding-loop knot. *J Am Assoc Gynecol Laparosc* 2000;7:556.
81. Eubanks TR, Clements RH, Pohl D, et al. An objective scoring system for laparoscopic cholecystectomy. *J Am Coll Surg* 1999;189:566.
82. Rosen J, MacFarlane M, Richards C, et al. Surgeon-tool force/torque signatures—evaluation of surgical skills in minimally invasive surgery. *Stud Health Technol Inform* 1999;62:290.
83. Rosen J, Hannaford B, Richards CG, et al. Markov modeling of minimally invasive surgery based on tool/tissue interaction and force/torque signatures for evaluating surgical skills. *IEEE Trans Biomed Eng* 2001;48:579.
84. Rosen J, Solazzo M, Hannaford B, et al. Task decomposition of laparoscopic surgery for objective evaluation of surgical residents' learning curve using hidden Markov model. *Comput Aided Surg* 2002;7:49.
85. Schijven M, Jakimowicz J. Virtual reality surgical laparoscopic simulators. *Surg Endosc* 2003;17:1943.
86. Gallagher AG, Satava RM. Virtual reality as a metric for the assessment of laparoscopic psychomotor skills. Learning curves and reliability measures. *Surg Endosc* 2002;16:1746.
87. Gallagher AG, Lederman AB, McGlade K, et al. Discriminative validity of the minimally invasive surgical trainer in virtual reality (Minimally invasive surgical trainer-virtual reality) using criteria levels based on expert performance. *Surg Endosc* 2004;18:660.
88. Gallagher AG, Smith CD, Bowers SP, et al. Psychomotor skills assessment in practicing surgeons experienced in performing advanced laparoscopic procedures. *J Am Coll Surg* 2003;197:479.
89. Seymour NE, Gallagher AG, Roman SA, et al. Virtual reality training improves operating room performance: results of a randomized, double-blinded study. *Ann Surg* 2002;236:458.
90. Grantcharov TP, Kristiansen VB, Bendix J, et al. Randomized clinical trial of virtual reality simulation for laparoscopic skills training. *Br J Surg* 2004;91:146.
91. Gallagher HJ, Allan JD, Tolley DA. Spatial awareness in urologists: are they different? *BJU Int* 2001;88:666.
92. Duffy AJ, Hogle NJ, McCarthy H, et al. Construct validity for the LAPSIM laparoscopic surgical simulator. *Surg Endosc* 2005;19:401.
93. Ro CY, Toumpoulis IK, Ashton RC Jr, et al. The LapSim: a learning environment for both experts and novices. *Stud Health Technol Inform* 2005;111:414.
94. Youngblood PL, Srivastava S, Curet M, et al. Comparison of training on two laparoscopic simulators and assessment of skills transfer to surgical performance. *J Am Coll Surg* 2005;200:546.
95. Hance J AR, Undre S, Patel H, Selvapatt N, Darzi A. Evaluation of a laparoscopic video trainer with in-built measures of performance. Presented at the Society of Laparoscopic Surgeons, 2004.

MATHEMATICAL MODELING FOR PREDICTING OUTCOMES IN LAPAROSCOPIC UROLOGY

Sijo Joseph Parekattil

*Glickman Urological Institute, Cleveland Clinic Foundation,
Cleveland, Ohio, U.S.A.*

<ul style="list-style-type: none"> ■ INTRODUCTION ■ WHAT IS MATHEMATICAL MODELING? <ul style="list-style-type: none"> Artificial Neural Networks Linear Regression Models Nonlinear Regression Models Logistic Regression Models ■ HOW GOOD IS A MODEL? ■ APPLICATION OF MODELING IN UROLOGY ■ APPLICATION OF MODELING IN LAPAROSCOPY <ul style="list-style-type: none"> Mathematical Models to Predict Duration of Stay After Laparoscopic Nephrectomy (Radical/Simple or Partial) Laparoscopic Radical/Simple Nephrectomy Models Laparoscopic Partial Nephrectomy Models 	<ul style="list-style-type: none"> ■ RESULTS <ul style="list-style-type: none"> Laparoscopic Radical/Simple Nephrectomy: Lesser or Greater Than Two Days Duration of Hospital Stay Predictor Laparoscopic Radical/Simple Nephrectomy: Lesser or Greater Than One Day Duration of Hospital Stay Predictor Laparoscopic Partial Nephrectomy: Greater or Lesser Than Two Days Duration of Hospital Stay Predictor Laparoscopic Partial Nephrectomy: Greater or Lesser Than One Day Duration of Hospital Stay Predictor ■ THE FUTURE ■ REFERENCES
--	---

INTRODUCTION

In our current medical climate, the efficient use of medical resources is of prime importance. Unfortunately, this places the onus on medical care providers to develop measures to promote cost containment and reduce redundancy. This is a commonly shared theme in other fields such as engineering and business.

For example, let us look at the semiconductor chip design industry. Over the last 10 years, there has been an explosion in the ability to increase the complexity and density of semiconductor circuitry. This has driven the need to develop more cost effective and efficient methods to fabricate and test these chips.

Engineers have developed specialized fabrication and testing protocols to enhance the efficiency of these processes. The use of such protocols diminishes redundancy.

Similar techniques can also be applied to medicine. The use of clinical pathway protocols in the management of patients has been shown to provide significant cost containment and enhance efficiency in the use of medical resources (1,2).

Koch and Smith (2) presented some very elegant work in demonstrating cost containment by the use of a standardized clinical pathway protocol in the management of post-radical prostatectomy patients. This consolidated the use of such protocols at several institutions around the country. Flickinger et al. (1) demonstrated the beneficial use of clinical pathways in the management of pediatric ureteroneocystostomy patients.

This opens the door to a whole range of possibilities. The application of such protocols in patients that undergo laparoscopic or minimally invasive procedures is likely to have similar benefits. The design of current clinical protocols is usually based on the average or typical patient for that particular scenario. However, as we all know, not every patient is identical.

In the silicon chip fabrication process, not every wafer develops in an identical fashion. Thus, there are complex readjustment protocols that tailor the fabrication process to the specific requirements of that particular wafer.

Similarly, it only seems logical to design "smart" clinical pathway protocols that would readjust to a particular patient's needs to better suit the scenario.

Mathematical prediction modeling could be incorporated into such clinical pathways to provide this "intelligence."

Engineers have developed specialized fabrication and testing protocols to enhance the efficiency of these processes. The use of such protocols diminishes redundancy.

The use of clinical pathway protocols in the management of patients has been shown to provide significant cost containment and enhance efficiency in the use of medical resources.

It only seems logical to design "smart" clinical pathway protocols that would readjust to a particular patient's needs to better suit the scenario.

This is but one example of the potential use of mathematical modeling in medicine. This chapter is dedicated to the discussion and presentation of mathematical modeling techniques and solutions in the field of laparoscopic or minimally invasive urology.

WHAT IS MATHEMATICAL MODELING?

The first person possibly documented to have used logic or mathematics in a device to create an outcome was the Spanish theologian Ramon Lull in 1274 A.D. (3). Lull's device was based on concentric disks of card, wood, or metal mounted on a central axis. Each disk would contain a number of different words or symbols, which would be combined in different ways by rotating the disks. By spinning the disks, you could achieve different sentences such as "This is an apple" or "That is a book."

We have come a long way from such humble beginnings to complex statistical methods of linear, logistic, nonlinear regression and artificial neural networks. Mathematical modeling is simply the use of equations or relationships (linear or non-linear) and logic to achieve some outcome, be it a prediction or a representation of the truth.

Some of the more commonly used methods will now be discussed.

Artificial Neural Networks

This is a computational method that strives to mimic the complex interconnections between neurons in a biologic system.

Essentially there are three main components to the model; (i) specific inputs (input nodes), (ii) connections between these inputs and some intermediary data points (hidden nodes) that then lead to (iii) specific outputs (output nodes). Figure 1 illustrates this model.

Each level (input nodes, hidden nodes and output nodes) of the neural network is called a "layer." A simple linear model has inputs and an output—two layers. Neural networks have at a minimum three layers.

When designing a neural network, the data to be analyzed is randomly distributed into three groups: a training data set, a testing data set and a validation data set.

The training data set is initially used to "train" the network. A set of inputs are entered, these inputs are multiplied by weights along each connection to produce hidden node values. These values are then multiplied by secondary weights along the next set of connections to finally produce an output. The error between the produced output and the desired output is then calculated and used to readjust the weights along the connection pathway from the first layer through the last. This process is repeated till the error between produced output and desired output is minimized. This is called the *perceptron learning rule*. More complex networks can be designed by utilizing more layers and designing feedback mechanisms that can adjust weighting values at any layer level without sequentially propagating through the system.

One must remember, though, that just because a model is designed as a neural network does not mean that it will perform better than a linear model. In fact, most neural networks must be compared to linear counterparts, if available, to assess if it is truly a benefit to utilize it.

Linear Regression Models

These models are utilized to design models where a linear relationship exists between the input variables and output variables. The format of the model is represented as:

$$Y = ax_0 + bx_1 + cx_1 + \dots$$

Nonlinear Regression Models

These are utilized to design models where the relationship between input variables and output variable cannot be described by a simple linear model. The format of the model usually takes the form of:

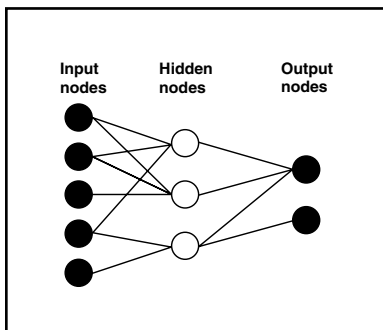
$$Y = f(X, \beta) + \varepsilon$$

Here f is a function of X and β . X represents an input matrix, β a vector of weights and ε a vector of errors or disturbances from an expected outcome.

Artificial neural network is a computational method that strives to mimic the complex interconnections between neurons in a biologic system.

When designing a neural network, the data to be analyzed is randomly distributed into three groups: a training data set, a testing data set and a validation data set.

FIGURE 1 ■ Artificial neural network model.



Logistic Regression Models

This type of model is used when the output parameter is not a continuous variable but takes an absolute value of 0 or 1. The relationship between input and output variables need not be linear in this case. The format of the model usually takes the form of:

$$\theta = \frac{e^{(\alpha + \beta_1 X_1 + \beta_2 X_2 + \dots)}}{1 + e^{(\alpha + \beta_1 X_1 + \beta_2 X_2 + \dots)}}$$

All these models are simply attempts to associate or pattern a set outcome with specific inputs.

HOW GOOD IS A MODEL?

Once a model is chosen, the question is how good is it?

The receiver operating characteristic curve is the graphical representation of the True Positive Rate (sensitivity) versus the False Positive Rate (1-specificity). The ideal model would have an receiver operating characteristic of 1.

Deciding which model to use is the most difficult component of the modeling process. The type of variables utilized and the output parameters desired usually influence the type of model used.

Once a model is chosen, the question is how good is it?

There are a number of methods to assess the accuracy or effectiveness of models. One commonly employed method is to calculate the area under the receiver operating characteristic.

The receiver operating characteristic curve is the graphical representation of the True Positive Rate (sensitivity) versus the False Positive Rate (1-specificity). It essentially illustrates the trade-off between sensitivity and specificity for a model. The ideal model would have an receiver operating characteristic of 1.

Table 1 illustrates a general guide to the meaning of area under the receiver operating characteristic values.

TABLE 1 ■ The Meaning of Receiver Operating Characteristic Values

Area under ROC	How good is the model?
1	Perfect
0.9–1	Excellent
0.8–0.9	Good
0.7–0.8	Fair
0.6–0.7	Average to poor
0.5–0.6	Not of value
Abbreviation: ROC, receiver operating characteristic.	

APPLICATION OF MODELING IN UROLOGY

Mathematical modeling has been utilized increasingly in the field of urology. Table 2 lists some of the models currently available for various urologic applications.

In order to facilitate the widespread development and free distribution of clinically applicable models, our group has created a web-based platform (www.uroengineering.com). This is a noncommercial platform to further the use of mathematical and engineering techniques in urology. The hope is that this conduit would provide urologists easy access to urological models as they become available. This would allow for multi-institutional testing, refinement and validation of these models. The end result would be models that are actually widely clinically applicable.

APPLICATION OF MODELING IN LAPAROSCOPY

The use of mathematical modeling in laparoscopy is expanding. Gettman et al. (20) recently published an elegant study on the use of a nonlinear method to predict operative performance of laparoscopic surgery based on the assessment of surgeon performance in completing certain skill tasks. Lotan et al. have utilized decision tree models to perform cost effectiveness comparison between laparoscopic and open nephrectomy cases (21,22). These are but a sample of some of the potential applications in laparoscopic urology.

The use of mathematical modeling to predict hospital duration of stay after laparoscopic radical, simple, or partial nephrectomy by our group will now be presented.

Mathematical Models to Predict Duration of Stay After Laparoscopic Nephrectomy (Radical/Simple or Partial)

Laparoscopic nephrectomy (radical, simple or partial) is a minimally invasive procedure that is offered to patients for the treatment of renal malignancy or chronic renal disease. In our current medical climate, efficient use of resources in the postoperative care of patients undergoing these procedures is of prime importance.

Duration of hospital stay plays a critical role in determining the cost of individual surgical procedures (23).

Minimally invasive procedures offer significant cost savings in that they decrease duration of hospital stay (21,23). However, even within minimally invasive procedures, there may be differences in duration of hospital stay based on preoperative patient

Duration of hospital stay plays a critical role in determining the cost of individual surgical procedures.

TABLE 2 ■ Listing of Some of the Models Currently Available in Urology

Group ^a	Model	Website downloads
Anagnostou (4)	Neural network for urologic oncology decision making	
Bagli (5)	Neural network to predict sonographic outcome following pyeloplasty	godot.urol.uic.edu/~web/index.html
Frank (6)	Outcome prediction model for clear cell RCC patients post-radical nephrectomy	
Frank (7)	Post-op surveillance model for patients with surgically treated clear cell RCC	
Kattan, Eastham (8,9)	Nomograms to predict prostate cancer staging and progression	www.mskcc.org/mskcc/html/10088.cfm
Kattan (10)	Renal cancer nomogram to predict postoperative progression	www.mskcc.org/mskcc/html/6156.cfm
Krahn (11)	Model to estimate life expectancy in patients with localized prostate cancer	
Krongrad (12)	Neural network to predict quality of life in patients with BPH or prostate cancer	
Moul (13)	Neural network to predict pathological stage in nonseminomatous testicular cancer	
Moul (14)	Model to predict post-radical prostatectomy PSA recurrence	
Mulhall (15)	Model to predict area of venous leak in men with erectile dysfunction	
Niederberger	Models to predict presence of prostate cancer and post ESWL outcome	godot.urol.uic.edu/~web/index.html
Parekattil (16)	Model to detect bladder cancer based on urinary NMP-22, uICAM-1 and MCP-1	
Parekattil (17)	Model to predict the outcome and duration of ureteral or renal calculous passage	www.uroengineering.com
Parekattil	Models to predict outcomes in male infertility surgery and IUT outcome	www.uroengineering.com
Tanthanuch (18)	Neural network to predict upper urinary tract calculi	
Tewari (19)	Neural network for initial staging of prostate cancer patients	

^aGroups are listed alphabetically.
Abbreviations: RCC, renal cell carcinoma; ESWL, extracorporeal shock wave lithotripsy; PSA, prostate specific antigen; IUT, Intrauterine transfusion; BPH, benign prostate hyperplasia.

Our goal was to design algorithms to predict the duration of hospital stay after laparoscopic renal surgery based on preoperative patient parameters.

parameters. The identification of patients who require a longer duration of hospital stay would better prepare ancillary staff for more efficient use of medical resources.

Preoperatively predicting duration of hospital stay for patients undergoing a laparoscopic nephrectomy (radical, simple or partial) would provide the hospital scheduling staff a planned approach to the recovery period. Such models could be incorporated into clinical pathways for postoperative management. The use of clinical pathways in postoperative management of patients after radical prostatectomy (2) and ureteroneocystostomy (1) has been shown to provide significant improvements in cost containment and medical resource utilization. The use of predictive models in clinical pathways may only further enhance these benefits.

Our goal was to design algorithms to predict the duration of hospital stay after laparoscopic renal surgery based on preoperative patient parameters.

There are a number of confounding variables involved in determining duration of hospital stay, such as the patient's expectations, baseline patient coping ability, surgeon bias, and timing of the surgery (e.g., would the patient be discharged on a weekend day vs. a workday, etc.). However, our goal was to identify if there were any identifiable preoperative patient characteristics that predisposed the patient to a longer duration of hospital stay.

Retrospective review was performed on all 392 patients (July 1997–March 2004) who underwent laparoscopic nephrectomy (simple or radical) and all 334 patients (September 1999–April 2004) who underwent laparoscopic partial nephrectomy at our institution.

Prospective testing of models was performed on all 29 patients who underwent a laparoscopic nephrectomy and all 19 patients who underwent a laparoscopic partial nephrectomy from May 2004 to July 2004 at our institution. The protocol was approved by our Institutional Review Board. Age of the patients in the radical/simple nephrectomy group ranged from 24 to 89 years (mean, 61). Age in the partial nephrectomy group ranged from 17 to 87 years (mean, 60). Racial background was not recorded.

Laparoscopic Radical/Simple Nephrectomy Models

The following patient parameters were recorded during the retrospective chart review (392 patients): age, sex, surgeon, radical versus simple, unilateral versus bilateral,

These “design group” data were used to create two duration of hospital stay prediction algorithms: to predict if the duration of hospital stay would be greater or lesser than two days, and to predict if the duration of hospital stay would be greater or lesser than one day.

planned adrenalectomy, planned lymph node dissection, gastro-esophageal reflux disease, hypertension, smoking, diabetes mellitus, hyperlipidemia, chronic obstructive pulmonary disease, coronary artery disease, hematuria (micro or gross), kidney stones, obstructive sleep apnea, congestive heart failure, cerebrovascular accident, polycystic kidney disease depression, fibromyalgia, liver cirrhosis, bleeding disorders, planned transperitoneal versus retroperitoneal approach, side of nephrectomy, tumor size, nodal involvement, renal vein involvement, body mass index, American Society of Anesthesiology grade, planned specimen extraction incision and duration of hospital stay (in days).

These “design group” data were used to create two duration of hospital stay prediction algorithms: to predict if the duration of hospital stay would be greater or lesser than two days, and to predict if the duration of hospital stay would be greater or lesser than one day.

The design group was initially divided into two groups: (i) patients with a duration of hospital stay less than or equal to two days (258 patients) and those with a duration of hospital stay greater than two days (134 patients). Univariate and multivariate logistic regression analysis comparing patient parameters between these groups identified significant predictors of duration of hospital stay. These results were used to generate a linear regression algorithm to predict duration of hospital stay (greater or lesser than two days) (24,25).

The same process was repeated for the greater or lesser than one day duration of hospital stay predictor. The design group in this case was divided into: (i) those patients that had a duration of hospital stay lesser than or equal to one day (123 patients) and those with a duration of hospital stay greater than one day (269 patients).

By combining the above two models, the algorithm would predict if the duration of hospital stay was lesser than or equal to one day, one to two days or greater than two days. These models were then prospectively tested on a separate 29 patient “test group” to assess the duration of hospital stay prediction accuracy. Testing was performed on this separate group to avoid any training bias.

Laparoscopic Partial Nephrectomy Models

The following patient parameters were recorded during the retrospective chart review (334 patients): age, sex, surgeon, body mass index, American society in anesthesiology grade, hypertension, prior pancreatitis, prior abdominal surgery, prior deep venous thrombus, peripheral vascular disease, smoking, coronary artery disease, gastric esophageal reflux disease, anxiety, hyperlipidemia, depression, renal stone disease, constipation, liver cirrhosis, hepatitis C, hematuria (micro or gross), chronic obstructive pulmonary disease, alcohol use, hypothyroidism, diabetes mellitus, chronic renal insufficiency, cerebrovascular accident, gout, congestive heart failure, osteoarthritis, bleeding disorder, Crohn’s disease or inflammatory bowel disease, obstructive sleep apnea, polycystic kidney disease, seizures, anemia, von Hippel-Lindau disease, simple or partial nephrectomy, planned retroperitoneal versus transperitoneal approach, tumor size (by computed tomography), solitary kidney, preoperative serum creatinine, tumor location—anterior, posterior, medial, lateral, mid, lower, upper, exophytic, parenchymal, up to renal sinus, central, peripheral, abuts the collecting system and duration of hospital stay (in days).

These “design group” data were used to create two duration of hospital stay prediction algorithms: to predict if the duration of hospital stay would be lesser or greater than two days, and to predict if the duration of hospital stay would be lesser or greater than one day.

The design group was initially divided into two groups: (i) patients with a duration of hospital stay less than or equal to two days (147 patients) and patients with a duration of hospital stay greater than two days (187 patients). Univariate and multivariate logistic regression analysis comparing the above patient parameters between these groups identified significant predictors of duration of hospital stay (lesser or greater than two days). These results were then used to generate a linear regression algorithm to predict the duration of hospital stay (lesser or greater than two days) (24,25).

The same process was repeated to design the lesser or greater than one day duration of hospital stay predictor. The design group in this case was divided into: (i) patients with a duration of hospital stay less than or equal to one day (28 patients) and patients with a duration of hospital stay greater than one day (306 patients).

These models were then prospectively tested on a separate 19 patient “test group” to assess duration of hospital stay prediction accuracy. Testing was performed on this separate group to avoid any training bias.

RESULTS

In the laparoscopic radical/simple nephrectomy group (392 patients), 123 patients (31.4%) had a duration of hospital stay of less than or equal to one day, 135 patients (34.4%) had a duration of hospital stay of one to two days and 134 patients (34.2%) had a duration of hospital stay of greater than two days.

In the laparoscopic partial nephrectomy group (334 patients), 28 patients (8%) had a duration of hospital stay of less than or equal to one day, 119 patients (36%) had a duration of hospital stay of one to two days and 187 patients (56%) had a duration of hospital stay of greater than two days.

Laparoscopic Radical/Simple Nephrectomy: Lesser or Greater Than Two Days Duration of Hospital Stay Predictor

Univariate logistic regression analysis in the design group for duration of hospital stay lesser or greater than two days (Table 3) identified that bilateral nephrectomy, hypertension, smoking, chronic obstructive pulmonary disease, polycystic kidney disease, planned transperitoneal approach, elevated preoperative serum creatinine, and extraction incision were significant predictors of a duration of hospital stay of greater than two days. Extraction incision, if a patient had morcellation, was significant in predicting a longer duration of hospital stay. This is plausible in patients, who underwent morcellation and had a small port extraction incision, likely to have had chronic renal disease and may be in poorer overall health. The patients who underwent simple nephrectomy were combined with those that had a radical nephrectomy because the type of nephrectomy on its own was not significant in predicting duration of hospital stay. The above-mentioned factors identified the patients within the simple nephrectomy group that would require a longer duration of hospital stay. Therefore, having a simple nephrectomy as a factor alone did not contribute in predicting duration of hospital stay.

Multiple logistic regression analysis (Table 3) identified chronic obstructive pulmonary disease, planned transperitoneal approach and elevated preoperative serum creatinine as independent significant predictors of a duration of hospital stay greater than two days.

This analysis identified the appropriate weighting for the above characteristics in the design of a linear regression prediction algorithm. All the above patient parameters were utilized to optimize model accuracy.

The equation for the lesser or greater than two day duration of hospital stay prediction model is:

$$\begin{aligned} \text{2 Day Score} = & (\text{Unilateral/bilateral} \times 6) + (\text{Hypertension}) + (\text{Smoke} \times 4) \\ & + (\text{Chronic obstructive pulmonary disease} \times 4) \\ & + (\text{Polycystic kidney disease} \times 2) - (\text{Planned approach}) \\ & + (\text{Serum Cr}) - (0.1 \times \text{incision type}) \end{aligned}$$

Multiple logistic regression analysis identified chronic obstructive pulmonary disease, planned transperitoneal approach and elevated preoperative serum creatinine as independent significant predictors of a duration of hospital stay greater than two days.

TABLE 3 ■ Laparoscopic Radical/Simple Nephrectomy Group: Analysis for Duration of Hospital Stay Less Than or Greater Than Two Days

Pre-op predictor of less than or greater than 2 days	Odds ratio	Univariate 95% CI	P ^a val	Odds ratio	Multivariate 95% CI	P ^a val
Unilateral vs. bilateral	5.2	2.2-12.1	<0.001	133K	0-∞	0.995
Hypertension	1.7	1-2.7	0.038	1.2	0.7-2.3	0.536
Smoking	2.9	1.1-7.8	0.035	2.4	0.8-7	0.120
COPD	3.4	1.2-9.5	0.021	3.3	1.1-10.3	0.036
Polycystic kidneys	20.7	2.64-63.7	0.004	2.9	0.2-34.8	0.404
Retro vs. trans-peritoneal	0.6	0.4-0.9	0.022	0.6	0.31-1	0.047
Pre-op serum creatinine	1.5	1.2-4.8	<0.001	1.3	1-1.6	0.016
Planned extraction incision	0.7	0.5-0.9	0.017	1	0.6-1.5	0.970

^aP values in this table refer to the comparison of those patients that had a post-op duration of stay less than 2 day versus those greater than 2 day.

Abbreviations: COPD, chronic obstructive pulmonary disease; CI, confidence interval.

Key:

Type of nephrectomy: Unilateral = 0, bilateral = 1

Planned approach: Transperitoneal = 0, retroperitoneal = 1

Incision type: Morcellated = 0, Pfannenstiel, infraumbilical, McBurney's, Gibson = 1, flank incision = 2

If the score is greater than 5, then a duration of hospital stay of greater than two days is predicted. If the score is lesser than 5, a duration of hospital stay of less than or equal to two days is predicted. Model accuracy in the design group was 74% (receiver operating characteristic 0.8) and in the test group was 66% (receiver operating characteristic 0.7) as shown in Table 7.

Laparoscopic Radical/Simple Nephrectomy: Lesser or Greater Than One Day Duration of Hospital Stay Predictor

Univariate logistic regression analysis in the design group for duration of hospital stay lesser or greater than one day (Table 4) identified simple nephrectomy, hypertension and planned morcellation extraction incision as significant predictors of a duration of hospital stay of greater than one day.

Multiple logistic regression analysis (Table 4) identified hypertension and planned extraction incision as independent significant predictors of a duration of hospital stay greater than one day. This analysis identified the appropriate weighting for parameters in the design of a linear regression prediction algorithm. Simple nephrectomy and planned extraction incision were utilized in the final model to optimize accuracy. The addition of hypertension did not increase model accuracy and, thus, was not used. This may be due to the fact that patients with hypertension that stayed greater than one day had one of the other factors concurrently.

The equation for the lesser or greater than one day duration of hospital stay prediction model is:

$$1 \text{ Day score} = (\text{Simple or radical} \times 6) - (0.5 \times \text{Incision type})$$

Key:

Type of nephrectomy: Simple = 2, radical = 1

Incision type: Morcellated = 0, Pfannenstiel, infraumbilical, McBurney's, Gibson = 1; flank incision = 2

If the score is greater than 5, then a duration of hospital stay of greater than one day is predicted. If the score is lesser than 5, a duration of hospital stay of less than one day is predicted. The model accuracy in the design group was 73% (receiver operating characteristic 0.7) and in the test group was 97% (receiver operating characteristic 0.8) as shown in Table 7.

Laparoscopic Partial Nephrectomy: Greater or Lesser Than Two Days Duration of Hospital Stay Predictor

Univariate logistic regression analysis in the design group for duration of hospital stay greater or lesser than two days (Table 5) identified increased age, diabetes mellitus, planned transperitoneal approach, increased tumor size, parenchymal tumor, tumor extending up to renal sinus and tumor abutting the collecting system as significant predictors of a duration of hospital stay of greater than two days.

TABLE 4 ■ Laparoscopic Radical/Simple Nephrectomy Group: Analysis for Duration of Hospital Stay Less Than or Greater Than One Day

Pre-op predictor of less than or greater than 1 day	Odds ratio	Univariate 95% CI	<i>P</i> ^a val	Odds ratio	Multivariate 95% CI	<i>P</i> ^a val
Simple vs. radical	2.9	1.1–7.6	0.035	4.1	0.5–33.4	0.188
<i>Hypertension</i> ^b	4.2	2.2–8.3	<0.001	2.6	1.2–5.8	0.016
Planned extraction incision	0.5	0.3–0.6	<0.001	0.6	0.4–0.8	0.002

Note: Factors in italic were used to create the model.
^a*P* values in this table refer to the comparison of those patients that had a post-op duration of stay less than 1 day versus those greater than 1 day.
 Abbreviation: CI, confidence interval.

TABLE 5 ■ Laparoscopic Partial Nephrectomy Group: Analysis for Duration of Hospital Stay Less Than or Greater Than Two Days

Predictor of less than or greater than 2 days	Odds ratio	Univariate 95% CI	P ^a val	Odds ratio	Multivariate 95% CI	P ^a val
Age	1	1-1.04	0.006	1	1-1.04	0.013
Diabetes	5.4	1.6-18.7	0.007	7.5	2-28	0.003
Approach (trans vs. retro)	2.2	1.4-3.4	<0.001	1.5	0.9-2.5	0.157
Size of tumor (by CT)	1.5	1.2-1.8	<0.001	1.3	1.1-1.6	0.004
Exophytic tumor	0.3	0.2-0.5	<0.001	0.3	0.2-0.6	<0.001
<i>Tumor extends up to renal sinus</i>	4.2	2.3-7.5	<0.001	1.9	0.9-3.8	0.089
Tumor abuts collecting system	3.5	2.2-5.8	<0.001	1.8	1-3.3	0.065

Note: Predictors in italics were used to create the model.

^aP values in this table refer to the comparison of those patients that had a post-op duration of stay less than 2 day vs. those greater than 2 day.

Abbreviations: CT, computed tomography; CI, confidence interval.

Multiple logistic regression analysis identified increased patient age, diabetes mellitus, increased tumor size and parenchymal tumor to be independent significant predictors of a DOS greater than two days.

Multiple logistic regression analysis (Table 5) identified increased patient age, diabetes mellitus, increased tumor size and parenchymal tumor to be independent significant predictors of a duration of hospital stay greater than two days.

This analysis identified the appropriate weighting for the characteristics in the design of a linear regression prediction algorithm. All the above patient parameters except tumor extending up to the renal sinus were utilized to optimize model accuracy. The addition of this particular parameter did not enhance the model accuracy. This may be explained by the fact that all the patients with tumor extending up to the renal sinus had tumors that were more parenchymal, tended to be larger, and were more likely to abut the collecting system. Thus, these other factors identified patients with a duration of hospital stay greater than two days without any further added contribution from the characteristic of tumor extending up to the renal sinus.

The equation for the greater or lesser than two day duration of hospital stay prediction model is:

$$\begin{aligned} \text{2 Day score} = & (\text{Patient age}/59 \times 7) + (\text{Diabetes mellitus} \times 8) + (\text{Planned approach}) \\ & + (\text{Tumor size by CT in cm}) - (\text{Exophytic tumor} \times 5) \\ & + (\text{Abuts collecting system} \times 4) \end{aligned}$$

Key:

Planned approach: Transperitoneal = 1, retroperitoneal = 0

Exophytic tumor: Yes = 1, no = 0

Abuts collecting system: Yes = 1, no = 0

If the score is greater than 10, then a duration of hospital stay of greater than two days is predicted. If the score is less than 10, a duration of hospital stay of less than or equal to two days is predicted. The model accuracy in the design group was 73% (receiver operating characteristic 0.7) and in the test group was 68% (receiver operating characteristic 0.6) as shown on Table 7.

Laparoscopic Partial Nephrectomy: Greater or Lesser Than One Day Duration of Hospital Stay Predictor

Univariate logistic regression analysis in the design group for duration of hospital stay greater or lesser than one day identified 24 patient characteristics as significant predictors for a duration of hospital stay of greater than one day as listed in Table 6. As there were only 28 patients in the design group who had a duration of hospital stay of less than or equal to one day, the statistical significance of some of these parameters may be overstated.

Multiple logistic regression analysis (Table 6) identified congestive heart failure, parenchymal tumor, and tumor abutting the collecting system to be independent significant predictors of a duration of hospital stay greater than one day. This analysis identified the appropriate weighting for characteristics in the design of a linear regression prediction algorithm. The following parameters were utilized in the model: hypertension, gastric esophageal reflux disease, anxiety, hematuria (micro or gross), diabetes mellitus, CRI, gout, congestive heart failure, Crohn's disease, transabdominal approach, solitary kidney,

TABLE 6 ■ Laparoscopic Partial Nephrectomy Group: Analysis for Duration of Hospital Stay Less Than or Greater Than One Day

Predictor of less than or greater than 1 day	Odds ratio	Univariate 95% CI	P ^a val	Odds ratio	Multivariate 95% CI	P ^a val
Hypertension	0	0	<0.001	0.8	0.2–4.1	0.793
<i>History of deep venous thrombus</i>	∞	∞	<0.001	23K	0–∞	0.997
<i>Peripheral vascular disease</i>	0	0	<0.001	0.01	0–∞	0.999
Gastro-esophageal reflux disease	0	0	<0.001	385K	0–∞	0.992
Anxiety	∞	∞	<0.001	90K	0–∞	0.996
Depression	∞	∞	<0.001	178K	0–∞	0.997
<i>Liver cirrhosis</i>	0	0	<0.001	0	0–∞	0.998
<i>Hepatitis C</i>	∞	∞	<0.001	0.04	0–∞	0.999
Hematuria	∞	∞	<0.001	8M	0–∞	0.998
COPD	0	0	<0.001	6M	0–∞	0.993
<i>Alcohol use</i>	∞	∞	<0.001	11K	0–∞	0.997
<i>Hypothyroidism</i>	∞	∞	<0.001	12M	0–∞	0.995
Diabetes	0	0	<0.001	10M	0–∞	0.991
Renal insufficiency	∞	∞	<0.001	24M	0–∞	0.996
<i>Stroke/TIA</i>	∞	∞	<0.001	0.08	0–∞	1.000
Gout	∞	∞	<0.001	37B	0–∞	0.999
Congestive heart failure	0	0	<0.001	0.002	0–0.06	<0.001
<i>Osteoarthritis</i>	∞	∞	<0.001	77K	0–∞	0.997
<i>Thrombocytopenia</i>	∞	∞	<0.001	2M	0–∞	0.996
Crohn's disease	0	0	<0.001	0.2	0–325	0.657
<i>Obstructive sleep apnea</i>	0	0	<0.001	0.4	0–89	0.755
<i>Anemia</i>	∞	∞	<0.001	382K	0–∞	0.999
Transabdominal approach	∞	∞	<0.001	2.9	0.8–10.3	0.093
Solitary kidney	∞	∞	<0.001	72M	0–∞	0.997
Exophytic tumor	0	0	<0.001	0.06	0.01–0.3	<0.001
Tumor extends up to renal sinus	∞	∞	<0.001	1.5	0.3–8.4	0.648
Tumor abuts collecting system	0	0	<0.001	0.02	0–0.1	<0.001

Note: Predictors in italics were used to create the model.
^aP values in this table refer to the comparison of those patients that had a post-op duration of stay less than 1 day versus those greater than 1 day.
Abbreviations: COPD, chronic obstructive pulmonary disease; CI, confidence interval; TIA, transient ischemic attack.

exophytic tumor, tumor extending up to the renal sinus and tumor abutting the collecting system. The combination of these factors provided the optimal accuracy. The addition of the other factors listed in Table 4 did not enhance model accuracy, and thus they were not utilized.

The equation for the lesser or greater than one day duration of hospital stay prediction model is:

$$\begin{aligned}
 \text{1 Day score} = & \text{Hypertension} + \text{Gastro-esophageal reflux disease} \\
 & + \text{Anxiety} + \text{Hematuria} + \text{Diabetes mellitus} \\
 & + \text{COPD} + \text{Gout} + \text{Congestive heart failure} + \text{Crohn's} \\
 & + \text{Transabdominal approach} + \text{Solitary kidney} \\
 & - \text{Exophytic tumor} + \text{Up to sinus} + \text{Abuts collecting system}
 \end{aligned}$$

Key:

Presence of any of the above conditions: Yes = 1, no = 0.

If the score is greater than 0.5, then a duration of hospital stay of greater than one day is predicted. If the score is lesser than 0.5, a duration of hospital stay of less than or equal to one day is predicted. The model accuracy in the design group was 83% (receiver operating characteristic 0.8) and in the test group was 84% (receiver operating characteristic 0.8) as shown in Table 7.

In order to simplify the use of these four models Palm™- and Windows™-based versions were created.

TABLE 7 ■ Accuracy Profiles for the Duration of Hospital Stay Prediction Models

DOS model	Greater or lesser than 2 day		Greater or lesser than 1 day	
	Accuracy (%)	ROC	Accuracy (%)	ROC
<i>Laparoscopic radical/simple nephrectomy</i>				
Design group (393 pts)	74	0.8	73	0.7
Test group (29)	66	0.7	97	0.8
<i>Laparoscopic partial nephrectomy</i>				
Design group (344 pts)	73	0.7	83	0.8
Test group (19)	68	0.6	84	0.8

Abbreviations: ROC, receiver operating characteristic; DOS, duration of hospital stay.

The results illustrate that there are certain preoperative patient parameters that may predict a longer DOS in patients undergoing laparoscopic radical/simple or partial nephrectomy.

Comment: The results illustrate that there are certain preoperative patient parameters that may predict a longer duration of hospital stay in patients undergoing laparoscopic radical/simple or partial nephrectomy.

These parameters may help guide physicians when counseling patients considering these procedures. The models are a user-friendly tool to provide predictions as to the expected duration of hospital stay. These models may be implemented in clinical care pathways to provide efficient use of medical resources during the hospital stay. Two completely separate sets of models (using separate patient groups) were designed for the radical/simple nephrectomy patients and the partial nephrectomy patients, as these are two very different procedures.

The problem with such models is that they tend to be biased to the patient population at the design institution. Therefore, multi-institutional external validation and refinement of the models would enhance their utility. We are currently performing this phase of development.

There are some confounding variables that may be decreasing the predictive accuracy of the models: subjective, but important factors such as baseline patient coping capacity, motivational level of the patient and level of surgeon optimism. However, these factors are difficult to objectively quantify into modeling parameters. Despite these caveats, the models do provide fair predictions based on the patient parameters that were evaluated in this study.

Our design was based on strict statistical methods of univariate and multivariate analysis and logistic regression (24,25).

The accuracy of the models and the receiver operating characteristic values did vary in the test groups compared to the design groups. This may be in part due to the small sample size of the testing groups.

In order to facilitate free exchange and testing of the model, Hand-held and Windows-based computer versions of the model were created. A web-based distribution platform was designed and the programs can be downloaded as free shareware. (from www.uroengineering.com). This allows physicians to use the models in their practice and to validate the effectiveness of the models at their institution.

Conclusions: These models provide 66% to 97% accuracy in predicting the postlaparoscopic nephrectomy duration of hospital stay. These models may allow the urologist to preoperatively counsel patients and to optimize the delivery of care during the hospital stay.

Our group is currently in the process of performing a multi-institutional prospective testing, refinement and validation study for these models. This will assess and develop the model's true widespread clinical utility.

THE FUTURE

Mathematical modeling in laparoscopy and urology will only open more opportunities to further optimize the delivery of care to our patients.

These techniques are merely tools to help better the quality of care provided. However, without multi-institutional collaborative testing, refinement and validation of these models, these tools are unlikely to be widely accepted or utilized. Therefore, the creation of open, noncommercial, freely accessible website platforms (e.g., www.uroengineering.com) for the exchange and development of urology models and concepts is of prime value.

Our design was based on strict statistical methods of univariate and multivariate analysis and logistic regression.

Mathematical modeling in laparoscopy and urology will only open more opportunities to further optimize the delivery of care to our patients.

REFERENCES

1. Flickinger JE, Trusler L, Brock JW III. Clinical care pathway for the management of ureteroneocystostomy in the pediatric urology population. *J Urol* 1997; 158:1221.
2. Koch MO, Smith JA Jr. Cost containment in urology. *Urology* 1995; 46:14.
3. Maxfield C. *Bebop to the Boolean Boogie: An Unconventional Guide to Electronics Fundamentals, Components, and Processes*. 2nd ed. Amsterdam, Boston: Newnes, 2003.
4. Anagnostou T, Remzi M, Lykourinas M, et al. Artificial neural networks for decision-making in urologic oncology. *Eur Urol* 2003; 43:596.
5. Bagli DJ, Agarwal SK, Venkateswaran S, et al. Artificial neural networks in pediatric urology: prediction of sonographic outcome following pyeloplasty. *J Urol* 1998; 160:980.
6. Frank I, Blute ML, Cheville JC, et al. An outcome prediction model for patients with clear cell renal cell carcinoma treated with radical nephrectomy based on tumor stage, size, grade and necrosis: the SSIGN score. *J Urol* 2002; 168:2395.
7. Frank I, Blute ML, Cheville JC, et al. A multifactorial postoperative surveillance model for patients with surgically treated clear cell renal cell carcinoma. *J Urol* 2003; 170:2225.
8. Kattan MW, Scardino PT. Prediction of progression: nomograms of clinical utility. *Clin Prostate Cancer* 2002; 1:90.
9. Eastham JA, Kattan MW, Scardino PT. Nomograms as predictive models. *Semin Urol Oncol* 2002; 20:108.
10. Kattan MW, Reuter V, Motzer RJ, et al. A postoperative prognostic nomogram for renal cell carcinoma. *J Urol* 2001; 166:63.
11. Krahn MD, Bremner KE, Asaria J, et al. The ten-year rule revisited: accuracy of clinicians' estimates of life expectancy in patients with localized prostate cancer. *Urology* 2002; 60:258.
12. Krongrad A, Granville LJ, Burke MA, et al. Predictors of general quality of life in patients with benign prostate hyperplasia or prostate cancer. *J Urol* 1997; 157:534.
13. Moul JW, Snow PB, Fernandez EB, et al. Neural network analysis of quantitative histological factors to predict pathological stage in clinical stage I nonseminomatous testicular cancer. *J Urol* 1995; 153:1674.
14. Moul JW, Connelly RR, Lubeck DP, et al. Predicting risk of prostate specific antigen recurrence after radical prostatectomy with the Center for Prostate Disease Research and Cancer of the Prostate Strategic Urologic Research Endeavor databases. *J Urol* 2001; 166:1322.
15. Mulhall JP, Damaser MS. Development of a mathematical model for the prediction of the area of venous leak. *Int J Impot Res* 2001; 13:236.
16. Parekattil SJ, Fisher HA, Kogan BA. Neural network using combined urine nuclear matrix protein-22, monocyte chemoattractant protein-1 and urinary intercellular adhesion molecule-1 to detect bladder cancer. *J Urol* 2003; 169:917.
17. Parekattil SJ, White MD, Moran ME, et al. A computer model to predict the outcome and duration of ureteral or renal calculous passage. *J Urol* 2004; 171:1436.
18. Tanthanuch M, Tanthanuch S. Prediction of upper urinary tract calculi using an artificial neural network. *J Med Assoc Thai* 2004; 87:515.
19. Tewari A, Narayan P. Novel staging tool for localized prostate cancer: a pilot study using genetic adaptive neural networks. *J Urol* 1998; 160:430.
20. Gettman MT, Kondraske GV, Traxer O, et al. Assessment of basic human performance resources predicts operative performance of laparoscopic surgery. *J Am Coll Surg* 2003; 197:489.
21. Lotan Y, Gettman MT, Roehrborn CG, et al. Cost comparison for laparoscopic nephrectomy and open nephrectomy: analysis of individual parameters. *Urology* 2000; 59:821.
22. Lotan Y, Duchene DA, Cadeddu JA, et al. Cost comparison of hand assisted laparoscopic nephrectomy and open nephrectomy: analysis of individual parameters. *J Urol* 2003; 170:752.
23. Meraney AM, Gill IS. Financial analysis of open versus laparoscopic radical nephrectomy and nephroureterectomy. *J Urol* 2002; 167:1757.
24. Jekel JF, Elmore JG, Katz DL. *Epidemiology, Biostatistics, and Preventive Medicine*. Philadelphia: Saunders, 1996:172 (Chap. 113).
25. Matthews DE, Farewell VT. *Using and Understanding Medical Statistics*. 3rd rev. ed. Basel, New York: Karger, 1996:136 (Chap. 111).

Iqbal S. Shergill, Manit Arya, and Hiten Patel

Institute of Urology and Nephrology, University College London, London, U.K.

- INTRODUCTION
- POTENTIAL APPLICATIONS OF NANOTECHNOLOGY IN UROLOGY
- DELIVERY SYSTEMS FOR DRUG AND GENE THERAPY
- IMAGING AND LABELING WITH NANOSTRUCTURED MATERIALS
- MOLECULAR RECOGNITION
- NANOSURGICAL TOOLS
- SYNTHETIC THERAPEUTIC DEVICES
- NANOTECHNOLOGY AND LIMITATIONS
- NANOTECHNOLOGY AND THE FUTURE
- CONCLUSION
- REFERENCES

Nanotechnology refers to the creation of functional material devices and systems through the control of matter on an atomic or molecular scale—the nanometer scale ($1 \text{ nm} = 1 \times 10^{-9} \text{ m}$). It is at this size scale that most biological molecules inside living cells operate.

INTRODUCTION

Is it science fiction, or is it reality, when a miniscule chip, smaller than what is currently available, is used in the molecular genetics laboratory to considerably accelerate research and to help identify markers of diagnostic, prognostic and therapeutic value? Is it science fiction, or is it reality, when specific drugs are delivered selectively to individual cells in the human body and thus treat potentially incurable diseases, with no side effects? Is it science fiction, or is it reality, when molecular robots are sent into the circulation with the mission of detecting cancer cells, disabling them, and then causing their selective destruction. This apparent science fiction is actually fast becoming reality, in the world of Nanotechnology.

Nanotechnology refers to the creation of functional material devices and systems through the control of matter on an atomic or molecular scale—the nanometer scale ($1 \text{ nm} = 1 \times 10^{-9} \text{ m}$). It is at this size scale that most biologic molecules inside living cells operate.

The prefix “nano” actually originates from the greek word nanos, meaning “little old man” or “dwarf” and the strict definition of nanotechnology is the study, design, creation, synthesis, manipulation, and application of functional materials, devices, and systems through control of matter at the nanometer scale. Nanomedicine, an offshoot of nanotechnology, refers to the highly specific monitoring, repair, construction, and control of human biological systems at the molecular level, using engineered nanodevices and nanostructures (1,2). Over the next decade, it is widely expected that nanotechnology and nanomedicine will have important and innovative applications in clinical research and medicine, as well as contributing \$1 trillion to the global economy (3).

Preliminary designs of nanoparticles, such as artificial red blood cells, white cells, and killer cells that can identify a particular bacteria, or cancer cells, have already been developed, and it is anticipated that nanotechnology will allow urologists to intervene at the cellular and molecular level of any disease process in the future. In this chapter, we introduce important concepts of nanotechnology and discuss published data in the urological literature, which shows the potential for nanotechnology to link molecular signatures to urological cancer behavior and clinical outcome, develop nanoparticle probes for molecular and cellular imaging of urological disease, and for the novel use of nanoparticles for the delivery of drug therapy.

POTENTIAL APPLICATIONS OF NANOTECHNOLOGY IN UROLOGY

There are a wide range of potential applications of nanotechnology in the field of urology, as virtually every use of nanomaterials and nanotechnology in biology and medicine can be applied to urology. This ranges from prevention of disease, to early detection and improvement in diagnosis. In addition, treatment, prognosis, symptom management, and drug delivery of many urological conditions can be accelerated with nanotechnological devices.

Delivery systems for drug and gene therapy are particularly attractive targets in urological practice.

DELIVERY SYSTEMS FOR DRUG AND GENE THERAPY

Delivery systems for drug and gene therapy are particularly attractive targets in urological practice.

Novel drug delivery for prostate cancer using ceramic nanoparticles, carbon magnetic nanoparticles, protospheres and nanogold particles has been investigated in prostate cancer. Paclitaxel loaded biodegradable nanoparticles have been shown to be effective inhibitors of human prostate cancer cell lines in a murine model (4). In addition, enhanced cellular uptake of a triplex-forming oligonucleotide by nanoparticle formation in the presence of polypropylenimine dendrimers has also been found in metastatic prostate cancer cell lines, indicating their potential use for delivering therapeutic oligonucleotides in cancer cells *in vivo* (5). Furthermore, Thomas et al. (6) have shown *in vitro* targeting of synthesized antibody against prostate-specific membrane antigen with conjugated dendrimer nanoparticles as a suitable platform for targeted molecule delivery into appropriate antigen-expressing cells. Studies investigating gene therapy in prostate cancer, have also shown enhanced *in vitro* DNA transfection efficiency by novel folate-linked nanoparticles (7), and similarly a human transferrin-targeted cationic liposome-DNA complex, Transferrin-lipoplex, has shown enhanced stability, improved *in vivo* gene transfer efficiency, and long-term efficacy for systemic p53 gene therapy when used in combination with conventional radiotherapy (8). Anderson et al. (9) have recently demonstrated that a polymer, termed C32, is capable of delivering genes to cancer cells more efficiently and with less toxicity than other polymers that have been tested in the field to date. Therapeutic genes delivered to cells in this manner are able to drive cellular production of a gene-encoded protein through normal processes. By genetically engineering the normal diphtheria toxin gene, a toxin was created that would be produced only in prostate cells. When injected into prostate tumors in animals with C32 nanoparticles, tumour growth was suppressed or reversed, relative to untreated tumors. Research is also being carried out to explore whether nanoparticles can be delivered intravenously to attack metastatic tumor cells, which are found throughout the body in advanced stages of cancer (10).

With the obvious financial potential of a drug delivery system, this particular aspect of nanotechnology is receiving considerable attraction from the commercial sector, specifically the pharmaceutical industry.

IMAGING AND LABELING WITH NANOSTRUCTURED MATERIALS

Body or organ imaging and labeling with nanostructure materials are also being used for adjuncts to uroradiological diagnosis.

Recently, Harisinghani et al. (11) have demonstrated that highly lymphotropic super-paramagnetic nanoparticles, which gain access to lymph nodes by means of interstitial lymphatic fluid transport, allow the high-resolution magnetic resonance imaging of clinically occult lymph node metastases in patients with prostate cancer, which previously have not been detectable by any other non-invasive approach.

Using nanocantilevers, which are flexible beams, resembling a row of diving boards that can be coated with molecules, capable of binding to biomarkers, Wu et al. (12) demonstrated the quantification of prostate-specific antigen at clinically significant concentrations. In addition, a novel reagent for low-level detection in immunoassays has been described by Grubisha et al. (13). The reagent consists of gold nanoparticles modified to integrate bioselective species, such as antibodies, with molecular labels for the generation of intense, biolyte-selective surface-enhanced Raman scattering responses in immunoassays and other bioanalytical applications. In this study they demonstrated free prostate-specific antigen levels of approximately 1 pg/mL in human serum. It has to be appreciated that current research in its infancy at present, and the specificities and sensitivities of such methodology do not yet offer substantial advantages over conventional detection methods. However, it is inevitable that imaging and labeling with nanostructures will be clinically useful in the future in uro-oncology, as well as in non cancer cases (urinary tract stones).

Recently, Harisinghani et al. have demonstrated that highly lymphotropic super-paramagnetic nanoparticles, which gain access to lymph nodes by means of interstitial lymphatic fluid transport, allow the high-resolution magnetic resonance imaging of clinically occult lymph node metastases in patients with prostate cancer, which previously have not been detectable by any other non-invasive approach.

MOLECULAR RECOGNITION

Basic science urological research has undoubtedly benefited from the advantages of nanotechnology, and in the future it is expected that not only will ongoing pre-clinical work be accelerated, but meaningful clinical studies using nanotechnology devices will

be performed rapidly, with results and outcomes useful for clinical practice available as early as the next decade. Particular tools available for performing research include nanowires and nanotubes. Nanowires are sensing wires that can be coated with molecules to bind to proteins of interest and transmit their information through electrodes to computers, whereas nanotubes are cylinder-like assemblies of carbon atoms, with cross sectional dimensions in the nanometre range, and lengths that can extend over a thousand times their diameter. Using such devices, several thousand sensors can be placed on a single chip, offering even greater multiplexing advantages. A variety of novel devices are emerging, such as microarrays with their high precision patterning of biological molecules useful for molecular diagnostics, genotyping and biomarker guided therapeutic targeting (14).

NANOSURGICAL TOOLS

Nanoshells, which are gold shell nanoparticles surrounded by a semiconductor, which can be heated resulting in irradiation of the target cell have been recently used to eradicate transmissible venereal tumours in mice (15). It is widely anticipated that nanoshells will be of widespread use in many urological cancers in the future.

Although further applications of nanotechnology in urology are less well advanced, arguably, they have potentially significant implications. Surgical tools, such as nanotweezers are already in development, and it is anticipated that their everyday use in microsurgical procedures such as vasectomy reversal and varicocele repair are only a few years away. In addition, nanoprobe aiding diagnostic procedures, for example “nanorobots” being used for cystoscopy, ureteroscopy and fulguration of tumours, as well as searching the inferior vena cava and renal vein to detect venous involvement of renal cell cancer, may be just round the corner.

SYNTHETIC THERAPEUTIC DEVICES

The attraction of providing minimally invasive therapies with high functionality is immediately appealing.

Recently, a human nephron filter has been introduced, utilizing nanotechnology, that would eventually make possible a continuously functioning, wearable or implantable artificial kidney (16).

The human nephron filter has been computer-modeled, and operating 12 hr/day, seven days/wk the human nephron filter provides the equivalent of 30 mL/min glomerular filtration rate (compared to half that amount for conventional thrice-weekly hemodialysis). Animal studies should begin in the next one to two years, and clinical trials would follow. The enhanced solute removal and wearable design should substantially improve patient outcomes and quality of life.

Smart nanosensors with communication capability and synthetic therapeutic devices to provide minimally invasive therapies will undoubtedly be developed, with particular interest in urological tissue engineering for urinary tract reconstruction (1).

NANOTECHNOLOGY AND LIMITATIONS

There are potential problems associated with nanotechnology which will have to be fully addressed prior to universal acceptance. The time required for ascertaining their suitability for clinical use might therefore be quite substantial, but it appears that the establishment of faster, safe regulatory approval protocols would ameliorate concerns about the length of time it takes for agents to be assessed (14). Ethical, socio-economic, political and environmental concerns are real, and in addition, there will be a requirement for stringent regulations to prevent potential misuse, such as for terrorist activities.

NANOTECHNOLOGY AND THE FUTURE

The growing importance of nanotechnology is reflected by the increased U.S. Federal Nanotechnology budget from \$270 million in the financial year 2000 to \$738 million in financial year 2003 (17).

The National Institutes of Health has awarded researchers grants totaling nearly \$10 million, to establish a multidisciplinary research program in cancer nanotechnology

Recently, a human nephron filter has been introduced, utilizing nanotechnology, that would eventually make possible a continuously functioning, wearable or implantable artificial kidney.

The growing importance of nanotechnology is reflected by the increased U.S. Federal Nanotechnology budget from \$270 million in the financial year 2000 to \$738 million in financial year 2003.

Nanotechnology is expected to have a significant impact on urological research and clinical practice and will allow urologists to intervene at the cellular and molecular level, with diagnostic and therapeutic clinical benefit.

and to develop a new class of nanoparticles for molecular and cellular imaging. Working at the sub-atomic level, these scientists will be seeking data that will link molecular signatures to patient's clinical outcomes, so that cancers can be predicted, detected earlier, and treated more effectively. The primary focus of the new program will be prostate cancer.

CONCLUSION

Nanotechnology is expected to have a significant impact on urological research and clinical practice and will allow urologists to intervene at the cellular and molecular level, with diagnostic and therapeutic clinical benefit.

Concepts such as nanovectors for the targeted drug delivery, nanowires and nanocantilever arrays for the early detection of precancerous and malignant lesions, nanopores for DNA sequencing, and nanotubes and nanosensors for advanced delivery of therapeutic agents are quickly moving from imagination to a reality, with significant applications relevant to the diagnosis, management, and treatment of all urological conditions.

REFERENCES

1. Shergill IS, et al. Nanotechnology and potential applications in urology. *BJU Int* 2006; 97(2):219–220.
2. <http://nihroadmap.nih.gov/nanomedicine>
3. http://nsf.gov/eng/engadvice/PastMeetings/documents/nanoupdate_000.ppt
4. Sahoo SK, Ma W, Labhasetwar V. Efficacy of transferin-conjugated Paclitaxel-loaded nanoparticles in a murine model of prostate cancer. *Int J Cancer* 2004; 112(2):335–340.
5. Santhakumaran LM, Thomas T, Thomas TJ. Enhanced cellular uptake of a triplex-forming oligonucleotide by nanoparticle formation in the presence of polypropylenimine dendrimers. *Nucl Acids Res* 2004; 32(7):2102–2112.
6. Thomas TP, et al. In vitro targeting of synthesized antibody-conjugated dendrimer nanoparticles. *Biomacromolecules* 2004; 5(6):2269–2274.
7. Hattori Y, Maitani Y. Enhanced in vitro DNA transfection efficiency by novel folate-linked nanoparticles in human prostate cancer and oral cancer. *J Contr Release* 2004; 97:173–183.
8. Xu L et al. Self-assembly of a virus-mimicking nanostructure system for efficient tumor-targeted gene delivery. *Hum Gene Ther* 2002; 13(3):469–481.
9. Anderson DG, Peng W, Akinc A, et al. A polymer library approach to suicide gene therapy for cancer. *Proc Natl Acad Sci USA* 2004; 101(45):16028–16033.
10. <http://nanotechwire.com/news.asp?nid=1523>
11. Harisinghani MG et al. Noninvasive detection of clinically occult lymph-node metastases in prostate cancer. *N Engl J Med* 2003; 348(25):2491–2499.
12. Wu G et al. Bioassay of prostate-specific antigen (PSA) using microcantilevers. *Nat Biotechnol* 2001; 19(9):856–860.
13. Grubisha DS et al. Femtomolar detection of prostate-specific antigen: an immunoassay based on surface-enhanced Raman scattering and immunogold labels. *Anal Chem* 2003; 75(21):5936–5943.
14. Ferrari M. Cancer nanotechnology: opportunities and challenges. *Nat Rev Cancer* 2005; 5:161–171.
15. Hirsch LR et al. Nanoshell-mediated near-infrared thermal therapy of tumors under magnetic resonance guidance. *Proc Natl Acad Sci USA* 2003; 100:13549–13554.
16. Nissenson AR, Ronco C, Pergamit G, Edelstein M, Watts R. Continuously functioning artificial nephron system: the promise of nanotechnology. *Hemodial Int* 2005; 9(3):210–217.
17. <http://www.nano.gov/2003budget.html>

Richard M. Satava

Department of Surgery, University of Washington Medical Center, Seattle, Washington and Advanced Biomedical Technologies, Defense Advanced Research Projects Agency (DARPA), Arlington, Virginia, U.S.A.

- INTRODUCTION
- CLINICAL PRACTICE
- EMERGING TECHNOLOGIES
- EDUCATION AND TRAINING
- RESEARCH FOR CLINICAL TRIALS
- MORAL AND ETHICAL CHALLENGES
- CONCLUSION
- REFERENCES

Technology has become a major driver of the future direction of healthcare and surgery. Likewise, the speed of change has accelerated beyond comprehension, with a number of revolutions occurring during a surgeon's career. Being an agent of change or rapidly adapting to change has become the hallmark of the gifted surgeon. The fundamental challenges to a future surgeon are addressed from a technological viewpoint, with emphasis on the impact upon the practice of surgery.

INTRODUCTION

Technology has become a major driver of the future direction of healthcare and surgery. Likewise, the speed of change has accelerated beyond comprehension, with a number of revolutions occurring during a surgeon's career. Being an agent of change or rapidly adapting to change has become the hallmark of the gifted surgeon. The fundamental challenges to a future surgeon are addressed from a technological viewpoint, with emphasis on the impact upon the practice of surgery.

Everything occurs in cycles: revolution, change, adaptation to change, acceptance of the new standard, codifying the new establishment, resistance to further change, revolution, and the cycle begins again. In healthcare and surgery, this cycle had been occurring about every 100 years, but recently there has been a perceptible acceleration of this cycle. The first revolution for surgery came during the Industrial Age in the mid-1800s simultaneously with the introduction of anesthesia, asepsis, pathology, new instrumentation, and so on. Nearly a 100 years later, in the mid-20th century, as the Information Age was about to begin, surgery was advancing with antibiotics, intravenous fluid and hyperalimentation, radical surgery resections, and chemotherapy to name but a few. By the 1990s, laparoscopic (or minimally invasive) surgery emerged and became the standard for many procedures. Information Age technologies, such as video cameras and monitors, continued the evolution. But technology is accelerating faster than ever, and we are on the threshold of yet another revolution. This is referred to as the Biointelligence Age (1), an age of multidisciplinary medicine that can achieve much more than a single researcher or clinician can. The complexities of nature are yielding to interdisciplinary teams performing multidisciplinary research—genomics as a combination of biology and information sciences or robotics as a combination for physical (engineering) and information sciences. Much as previous revolutions, this current transformation is occurring because many different technologies are converging to fundamentally change surgery. There is a veritable explosion of new discoveries, such as genomics, micro-electro-mechanical systems, robotics, intelligent systems, molecular biology, etc. The entire surgical environment and culture is changing at an unprecedented rate of innovation that challenges the practicing surgeon every day. The change is occurring because of “disruptive technologies” that seemingly overnight completely reverse the fundamental approaches that have been standard for decades. In addition to technology, the surgical environment includes clinical practice, reimbursement, regulatory (such as Health Information Portability and Privacy Act), education and training, certification, research, and clinical trials. Because it is not possible to do justice to all those competing forces, the focus shall be upon the impact of technology, while fully admitting that at any one time, any of the factors play a dominant role in the life of a surgeon.

The opinions or assertions contained herein are the private views of the author and are not to be construed as official, or as reflecting the views of the Department of the Army, the Department of the Navy, the Defense Advanced Research Projects Agency, or the Department of Defense.

CLINICAL PRACTICE

Most practicing surgeons have already seen at least one significant revolution during their careers, the radical changes brought by the many discoveries of the Information Age. The most dramatic has been the shift to minimal access surgery (laparoscopic, endoscopic, etc). The surgeon of the near future will be trying to decide (just as was the case with the introduction of laparoscopic surgery) whether it will be necessary to train and practice with robotic surgical systems. Surgeons already have multiple options—open surgery, laparoscopic, endoluminal, endovascular, percutaneous, and so on. The answer to robotic surgery is an unequivocal yes.

Current view of robotic surgery is that the robot is used to enhance the performance of the surgeon—either through more precise motions or through providing access to very restricted places. While this is true, the real value of robotics is that it brings surgery completely into the Information Age. Open surgery is Industrial Age, with directly looking and feeling the organs and directly moving the tips of the instruments. Laparoscopic surgery is a transition: half in the Industrial Age—still directly moving instrument tips—and half in the Information Age—looking at the monitor with the electronic image (information) of the organs, not looking at the organs themselves. Robotics makes the transition to the Information Age complete by looking at information (the monitor) and manipulating information (hand motions send electronic signals that control the tip of the instruments). It is not longer blood and guts, it is bits and bytes.

This is a profound revolution, because it is now possible to integrate the entire surgical care of a patient with information science right at the surgical console of a robotic surgery system (Fig. 1). From the console, the surgeon can perform open surgery or laparoscopic surgery, can remotely operate with telesurgery, can rehearse a specific surgical procedure on a patient-specific three-dimensional image derived from the patient's computed tomography scan, can integrate the image during surgery with image-guided surgery to give the surgeon "X-ray vision," and can practice and train on the console using virtual reality surgical simulation. Thus from preoperative planning to specific surgical procedure rehearsal, to open or laparoscopic or interventional procedure, to training (for new procedures) all components become a single, seamless continuity for patient care. Although not yet implemented, the surgeon's hand motions can be recorded and archived as proof of proficiency on a continual basis (instead of periodic recertification).

Next generation robotic systems will also incorporate automatic tool changers (instead of scrub nurse to change the instruments) (Fig. 2) and automatic supply dispensers (instead of the circulating nurse) for suture, gauze, etc. Soon the surgeon will become a solo-surgeon in the truest sense of the word, controlling the entire operation from the console. Because there will be no people assisting the robot (the three systems together are called a "robotic cell"), the surgeon can sit at the console just outside of the operating room (looking through a glass window), and there will be no people in the operating room. Every time a tool is changed or a supply is dispensed, three actions immediately occur: The patient is billed, the tool or supply is restocked, and an order is



FIGURE 1 ■ Integrating surgery with surgical robotics. *Source:* Courtesy of Joel Jensen, SRI International, Menlo Park, California.



FIGURE 2 ■ Penelope—the robotic scrub nurse. *Source:* Courtesy of Michael Treat, MD, Columbia University, New York, New York.

FIGURE 3 ■ The force reflecting grasper. Source: Courtesy of Blake Hannaford and Jacob Rosen, University of Washington, Seattle, Washington.



sent to inventory control to order a new tool or supply—all within 50 msec with 99.99% accuracy (which is the current industry standard). The result is clearly a dramatic improvement in performance and efficiency, as well as cost saving.

Another change in robotic systems is that they are incorporating new types of tools. By using micro-electro-mechanical system technology, tiny sensors can be inserted into the instruments to measure pressure, forces, etc. (Fig. 3) to provide for the surgeon the sense of touch (2), not only mimicking what the surgeon would actually feel, but also providing delicate touch beyond what is possible with the human fingertip.

There will also be an entire new tool-set for the surgeon of the future. Although the scalpel will still be required, many other modalities will be used. The trend is from mechanical instruments (of the Industrial Age) to energy-directed instruments (of the Information Age). Surgeons have begun using lasers, and next generation systems will employ high intensity focused ultrasound, thermal-directed systems (brachytherapy and cryotherapy), microwave instruments, and femtosecond lasers. These systems will require a complete rethinking of what it means to be a surgeon. The high intensity focussed ultrasound concentrates two beams of ultrasound at a distance, in this case inside the body. Early clinical trials are being conducted in breast, prostate, and liver tumors to completely coagulate or vaporize them from external high intensity focussed ultrasound system. In addition, animal trials have been successful in stopping bleeding from the liver and spleen transcutaneously (3). Thus surgeons will have to begin thinking about performing surgical procedures without entering the body or using a scalpel. There is also significant progress with femtosecond lasers. These new lasers are totally different from those used today—they release their energy in 10^{-15} seconds. The result is that it is possible to create a hole in the cell membrane without injury to the cell. This allows optical tweezers (another form of laser) to enter the cell and manipulate individual organelles, such as Golgi bodies or mitochondria. Additional progress is being made on entering the nucleus and directly manipulating the DNA. The significance is that the surgeon of the future may not be removing organs or tissues but rather using a microscope and laser rearrange the DNA inside the cell to change the fundamental biology—this is referred to as biosurgery (4).

EMERGING TECHNOLOGIES

The craft of surgery has revolved around correcting the structural and anatomic consequences of diseases. Malignant growths require the removal of entire organs or tissues and even radical resection of adjacent areas. However, there is always the conflict of goals, between removing enough tissue and conserving enough organ function. Transplantation has been a growing discipline because of the opportunity to remove entire organs and then replace their function with a donated organ. However, the supply is limited, and rejection is a constant problem. Tissue engineering artificial organs has progressed to a level where small amounts of organs are being synthetically grown. Vacanti and coworkers at Massachusetts General Hospital have been able to grow an artificial blood vessel system from endothelial stem cells, and are now using that vascular tree with

hepatic stem cells to grow artificial livers (5). These, and other approaches by different researchers, point to a time in the near future when it will be possible to grow a new organ from a patient's own stem cells. If this becomes the case, then it is theoretically possible that for nearly every disease, the surgeon will simply remove the patient's diseased organ and replace it with a new one (grown from the patient's own stem cells), without the fear of rejection. Therefore it may be that the future surgeon will perform only one operation for each organ system, no matter what the disease—remove the old one and replace it with a new one. This will dramatically impact the way the surgeon will practice, either by having a single operation for all patients in a practice (in the case of specialists) or a return of preeminence of general surgery, where every practice will consist a few operations to take care of all the major organ systems.

The replacement of human organs or functions has also been addressed by the use of prostheses; however, with the exception of the cardiac pacemaker, all prostheses have been inert and “dumb,” that is, they do not respond the changing conditions in the body. Once implanted, artificial hips keep their position, and over time either wear out or cause problems such as loosening or damage to surrounding structures. Now prostheses are becoming “smart,” with micro-electro-mechanical system sensors to detect changes and actuators to adjust the prostheses. This same feedback is being programmed into implantable devices, such as an insulin pump for diabetes (6). Ophthalmologists are implanting the first generation of artificial retinas into patients (7). This implies a future where surgeons will be asked to implant more and more artificial “parts,” to either replace or enhance human function.

EDUCATION AND TRAINING

Until the beginning of the 20th century, nearly all training of surgeons was by passing down the conventional knowledge from previous surgeons—this was not based upon any scientific principles, but rather by ritual and tradition. In 1908, Senn was the first surgeon to criticize this practice (8), and bring forward the scientific principles of using observation and experience for education and training. Although this mentoring process continued, it was strict scientific principles, gained through experimentation and evidence, that formed the basis for surgical education and training. The Halstedian method of apprenticeship has become the model for surgical training, based upon rigorously applied scientific principles. However, this model is somewhat capricious, with the determination of competency of the resident being at the discretion of the supervising faculty and department chairman. With the exception of the written examination of the resident's knowledge, there are no objective measures of performance.

There is a new paradigm emerging in the field of surgical education. Objective measures are the new basis for training and assessing residents. Some of this change is being driven by new training methods, such as the Objective Structured Clinical Exam and the Objective Structured Assessment of Technical Skills (9). Other pressure is coming from the need for objective demonstration of competency. One technology that is fueling this change is the use of surgical simulators that can accurately measure hand motions and quantitatively report psychomotor skills. This ability to measure is driving the most fundamental change of all—that of training for a given period of time to the new paradigm of setting of criteria which the resident must achieve before progressing to the next level—so called criterion- or proficiency-based training. In 2002, Seymour et al. demonstrated unequivocally that residents that train on a simulator perform better in the operating room, taking less time and making less errors (10). Thus, the time is near when every resident will have to train on a simulator to reach a certain level; those who have better skills will achieve it faster, those who are slower will take longer. However no resident will operate on a patient until they have passed the simulator by achieving a high level of technical proficiency. No longer will residents be permitted to “practice” on patients. This will eventually spread to all surgeons, especially in learning new procedures such as laparoscopy. A week-end course may or may not be long enough—for the gifted surgeon may be able to demonstrate proficiency in that short period of time, while others may need further training. For the long-term maintenance of surgical privileges, it will be required to be recertified, including technical skills on a simulator. Eventually, each surgical procedure will be objectively assessed, as a method to continuously assure maintenance of surgical skills. This is not unlike the requirement for airline pilots today. Thus, surgical simulation and continuous assessment of performance to an objective level of proficiency will become the new standard for training, assessment, credentialing, and practice.

RESEARCH FOR CLINICAL TRIALS

Many practicing clinical surgeons engage in clinical research, either for a new medication, a new surgical procedure, or other innovation. The simple reporting of a series of cases to the literature has yielded to the randomized, double-blind clinical trial, adding a new level of scientific rigor to the research and reporting of new therapies. This requirement for “evidence-based medicine” is significantly increasing the quality of research and improving overall patient care; however, the time and cost involved in conducting such rigorous trials are enormous and have delayed many new therapeutic options. In addition, it is not possible to know the final outcomes in many instances, such as cancer, where it takes 20 years or longer until the long-term results (including possible complications) are known. However, other industries have been using modeling and simulation to predict outcomes into the future. Theoretically, the day will come when a virtual clinical trial will use predictive simulation of a therapy on a million patients over 50 years—on one week of supercomputer time. The accuracy of such predictions will be determined by how accurate the models of humans can become, from the genetic and cellular all the way to the organ and whole body level. Today drug companies are using “rational drug design” by computer programs and then doing virtual testing and evaluation of the products based upon the pharmacologic properties. This is the first step toward doing “predictive simulation” for clinical trials. The advantage for surgeons is that it will be possible to provide much more accurate information on the efficacy of drugs or surgical procedures that is available today as well as to customize the therapy for each patient.

MORAL AND ETHICAL CHALLENGES

A number of these new technologies will be raising moral and ethical questions that have never been considered before. Success with nanotechnology will be forthcoming rather soon, with a significant amount of speculation on the role of “nanomachines”—tiny systems that are injected into the blood stream or other areas of the body, for diagnostic or therapeutic purposes. The long-term effect of such systems will not be known for decades to come, however, there will be pressure to begin inserting them. Should surgeons comply with their patients’ requests, even in the face of unconvincing evidence of efficacy, or if efficacy is shown but long-term results are not known? Robotics is moving forward deliberately, but a new dimension will likely be soon available—femtosecond lasers to operate within the cell and even upon the nucleus and DNA. Although, it seems reasonable to remove a gene that leads to a congenital defect, should surgeons be tinkering with genes directly, and leading to the purposeful genetic design of children for characteristics such as eye or hair color? Or perhaps provide genetic material, such as the sequence that allows the pit viper snake to use infrared vision to see in the dark, to have characteristics that humans do not naturally have? With smart prostheses and artificial organs, it may be possible to extend life beyond the average life span for humans—to 150 or 200 years. What would the consequences to society be of such a prolonged lifespan, and will a person retire at age 65 with 90 to 100 years of “retirement?” The results of the research in today’s laboratories are providing potential not only to change an individual or even society, but also to define what it means to be human. If 90% of our body parts are replaced with artificial organs or prostheses, will we still be human—is it the flesh and blood that we were born with determine whether we are “human?” While these have previously been mere speculations of fantasy, the scientific underpinnings are being created in the laboratory today, and the students we are training today will have to answer the above questions, and more. How can we prepare for such a future challenge?

CONCLUSION

This is a time in the history of medicine when truly revolutionary change is occurring, and at a rate that has never been seen before. While it is a historic fact that each generation of surgeons greatly surpasses the accomplishments of the preceding generation, the order of magnitude of change that is occurring now is unprecedented. The surgeon of the future will need to adapt, to be able to learn a wider range of the new technologies, and quicker than ever before. And the amount of information that needs to be learned will increase. The paradigm of training is changing from simple mentorship to proficiency-based, quantifiable assessment, and the surgeon will be held to even higher

standards than today. Yet, the extra amount of work required to achieve these new standards is essential to be worthy of the enormous responsibilities that the changes of the coming generation will bring—the surgeons of the future will not only hold the lives of their individual patients in their hands, but may be responsible for the future of what it means to be human.

REFERENCES

1. Satava RM. Innovative technologies: the Information Age and the Biointelligence Age. *Surg Endosc* 2000; 14:417–418.
2. Rosen J, Hannoford B, MacFarlane MP, Sinsman MN. Force controlled and teleoperated endoscopic grasper for minimally invasive surgery—experimental performance evaluation. *IEEE Trans Biomed Eng* 1999; 46(10):1212–1221.
3. Noble ML, Vaezy S, Keshavarzi A, et al. Spleen hemostasis using high intensity ultrasound: survival and healing. *J Trauma* 2002; 28:1115–1120.
4. Satava RM, Wolff R. Disruptive visions: BioSurgery. *Surg Endosc* 2003; 17:1833–1836.
5. Lalan S, Pomerantsva L, Vacanti JP. Tissue engineering and its potential impact on surgery. *World J Surg* 2001; 25:1458–1466.
6. Selam JL. External and implantable insulin pumps: current place in the treatment of diabetes. *Exp Clin Endocrinol Diab* 2001; 109(suppl 2):S333–S340.
7. Hammerle H, Kobuch K, Kohler K, Nisch W, Sach H, Stelzle M. Biostability of micro-photodiode arrays for subretinal implantation. *Biomaterials* 2002; 23:797–804.
8. Senn N. The dawn of modern military surgery. *Surg Gynecol Obstet* 1908:477–482.
9. Martin JA, Regehr G, Reznick R, et al. Objective structured assessment of technical skill (OSATS) for surgical residents. *Br J Surg* 1997; 84: 273–278.
10. Seymour NE, Gallagher AG, Roman SA, et al. Virtual reality training improves operating room performance: results of a randomized, double-blinded study. *Ann Surg* 2002; 236:458–464.

INDEX

Abdomen

- adhesions, 381
- cavity, hand incision, 789
- extraperitoneal drain, 7
- fascia, anterior, 971
- hysterectomy, 411
- surgery, 242, 971
 - preparation for, 188
- viscera, inspection of, 5
- wall, 432
 - anatomy, 432
 - injury, risk of, 1036
 - layers, 68, 435
 - lifting method, 813, 818
 - metastases, 817
 - neuralgias, body mass index, 930–931
 - parietal peritoneum of, 433
 - relaxation, 456
 - vasculature, by transillumination, 1036

Abdominal wall lift (AWL), 813, 818

- cardiovascular and respiratory effects, 976
- mechanical, 976

Abdominopelvic inspection, 396

Absorbable fibrin adhesive bandage (AFAB), 94

Accessory pudendal arteries, 738

Acellular bladder submucosa (ABS), 1056

Acellular collagen matrix, 1057

Acidosis, 33, 475

- See also Acidosis fetal, 987

Acoustic coupling, 1001

Acute appendicitis, 984

- diagnosis of, 989

Acute febrile abdominal pain, 941

Acute ischemic necrosis, postoperative, 404

Acute renal failure, 40

Acute-phase response (APR), 954

- molecules in, 956
- tumor necrosis factor (TNF) receptors in, 956

Adenocarcinoma cells, 468

- prostatic, 631

Adhesions, incidence and severity of

- intraoperative, 479

Adhesive glycoproteins, 92

Adnexal masses, 944, 991

- benign, characteristics of, 944
- complications of, 991
- management strategies of, 991
- during pregnancy, 991
- symptoms of, 991

Adnexal torsion, 991, 992

- during pregnancy, 991
- in postmenopausal women, 944
- risk of, 991

Adrenal gland

- anterio-medial, 17
- arterial supply of, 207
- bleeding in, 198
- dissection of, 17, 198
- injury to, 198
- left, retroperitoneal approach to, 17
- left, transperitoneal approach to, 16–17
- lesions of, 223
- malignancy, 468
 - laparoscopic management of, 187
- mass, case reports of, 467
- metastasis, 468
- mobilization of, 16, 123
- parenchyma, 212, 1003
- posterior-medial, dissection of, 17
- retroperitoneal approach, 17
 - lateral, 190
 - posterior, 190
- right, retroperitoneal approach to, 16
- right, transperitoneal approach to, 15–16
- transperitoneal lateral approach, 189
 - advantages and disadvantages of, 189
- tumors, 757
 - hormonally active, 223
- vein, intraoperative ultrasound of, 212
- venous drainage, 478
- vessels, divisions of, 207
 - artery, 196
 - cancer, 224
 - carcinoma, 825

Adrenalectomy, 223, 578–579

- for adrenocortical carcinoma, 466
- bilateral *da Vinci*® assisted, 892
- laparoscopic, 891
 - indications and contraindications of, 825
- left, 884
- for malignant adrenal lesions, 468
- metastasis, solitary, 465–466
- open, 187, 225
- partial
 - drawback of, 209
 - for nonfunctioning incidentaloma, 210
- right, 885
- robotic, 891
- supragastric left-sided, 200
- thoracoscopic transdiaphragmatic, 201
 - clinical experience, 831
 - patient selection, 827–828
 - surgical technique, 828–831

Adrenalectomy, laparoscopic, 1002

- for benign disease, 226–228
- bilateral, 186
- for cancer, 469
- contraindications for, 187–188, 226, 825

- equipment and set-up, 193
- hand-assisted, 201
- indications for, 186, 223, 226
- lateral, retroperitoneal, 199
- lateral, transperitoneal technique of, 193
- for malignancy, 469
- for metastatic disease, 187
- for pheochromocytoma, 186, 989–990
- postoperative care in, 196
- during pregnancy, 188
- right-sided transperitoneal, 194–195
- robotic applications, 201
- safety of, 467
- technique, 198
- transperitoneal patient positioning in, 194

Adrenal hyperplasia, 209

Adrenal lesions

- computed tomography scanning of, 224
- diagnosis, 223
- evaluation, 224
- magnetic resonance imaging of, 224

Adrenocortical carcinoma (ACC), 187, 466, 469

- adrenalectomy for, 466
- staging system for, 466
- treatment of, 825

Advanced robotics and telemanipulator system for minimally invasive surgery (ARTEMIS) system, 110

Aerosolization, 468

- of tumor cells, 749

AESOP® (Computer Motion, California), 107, 109, 142, 172, 211, 266, 340, 1092

Air embolism, risk of, 6

Aldosteroma, treatment of, 825

Aldosterone adenoma, 213

Aldosterone-producing adenoma (APA), 207

Aldosteronomas, 225

- medical management of, 224
- resection of, 186

Alias®, computer graphics animation in, 1118

Alken's needle insertion, 282

Allen stirrups (Allen Medical, Ohio), 395

Amyloidosis, 973

Anatrophic nephrolithotomy, laparoscopic, 98, 283–284

Anderson-Hynes dismembered pyeloplasty, 160, 847, 887

- in adult patients, 306
- in pediatric patients, 308
- for robotic-assisted cases, 308
- trocar positioning in, 306

Androgen replacement therapy, 1084

Anesthesia

- considerations, 986

- Anesthesia (*continued*)
 cost of, 1011
 induction of, 786
 management strategies, 986
 simulator, 1116
- Angiocatheter, 761, 839
- Angiography, 904
- Antegrade continent enema (ACE), 662
- Anterolateral wall, 432
- Anti-inflammatory drugs, nonsteroidal, 973
- Antibiotic prophylaxis, 718, 779
- Antigen
 carcinoembryonic, 465
 cells, expressing, 1142
 genes, recognition, 954
- Antigen presenting cells (APCs), 954
- Antithromboembolism stockings, 189
- Antithrombotic prophylaxis, 626
- Antituberculosis drugs, 243
- Aortic bifurcation, 620
- Aortorenal bypass, laparoscopic, 841–842
- Aponeurosis, 23, 433
- Appendectomy, 989
 laparoscopic, 6, 8
- Aprotinin, bovine, 94
- Argon beam coagulator (ABC), 69, 98, 249, 269, 331, 343
- Arterial blood gas, 928
- Arterial resistance, 30
- Arterial vasospasm, 341
- Arteriovenous, fistula development, 132
- Aspirator, 71
 systems, ultrasonic, 198
- Asynchronous transfer mode (ATM), 1093
- Atherosclerosis, 479
- Atherosclerotic renovascular disease, 523
- Atracurium(tm), 626
- Atraumatic graspers, 69, 719
- Atraumatic ring clamp, 284
- Atraumatic suction graspers, 199
- Auscultation, 828
- Autoimmune thrombocytopenic purpura, 990
- Automated endoscopic system for optimal positioning. *See* AESOP®.
- Autopsy, 842, 1074
- Autosomal dominant polycystic kidney disease (ADPKD), 241, 243–244, 261
- Autotransplantation, laparoscopic-assisted, 162
- Axial force control, 907
- Bair Hugger (Augustine Medical Inc., Minnesota), 839
- Balloon
 cannula, 514
 dilation, 121
 Balloon dilator, 255, 514
 Balloon mounted tip, 514
 Balloon trocar, 68
- Beam radiation therapy, 718
- Benign disease, laparoscopic adrenalectomy for, 226–229
- Benign epithelial neoplasms, 945
- Benign prostatic hypertrophy (BPH), obstructive symptoms of, 859
- Benign tumors, of reproductive age women, 940
- Beriplast P® (Aventis Behring, Germany), 93
- Bernstein anastomosis, 650
- Bile duct injury, 1028, 1045
- Biliary disease, symptoms of, 988
- Bioadhesive agents, 101
- Biocol® (LFB-Lille, France), 93
- Biologic hemostatic sealant, 528
- Biopsy
 in children, 250
 diagnostic, 555
 incisional, 557
 laparoscopic, 251
 open, 251
 prostate, 108
 transjugular kidney, 251
- Bladder augmentation, 164, 382
 intestinal segments for, 1067, 1075
 laparoscopic, 1055
- Bladder cancer, 619–620, 637, 670
- Bladder cuff excision, 166, 575
 contraindications of, 576
 dissection of, open, 576
 indications of, 576
 and laparoscopic radical nephroureterectomy, 886
 management of, 565–566
- Bladder defects, 413
- Bladder diverticulectomy, 287
 advantages and disadvantages, 857
 complications, 857
 history of, 855
 indications and contraindications, 855–856
 laparoscopic, 855
 surgical technique, 856–857
- Bladder drainage, postoperative, 386
- Bladder flap reimplantation, 851
- Bladder injury, 947
 diagnosis of, 1038
- Bladder integrity, 413
- Bladder mobilization and cystotomy, 385–386
- Bladder mucosa, 863
- Bladder neck, 396, 730
 anterior aspect of, 708
 contractures, 878
 dissection of, 684, 718
 incision, 684
 intracorporeal, 150
 palpation of, 708
 posterior, 152, 708, 721
 reconstruction of, 684
 suspensions, 165
 suture, 404
 transection, 708, 720–721
- Bladder neck-sparing technique, 684
- Bladder outlet obstructive symptoms, 1117
- Bladder perforation, 763
 intraperitoneal, 164
- Bladder reconstruction
 laparoscopic, 164
 muscular, 146
- Bladder smooth muscle cells, 1068
- Bladder stab wounds, 1038
- Bladder stricture rate, 738
- Bladder submucosa coated with urothelial and detrusor cells (BSCC), 1056
- Bladder surgery, laparoscopic technique to, 669
- Bladder sutures, 403
- Bladder symptomatology, 940
- Bladder tumor, 577, 749
- Blood coagulation, 92
- Blood gas, arterial, 928
- Blood tests, preoperative routine, 511
- Blood transfusion, 529, 980
- Blue Dragon® robot, 1121
- Blunt cannula, 972
- Blunt dissection, 123, 443, 971
- Blunt finger dissection, 547, 711
- Blunt tip trocar, 255, 547
- Bluntip® cannula (U.S. Surgical, Connecticut), 836
- Bluntip® trocar (Origin MedSystems), 121
- Bluntport® (U.S. Surgical, Connecticut), 706
- Body mass index (BMI), 718, 892, 1133
- Bolheal® (Kaketsuken Pharmaceuticals, Japan), 93
- Bosniak classification, for renal cyst lesions, 262
- Bovine aprotinin, 94
- Bowel anastomosis, 670
- Bowel injury, 441, 1030, 1036
 abdominal access-related, 911–913
 electrocautery, 915–917
 Hasson's method, 913
 laparoscopic, 915
 etiology of, 914
 pelvic lymph node dissection, 1038
 non-access-related, 913–915
 risk factor for, 918
 thermal, 915, 916
 trocar-induced, 912
- Bowel insufflation, 911
- Bowel lacerations, laparoscopic management of, 1032
- Bowel obstruction, complications of, 1040
- Bowel perforation, 915
 mechanical, 475
- Bowel segment, isolated, detubularization and reconfiguration of, 384
- Bowel surgery, laparoscopic
 indications and contraindications, 643
 operative techniques, 644–646
 right colectomy, 644
 sigmoid/left colectomy, 644–646
 perioperative care, 643
- Bozzini Phillip, 3
- Brachial plexus, 923, 926, 929–931
- Brachytherapy, 1079
- Bradydysrhythmias, 37
- Brain damage, anoxic, 357
- Bricker-type ureteroileal anastomoses, 651, 670
- Bronchopulmonary dysplasia, 758
- Bruck julius, 4
- Bruck's technique, 4
- Burch colposuspension, 393
 gasless laparoscopy, 399
- Burch laparoscopic, 397
 abdominal wall vascular injury in, 404
 acute ischemic necrosis of, 404
 advantage of, 399, 404
 anastrophic nephrolithotomy, 98, 284
 aortorenal bypass, 841–842
 appendectomy, 6, 8
 appendicovesicostomy, 662
 transperitoneal approach, 473–474
 augmentation ureterocystoplasty, 1072
 bilateral pelvic lymphadenectomy, 638
 bladder augmentation, 381–388

- bladder injuries, 412
- blood loss with, 403
- boari flap ureteroneocystostomy, 851–852
- bowel injury, 851
- comparison of, 401–402
- complications of, 398, 402–405
- extraperitoneal, 398, 399
- hernia formation in, 13
- injury rate in, 403
- lower urinary tract (LUT) injury rate, 403
- and open procedures, hospital cost for, 1021
- and Raz procedure, comparison of, 400
- suture technique of, 399
- transperitoneal, 398
- versus bone-anchored sling, 402
- versus open Burch colposuspension, 400–401
- versus tension-free vaginal tape suburethral sling
- Burch sutures, 397
- parasagittal view of, 395
- Burch-Tanagho colposuspension, 393, 400

- Cadaver kidney grafts, 354
- Cadaveric fascia, 402
- Cadaveric renal transplantation, 337, 362
- Calicoplasty, laparoscopic, 161
- Calicorrhaphy, laparoscopic, 161
- Calyceal diverticula
 - epithelium, management of, 332–333
 - identification, 329
 - imaging, 326
 - infundibulum, identification and management of, 331–332
 - treatment selection, 327
 - types, 325
- Calyceal diverticulectomy laparoscopic technique, 329–335
- cystoscopic placement of ureteral catheter, 329
- drain placement and exit, 9
- epithelium, management of, 332–333
- excision of overlying renal parenchyma, 330–331
- identification, 329
- instruments, materials, and devices utilized for, 10
- nephrolithotomy, 331
- obliteration of diverticular cavity, 8–9
- operative exposure, 330
- Cancer, 734–736, 1083
 - cells, dissemination of, 1063
 - cervical, 945
 - ovarian, 173
 - surgery, 1039
- Cannula, 435
 - for pediatric cases, 759
- Capnography, 33
- Carcinoembryonic antigen, 465
- Carcinoma, 56, 62, 632
 - adrenocortical, 187
 - gallbladder, 745
 - hepatocellular, 751
 - ovarian, 751
 - squamous cell, 750
- Carcinoma in situ (CIS), 573
- Carcinomatosis
 - peritoneal, 468
 - tumor, 468
- Cardiac dysrhythmias, 37
- Cardiac tamponade syndrome, 934
- Cardiopulmonary complications, 813
- Cardiopulmonary disorders, 977
- Cardiopulmonary morbidity, 980
- Cardiovascular monitoring, 979
- Cardiovascular and respiratory effects, 976
- Carotid body, 217
- Carter-Thomason® fascial closure
 - device (Inlet Medical, Minnesota), 12, 548, 885
 - needle, 300, 796
 - needle grasper, 72
 - port-closure device, 863
- Catheter
 - diameter of, 434
 - patency, 442
 - placing by Y-Tec procedure, 440
 - polyurethane, 434
 - Tenckhoff, 440
 - transurethral, 1068
 - ureteral, 532, 566
- Caudal aorta, dissection of, 607
- Cautery injury, in children, 761
- Cavotomy, 36
- CCD. *See* Charged coupled device
- Cecocolocystoplasty, 387–388
- Celioscopy, 5
- Celiotomy, 998
 - prostatic transitional carcinoma, 632–633
 - transitional, carcinoma, 166
- Cell-adhesion substrate, 1054
- Cell-mediated immune properties, 956
- Cell-seeded graft materials, 1056
- Cellular collagen matrix, electron microscopy of, 1056
- Cellulose
 - oxidized, 96, 97
 - spinal cord compression of, 97
 - swelling of, 97
- Center for Minimal Access Surgery (CMAS), 139, 1092
- Cerebral ischemia, 39
- Cerebral vascular engorgement, 39
- Cerebrovascular accident (CVA), 1133
- Cervical cancer, 945
- Charged coupled device (CCD) chip, 78
 - miniaturization of, 79
- Chemotherapy, primary, 611
 - adjuvant, 614
 - disadvantages of, 612, 613
- Chicken thoraco-abdominal cavity, 879
- Childhood hematologic cancer, 986
- Chimney effect, 468
- Cholecystectomy, 979
 - laparoscopic, 130, 745, 813, 979, 1061
 - robotic, 172
- Cholecystectomy, laparoscopic, 8, 818, 988–989, 1061
 - claims related to, 1028
 - risks prior to, 1027
 - for symptomatic cholelithiasis, 989
 - vascular injury in, 1028
 - video performance metrics on, 1123
- Chromophobe carcinomas, 519
- Chronic obstructive pulmonary disease (COPD), 976, 1133
- Chronic renal failure (CRF), 431
- Chronic renal insufficiency (CRI), 1133
- Chylomicrons, layer of, 449
- Chylothorax, 935
- Chyluria
 - classification, 448
 - clinical presentation and evaluation, 449
 - clots of, 449
 - conditions mimicking, 448
 - etiopathogenesis, 447–449
 - treatment of, algorithm, 449
- Cirrhosis, 746
- Cleveland technique, trocar positioning in, 690
- Clips, titanium, 70
- CloseSure™ system (Inlet Medical, Minnesota), 300
- Clotting factors, synthesis of, 985
- Clutton's urethral dilator, 286
- CO₂ insufflation
 - immunological effects of, 958
 - physiological effects of, 958
- CO₂ pneumoperitoneum for, 987
- Coagulation, 985
 - argon beam, 69, 331
 - disorders, 972
 - necrosis, 916
- Coagulative necrosis, 1081
- Codman surgical strip (Codman and Shurtleff, Inc., Massachusetts), 724
- Cold saline infusion, endoscopic retrograde, 837–838
- Colectomy laparoscopic, steps for, 644
- Collagen
 - implantation, 1054
 - microfibrillar, 96
 - protein component of skin, 96
- Collagen-rich matrices, 1054
- Collins knife, 780
- Collision detection algorithms, 1107
- Collision polygons, 1110
- Cancer colon, 1039
- Colonic injury, 913, 914
- Colposuspensions
 - Burch, 393
 - laparoscopic, 1–2, 393, 394–396
- Computed tomography, 260, 935, 1005
 - and creatinine level, 48
 - developments in, 48
 - helical, 48
 - parenchymal phase, 48
 - protocol for laparoscopic surgical planning, 48
 - spatial resolution, 48
 - spiral, 48
- Computer-aided surgical systems, 1091
- Computer-assisted robotic
 - Heller myotomy, 172
- Computer-based simulators, 1116
- Concomitant adrenalectomy, 526
- Congestive heart failure (CHF), 1133
- Conn's syndrome
 - clinical manifestations of, 225
 - symptoms of, 225
- Continuous ambulatory peritoneal dialysis (CAPD) catheter, 432
 - in abdominal wall, 432

- Continuous ambulatory peritoneal dialysis (CAPD) catheter, (*continued*)
- alignment of, 439
 - cross section of, 438
 - cuff of, 434
 - designs of, 434
 - insertion into pelvis, 438
 - laparoscopic-assisted implantation of, 439
 - advantages, 438
 - Hasson cut-down technique for, 438
 - instrumentation used for, 438
 - patients preparation for placement of, 438
 - technique for, 438
 - videolaparoscopy-assisted implementation of, 439
 - insertion of, 439
 - technique for, 439
- Contralateral metachronous tumors
- formation, risk of, 209
- Cooling sheath, laparoscopic, 839–840
- Cooper's ligament, 22, 396, 458
- Coronary artery disease (CAD), 1133
- CoSeal™ (Baxter Healthcare Corp., California, U.S.A.), 101, 333
- Costasis (Angiotech Pharmaceuticals, Inc., Canada), 93
 - advantage of, 95
 - fibrin-sealant variant, 95
 - in orthopedic surgical field, 95
 - plasma collecting system for, 95
- Cough stress test (CST), 394
- Cranial pedicles
- dissection, 688
 - and seminal vesicle dissection, 684
- Creteil technique, trocar positioning in, 689
- Crohn's disease, 965
- Crosseal (American Red Cross, Washington, D.C.), 93
- Cryolesion monitoring, 549, 550
- Cryomachine (Accuprobe®), (Ethicon, New Jersey), 548
- Cryopobes, 6–7
- Cryotherapy, 524
- Cryptorchidism, 767
 - laparoscopic management of, 9
- Culdoscopy, 7
- Cushing's adenoma, 209
 - biochemical diagnosis of, 210
 - treatment of, 825
- Cushing's syndrome, 186
 - cause of, 209
 - clinical features, 225
 - etiology, 225
 - symptoms, 225
- Cyanoacrylate sealants, 101
- Cyst manipulation, laparoscopic, 534
- Cystectomy, 803
 - laparoscopic, 166
 - radical, 651–652, 893
- Cystic fluid, 504
- Cystic kidney diseases, 431
- Cystic lesions, 534
- Cystic renal lesions, 521
- Cystogram, 725
- Cystography, 1073
- Cystoplasty, augmentation, 388
- Cystoprostatectomy, 166
 - laparoscopy-assisted, 894
 - robot-assisted radical, 894
- Cystoprostatectomy laparoscopic radical, 651
- Cystorrhaphy, laparoscopic sutured, 163
- Cystoscope, 4, 396, 403, 1073
- Cystourethrogram, 920
- Cytokines, 954
- Cytoreductive surgery, 497
- Cytotoxic agents, shock waves on, 1080
- Cytotoxicity
 - Kupffer cell-mediated, 957
 - monocyte-mediated, 957
- da Vinci® Surgical System (Intuitive Surgical, Inc.), 10, 304, 306, 717, 719, 1010
- Decker, albert, 7
- Defense Advanced Research Projects Agency (DARPA), 1100
- Delayed graft function (DGF),
 - etiology, 354
- Delayed-type hypersensitivity (DTH), 954
 - effect on, 958–959
- Dendrimers, polypropylenimine, 1142
- Denonvilliers' fascia (DF), 24, 708, 920
 - anterior layer of, 683
 - incision of, 687
- Dermabond® (Ethicon, Inc., New Jersey), 101
- Desormeaux antonin, 4
- Desflurane™, 626
- Dexon™, 140
- Diabetes mellitus (DM), 1133
- Diabetic nephropathy, 431
- Dialysis, indication for, 433
- Diaphragmatic-adrenal-renal channel, 200
- Diastolic blood pressure, 928
- Diathermy, 193, 238
- Dietl's crisis, 253
 - symptoms, 254
- Digital camera technology, development in, 79
- Digital dissection, 286
- Digital fusion technologies, 1041
- Digital monitors, high-resolution, 78
- Digital rectal examination (DRE) simulator,
 - for prostate cancer, 1116
- Digital still cameras, in image documentation and editing, 80
- Digital still images, quality of, 80
- Digital video (DV) camera, 78
- Digital videocystoscopy (Olympus America, New York), 79
- Diphtheria, 1142
- Distal gastrectomy, gasless laparoscopic surgery for, hand-assisted, 813
- Distal obliterate ureteral stricture, treatment of, 372
- Distal ureter, 287
 - dissection, open, 576
 - laparoscopic stapling of, 576
 - management of, 565
 - tumors, 580
- Distal ureterectomy, 575, 852
 - contraindications of, 576
 - indications of, 576
- Distal uterosacral ligaments, 946
- Diuresis, copious, 839
- Diverticular cavity, obliteration of, 8–9
- DNA transfection efficiency, 1142
- Donor kidney transplantation, 337
 - Donor nephrectomy, 978
 - laparoscopic, 893
 - robotic, indications and operative techniques for, 893
 - Doppler probe laparoscopic, 426
 - Doppler ultrasound, 1002–1003
 - intraoperative, laparoscopic color, 211
 - Dorsal lithotomy, 412, 893
 - Dorsal vascular complex, 738
 - Dorsal-vein complex (DVC), 698
 - coagulation of, 682
 - transection of, 682
 - Dorsolumbar fascia (DLF), 450
 - Douglas, aponeurosis of, 23
 - Douglas, pouch of, 20
 - Drug(s)
 - antituberculosis, 243
 - delivery systems, 1141
 - design, rational, 1149
 - Dubois francois, 8
 - Duncan knot, 140
 - Duploject® Preparation and Application System (Baxter Healthcare Corporation, Illinois), 94
 - Duration of hospital stay (DOS)
 - determination of, 1133
 - predication model, 1134
 - and preoperative patient parameters, 1132, 1138
 - Dye materials, for laparoscopy suturing, 150
 - Dysrhythmias, cardiac, 37
- Ectoderm, 944
- Ectopic kidneys, 5
- Ectopic testes, abdominal medial, 775
 - effects of, 31
 - efficacy of, 613
- Electrical prostate morcellator (VersaCut® Lumenis, California), 590
- Electrical tissue morcellation, 588
- Electro-mechanical Steiner morcellator, 587
- Electrocautery injury, 1033–1035
 - insulation failure injuries with, 1034
 - microprocessor-controlled, 1034
- Electrocautery, 7
 - meticulous hemostasis with, 488
 - risks of, 1033
 - shears, 792
- Electrocautery injury laparoscopic methods of, 1034
- Electrocoagulation, 1093
- Electrolytes, in serum, 928
- Electrosurgery injury, 1045
- Electrosurgery laparoscopic, potential complications of, 915
- Electrothermal injury, 915, 1034
- Emphysema, subcutaneous, 37, 250
- Endo-Avitene™ (MedChem Products, Massachusetts), 96, 1036
- Endocatch bag (U.S. Surgical, Connecticut), 126, 220, 305, 421, 514
- Endocatch device, 123
- Endocatch Gold (U.S. Surgical, Connecticut), 588
 - advantages of, 588
 - deployment suture on, 589
 - integrity of, 590

- Endo-GIA staplers (U.S. Surgical, Connecticut), 196, 488, 640, 829, 830
 applications of, 656
 Endo-GIA universal device (U.S. Surgical, Connecticut), 1010
 Endo Retractor (U.S. Surgical, Connecticut), 837
 EndoClip II, U.S. Surgical, 132
 EndoClose™ (U.S. Surgical, Connecticut), 140
 Endodissector, retraction of, 682
 EndoEye™ technology, 79
 Endometriosis, 164, 945–946
 laparoscopic visualization of, 946
 medical therapy of, 946
 treatment for, 946
 Endopath bladeless trocar, 719
 Endopath® Pneumoneedle (Ethicon Endo-Surgery Inc., Ohio), 719
 Endopath Optiview (Ethicon Endo-Surgery, Ohio), 425
 Endopelvic fascia, 22, 720
 incision of, 682
 Endophotography, 7
 Endophytic tumors, 558
 Endopouch® Retriever (Ethicon Endo-Surgery, Inc., Ohio), 722
 Endopyelotomy, 313, 314
 retrograde, 318
 Endoscopic camera systems, 78
 Endoscopic carts, 86
 Endoscopic linear stapling device, 791
 Endoscopic loop ligature, 140
 Endoscopic retrograde cold saline infusion, 837–838
 Endoscopic spoon biopsy forceps, 618
 Endoscopic stapling device, 70, 793
 malfunctioning of, 904
 Endoscopic suturing technique, 682
 Endoshears laparoscopic, 307
 Endostitch® (U.S. Surgical, Connecticut), 71, 221, 372, 877, 1056
 Endothelial cell damage, 92
 Endotracheal tube anesthesia, 247
 Endovascular stapler device, applications of, 237
 EndoWrist® robotic instruments, 171, 719
 End-stage renal disease (ESRD), 431
 causes of, 431
 population, 432
 treatment, 432
 in United States, 431
 Enterocystoplasty, 628
 laparoscopic procedures, 382
 bowel segment in, 383–384
 intraoperative complication, 387
 port placement in, 382–383
 postoperative management of, 386
 open, 382
 bladder and bowel function of, 388
 operative time for, 388
 preoperative preparation for, 382
 Epidermal growth factor (EGF), 1068
 Epigastric artery, 907–908, 1036
 Epithelial tumors, 519
Escherichia coli, 243
 Esophagectomy, 827
 Ethicon needle driver, 71
 Exit™ (Advanced Surgical, New Jersey), 140
 Extracorporeal high energy tissue tripsy, 1081
 Extracorporeal knotting, 71, 164
 Extracorporeal shock wave lithotripsy (ESWL), 279, 960
 Extraperitoneal approach, patient position in, 605
 Extraperitoneal ascending technique
 See-Heilbronn technique
 Extraperitoneal space preparation, 606
 trocar placement in, 607
 Extravesical reimplantations laparoscopic, 780
 Fascia gerota, 451
 Fasciectomy, 451
 Femoral neuropathy, 930–931
 Fenger plasty, 3
 pyeloplasty, 299, 890
 Fiber optic network, terrestrial, 1093
 Fibrin
 clot, 92
 monomers, 93
 preparations of, 94
 sealant
 adhesive properties of, 91
 applications of, 91, 528
 as bioadhesive, 91
 components of, 94
 purification and fractionation for, 91
 quality of, 91
 tensile strength of, 91
 Fibrinogen
 clinical use of, 91
 soluble blood component, 93
 substrates, clinical use of, 91
 Fibrinotherm heating and stirring device, 94
 Fibroids, 940
 Fibroinflammatory pseudomembrane, 538
 Fibromuscular dysplasia, mild, 339
 Fibrosis, retroperitoneal, 163
 Fibularis muscles, 925
 Fistula, 946
 development, arteriovenous, 132
 Floating kidneys, 162, 253
 FloSeal® Matrix (Bartex Healthcare Corporation, California), 94, 331, 724, 918
 Focalseal-L (Focal, Inc., Massachusetts), 101
 Foley Y-V plasty, 299
 Fowler—Stephens orchidopexy
 single-stage, 773
 two stage, 773–776
 French pigtail catheter (Cook Urological, Indiana), 838
 French red rubber catheter tubing, 549
 French Society of Gynecological Endoscopy, vascular injury in, 902
 Fresh frozen plasma (FFP), 975–977
 Furosemide therapy chronic, 52
 Gall bladder carcinoma, 745
 Gall stone pancreatitis, risk of, 989
 Gas collections, extraperitoneal, 37
 Gas insufflation tubing, 439
 Gasless laparoscopic surgery, 813, 987
 Burch bladder neck suspension, 814
 cardiopulmonary dysfunction, 818
 clinical study of, 818
 live donor nephrectomy, 814
 pelvic lymph node dissection, 814
 renal biopsy, 814
 respiratory function, 818
 techniques of, 815
 varicocelectomy, 814
 Gasless laparoscopy-assisted radical nephrectomy, concept of, 814
 Gasless retroperitoneoscopic live donor nephrectomy, disadvantages of, 815
 Gastric decompression, 419
 Gastric/duodenal injuries, 917
 Gastro-esophageal reflux disease (GERD), 1133
 Gastrointestinal anastomosis (GIA) stapler, 235, 384. *See also* Endo-GIA.
 Gastrophrenic ligament, 200
 Gastroscope, fiber optic, 7
 Gelatin granules, 528
 Gelatin matrix, 95
 Gelfoam® (Pfizer, New York), 94, 98
 GelPort® (Applied Medical Resources, California), 494, 788, 1010
 Gene therapy, delivery systems for, 1142
 Genital tumors, 758
 Genitourinary system, 1053
 Gerota's fascia, 121, 200, 343
 dissection of, 16
 layer of, anterior, 235
 Gleason score, 682, 734
 Glioma tumors, 1082
 Glomerular filtration rate (GFR), 431, 530
 Glomerulonephritis, 431
 Glomus jugular tumors, 217
 Glove-like input devices, 170
 Glycoproteins, adhesive, 92
 Gold nanoparticles, 1142, 1143
 Gonadoblastoma, 758
 Grasper, laparoscopic, 772
 Gynecologic procedures, 814
 disorders, 939
 evaluation, preoperative, 939–940
 laparoscopic procedures, 991–992
 lower urinary tract (LUT) injury in, 403
 pathology, 130
 procedures, 373, 946–947
 surgery
 ureteral and bladder injuries in, 941–942
 Halstedian method, for surgical training, 1148
 Hand-assisted dissection, benefits of, 800
 Hand-assisted laparoscopic (HAL) versus open donor nephrectomy, 788, 794
 Hand-assisted laparoscopic nephrectomy (HALN), 785
 complications, 795
 contraindications, 786
 dissection technique for, 790
 equipment used, 787–788
 for functional renal masses, 786
 hand incision configurations in, 788
 indications for, 786
 in obese patients, 786
 for renal procedures, 785
 reoperative preparation in, 786

- Hand-assisted laparoscopy (HAL), 295, 746, 918
 advantage of, 804, 806
 complications of, 803–804
 donor nephrectomy series, 802
 nephroureterectomy, 807
 partial nephrectomy, 806–807
 radical nephrectomy, 805–806
 selection of patients for, 808
 Haptica ProMis® trainer, 1123
 Haptics, 1103–1104
 Harmonic® scalpel (Ethicon Endosurgery Inc., Ohio), 74, 219, 340, 771
 Hassan technique, 266
 Hasson cannula, 425, 603, 760
 Hasson technique, 235, 306, 682, 907
 Hautmann ileal neobladder, 655
 Head-mounted displays (HMDs), 1111
 Heilbronn laparoscopic radical
 port positions in, 682
 prostatectomy, 691
 technique, 679
 trocar positioning in, 690
 training program, 698
 Heimlich valve tube, 796
 Heineke-Mickulicz repair, 299, 847
 Helium insufflation, 34
 Helix Hydro-jet® (ERBE, Tübingen, Germany), 537, 1062
 Heller myotomy, computer-assisted
 robotic, 172
 Hem-O-Lok® clips (Week Closure Systems, North Carolina), 627, 684, 722, 1010
 Hemaseel (Haemacure Corp., Canada), 93
 Hematuria, 247, 250–251
 Hemicolectomy, 718
 Heminephrectomy, 847–848
 for nonfunctioning kidney, 847
 for renal cell carcinoma, 847
 for renal mass, 847
 Hemithorax, ipsilateral, 828
 Hemodialysis (HD), 431, 530
 Hemodialysis patients chronic, 502
 Hemolytic uremic syndrome, 977
 Hemorrhage
 complications, 39, 526
 delayed, 806
 Hemostasis, 123, 283, 527–528, 804
 chemical augmentation of, 1036
 coagulation cascade for, 92
 parenchymal, 527
 platelets for, 92
 tissue factors of, 92
 Hemostatic agents, 71
 biologic and synthetic, 101
 laparoscopic armamentarium of, 95
 Hemostatic clamps, 971
 Hemostatic clips, 8, 538
 Hemostatic energy source, 98
 Hemostatic fibrin-sealant powder
 (HFSP), 94
 Hemostatic modalities, 771
 Hemostatic plug, 92
 Hemothorax, acute, 935
 Heminephrectomy, in horseshoe
 kidneys, 847
 Hepatobiliary, splenic/pancreatic injury,
 917–918
 Hepatocellular carcinoma, 751
 Hereditary pheochromocytoma syndromes,
 217
 Hernia
 extraction site, 357
 formation, 997
 prevention of, 652
 postoperative, risk of, 1038
 repair, 459, 460
 surgery, postoperative care for, 458
 symptoms of, 1038
 Hernia repair, laparoscopic, 455–456
 Herniorrhaphy, laparoscopic, 455, 1038
 Herniorrhaphy, laparoscopic surgery for, 813
 High intensity focused ultrasound (HIFU),
 1082, 1085, 1147
 for benign prostatic enlargement, 1083
 extracorporeal, 1082
 indications, 1082–1083
 High-definition television (HDTV), 78, 82
 High-definition video systems, 82, 83
 High-energy shock wave (HESW) tissue
 tripsy, 1081
 clinical application of, 1082
 effects of, 1081
 High-speed electrical laparoscopic (HSEL)
 morcellator, 590
 Hilar clamping time, 531, 533
 Hilar dissection, 123
 Hilar tumor, 534–535
 Hilar vessels, stripping of, 451
 Holmium laser, 860
 Hopkins® II (Karl Storz, California), 884
 Horseshoe kidney
 extirpative surgery on, 847
 laparoscopic pyeloplasty in, 845
 extraperitoneal, 846
 hand-assisted, 846
 retroperitoneal approach for, 846
 transperitoneal approach for, 846
 Hulka tenaculum device, 948
 Human immunodeficiency virus (HIV), 975
 Human leucocyte antigen (HLA) locus, 954
 Human papilloma virus, 945
 Hydro-Jet® (Erbe), 1062, 1065
 dissection, 1061, 1063
 technology, 1064
 clinical application of, 537–538
 for nerve-sparing approach, 1065
 retroperitoneal dissection in, principle of,
 1063
 in surgical field, 1061
 in urologic surgery, 1062
 Hydrodissection
 for gynecologic pelvic procedures, 1061
 indication for, 1062
 principle of, 1062
 Hydrogels, 101
 Hydronephrotic collecting system, 848
 Hydronephrotic kidney, 232
 Hydronephrotic pelvis, 14
 Hydronephrotic renal moiety, 847
 Hydrosalpinx, 943
 Hyperaldosteronism, 208, 225
 Hypercapnia, 31, 36
 Hypercortisolism, non-adrenal causes of, 225
 Hypertension (HTN), 18, 40, 1133
 Hypocholeic fluid filled cavities, 419
 Hypogastric plexus, 22, 25
 Hypotension, 928
 Hypothermia, 40–41, 835
 effects, 974
 negative effect of, 836
 renal. *See* Renal hypothermia
 temperature, optimal, 531
 Hypothermia, renal, 842
 Hypoxemia, 40
 Hysterectomy, 940–941
 Hysterectomy laparoscopic, 412, 588
 Iatrogenic T3–4 disease, 580
 Ice slush renal hypothermia, 836–837
 Idiopathic retroperitoneal fibrosis (IRPF),
 370–371
 causes, 370
 laparoscopic approach, 371
 ureterolysis for, 370
 Idiopathic thrombocytopenia purpura, 172
 Ileal anastomoses, 854
 Ileal conduit, 650–651
 open-assisted techniques for, 663
 Ileal conduit laparoscopic without
 cystectomy, 650
 Ileal peristalsis, 852
 Ileal stoma, creation of, 652
 Ileal surgery, bowel preparation for, 853
 Ileal ureter replacement, laparoscopic, 852
 Ileocolic anastomosis, 644
 Ileocystoplasty, 381
 Ileovesical anastomosis, 654
 free hand suturing of, 390
 single-layer, 390
 Ileovesicostomy, 389
 laparoscopic, 389–390, 654
 surgical components of, 389
 Ileal ureter replacement
 laparoscopic, 852–853
 Ileovesicostomy formation, laparoscopic
 Ileovesicostomy, laparoscopic, 654
 transperitoneal, 389
 Iliac vessels, 21
 Immune responses, peritoneal, 750
 Immunoglobulin therapy, 990
 Immunosuppression, 1057
 Implanter Tool™, 435
 Infection chronic, renal units with, 242–243
 In vitro fertilization (IVF), 424, 943
 Inlet® Closure Device (Inlet Medical, Inc.,
 Minnesota), 395
 InnerDyne® Radial Dilating Step introducer
 system, 769
 Instant Response™ (Valley Lab, Colorado),
 1034
 Instrument injuries, 1032
 Insufflators, accessory devices for, 72
 Interfascial dissection, laparoscopic, 25
 Interfascial neurovascular dissection, 25
 International Federation of Gynecology
 and Obstetrics (FIGO) staging
 system, 945
 Intestinal injuries, 1037
 Intracellular antigens, 954
 Intracellular Kupffer cell signaling, 957
 Intracellular pathogens, 954
 Intracorporeal knotting technique, 164, 684
 Intracorporeal suturing, laparoscopic, 177, 511
 Intracranial pressure, 39
 Intracytoplasmic sperm injection (ICSI), 424

- Intraoperative conversion, indications for, 197
 Intraperitoneal drainage, 413
 Intraperitoneal onlay mesh (IPOM), 455
 Intraperitoneal surgery laparoscopic, in children, 761
 Intrathoracic pressure, 31
 Intravenous contrast volume, 52
 Intravenous pyelogram (IVP), 370
 Intravenous urogram (IVU), 253, 419, 1074
 Intravesical laparoscopic method, 567
 Intuitive Surgical® (Sunnyvale, California), 107
 Ipsilateral adrenal fossa, 521
 Ipsilateral colon, 267, 283, 853
 Ipsilateral hemiscrotum, 772
 Ipsilateral lung, 828
 Ipsilateral renal calculi, 314, 1069
 Ipsilateral seminal vesicle, 686, 721
 Ischemia, 802, 842
 Ischemia, chronic and adhesion formation, 971
 Ischioprostatic ligaments, 23
 Isthmectomy, 846
 Ivanssevich, inguinal approach, 425
- Jacobaeus Hans Christian, 6
 J-hook electrocautery, 620
 J-hook laparoscopic electrosurgical, 654
 J-stenting, preoperative, 282
 Jackson-Pratt drain, 283, 299, 514, 654
 Jet propulsion laboratory's telerobotics program, 107
 Joule-Thompson principle, 548
- Kelly clamp, 856
 Ketorolac, intravenous, 256
 Kidney
 blunt dissection of, 488
 cancer, 521
 carbon dioxide pneumoperitoneum, 814
 cephalad displacement of, 255
 dissection, 10
 ectopic, 5
 horseshoe, 5, 845
 infectious conditions of, 242
 mobilization of, 490–491
 renal parenchyma of, 1085
 retraction of, 199
 therapeutic cloning, 1057
 transplantation, robotic-assisted, 162
 tumors, 1085
 Knotting, extracorporeal, 71, 131, 164
 Knotting, laparoscopic extracorporeal, 139–140
 Kocher's clamps, 72
 Kupffer cell signaling, intracellular, 957
- Lap Sac® (Cook Surgical, Indiana), 237, 488, 656
 Laparofan, 816
 Laparolift™ (Tyco-Origin Medsystems Inc.), 813, 816
 Laparoscopy diagnostic, 768
 Laparoscopic equipment, 1021
 cost of, 1010
 standards of, 193
- Laparoscopic extra-adrenal literature, review of, 220
 Laparoscopic force feedback device, 1105
 Laparoscopic forceps, 487
 Laparoscopic injuries, 99, 1028
 foreign body retention, risk for, 1040
 Laparoscopic instruments, 1123
 Laparoscopic intestinal surgery, component of, 390
 Laparoscopic live donor nephrectomies (LLDN), 337
 equipment for, 345
 hand-assisted, 13, 14
 instrumentation for, 341
 operating-room configuration for, 341
 retroperitoneoscopic, 14, 15
 right-sided, 348–349
 trocar placement for, 13
 Laparoscopic lymphocele drainage, 886
 Laparoscopic lymphocele fenestration, complication of, 378
 Laparoscopic manipulation, in children, 760–761
 pros and cons of, 793
 Laparoscopic models, gasless, 749
 Laparoscopic nerve- and seminal-sparing cystectomy, 674
 Laparoscopic operating room systems, modern, 74
 Laparoscopic orthotopic neobladder
 Laparoscopic paravaginal repair, 398
 Laparoscopic partial adrenalectomy (LPA), 207, 1002
 contraindications of, 208
 feasibility of, 213
 operative time for, 213
 preoperative investigations of, 210
 for recurrent pheochromocytomas, 214
 retroperitoneal approach for, 212
 safety and efficacy of, 213
 surgical techniques of, 211–213
 therapeutic concepts of, 208
 transperitoneal approach for, 211–213
 Laparoscopic pelvic procedures, 394
 Laparoscopic pluck technique, 567
 Laparoscopic port site risk, 1039
 Laparoscopic procedures
 adhesion formation in, 1040
 children to
 anesthetic response of, 762
 complications in, 1018, 1019
 cost-effectiveness of, 1010–1014
 nongynecologic, 988
 operative time for, 1018
 trocar injury in, 1028
 vascular injury in, 1028
 Laparoscopic skills, inanimate models for, 1120
 Laparoscopic surgical workstation, 1105
 Laparoscopic suturing techniques, 869
 Laparoscopic suturing, free hand, 386
 Laparoscopic testicular denervation, 7
 Laparoscopic tissue dissection, 211
 Laparoscopic trocar sites, abdominal wall, 395
 Laparoscopic trocars, types of, 69
 Laparoscopic tubal disruption, 8
 Laparoscopic tubal sterilization, 7
 Laparoscopic ultrasound probe, 15, 198
- Laparoscopic ultrasound,
 intraoperative, 249
 Laparoscopic vascular instruments, 511
 Laparoscopic vascular suturing, 841
 Laparoscopy versus open
 Burch colposuspension, 403
 open pelvic lymph node dissection (PLND), 619
 open procedures, operative time for, 1018
 open radical prostatectomy, 696
 Laparoscopic visualization, 126
 Laparoscopic VVF repair, 414
 Laparoscopic wound infections, 1039
 Laparoscopy
 access injuries, 905
 advantages, 381, 453
 autostaplers, 132
 bilateral varix ligation, 960
 bladder cuff, 166
 bladder injury and, 947
 bladder reconstruction, 164
 bowel injuries, 959
 color Doppler ultrasound, 211
 for colorectal cancer, 953
 conventional instruments, 719
 cryoablation, 544
 cryosurgery, 1004
 cyst-aspiration needle, 330
 cyst decortication, 243
 cyst manipulation, 534
 decortication, 1005
 diagnostic, 773
 dismembered pyeloplasty, 321
 donor grafts, 361
 donor nephrectomy, 9, 15, 893, 901
 gasless, 34–35, 823
 hand-assisted, 295
 Hasson technique, 68
 heminephrectomy, 532
 hemodynamic response to, 32
 and hemostasis, 132–133
 human, 6
 ileal ureter, 526
 ileal vaginal reconstruction, 159
 instruments for, 67
 intracorporeal needles, for, 150
 intracorporeal suturing fluid, 143–144
 knot tying, 129, 147, 1070
 mathematical modeling in, 1130
 mesh fixations, 166
 operating room systems, 74
 orchidopexy, 767
 parenchymal suturing, 526
 physiologic complications of, 39
 principles, 724
 psychomotor skills, 134, 136
 radiofrequency ablation (RFA), 554
 renal hypothermia, 531
 renal vascular surgery, 161, 531
 role in malignancy, 467–468
 sacrocolpopexy, 894
 skill development and assessment, 133
 surgical skill, 129, 134
 surgical technique of, 120
 suturing
 dye materials for, 150
 ergonomics of, 145
 essentials of, 132–133
 instruments, 129

- Laparoscopy (*continued*)
 intracorporeal, 130, 1070
 microsurgical, 146
 time line, 130
 task goals in, 698
 telementoring, 173
 therapeutic, 731–753
 tissue reapproximation and healing, 133
 training, 129, 135–139, 698
 transperitoneal, 933
 urologic reconstructive techniques, 129–130
 Veress needle, 67
 visualization, 69
 VR models for, 1122
- Lapdisc® (Ethicon Endosurgical, Ohio), 494, 788
- LapMentor® simulator, 1111, 1123
- Lapra-Ty® suture clips (Ethicon Endosurgery, Ohio), 167
- LapSac® (Cook Urological Inc., Indiana), 494, 589
- Laser tissue welding, 517
- Laser
 partial nephrectomy, 538
 soldering, 538
 technology, 538
- Lateral umbilical ligament (LUL), 19, 20
- Left para-aortic dissection, 607
- Leinodiaphragmatic ligament, 200
- Leiomyomata, 940
- Leukocytosis, 986
- Lichtleiter of Bozzini, 4
- Ligasure™ (Valleylab, Tyco Healthcare, Connecticut), 69, 771
- Lithotripsy, shock wave, 1080
- Live donor nephrectomy, 813–814
 gasless retroperitoneoscopy-assisted, 815
 hand assisted, 816
 retroperitoneal laparoscopy-assisted, 815
 video-assisted minilaparotomy, 816
- Liver, intraoperative ultrasound of, 212
- Lucent cannulas, 772
- LULs. *See* Lateral umbilical ligament
- Lumbar vein, 14, 791
- Lumbodorsal fascia, 330
- Lung cancer metastasis, 466
- Lung, ipsilateral, 828
- Lymph node dissection, bilateral, 893
- Lymph node metastases, 578, 618
- Lymph node removal, endoscopic
 bag for, 606
- Lymphadenectomy
 bilateral pelvic, 627
 laparoscopic pelvic, 9
 ureterolysis and, 1005
- Lymphadenectomy Laparoscopic, for bladder cancer, 671
- Lymphatic disconnection Laparoscopic, 450–451
 patient selection for, 450
- Lymphatic metastatic spread, with testicular cancer, 602
- Lymphocele drainage, Laparoscopic, 886
- Lymphocele fenestration Laparoscopic, complication of, 288
- Lymphocele
 cavity, 377–378
 complications in, 378
 etiologic factors of, 375
 laparoscopic, 2–4
 marsupialization of, 376–377
 pathologic analysis of, 377
 surgery, 1005
 symptomatic, 376, 1005
 treatment, 376
 visualization of, 378
- Lymphocelelectomy
 indications for, 375–376
 pelvic, 376
- Lymphocelelectomy, laparoscopic, 1004
- Lymphadenectomy, laparoscopic
 retroperitoneal, dissection time of, 1065
- Lymphocytic stimulation index, 961
- Lympholysis, retroperitoneal vs. transperitoneal, 454
- Lysis laparoscopic of adhesions, 941
- Magnetic resonance imaging
 advantages of, 50
 imaging quality in, 50
 intravenous contrast volume, 52
 motion-free, 51
 for renal cysts, 261–262
 software design, 47
- Mainz II pouch, laparoscopic
 closure and drains in, 662
 patient preparation in, 660
 postoperative period of, 662
 radical cystectomy in, 661
 sigmoid pouch creation, 660
 ureteral reimplantation in, 661–662
- Major histocompatibility complex (MHC), class I molecules, 954
- Malignancy
 adrenal, 465, 467
 adrenalectomy for solitary, 465–466
 laparoscopic excision of, 469
 role of laparoscopy for, 467–468
- Malignant ascitic fluid, characteristics of, 977
- Mammalian cell types, 1054
- Maniceps®, 877
- Manitol, 339
 intravenous administration of, 513
- Mantis® (Mimic Technologies, Seattle, Washington), 1109
- Master-slave robotic devices, 730
- Maternal and fetal monitoring, 988
- Maya® (Alias Systems Corp, Canada), 1106
- Mayer-Rokitansky-Kuster syndrome, 159
- McBurney's incision, 688
- Mechanical tissue tripsy, 1079–1082
- Medial umbilical ligament (MULs), 20, 1070
- Medicolegal considerations, 1025, 1044–1045
- Membrane, peritoneal, 433
- Memorial Sloan-Kettering Cancer Center (MSKCC), 731
- Mental imagery techniques, 1098
- Metabolic acidosis, 33
- Metabolic activities, renal, 835
- Metastases, visceral organ, 60
- Metastasis
 lung cancer, 466
 patients with, 466
 port-site, 467
 renal cell carcinoma (RCC), 465
 Metastatic disease, biologic behavior of, 746
- Metzenbaum scissors, 577
- Miami Pouch, laparoscopic
 hand-assisted, 663
- Micro-electro-mechanical systems (MEMS), 1147
- MicroDexterity systems, 107
- Microprocessor-controlled electrocautery units, 1034
- Microvascular bleeding, 974
- Microvascular techniques, 10
- Micturitional headaches, 217
- Mignon lamp, 4
- Millin's adenomectomy, 871
- Millin's prostatectomy, laparoscopic
 extraperitoneal, 866
- Minilaparoscopy
 benefits and limitations of, 887
 cosmetic advantage of, 887
 image resolution with, 887
 instruments, 883
 pyeloplasty, 887
 urologic procedures, 884
- Minilaparotomy live donor nephrectomy, video-assisted, 816
- Minilaparotomy, 816
- Minisite® (U.S. Surgical Corp., Connecticut), 67, 884
- Mitrofanoff principle, bladder reconstruction, 165
- Monocryl™ (poliglecaprone 25) sutures, 724
- Monocyte-macrophage function, 957
- Monofilament polydioxanone, 176
- Montsouris technique, 678, 686
 bladder dissection, 687
 prostate dissection, 686, 688
 retzius space in, development of, 687
 trocar positioning, 687–688
 urethrovessical anastomosis, 688
- Montsouris technique, urethrovessical anastomosis in, 871–872
- MULs. *See* Medial umbilical ligament
- Multipolar resections, 49
- Muritz 996 Hydro-Jet® generator (Euromed Medizintechnik, Germany), 1064
- Myelolipomas, 187
- Myelomeningocele patients, 39
- Myoglobin, toxic effects of, 928
- Nanofiltration, 101
- Nanoparticle
 designs of, 1141
 formation, 1142
 gold, 1142, 1143
- Nanosensors, 1143
- Nanoshells, 1143
- Nanotechnology, 1143–1144
 limitations of, 1143
 in urology, potential applications of, 1141
- Nanotweezers, 1143
- National Aeronautics and Space Administration (NASA), 107
- National Association of Insurance Commissioners (NAIC) severity index score, 1041, 1045
- National Television Standards Committee (NTSC), 82

- Natural killer (NK) cells, 954
- Neck surgery, 814
- Neck-sparing technique, non-bladder, 684
- Necrosis, tubular, 842
- Needlescopic lymphocele drainage, 886
- Needlescopic dissection, 885
- instruments, 884
 - urologic procedures, 884–885
- Neoadjuvant chemotherapy, 580
- Neobladder, 1055
- anterior plate of, 657
 - in pelvis, 658
- Neobladder creation, 654, 657
- Neobladder stenosis, 630
- Neoplasm, solid, 260
- Nephrectomy, 1139
- bilateral, 800
 - complications, 527
 - donor, 802–803, 807
 - laparoscopic, 281, 287, 291
 - laparoscopic partial, 1132
 - laparoscopic radical, 483
 - laparoscopic radical/simple, 1132–1133
 - comparison of, 1134
 - partial, 543, 801
 - radical, 800
 - reconstruction, partial, 160
 - robotic, 892
 - simple, 800
 - surgical approach, 483
 - telerobotic laparoscopic, 892
 - thoracoscopic transdiaphragmatic, 826
 - transperitoneal laparoscopic, 807
 - types of, 1018
 - ureteral complications, 803
- Nephrectomy, laparoscopic, 9, 34, 97282, 474, 574, 1132
- anesthetic considerations for, 232
- Nephrectomy, laparoscopic retroperitoneal radical, 483
- complications of, 490
 - contraindication of, 484
 - equipments for, 484
 - hemostasis and closure in, 488–489
 - indications for, 484
 - patient positioning in, 484–485
 - port placement in, 486–487
 - preoperative preparation in, 484
 - in urologic armamentarium, 483
- Nephrectomy technique, laparoscopic, 1012
- for autosomal dominant polycystic kidney disease (ADPKD), 244
 - benefits, 241
 - for benign conditions, 241
 - complications, 237–238, 241
 - cost comparison of open and, 1012–1013
 - evaluation of, 1012
 - indications, 241
- Nephrolithotomy, 331
- laparoscopy anatomic, 161
 - percutaneous, 326
- Nephrolympholysis, 451
- Nephron-sparing surgery (NSS), 47, 503, 520, 553
- Nephropexy, 256–257, 452
- Nephropexy, laparoscopic
- patient preparation for, 254
 - patient selection of, 254
 - postoperative care, 256–257
 - retroperitoneal approach for
 - kidney fixation in, 256
 - patient positioning in, 255
 - port placement in, 256
- Nephrolithotomy, laparoscopic, 1006
- limitations of, 785
 - minilaparotomy-assisted, 814
 - nephroureterectomy, 587
 - transperitoneal, 592
 - and open simple nephrectomy, 241–242
 - operative techniques of, 588
 - patient selection, 223, 242–243
 - preoperative preparation, 231–232
 - technique, 233–236
 - insufflation and trocar placement, 232–233
 - mobilization of the upper pole, 235
 - modifications, 235–236
 - patient positioning, 232
 - pedicle control, 234–235
 - tips, 236–237
 - ureteric division, 235
 - transperitoneal approach for, 254, 255
 - for tuberculosis, of kidney, 243
 - for xanthogranulomatous pyelonephritis (XGP), 241, 243
- Nephrectomy, laparoscopic radical
- complications of, 496
 - diagnosis of, 592
 - hand-assisted, 494
 - open radical nephrectomy, 495
 - oncologic outcome of, 495–496, 794
 - for renal cell cancer, 495–496
 - retroperitoneal approach for, 494
 - transperitoneal, 493
- Nephroureterectomy, laparoscopic, 747, 748
- hand-assisted, 4–5
 - morbidity of, 565
- Nephroureterectomy, laparoscopic radical (LNUX), 573
- adjunctive procedures of, 578–579
 - advantages of, 565
 - complications of, 577
 - and distal ureter approach, 575
 - hand-assisted, 574
 - histopathologic results of, 578
 - morbidity of, 577–578
 - oncologic efficacy of, 578
 - with open bladder cuff resection, 578
 - and open radical nephroureterectomy, 578
 - and port site metastasis, 580
 - perioperative results of, 574
 - retroperitoneal approach, advantages of, 574
 - transperitoneal, 7
 - for upper tract urothelial carcinoma, 565
- Nephroptosis, 162
- diagnosis, 254
 - pathogenesis, 253
 - symptoms, 253–254
 - therapeutic options for, 251
- Nephrostomy drainage, proximal, 1069
- Nephrostomy tube, 991
- Nephrotoxic agents, adverse effects of, 40
- Nephrotoxicity, 48
- Nephroureterectomy, 758, 786
- Nerve injury, 459
- motor obturator, 1040
- Nerve-sparing dissection, 722
- Nerve-sparing retroperitoneal lymphadenectomy, 1064
- Nerve-sparing robot-assisted radical cystectomy, with urinary diversion, 669
- Nerves
- femoral, 924–925
 - median, 923–924
 - obturator, 925
 - peroneal, 925, 930
 - ulnar, 923–924
- Neisseria gonorrhea*, 941
- Neuroblastoma, 757, 758
- Neurogenic bladder dysfunction, 381–382, 851
- management of, 389
 - pediatric patients with, 662
 - treatment for, 650
- Neuromuscular bundles, preservation of, 1066
- Neuromuscular complications, 923
- risk factors for, 925
- Neuromuscular injuries, 923
- operative factors, 927
 - patient factors for, 925–926
 - risk factors for, 925–926
- Neuromuscular, complications of, 931
- Neuropathies, 395
- femoral, 930
 - median, 930
 - obturator, 930
 - peroneal, 930
 - ulnar, 930
- Neurosurgery, 1079
- Neurovascular bundle (NVBs), 682
- dissection, 721–722, 738
 - pedicle control of, 721–722
 - posterolateral, 725
 - preservation of, 709, 721–722
 - thermal damage to, 688
- Neurovascular dissection, interfascial, 25
- Neurovascular plexus, prostatic, 25
- Neurovascular structures, 721–722
- Neutrophils, chemotactic activity of, 965
- Newman, David, 4
- Nielsen's law, 1105
- Nitze-Leiter cystoscope, 4
- Nitze max, 4
- Non-bladder neck-sparing technique, 684
- Non-nerve-sparing technique, 682
- Non-nerve-sparing versus nerve-sparing procedures, 687
- Non-seminomatous germ cell tumors (NSGCT), clinical stage I and II, 599–601
- Nongynecologic laparoscopic procedures, 988
- Nonobstetrical abdominal surgery
- Nonrefluxing anastomoses, in animals, 852
- Nonrenal tissue, initial biopsy of, 250
- Nonseminomatous germ cell tumors (NSGCT), 611–612
- Obesity, 360, 475
- Omnipoint (Intermed, Nevada), 788
- Oncologic surgery, principles of, 738, 785
- Oophorectomy, complication of, 944
- Open and laparoscopic surgery, operative costs, 1010

- Open and laparoscopic-assisted radical cystectomy, comparison of, 674
- Open bladder technique, 577
- Open burch, de novo detrusor instability in, 403
- Open laparoscopic access, 1043
- Open pelvic lymph node dissection (OPLND), for prostate cancer, 375
- Open radical cystectomy (ORC), 953
with urinary diversion, 669
- Open retropubic radical prostatectomy, sutures at, 876
- Open surgical renal revascularization, 843
- Open suturing procedure, 877
- Operating room
for laparoscopic and endourology, 86
for robotics surgery, 86
- Optical catheters, 883
- Optical trocar, advantage of, 905
- Optimal hypothermia temperature, 531
- Optiview™ (Ethicon, New Jersey)
- Oral-gastric decompression tube, 386
- Orchalgia, 423
- Orchidopexy
considerations for, 768
laparoscopic, complications of, 773
pelvicoscopic, 767
single-stage Fowler—Stephens, 771
two stage Fowler—Stephens, 773–776
- Orchiopexy, 885
bilateral, 886
blood loss for, 886
operative time for, 886
- Organ bag via periumbilical incision, extraction of, 685
- Orthotopic ileal loop, laparoscopic, 670
- Orthotopic ileal neobladder, laparoscopic, 670
closure and drains, 658
harvesting small bowel, 657
neobladder creation, 654
postoperative management of, 658
restoring bowel continuity in, 657
ureteroneovesical anastomoses, 657
- Orthotopic neobladder
intracorporeal, 655
laparoscopic open-assisted, 655
operative time for, 655
- Orthotopic W-shaped neobladder
- Ovarian cancer, 173, 1039
epithelial, 945
- Ovarian carcinoma, 751
- Ovarian remnant syndrome, risk of, 944–945
- Ovarian tumor, 944
- Oxycel (Ethicon, Somerville, New Jersey), 97
- Partial cystectomy laparoscopic, 1056
- Prostate surgery laparoscopic, innovations in, 737
- Prostatectomy laparoscopic, 930, 1012
- Prostatic adenomectomy laparoscopic, extraperitoneal, 864
- Pyelolithotomy laparoscopic, 281
- Pyeloplasty laparoscopic, 304, 313
in children, 316
complexity of, 295
contraindications, 296
dissection in, 298
in horseshoe kidney, 845
- indications for, 296
intracorporeal suturing of, 297
patient positioning for, 296
postoperative complications of, 300
preoperative preparation in, 296
retroperitoneal approach for, 296
robot-assisted, 4, 890
for secondary ureteropelvic junction (UPJ), obstruction, 4
surgical technique for, 296–298
transperitoneal approach for, 296
- Partial nephrectomy, laparoscopic, 9, 97, 327, 328, 511, 503
cleveland clinic technique of, 512
dissection time for, 1064
and hemostasis, 517
indications and contraindications, 511
preoperative preparation, 328–329
retroperitoneal approach, 329
transperitoneal approach, 33
- Pelvic lymph node dissection, laparoscopic, 377, 747, 1120
- Pelvic lymphadenectomy, laparoscopic, 9, 618
- Palomo, retroperitoneal approach, 425
- Pancreatic surgery, robotic, 172
- Paraganglioma
clinical manifestations of, 217
extra-adrenal, classification of, 217
pathologic behaviors, 220
- Paravaginal herniation, 405
- Parenchyma, renal, 326
- Parenchymal bleeding, 331
- Parenchymal compression, 536
- Parenchymal hemostasis, 527
- Parenchymal hemostatic sutures, 513
- Parenchymal hydrodissection, 537
- Parenchymal suturing, laparoscopic, 526
- Parenchymal temperature, renal. *See* Renal parenchymal temperature
- Parenchymal thermal coagulation depth, 529
- Parenchymal tumor invasion, 532
- Parenchymatous tissue, 1079
- Parenteral nutrition, 914
- Parra's simple cystectomy, 663
- Partial nephrectomy, laparoscopic, 97
- Partial thromboplastin time (PTT)
- PDB balloon dilator (U.S. Surgical, Connecticut), 68
- PDSII™, 140
- Pediatric cardiorespiratory physiology, pneumoperitoneum on, 762
- Pediatric laparoscopic complications, 763
- Pediatric oncologic applications, 757
- Pediatric technique, 308
- Pediatric tumors, 757
- Pediatric urologic laparoscopy, 905
evolution of, 758
open access system in, 760
patient preparation in, 758
surgical complications of, 763
Veress access system in, 760
- Pelvic adhesions, 941
- Pelvic anatomy, 456–457
- Pelvic examination simulator, 1116
- Pelvic fascia, lateral, 683
- Pelvic fractures, 999
- Pelvic inflammatory disease (PID), 941–943
- Pelvic lymph adenectomy
bleeding, 682, 708, 1035
- Pelvic lymph node dissection, 376, 708, 722–723, 913
- Pelvic lymphoceles, 886
- Pelvic mass, clinical assessment of, 940
- Pelvic mesocolon, 21
- Pelvic pain chronic, 941
- Pelvic plexus, 22
- Pelvic procedures in child, 759
- Pelvic radiation therapy, 648
- Pelvic reconstructive surgery, 398
- Pelvic region, laparoscopic approach to, 679
- Pelvic ultrasound, 944
- Pelviculiceal suture repair, impact of, 532
- Pelvicoscopic orchidopexy, 767
- Perceptron learning rule, 1130
- PercMentor® (Simbionix), 1105
- Percutaneous access of kidney (PAKY), 108, 1109
- Percutaneous nephrolithotripsy (PCNL), 279
- Perineal prostatectomy, 420
- Perineal radical prostatectomy, 705
- Peripheral nerve injury, 925, 927
- Peripheral neuropathies, 929–931
- Periprosthetic fibrosis, 679
- Peritoneal catheters, 434
- Peritoneal dialysis (PD) catheter, 434, 441
- Peritoneal flap, 413
- Peritoneal immunity, importance of, 750
- Peritoneal insufflation, 979
- Peritoneal irritation, 976
- Peritoneal macrophages, 957
- Peritoneal planar lifting device, 816
- Peritoneal trauma, 750
- Peritoneoscopy, 6, 7, 435
- Peritoneotomy, inadvertent, 126
potential complications of, 737
prevention of, 490
- Peritoneum, 232, 386
- Peritonitis, 378
- Periureteral adhesions, 1072
- Periureteral tissue, 9, 284, 722
- Petit's inferior lumbar triangle, 485
- Pfannenstiel extraction incision, 342
- Pfannenstiel incision, 494
- Phagocytosis, 954
- Phase-alternation-by-line (PAL), 82
- Pheochromocytomas, 209
adrenalectomy for, 225–226
algorithm for, 219
biochemical assays testing for, 217
diagnosis of, 225, 990
imaging study for, 218
management of, 211, 214
metaiodobenzylguanidine (MIBG) imaging of, 218
surgical
risks of, 210
technique of, 218
treatment of, 225, 825, 990
extra-adrenal, 217
laparoscopic management of, 219, 220
laparoscopic partial cystectomy for, 221
- Pheochromocytoma extra-adrenal, 217
- Phillips Jordan M., 8
- Phrenic veins, 792

- Physician Insurers Association of America (PIAA) claims, in United States, 1028, 1045
- Phytohemagglutinin (PHAP), 960–961
- Piezoceramic elements, ultrasound shock waves from, 1080
- Pixie[®] microendoscope (Origin MedSystems, California), 884
- Platinum wire loop, 4
- Pleurocentesis, 935
- Pleurotomy, 934
- Plexus, inferior hypogastric, 22
- Pneumoinflation, blind Veress needle method for, 1043
- Pneumopericardium, mechanism of, 934
- Pneumoperitoneum, 339, 413, 554, 884
effects of, 468
gastrointestinal, 913
physiologic, 977
and gasless laparoscopic surgery, immune response of, 817
hydration of, aggressive, 354
properties of, antioxidant, 354
injury, complications of, 1035
needle, 439
supraumbilical incision of, 673
tamponade effect of, 729
- Pneumoretroperitoneum, 121, 126, 256
- Pneumosleeve, 799
- Pneumothorax, 524, 935, 998
- Polycarbonate membranes, collagen-coated cylindrical, 1057
- Polycystic kidney disease (PKD), 243, 800, 1133
- Polyethylene film (3M Health Care, Minnesota), 589
- Polyethylene glycol (PEG) polymers, 101
- Polyglactin suture, 12
- Polygon models, 1106, 1108
- Polymer, C32, 1142
- Polymerization, 94
- Polymorphonuclear leukocytes (PMNs), 965
- Polypropylene mesh, 459
- Polypropylenimine dendrimers, 1142
- Polysorb[™] (U.S. Surgical, Connecticut), 140, 168
- Polyurethane catheters, 434
- Porcine model, focal renal ablation in, 698, 1079
- Porcine renal cryosurgery, 543
- Porcine skin, healing characteristics of, 651
- Port closure device (Carter-Thomasson, Inlet Medical, Minnesota), 547
- Port placement, in children, 758, 760
- Port site herniation, 1038, 1041
- Port site metastases, 1039
- Port site recurrence (PSR), 745
growth of, 750
implications on, 749
incidence of, 749
prevention, 751
- Port site skin incision, 836
- Port-site metastasis, 467
- Port-site tumor seeding, 621
- Postganglionic retroperitoneal sympathetic nerves, dissection of, 1066
- Posthysterectomy vaginal vault prolapse, 894
- Postprostatectomy, 1019
- Postpyeloplasty
procedure, 299–300
right-sided, 298
- Pre-peritoneal distention balloon, 486
- Precystectomy, bladder capacity of, 1055
- Pregnancy
anemia in, physiologic, 89
deep venous thrombosis, risk of, 985
magnetic resonance imaging during, 986
open surgical procedures during, 987
- Preperitoneal insufflation, 37
- Preston, Charles, 4
- Primovox, 19
- Progesterone therapy, 992
- Prolene hernia mesh, 399
- Prophylaxis, thromboembolism, 196
- Propofol[™], 626
- Prostate, transurethral resection of, 108
- Prostate apex, dissection of, 683
- Prostate biopsy, 108
- Prostate cancer, 617, 717, 729
drug delivery for, 1142
metastatic, 1084
risk of, 632–633
screening, 419
treatment, cost of, 1013
- Prostate dissection, 920
nerve sparing of, 686
non-nerve sparing, 687
- Prostate, posterior dissection of, 686
- Prostate-sparing laparoscopic radical cystectomy, 673
- Prostate specific antigen (PSA), 617, 860, 1019
- Prostatectomy, 724
cancer control, 1019
laparoscopy radical, 150, 678
robotic radical, 717, 894
open radical
oncological outcome, 693
operating time, 691
- Prostatic adenoma, 865
- Prostatic adenectomy, 865
- Prostatic apex, 23
neurovascular bundle from, 683
- Prostatic fascia, 24–26, 683
- Prostatic lymph node drainage, 617
- Prostatic neurovascular plexus, 25
- Prostatic pedicle, 683
- Prostatic pedicles, 24–26, 709
right, 25
- Prostatic urothelium, texture maps of, 1118
- Prostatorectal fascia, 22, 24
- Prostatoseminal vesicular fascia, 25
- Prostheses, with micro-electro-mechanical systems (MEMS) sensors, 1148
- Protein measurement, urinary, 537
- Proteinuria, 247, 250–251
- Prothrombin time (PT), 973
- Protractor[™] (Weck Closure Systems, North Carolina), 644
- Psoas fascia, 330
- Psoas muscle, 126, 487
- Pubic tubercle, 457
- Puboprostic ligaments, 23, 681
- Pubescent ligaments, 23
- PUMA (Programmable Universal Machine for Assembly) 558 robot, 107
- Pyelocaliceal diverticulectomy, 162
- Pyelocaliceal repair, 161
- Pyelogram, retrograde, 296, 396
- Pyelolithotomy, 280
with concomitant pyeloplasty, 283
laparoscopic, 160
robot-assisted, 283, 288
- Pyelonephritis, 1076
- PPyeloplasty, 98, 282, 304, 845–846
Anderson-Hynes technique, 295
Culp-DeWeerd, 295
Fenger, 295, 299
Foley Y-V plasty, 295, 299
incision, 283
robot-assisted, 283, 305
techniques for, 295
- Pyocystis, 803
- Pyosalpinx, 943
- Pyrotech[™] (EDAP, France), 1080
- Pyrotherapy, 1080
- Quadratus lumborum muscle, 255
- Quill and cannula, 440
- Quixil (Omrix Biopharmaceuticals S.A., Rhode St Genesé, Belgium), 93
- Radiation therapy, 637
for pelvic extravesical disease, 580
- Retroperitoneal colposuspension, laparoscopic, 947
- Retroperitoneal prostatectomy, laparoscopic, 860
- Reanastomosis, laparoscopic, 947
- Rectosigmoid pouch creation, laparoscopic, 671
- Renal autotransplantation, laparoscopic, 842–843
- Renal biopsy, laparoscopic, 247
complications, 250
disadvantage of, 251
epidural anesthesia in, 251
pneumocephalus in, 250
retroperitoneal approaches for, 247, 250
surgical technique of, 247–250
transperitoneal approaches for, 247
- Renal donation, laparoscopic, 359
- Renal hypothermia, laparoscopic, 517
- Retroperitoneal lymph node dissection
laparoscopic (RPLND), 9, 98, 611
- Radical cystectomy, laparoscopic, 953
blood loss in, 669
complications of, 671
hand-assisted, 674
history of, 670
with ileal neobladder, 671
international registry of, 674
lymphadenectomy, oncological outcomes of, 670
robot-assisted, 673
- Radical cystectomy, laparoscopic, 655
steps in, 620
- Radical cystectomy (prostate sparing),
laparoscopic, 625, 632
- Radical cystectomy, 651–652, 656
- Radical hysterectomy, 945
- Radical nephrectomy (RN), 123, 527, 543
bowel preparation for, 475
complications, 479
contraindications to, 474
evaluation, preoperative, 474–475
intraoperative steps of, 475
laparoscopic, 477, 978
retroperitoneoscopic, 495

- Radical nephrectomy (RN) (*continued*)
 surgical technique, 475–479
 patient positioning, 475–479
 port placement schemes, 476
 technical steps, 476–479
- Radical open nephroureterectomy, 577
- Radical prostatectomy, 420, 695
- Radical prostatectomy, 692
 and rectal injury, 919–920
 management of, 919–920
- Radical retropubic prostatectomy (RRP), 724, 1014
- Radio-frequency ablation (RFA), 553, 751, 1004
 chronic histopathologic effects of, 558
 clinical studies of, 559–561
 indication and contraindications for, 554
 laparoscopic, 554, 557
 partial nephrectomy for, 560
 mechanism of action, 554
 oncologic adequacy of, 559
 percutaneous, 556
 temperature-based, 559
- Radio frequency electrode, 553
- Radio frequency energy, 529
- Radiolucent needle driver, 108
- Radiosensitive organs, tissue ablation in, 1079
- Radiosurgery, 1079
 Palmer Raoul, 7
- RB-1 needle, 724
- Rectosigmoid carcinoma, 965
- Rectosigmoid junction, antimesenteric incision at, 661
- Rectosigmoid pouch, 659–660
- Rectourethral fistula, 919
- Rectourethralis muscle, 25, 688, 709
- Rectus fascia, anterior, 706
- Rectus muscle, 433, 457
- Remote center of motion (RCM), 108
- Remote telepresence surgery, 1095
- Remote telesurgery, 1094
- Renal ablative techniques, 1004–1005
- Renal artery
 aneurysm, laparoscopic repair of, 843
 clamping, 523
 pulsations, 14, 125
 stenosis, 162
- Renal autotransplantation, 852
 laparoscopic, 842–843
- Renal biopsy
 direct-vision, 247
 laparoscopic, 247
 transurethral, 251
- Renal blood vessels, 14
- Renal capsule, anterior aspect of, 792
- Renal cell carcinoma (RCC), 466, 519–520, 1003
 biology of, 962
 for high intensity-focused ultrasound (HIFU), 1004
 pathology, 524
- Renal cyst, 360–361
 coagulation, 268–269
 computed tomography criteria for, 260, 261
 cystoscopy and ureteral stent placement of, 265–266
 diagnosis of, radiologic, 260
 drain placement, 269
 exophytic, 267
 fluid, 267–268
 histopathologic and cytologic analysis of, 16
 indications and contraindications of, 262–263
 laparoscopic, 259
 lesions, 264
 management of, complex, 14
 peripelvic, 15, 262, 263
 recurrence rate, 259
 solitary, 17
 surgical management of, 273
 symptoms of, 262
 ultrasonography of, 260
- Renal cysts ablation, 273
 instrumentation and equipment for, 265
 laparoscopic, 262
 patient positioning, 264–265
 retroperitoneal approach, 14, 265
 transperitoneal approach, 266
- Renal cyst base, biopsy and coagulation of, 268–269
- Renal cyst drainage
 blood loss for, 887
 marsupialization of, 886
 operative time for, 887
- Renal cyst fluid, needle aspiration of, 267
- Renal cyst surgery, 1005
- Renal cyst wall, excision of, 268
- Renal failure, 250–251
- Renal hilar vascular stumps, 792
- Renal hilum, 16, 126, 344–345
 bleeding from, 490
 complications, 490
 control of, 478
 dissection of, 487, 791
 ligation of, 487
- Renal hypothermia
 ice slush, 836–837
 laparoscopic, 531
 physiology of, 835–836
 techniques of laparoscopic, 836
 transarterial, 838–839
- Renal ischemia time, 530
- Renal lesions, characterization of, 52
- Renal malignancy, 1131
- Renal metabolic activities, 835
- Renal mobilization, 490
- Renal parenchyma, 255, 326, 590, 1068
 circumferential compression of, 517
 hemostasis, 511
 incision, 537
 temperature, 837
- Renal pelvis dissection, 282
- Renal procedure in child, surgical setup, 759
- Renal reconstruction, 159–163
- Renal replacement therapies, 432
 hemodialysis (HD) of, 432
 peritoneal dialysis (PD) of, 432
- Renal scan diuretic, 307
- Renal stones, 360
- Renal surgery, 531, 1003
- Renal transplantation, 161, 337, 376
- Renal tumors, 474, 522, 1085–1088
 ablation, 60
 lesioning in, 1087
 hereditary, 559
- Renal ultrasonography, 512
- Renal vascular surgery, laparoscopic method of, 161
- Renal vasculature, 9, 54
- Renal vein, 238, 358, 790
- Renal vessels, transection of, 11
- Renin activity, peripheral, 842
- Renography diuretic, 296, 300
- Renovascular surgery, laparoscopic, 841
- Residual retroperitoneal masses, surgical removal of, 600
- Respiratory acidosis, 33
- Retrocaval ureter
 laparoscopic surgical management of, 370
 retroperitoneoscopic approach, 370
 symptoms, 369
 transperitoneal laparoscopic management of, 369
- Retrograde ejaculation, 614
- Retrograde injection, 532
- Retroperineoscopy, balloon rupture in, 1040
- Retroperitoneal access, 485, 761–762
 complications of, 127, 490
- Retroperitoneal balloon dilators, 486
- Retroperitoneal fibrosis, 163, 371
- Retroperitoneal laparoscopic nephrectomy
 right-sided, 485
- Retroperitoneal laparoscopy, 483, 926
 equipment necessary for, 120
 time management of, 126
- Retroperitoneal lymph node dissection (RPLND), 746
 advantages of, 612
 complications of, 614
 efficacy of, 613
 morbidity of, 611
 postchemotherapy, 614
 therapeutic, 612
- Retroperitoneal lymphadenectomy, 600, 1006
 diagnosis of, 1066
- Retroperitoneal soft tissue, 1063
- Retroperitoneal space (RPS), 450
 balloon dilation of, 486
- Retroperitoneal tumors, 218
- Retroperitoneal vascular injury, 904
- Retroperitoneoscopic adrenal surgery, 16
- Retroperitoneoscopic partial nephrectomy, 522
- Retroperitoneoscopic ureterolithotomy (RPUL), 286
- Retroperitoneum, 477
 dilatation of, 236
 dissection of, 489
 orientation in, 126
 risk of bleeding in, 251
- Retropubic prostatectomy, 618, 708, 860
- Retropubic space, 22
- Retzius space, 23, 397–398, 682, 737
- Rhabdomyolysis, 923, 927–929
 cushioning, 931
 etiology of, 8–9
 pathogenesis of, 927, 928–929
 risk factor for, 927
- Rhabdomyosphincter, 26
- Rhinoceros-3D® (Robert McNeel and Associates, Seattle, Washington), 1106
- Ribbon gauze, 237
- Ricordeau, 7
- Right para-aortic dissection, 608
- Ringer solution, 71
- ROBODOC® surgical system (Integrated Surgical Supplies Ltd., California), 107

- Robot assisted remote telepresence surgery (RARTS), 1091, 1094
 applications of, 1093
- Robot-assisted kidney transplantation, 162
- Robot-assisted laparoscopic radical cystectomy, 673–674
- Robot-assisted laparoscopic surgery, 304
- Robot-assisted microsurgery (RAMS) project, 107
- Robot-assisted prostatectomy (RAP)
 equipment, 1014
 costs, 1014
 of extraperitoneal space, 724
 port placement of, 724
 simulator, 1111
 technique, 718
- Robot-assisted pyeloplasty
 in adult patients, 306–308
 clinic application of, 890
 operative times of, 309
 preoperative preparation in, 305
 repair contraindications, 305
 retroperitoneal approach, 308
 surgical steps in, 308–309
 for ureteropelvic junction obstruction (UPJO), 889
- Robot-assisted retroperitoneoscopic pyeloplasty, 309
- Robotic bilateral salpingo-oophorectomy, 173
- Robotic cholecystectomy, 172
- Robotic laparoscopic applications, 1103
- Robotic pancreatic surgery, 172
- Robotic radical cystectomy, 893
- Robotic radical prostatectomy, 717
 extraperitoneal approach for, 724
- Robotic surgery, 201
 advantage of, 309
 applications, 107
 complications in, 311
 disadvantage of, 310
 future of, 113
 limitations of, 113
 operating rooms for, 86
 role of surgeon in, 109, 1146
 technology, 642, 717, 892
- Rumi manipulator, 948
- Running suture technique, 878
 single knot, 874–876
- Sacral promontory, 895
- Sacrocolpopexy, 894
- Saddle bag pouch, 395
- Sailor's knots, 140
- Salpingitis, diagnosis of, 943
- Santorini's plexus, 24, 682, 709
- Sclerotherapy, 1005
- Scrotal skin incision, 772
- Semen parameters, 7
- Seminal vesicle
 calculi, 418
 carcinoma, 418
 cystic disease of, 417
 dissection of, 709, 721, 737
 imaging of, 418
 inflammatory lesion of, 419
 pathology of, 417
 size of, 421
 stones, 418
 therapeutic excision of, 417
 tumors, 418
- Seminal vesicular complex, 639
- Seminal vesiculography, 418
- Semm kurt, 6, 8
- Septum rectovesicale, 25
- Sequential color and memory (SECAM) monitors, 82
- Sequential compression devices, 718
- Sequential compression stockings, 264
- Serial analysis of gene expression (SAGE), 963
- Seromyotomy, 164
- Sevoflurane™, 626
- SewRight (LSI Solutions, New York), 71
- Sexual health inventory for men (SHIM) score, 1019
- Shock wave lithotripsy, 326, 327, 1005, 1080
- Sigma-rectum pouch, 660
- Sigmoid/left colectomy, 644–646
- Sigmoidocystoplasty, 387
- Sigmoidocystoplasty laparoscopic port sizes in, 384
- Simple cystectomy laparoscopic, 670
- Simple prostatectomy laparoscopic, 860
 for benign prostatic hypertrophy (BPH), 860
 complications of, 866
 contraindications for, 860
 extraperitoneal technique for, 865
 indications for, 860
 patient positioning in, 861
 preoperative preparation in, 861
 prostatic adenomectomy in, 862
 prostatic fossa in, 862
 subcapsular plane in, 862
 transverse cystotomy in, suture repair of, 862
- Sterilization procedures laparoscopic, 1037
- Sigmoidoscopy, preoperative, 660
- Sigmoid pouch creation, 660
- Silastic Y-graft, 895
- SimPraxis™, 1116
- Single nucleotide polymorphisms (SNP), 963
- Small bowel laparoscopic surgical resection, of, 1039
- Small renal tumors
 in chronic hemodialysis patients, 502
 natural history of, 502–503
 nephron-sparing surgery for, 503
- Society of American Gastrointestinal Endoscopic Surgeons (SAGES), 1044
- Society of Laparoscopic Gynecologists, 1044
- Solvent detergent (SD) plasma, 975
- Somatic cell nuclear transfer, 1057
- Somatic nerves, 433
- Sotelo prostatotome, 864
- Spacemaker (GSI, California), 486
- Spermatic artery, preservation of, 425
- Spermatic cord, 21
- Spermatic vascular bundle, 427
- Spermatic vein
 dissection of, 603
 ligation of, 425
- Spermatic vessels, 456, 772
 resection of, 608
- Spermatogenesis, 423
- Sphincteric complex, 26
- Sphincteric fascia, 23, 24
- Spirinolactone, side effects of, 225
- Splanchnic hypoperfusion, 33
- Splenectomy, laparoscopic, 172, 990–991
- Splenic flexure, 790
- Splenic injury, 14, 343
- Splenic laceration, 99
- Splenic mobilization, 343–344
- Splenocolic ligament, 211, 604
- Splenorenal bypass, 162
- Splenorenal ligaments, 790
- Staple-mesh colposuspensions, laparoscopic, 399
- Staplers, prototypic automated, 168
- Staphylococcus aureus*, 442
- Starburst XL probe (RITA Medical Systems, Inc., California), 554
- Steiner morcellator (Karl Storz, Tuttlingen, Germany), 587
- Stem cells, 1057
- Step® system (U.S. Surgical), 760
- Stereoendoscope, three-dimensional, 84
- Stereoendoscopic image processing, principles of, 83
- Stereotactic radiosurgery, 553, 1079
- Steroidogenesis, 423
- Stone formation, synthetic, 283
- Stone surgery, 1005–1006
- Storz microendoscope (Karl Storz, California), 884
- Stretch-induced tissue expansion, 1068
- Stricture, 300–301
- Studer limb, 657
- Subcapsular venous plexus, 865
- Suction-irrigation device, 71, 344, 657, 873
 dissection with, 344
- Sufentanil™, 626
- Superior iliac spine, anterior, 707
- Superior mesenteric artery (SMA), 14
- Suprahilar dissection, 123
- Surgeon-driven robotic systems, 109
- Surgicel®, 60, 97, 331
- Surgidac™, 140
- Surgiflex®P™ suction-irrigation system (ACMI Corporation, Massachusetts), 719
- Surgifoam (Johnson & Johnson, New Jersey), 96
- Suture technique, running, 878
- Suturing devices, 169, 877
- Suturing, intracorporeal, 71
- Suturing, laparoscopic, 317
- Suturing simulator, 1111
- Symphysis pubis, 682, 706
- Synthetic polymers, biodegradable, 1055
- Systemic immunosuppression
 advantages of, 957
 effects of, 965
- Szabo-Berci™ (Karl Storz, Culver City, California), 142
- T cell, 468, 817, 954, 956
- Transabdominal preperitoneal repair (TAPP) laparoscopic, 455
- Transperitoneal ascending radical prostatectomy laparoscopic
 apical dissection of, 682
 patient preparation in, 679–680
 trocar placement in, 682

- Transperitoneal cryoablation, laparoscopic
patient's positioning for, 546
trocar placement for, 546
- Transperitoneal cutaneous ureterostomy
laparoscopic, 654
- Transperitoneal descending laparoscopic
radical prostatectomy,
trocar positioning in, 688
- Transperitoneal lymphadenectomy,
laparoscopic (LPLND), for prostate
cancer, 375
- Transperitoneal nephrectomy, laparoscopic,
243
- Tachocomb (Nycomed, Linz, Austria.), 839
- Taenia coli*, 660
- Teflon injection, 779
- Telemedicine, 85
- Telementoring, 1092–1095
- Telerobotic surgery, 85, 174, 896, 1094
- Telesurgery, 111, 1094–1095
- Tenckhoff catheter, 440
- Tension pneumothorax, 791
- Testes, contralateral, 424
- Testicle
abdominal undescended, 771
intra-abdominal, 770
management of impalpable undescended,
772
peeping, 769
- Testicular atrophy
ipsilateral, 424
risk of, 426
- Testis tumors, 599, 1084–1085
- Testis/spermatic cord, external traction on,
427
- Texture mapping, for tissue blanching, 1108
- Thermal lesions, risk of, 688
- Thermal necrosis, at trocar sites, 1034
- Thermal tissue ablation, 1082
- Thoracoabdominal injury, 998
- Thoracolumbar fascia, 286, 559
- Thoracoscopic transdiaphragmatic
adrenalectomy, 201
clinical experience, 831
patient selection, 827–828
surgical technique, 828–831
- Thoracoscopic transdiaphragmatic nephrec-
tomy, 826
- Thromboembolic phenomena, risk of, 985
- Thromboembolism prophylaxis, 196
- Thromboprophylaxis, 638
- Thrombosis, prophylaxis, deep venous,
718, 725
- Thrombotic thrombocytopenic purpura,
975
- Thrombus propagation, intravascular, 555
- Thyroid and parathyroid diseases,
laparoscopic surgery for, 814
- Thyroid lobectomy, video-assisted, 814
- Tisseel™ (Baxter Healthcare Corporation,
Illinois), 93, 333, 549
- Tissue ablation, 1079–1080
- Tissue ablative therapy, 1007
- Tissue dissection, laparoscopic, 211
- Tissue engineering, 1053–1054
clinical application of, 1054
genitourinary, biomaterials for, 1054
principles of, 1053
- Tissue-engineered neobladder, 1055
- Tissue fragmentation process, 1079
- Tissue necrosis, acute, 1086
- Tissue realignment, 130
- Tissue sealant products, 333
- Tissue strangulation, 414
- Tissue tripsy, mechanical, 1079–1082
- Titanium clips, 70
- Tonsillectomies, 130
- Toxin gene, 1142
- Tranexamic acid, 94
- Transabdominal preperitoneal hernia repair,
457–458
- Transferrin-lipoplex, 1142
- Transient postoperative gross hematuria, 250
- Transitional cell carcinoma (TCC), 573, 749
biologic susceptibility of, 750
port site metastasis of, 580
of upper urinary tract, 578
- Transjugular kidney biopsy, 251
- Transmural fibrosis, 1076
- Transperitoneal ascending prostatectomy
See Heilbronn technique
- Transperitoneal descending prostatectomy
See Montsouris technique
- Transperitoneal laparoscopic pyeloplasty,
port placement for, 758
- Transperitoneal laparoscopic radical
prostatectomy (TLRP), 678
advantages and disadvantages of, 690
extraperitoneal and, 689
and open radical prostatectomy, 692–693
- Transperitoneal laparoscopy, 933
- Transplantation, renal, 161
- Transrectal ultrasonography (TRUS), 108, 417
advantages of, 1004
- Transthoracic laparoscopy, 826–827
- Transureteroureterostomy, laparoscopic
approach, 371
- Transurethral detachment and ligation
(TUDL), 576
- Transurethral dissection, 566
- Transurethral intussusception technique, 4
- Transurethral prostate enucleation, 860
- Transurethral resection (TUR), of ureteral
orifice, 575
- Transurethral resection of bladder tumor
(TURBT), 221, 621
- Transurethral resection of the prostate
(TURP), 108, 859
morbidity of, 1117
simulation model training for, 1117–1118
- Transurethral resection of tumor
(TURBT), 577
- Transurethral resectoscope, 4
- Transurethral surgery, complications of, 865
- Transvaginal bone-anchored sling
procedures, 402
- Transvaginal radical cystectomy,
laparoscopically assisted, 650
- Transvesical prostate adenomectomy, 860
- Trauma, peritoneal, 750
- Traumatic tissue handling, 411
- Trocar
configuration, 270
dilation, 772
geometry, 712
injuries, 441, 1043, 1035
insertion, 270, 567
minisite, 67
types of, 69
- Trocar site hernias, 919
- Trocar site infection, 1039
- Tubal sterilization, diathermy for, 8
- Tube thoracostomy, 935
- Tuberculosis, of kidney, 243
- Tubo-ovarian abscess, treatment of, 943
- Tubular cells, proximal, 835
- Tubular necrosis, 353, 842
- Tumors
adrenal, 223, 757
anatomic characteristics, 535
bladder, primary, 749
carcinomatosis, 468
characteristics, 214
dissection of, 212
endophytic, 558
excision, 522
genital, 758
glomus jugulare, 217
growth properties, 502, 504
Hilar, 535
histology, 593
hormonally inactive, 224
implantation rates, 1039
intracranial, treatment of, 1079
intraoperative manipulation of, 210
kidney, 1085
metastases, development of, 959
ovarian, 944
pediatric, 757
recurrence patterns, 537, 580
renal, 474, 522, 1085–1088
retroperitoneal, 218
seeding, 817
size, 502
in solitary testis, 1084
spillage, 621, 574, 751
staging, 595
testis, 1084–1085
ureteric, 852
vaccines, perioperative, 963
aerosolization of, 749
dissemination, 749
in port metastasis, 817
wedge resection, 524
- Tumor growth, with pneumoperitoneum, 817
- Turner's syndrome, 845
- U-shaped vesicostomy, 654
- Ultrasonography laparoscopic (LUS), 836,
1001, 1003, 1006
- Ureterolithotomy laparoscopic, 9, 284, 991
- Ureteroneocystostomy laparoscopic, 372
- Ureteropelvic junction obstruction laparo-
scopic (UPJ), 99
- Ureteroscopy diagnostic, 1120
- Urethrovesical anastomosis laparoscopic,
1121
- Urinary diversion, reports of laparoscopic,
649
- Urologic surgery laparoscopic, 242, 618
complication rates of, 1042
medicolegal aspects of, 1025, 1029
risk of, 1043
- Ultrasonic aspirator systems, 198
- Ultrasonically activated devices, 1035
- Ultrasonography, 47

- hyperechoic changes on, 1087
- intraoperative, 935
- laparoscopic, 836
- Ultrasound dissection, disadvantages of, 70
- Ultrasound probes, laparoscopic, 47
- Ultrasound thermal mapping technology, 1004
- Ultrasound transducers, 47
- Umbilical cicatrix tube, 972
- Umbilical incision, 719
- Umbilical ligament, medial, 720, 772
- Unilateral hydronephrosis, 671
- Unilateral nonpalpable testicles, laparoscopic surgery for, 771–773
- United Network for Organ Sharing (UNOS), 359
- Upper tract transitional cell carcinoma (UTTCC), treatment of, 573
- Urachal anomalies, pediatric, 166
- Ureter, 21
 - dissection, 9, 371, 792
 - spatulated, 283
 - transection, 10
- Ureteral anastomosis, 99, 660
- Ureteral anatomy, 300
- Ureteral catheter, 15, 532, 566, 780
- Ureteral catheterization, 511–512
- Ureteral complications, 355, 389
- Ureteral dilation, 1068
- Ureteral dilation balloon (Uromax; Microvasive), 1069
- Ureteral expansion chronic, 1070, 1072
- Ureteral implantation, submucosal, 662
- Ureteral injuries, 947, 1038
- Ureteral mobilization, 371
- Ureteral obstruction, 396, 779, 1026
- Ureteral orifice, 567, 577
- Ureteral reconstruction, 163
- Ureteral reimplantation, 661–662, 779
 - indications for, 373
 - laparoscopic bladder flap technique of, 852
- Ureteral stent, 16, 370, 532
- Ureteral stump, residual, 577
- Ureteral tissue, 1073–1075
- Ureteral vascular supply, 281, 652
- Ureteric pathology, bilateral, 852
- Ureteric peristalsis, 284, 285
- Ureteric tumors, 852
 - in solitary kidney, 853
- Ureteroenteric anastomotic strictures, 660
- Ureteroileal anastomoses, 652
- Ureterolithotomy, 280, 991
 - advantages, 285
 - contraindications, 284
 - J ureteric stent in, 285
 - laparoscopic, 9, 284, 288
 - retroperitoneal approach for, 284–285
 - transperitoneal approach for, 284–285
- Ureterolympholysis, 451
- Ureterolysis
 - bilateral, 371
 - and lymphadenectomy, 1006
- Ureteroneocystostomy, 851
 - in adults, 372–373
 - laparoscopic, 372
- Ureteroneovesical anastomoses, 657
- Ureteropelvic anastomosis, 847, 887
- Ureteropelvic junction (UPJ), 758
 - anatomy, 315
 - indications for laparoscopic pyeloplasty, 313–314
 - management of, 313–314
 - obstruction, 160, 286, 296, 303–305, 313–314
 - reconstruction of, 304
- Ureteropyeloscopies, 1043
- Ureterosacral ligaments, 895
- Ureteroscopic endopyelotomy, 160
- Ureteroscopic retrograde endopyelotomy, 304
- Ureteroscopy, 84, 280, 991
- Uretersigmoid diversion, 661
- Uretersigmoidostomy, laparoscopic construction of, 660
- Ureterotomy, 284, 285
 - cutaneous, 372, 654
- Ureteroureterostomy, Heinike-Mikulitz type of, 163
- Ureterovaginal fistula, 412, 940
- Ureterovesical junction, 287
- Urethra, 709
 - apical dissection of, 683
 - incision of, 688
- Urethra-neobladder anastomosis, 673
- Urethra-vesical anastomosis, 690
- Urethral carcinoma, risk of, 632–633
- Urethral catheter, 232, 412, 419, 732
- Urethral injury, 947
- Urethral sphincter, 683
- Urethral strictures, postoperative risk of, 878
- Urethral transection, 683, 722
- Urethroileal anastomoses, laparoscopic, 655
- Urethronovesical anastomosis, 654, 657, 894
- Urethrorectal fistula repair, 1019
- Urethrovesical anastomosis, 684, 688, 710
 - ladder neck in, 870–871
 - laparoscopic running, single knot method for, 874–875
 - in Montsouris technique, 871–872
 - simulation of, 698
 - surgeon's positioning in, 870
 - urethral stump in, 870
- Urethrovesical junction, 400
- Urethrovesical suture line, 870
- Urinary bladder
 - diversion, 372
 - mobilization of, 852
 - reconstructive surgery of, 1067
 - tissue substitutes for, 1067
 - vascularized intestinal segments, 1067
- Urinary catecholamines, 990
- Urinary catheter, 7
- Urinary cytology, 1081
- Urinary diversion, 620
 - appendicovesicostomy, 662
 - conventional incontinent, 389
 - Indiana pouch, 663
 - operative outcomes of reconstructive, 673
 - types of, 675
- Urinary drainage, proximal, 1072
- Urinary incontinence, 694
- Urinary leak, 300
- Urinary metabolites, absorption of, 853
- Urinary protein measurement, 537
- Urinary stones, 991
- Urinary tract
 - anomalies, 846
 - infection, 851
 - injury, 939
 - in laparoscopic hysterectomy, 946
 - lower, 893
 - reconstruction, 1067–1068
 - upper, carcinoma in situ (CIS) of, 573
- Urinoma formation, 532
- Urography, intravenous, 256
- Urogynecologic cancers, radiation therapy of, 411
- Urogynecologic procedures, 403
- Urolithiasis, 281
 - laparoscopic surgery results for, 288–289
 - in pregnancy, 991
- Urologic laparoscopic reconstructive surgery, 175
- Urologic laparoscopy, 531, 911, 973
 - risks of, 1042
 - vascular injuries, 903
- Urologic malignancy, minimally invasive management of, 746, 747
- Urologic laparoscopic telesurgery, 85
- Urology
 - application of modeling in, 1131
 - clinical applications in, 1065
 - duration of hospital stay (DOS) model, 1133–1138
 - experimental data in, 1064
 - laparoscopic procedures in, 1120
 - mathematical prediction modeling in, 1131
 - robotics in, 107
 - simulators in, 84
 - training program, 1116
 - VR simulator in, 1119
- UroMentor, 1119
 - ureteroscopy on, 1120
- Urothelial carcinoma, 591
 - organ-confined, 894
- Urothelial growth, 1053
- Uterine leiomyomata, symptoms of, 940
- Uterine manipulators, 948
- Uteroplacental blood flow, 940, 986
- Uterus, fundus of, 984
- Vagal stimulation, 37
- Vaginal prolapse repairs, 405
- Varicocele laparoscopic, 425
- Varix ligation laparoscopic
 - advantages of, 425
 - complications of, 428
 - contraindications to, 425
 - instrumentation in, 426
 - for painful varicocele, 426
 - patient preparation in, 425–426
 - port placement in, 426–427
 - surgical technique of, 425
- Vascular injuries laparoscopic, 902, 1035
- Vesicourethral anastomosis laparoscopic, complication rates in, 877
- Vaginal hysterectomy laparoscopic-assisted, 641, 1038
- Varicocele
 - bilateral, 423
 - diagnosis, 423
 - indications for treatment of, 424
 - nonoperative therapy of, 424–425
 - operative therapy of, 425
 - palpable, 424
 - repair, 7
- VarioLift™ (AESCLAP Inc., Pennsylvania), 816

- Varix ligation, 424
 laparoscopic transperitoneal, 425
 open retroperitoneal, 425
 retroperitoneal approach to, 425
 Varix pathophysiology, 425
 Varix thrombosis, 424
 Vasa deferentia dissection, 721
 Vascular autostapling devices, 132
 Vascular endothelial growth factor (VEGF), 1068
 Vascular hilar control, 98
 Vascular injuries, 127, 907, 1030, 1035–1036
 in dissection, 1035
 hallmark features of, 1035
 in pneumoperitoneum insertion, 1035
 Vascular pedicle, 132, 166
 division of, 489
 Vascular structures, 904
 blood-free dissection of, 1079
 control of, 689–690
 magnification of, 3
 preservation of, 590
 Vasography, antegrade, 418
 Velcro® straps, 719
 Venotomy, 36
 Venous complex, division of, 688
 Venous gas embolism (VGE), clinical effects of, 35–36
 Venous pressure intracardiac, 30
 Venous thromboprophylaxis, 974
 Venous thrombosis, 39
 Venous thrombosis deep, 620
 prophylaxis, 189
 Ventriculoperitoneal shunts, for hydrocephalus, 762–763
 Ventroscopy
 for inspection of abdominal cavity, 4
 intra-abdominal insufflation for, 31
 pulmonary effects of, 33
 physiologic responses to, 31–33
 Veress needle, 249, 420, 512, 768, 906
 Versaport (U.S. Surgical, Connecticut), 706
 Verumontanum, 683
 Vesicoprostatic commissure, 684
 Vesicoureteral reflux, 779
 Vesicoureteroplasty, 164
 Vesicourethral anastomosis, 169
 clinical application of, 169
 interrupted, stitches in, 876
 running single knot, stitches in, 877
 running suture technique for, 875
 stricture, 879
 See Urethrovesical anastomosis
 Vesicourethral reconstruction, 710–711
 Vesicovaginal fistula (VVF)
 etiology, 411
 prevention of, 414
 surgical techniques of, 412
 Vesicovaginal space, 413
 Vesicular fascia, prostatoseminal, 25
 Vesiculodeferential artery, 417
 Vicryl™, 140, 284, 698, 1056
 Video endoscopic/laparoscopic systems, 83
 Video endoscopy, 79
 Videoendoscopic cutaneous ureterostomy, 654
 Videolaparoscopy, uses of, 80, 439
 VIGuard F.S. (Vitex: VI Technologies, Inc., Watertown, Massachusetts), 93
 Virtual cystoscopy, 84
 Virtual polygonal model, 1118
 Virtual reality applications, surgical, 1103
 Virtual reality endoscopic/laparoscopic simulation, 84, 1122
 Virtual reality simulator, 1146
 advantages of, 1100
 collision detection in, 1110
 computer processing in, 1105
 curriculum development and implementation of, 1101
 design of, 1101
 disadvantages of, 1100
 metrics used in, 1102
 raw data collection repositories in, 1112–1113
 sensory modes in, 1103
 steps of, 1100
 for training tasks, 1101
 Virtual reality training, for laparoscopic skills, 1117, 1120–1121
 Virtual reality urological simulators, survey of, 1115–1116
 Visceroautonomic paraganglia, 217
 Visiport® introducer (U.S. Surgical, Connecticut), 248, 266, 760
 Visual-spatial subtask cystoscopic module, 1119
 Voice-controlled robot (AESOP®), 679
 Voltaren®, 644
 Volumetric models, types of, 1107–1108, 1112
 von Willebrand factor (vWF), 92

 Warm ischemia time (WIT), 807
 for typical open surgery, 354
 Wilms' tumor, 758
 Wire lifting methods, subcutaneous, 816
 Wound infections, risk of, 1038
Wuchereria bancrofti, 447

 Xanthogranulomatous pyelonephritis (XGP), 243
 Xenografts, 1075
 Xenon sources, 81

 Y-Tec® Scope (Medigroup, Illinois), 446

 Zeus robotic system, for clinical application, 890

Textbook of LAPAROSCOPIC UROLOGY

about the book ...

Divided into eleven detailed sections, this reference displays the expertise and research of specialists from leading urology centers around the world and offers authoritative chapters on the entire spectrum of urologic laparoscopy. The chapters cover methods in patient selection, perioperative management, and complication avoidance; step-by-step descriptions of specific techniques; and the pros and cons of each procedure for a clear grasp of the many principles and practices currently utilized in the field.

Placed alongside the *Atlas of Laparoscopic Urology with DVDs*, this set will likely become the standard reference text in the field of urologic laparoscopic surgery.

This wide-ranging and reader-friendly guide covers all the essential strategies, techniques, and equipment required for successful laparoscopic surgeries...every laparoscopic procedure for benign and malignant disease...specific issues related to pediatric procedures...and developing issues in laparoscopy, as well as future advances that may impact the field in forthcoming years.

about the editor ...

MURRIS S. GILL is Professor of Surgery, and Head, section of Laparoscopic and Robotic Surgery, Shkman Urological Institute, Cleveland Clinic Foundation, Cleveland, Ohio. He has authored or coauthored more than 280 peer-reviewed scientific publications, 50 book chapters, and 4 books. Dr. Gill has been a visiting professor and invited speaker at more than 200 academic institutions and scientific meetings worldwide, and has mentored more than 50 post-graduate clinical and research fellows. He is President, 20th World Congress of Endourology, 2006. Widely recognized as a leader at the forefront of minimally-invasive urology, he specializes in laparoscopic surgery of the adrenal gland, kidney, prostate, and bladder.

Printed in the United States of America

informa

healthcare

www.informahc.com

170 Montross Avenue
Hawthorne, NJ 07040

© 2006 Informa, a Division of
Wolters Kluwer Health | Lippincott Williams & Wilkins

DK994X

ISBN 0-8493-3994-4

90000



5 780849 339943