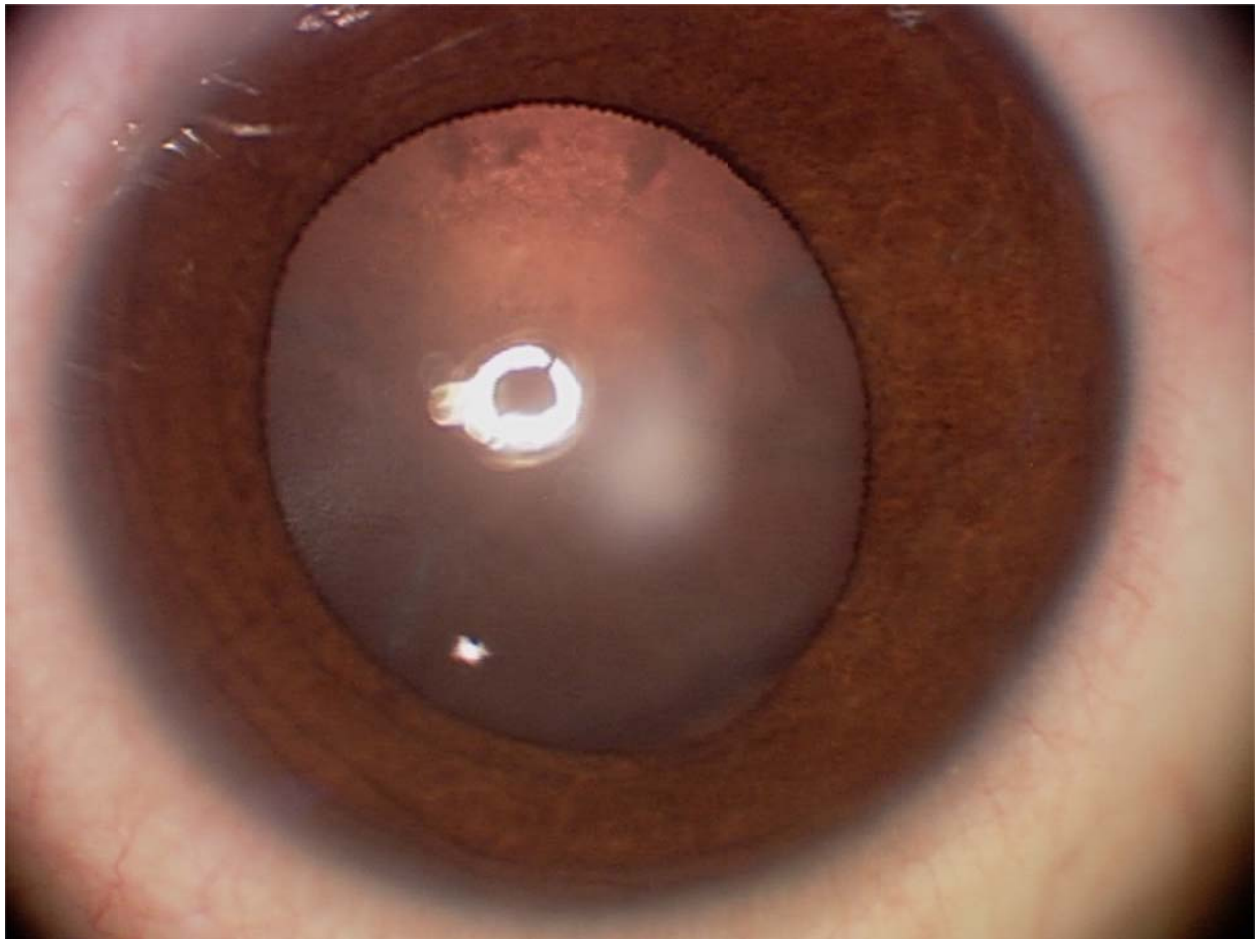


**Appendix 1 (as submitted by the authors): Right eye of a 14-year-old boy with autism spectrum disorder and self-injury.**



**Figure:** Posterior capsular and cortical cataract on retroillumination in the right eye.