

Clark A. Rosen, C. Blake Simpson  
**Operative Techniques in Laryngology**

Clark A. Rosen  
C. Blake Simpson

# Operative Techniques in Laryngology

Forewords by Hans von Leden  
and Robert H. Ossoff

With 390 Figures and 11 Tables

**Clark A. Rosen, M.D.**

University of Pittsburgh Voice Center  
UPMC Mercy Hospital  
1400 Locust Street, 2100 Bldg D  
Pittsburgh, PA 15219, USA  
E-mail: rosenca@upmc.edu

**C. Blake Simpson, M.D.**

The University of Texas Health Science Center  
Department of Otolaryngology  
7703 Floyd Curl Drive MC-7777  
San Antonio, TX 78229-390, USA  
E-mail: simpsonc@uthscsa.edu

ISBN 978-3-540-25806-3

e-ISBN 978-3-540-68107-6

Library of Congress Control Number: 2008926220

© 2008 Springer-Verlag Berlin Heidelberg

This work is subject to copyright. All rights are reserved, whether the whole or part of the material is concerned, specifically the rights of translation, reprinting, reuse of illustrations, recitation, broadcasting, reproduction on microfilm or in any other way, and storage in data banks. Duplication of this publication or parts thereof is permitted only under the provisions of the German Copyright Law of September 9, 1965, in its current version, and permission for use must always be obtained from Springer Verlag. Violations are liable to prosecution under the German Copyright Law.

The use of general descriptive names, registered names, trademarks, etc. in this publication does not imply, even in the absence of a specific statement, that such names are exempt from the relevant protective laws and regulations and therefore free for general use.

Product liability: The publishers cannot guarantee the accuracy of any information about dosage and application contained in this book. In every individual case the user must check such information by consulting the relevant literature.

*Cover design:* eStudio Calamar, Spain

*Production:* le-tex publishing services oHG, Leipzig

Printed on acid-free paper

9 8 7 6 5 4 3 2 1

springer.com

# Videostroboscopy and Dynamic Voice Evaluation with Flexible Laryngoscopy

## 3.1 Fundamental and Related Chapters

Please see Chaps. 1, 2, 4, and 5 for further information.

## 3.2 Introduction

Visualization of the larynx and specifically the vocal folds is paramount for the evaluation and care of patients with voice disorders. There are a variety of methods used for this visualization, ranging from indirect mirror laryngoscopy to high-speed photography. The most common and relevant clinical tools for modern-day voice evaluation and care include stroboscopic visualization of vocal fold vibration and dynamic voice evaluation with flexible laryngoscopy. These two techniques when used in a complimentary fashion can provide the clinician with detailed information on intricate vocal fold vibratory activity and phonatory and functional use of the entire vocal tract. This chapter focuses on these two main clinical methods.

## 3.3 Surgical Indications and Contraindications

Stroboscopy utilizes a method of “shuttering,” or synchronized illumination of the vocal folds during vocal fold vibration (Fig. 3.1). This provides “pseudo” slow motion visualization of vocal fold vibration. Real-time vocal fold vibration is too rapid to visualize with the unaided eye. The stroboscopic light source illumination provides representative images from the entire vibratory cycle. A periodic or nearly periodic vocal fold vibratory activity is required for stroboscopy to be successful. It is important to note that stroboscopy can be done through any type of visualization instrument including flexible laryngoscopy and rigid perioral laryngoscopy. Stroboscopy is strictly the light source and not the actual equipment used for visualization of the vocal folds. (i.e., flexible laryngoscopy or rigid telescope).

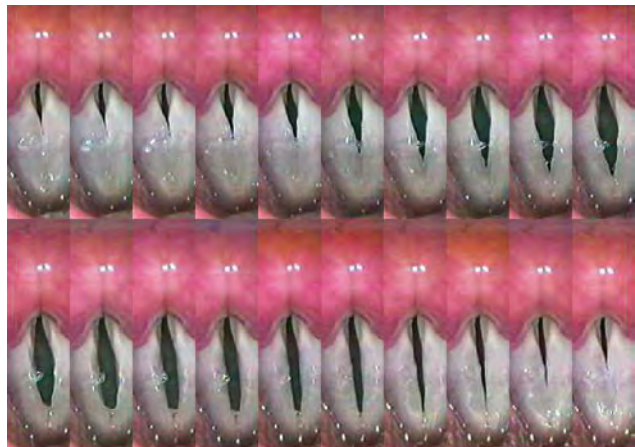The most common vocal fold vibratory characteristics that stroboscopy allows one to view are:

- Vocal fold closure (pattern and duration)
- Mucosal wave movement (propagation)
- Symmetry of vibration
- Amplitude of vocal fold vibration
- Periodicity

Stroboscopy helps elucidate specific lesions of the vocal folds, especially as they relate to closure pattern for exophytic lesions and defects of the lamina propria such as seen in adynamic segments of the vocal fold, vocal fold scar, and sulcus vocalis. Vocal fold closure pattern is typically described as the global overall pattern of vocal fold closure, as seen during the majority of the examination specifically at modal pitch and intensity of vowel prolongation. The most commonly cited and utilized closure patterns include complete, incomplete, hourglass, anterior glottic gap, and excessive posterior glottic gap (Fig. 3.2).

Mucosal wave as seen during stroboscopy refers to a rippling motion traveling over the vocal fold and within the vocal fold mucosa. The wave is propagated from the subglottic area and travels from underneath the vocal fold along the free edge, then over the superior surface of the vocal fold and is dampened in the area of the ventricle. This mucosal wave activity is crucial for assessing the pliability and functional characteristics of the lamina propria of the vocal folds. Areas of diminished mucosal wave represent loss of pliability or viscoelasticity of the vocal fold lamina propria and are an important aspect of voice evaluation. Mucosal wave activity should be assessed at a variety of phonatory tasks, specifically at low, medium, and high pitch and different levels of intensity.

The duration of vocal fold closure is also an important clinical assessment parameter. At modal pitch and intensity, vocal fold vibratory closure should occur approximately half of the vibratory cycle. This can be measured in a detailed fashion us-



**Fig. 3.1** “Representative” set of images from stroboscopy depicting “one” vibratory cycle

ing electroglottography but can also be estimated using frame-by-frame review of the recorded stroboscopic images.

Vocal fold vibration symmetry during stroboscopy is judged by comparing the vocal folds' vibratory activity to one another. The vibration of one vocal fold should be a mirror image of the contralateral fold.

The degree of vocal fold amplitude (horizontal excursion from midline) during vocal fold vibration as seen during stroboscopy is an important assessment tool and involves both the comparative as well as overall subjective assessment of the amount of amplitude of each vocal fold during vocal fold vibration (Fig. 3.3). Of course, amplitude and closure are two stroboscopy parameters that are directly affected by the voice intensity and pitch during the stroboscopic examination and these factors must be constantly monitored and taken into consideration when assessing these parameters. For example, at high pitches both the amplitude and mucosal wave decrease as compared to lower pitches.

Periodicity describes the regularity of vocal fold vibration. Periodicity is based on the regularity of successive cycles of vibration. Even though symmetry and periodicity may be thought to assess similar behavior, in fact, vocal folds can have distinctly different amplitude and symmetrical activity and still be quite periodic. The converse is also true where vocal folds can demonstrate aperiodic activity with normal and symmetric amplitude (as often seen with vocal fold paresis).

Stroboscopy of the vocal folds is helpful for visualization of a variety of vocal fold lesions, which are discussed in detail in Chap. 4, "Pathological Conditions of the Vocal Cords." Stroboscopy is also extremely important for visualization of seg-

ments of the vocal fold with poor vibratory characteristics due to scar, subtle lesions, loss of lamina propria tissue or sulcus vocalis (see Chap. 23, "Sulcus Vocalis and Vocal Fold Scar").

Stroboscopy to assess vocal fold vibratory activity should be done using a fairly consistent assessment protocol. First, it is essential to identify that the patient has a periodic or nearly periodic signal. A typical stroboscopy examination protocol includes:

- Modal voice (most comfortable pitch and intensity)
- Low pitch (soft and loud to assess maximum pliability)
- High pitch, soft intensity phonatory task

The latter is extremely helpful for identifying subtle lesions of the vocal fold as well as assessing abnormalities associated with vocal fold pliability and vocal fold vibratory activities. The low pitch-loud task is helpful not only for assessing overall pliability, but also for patients with the most aperiodic voice. When performing stroboscopy, the vocal fold vibratory activity and characteristics should be first compared internally (to each other), and then compared to the examiners experiential database and most importantly correlated with the amount and nature of dysphonia of the patient. There should be a good correlation from an auditory and visual perceptual basis. If this is not the case, then a repeat examination or careful examination of other factors should be undertaken.

### 3.4 Dynamic Voice Assessment with Flexible Laryngoscopy

Flexible laryngoscopy is an essential evaluation technique for voice disorders-related "functional" problems such as muscle tension dysphonia, paradoxical vocal fold motion disorder and

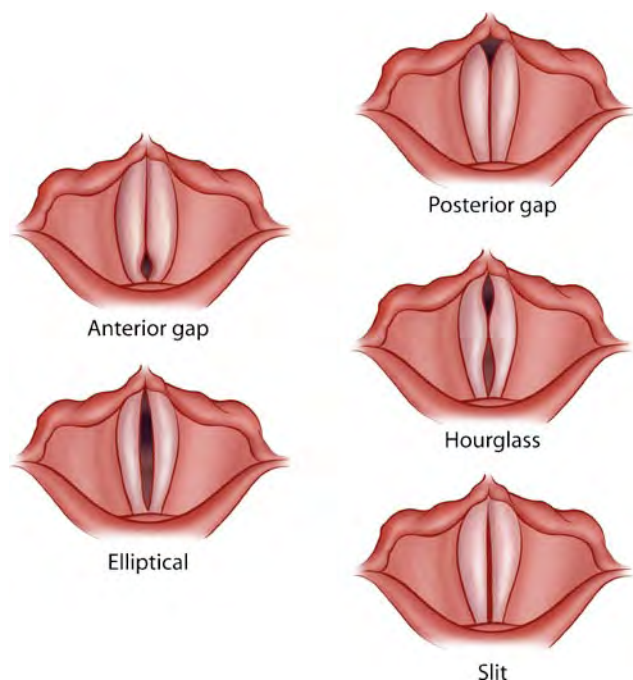


Fig. 3.2 Different vocal fold closure patterns

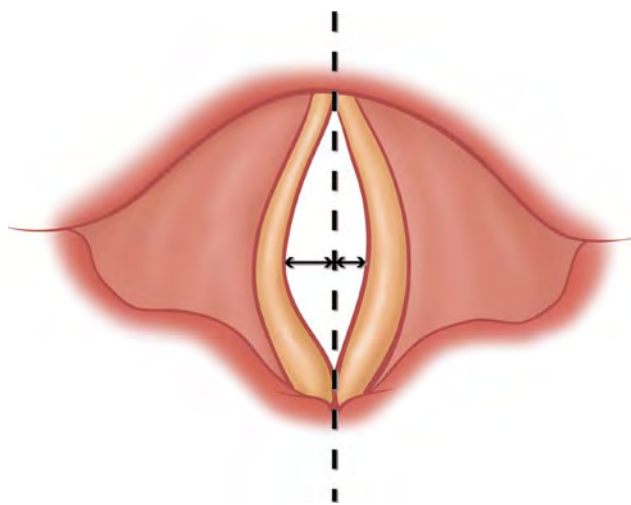


Fig. 3.3 Vocal fold amplitude

functional aphonia, neurologic voice disorders (spasmodic dysphonia, essential tremor, etc.), and vocal fold paresis. Dynamic voice assessment with flexible laryngoscopy evaluates multiple parameters associated with phonation done in a dynamic and “most natural” setting. Equipment required includes nasal speculum, decongestant and anesthetic for the nasal cavity, flexible laryngoscopy, and illumination light source(s) (continuous halogen and preferably stroboscopy). This examination is done in a stepwise fashion, examining each section of the vocal tract which is outlined below from an anatomic and a physiologic perspective (at rest and then in activation). The specific areas of activation include vegetative functions and phonation. The subregions of the dynamic voice assessment include nasopharynx, base of tongue, larynx (global), and the vocal folds. At each one of these specific subportions of the dynamic voice assessment, specific tasks are elicited from the patient to look for different pathologies in the area and confirm or rule out a variety of disorders (Table 3.1).

### 3.4.1 Nasopharynx

1. Patient task: rest, sustained phonation (/ee/) and speech (/koka kola/) and prolonged fricative /s/
2. Parameters of evaluation: nasal disease, masses of the nasopharynx, tremor of the soft palate (rest and activation) and velopharyngeal incompetence (VPI)
3. Pathology: velopharyngeal incompetence, vocal tremor, sinonasal disease, (infectious or allergic) nasopharyngeal neoplasms

### 3.4.2 Base of Tongue

1. Patient task: rest and tongue protrusion
2. Parameters of evaluation: tremor, fasciculations (ALS), tumors, infections
3. Pathology: essential tremor of the vocal tract, amyotrophic lateral sclerosis (ALS), neoplasm (benign and malignant) and infection

### 3.4.3 Larynx (Global)

1. Patient task: quiet respiration, alternating sustained phonation and respiration (hee-hee-hee, with a breath between each “hee”) and connected speech (“We were away a year ago.”)
2. Parameters of evaluation: vocal fold mobility and synchrony of mobility Paradoxical vocal fold motion, supraglottic constriction associated with phonation, and global laryngeal tremor
3. Pathology: paradoxical vocal fold motion disorder, primary muscle tension dysphonia, secondary muscle tension dysphonia, vocal tremor, vocal fold paralysis, vocal fold paresis, as well as pyriform/vallecular lesions, LPR

**Table 3.1** DVA tasks, findings, and correlated diagnoses: examination protocol—tasks

Velum
Sustained /ee/
/koka kola/
Base of tongue
Evaluation of symmetry and mucosa
Larynx
Quiet respiration
Sustained /ee/—comfortable pitch
Sustained /ee/—low and high pitch
/ee/ /ee/ /ee/ (with a breath between each “hee”)
“We were away a year ago.”
“We were away a year ago.”—comfortable pitch
Example of connected speech (Ask,
“What did you do yesterday?”)
Sing “Happy Birthday”
Cough
Laugh

### 3.4.4 Vocal Fold (Focal)

1. Patient task: respiration, sustained phonation and alternating speech and respiration (see Table 3.1)
2. Parameters of evaluation: vocal fold lesions, glottal insufficiency and tremor
3. Pathology: focal vocal fold lesions (polyp, nodules, etc.) cancer, vocal fold atrophy, vocal fold paralysis and vocal fold paresis

## 3.5 Recording of Laryngeal Examination

It is highly recommended but not absolutely necessary that the stroboscopy and/or dynamic voice evaluation be recorded. The two most common methods of recording portions or all of these examinations are with either still photography or video recording. The advantages of recording all or portions of the laryngeal examinations include:

- Longitudinal comparison
- Preoperative planning
- Patient education
- Medical/legal uses

Further justification and use of a video recording include the ability to record an audio track in conjunction with the video examination. Both audio and video examination can be extremely helpful for all of the above-mentioned reasons; especially in a court of law. It is essential to have a baseline or preoperative audio and/or voice recording prior to and after

elective surgical procedures. This is analogous to the documentation procedures for cosmetic surgical procedures. Video recordings of the vibratory parameters of the vocal fold are also very helpful to refer to when surgically resecting a lesion.

### Key Points

- Stroboscopy and dynamic voice assessment (DVA) with flexible laryngoscopy are essential aspects of a voice evaluation and care.
- Strobe and DVA are complementary and should not be viewed in isolation.
- The dynamic voice assessment and evaluation allows for a natural in vivo evaluation of the entire vocal tract during rest, vegetative activities, and phonation (connected and sustained), and stroboscopy allows the examiner insight into key vocal fold vibratory activity, specifically the physiologic and pathophysiologic activities related to the patient's dysphonia.

- The combination of stroboscopy and dynamic voice assessment with flexible laryngoscopy allows the clinician to correlate the patient's voice symptoms, related physical exam abnormal findings, craft an accurate diagnosis and form a successful treatment plan.

### Selected Bibliography

- 1 Hirano M, Bless DM (1993) Videostroboscopic examination of the larynx. Singular, San Diego
- 2 Stasney CR (1996) Atlas of dynamic laryngeal pathology. Singular, San Diego
- 3 Cornut G, Bouchayer M. Assessing dysphonia: the role of videostroboscopy. Five videocassettes, 254 min
- 4 Rosen CA (2005) Stroboscopy as a research instrument: development of a perceptual evaluation tool. *Laryngoscope* 115:423–428
- 5 Roehm PC, Rosen C (2004) Dynamic voice assessment using flexible laryngoscopy—how I do it: a targeted problem and its solution. *Am J Otolaryngol* 25:138–141