Operative Techniques in Thoracic and Cardiovascular Surgery

Rigid Bronchoscopy: Indications and Techniques

Daniel G. Nicastri, MD,* and Todd S. Weiser, MD†

Rigid bronchoscopy is an important procedure for the thoracic surgeon to master. Its utility has been evident since the 1890s when Gustav Killian removed a foreign body from a patient's right main bronchus and Chevalier Jackson developed his own endoscopes with distal illumination.[1,2] Today's rod-lens telescope was developed by Harold Hopkins in England and is the basic telescope inserted through the rigid bronchoscope. Karl Storz modified this technology with a cold illumination source for his rigid bronchoscope in the 1950s.[3]

The modern rigid bronchoscope is used for the diagnosis and treatment of benign and malignant pathology of the central airways. Indications for use include, but are not limited to, foreign body retrieval, obtaining hemostasis and removing blood clots in patients with hemoptysis, and relieving airway obstruction from tumors or intubation-related stenoses. When necessary, rigid bronchoscopy can facilitate the placement of tracheal or bronchial stents. Endoluminal therapies, such as laser treatment, argon plasma coagulation, and debriding instruments, are best used under the protection of a rigid bronchoscope. Rigid bronchoscopy is best used in combination with other modalities, including radiologic studies, such as thin-slice computed tomography scans, flexible bronchoscopy, esophagoscopy, and laryngoscopy.

Although they come in various types and sizes, the overall construction of the rigid bronchoscope is typically uniform: a solid tube that is open on each end with usual side holes along the distal aspect of the scope (Figs. 1-3). The latter enables ventilation to the contralateral lung when working on an obstructing lesion in a main bronchus. There are also multiple ports on the proximal end that can be used for various forms of ventilation: jet (Venturi) ventilation, intermittent volume ventilation, continuous insufflation, and spontaneous ventilation (Fig. 4). We most commonly use Jet ventilation. This is the Venturi model based on air entrapment. It is accomplished by connecting a high-pressure oxygen jet through the side port at the proximal end of the scope. The modified Sanders Jet ventilator delivers oxygen at a pressure of 25 to 30 lb/in^2 with approximately 10 to 20 breaths per minute. The entrainment of air allows ventilation to occur as well as oxygenation. Care must be taken to ensure that this is not a closed system when ventilating as significant barotrauma may occur. Intermittent insufflation is accomplished by connecting ventilation tubing to the side port or proximal open end of the scope. The upper airway and nose may need to be occluded to prevent a large leak. The limitation of this technique is that there can only be intermittent viewing. Continuous ventilation allows continual viewing and ventilation by having a Hopkins telescope in place or a viewing lens while ventilating through a side port. Finally, spontaneous inhalation ventilation requires a breathing patient and light anesthesia. It is useful for induction in a patient with an obstructed airway where airway control is precarious.

*Department of Surgery, Uniformed Services University of Health Sciences, Bethesda, Maryland; Fort Belvoir Community Hospital, Fort Belvoir, Virginia.

†Section of Thoracic Surgery, White Plains Hospital, White Plains, New York.

Address reprint requests to Todd S. Weiser, MD, Director, Thoracic Surgery, White Plains Hospital, 41 East Post Road, White Plains, NY 10601. E-mail: TWeiser@wphospital.org

doi:10.1053/j.optechstcvs.2012.03.001

Figure 1 The 9-millimeter rigid bronchoscope (Bryan Corporation). (Color version of figure is available online at http://www.optechtcs.com.)

Figure 2 Various lengths of the tubes for lesions in the trachea and lesions in the bronchi. There are also various diameter pictures here. The longer bronchial tubes (for more distal lesions) have distal side holes (Bryan Corporation). (Color version of figure is available online at http://www.optechtcs.com.)



Figure 3 This close-up demonstrates the side holes along the distal aspect of the bronchoscope that allows cross-ventilation to the contralateral lung when working on an obstructing lesion in 1 main bronchus. (Color version of figure is available online at http://www.optechtcs.com.)

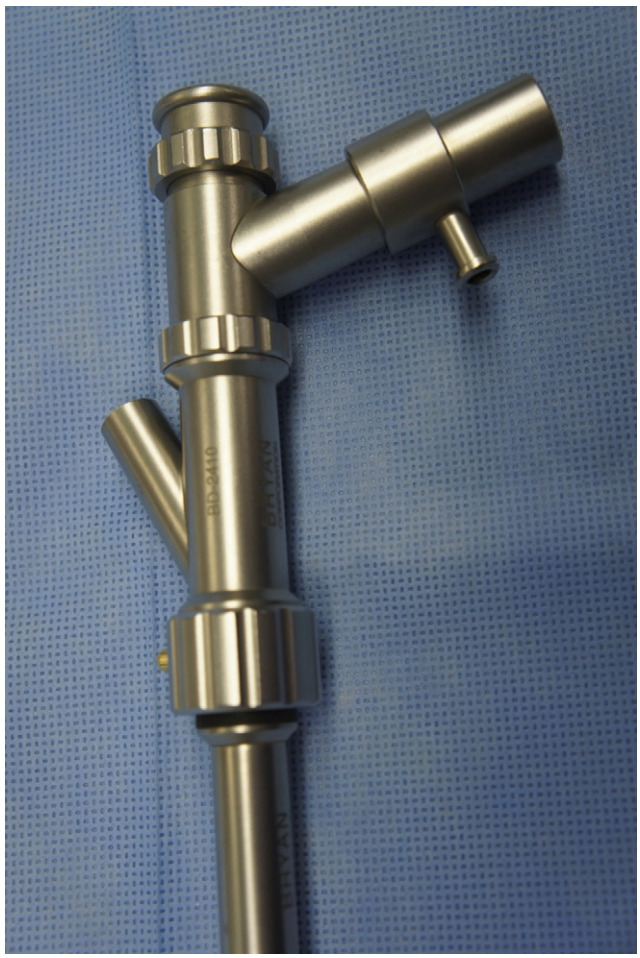

Figure 4 This is a close-up of the proximal attachments of the rigid scope. To the right is the wider port for connecting to ventilation. This attachment can be modified to allow for Jet ventilation, intermittent ventilation, or continuous insufflations. To the left is a smaller attachment that allows passage of instrumentation, including a flexible bronchoscope. (Color version of figure is available online at http://www.optechtcs.com.)

Figure 5 The viewing telescope with its light source is inserted into rigid bronchoscope. (Color version of figure is available online at http://www.optechtcs.com.)

Operative Technique

Equipment

Before the procedure begins, it is imperative that the surgeon and operating room staff be familiar with the necessary equipment. Operating room trays should be organized properly and in good working order. Effectively addressing acute airway pathology takes considerable focus by all involved. When this procedure is new to an institution, we advise performing several well-rehearsed simulated cases with the surgeon, anesthesia team, and nursing staff all present. This will familiarize each with their crucial role; a poorly prepared team will be a disservice to the patient with an acute airway emergency. There should be at least 3 different sizes of rigid bronchoscope—usually 7-, 8-, and 9-mm scopes. Having pediatric Jackson scopes available of various sizes, such as 3.5, 4, 5, and 6 mm (2.5-3 mm may be necessary for children less than 10 kg), may be helpful in dilating very tight lesions. If these are not available, balloon dilators may be passed through the working channel of a therapeutic flexible bronchoscope introduced via the proximal end of the rigid scope. Alternatively, one may have esophageal bougies available; the use of which is described later. Obviously, the surgeon must be ready at the induction of anesthesia to establish an airway emergently, if necessary. Again, our preferred method of ventilation is the Jet/Venturi technique. This should be tested before beginning the procedure. Other important equipment that must be available are large-bore suction catheters, video telescopes (Fig. 5) with a gasket to seal the proximal end of the scope and allow ventilation, flexible bronchoscopes, biopsy forceps (Fig. 6), metal centimeter ruler, and rubber tooth guard or saline-soaked gauze to protect the teeth.

Indications and Contraindications

The indications for rigid bronchoscopy include airway bleeding, foreign body retrieval, deeper tissue biopsy specimens when fiberoptic specimen is not sufficient, dilation of airway strictures, relief of airway obstruction, insertion of stents, and various uses in pediatric bronchoscopy, as well as laser therapy or other mechanical tumor ablation.[4] There are also relative contraindications. These include uncontrolled coagulopathy, extreme ventilatory or oxygenation demands, and tracheal obstruction with a novice operator. The potential complications include injury to the teeth and gums, tracheal or bronchial tears, and severe bleeding. That said, in the hands of the experienced operator, it is superior in the assessment and treatment of an obstructed or bleeding airway when compared with flexible bronchoscopy.

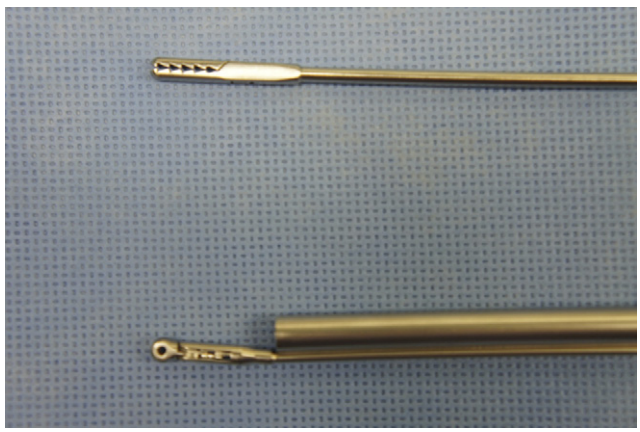

Figure 6 On top is a grasping forceps, which would be inserted into the main channel. This can be used for grasping foreign bodies or taking biopsies. On the bottom is an optical biopsy forceps (Bryan Corporation). The advantage of this particular instrument is the ability to watch on a monitor when biopsying a lesion or extracting a foreign body. (Color version of figure is available online at http://www.optechtcs.com.)

Patient Positioning

The patient should be positioned in the supine position with the head in the "sniffing/intubation" position with the patient's head at the edge of the bed. The "sniffing" position optimally aligns the pharynx, larynx, and trachea (Figs. 7A and 7B). There should be a pillow underneath the head and a shoulder role in place. There are various techniques to traversing the scope across the vocal cords. For those surgeons without significant experience with rigid bronchoscopy, 2 maneuvers may prove useful. One could pass the bronchoscope over an endotracheal tube already placed through the glottis and then slide the rigid scope over the endotracheal tube as it is removed. The second involves using a laryngoscope to visualize the cords and then passing with the rigid scope under direct visualization. With regard to the first technique, as the endotracheal tube is pulled back toward the glottis, the cuff can often catch the cords and the scope. At this point, it is best to pull the cuff back without moving the rigid scope forward and, once the tip of the endotracheal tube is visualized, gently advance to the cords before extubating the patient.

More commonly, after properly positioning the patient, in conjunction with the anesthesia team, we insert the rigid bronchoscope directly and intubate the cords. At all times, the patient's lips and teeth should be protected. The latter is done directly with either a tooth guard or a saline-soaked sponge. Importantly, the surgeon's thumb protects the teeth and one makes certain that torque is not placed on the teeth when moving the rigid scope.

Intubation

A right-handed surgeon protects the teeth with the left thumb in the mouth and inserts the scope into the right side of the mouth (when inserting the ventilator, the sidepiece is oriented upward), advancing to the base of the tongue at the posterior median groove. This is achieved by directing the scope directly down. The proximal end is then slowly brought downward into a more horizontal fashion while carefully protecting the patient's teeth. Elevating the tongue and advancing slowly will bring the epiglottis into view (Figs. 7C and 7D). If the epiglottis is not visualized, then the scope should be brought back and advanced slowly again. Proper observation of the epiglottis is the crucial step in proceeding to intubate the cords. Once the epiglottis is visualized, the scope is advanced posteriorly and is used to lift the epiglottis gently, exposing the glottis (Figs. 7E-7H). As the cords are approached, the bronchoscope should be rotated 90 degrees so that it traverses the cords with the minimum diameter (Figs. 7J-7L). In general, when choosing the size of the scope, the largest scope that is anticipated to traverse the stenosis (if one is present) should be used, without damaging the cords. In men, generally an 8- or 9-mm scope can be used without a tight stenosis, and a 7- or 8-mm scope can be used in women. Once the tip of the scope has passed the glottic aperture, the bronchoscope should be rotated back to its usual orientation with the ventilating side port pointing toward the ceiling. If any resistance is encountered while passing the scope, the use of a smaller scope should be considered.

After intubation of the cords, the pillow may be removed and the head extended farther. To assess the right or left bronchi, the patient's head is turned to the opposite side. Similarly, the scope is placed on the contralateral side of the patient's mouth while carefully protecting the teeth while changing position.

Definition and Dilation of Obstructing Pathology

Rigid bronchoscopy is always commenced via the mouth, even in patients with a preexisting tracheostomy. Pulmonary toilet should be carried out with a flexible bronchoscope, when possible, before proceeding to measurements for planning a resection. When presenting with an obstructing lesion, a smaller scope may allow "coring out" if it is done carefully to pass through a circumferential lesion. Again, if the initial bronchoscope does not pass easily, a smaller diameter scope should be used. This initial airway dilation may allow for more effective ventilation.

Initial examination of the larynx should note any pathology of the upper airway. One should note any strictures of the anterior or posterior commissures, appearance of the vocal cords, and appearance of the subglottic larynx. Then, with direct visualization through the bronchoscope, we proceed as far into the distal trachea as possible. Care is always taken to avoid causing trauma to the airway. Once this is done, flexible bronchoscopy may be performed either through the proximal end of the rigid bronchoscope or through a present tracheal stoma. At this point, we introduce a 0-degree video telescope through the proximal end of the rigid scope. Ventilation is possible using a sealing gasket.

When considering tracheal resection for benign and malignant pathology, precise measurements of normal and abnormal airway must be taken. The rigid bronchoscope has a distinct advantage over its flexible counterpart in this regard. The cricoid can be visualized past the cords as a broad ring immediately above the narrower tracheal rings. If definitive delineation cannot be made because of mucosal pathology, a small-bore needle can be passed through the skin through a palpable cricothyroid membrane to identify the cricoid cartilage properly. After evaluating the glottis, the trachea is inspected, including abnormalities in the membranous and cartilaginous trachea.

With the tip of the rigid bronchoscope at the tracheal carina, the metal ruler is used to measure the distance, in centimeters, from the incisors to a fixed point on the outside of the proximal scope (Fig. 8). This number is then recorded by the nursing staff and noted as "carina." The bronchoscope is then withdrawn gently so the tip of the scope is now over the inferior-most margin of the tracheal pathology. The distance is again measured from the incisors to the same fixed point on the bronchoscope. This number is recorded as "inferior margin of lesion." The use of the video telescope will enable precise localization of airway pathology. This technique continues further with identification of the superior margin of the pathology, cricoid cartilage, and vocal cords. One now has all the information necessary to define the length of pathologic trachea exactly relative to the normal airway. This is critical in ascertaining whether a patient can safely undergo tracheal resection with reconstruction.

The technique for dilating a fibrous stenotic lesion does not involve excessive force. It must be carried out systematically to avoid injury to the normal surrounding trachea. The

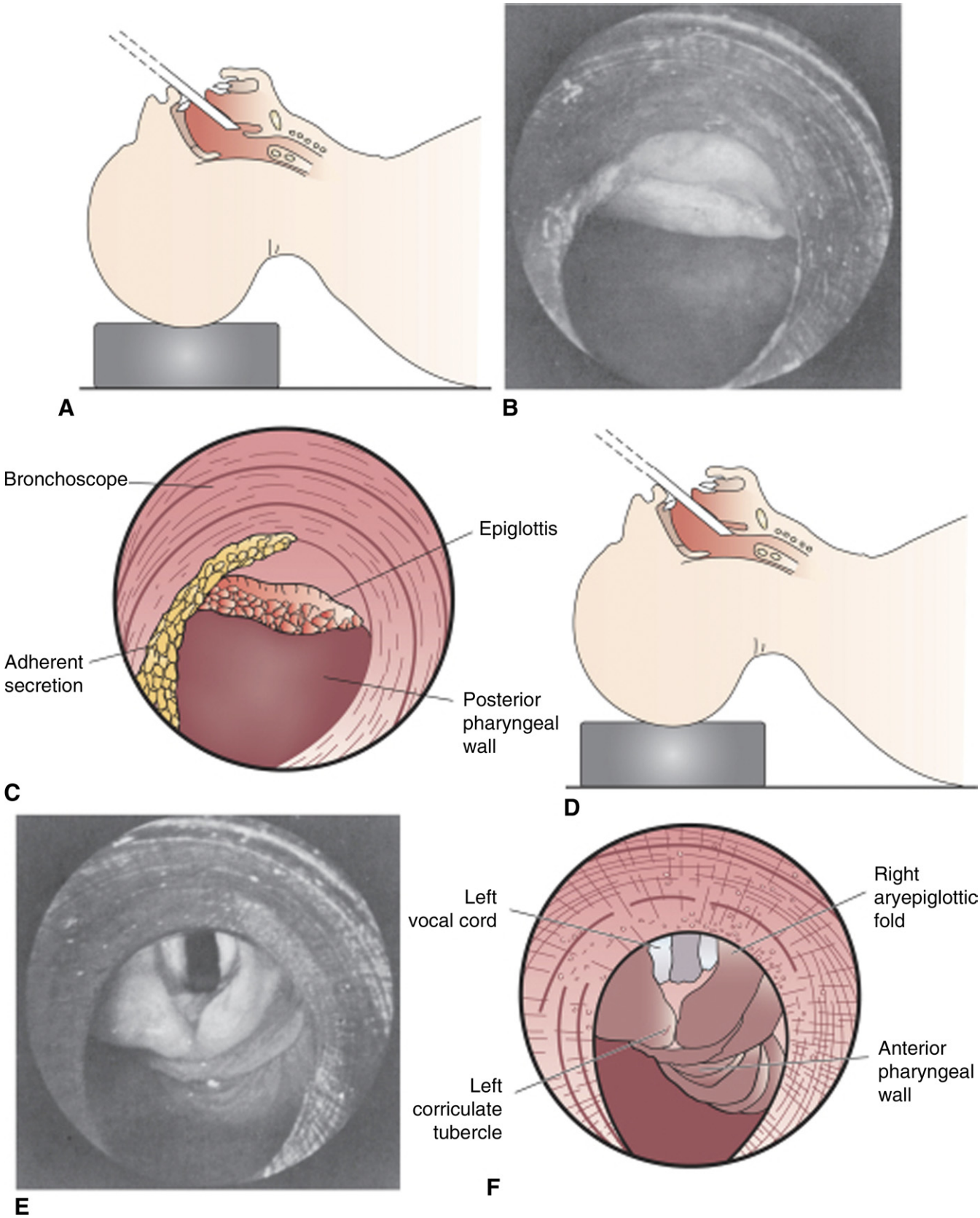

Figure 7 Intubation of the trachea with the rigid bronchoscope. Before the procedure begins, it is imperative that the surgeon be familiar with the necessary equipment and that the operating room trays be properly organized. The patient should be positioned in the supine position with the head in the "sniffing/intubation" position with the patient's head at the edge of the bed. The "sniffing" position optimally aligns the pharynx, larynx, and trachea (A and B). A right-handed surgeon protects the teeth with the left thumb in the mouth and inserts the scope into the right side of the mouth (when inserting the ventilator sidepiece is oriented upward), advancing to the base of the tongue at the posterior median groove. This is achieved by directing the scope directly down. The proximal end is then slowly brought downward into a more horizontal fashion while carefully protecting the patient's teeth. Elevating the tongue and advancing slowly will bring the epiglottis into view (C and D).

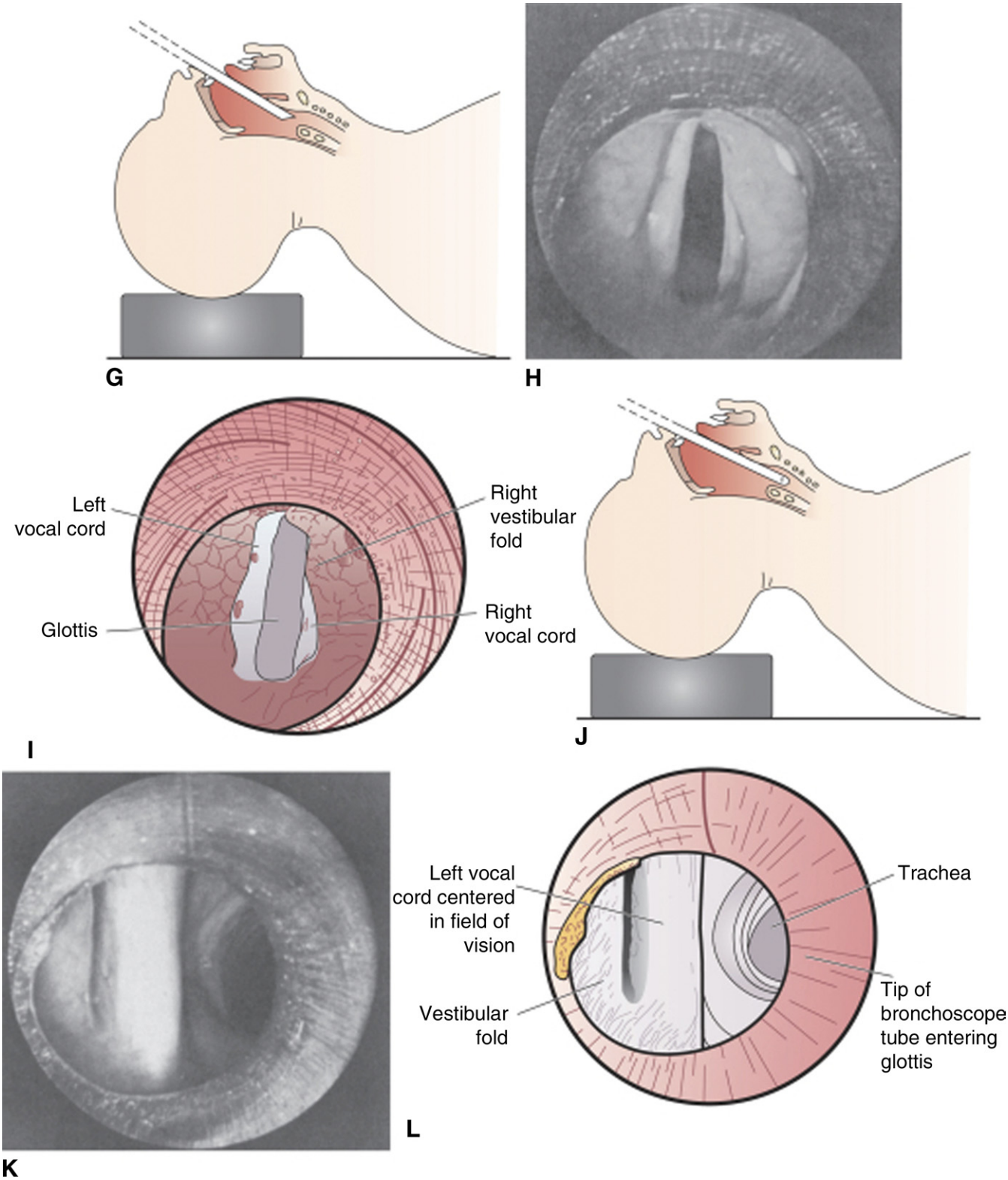

Figure 7 *(Continued)* If the epiglottis is not visualized, the scope should be brought back and advanced slowly again. Proper observation of the epiglottis is the crucial step in proceeding to intubate the cords. The scope is then advanced posteriorly and is used to lift the epiglottis gently, exposing the glottis (E-H). As the cords are approached, the bronchoscope should be rotated 90 degrees so that it traverses the cords with the minimum diameter (J, K, and L). In the picture shown, the scope is rotated 90 degrees clockwise so the left cord is visualized and the distal tip of the scope traverses the glottis and enters the trachea first (I and L). Once the airway is entered, the scope is rotated back to the original orientation. In general, when choosing the size of the scope, the largest scope that is anticipated to traverse the stenosis (if one is present) should be used, without damaging the cords (Adapted with permission from Pierre AF.[5]) (Color version of figure is available online at http://www.optechtcs.com.)

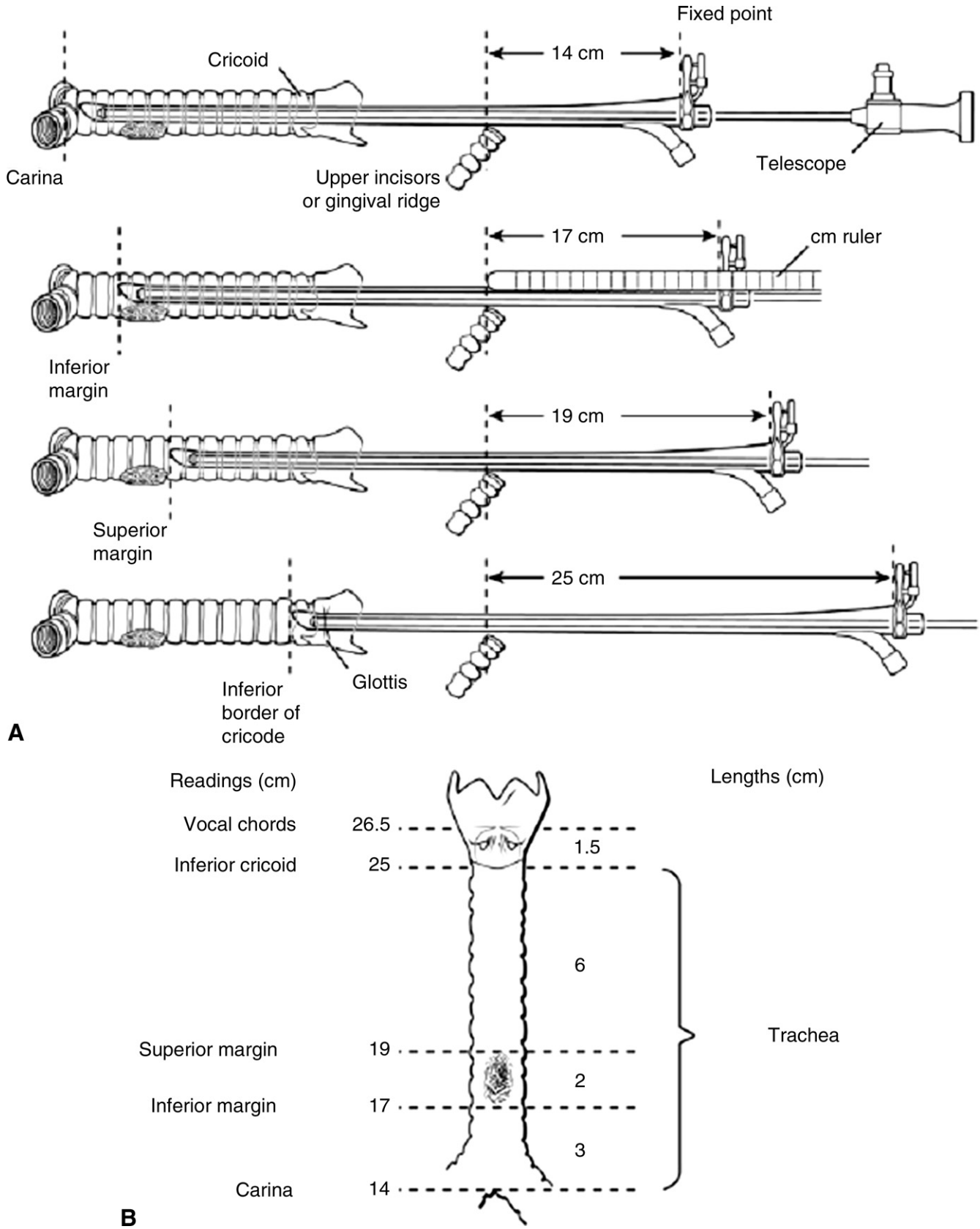

Figure 8 Shown is Dr. Grillo's technique of measuring the location and length of airway pathology. The rigid bronchoscope with telescope inserted almost to the end is used to measure the distance from the carina to the inferior margin, superior margin, and inferior border of the cricoids (A). This is done by starting distally and moving proximally. A ruler measures a *proximal* fixed point from the bronchoscope to the incisors. This allows the surgeon to draw a schematic with relative distances between the carina and the distal margin of the lesion, the length of the lesion, and between the proximal margin of the lesion and the cricoid cartilage (B). Thus, a tracheal resection can be planned when appropriate. (Adapted with permission from Grillo HC.[6])

lesion is approached and traversed with the tip of the rigid bronchoscope in excellent view. Without undue pressure and with a gentle corkscrew motion, the scope is advanced beyond the lesion. This should not be done blindly or with excessive force. The patient is effectively ventilated and, when the anesthesiologist is ready, the scope is removed and the next larger one is selected. Bleeding is often easily controlled with pressure from an advanced bronchoscope. If one does not have pediatric rigid scopes available, we recommend the use of esophageal bougies used with a standard adult rigid scope. With the distal end of the bronchoscope placed above a tight lesion, the bougie is then placed across the stenotic lesion (Fig. 9). Serially enlarging bougies can be used to dilate this stricture until an adult bronchoscope can be passed through the stenosis. Of note, the length of the entire bougie should not be passed beyond the stenosis to minimize trauma to the distal airway. Tumors can always be bypassed on the contralateral side from which the tumor is adherent. Circumferential tumors can be passed through the middle. These systematic techniques require careful up-sizing of the rigid bronchoscope.

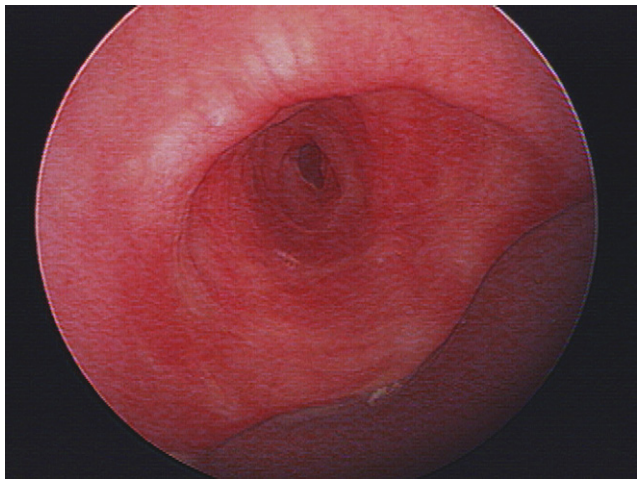

Figure 9 Typical circumferential postintubation stenosis. This lesion was initially dilated with an esophageal bougie to accommodate an adult rigid bronchoscope. The measurements listed in Figure 8 can then be used to plan a resection. (Color version of figure is available online at http://www.optechtcs.com.)

Conclusions

Although there are some limitations to performing rigid bronchoscopy, such as the requirement of general anesthesia and an experienced operator, it is an invaluable skill to the thoracic surgeon. One must focus on the task at hand and avoid excessive force when manipulating these rigid instruments. We believe that a surgeon must perform at least 25 of these procedures to obtain the proper level of experience. The familiarity of the operating room team with the necessary equipment and safe anesthetic technique is a prerequisite for safely addressing central airway pathology. The procedural plan should be rehearsed thoroughly and discussed between all staff members so that each is aware of their crucial role. It is through these steps that the pitfalls associated with this procedure can be avoided, because when they are not, the often fatal complications encountered with rigid bronchoscopy are seen. Cardiothoracic surgery training programs should ensure that their graduates have had thorough education and exposure to the art of rigid bronchoscopy.

References

1. Zollner F: Gustav Killian: Father of bronchoscopy. Arch Otlaryngol 82: 686-659, 1965
2. Boyd AD: Chevalier Jackson: The father of American bronchoesophagoscopy. Ann Thorac Surg 57:502-505, 1994
3. Bolliger CT, Mathur PN: Interventional Bronchoscopy. Basel, Switzerland: S Karger Publishers, 1999
4. Ernst A, Silvestri GA, Johnstone D, et al: Interventional pulmonary procedures: Guidelines from the American College of Chest Physicians. Chest 123:1693-1717, 2003
5. Pierre AF: Bronchoscopy, Chapter 7, in Pearson's Thoracic and Esophageal Surgery ed 2. Philadelphia, PA, Churchill Livingstone, 2008, pp 89-101
6. Grillo HC: Diagnostic endoscopy, in Surgery of the Trachea and Bronchi. Hamilton Ontario, BC Decker, 1994, pp 161-172